Acta

Scandina

50 years
1930/1980
Anniversary
Issue

NKSGAARD, Copenhag

ACTA ORTHOPAEDICA SCANDINAVICA

is the official publication of the Scandinavian Orthopaedic Association

Acta Orthopaedica Scandinavica publishes original papers on orthopaedic surgery including traumatology Authors are also invited to publish follow-up notes and comments. Papers previously published in other periodicals are not accepted

Editorial Correspondence Manuscripts should be addressed to the Editor No part of this journal may be reproduced by any process without written permission from the author(s) and the editor

Business communications, including subscriptions and orders for offprints or advertisements, should be sent to the publishers *Munksgaard*, International Booksellers and Publishers Ltd, 35 Nörre Sogade, DK-1370 Copenhagen K, Denmark

Acta Orthopaedica Scandinavica is published bimonthly The subscription price per volume of six issues is at present Danish kroner 300 00 plus postage D.kr 60 00 (US $68 40, £32.40, DM118 80) payable in advance Prices are subject to exchange rate fluctuation

INSTRUCTIONS TO CONTRIBUTORS

It is expected that any manuscript submitted represents unpublished original work that is not being considered for publication elsewhere.

The paper should be written in English. The title, which is not to exceed 12 words should be chosen with great care Most of the indexing and abstracting services depend on the accuracy of titles. The manuscript must be typewritten on one side of the paper only (quarto), with wide margins and be double spaced The first page should contain, on separate lines, the title of the article and the authors' names and institutions If the title is longer than 45 letters and spaces a short title, containing the essence of the article and not exceeding this limit, will be required for use in the running head The last page should include the full postal address of the author to whom communications and proofs are to be sent and from whom reprints are to be requested

The manuscript including tables and figures should if possible be sent in duplicate to facilitate rapid refereeing, and the author should retain a further copy for own use No roman numerals should be used in the [illegible] In decimal fractions a full stop, and not a comma, [illegible] be used The % sign should be replaced in the tex[t by] "per cent" The minus sign should be shown as –

All papers will be read and corrected for languag[e in] the editorial office Manuscripts produced in [illegible] English will be returned for revision

Articles should not exceed 16 printed pa[ges] Additional pages must be paid for by the authors [at a] rate of 400 Danish kroner per page Articles of [more] than 20 pages are not accepted

Papers should normally be divided into the follow[ing] sections

Abstract The purposes of the abstract are to c[on]venience the readers of the journal and to expedite [the] work of the abstracting journals. The opening sente[nce]

(Cont cover pag[e])

Second-class postage paid at Jamaica, N Y Airfreight and mailing in the U S by Publications Expediting I[nc] Elmont N Y 11003 Printed in Great Britain by The Whitefriars Press Ltd, London and Tonbridge

Acta Orthopaedica Scandinavica

Volume 51

ACTA ORTHOPAEDICA SCANDINAVICA

INDEX

Vol 51, Fasc 1, February 1980

ACTA ORTHOPAEDICA SCANDINAVICA

INDEX

Vol 51, Fasc 1, February 1980

should indicate the subjects of the investigation. The abstract should comprise a brief and factual summary of the contents and conclusions of the paper, a pointer to any new information which it may contain, and an indication of its relevance

It should be presumed that the reader has some knowledge of the subject but has not read the paper The abstract should therefore be intelligible in itself without reference to the paper It should only in exceptional cases exceed 200 words.

Key words 4–9 key words for indexing should be given by the author(s) together with the abstract. They should be placed in alphabetical order and be in accordance with the Annual Bibliography of Orthopaedic Surgery (*J Bone Jt Surg* Boston, Mass., U S.A.).

Introduction. This should be a brief outline of the nature of the problem with particular emphasis on the state of knowledge at the start of the investigation, followed by a short description of the investigation itself and an outline of the reasons for publication.

Patients and Methods/Materials and Methods For clinical work dealing with patients the first heading will be preferred. The second is used in articles dealing with laboratory work or animal experiments.

Results This part of the paper provides a description of the results obtained (but neither a discussion nor a review of the literature). Double documentation in text and tables should be avoided.

Discussion The author is recommended to discuss, and not just recapitulate, the results, giving particular emphasis to unsettled and controversial points and pointing to some conclusion No new findings should appear in this section

Conclusion. In most articles a brief section summarizing the conclusions of the work is appropriate

Acknowledgements If applicable

References References should be mentioned in the text by name of author(s) and year of publication. Citations in the text should appear as Smith & Jones (1960) or (Smith & Jones 1960) When there are three or more authors, cite their paper as Doye et al (1960) All authors cited, and only these, must be listed at the end of the paper in alphabetical order according to the name of the first author

Examples

Lazcano, M A., Anzel, S H & Kelly, P J (1961) Complete dislocation and subluxation of the acromioclavicular joint *J Bone Jt Surg* 43-A, 379–391

Watson-Jones, R (1955) *Fractures and joint injuries* Vol. 2, 4th ed. pp 464–468 E and S Livingstone Ltd., Edinburgh

Illustrations All illustrations are to be considered as figures, and each graph drawing or photograph must be numbered in sequence with arabic numerals. When a figure has several parts e g a b c this should be clearly indicated on the figure itself The approximate location of the figure in the text should be indicated by a circled marginal note Legends to illustrations should be listed on a separate sheet, identified with the name of the journal the authors names, and the figure number Lettering should be stencilled in black India ink in capitals and lar[ge] enough for the necessary reduction. *Line drawings* shou[ld] be drawn with black India ink on white paper In order f[or] line drawings to be reasonably consistent within th[e] journal *they should be double their intended finished s[ize]* and as such their width should be one of the thr[ee] following standard sizes 135 mm for single colum[n] width, 200 mm for 1½ column width, 280 mm for doub[le] column width. Lettering on the figures should be 3 to 4 mm high Helvetica Leight, 14°, obtainable as transf[er] letters, is recommended *Graphs* may be plotted on pla[in] white or blue squared paper, grid lines that are to show i[n] the engraving should be inked in black

Photographic reproductions must be prepared so as t[o] fit the columns of the journal Most illustrations can b[e] properly shown within the width of one column (6.7 cm). *Micrographs* should be planned so that they can b[e] produced without reduction

[illegible]

with figure number, authors' names, and if desirable, the magnification of the print

Colour illustrations are expensive and will b[e] considered only when it is important to illustrate [a] particular feature that cannot be made clear by othe[r] techniques. Original transparencies (not smaller tha[n] 35 mm) as well as three sets of colour prints should b[e] submitted

Tables Tables should be used only when necessary t[o] clarify important points and elaborate tables should b[e] avoided They should be numbered consecutively [in] arabic numerals. Each table should be typed on [a] separate sheet. So far as possible sufficient descriptio[n] should be included in the titles to make tables sel[f-]explanatory

Abbreviations and Symbols Only abbreviations an[d] symbols that have been generally accepted should b[e] used Unfamiliar abbreviations must be defined whe[n] first used

Proofs First proofs will be sent to the author The[y] should be returned with the least possible delay Author[s] will be required to pay for any major alterations to thei[r] original manuscript

[illegible] of each artic[le] ... Addition[al] ... rint orde[r]

Supplements An article or a series of articles exceeding a total of 16 printed pages may be accepte[d] for publication as a supplement. This applies to paper[s] which have received national or international academi[c] ... The acceptance ... acceptance ... ral revision ... Authors are requested as soon as possible to contact the publisher who will provide the necessary information concerning number of copies to be printed, text on cover and title page, size etc.

Ed[itor]

ACTA ORTHOPAEDICA SCANDINAVICA

INDEX

Vol 51, Fasc. 3, June 1980

should indicate the subjects of the investigation The abstract should comprise a brief and factual summary of the contents and conclusions of the paper, a pointer to any new information which it may contain, and an indication of its relevance

It should be presumed that the reader has some knowledge of the subject but has not read the paper The abstract should therefore be intelligible in itself without reference to the paper It should only in exceptional cases exceed 200 words.

Key words 4–9 key words for indexing should be given by the author(s) together with the abstract They should be placed in alphabetical order and be in accordance with the Annual Bibliography of Orthopaedic Surgery (*J Bone Jt Surg* Boston Mass., U S A).

Introduction This should be a brief outline of the nature of the problem with particular emphasis on the state of knowledge at the start of the investigation, followed by a short description of the investigation itself and an outline of the reasons for publication

Patients and Methods/Materials and Methods For clinical work dealing with patients the first heading will be preferred The second is used in articles dealing with laboratory work or animal experiments.

Results This part of the paper provides a description of the results obtained (but neither a discussion nor a review of the literature) Double documentation in text and tables should be avoided

Discussion. The author is recommended to discuss, and not just recapitulate, the results, giving particular emphasis to unsettled and controversial points and pointing to some conclusion No new findings should appear in this section

Conclusion In most articles a brief section summarizing the conclusions of the work is appropriate

Acknowledgements If applicable

[illegible] References should be mentioned in the text [illegible] of author(s) and year of publication Citations in [illegible] should appear as Smith & Jones (1960) or (Smith [illegible]ones 1960) When there are three or more authors, [illegible]te their paper as Doye et al. (1960). All authors cited, and only these, must be listed at the end of the paper in alphabetical order according to the name of the first author

Examples

Lazcano, M A, Anzel, S H & Kelly, P J (1961) Complete dislocation and subluxation of the acromioclavicular joint *J Bone Jt Surg* 43-A, 379–391

[illegible]atson-Jones, R (1955) *Fractures and joint injuries* Vol 2, 4th ed. pp 464–468 E and S Livingstone Ltd., Edinburgh.

Illustrations All illustrations are to be considered as [illegible]igures, and each graph drawing or photograph must be [illegible]umbered in sequence with arabic numerals. When a [illegible]igure has several parts e g a b c this should be clearly indicated on the figure itself The approximate location of the figure in the text should be indicated by a circled marginal note Legends to illustrations should be listed on a separate sheet, identified with the name of the journal the authors' names, and the figure number Lettering should be stencilled in black India ink in capitals and large [illegible]

and as such their width should be one of the three following standard sizes 135 mm for single column width, 200 mm for 1½ column width, 280 mm for double column width Lettering on the figures should be 3 8 to 4 mm high Helvetica Leight, 14°, obtainable as transfer letters, is recommended *Graphs* may be plotted on plain white or blue squared paper, grid lines that are to show in the engraving should be inked in black

Photographic reproductions must be prepared so as to fit the columns of the journal Most illustrations can be properly shown within the width of one column (6 7 cm) *Micrographs* should be planned so that they can be produced without reduction

Photographs must be submitted as unmounted glossy enlargements showing good detail and contrast Pictures or X-ray photos should be cut to present only what is essential Indicate 'up' and 'down' Mark each photograph with figure number, authors' names, and, if desirable the magnification of the print

Colour illustrations are expensive and will be considered only when it is important to illustrate a particular feature that cannot be made clear by other techniques. Original transparencies (not smaller than 35 mm) as well as three sets of colour prints should be submitted

Tables Tables should be used only when necessary to clarify important points and elaborate tables should be avoided They should be numbered consecutively in arabic numerals. Each table should be typed on a separate sheet So far as possible sufficient description should be included in the titles to make tables self explanatory

Abbreviations and Symbols Only abbreviations and symbols that have been generally accepted should be used Unfamiliar abbreviations must be defined when first used

Proofs First proofs will be sent to the author They should be returned with the least possible delay Authors will be required to pay for any major alterations to their original manuscript

[illegible] of each article [illegible] dditional [illegible] nt order [illegible]

Supplements An article, or a series of articles, exceeding a total of 16 printed pages may be accepted for publication as a supplement This applies to papers which have received national or international academic recognition (e g doctoral thesis award) The acceptance is dependent on the editor's approval. After acceptance, the supplements are not subject to editorial revision. The full cost is paid by the author(s) Authors are requested as soon as possible to contact the publishers who will provide the necessary information concerning number of copies to be printed, text on cover and title page, size etc.

Editor

ACTA ORTHOPAEDICA SCANDINAVICA

INDEX

Vol 51, Fasc 4, August 1980

should indicate the subjects of the investigation. The abstract should comprise a brief and factual summary of the contents and conclusions of the paper, a pointer to any new information which it may contain, and an indication of its relevance.

It should be presumed that the reader has some knowledge of the subject but has not read the paper The abstract should therefore be intelligible in itself without reference to the paper It should only in exceptional cases exceed 200 words.

Key words 4–9 key words for indexing should be given by the author(s) together with the abstract. They should be placed in alphabetical order and be in accordance with the Annual Bibliography of Orthopaedic Surgery (*J Bone Jt Surg* Boston, Mass., U S.A.).

Introduction This should be a brief outline of the nature of the problem with particular emphasis on the state of knowledge at the start of the investigation, followed by a short description of the investigation itself and an outline of the reasons for publication.

Patients and Methods/Materials and Methods For clinical work dealing with patients the first heading will be preferred The second is used in articles dealing with laboratory work or animal experiments.

Results This part of the paper provides a description of the results obtained (but neither a discussion nor a review of the literature). Double documentation in text and tables should be avoided.

Discussion. The author is recommended to discuss, and not just recapitulate, the results, giving particular emphasis to unsettled and controversial points and pointing to some conclusion. No new findings should appear in this section

Conclusion. In most articles a brief section summarizing the conclusions of the work is appropriate

Acknowledgements. If applicable

[illegible]

& Jones 1960) When there are three or more authors, cite their paper as Doye et al. (1960) All authors cited, and only these, must be listed at the end of the paper in alphabetical order according to the name of the first author

Examples

Larcano, M. A., Anzel, S H & Kelly, P J (1961) Complete dislocation and subluxation of the acromioclavicular joint *J Bone Jt Surg* 43-A, 379–391

Watson-Jones, R. (1955) *Fractures and joint injuries* Vol. 2, 4th ed. pp 464–468 E and S Livingstone Ltd., Edinburgh.

Illustrations All illustrations are to be considered as

[illegible]

the authors' names, and the figure number Lettering should be stencilled in black India ink enough for the necessary reduction. *Line drawn* be drawn with black India ink on white paper line drawings to be reasonably consistent journal, they should be double their intended and as such their width should be one of following standard sizes 135 mm for singl width, 200 mm for 1½ column width, column width. Lettering on the figures should 4 mm high Helvetica Leight, 14°, obtainabl letters, is recommended *Graphs* may white or blue squared paper, grid li the engraving should be inked in black.

Photographic reproductions must be prepared fit the columns of the journal. Most illu properly shown within the width of one column *Micrographs* should be planned so that they produced without reduction.

Photographs must be submitted as unmount enlargements showing good detail and contrast. or X-ray photos should be cut to present only wl sential Indicate 'up' and 'down' Mark each ph with figure number, authors' names, and, if desi magnification of the print.

Colour illustrations are expensive and considered only when it is important to illu particular feature that cannot be made clear l techniques. Original transparencies (not smal 35 mm) as well as three sets of colour prints s submitted

Tables Tables should be used only when nec clarify important points and elaborate tables s avoided. They should be numbered consecu arabic numerals. Each table should be typ separate sheet. So far as possible sufficient de should be included in the titles to make tal explanatory

Abbreviations and Symbols Only abbreviati symbols that have been generally accepted sh used. Unfamiliar abbreviations must be define first used

Proofs First proofs will be sent to the autho should be returned with the least possible delay will be required to pay for any major alterations original manuscript.

[illegible] of eac rge. A offpri

Supplements An article, or a series of exceeding a total of 16 printed pages may be for publication as a supplement. This applies to which have received national or international recognition (e.g doctoral thesis, award). The acc is dependent on the editor's approval. After acc the supplements are not subject to editorial The full cost is paid by the author(s). Auth requested as soon as possible to contact the pu who will provide the necessary information con number of copies to be printed, text on cover page, size etc.

ACTA ORTHOPAEDICA SCANDINAVICA

INDEX

Vol 51, Fasc. 6, December 1980

should indicate the subjects of the investigation The abstract should comprise a brief and factual summary of the contents and conclusions of the paper a pointer to any new information which it may contain, and an indication of its relevance

It should be presumed that the reader has some knowledge of the subject but has not read the paper The abstract should therefore be intelligible in itself without reference to the paper It should only in exceptional cases exceed 200 words.

Key words 4–9 key words for indexing should be given by the author(s) together with the abstract They should be placed in alphabetical order and be in accordance with the Annual Bibliography of Orthopaedic Surgery (*J Bone Jt Surg* Boston Mass , U S A)

Introduction This should be a brief outline of the nature of the problem with particular emphasis on the state of knowledge at the start of the investigation followed by a short description of the investigation itself and an outline of the reasons for publication

Patients and Methods/Materials and Methods For clinical work dealing with patients the first heading will be preferred The second is used in articles dealing with laboratory work or animal experiments.

Results This part of the paper provides a description of the results obtained (but neither a discussion nor a review of the literature) Double documentation in text and tables should be avoided

Discussion The author is recommended to discuss, and not just recapitulate the results, giving particular emphasis to unsettled and controversial points and pointing to some conclusion No new findings should appear in this section

Conclusion In most articles a brief section summarizing the conclusions of the work is appropriate

Acknowledgements If applicable

References References should be mentioned in the text by name of author(s) and year of publication Citations in the text should appear as Smith & Jones (1960) or (Smith & Jones 1960) When there are three or more authors, cite their paper as Doye et al (1960) All authors cited and only these must be listed at the end of the paper in alphabetical order according to the name of the first author

Examples

Lazcano M A Anzel S H & Kelly P J (1961) Complete dislocation and subluxation of the acromioclavicular joint *J Bone Jt Surg* **43-A,** 379 391

Watson Jones, R (1955) *Fractures and joint injuries* Vol. 2 4th ed pp 464–468 E and S Livingstone Ltd. Edinburgh.

Illustrations All illustrations are to be considered as figures and each graph drawing or photograph must be numbered in sequence with arabic numerals When a figure has several parts e g a b c this should be clearly indicated on the figure itself The approximate location of the figure in the text should be indicated by a circled marginal note Legends to illustrations should be listed on a separate sheet identified with the name of the journal the authors names, and the figure number Lettering should be stencilled in black India ink in capitals and [illegible] enough for the necessary reduction *Line drawings* [illegible] be drawn with black India ink on white paper In ord[illegible] line drawings to be reasonably consistent with[illegible] journal they should be double their intended fin[illegible] and as such their width should be one of the following standard sizes 135 mm for single width 200 mm for 1½ column width 280 mm for d[illegible] column width Lettering on the figures should be 3[illegible] 4 mm high Helvetica Leight 14° obtainable as tra[illegible] letters, is recommended *Graphs* may be plotted on [illegible] white or blue squared paper grid lines that are to sho[illegible] the engraving should be inked in black

Photographic reproductions must be prepared so [illegible] fit the columns of the journal Most illustrations ca[illegible] properly shown within the width of one column (8[illegible] *Micrographs* should be planned so that they can [illegible] produced without reduction

Photographs must be submitted as unmounted gl[illegible] enlargements showing good detail and contrast [illegible] or X-ray photos should be cut to present only wha[illegible] sential Indicate up and down Mark each photogr[illegible] with figure number authors names, and if desirable [illegible] magnification of the print

Colour illustrations are expensive and will [illegible] considered only when it is important to illustr[illegible] particular feature that cannot be made clear by ot[illegible] techniques. Original transparencies (not smaller t[illegible] 35 mm) as well as three sets of colour prints shou[illegible] submitted

Tables Tables should be used only when necessar[illegible] clarify important points and elaborate tables shou[illegible] avoided They should be numbered consecutiv[illegible] arabic numerals. Each table should be typed o[illegible] separate sheet So far as possible sufficient descr[illegible] should be included in the titles to make tables [illegible] explanatory

Abbreviations and Symbols Only abbreviations [illegible] symbols that have been generally accepted shoul[illegible] used Unfamiliar abbreviations must be defined [illegible] first used

Proofs First proofs will be sent to the author [illegible] should be returned with the least possible delay Aut[illegible] will be required to pay for any major alterations to [illegible] original manuscript

Offprints Fifty offprints, without covers, of each [illegible] will be supplied to the authors free of charge. Add[illegible] offprints can be supplied if ordered on the offpr[illegible] form which will accompany the proofs.

Supplements An article, or a series of [illegible] exceeding a total of 16 printed pages may be ac[illegible] for publication as a supplement This applies to [illegible] which have received national or international recognition (e g doctoral thesis award). The s[illegible] is dependent on the editor's approval. After accep[illegible] the supplements are not subject to editorial re[illegible] The full cost is paid by the author(s). Author[illegible] requested as soon as possible to contact the [illegible] who will provide the necessary information [illegible] number of copies to be printed, text on cover [illegible] page size etc.

YEARS OF SERVICE – A review by the Editor

With the publication of Volume 51 Acta Orthopaedica Scandinavica celebrates its fiftieth anniversary, the first issue having been launched in 1930 Despite its fifty years the journal is still a newcomer in comparison with the age of the art and science of our speciality

The Scandinavian orthopaedic service has since its inception in the nineteenth century been closely linked with the care of disabled persons and the management of bone and joint tuberculosis. Our speciality owes a great deal to the pioneers in the twenties who envisioned the future development of orthopaedic practice and research

The foremost initiators and founders of the journal were Patrik Haglund and P G K. Bentzon who realized the need for an independent channel of communication separate from that of general surgery The journal was founded in January 1930 at a meeting of eleven leading Scandinavian orthopaedists, "the great elephants", and all those present invested financially in the new venture Patrik Haglund was elected Editor, P G K. Bentzon "redigenda curavit", managing editor, and an editorial committee consisting of two representatives from each of the four countries was formed After the death of Patrik Haglund in 1937, P G K Bentzon became the sole editor and continued progress was made under his guidance

In 1947 Sten Friberg became editor and Sven Kiaer redigenda curavit, followed in 1948 by J Agerholm Christensen In 1950 Sophus von Rosen was elected redigenda curavit and he managed the journal throughout a period of flourishing development until his seventieth year

Over the years the editorial and administrative structure was amended in accordance with developments. In the forties Acta came up against serious economic problems and after the financial state had been improved and stabilized the journal was adopted as the official publication of the Scandinavian Orthopaedic Association.

In 1971 the editorial structure was modified and its present form established. Acta is managed by an editor, an associate editor and a Scandinavian editorial board, which in 1978 was joined by an Icelandic member The chairman of the board from 1970–1978 was Anders Langenskiöld and at the present time the chairman is Magnor Foss Hauge The editors are supported by an editorial committee attended by specialist referees from the five participating nations.

From the beginning Acta has been published in close cooperation with Munksgaard International Publishers Ltd. At first articles were accepted in three languages, English, French and German, but since 1970 the official language has been English.

The volume of material for publication and the increasing costs led in 1976 to the change from single to double column typography and in 1978 from letterpress to offset printing In addition to the regular journal issues Acta has

01–6470/80/010001–03$02.50 0

should indicate the subjects of the investigation The abstract should comprise a brief and factual summary of the contents and conclusions of the paper a pointer to any new information which it may contain and an indication of its relevance

It should be presumed that the reader has some knowledge of the subject but has not read the paper The abstract should therefore be intelligible in itself without reference to the paper It should only in exceptional cases *exceed 200 words*

Key words 4–9 key words for indexing should be given by the author(s) together with the abstract. They should be placed in alphabetical order and be in accordance with the Annual Bibliography of Orthopaedic Surgery (*J Bone Jt Surg* Boston Mass. U S A)

Introduction This should be a brief outline of the nature of the problem with particular emphasis on the state of knowledge at the start of the investigation followed by a short description of the investigation itself and an outline of the reasons for publication

Patients and Methods/Materials and Methods For clinical work dealing with patients the first heading will be preferred The second is used in articles dealing with laboratory work or animal experiments.

Results This part of the paper provides a description of the results obtained (but neither a discussion nor a review of the literature) Double documentation in text and tables should be avoided

Discussion The author is recommended to discuss, and not just recapitulate the results giving particular emphasis to unsettled and controversial points and pointing to some conclusion No new findings should appear in this section

Conclusion. In most articles a brief section summarizing conclusions of the work is appropriate

Acknowledgements If applicable

References References should be mentioned in the text by name of author(s) and year of publication Citations in the text should appear as Smith & Jones (1960) or (Smith & Jones 1960) When there are three or more authors, cite their paper as Doye et al (1960) All authors cited and only these must be listed at the end of the paper in alphabetical order according to the name of the first author

Examples

Lazcano M A Anzel S H & Kelly P J (1961) Complete dislocation and subluxation of the acromioclavicular joint *J Bone Jt Surg* **43-A**, 379–391

Watson Jones R (1955) *Fractures and joint injuries* Vol 2, 4th ed pp 464–468 E and S Livingstone Ltd Edinburgh.

Illustrations All illustrations are to be considered as figures and each graph drawing or photograph must be numbered in sequence with arabic numerals. When a figure has several parts e g a b c this should be clearly indicated on the figure itself The approximate location of the figure in the text should be indicated by a circled marginal note Legends to illustrations should be listed on *a separate sheet* identified with the name of the journal the authors names, and the figure number Lettering should be stencilled in black India ink in capitals and l[...] enough for the necessary reduction *Line drawings sh[...]* be drawn with black India ink on white paper In orde[...] line drawings to be reasonably consistent within [...] journal they should be double their intended fin shed [...] and as such their width should be one of the [...] following standard sizes 135 mm for single col[...] width 200 mm for 1½ column width 280 mm for do[...] column width Lettering on the figures should be [...] 4 mm high Helvetica Leight 14° obtainable as tra[...] letters is recommended *Graphs* may be plotted on p[...] white or blue squared paper grid lines that are to show [...] the engraving should be inked in black

Photographic reproductions must be prepared so [...] fit the columns of the journal Most illustrations ca[...] properly shown within the width of one column (8 [...] *Micrographs* should be planned so that they can [...] produced without reduction

Photographs must be submitted as unmounted gl[...] *enlargements* showing good detail and contrast Pa[...] or X ray photos should be cut to present only what is e[...]sential Indicate 'up and down Mark each photogr[...] with figure number authors names, and if desirable [...] magnification of the print

Colour illustrations are expensive and will [...] considered only when it is important to illustra[...] particular feature that cannot be made clear by oth[...] techniques. Original transparencies (not smaller th[...] 35 mm) as well as three sets of colour prints shoul[...] submitted

Tables Tables should be used only when necessar[...] clarify important points and elaborate tables should [...] avoided They should be numbered consecutively [...] arabic numerals. Each table should be typed o[...] separate sheet So far as possible sufficient descrip[...] should be included in the titles to make tables s[...] explanatory

Abbreviations and Symbols Only abbreviations [...] symbols that have been generally accepted should [...] used Unfamiliar abbreviations must be defined w[...] first used

Proofs First proofs will be sent to the author Th[...] should be returned with the least possible delay Autho[...] will be required to pay for any major alterations to the [...] original manuscript

Offprints Fifty offprints, without covers, of each art[...] will be supplied to the authors free of charge Addi[...] offprints can be supplied if ordered on the offprint or[...] form which will accompany the proofs.

Supplements An article or a series of artic[...] exceeding a total of 16 printed pages may be accep[...] for publication as a supplement This applies to pap[...] which have received national or international acade[...] recognition (e g doctoral thesis award). The accepta[...] is dependent on the editor s approval. After accepta[...] the supplements are not subject to editorial revis[...] The full cost is paid by the author(s). Authors ar[...] requested as soon as possible to contact the publisher [...] who will provide the necessary information concern[...] number of copies to be printed text on cover and t[...] page size etc.

In the jubilee year a multitude of questions remain unanswered and several areas of research are still untouched or have only recently begun to be explored. The field of surgical implants is still in a phase of investigation. The answer, if there is one, is still unknown. Only thorough studies combining biomechanical, physiological, technological and clinical considerations may provide that answer.

Whereas clinical studies in the past were mostly based on follow-up results, the future may offer even more reliable prospective studies – of course in accordance with the Helsinki II declaration.

It may be discussed whether or not cost-benefit studies are true science or research. Nevertheless, the limitation of the resources available to the health sector in the future will certainly also force orthopaedic surgeons to perform investigations with this aim, in order to define gains, losses and finally priorities. The ever growing geriatric section of the population is in focus in this respect.

The editorial board firmly believes that endeavours in the future will provide the answers to the multitude of questions still open and Acta will constantly aim to serve its readers with reliable guidance and true enrichment.

Knud Jansen

published separate supplements now totalling 180 in number. The supplements have been reserved primarily for academic studies and special topics.

The capacity of the journal has been growing steadily but this has been more than matched by the inflow of contributions. The policy has been to screen the papers more critically, rather than just expand the volumes, with the aim of securing a high scientific standard. In its fifty-year history the volumes of Acta have grown from 364 single column pages in 1930 to 808 double column pages in 1979 (corresponding to 1150 pages in the previous format).

The journal has had the pleasure of extending its boundaries and gaining increasing attention from readers and authors in Europe, USA, Japan and the Third World. In particular the group of subscribers in the USA and Japan is large and still growing. The total number of subscribers in 1939 was approximately 400 and today that number has increased tenfold.

The contents of the fifty volumes and the 180 supplements reflect the changing problems over the years and outline the trends in research and development both in Scandinavia and internationally. In the early period the problems related to "classic orthopaedics" predominated. Surgical tuberculosis, congenital dislocation of the hip, other congenital deformities and the aftermath of polio were the subjects in focus. With the eradication of polio with vaccination and the almost complete elimination of C.D.H. with early diagnosis and "preventive treatment" the picture changed greatly. Palliative and reconstructive treatment of acquired diseases became the topics of discussion. In the treatment of osteoarthritis: arthrodesis, hemialloplasty, osteotomy and recently total joint replacement have been introduced after encouraging follow-up studies. More recently the trends show an increasing interest in controversies and critical long-term studies.

The greatest impact on the image of Acta has been without doubt the inclusion of traumatology in orthopaedic practice and research. The classification and management of fractures and joint lesions, the results of conservative treatment and the various methods of fracture fixation have occupied considerable space in the journal. In both fields, elective orthopaedics and traumatology, recent trends indicate a growing awareness of the risks of treatment and a greater interest in long-term findings. Interest is also growing in the area of basic and experimental investigation. In this context, new tools and new procedures have opened up gates to new knowledge – scintigraphy, histochemistry, electronmicroscopy, and equipment for biomechanical research.

This is the state of affairs in 1980.

The present situation is the result of fruitful activity and the co-operation of several forces. Our predecessors on the board of Acta deserve our respect. Our collaborators and in particular our consultants deserve a word of gratitude for their qualified and faithful service with the aim of maintaining and raising the scientific level of the journal. We would also like to thank our contributors from all parts of the world for submitting their reports. They have provided a global picture of orthopaedic research – and the editor sincerely regrets that some articles even after revision must be rejected.

The advertising pages of the journal are an interesting section of Acta. We wish to thank the participating suppliers – also for their understanding of the limitations we feel are essential in the production of a scientific journal.

scand. 51 5–8 1980

ĸACTURE HEALING

Concept of Competing Healing Factors

HULTH

ɿepartment of Orthopaedic Surgery, Malmö General Hospital,
Jniversity of Lund), Malmö, Sweden

In the discussion concerning the theory of the healing of shaft fractures the demand for absolute stability of the fracture has been a dominating factor This cannot be an absolute prerequisite because fractures of the tibia or femur heal well even with continued weight-bearing and movement. The ingrowth of vessels is apparently not a crucial factor It is evident, however, that fractures caused by direct violence with soft tissue damage heal more slowly than fractures caused by indirect violence, irrespective of the treatment. Soft tissue heals with fibrous scar, fractures heal by bone regeneration. The author postulates that the damaged tissue stimulates (possibly via molecular determinants) the structural genes of undifferentiated cells to produce mRNA and proteins for either fibrous tissue or bone formation. The rate of healing of the fracture is determined by the degree of bone damage in relation to soft tissue damage In fractures with extensive soft tissue injury there occurs a competitive condition in the common haematoma, with a risk of delayed fracture healing due to the dominance of cells that are triggered off by fibrous tissue formation.

Key words bone healing, bone trauma, callus, fractures, fracture blastema, osteogenesis, osteosynthesis, soft tissue trauma, tibia fractures

Accepted 22.iv 79

'he methods of managing shaft fractures, articularly fractures of the tibial shaft, differ gnificantly The methods are so divergent ıat one is tempted to ask whether the basis f fracture repair is understood. The older enerations of surgeons, cited by Sir Watson-ᴐnes (1952), thought like himself that ability such as that obtained by plaster imıobilization without weight-bearing, was the ıly basis of good fracture healing This ɔinion has deeply influenced our thinking ıd has dominated treatment in the earlier ages. When certain fractures did not heal ell, many fracture surgeons became ɔncerned with methods of still further inᴇasing the stability of the fragments, and, ɔove all, of hindering rotatory forces. The ultimate stage has been the use of the rigid compression plates (A O or A S I F) by Swiss surgeons (Müller 1963).

The principal idea behind the "rigid stability hypothesis" has been the necessity to ensure proper vascularization of the fracture area Representatives of the A.O school claim that micromovements in the fracture cause the development of a fibrocartilaginous substance in the fracture region (Müller 1978) There are, however, shaft fractures which heal very well without any fixation of the fragments, e g femoral fractures in traction or humeral fractures treated with a simple bandage. The prerequisite in these cases seems to be the non-operative management of the fractures. Based on experience

01–6470/80/010005–04$02.50/0

scand. 51, 5–8, 1980

RACTURE HEALING

Concept of Competing Healing Factors

NDERS HULTH

epartment of Orthopaedic Surgery, Malmö General Hospital,
Jniversity of Lund), Malmö, Sweden.

In the discussion concerning the theory of the healing of shaft fractures the demand for absolute stability of the fracture has been a dominating factor This cannot be an absolute prerequisite because fractures of the tibia or femur heal well even with continued weight-bearing and movement. The ingrowth of vessels is apparently not a crucial factor It is evident, however, that fractures caused by direct violence with soft tissue damage heal more slowly than fractures caused by indirect violence, irrespective of the treatment. Soft tissue heals with fibrous scar, fractures heal by bone regeneration The author postulates that the damaged tissue stimulates (possibly via molecular determinants) the structural genes of undifferentiated cells to produce mRNA and proteins for either fibrous tissue or bone formation. The rate of healing of the fracture is determined by the degree of bone damage in relation to soft tissue damage. In fractures with extensive soft tissue injury there occurs a competitive condition in the common haematoma, with a risk of delayed fracture healing due to the dominance of cells that are triggered off by fibrous tissue formation.

Key words bone healing, bone trauma, callus, fractures, fracture blastema, osteogenesis, osteosynthesis, soft tissue trauma, tibia fractures

Accepted 22 iv 79

he methods of managing shaft fractures, articularly fractures of the tibial shaft, differ gnificantly The methods are so divergent iat one is tempted to ask whether the basis fracture repair is understood The older enerations of surgeons, cited by Sir Watson-ines (1952), thought like himself that ability such as that obtained by plaster immobilization without weight-bearing, was the ily basis of good fracture healing This inion has deeply influenced our thinking id has dominated treatment in the earlier ages. When certain fractures did not heal ell, many fracture surgeons became incerned with methods of still further increasing the stability of the fragments, and, ove all, of hindering rotatory forces. The ultimate stage has been the use of the rigid compression plates (A O or A S I F) by Swiss surgeons (Müller 1963).

The principal idea behind the "rigid stability hypothesis" has been the necessity to ensure proper vascularization of the fracture area Representatives of the A.O school claim that micromovements in the fracture cause the development of a fibrocartilaginous substance in the fracture region (Müller 1978) There are, however, shaft fractures which heal very well without any fixation of the fragments, e g femoral fractures in traction or humeral fractures treated with a simple bandage. The prerequisite in these cases seems to be the non-operative management of the fractures. Based on experience

01-6470/80/010005-04$02.50/0

gained over the past 10 years or more many fractures of the tibia heal well when treated with long plasters and immediate weight-bearing (Dehne et al 1961) or even with short braces and early weight-bearing (Sarmiento 1967, 1974) Thus, the categorical statement of Watson-Jones is not correct Many investigations show that in fact the healing of tibia fractures is more related to the manner in which the tibia was broken Fractures caused by direct violence with extensive soft tissue damage take longer to heal than fractures caused by indirect rotatory or bending forces (Edwards 1965, Karlstom & Olerud 1974, Thunold et al 1976) On the basis of the now abundant literature, Austin (1977) concludes that most fractures with a poor outcome belong to the high-energy group, irrespective of the treatment given

If the slower healing of fractures with extensive soft tissue injury is due to a more difficult revascularization of the fragments, the results of open treatment with rigid plates (giving greater opportunity for the ingrowth of vessels), should give better results than conservative methods, but this is not the case (Karlstrom & Olerud 1974, Thunold et al 1976) One can therefore assert that the vessels are not the crucial factor in fractures These vessels grow into the site even when this is exposed to movements. Another factor of greater importance must be involved, and therefore we need another hypothesis

In the following, a hypothesis is presented which is called the concept of *competing healing factors* Firstly, a few basic facts concerning the hypothesis are necessary

1 Most wounds of soft tissue, such as muscles, fasciae and skin, heal by fibrous scars. Fractures of bone behave differently because a regenerate (or blastema), consisting of new bone, is formed during the fracture healing
2. To heal a wound or a fracture, structural genes in the nuclei of poorly differentiated mesenchymal cells must be activated in order to produce the mRNAs and proteins *needed, and these must be of a d*... kind in wound and bone he... respectively The activation of ... structural genes occurs thanks to spe... molecules, probably derived from ... *damaged tissue itself*
3 There is some experimental evidence ... bone formation is not exclus... dependent on specific precursor ... (preosteoblasts), but that other ... differentiated, embryonic type ... perhaps migratory (Trueta 1968, ... et al 1975), might contribute to b... formation Here, we may compare ... (1978) determined osteogenic pre... cells (DOPC) and inducible osteog... precursor cells (IOPC)

The transfer of the specific molecules ... the damaged tissue to the undifferent... cells might occur directly or indirectly ... other cells, e g macrophages/osteocla... There is a hypothesis that young fibrobl... formed during wound healing, receive ... formation from collagen breakdown prod... (Shekter et al 1976) The macrophage ... be required to stimulate fibroblast proli... tion in some as yet unidentified ... (Leibovich & Ross 1975) In the second... osteons, e g. those seen during bone re... ling in primary union of cortical bone ... teoclasts are located at the blind end of ... canal *Behind them are* mesenchymal ... differentiating into osteoblasts (Shen... Willenegger 1963, Olerud & Danckw... Lilliestrom 1971) Do the latter receive ... formation from the osteoclasts? This ques... is justified in the light of the pre... knowledge of the function of the macroph... during antigenic challenge to the body ... the macrophages are able to digest ... process the antigens, presenting this ... as an antigen-RNA complex to ... lymphocytes Thus, the macrophages ... not only a scavenging function but ... perform a delicate molecular-biological ...

The essential factor in the hypothes... not, however, the precise manner by ... information *from* damaged tissue ... transferred but that it occurs and is ...

or the initiation of repair If this is accepted, it is much easier to explain hitherto obscure aspects of fracture healing, which the "stability hypothesis" is unable to do Urist et al (1976) have shown the existence of the so-called BMP or bone morphogenetic polypeptide and this is exactly in line with the present hypothesis

With the new hypothesis it is easy to understand the poorer healing of open fractures compared with closed fractures In fractures with extensive soft tissue injury, competition may arise in the common haematoma between the specific molecules (determinants) for scar formation and bone formation Should the former dominate, the wound-scarring might prevent bone formation thus resulting in non-union On the other hand, fractures with minor soft tissue injury heal more quickly because the undifferentiated cells are stimulated to produce the mRNA (and consequently the proteins) needed solely for bone matrix formation

The greater the injury to the bone tissue in comparison with that of the soft tissue, the more rapid is the healing and *vice versa* Longitudinal fractures of the tibia are good examples of a greater amount of bone than soft tissue damage and therefore these fractures heal rapidly Careful soft tissue dissection at elective surgery, e g osteotomies, creates better healing conditions than rough incisions Yet there is a greater risk of delayed healing of an osteotomy of the proximal tibia than in a closed fracture in the same region. Most operations for non-united fractures introduce new injury to the bone Also, there is often an addition of bone as chips and other grafts or a decortication, constituting the source of the release of bone determinants. On the other hand rough incisions through soft tissue with crushed muscles e g, in the case of plate osteo- of fresh fractures might result in delayed healing because the twice injured soft tissue dominates over the bone damage Due to the anatomical reduction with this method, the bone-forming space becomes limited to the little gap between the fragments the entire external space is certainly dominated and filled up by scar-healing determinants Rigid osteosynthesis becomes imperative in such invasive operations since movements let in abundant fibrous determinants and let out bone determinants The "irritation callus" then occurs In exactly reduced, conservatively treated spiral fractures, where the bone-forming space is fenced in by corticalis, the visible callus is often sparse though strong, owing to the absence of competition from fibrous determinants In some cases, even a soft tissue incision for encircling wires, according to the cerclage method, is enough to result in disturbed healing

Treating shaft fractures of the tibia or femur by weight-bearing plasters or braces causes rubbing of the fracture ends against each other which, in turn, releases bone determinants, whereas the soft tissues are "stabilized" to a sufficient degree Open fractures with necrotic soft tissue debris (e g missile injuries) must be cleansed by debridement, since the debris makes use of the macrophages which might be crucial for the initiation of bone formation Of course a still greater degree of competition occurs after bacterial contamination of the fracture wound The mobilized cell apparatus (macrophages and leucocytes) is the same wherever the body is injured

This hypothesis is based on known molecular-biological facts To heal tissue damage, there must occur a transfer of information via molecular determinants from the damaged tissue to the poorly differentiated cells, the structural genes of which become activated in order to produce mRNA specific for tissue repair Fractures caused by direct violence involve healing of both soft tissue damage and bone damage. In a common haematoma a competition between the two types of determinants occurs. This hypothesis provides another way of viewing fracture healing which makes it no longer merely a carpenter's affair During fracture healing it is essential that a bone-forming blastema is allowed to develop undisturbed as much as possible, by fibrous scar-

formation. The risk of fibrous scar formation occurring is greater in open fractures or in the case of open fracture treatment with large incisions into crushed soft tissue. The risk of scar formation is reduced at elective surgery with anatomically made incisions in intact soft tissue. Generally, closed treatment of fractures is preferable because the chances of the formation of an undisturbed fracture blastema are greater, even with early weight bearing Stability of a fracture is not a *conditio sine qua non*, but might promote bone-healing especially in compound fractures if the stability can be accomplished by non invasive methods, e g transfixation by pins and plaster or by the Hoffman method (or Adrey Vidal).

REFERENCES

Austin, R T (1977) Fractures of the tibial shaft is medical audit possible? *Injury* **9**, 93–95

Dehne, E., Metz, C. W., Deffer P A. & Hall, R. M (1961) Non-operative treatment of the fractured tibia by immediate weight-bearing *J Trauma* **1**, 514–533

——— P (1965) Fracture of the shaft of the tibia 492 consecutive cases in adults. *Acta orthop scand.* Suppl. 76

Karlstrom, G & Olerud, S (1974) Fractures of the tibial shaft. *Clin Orthop* **105**, 82–115

Leibovich, S J & Ross, R. (1975) The role of the macrophage in wound repair *Amer J Path.* **78**, 71–79

Muller M. E. (1963) Internal fixation for fresh fractures and for non-union. *Proc. roy Med* **56**, 455–461

Muller W E. (1978) Bases expérimentale principes de l ostéosynthèses par compres International Orthopedics (SICOT) 115–125

Olerud, S & Danckwardt Lillieström, G (1 Fracture healing in compression osteosynth *Acta orthop scand* Suppl. 137

Owen, M (1978) Histogenesis of bone c *Calcif Tiss Res* **25**, 205–207

Sarmiento A. (1967) A functional below-the-k cast of tibial fractures. *J Bone Jt Surg* 4 855–875

Sarmiento A. (1974) Functional bracing of t fractures. *Clin. Orthop* **105**, 202 219

Schenk, R. & Willenegger H (1963) Z histologischen Bild der sogenan Primarheilung der Knochenkompakta nach perimentellen Osteotomien am Hund. *E perientia (Basel)* **19**, 593–601

Shekhter A. B., Berchenko G N & Nikolaev V (1976) Macrophage-fibroblast interac and its possible role in the regulation collagen metabolism during wound heal *Byull éksp Biol Med.* **83**, 627–630

Thunold, J., Varhaug J E. & Bjerkeset, T (19 Tibial shaft fractures treated by rigid inter fixation *Injury* **7**, 125–131

Trueta, J (1968) *Studies of the development a decay of the human frame* William Heinem London.

Uhthoff H K., Ferland, M. A. & Coté, M. (1975) A possible contribution of differentiated cells to post-traumatic teogenesis. *Rev Can. Biol.* **34**, 11–22

Urist, M. R., Nogami, H & Mikulski, A. (19 bone morphogenetic polypeptide. *Calcif Ti Res* (Suppl.) **21**, 81–85

Watson Jones, R (1952) *Fractures and j injuries* Vol. 1 4th ed. E. and S Livingsto Ltd. Edinburgh and London.

Correspondence to Anders Hulth, Department of Orthopaedic Surgery Malmo General Hospital (University of Lund) S-21401 Malmö Sweden.

Acta orthop. scand. 51, 9–17, 1980

IN VIVO STUDIES OF BONE GRAFTS

The Possibility of Vascular Anastomoses in Healing Bone

T ALBREKTSSON

Institute for Applied Biotechnology, Gothenburg, and the Laboratory for Experimental Biology, Department of Anatomy, University of Gothenburg, Gothenburg, Sweden

A titanium chamber enabling vital microscopic studies of bone tissue *in situ* was installed in the tibiae of 10 rabbits. Using a gentle surgical technique the chamber and surrounding bone were cut *en bloc*, twisted 360° and reinserted into the same donor bed. Vital microscopy of these orthotopical bone grafts revealed that the circulation was mainly regained via ingrowth of newly developed vessels of host origin, starting at 5–8 days after grafting Bone remodelling was observed at 3 weeks post grafting in these cases. In two grafts, however, an additional mode of blood flow recovery was seen. Here vessels of more than 30 microns width, registered before grafting, apparently were functioning also afterwards, indicating end-to-end anastomoses between host and pre-existing graft vessels. In these two grafts bone remodelling started as early as 1 week after transplantation.

Key words animal experiments, bone transplantation, *in vivo* studies, vascular anastomoses, bone remodelling

Accepted 17 v 79

A rapid re-establishment of the blood flow in bone grafts is beneficial for graft incorporation (Stringa 1957) The primary graft circulation is thought to be dependent either on the ingrowth of new vessels of host origin – *revascularization* – or on anastomoses between host and pre-existing graft vessels – *recirculation*

Revascularization

Most authorities agree that the blood circulation in bone grafts is dependent on *revascularization* (Burwell 1969, Albrektsson, B 1971) The creeping substitution procedure believed to be responsible for the primary *revascularization*, at least of cortical bone grafts, is known to be slow Schenk & Willenegger (1967) estimated the rate of the cutter head ingrowth to be 50–80 microns a day On the basis of findings indicating that the necrotic border zone in the host bed is 0 5–1 mm wide (Rhinelander 1974, Albrektsson et al 1978), ingrowing vessels from the host bone would need a minimum of 6 days to reach the cortical graft tissue

Recirculation

Recirculation has been suggested as a complementary possibility for the re-establishment of graft blood flow (Hancox 1947, Stringa 1957, Graf 1959, Zeiss et al. 1960, Deleu & Trueta 1965, Forgon & Bornemisza 1970, Albrektsson, B 1971, Olerud & Danckwardt-Lilliestrom 1971, Ray

0001–6470/80/010009–09$02.50/0

1972) *Recirculation* was proved by vital microscopy to be possible in skin grafts (Birch & Brånemark 1969) but as far as bone grafts are concerned it is as yet a theory of uncertain validity The assumption of *recirculation* in bone grafts is as a rule based on indirect observations of the vasculature during the first week after the transplantation Some authors report a strikingly early appearance of blood vessels (Hancox 1947, Ray 1972), others a remarkable acceleration of the injectiability of graft vessels from one day to another (Graf 1959, Deleu & Trueta 1965, Forgon & Bornemisza 1970)

Aims of the present study

Summarizing the opinions from the literature reviewed above, there is no true disagreement that revascularization is the important mode of re-establishment of graft blood flow The debate has instead been focused on the following questions

1 How fast is the revascularization process?

2 Is revascularization under favourable circumstances combined with recirculation?

The present article is an attempt to illustrate the early stages of autologous bone incorporation with specific emphasis on two questions

MATERIALS AND METHODS

Ten adult male and female Belgian hares and lop-eared rabbits 9–14 months old and weighing 5–7 kilograms were used for vital microscopic studies. A bone chamber (Figure 1) was installed in the tibial metaphysis The chamber type used in the present experimental series was partly unthreaded, but was in all other aspects the same as the type A chamber described by Albrektsson & Albrektsson (1978) in which paper the principles concerning the bone chamber method were presented

During a healing period of 6–9 weeks vessels and bone tissue grew to fill out the chamber gap as seen in the enlarged part of Figure 1e A Leica ESR and a Vinten scientific 16 mm camera were connected to a Leitz intravital microscope allowing registration of the bone and vascular architecture of the 'future graft At grafting a trephine was used, under flowing saline cooling, to gently cut out the chamber with a surrounding bone collar The graft-chamber complex was lifted out of the host bed twisted 360° and returned in the same position as before grafting (Figure 1e) Graft stability was ensured by using a specially constructed plate (Figure 1e) The animals were then scheduled for two examinations, one at 6 days after surgery and another at sacrifice which was planned at 12–15 days (5 animals) or 18 2 days (5 animals) post grafting

The studied bone graft was regarded as "fully vascularized " when the amount of vessels was the same as before grafting Numerically this was defined by dividing the vessels into three groups minor (< 12 microns) intermediate (12 30 microns) and large (> 30 microns) and measuring the added length of the vessels on intravitally performed drawings with the aid of a cartometric wheel pen Bone surface area was calculated with A Teknor 95 planimeter

During surgery and the vital microscopic sessions the animals were under general anaesthesia maintained by i m injections of Hypnorm (Mecos, Helsingborg Sweden) at a dose of 0 7 ml/kg body weight

RESULTS

Definitions

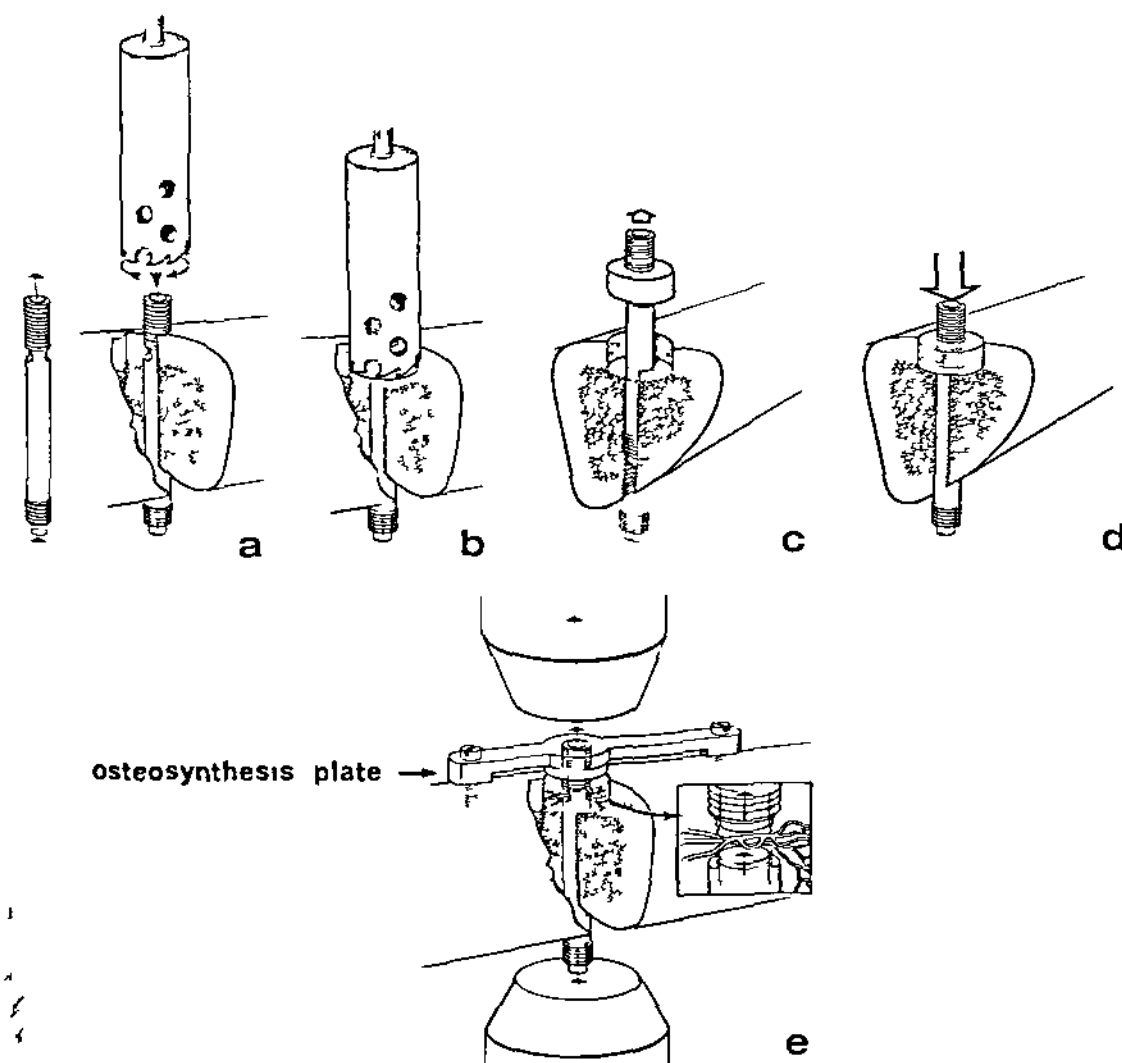
Prior to grafting the differentiation between arteriolar and venular vessels could be made according to morphological characteristics and observations of the blood flow In the first weeks after transplantation this was found to be difficult due to poor anatomical differentiation and irregular vascular arborization found in the repair tissue Because of this the concepts minor intermediate and major vessels – defined in the methods section of the present paper – used in the text below

The results from eight of the chamber grafts are presented together in Table 1, whereas two grafts are presented separately as the mode of vascular recurrence was different

Table 1 Results from eight of the chamber grafts

Chamber no.	1	2	3	4	5	6	7	8
Animal sacrifice	II	II	II	II	III	III	III	III
Full vascularization	—	—	—	II	III	III	III	III
Bone accretion	—	—	—	—	—	III	III	III
Bone resorption	—	—	—	II	—	—	—	III

Period I 5–8 days Period II 12–15 days Period III 18–21 days



Figu-... 100 ... chan ... twis... grafting

Primary vessels

All chamber grafts contained functioning vessels at 5–8 days post grafting These vessels were always primarily confined to the connective tissue parts of the bone as illustrated in Figure 2. By calculating the length of the primary vessels and estimating the maximal capillary sprout penetration rate in cancellous bone to be about ½ mm a day it was concluded that the observation area in two cases might have been invaded by the first vessels on day 4 The primary vessels were always of minor size growing in vascular arcs entering the observation field close to the point of leaving it The vessels were tortuous with irregular and occasionally stagnant blood flow The invading vessels seemed to penetrate the graft gradually by adding further vascular arcs on top of the old ones as indicated by the asterisk in Figure 2

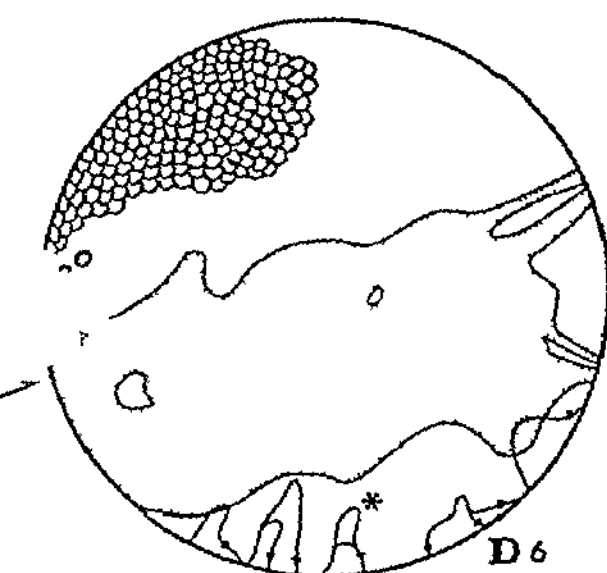


Figure 2 Drawing of chamber no 2 6 days after the reinsertion procedure The primary vessels with arrows indicating the flow direction are seen entering the connective tissue (white) in the observation field These vessels gradually grow towards and into the bone tissue (dotted) during the following week. The asterisk indicates the typical vascular arcs seen in the early vascularization period In the top left of the observation field a cluster of fat cells is seen.

Full vascularization

Three of the four chamber grafts observ[ed] at 12–15 days post grafting were not fu[lly] vascularized The vessels found were le[ss] tortuous compared with those at 5–8 da[ys] post grafting Most of the vessels were s[till] minor in size although a few intermedi[ate] ones were seen. Vessels were observed no[t] only in the connective tissue but also in the calcified parts of the observation field. Th[e] vascularization particularly in the bone parts of the graft was not as abundant as befor[e] grafting One chamber at 14 days (Figure 3a b) and all four chambers observed a[t] 18–21 days post grafting were fu[lly] vascularized Vessels of minor intermedi[ate] and large size were observed There was no longer any vascular tortuosity to be seen. The blood flow was steady not slow or irregular Even if there were as many vessels in the graft as before transplantation there was n[o] resemblance between the original vascula[r] architecture seen before grafting and th[at] observed 1–3 weeks afterwards.


Bone remodelling

At 18–21 days post grafting in thre[e] chambers out of four new bone was laid down upon the original trabeculae observed before grafting Bone accretion was alwa[ys]

Figure 3 In vivo colour photograph 14 days po[st] grafting, of chamber no 4 (3a) with an enlarg[ed] section (110×) shown in Figure 3b The tr[ue] diameter of the observation field is 2 mm. Th[e] minor spots seen especially in Figure 3b c[...] osteocyte lacunae Vessels of varying width [...] crossing the graft Although the vessels are co[m]paratively wide this short time after surgery th[ey] are newly developed vessels of host origin.

Figure 4 In vivo colour photograph 55 days po[st] grafting of chamber no 9 with an enlarged sectio[n] (65×) shown in Figure 4b The same gra[ft ...] shown in the drawings Figure 5a f The m[...] central vessels were also seen before grafting a[nd] it is concluded that these vascular channels [...] surviving because of end-to-end anastomoses.


a


a


b


b

limited to the very region of the old bone – in no case did bone formation occur without direct connection to previously calcified tissue In one chamber bone resorption was evident in parts of the observation field at the same time as bone accretion was seen in another part. The chamber that was fully vascularized already at 14 days post grafting then showed evidence of ongoing bone resorption The bone in this case covered an area 8 per cent less than that registered before grafting

Evidence of recirculation

The two remaining chamber grafts behaved differently from the other eight studied At the first observation after 7 and 8 days, respectively, the vascular architecture closely resembled the conditions before grafting Some intermediate to large vessels seemed to be identical. By comparing pictures before and after grafting it was concluded that recirculation by end to-end anastomoses must have occurred. One of the anastomosed rabbits unfortunately died for unknown reasons 11 days after transplantation It was photographed 8 days after transplantation. The chamber bone was then already fully vascularized Bone [illegible] had started and the bone surface [illegible] was reduced by 6 per cent. There was no evidence of bone accretion. The other recirculation graft was not, as originally planned, sacrificed after 55 days. It was checked five times between 7 and 55 days post grafting (*Figure* 4a,b, 5a-f). *Before* grafting 77 per cent of the visible chamber area was occupied by bone and 23 per cent by connective tissue "islands" At 7 days there was evidence of both osteogenesis and resorption At 27 days post transplantation the bone surface area occupied 49 per cent of the observation field Bone resorption had then reached its peak and osteogenesis became very dominant in the form of woven bone that later became lamellarized. At 55 days when the experiment was terminated the bone surface area occupied 55 per cent. The major vessels seen passing across the central field of the chamber bone already before grafting were still recognizable 55 days afterwards. At 7 days it was noted that the blood flow was slow, occasionally stagnant, in these vessels, the diameter of which had *increased from 30 microns before grafting to about 70 microns.* With the exception of these major vessels the flow in other parts of the graft was principally indistinguishable from that before grafting

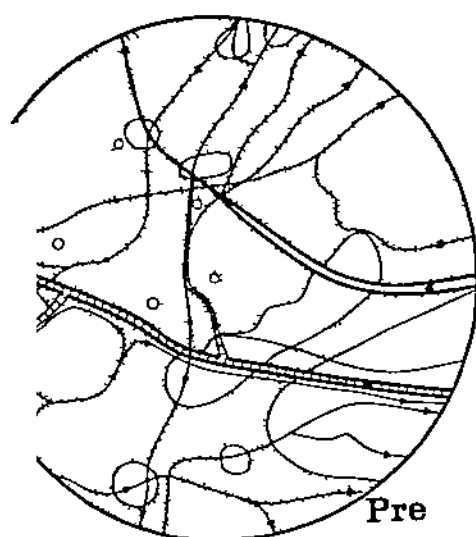
DISCUSSION

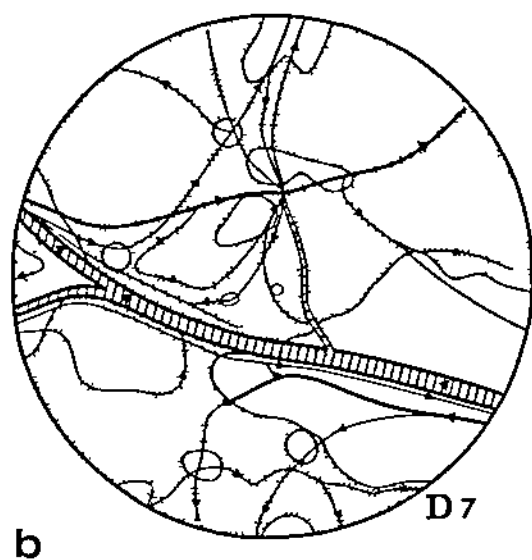
Revascularization and recirculation in grafted tissue

Most of the grafts described in this study regained blood flow via ingrowth of newly developed vessels – revascularization. As this mode of vascular penetration is described in many studies, the focus of the present discussion is aimed at the recirculation chambers.

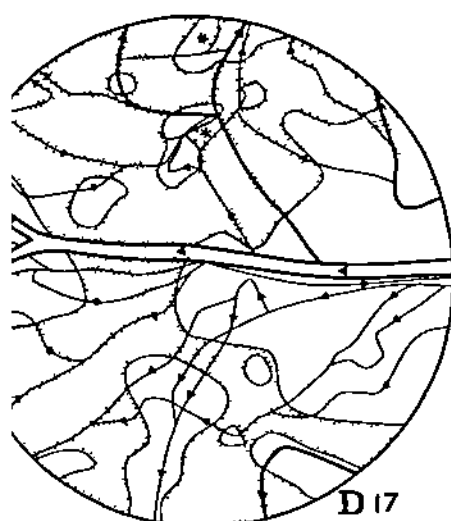
Free grafted tissue is, by definition, deprived of its blood supply The possibility of cell survival is dependent on the rapid return of the blood flow Even if the graft cells primarily might be nourished through "plasmatic circulation" (Huebscher 1888) it is generally agreed that regaining the blood flow is essential for normal cell function (Burwell 1969). Numerous reports investigating the possibility of anastomoses in *skin grafts* have been published (cf Pihl & Weiber 1951, Zarem 1965, Marckmann 1966). Only by using a direct vital microscopic method (Birch & Brånemark 1969) was it possible to

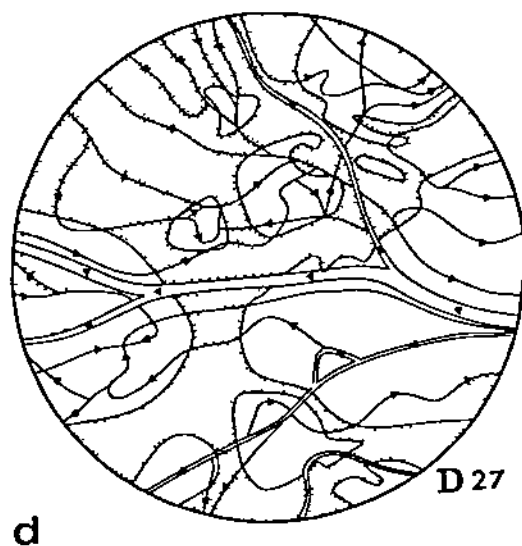
Figure 5 Chamber no 9 before and at intervals between 7 and 55 days post grafting The major vessels seen before grafting are still recognizable 55 days later indicating end to-end anastomoses. The vessels are crossed in Figures 5a and 5b to make comparisons easier The beginnings of bone accretion can be seen in a small area in the left part of the chamber as early as 7 days when also a more [illegible] bone resorption is evident especially in the right part of the chamber Bone tissue close dots [illegible] bone and newly built lamellarized bone thin dots Vessels with arrows indicate direction of flow





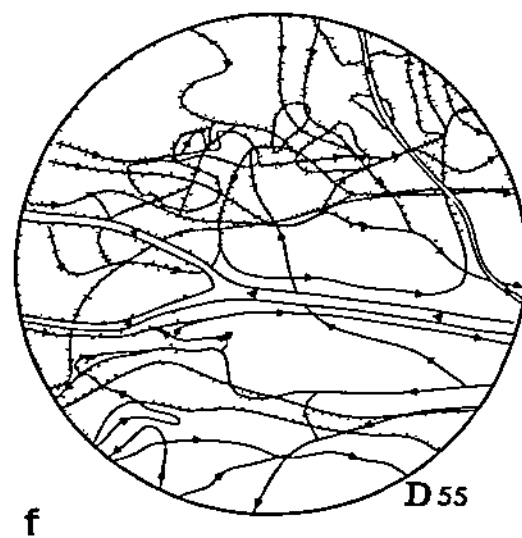
b





d





f

limited to the very region of the old bone – in no case did bone formation occur without direct connection to previously calcified tissue In one chamber bone resorption was evident in parts of the observation field at the same time as bone accretion was seen in another part The chamber that was fully vascularized already at 14 days post grafting then showed evidence of ongoing bone resorption The bone in this case covered an area 8 per cent less than that registered before grafting

Evidence of recirculation

The two remaining chamber grafts behaved differently from the other eight studied At the first observation after 7 and 8 days, respectively, the vascular architecture closely resembled the conditions before grafting Some intermediate to large vessels seemed to be identical By comparing pictures before and after grafting it was concluded that recirculation by end to-end anastomoses must have occurred One of the anastomosed rabbits unfortunately died for unknown reasons 11 days after transplantation It was photographed 8 days after transplantation The chamber bone was then already fully vascularized. Bone had started and the bone surface was reduced by 6 per cent There was no evidence of bone accretion The other recirculation graft was not as originally planned sacrificed after 21 days It was checked five times between 7 and 55 days post grafting (Figure 4a,b, 5a-f) Before grafting 77 per cent of the visible chamber area was occupied by bone and 23 per cent by connective tissue islands At 7 days there was evidence of both osteogenesis and resorption At 27 days post transplantation the bone surface area occupied 49 per cent of the observation field Bone resorption had then reached its peak and osteogenesis became very dominant in the form of woven bone that later became lamellarized. At 55 days when the experiment was terminated, the bone surface area occupied 55 per cent. The major vessels seen passing across the central field of the chamber bone already before grafting were still recognizable 55 days afterwards. At 7 days it was noted that the blood flow was slow, occasionally stagnant, in these vessels, the diameter of which had increased from 30 microns before grafting to about 70 microns. With the exception of these major vessels the flow in other parts of the graft was principally indistinguishable from that before grafting

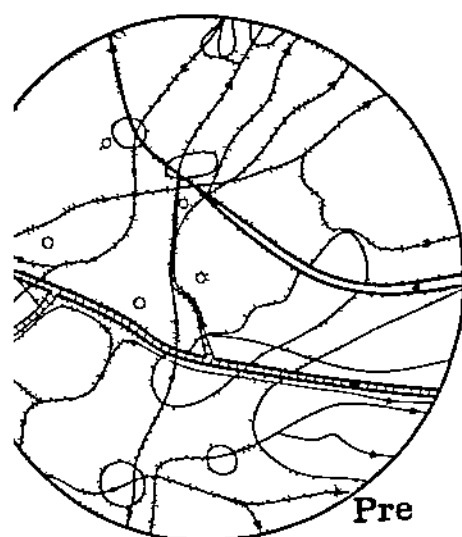
DISCUSSION

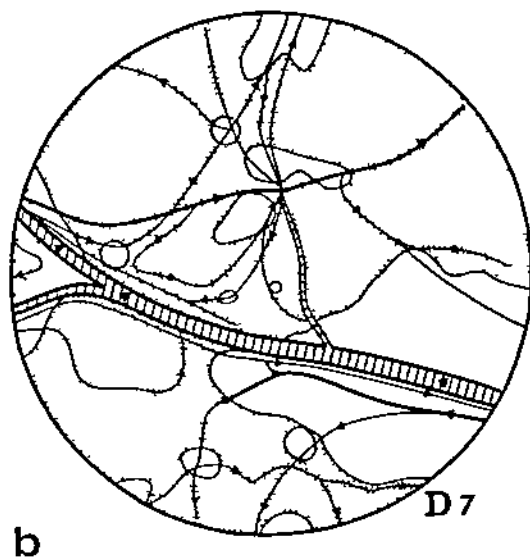
Revascularization and recirculation in grafted tissue

Most of the grafts described in this study regained blood flow via ingrowth of newly developed vessels – revascularization. As this mode of vascular penetration is described in *many studies*, the focus of the present discussion is aimed at the recirculation chambers.

Free grafted tissue is, by definition, deprived of its blood supply The possibility of cell survival is dependent on the rate of return of the blood flow Even if the graft cells primarily might be nourished through "plasmatic circulation" (Huebscher 1888) it is generally agreed that regaining the blood flow is essential for normal cell function (Burwell 1969) Numerous reports investigating the possibility of anastomoses in *skin grafts* have been published (cf Pihl & Weiber 19[illegible] Zarem 1965 Marckmann 1966). Only by using a direct vital microscopic method (Birch & Brånemark 1969) was it possible [illegible]

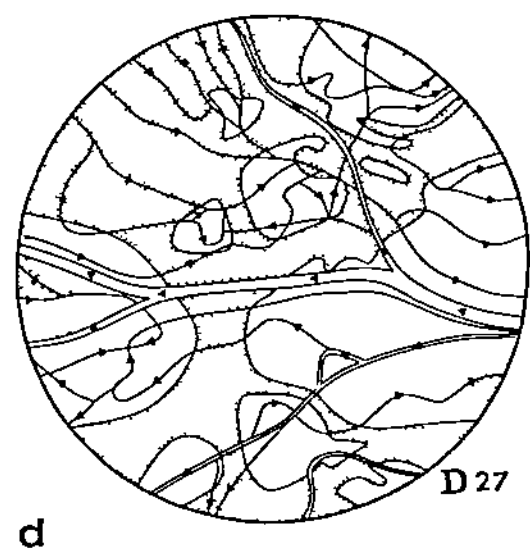
Figure 5 Chamber no 9 before and at intervals between 7 and 55 days post grafting The major vessels seen before grafting are still recognizable 55 days later indicating end to-end anastomoses. The vessels are crossed in Figures 5a and 5b to make comparisons easier The beginnings of bone accretion can be seen in a small area in the left part of the chamber at early as 7 days when also a more [illegible] bone resorption is evident especially in the right part of the chamber Bone tissue close dots. [illegible] bone and newly built lamellarized bone thin dots Vessels with arrows indicate direction of flow



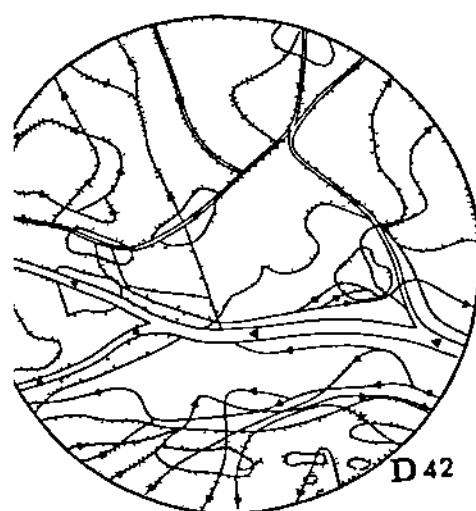


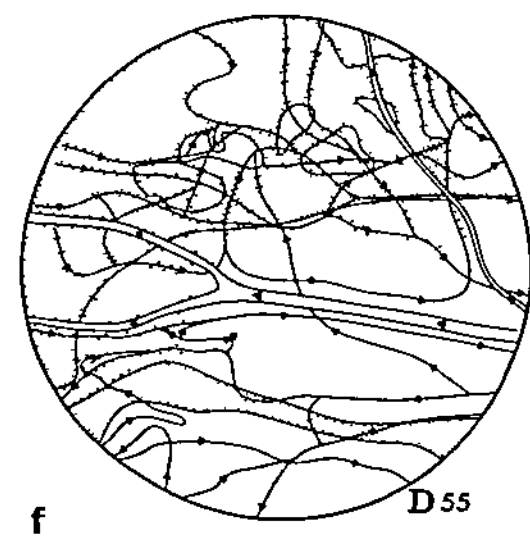
b





d





f

reveal that the early circulation in skin grafts started 24–28 hours post grafting in pre-existing graft vascular channels. Comparing the data from the present article with those obtained by Birch & Branemark (1969) some important differences are noted Firstly, vascular anastomoses being a rule in free skin grafts (provided a gentle surgical technique is used) are an exception in the type of bone transplants described here Secondly, the vascular architecture in the skin grafts rapidly underwent marked modifications completely changing the vital microscopic picture in a couple of days. The bone vascular picture is much more constant, probably due to the fact that the bone vessels, having to pierce the calcified tissue before establishing new connections are less apt to change their architecture

Whether the vascular anastomoses described in this paper are actually bone-to-bone or rather marrow space-to-bone vessel connections is an interesting question to which at present no safe answer can be given

Apart from the earlier mentioned reports about direct vascular connections in various types of grafts there are also critical studies claiming the improbability of end to-end anastomoses (Zarem 1965, 1970) Even if the ...cyte canaliculae do permit diffusion ... tissue fluid, the calcified ground substance in bone acts as a barrier to the primary tissue fluid circulation (Ham 1952), further diminishing the chances for vascular anastomoses in this special tissue It should indeed be kept in mind that what has been performed in the surgical procedure described in the present paper might be referred to as an osteotomy rather than an actual transplantation In other recent studies where the graft was twisted 180° on transplantation or transferred to the contralateral bone (Albrektsson T 1979) revascularization always occurred via newly developed minor vessels of host origin What it is believed is shown in the present study is that, under ideal conditions – i e control of the surgical trauma and immediate reinsertion of the graft into the same position – a direct conne... with re-established circulation between ... vessels of host and graft origin is possib... bone tissue

CONCLUSIONS

1 Re-establishment of blood flow in b... grafts occurs mainly by the process ... *revascularization* – ingrowth of ne... developed vessels of host origin.

2 Evidence is presented for the occurre... of *recirculation* – anastomoses between p... existing graft and host vessels – und... favourable circumstances.

3 In cases of *recirculation* bone remod... ling was observed at 1 week after graft... whereas when *revascularization* occur... there was usually a delay of 3 weeks bef... observable bone remodelling

ACKNOWLEDGEMENT

This study was supported by grants fr... Goteborg Medical Society, the Swedish Board ... Life Insurance Foundation Wilhelm and Mart... Lundgrens vetenskapsfond and the Faculty ... Medicine University of Gothenburg

REFERENCES

Albrektsson B (1971) Repair of diaphy... defects. Thesis, University of Gothenb... 95 p.

Albrektsson T & Albrektsson B (1978) M... circulation in grafted bone. A ch... technique for vital *microscopy of rabbit b...* transplants. *Acta orthop scand* 49, 1–7

Albrektsson T., Brånemark, P I., Eriksson, ... Lindstrom, J (1978) The preformed autoge... bone graft *Scand J plast reconstr Surg* ... 215–223

Albrektsson T (1979) Repair of bone gr... *Scand J plast reconstr Surg* (Subm... Publ.)

Birch, J & Brånemark, P I (1969) ... vascularization of a free full thickness ... graft. A vital microscopic study *Scand plast reconstr Surg* 3, 1–10.

ˉta orthop scand. *51*, 19–28 1980

NTRAOSSEOUS PHLEBOGRAPHY, INTRAOSSEOUS 'RESSURE MEASUREMENTS AND ^{99m}TC-POLYPHOSPHATE ,CINTIGRAPHY IN PATIENTS WITH VARIOUS \INFUL CONDITIONS IN THE HIP AND KNEE

ARL C ARNOLDI, J C DJURHUUS, J HEERFORDT & A KARLE

)epartments of Orthopaedic Surgery, Diagnostic Radiology XN and the Circulation Research aboratory Department of Urology, Rigshospitalet Copenhagen, Denmark

Twenty five patients with pain in the knee or hip were examined by means [illegible]

pain syndrome – showed venous stasis and increased pressure in the bone marrow near the painful joint and abnormally high uptake of the [illegible]

engorgement pain syndrome in patients [illegible] increased isotope uptake in a joint region may be due to a variety of other causes. The identical findings with all three methods of investigation in patients with the intraosseous engorgement pain syndrome and osteoarthritis *suggest a common pathomechanism.*

Key words engorgement pain syndrome, intraosseous phlebography intraosseous pressure osteoarthritis

Accepted 22 v 79

n patients with painful osteoarthritis of the up and knee the drainage of venous blood rom the marrow of juxta-articular bone is mpaired Intraosseous phlebography reveals ı state of intraosseous stasis (Mériel et al 955, Phillips 1966, Arnoldi et al 1972a) and he pressure in the bone marrow is increased Arlet et al 1968, Arnoldi et al 1972a, Lynch 974)

Recently, Arnoldi and co-workers (1975) liscovered that intraosseous stasis and ıypertension were more closely related to the ymptom of rest pain than to the presence of ısteoarthritic changes *in the joint*

This work was supported by the Danish Medical Research Council (project no 512–4180)

Based on findings from the knee joint Lemperg & Arnoldi (1978) described the *intraosseous engorgement pain syndrome* and further experience has shown that the same syndrome occurs in the hip region

These patients suffer from rest pain in the hip or knee areas, aggravated by physical activity Anatomically, the joints are normal and X ray examination reveals no signs of osteoarthritis There is, however, in many cases a more or less marked osteoporosis of the joint bearing bone The pain in the hip tends to spread towards the knee and the pain in the knee towards the lower leg Intraosseous phlebography always shows poor drainage from the bone marrow and the intraosseous pressure is as a rule high In our opinion

ˈ001 6470/80/010019-10$02.50/0

ich region of interest are Poisson distributed, the andard deviation (S D) of the ratio (R) is

$$D = R\sqrt{\frac{1}{x}+\frac{1}{y}}$$

here x and y are the number of counts on either de

Ieasurements of intraosseous and intravenous ressure

These measurements were performed according the methods described by Arnoldi and co-workers (1972a) The pressures were measured ith the patient lying supine on a roentgen table ull anaesthesia was used For examinations in he hip region conical cannulae with a lumen easuring 2 6 millimetres were introduced hrough the trochanter into the femoral neck In he knee region the cannulae were inserted both in e femoral condyle and the proximal part of the ibia All measurements were done bilaterally The annulae were flushed with a heparin-saline olution and connected to the pressure recording ystem by means of liquid filled tubes. Except for he brief periods of pressure recording saline lowed slowly through the tubes into the bone narrow with the saline infusion bottle at 150 cm bove heart level Unilateral measurements of enous pressure were obtained by means of a tube ntroduced into the internal saphenous vein at the nkle In patients examined for intraosseous ressure of the femoral neck the tip of the intravenous tube was placed in the distal internal liac vein, for measurement in the knee region the ip was placed at the level of the knee joint

All intraosseous and venous pressures were eferred to heart level This was arbitrarily fixed t the midaxillary plane at the level of the fourth ostal insertion on the sternum

With intact arterial inflow to the bone marrow e intramedullary pressure is largely dependent pon the pressure in the draining extraosseous ein and varies with this pressure (Arnoldi & inderholm 1971, Arnoldi & Linderholm 1972) he values of intraosseous pressure in this study re therefore given as the difference between enous and intraosseous pressure in mmHg igure 5) In measurements around the knee joint e highest pressure, either from the distal femur r from the proximal tibia, was chosen as epresentative (Arnoldi et al 1975)

ntraosseous phlebography

When the measurements of intraosseous ressure were finished 10 ml of water-soluble ontrast medium Isopaque-Amin® was injected into the bone marrow through the wide bore cannulae used for pressure measurements. The injections were performed bilaterally and simultaneously The injection time was 20–40 seconds Focus-film distance was 125 cm The films were exposed at 60 to 70 kV and 640 mA with an exposure time of 0 40 s The first exposure was made immediately after the injection of contrast Further exposures were made at fixed intervals, the last being 30 minutes after the injection

In the bone marrow of healthy joints the contrast medium disappears rapidly into the extraosseous veins (Arnoldi et al. 1972a) while in painful osteoarthritis, and in patients suffering from the intraosseous engorgement-pain syndrome intramedullary retention of contrast is characteristic A clearance time of 6 minutes or less was considered normal for intraosseous contrast (Arnoldi et al 1972a)

In addition, the intraosseous distribution of contrast was noted Normally, the contrast passes directly from the tip of the cannula to the extraosseous vein and filling of intraosseous veins or sinusoids is only seen in a very limited area around the tip In patients with painful osteoarthritis or intraosseous engorgement-pain syndrome the impaired drainage across the cortex results in an abnormal filling of large parts of the intraosseous veins of the region and in extreme cases the entire venous system of the marrow of a long bone can be observed Thus, phlebograms with extensive intraosseous contrast filling, and delayed emptying (clearance time longer than 6 minutes) were considered abnormal (Figures 6 and 7)

FINDINGS

A Patients suffering from typical rest pain

Patients with osteoarthritis of the hip or knee joint, n = 10 Table 1 shows the results of the various examinations in 10 patients suffering from severe rest pain and osteoarthritis of the hip or knee joints.

As shown in Table 1 severe painful osteoarthritis in the hip or knee was always accompanied by intramedullary venous stasis. The intraosseous pressure was always higher on the affected side than in the bone marrow of normal joints In unilateral cases the mean pressure difference was 29 4 mm Hg (range

(Arnoldi et al 1975) the intraosseous hypertension is the pain-triggering factor in these patients High intraosseous pressure is lowered when the cortical wall is broken, either by an osteotomy or by fenestration of the cortex and the typical rest pain disappears promptly after these interventions (Arnoldi et al 1971, Åstrom 1975)

When using ^{99m}Technetium-labelled phosphate compounds for bone scintigraphy osteoarthritic joints are likely to show an increased uptake of various degrees at all stages of this disease (Hoffer & Genant 1976, Subramanian & McAfee 1971) Scintigraphy with these short-lived radiotracers is a painless and non invasive examination, while intraosseous pressure measurements and phlebography usually have to be performed during full anaesthesia and the necessary intraosseous injections may cause unwarranted complications (Lemperg & Arnoldi 1978)

The main purpose of the present study was to examine the usefulness of bone scintigraphy with ^{99m}Tc-Polyphosphate (Tc-PP) in the diagnosis of the intraosseous engorgement-pain syndrome and to compare the findings of scintigraphy with the results of pressure measurements and intraosseous phlebography It was further hoped that these studies might throw some light upon the relationship between this syndrome and osteoarthritis.

PATIENTS

Twenty-five patients, 15 men and 10 women, with a mean age of 50 2 (range 25–75) years were examined in the present study Seventeen patients suffered from typical rest pain around the knee or hip joint i e a dull aching or throbbing pain felt diffusely around the joint usually increasing towards the end of the day and persisting at rest (Arnoldi et al 1972a Helal 1965) These 17 patients either suffered from severe osteoarthritis of the hip or knee (10 patients) or fulfilled the criteria for the "intraosseous engorgement-pain syndrome" (Lemperg & Arnoldi 1978) (7 patients).

In the remaining eight patients the pain had a different character, either pain on loading or intermittent periods of sharp pain in the [...] combined with locking of the joint. These p[...] were never present when the joint was com[...] at rest

METHODS

The patients were subjected to the follo[...] examinations

1 X-ray examination of the hip and knee j[...]
2 Scintigraphic examination of the lower ext[...] including the pelvis.
3 Measurement of intraosseous pressure of [...] femoral neck or the bones around the k[...] joint combined with measurement of pres[...] in the internal iliac or internal saphenous ve[...]
4 Intraosseous phlebography of the hip or k[...] joint

X ray examination

Both hips and both knees were examined [...] the patient standing Frontal and lateral expo[...] were performed on all four joints, and the k[...] joints were further exposed in forced varus [...] valgus.

Scintigraphy

Twelve mCi of Tc-PP was administered [...] hours before the patient was examined using [...] inch dual probe whole-body rectilinear sca[...] ('Elscint') The collimators used had an [...] depth independent response over the range of [...] inches, and joint regions were examined [...] positions symmetrical to the collimat[...] Scintigraphies were studied visually [...] photorecordings and in the corresponding [...] display processing (the latter was all stored [...] tape) The positive finding dealt with below [...] an increased osseous tracer uptake in the p[...] region assessed by visual study of the scintig[...] (Figures 1 and 3).

In cases with unilaterally positive scintigraphic findings, the visual assessment of the scintigr[...] was supplemented by a numerical assessmen[...]

On the video display unit rectangular regions [...] interest were set to frame the whole joint reg[...] in a pair of joints. In anatomical size these reg[...] of interest corresponded to a 9 × 10.5 cm fr[...] around a knee joint region and a 6 × 6 cm fr[...] around a hip joint region. The count r[...] between the affected and normal sides [...] calculated from the number of counts in each p[...] region of a pair of joints. Assuming this [...]

A *Patients with unilateral rest pain*

	age mean and (range)	men	women	hip	knee	phlebogram		intraosseous pressure mmHg mean and (range)		scintigraphy	
						affected joint norm/abn	normal joint norm/abn	affected joint	normal joint	affected joint norm/inc	normal joint norm/inc
	49 0 (33 69)	3	1	0	4	0/4	3/1 *	40 3 (25–59)	16 0 (13 19)	0/4	4/0

B *Patients with bilateral rest pain*

	age mean and (range)	men	women	hip	knee	phlebogram affected joint	phlebogram normal joint	intraosseous pressure affected joint	intraosseous pressure normal joint	scintigraphy affected joint	scintigraphy normal joint
	46 7 (25–58)	1	2	1	2	1/5 **	–	41 3 (32–47)	–	1/5	–

n number of patients. norm – normal abn – abnormal inc increased
* clearance time > 6 minutes distribution of contrast normal
** clearance time < 6 minutes distribution of contrast normal



Figure 3 X ray picture of a hip with intraosseous engorgement pain syndrome taken after fenestration.

the unaffected joint was 24 3 mmHg (range 6–41) In one case the clearance time of a painless joint was longer than 6 minutes. Thus it was classed as abnormal although the area of bone marrow filled with contrast was small The scintigram of the painful joint



Figure 4 Tc-PP scintigram of the same patient before the fenestration operation




Figure 5 Pressure tracings from the internal saphenous vein at the knee level and from the knee marrow of the right and left femoral condyles The patient suffered from the intraosseous engorgement pain syndrome in the right knee region

always showed increased tracer uptake (Figures 3 and 4)

Numerical assessment of the scintigrams

The results of a numerical assessment of the Tc-PP uptake in the cases of unilateral affection As described in "Methods" a count ratio between the affected and normal hip or knee joint region was calculated (A) Among the 10 patients with osteoarthritis a unilateral affection of a hip joint or a knee joint was seen in two and four patients, respectively Ratios and standard deviations in the former

Table 3 Findings in eight patients with miscellaneous painful joint diseases without rest pain (see text) by means of bilateral intraosseous phlebography measurements of intraosseous pressure and Tc PP scintigraphy

A Unilateral cases											
n	age mean and (range)	men	women	hip	knee	phlebogram		intraosseous pressure mmHg mean and (range)		scintigraphy	
						affected joint norm/abn	normal joint norm/abn	affected joint	normal joint	affected joint norm/inc	contralateral joint norm/inc
7	45 0 (28–55)	4	3	2	5	3/4	7/0	21 3 (8–32)	22 4 (8–32)	3/4	6/1
B Bilateral cases											
1	60	1	0	0	1	2/0	–	26 (25–27)	–	2 0	–

n = number of patients norm – normal abn = abnormal inc = increased



Figure 6 Intraosseous phlebogram from a normal pain free knee The cannula is placed in the tibial metaphysis and the exposure made immediately after injection of 10 ml of contrast medium The contrast is seen in the extraosseous draining vessels Filling of intraosseous vessels is observed in a small area around the tip of the cannula



Figure 7 Intraosseous phlebogram of a patient with intraosseous engorgement pain syndrome obtained immediately after injection of 10 ml of contrast medium The contrast is observed in intraosseous vessels in the proximal part of the tibia Drainage to extraosseous veins is not seen (cf Figure 6)

oup were 2 39 ± 0 24 and 1 30 ± 0 06, and in e latter group 1 68 ± 0 11, 2.17 ± 0 04, 22 ± 0 04, and 1 37 ± 0 04 (B) Among the ven patients with intraosseous ngorgement pain syndrome a unilateral ffection was seen in four patients, in all of em it was located in the knee joint Ratios nd standard deviations were 1 23 ± 0 01, 26 ± 0 05, 1 23 ± 0 06, and 1 59 ± 0 05 It is en that (a) the individual ratios were easured with an accuracy greater than 10 er cent, (b) that count ratios tended to be igher in the osteoarthritic cases (in hip joints nd knee joints with a mean of 1 85 and 1 61, spectively), than in the engorgement-pain yndrome cases (mean 1 33)

Patients with other types of pain in the ip or knee region, n = 8

Eight patients suffering from other types of ain in the knee and hip region were xamined in a similar manner Four suffered om intermittent sharp pain combined with cking of the knee The diagnosis in three ases was a torn meniscus, and in one case a ose body in the knee One patient was und to have an old partial rupture of the ternal collateral ligament with pain on alking that disappeared after physical erapy One patient suffered pain on loading in the right hip due to secondary osteoarthritis after a tuberculous infection. Another patient with moderate pains of the same type had a roentgenologically severe unilateral osteoarthritis The last patient complained of intense pain in both knees on loading No reason for this was detected while he was in our care

Table 3 shows the findings in this group

Of the seven patients with unilateral pain, three (all with torn menisci) showed abnormal phlebograms. The pressures were normal The scintigrams showed increased uptake in the same three patients and in one of the apparently normal and painless knee joints. The findings in the patient with bilateral pain were completely normal

DISCUSSION

The techniques for intraosseous phlebography and pressure measurements used in this study have been described in detail in previous publications (Arnoldi & Linderholm 1971, Arnoldi et al 1972a, Arnoldi et al 1972b) An extensive analysis of the reliability and reproducibility of intraosseous pressure measurements has been published by Lemperg & Arnoldi (1978) and the same authors discussed the relationship

between rest pain, delayed clearance of intraosseous contrast and intraosseous pressure They concluded that intraosseous venous stasis *seemed to be a constant finding in* patients with rest pain In patients with rest pain in the hip or knee the intraosseous pressure is higher on the painful side, but there does not seem to be a clear demarcation between normal and pathological pressure Increased intraosseous pressure is probably the mechanism that triggers the pain sensation, but the threshold *for pain* varies from patient to patient

The findings in the present study confirm earlier observations that patients with painful osteoarthritis always show impaired venous *drainage from the marrow of juxta-articular* bone They also confirm that the same vascular disturbances may be present in the bone marrow of patients with rest pain but without clinical or roentgenological signs of osteoarthritis (the engorgement-pain syndrome)

Tc-PP scanning as a diagnostic method in patients with the intraosseous engorgement-pain syndrome

In patients with osteoarthritis of the hip joint accompanied by rest pain osteotomy or cortical fenestration is followed by an immediate fall of intraosseous pressure and relief of pain (Arnoldi et al 1971). Recently, Åstrom (1975) and Hietala & Åstrom (1977) showed that fenestration had the same effect on intraosseous pressure and pain in patients with osteoarthritis of the knee joint and in patients with *the intraosseous engorgement*-pain syndrome in this region At the moment surgery is the only known effective therapy for patients with the intraosseous engorgement-pain syndrome and the only means of reaching a correct diagnosis are intraosseous phlebography and pressure measurements, time consuming procedures that demand full anaesthesia and intraosseous injections with the risk of bone marrow infection.

In this study Tc-PP scanning consi[...] showed increased uptake over joints w[...] traosseous stasis and hypertension, inde[...] dent *of the presence or absence* of [...] teoarthritis. These results indicate that T[...] scanning can be used as a screening me[...] for impaired venous drainage from ju[...] chondral bone marrow A nega[...] scintigraphy means that it is highly [...] probable that a sensation of pain in the k[...] or hip is caused by intraosseous engorge[...] and hypertension Increased tracer up[...] and a typical history implies the prese[...] the intraosseous engorgement pain syndr[...] However, a positive scintigram [...] unspecific reaction and if surgical interve[...] is considered the diagnosis should be fu[...] verified by means of intraoss[...] phlebography

The relationship between osteoarthritis [...] the intraosseous engorgement pain syndr[...]

Intraosseous stasis and hypertension [...] observed in patients with painful [...] teoarthritis as well as in patients with the [...] traosseous engorgement pain syndrome [...] *to be caused* by a blockage of the [...] drainage vessels somewhere near the co[...] The mechanism is not known at pr[...] However, investigations on the hip [...] patients with osteoarthritis indicate th[...] *normal drainage vessels* from the fe[...] head the intracapsular retinacular vei[...] be compressed by high intra-artic[...] pressure caused by synovitis (Arnol[...] Reiman to be published).

High resistance to flow in the bone ma[...] reduces the nutritive capillary flow ([...] et al 1971, Hernborg *1969*) and it is [...] this circulatory derangement that is re[...] sible for the characteristic changes [...] cancellous bone in osteoarthritis, such as [...] alternating zones of bone necrosis and [...] teogenesis described by *Harrison* et al ([...]

This assumption is supported by [...] findings of Brookes & *Helal* (1968) [...] ligated the femoral and internal iliac [...]

rats and observed a coarsening of s trabeculation and increased iodensity of the femur In patients with a history of severe incompetence of the is pump of the calf and intermittent in- hypertension in the ankle region, Arnoldi et al (1972b) observed characteristic skeletal changes with apposition of new layers of bone in the cortex and a mixture of and sclerosis of the lamellae of ous bone

The findings by Tc-PP scanning were identical in patients with painful osteoarthritis and the intraosseous engorgement-pain syndrome Recently, Bach Christensen & Arnoldi (in press) observed by means of autoradiographical and histochemical analyses of the osteoarthritic femoral head and the synovial membrane that ^{99m}Tc-phosphate accumulated in areas of new bone formation, especially in immature newly formed bone, while the uptake in the synovium was minimal

The findings mentioned in this section may indicate that intraosseous stasis is induced by blockage of extraosseous intracapsular drainage vessels Changes in skeletal metabolism follow as a result of impaired nutritive flow One of the results of this disturbance – new bone formation – is noted on the Tc-PP scan long before it can be seen, for instance as osteophytes, on the X-ray Thus, there is some evidence that the intraosseous engorgement-pain syndrome and osteoarthritis may be two stages of the same pathological process

REFERENCES

Åstrom, J (1975) Peroperative effect of fenestration upon intraosseous pressure in patients with osteoarthritis of the hip *Acta orthop scand* **46**, 963–967

Arlet, J, Ficat P & Sebbag O (1968) Intéret de la mesure de la pression intra médullaire dans le massif trochantérien chez l'homme en particulier pour le diagnostic de l ostéonécrose fémoro-capitale Rev Rhum **35**, 250–256

Arnoldi, C C & Linderholm, H (1971) Intracalcanean pressures in patients with different forms of dysfunction of the venous pump of the claf *Acta chir scand* **137**, 21–27

Arnoldi, C C & Linderholm, H (1972) Fractures of the femoral neck I Vascular disturbances in different types of fractures, assessed by means of intraosseous pressure *Clin Orthop* **84**, 116–127

Arnoldi, C C, Lemperg R K & Linderholm, H (1971) Immediate effect of osteotomy on the intramedullary pressure of the femoral head and neck in patients with degenerative osteoarthritis *Acta orthop scand* **42**, 357–365

Arnoldi C C, Linderholm, H & Mussbichler, H (1972a) Venous engorgement and intraosseous hypertension in osteoarthritis of the hip *J Bone Jt Surg* **54** B, 409–421

Arnoldi, C C, Linderholm H & Vinnerberg, A (1972b) Skeletal and soft tissue changes in the lower leg in patients with intracalcanean hypertension *Acta chir scand* **138**, 25–37

Arnoldi, C C, Lemperg, R K & Linderholm, H (1975) Intraosseous hypertension and pain in the knee *J Bone Jt Surg* **57** B, 360–363

Bach Christensen, S & Arnoldi, C C Radionucleide uptake of ^{99m}Tc-phosphate compounds in the human osteoarthritis femoral head elucidated by autoradiography, sample counting and comparative histological histochemical studies *J Bone Jt Surg* (accepted for publication 1979)

Brookes, M & Helal, B (1968) Primary osteoarthritis venous engorgement and osteo- [illegible] 50 B 493 504

[illegible] *Surg* **35** B 598–626

Helal, B (1965) The pain in primary osteoarthritis of the knee *Postgrad med J* **41**, 172–184

Hernborg J (1969) Elimination of Na^{131} from the head and the neck of the femur in unaffected and osteoarthritic hip joints *Arthr and Rheum* **12**, 30–35

Hietala S O & Åstrom J (1977) The effect of fenestration on intraosseous drainage in osteoarthritis of the hip *Acta orthop scand* **48**, 80–85

Hoffer P B & Genant K K (1976) Radionucleide joint imaging *Sem Nucl Med* **6**, 121–132.

Lemperg R K & Arnoldi C C (1978) The significance of intraosseous pressure in normal and diseased states with special reference to the intraosseous engorgement pain syndrome *Clin Orthop* **136**, 143–156

Lynch J A (1974) Venous abnormalities and in

traosseous hypertension associated with osteoarthritis of the knee In *The knee joint* Proceedings of the International Congress Rotterdam 1973, Excenpta Medica, Amsterdam, American Elsevier Publication Co Inc, New York

Mériel, P, Ruffié, R & Fournié, A (1955) La phlebographie de la hanche dans les coxarthroses *Rev Rhum* 22, 238–241

Phillips, R S (1966) Phlebography in osteoarthritis of the hip *J Bone Jt Surg* 48 280–288

Subramanian, G & McAfee, J G (1971) A new complex of ^{99m}Tc for skeletal imaging *Radiology* 99, 192–203

... M D, Department of Orthopaedic Surgery, Rigshospitalet DK

cta orthop scand *51*, 29–35, 1980

THE EFFECT OF THE THICKNESS OF THE CORTICAL BONE ON BONE FORMATION BY OSTEOPERIOSTEAL GRAFTS

A Comparative Study Employing Routine Histological Stains and Triple Fluorochrome Labelling

Mikko Poussa Jens Rubak & Veijo Ritsilä

The Orthopaedic Hospital of the Invalid Foundation, Helsinki

The bone-forming capacity of free periosteum was compared with that of 100 µm thick osteoperiosteum and periosteum with full thickness cortex taken from the tibia of 6-week-old rabbits. Altogether 78 rabbits were operated on

The results revealed that the osteogenic capacity of free periosteum and 100 µm thick osteoperiosteum was about the same, and that osteoperiosteum with full thickness cortex was inferior in this regard

Key words bone formation, osteogenesis, periosteum, osteoperiosteum, thickness of osteoperiosteal graft

Accepted 15 v 79

In a previous study (Poussa & Ritsila 1979) the osteogenic capacities of free periosteum and 100 µm thick osteoperiosteum were compared The study revealed that the bone-forming capacity of free periosteum was faster and more vigorous. The cortical bone had a suppressing effect upon proliferation of periosteal cambium cells.

The new bone both in free periosteal and osteoperiosteal grafts is produced by the cambium layer cells (Tonna & Cronkite 1963, Ritsilä et al 1972, Ritsilä & Alhopuro 1973, Poussa & Ritsila 1979) In osteoperiosteal grafts resorption of the cortex occurs first and then proliferation of the cambium cells. It was proposed that a thinner layer of bone attached to the periosteum would be less impeding for the osteogenesis than a thick cortical layer A study was therefore made to compare the bone-forming capacities of free periosteum, 100 µm thick osteoperiosteum and osteoperiosteum with full thickness cortex

MATERIAL AND METHODS

Series 1

In this series the osteogenic capacity of free periosteum was compared with that of 100 µm [illegible] The series comprised 53

[illegible]

Lorenzi 1970) Both grafts were taken from the proximal third of the medial facet of the tibia The periosteal graft was taken by stripping, the osteoperiosteal graft was detached as a whole with a circular saw The cortex was made thinner by reaming the excess bone from the medullary side of the graft The 100 micron thickness was checked with an operating microscope. Some osteoperiosteal grafts were detached with a sharp knife Thereafter these two graft types were fixed to two adjacent lumbar vertebra between the spinous and mamillary processes. There were thus 82 histologically studied periosteal and osteoperiosteal grafts and 24 periosteal and osteoperiosteal grafts studied with triple fluorochrome labelling

001–6470/80/010029–07$02.50/0







Figure 1. Low power photomicrograph of the lumbar vertebra 3 days postoperatively (×4). There is marked proliferation in the periosteum (arrow). This is better seen in the higher magnification (×…) on the left, where osteoid-like material can be seen between the proliferating cells. The 100 micron thick osteoperiosteum looks inactive, also in the higher magnification on the right (× 100) (van Gieson). (Fb=fibrotic layer, CL=cambium layer, C=cortex)

eries 2

The second series comprised 25 six-week-old rabbits with 50 periosteal and 50 osteoperiosteal grafts with full thickness cortex The bone marrow was rinsed out with Ringer's solution.

The rabbits were killed 3, 4, 5, 6, 7, 8, 10, 14, 18, 21, 28, 42 and 84 days after grafting The histological specimens were prepared according to the same method as in a previous study (Poussa & Ritsilä 1979) In series 1 triple fluorochrome labelling was carried out in 12 rabbits according to the following scheme

Postoperative labelling

No. of animals	Tetrac 50 mg/kg	Haematoporp 300 mg/kg	DCAF 20 mk/kg
	Day	Day	Day
6	5	10	15
6	15	20	25

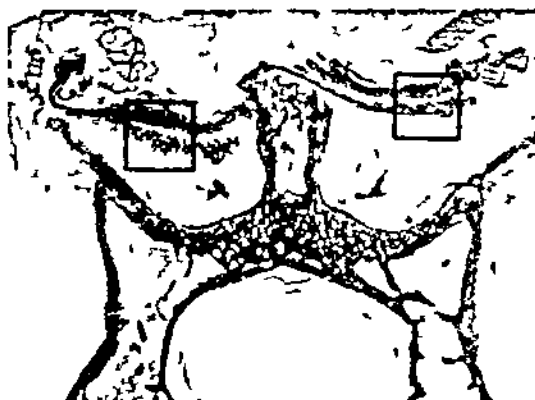
The rabbits were killed 2 days after the last labelling The specimens were fixed in 70 per cent alcohol for 24 hours, followed by dehydration in rising alcohol series. Methylmethacrylate was used for embedding, 150 µm sections were cut and polished to 100 µm thickness. The sections were studied with a fluorescence microscope with UV excitation, and photographed with a standard photomicrographic apparatus.

RESULTS

Series 1

Histology

3–4 days. After 3 days marked proliferation of the cambium layer can be seen in the grafted periosteum. Numerous spindle







igure 2 Low power photomicrograph of the lumbar vertebra 5 days postoperatively (×4) New bone as been formed by both the periosteum on the left and the 100 micron thick osteoperiosteum on the ght The immature structure of the newly formed bone is better seen in the higher magnifications (×125) (van Gieson)
Fb=fibrotic layer, NB=new bone, C=cortex)

naped, round and ovoid cells as well as steoid-like material are seen among the cells Figure 1)

In the 100 µm osteoperiosteum no such cell proliferation is observed The cambium layer etween the fibrous layer and the cortex eems inactive (Figure 1)

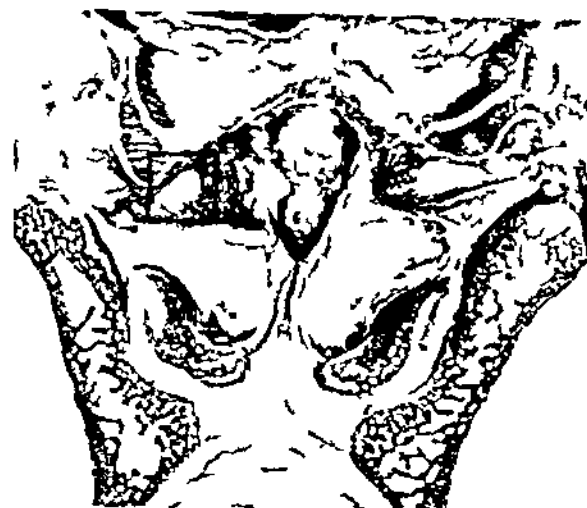
After 4 days the first signs of cartilage and one formation are seen in both grafts.


–8 days The free stripped periosteum has ormed bone The formed bone is structurally mmature and coarse-fibred In some sections o cartilage can be seen (i e 5 days ostoperatively) (Figure 2)

In the 100 µm osteoperiosteum there is lso formation of new bone This woven bone seen between the periosteum and the cortex Structurally the new bone is similar to that formed by the free periosteum (Figure 2) Loose connective tissue is seen between the fibrous layer of the periosteum and the new bone Qualitatively the microscopic picture of the osteogenic process appears identical in both graft types.

10–18 days The grafted periosteum has in all sections formed a cartilage-bone bridge between the spinous and mamillary processes (Figure 3) Typical secondary cartilage cells are seen between the bone and the cartilage

The 100 µm periosteum has reached the same stage of osteogenesis. Bone and cartilage are consistently seen between the periosteum and the cortex (Figure 3)





stoperatively Cartilage magnification (x 11)

21 days There is a uniform bony bridge between the fixation points of the grafts. The new bone formed is still structurally immature and osteoblasts line its trabeculae There is no difference between the developmental stage in the two graft types

Later on (28–84 days postoperatively) the bone structure matured and resembled that of the neighbouring vertebral processes

Triple fluorochrome labelling

three dyes were seen in all of the sections. the periosteal grafts labelled between 5–15 days tetracyline (yellow dye) was seen facing the underlying muscle haematoporphyrin (red dye) in the middle and DCAF (green dye) in the upper part of the grafted periosteum This revealed that periosteum formed bone in its cambium layer 5–15 days after grafting In the 100 μm osteoperiosteum the dyes appeared in the same order between the cortex and the periosteum (Figure 4)

In the grafts labelled 15–25 days postoperatively the dyes showed up with equal intensity both in the periosteal and osteoperiosteal grafts. The three dyes were distinguishable but there were not such clear-cut colour lines as in the grafts labelled at earlier stages of ossification

Series 2

Histology

1–10 days Free periosteal grafts fo cartilage and bone as described in Se

The most remarkable feature of th teoperiosteum with full thickness cort necrosis and dissolving of the cortical b The nucleoles in the lacunae appeared rounded even though the bony structur disintegrating In some areas there was invasion towards the cortical bone fr periphery There was no cell prolifera the periosteum covering the cortex

11–21 days The cortical bone was dead disarranged There was cell invasion in cortex both from the muscular tissue be the graft and from the periosteum above cortex The cell population consist spindle-shaped ovoid and round cells some osteoclasts were seen (Figure 5). Th was only weak new bone formation in resorption cavities.

28–84 days Resorption of the graft formation of new bone on both sides had gressed so that symmetrical bone bridges grown between the spinous and mamil



igure 4 Transverse section of the lumbar vertebra with periosteal (on the left) and 100 µm os operiosteal (on the right) grafts labelled with the triple fluorochrome method Labelling was started 5 ays postoperatively with tetracycline, followed at 5 day intervals with haematoporphyrine and DCAF, nd the rabbit was killed 2 days later The dyes are seen separately as colour bands The development f new bone appears symmetrical in both grafts (× 5)

rocesses Also the bone structure matured in ne same manner as in Series 1

DISCUSSION

Conventional histological techniques formed ne basis of this investigation and triple uorochrome labelling was used as a complementary method Histological methods eem to be suitable for the study of osogenesis in periosteal grafts, the separate hases of bone formation can be easily ecognized It is not, however, possible to tudy the exact cell kinetics with routine istological methods This has been erformed by using tritiated thymidine Tonna & Cronkite 1963) However, since Milch et al. (1958) demonstrated the binding f tetracycline to regions of new bone ormation this method as well as the various ombinations of different fluorochrome dyes as gained increasing popularity in the study f osteogenic processes.

When bone was formed, cartilage was sually seen first, later to be replaced by new one In some sections in the histological tudy bone was observed 5 days postoperatively in the periosteal and 100 µm thick osteoperiosteal grafts, but there was no trace of cartilage Two days earlier in the periosteal grafts osteoid-like material was seen among the proliferating cells of the cambium layer In series 1 sections 7–14 days postoperatively cartilage was always present, proportionally decreasing with time We do not know the exact mechanism or cause of cartilage formation in osteogenesis, but here the cartilage formation was always temporary and was replaced by bone According to Ham (1930) osteogenetic cells have dual potentiality, being able to form bone or cartilage in response to the degree of vascularization in the area in which they differentiate In Basset's studies (1962) bone was formed in the culture media when a high oxygen pressure was used, and cartilage and tendon like tissue in lower oxygen concentrations. Also the effect of stretching or compressing the culture can be explained by the differences in oxygen pressure

During the first days tissue fluids aid the nutrition of the grafts but as the cell proliferation progresses the development of circulation should progress with the same speed or anoxia occurs with consequent





Figure 5 Low power photomicrograph of the lumbar vertebra 21 days postoperatively Free per graft on the left has formed a bone bridge On the right osteoperiosteum with full thickness cortex re solving (×5) On the right in the higher magnification (×125) there is cell invasion from the rounding tissues, from the periosteum above and the muscle beneath Some osteoclasts (OC) formation of new bone (NB) (H–E stain)
(P = periosteum, OB = old bone)

cartilage formation Under ideal environmental conditions during the first 5 days bone can probably be formed directly through the activity of the cambium layer cells. During the period 7 to 14 days postoperatively cartilage formation was consistently seen, during this period cell proliferation is probably so profuse that relative anoxia frequently occurs resulting in cartilage formation

In an earlier paper (Poussa & Ritsilä 1979) a hypothesis was presented that a thinner cortical bone layer attached to the periosteum could in theory result in better osteogenesis than the 200 micron thick osteoperiosteum The results of the present study seem to confirm this theory Free periosteum was osteogenically similar to 100 micron thick osteoperiosteum The only difference was the more vigorous proliferation of the cambium layer cells during the first 3 postoperative days. The easier development of circulation in the periosteal graft may be the main reason for the differences between these two grafts.

Some previous experimental studies (Trinci 1912, Davis & Hunnicut 1915, Melcher & Accursi 1971) have dealt with osteoperiosteal grafts. New bone formation was uniformly observed Unfortunately the authors do not give exact details about the thickness of cortical part of the graft Keith (1934) Siffert (1955) studied osteogenesis w bare cortical shavings without periost Keith used cortical shavings from the radius. New bone formation was observed young animals provided that there were too many fractures in the graft. In Siffe studies adult rabbits were used and the material consisted of tibial shavings. result the shavings were mainly destroyed a very strong phagocytosis. The difference between the above-mentio studies and the present one is that here cortical shavings with periosteum were and new bone formation was consist achieved

There are many earlier studies conce the reorganization of osteoperiosteal gr with full thickness cortex (Axhausen Vainio 1957, Puranen 1967). Compa with the present study is difficult becau the different experimental circumstances the present study the time lag betw transplantation and new bone formation 3 weeks in the case of osteoperiosteum full thickness cortex. In Vainio's study cer callus was seen 2 weeks after transplant

his rabbits were full-grown and ours 6-
-ek-old In our experiment the grafts were
-d between the tops of the spinous and
amillary processes and Vainio's grafts
re deep in the muscle tissue near the in-
-vertebral joint where the nutrition is
tter

From the present study we conclude that
o a thin cortical component of an os-
operiosteal graft has, during the first 3 days,
inhibiting effect on the proliferation of the
mbium layer cells. Because circulation is
andatory for osteogenesis (Trueta 1963) the
lay in the formation of circulation may
plain the slight differences between the
riosteum and the 100 micron thick os-
operiosteum These circulatory studies will
reported later

EFERENCES

lhopuro S (1978) Premature fusion of facial sutures with free periosteal grafts. *Scand J plast reconstr Surg*, Suppl 17

xhausen W (1956) The osteogenetic phases of regeneration of bone A histological and experimental study *J Bone Jt Surg* **38** A, 593–600

isset, C A. L (1962) Current concepts of bone formation *J Bone Jt Surg* 44-A, 1217–1244

avis, J S & Hunnicut, J A (1915) The osteogenic power of periosteum with a note on bone transplantation *Ann Surg* **61**, 672–685

Ham, A W (1930) A histological study of the early phases of bone repair *J Bone Jt Surg* *12, 827–844*

Keith W S (1934) Small bone grafts. *J Bone Jt Surg* **16**, 314–330

Melcher, A H & Accursi, G E (1971) Osteogenic capacity of periosteal and osteoperiosteal flaps elevated from the parietal bone of the rat *Arch oral Biol* **16**, 573–580

Milch R A, Rall, P & Tobie, J E (1958) Fluorescence of tetracycline antibiotics in bone *J Bone Jt Surg* 40-A 897–910

Olerud, S & Lorenzi, G L (1970) Triple fluorochrome labelling in bone formation and bone resorption *J Bone Jt Surg* 52-A 274–278

Poussa, M & Ritsila, V (1979) The osteogenic capacity of free periosteal and osteoperiosteal grafts. *Acta orthop scand* **50**, 491–500

Puranen, J (1967) Reorganization of fresh and preserved bone transplants. *Acta orthop scand*, Suppl 92

Ritsila, V, Alhopuro, S & Rintala, A (1972) Bone formation with free periosteum. *Scand J plast reconstr Surg* **6**, 51–56

Ritsila, V & Alhopuro S (1973) The repair of bone defects with free periosteum. *Acta orthop scand* **44**, 137

Siffert, R S (1955) Experimental bone transplants *J Bone Jt Surg* 37-A 742–758

Tonna E A & Cronkite, E P (1963) The periosteum Autoradiographic studies on cellular proliferation and transformation utilizing tritiated thymidine *Clin Orthop* **30**, 218–232

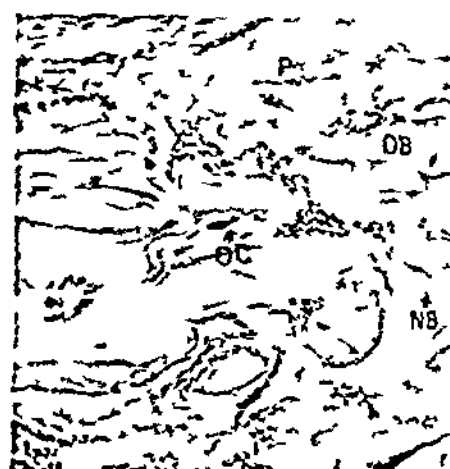
Trinci U (1912) Experimentelle Beitrag zum Studium der Periostuberpflanzungen *Z orthop Chir* **30**, 69–85

Trueta, J (1963) The role of the vessels in osteogenesis *J Bone Jt Surg* 45-B, 402–418

Vainio, S (1957) Transplantation of bone *Ann Chir Gynaec Fenn* **46**, Suppl 68

orrespondence to Mikko Poussa M D, The Orthopaedic Hospital of the Invalid Foundation, Tenholantie , Helsinki, Finland





rounding tissues from the periosteum above and the muscle beneath Some osteoclasts (OC formation of new bone (NB) (H E stain)
(P—periosteum OB=old bone)

cartilage formation Under ideal environ mental conditions during the first 5 days bone can probably be formed directly through the activity of the cambium layer cells During the period 7 to 14 days postoperatively cartilage formation was consistently seen during this period cell proliferation is probably so profuse that relative anoxia frequently occurs resulting formation

In an earlier paper (Poussa & Ritsila 1979) a hypothesis was presented that a thinner cortical bone layer attached to the periosteum could in theory result in better osteogenesis than the 200 micron thick osteoperiosteum The results of the present study seem to confirm this theory Free periosteum was os teogenically similar to 100 micron thick os teoperiosteum The only difference was the more vigorous proliferation of the cambium layer cells during the first 3 postoperative days The easier development of circulation in the periosteal graft may be the main reason for the differences between these two grafts

Some previous experimental studies (Trinci 1912 Davis & Hunnicut 1915 Melcher & Accursi 1971) have dealt with osteoperiosteal grafts New bone formation was uniformly observed Unfortunately the authors do not give exact details about the thickness o cortical part of the graft Keith (1934) Siffert (1955) studied osteogenesis util bare cortical shavings without periost Keith used cortical shavings from the radius New bone formation was observ young animals provided that there wer too many fractures in the graft. In Sif studies adult rabbits were used and the d material consisted of tibial shavings. result the shavings were mainly destroye a very strong phagocytosis The difference between the above-ment studies and the present one is that here cortical shavings with periosteum were and new bone formation was consist achieved

There are many earlier studies conce the reorganization of osteoperiosteal g with full thickness cortex (Axhausen 1 Vainio 1957 Puranen 1967). Compa with the present study is difficult becau the different experimental circumstance the present study the time lag betw transplantation and new bone formation 3 weeks in the case of osteoperiosteum full thickness cortex. In Vainio s study os callus was seen 2 weeks after transplanta

.cta orthop. scand. 51, 37–41, 1980

CHRONIC RECURRENT MULTIFOCAL OSTEOMYELITIS

A New Clinical-Radiological Syndrome

LUDVIG FJELD SOLHEIM[1], BERNHARD PAUS[1], KJELL LIVERUD[2] & ERLING STOEN[3]

[illegible]

Chronic recurrent multifocal osteomyelitis is characterized clinically and radiologically by multiple, sometimes symmetrical, infectious bone lesions and a prolonged course over several years with relapses and new lesions. The distribution of the osteolytic bone lesions follows the pattern of acute *haematogenous osteomyelitis in infancy and childhood.* The aetiology and pathogenesis of this disease is unclear. A 5-year-old girl with this disease and 19 similar cases from the literature are reviewed.

Key words: osteomyelitis, multifocal lesions, chronic recurrent disease

Accepted 9.viii.79

Giedion et al. (1972) reported four children with a subacute or chronic symmetrical osteomyelitis. Since then 13 other cases have been reported by Gustavson & Wilbrand (1974), Probst (1976) and Probst et al. (1978) and the term chronic recurrent multifocal osteomyelitis (CRMO) has been suggested for this condition. Another two cases with a similar condition have been reported by Kerpert & Campbell (1970) and Willert & Enderle (1977). A further report of a girl with CRMO is presented in this article.

CASE REPORT

The patient was a girl who limped on one leg (which one) for a week at 4 years of age. Clinical and radiological examination at that time was normal. A year later, at the age of 5 years, she was admitted to the hospital after 3 months of pain on her left leg and increasing pain and swelling in her left ankle. Her general condition was good. She was without fever. She presented swelling and tenderness of her left ankle and moderate ankle joint effusion.

On admission skeletal roentgenograms showed lesions in both distal tibial metaphyses, in the left distal tibial epiphysis, in the left talus (Figures 1, 2) and also in the left distal femoral epiphysis (Figure 3). Skeletal X-ray survey was otherwise normal. Skeletal scintigrams (100 MBq 99m Te-Sn-diphosphonate i.v.) showed pathologically increased activity in the left distal tibia and the left talus, corresponding to the X-ray findings, and also in the right sacroiliac joint.

The ESR was 50 mm/hour and the white cell count 29,000/mm³. The alkaline phosphatasis was 486 units/l (normal for her age), the antistreptolysin titre (AST) 250 units/ml (slightly elevated) and the antistaphylococcal titre (ASTA) 4.0 units/ml (normal). The Tuberculin test, Widal's test and tests for rheumatoid factor and antinuclear factor (ANF) were all negative. Serum electrophoresis was normal except for a little increase in α-2 globulin and the quantitative serum immunoglobulin assay and c-reactive protein (CRP) were normal. From an open biopsy










Figure 1 Osteolytic lesion in the right distal tibial metaphysis

Figure 2 Osteolytic lesions in the left distal tibial metaphysis, in the medial part of the tibial epiphysis and in the distal end of the left talus




Figure 3 A defect in the lateral part of the left distal femoral epiphysis an osteomyelitic focus or a developmental radiolucency?

of her left distal tibial metaphysis the histopathological findings showed a nonspecific in ammatory process with only slight infiltration of plasma cells, and the aerob c and anaerobic cultures from the tissue showed no growth.

A diagnosis of CRMO was made and the girl was dismissed without treatment or restrictions. ...e symptoms and signs subsided during the next months and the ESR and white cell count gradually became normal. In the following 10 months she has been in good health and symptom-free.

ISCUSSION

... predominately affecting children and escents, is characterized clinically by an onset of local swelling and pain in affected bones, usually accompanied by a low grade fever and moderately elevated ESR in the absence of general illness Joint associated with the involvement of articulating bones seldom occur according to Probst et al (1978) They also reported 6 out of 13 patients with concomitant palmoplantar pustulosis

In contrast to the multifocal, sometimes symmetrical radiological findings (Table 1) the symptoms may be related to only some of the bone lesions During its subacute or chronic course recurrent periods of ex acerbations or relapses occur after varying in tervals. The mean duration of the disease is 6 years (range 1–15 years) but subsequent lesions have occurred after 3 to 6 years without symptoms (Probst et al. 1978).

The sites of predilection follow the pattern of acute haematogenous osteomyelitis in infancy and childhood i.e, the metaphyses of the long and short tubular bones. The proximal and distal tibial metaphyses, the distal femoral metaphyses as well as the sternal ends of the clavicles are particularly

Table 1 The distribution of bone lesions in 20 patients with CRMO (19 cases from the literature and one case reported here)

	Right	Left
Mandible	1	1
Clavicula	7	8
Costa		1
Sacroiliac joint	1	1
Pubis	2	1
Humerus	2	
Radius	3	1
Femur	3	6
Tibia	15	15
Fibula	5	4
Metacarpal		5
Metatarsal	3	
Talus		1
Sternum	3	
Spine	12	

Number of bones affected 15 Number of bone lesions 101, mean 5 lesions per patients.

prone to be affected (Gustavson & Wilbrand 1974, Probst 1976). Our patient seems to be the first reported with lesions in the talus and probably in the epiphyses, however, in the epiphyses growth irregularities are quite common Radiologically, there are osteolytic bone lesions with an inflammatory component and reactive changes Immediately adjacent to metaphyseal growth plates, there are numbers of small rounded lacunar lesions while in the flat bones the sclerotic reaction tends to be more diffuse (Giedion et al 1972, Probst et al 1978) Skeletal scintigrams may be helpful in detecting new lesions

The aetiology and pathogenesis of the disease is unclear Cultures of bone biopsy material and blood usually show no growth (Giedion et al 1972, Probst et al 1978). Giedion et al. (1972) postulated that this disease might be an autoimmune disease of bone, but usually an extensive search for humoral and cellular immunological or haematological defects, as well as rheumatoid arthritis, is unsuccessful The histopathological findings are usually non-specific, indicating a chronic inflamma process (Probst et al. 1978), but sometim plasmacellular osteomyelitis may encountered (Giedion et al. 1972, Willert Enderle 1977) However, CRMO can be d tinguished from plasmacellular osteomyeli which is a primary, monofocal, chron haematogenous osteomyelitis caused *staphylococcus aureus* (Exner 1970). Multip symmetrical bony lesions are seen in neg children with sickle-cell anaemia bone infar (Bohrer 1970) or salmonella osteomyeli (Engh et al 1971), but the radiological pictu is quite different Round cell sarcoma bo metastases, fibrous dysplasia and eosinophi granuloma may cause radiological differenti diagnostic problems in monofocal lesions

In the treatment of CRMO antibiotics ha no obvious effect on the course of the diseas Corticosteroids have been tried during the e acerbations (Probst et al 1978) The prognos is good, but the course prolonged. Corre diagnosis of CRMO is important in order avoid unnecessary diagnostic procedures treatment Once the diagnosis has been e tablished the radiological follow-up should kept to a minimum

REFERENCES

Bohrer, S P (1970) Acute long bone diaphyse infarcts in sickle cell disease *Brit J Radio* 43, 685–697

Engh, C A, Hughes, J L, Abrams, R. C Bowerman J W (1971) Osteomyelitis in th patient with sickle-cell disease *J Bone J Surg* 53-A 1–15

Exner G U (1970) Die Plasmacellulär Osteomyelitis. *Langenbecks Arch klin. Chi* 326, 165–185

Giedion, A, Holthusen, W Masel L. F Vischer, D (1972) Subacute and chron "symmetrical" osteomyelitis. *Ann. Radiol* 1 329–342

Gustavson K H & Wilbrand H F (197 Chronic symmetric osteomyelitis. *Acta radiol* 15, 551–557

Keipert, J A & Campbell, P E (1970) Recurren hyperostosis of the clavicles An undiagnose syndrome. *Aust paediat J* 6, 97–104

F P (1976) Chronic multifocal cleido-
,seal osteomyelitis of childhood *Acta*
ol Diagn 17, 531–537
F P, Bjorksten, B & Gustavson, K. H
1978) Radiological aspect of chronic recurrent
multifocal osteomyelitis *Ann Radiol* 21,
115–125
Willert H-G & Enderle A (1977) Multifocale
symmetrische, chronische Osteomyelitis. *Arch*
orthop Unfall Chir 89, 109–113

to Ludvig Fjeld Solheim, Martina Hansens Hospital, 1300 Sandvika, Norway

cta orthop. scand. 51, 43–48, 1980

EFFECTS OF OXYTETRACYCLINE ON SOLUBILITY AND SYNTHESIS OF COLLAGEN IN YOUNG RATS

ARS B ENGESAETER, TRINE UNDERDAL & ROLF LØVSTAD

nstitute for Surgical Research, Rikshospitalet, and Institute for Medical Biochemistry, University of Oslo, orway

In a recent study we demonstrated that the antibiotic oxytetracycline reduces both growth and mechanical strength of bone and skin in young rats. The present study deals with the effects of 14 [illegible]
medication [illegible]
^{14}C proline i [illegible]
medication [illegible]
the femurs and skin of rats receiving oxytetracycline than in controls. No effect of the antibiotic on the rate of collagen synthesis could be demonstrated These findings may indicate that oxytetracycline in young rats causes reduced mechanical strength of bone and skin by interfering with the cross-linking of collagen

Key words bones, collagen, oxytetracycline, rats, skin solubility, synthesis, tetracyclines

Accepted 3 v 79

Antibiotics of the tetracycline group may impair both growth and strength of growing bones (Cohlan et al 1963, Gudmundson 1971a) The nature of this impairment, however, remains unsettled (Uitto 1976) In a previous study (Engesaeter & Skar 1978) we have shown that oxytetracycline reduces the mechanical properties not only of bones, but also of skin As collagen acts as the major supporting framework of both tissues, an effect of oxytetracycline on collagen would be a plausible explanation for these findings.

The purpose of the present study was to [illegible] the influence of oxytetracycline on synthesis and on cross-linking of collagen in bone and skin. Synthesis was assayed by the conversion of ^{14}C-proline to ^{14}C-hydroxyproline (Firschein 1969) Cross-linking of collagen was assessed indirectly by the solubility of collagen in saline solution (Lapière & Nusgens 1976)

MATERIALS AND METHODS

Animals

Twenty four male Wistar rats, initially weighing 32–37 g, were used. Half of the animals received intraperitoneal injections of 2.8 mg oxytetracycline (Terramycin® Intravenous, Pfizer) in 0.5 ml water every 12 th hour for 14 days. In the middle of the period 49 mg/kg was given twice a day The other half of the animals, serving as controls, received corresponding injections of the vehicle Plasma concentrations of the antibiotic were comparable with therapeutic levels in man. Details of the rats and medication are given in a previous paper (Engesaeter & Skar 1978) The same animals were used in both studies

Biochemical analyses were performed on skin and bones (left femur and tibia) from animals killed at the end of the medication period and 3 weeks later Six rats were examined in each group Twenty-four hours before the animals were put to death 15 µCi L-(U-^{14}C)proline (The Radio-

0001-6470/80 010043–06$02.50/0

chemical Centre, Amersham, specific activity 285 mCi/mmol) per 100 g body weight was injected intraperitoneally Blood samples were obtained by heart puncture All materials were stored at −20°C until examined

Bone analyses were performed on the left femur and the proximal part of the left tibia Before the femur was analysed, cartilages and epiphyses were removed The major part of the longitudinal growth of the tibia takes place in the epiphyseal disc near the knee (Tapp 1966) As bone produced during the medication period was of special interest and as the tibia grew about 8 mm during the medication period, the 8 most proximal millimetres were studied in the animals killed at the end of medication In rats killed 3 weeks later 15 mm of the metaphysis had to be examined to be certain that bone produced during the medication period was also included Skin analyses were performed on skin from the back of the rats, i e the most cranial of the three skin specimens used in the mechanical testing (Engesaeter & Skar 1978)

Collagen analyses

Soluble collagen related to total collagen was assessed by modifications of the methods described by Kivirikko et al (1965) and Gudmundson (1971b) Bone and skin specimens were placed in acetone for 7 days with two changes of acetone, dried in air at 35°C for 3 days weighed (dry weight) Each specimen was minced with scissors and homogenized in 1 0 15M NaCl with an Ultra-Turrax® (18K, & Kunkel, Staufen, West Germany) The mogenization was performed for 15 seconds twice with a 30-second interval and in an icebath to prevent warming of the samples. Thereafter the homogenizer was washed in 4 ml 0 15M NaCl for another 15 seconds The two solutions were pooled, extracted in a shaking machine at 4°C for 20 hours and centrifuged at 14000*g* for 4 hours The supernatant obtained was called "the salt soluble" fraction and the precipitate "the insoluble" fraction Both fractions were hydrolysed at 125°C for 18 hours the salt soluble fraction in 4 ml concentrated HCl and the insoluble in 4 ml 6M HCl

As hydroxyproline is practically unique to collagen (LeRoy 1967) the quantitation of collagen was done by measuring the hydroxyproline in the hydrolysates u ng the method of Firschein (1969) The rate of collagen synthesis was assayed by the convers on of ^{14}C-proline to ^{14}C-hydroxyproline (Firschei 1969), as proline first is incorporated into the pol peptide and then hydroxylated to yield hydroxyproline (Urneti al 1966)

The radioactivity was measured in a l scintillation counter (Nuclear Chicago Mark with Dilusolve® (Packard Instr Corp) scintillation solution Counting effic determined by the two channels ratio method, 70 per cent

Serum albumin

Total serum protein was measured by a b method and the albumin fraction of the protein by photometric scanning of a cell acetate gel electrophoresis. Albumin synthesis assessed by measuring in the liquid scintill counter the radioactivity in the albumin frac of another cellulose acetate gel electrophoresis.

Serum iron

Serum iron was assayed by meas spectrophotometrically the coloured ferrozin complex (Bjerve 1976)

Serum copper

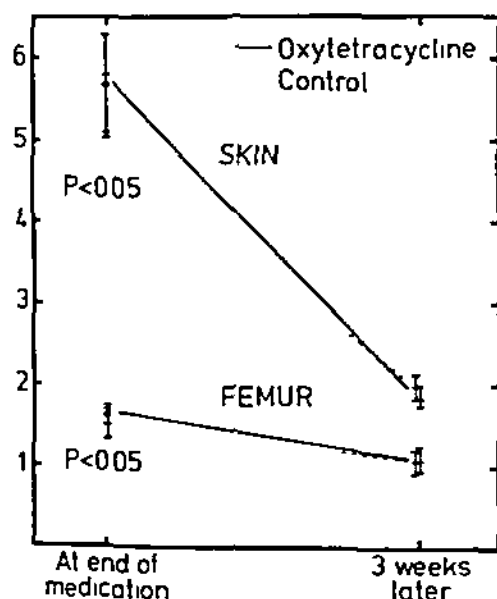
Ninety-nine per cent of rat serum coppe associated with ceruloplasmin and serum co

Statistics

The median with 25- and 75-fractiles was us an expression of the average and the dispersio the measured values Statistical significance evaluated by the Wilcoxon test for two sam (one-tailed test) and differences were consi significant if $P \leqslant 0.05$ (Diem & Lentner 1975).

RESULTS

At the end of the medication period soluble fraction of collagen was signific higher in both skin and femur of the tetracycline treated rats compared controls (Figure 1) In the tibia metapl the same trend was found, the so fraction constituted 1 67 per cent of collagen in the rats receiving oxytetracy and 1 47 per cent in the controls but difference did not reach statistical signif



gure 1 Collagen soluble in 0 15M NaCl lution in percent of total collagen in femur and skin of the oxytetracycline treated rats and of controls Six animals in each group ledian with 25– and 75–fractiles)

=0 07) Three weeks later no significant were observed in the solubility of between animals treated with biotic and controls, neither in bones nor skin.

activity of ^{14}C-hydroxyproline in tibia and femur is given in Table 1 No differences in the rate of collagen is were observed at any time Table 2 the content of collagen related to dry weight of the specimens expressed as per cent hydroxyproline to dry weight No differences were found between the two groups during the observation period

Radioactivity of albumin and concentrations of ceruloplasmin and iron in serum are given in Table 3 No differences between the two groups could be detected from these parameters

DISCUSSION

This study in young rats reveals that 14 days of oxytetracycline medication causes increased solubility of collagen in skin and bone No effect of the antibiotic on the rate of collagen synthesis could be detected

Collagen molecules are normally linked together in fibres by specific covalent bonds known as cross-links. If this cross-linking is disturbed in any way these fibres do not attain the necessary tensile strength (Uitto & Lichtenstein 1976) Defective binding of the collagen molecules within fibres causes not only reduced mechanical properties, but also increased solubility of collagen (Lapière & Nusgens 1976) The term "soluble collagen" is, however, biologically heterogeneous, depending on the nature of the extractants and on the conditions (temperature, ionic strength, pH) of the procedure The more efficient the method of extraction the greater

1 Spec ... roximal tibia metaphysis ... mals in each group

	FEMUR Spec. activity of hyp (dpm/ nmol hyp)		TIBIA Spec activity of hyp (dpm/nmol hyp)		SKIN Spec activity of hyp (dpm/nmol hyp)	
	At end of medication	3 weeks later	At end of medication	3 weeks later	At end of medication	3 weeks later
...TETRA-...CLINE	1 68 (1 46–1 73)	1 19 (1 19–1 20)	2.18 (2 03–2.27)	1 66 (1 65–1 74)	1 09 (0 90–1 22)	0 48 (0 40–0 56)
	NS	NS	NS	NS	NS	NS
...NTROL	1 68 (1 61–1 78)	1 26 (1 16–1 32)	2 23 (1 99–2.49)	1 91 (1 78–2.17)	0 96 (0 88–0 97)	0 53 (0 44–0 55)

Table 2 Amount of hydroxyproline (collagen) in percent of the dry weight of femur proximal t metaphysis and skin of the oxytetracycline treated rats and of the controls Six animals in each gr NS = Not significant (Median with 25– and 75–fractiles)

	FEMUR (Hyp in % of dry weight)		TIBIA (Hyp in % of dry weight)		SKIN (Hyp in % of dry weigh	
	At end of medication	3 weeks later	At end of medication	3 weeks later	At end of medication	3 weeks la er
OXYTETRA-CYCLINE	1 83 (1 79–1 87)	1 87 (1 81–1 93)	1 92 (1 78–2 00)	1 81 (1 76–1 87)	4 35 (4 11–4 58)	7 10 (6 70–7
	NS	NS	NS	NS	NS	NS
CONTROL	1 82 (1 76–1 93)	1 83 (1 74–1 95)	1 80 (1 69–1 91)	1 75 (1 69–1 86)	4 50 (4 24–4 82)	6.57 (6.48 6

is the heterogenity (Jackson & Bentley 1960) Cold neutral saline solutions, as used in our study, are thought to act by disrupting non-covalent interactions and in this way can solubilize noncovalent cross-linked collagen (Bornstein & Traub 1979) In our study increased solubility of collagen was observed in the same bone and skin specimens that previously had been shown to have reduced mechanical strength (Engesaeter & Skar 1978) which may indicate that oxy-tetracycline interferes with the covalent binding of collagen in the fibres. These results compare favourably with those achieved by (1971b) He found reduced strength and increased salt solubility of collagen in fracture callus of oxytetracycline-treated mice

Oxytetracycline could be considered to influence the cross linking of collagen several ways. Firstly, oxytetracycline co have a mode of action similar to that of lathyrogens. These drugs cause red mechanical strength and increased solub of collagen by inhibiting the formation cross-links (Barrow et al 1974) This achieved by inactivating the enzyme l oxidase which catalyses the first step in cross-linking of collagen (Siegel 1976). lysyl oxidase requires copper (Siegel et 1970) and as tetracyclines have chelator pertıes (Ibsen & Urist 1964) oxytetracy may inhibit the enzyme by binding co (Lancet 1978) In our study, however reduction in serum copper was detected. the other hand this does not exclude possibility of local reduction in the tissues

Secondly, the observed effects of

Table 3 Radioactivity of albumin (dpm/g albumin) and concentrations of ceruloplasmin and ir serum of the oxytetracycline treated rats and of the controls Five animals in each group NS = Not significant (Median with 25– and 75–fractiles)

	ALBUMIN Radioactivity of albumin (dpm/μg albumin)		CERULOPLASMIN (IU/ml)		IRON (mol l)
	At end of medication	3 weeks later	At end of medication	3 weeks later	At end of medica
OXYTETRA CYCLINE	2 79 (2 68 3 01)	2 85 (2.43–3 03)	0 23 (0 18–0 26)	0 21 (0 19–0 24)	62.0 (50 0–73
	NS	NS	NS	NS	NS
CONTROL	2 26 1 77 2 57)	2 95 (2 65–3 20)	0 25 (0 19–0 27)	0 23 (0 21–0 24)	77 4 (57 8 8

acycline could be explained by a defect in conversion of pro collagen to collagen, as dermatosparaxis, a heritable disease in -le and sheep (Uitto & Lichtenstein 1976) anticipated that in this condition a Ca^{++} endent enzyme, amino-terminal pro-agen protease, has reduced activity The sence of amino-terminal extension on agen results in deficient formation of the rmolecular cross-links This biochemical ct explains the extremely fragile skin and eased extractibility of collagen which are nd in this condition

The observed increased fraction of soluble agen in the oxytetracycline treated mals could also be considered to be caused an increased degradation of collagen If reased degradation gives increased content collagen cleavage products in the tissues se would have been measured as soluble lagen The observed reduced mechanical ength could then simply be a consequence a reduced amount of collagen Collagenase-oduced collagen fragments would, however, t be expected to accumulate in the tissues they have lost the protection afforded by triple helical conformation of the native olecule and thereby have become suscept e to a variety of extracellular proteases ornstein & Traub 1979) In addition, it ly be difficult to understand why oxy-racycline should increase degradation of llagen in both bone and skin if the produced llagen were completely normal

The solubility of dermal collagen declined oth in oxytetracycline treated and control nimals during the 3 weeks following the edication period Since the rate of collagen nthesis is known to affect the solubility Gross 1958) this may be explained by the duced rate of collagen synthesis observed in oth groups at that moment (Table 1) imilar age-related changes in the solubility f skin collagen in rats have been described y Dawson & Milne (1978)

Tetracyclines exert their antibacterial effect hrough inhibition of the protein synthesis uch an inhibition has also been emonstrated in mammalian cells (Yeh & Shils 1966, Morgan & Ribush 1972, Vazquez 1974) In our study, however, no diminution of the synthesis of albumin or collagen was detected

Based on *in vitro* experiments several authors (Halme et al 1969, Uitto 1975) have proposed that tetracycline selectively inhibits collagen synthesis by binding ferrous iron which is required in the hydroxylation of proline by prolyl hydroxylase (Bornstein & Traub 1979) In our study, however no significant reduction was found, at the end of the medication period, in iron concentration in serum of the oxytetracyline treated rats compared with the controls Furthermore the amount of collagen in relation to dry weight of the bone and skin specimens was unaffected by the medication These findings are in accordance with the statement of Chvapil et al (1974) that the hydroxylation of proline could not be inhibited by administration of chelating agents to intact animals

In conclusion we have shown that oxytetracycline in young rats reversibly reduces the mechanical properties and reversibly increases the salt solubility of collagen in bone and skin Oxytetracycline may cause these effects by interfering with the cross-linking of collagen

ACKNOWLEDGEMENTS

The authors wish to thank Ms Astrid Hunderi for technical assistance and Assistant Professor Sverre Skrede for helpful discussions

REFERENCES

Barrow M V Simpson C F & Miller E J (1974) Lathyrism A review *Quart Rev Biol* **49**, 101–128

Bjerve K S (1976) An automated micromethod for the determination of serum iron *Scand J clin Lab Invest* **36**, 673–677

Bornstein P & Traub W (1979) The chemistry and biology of collagen *The proteins* Vol IV, Academic Press New York (In press)

Chvapil M, McCarthy, D, Madden, J W & Peacock, E. E Jr (1974) Effect of 1,10-phenanthroline and desferrioxamine *in vivo* on prolyl hydroxylase and hydroxylation of collagen in various tissues of rats. *Biochem Pharmacol.* 23, 2165–2173

Cohlan S Q, Bevelander, G & Tiamsic, T (1963) Growth inhibition of prematures receiving tetracycline *Amer J Dis Child* 105, 453–461

Dawson, R & Milne, G (1978) The effects of dietary nitrogen level on the collagen of rat skin *Brit J Nutr* 39, 181–192.

Diem K. & Lentner, C (eds.) (1975) Documenta Geigy *Scientific Tables* 7th ed 810 pp Ciba-Geigy Ltd., Basle

Engesaeter, L. B & Skar, A G (1978) Effects of oxytetracycline on the mechanical properties of bone and skin in young rats. *Acta orthop scand* 49, 529–534

Evans, G W & Wiederanders, R E (1967) Blood copper variation among species. *Amer J Physiol* 213, 1183–1185

Firschein H E. (1969) Collagen and mineral dynamics in bone *Clin Orthop* 66, 212–225

Gross, J (1958) Studies on the formation of collagen II The influence of growth rate on neutral salt extracts of guinea pig dermis. *J exp Med* 107, 265–277

Gudmundson, C (1971a) Oxytetracycline-induced fragility of growing bones. An experimental study in rats. *Clin Orthop* 77, 284–289

Gudmundson C. (1971b) Oxytetracycline-induced disturbance of fracture healing *J Trauma* 11, 511–517

Halme, J., Kivirikko K I, Kaitila, I & Saxén L (1969) Effect of tetracycline on collagen biosynthesis in cultured embryonic bones. *Biochem Pharmacol* 18, 827–836

Ibsen K. H & Urist, M. R. (1964) The biochemistry and the physiology of the tetracyclines With special reference to mineralized tissues. *Clin. Orthop* 32, 143–168

Jackson D S & Bentley J P (1960) On the significance of the extractable collagens. *J biophys biochem. Cytol* 7, 37–42.

Johnson D A., Osaki S & Frieden E (1967) A micromethod for the determination of ferroxidase (ceruloplasmin) in human serums. *Clin Chem* 13, 142–150

Kivirikko K. I, Laitinen O, Aer J & Hal[illegible] (1965) Studies with ¹⁴C proline on the a[illegible] cortisone on the metabolism of collagen [illegible] rat *Biochem Pharmacol* 14, 1445 14[illegible]

Lancet (1978) Collagen in health and dis[illegible] *Lancet i*, 1077–1079

Lapière C. M & Nusgens, B (1976) Col[illegible] pathology at the molecular level. pp. 37[illegible] *Biochemistry of collagen* (Ed. Ramachan[illegible] G N & Reddi A H) 536 pp Plenum P[illegible] New York & London.

LeRoy E C. (1967) The technique [illegible]

[illegible] 4486–4492

Tapp, E (1966) Tetracycline labelling metho[illegible] measuring the growth of bones in the r[illegible] *Bone Jt Surg* 48 B, 517–525

Uit[illegible] R. (1976) Defe[illegible]

Uit[illegible] collagen biosynthesis *in the dental pulp*[illegible] *odont scand* 33, 279–285

Uitto V-J (1976) Collagen biosynthesis [illegible] dental pulp *in vitro* A biochemical st[illegible] rabbit rat and man with emphasis o[illegible] topical effects of glucocorticoids [illegible] tetracyclines. *Proc Finn Dent. Soc* [illegible] (Suppl) 1–30

Urivetzky, M Frei J M & Meilman, E [illegible] Hydroxprolyl soluble ribonucleic acid a[illegible] biosynthesis of collagen. *Arch Bio[illegible] Biophys* 117, 224–231

Vazquez, D (1974) Inhibitors of protein syn[illegible] *FEBS Letters* 40 (Suppl.), 63 84

Yeh S D J & Shils, M E. (1966) Tetrac[illegible] and incorporation of amino acids into pr[illegible] of rat tissues. *Proc Soc exp Biol Med* [illegible] 729–734

Correspondence to Lars B Engesaeter Institute for Surgical Research Rikshospitalet Oslo 1 No[illegible]

ta orthop scand 51 49 56 1980

NTIBIOTICS AND BONE CEMENTS

perimental and Clinical Long-Term Observations

WAHLIG & E DINGELDEIN

partment of Chemotherapy Medical Research Division E Merck Darmstadt Germany

Comparing several antibiotics and different bone cements, the mixture of [illegible]

was observed for more than 5 years. Gentamicin proved to be stable in Palacos R for the whole period of time

The release of 12 antibiotics from Palacos R was evaluated *in vitro* Four other bone cements were included in this study as well in order to evaluate the leaching of gentamicin from these materials The combination Gentamicin Palacos R (GP) showed a 2–3 fold higher and much more prolonged release than did the other mixtures. From this investigation which also included studies of commercially available antibiotic bone cement mixtures, it is quite obvious that there exist distinct differences in the various bone cements as well as in the various antibiotics as regards their qualification for use in alloarthroplasty

Pharmacokinetic studies in patients after implantation of GP showed low gentamicin concentrations in serum (on average 1 8 µg/ml) and urine However in wound exudate derived directly from the vicinity of the implanted cement gentamicin concentrations up to 150 µg/ml were observed Also in tissue samples from the vicinity of the implant high con centrations were measurable for a long period of time (up to 5½ years).

Key words antibiotics bone cements gentamicin Palacos R pharmacokinetics tissue concentrations

Accepted 30 vii.79

entamicin loaded polymethylmethacrylate alacos® R) has been successfully used for bout 10 years in Europe (Buchholz & ngelbrecht 1970) In alloarthroplasty, mainly insertion of total hip endoprostheses, the se of this antibiotic bone cement mixture* as diminished the rate of postoperative nfection markedly (Buchholz & Gartmann 1972 Wannske & Rogge 1976) Furthermore it has been possible for the first time to treat the infection locally, using Gentamicin-Palacos R (GP) while changing the infected endoprosthesis (Buchholz 1973, Carlsson et al 1978)

From extensive experimental and pharmacokinetic studies during this period of time it has been observed that there exists a distinct and very prolonged leaching of antibiotics from bone cements which leads, also *in vivo* to high local antibacterial con-

* Refobacin® Palacos® R manufactured by E Merck Darmstadt, in collaboration with Kulzer & Co., Ltd Bad Homburg v d H Federal Republic of Germany

001 6470 80 010049 08$02.50 0

centrations after GP implantation (Wahlig et al 1972b, Wahlig & Buchholz 1972) This paper deals with the release kinetics of several antibiotics from different bone cements and long-term observations with GP, *in vitro*, in animals and in patients

MATERIALS AND METHODS

Microbiological determination of antibiotics The concentrations in phosphate buffer, serum, urine,

lividomycin, neomycin, erythromycin, dicloxacillin, cefazedone), Micrococcus flavus ATCC 10240 (bacitracin), Bordetella bronchoseptica ATCC 4617 (colistin) Bacillus cereus ATCC 11778 (tetracyclin) Sarcina lutea ATCC 9341 (fucidinic acid, lincomycin, clindamycin) Standard dilutions were always prepared in appropriate media

In vitro *studies* To determine the release of antibiotics from the hardened bone cements, standardized cylinders were made from commercially available GP and two other antibiotic bone cement mixtures. Furthermore, cylinders were prepared from palacos R and four other cements used in THR after having mixed 12 different antibiotics into the polymer powder The cylinders were 25 mm in diameter and 10 mm high The weight was 5 9 g (on average), the volume 4 8 cm^3 and the surface area 17 7 cm^2 In the long term *in vitro* studies with GP, two other cylinder sizes were used as well diameter again 25 mm but height 20 and 3 mm, weight 11 5 and 2 1 g, volume 9 8 and 1 5 cm^3, surface area 25 5 and 12 1 cm^2 The antibiotic concentrations used are indicated in Tables 1–7 The right column in Tables 1–3 indicates the total amount of antibiotics (in mg or units) released during the whole observation time (10 days)

Each cylinder was placed in a large test tube, covered by 20 ml of phosphate buffer, pH 7 4 or pooled human serum and stored at 37° C The antibiotic concentration in the elution fluid was determined at first daily then weekly and finally monthly, the buffer solution or serum being removed and frozen at −20° C until assayed The

In order to estimate the amount of gentamicin in the test blocks after an elution period of 5 years the cylinders were cut into thin slices (– mm) After cutting, the different fragments were dissolved separately in chloroform. Gentamicin then was extracted from the chloroform mixture with phosphate buffer, pH 7 4 and bioassayed

The bone cements used were Palacos R, Surgical Simplex, CMW Bone Cement, Sulfix 6 and Bonemite The following antibiotics were used gentamicin, lividomycin neomycin bacitracin, colistin, tetracyclin fucidinic acid erythromycin, lincomycin clindamycin, dicloxacillin cefazedone Furthermore three commercially available antibiotic bone cement mixtures were included in this study

In vivo *studies* In 14 beagle dogs the medullar femur cavity was opened and after removing 2 ml marrow the cavity was filled with GP

Tissue samples (hematoma after 3 7 10 and 1 days, connective tissue, cancellous bone and cortical bone) were taken from the vicinity of the GP implant after various times intervals between days and 12 weeks, as well as more than months, after operation. The tissues were homogenized in phosphate buffer pH 7 4 and after centrifugation the supernatant was stored at −20°C until assay Bone filings were prepared from the cortical bone samples and eluted in buffer

Clinical studies After total hip replacement operations using GP in 15 patients, the gentamicin concentrations in serum and urine as in the secretion from the wound were assayed

Blood samples were taken 30 min, 3 8, 24 hours and 4 days after implantation of GP After coagulation and centrifugation the serum was stored at −20° C until assay

All urine was collected for 24-hour periods during the first three postoperative days and subsequently on days 10 and 21 after operation.

The wound secretion from a Redon drain was collected for 24-hour periods after operation including the first postoperative day

In 18 patients it was possible to take tissue samples from the vicinity of the implant between 4 days and several months, as well as up to years, after total hip replacement using GP The preparation of the samples for bioassay was the same as described above (see *in vivo* studies)

RESULTS

In vitro *studies* Gentamicin, in the same way as the other antibiotics, is released from the hardened bone cements into buffer solution by diffusion, the rate of which can be read

1 In vitro *release of gentamıcın, cefazedone and colıstın from commercıally avaılable bone cements*

ment	Antibiotic 0 5 g per 34 or 40 g polymer powder	Release µg/ml at day 1	2	3	4	5	6	7	8	9	10	mg day 1 10
s(R) R	gentam cin[1]	110 0	16 4	5 4	2 4	2 2	1 7	1 1	1 5	1 1	1 3	2 86
1		42 0	3 2	1 9	0 7	0 6	0 6	0 3	0 3	0 3	0 2	1 00
2		56 0	3 0	0 6	0 3	0 1	0 1	0 1	0 1	0 05	0 1	1 21
3		44 0	3 7	1 0	0 5	0 3	0 3	0 1	0 2	0 1	0 07	1 01
4		52 8	1 6	0 7	0 5	0 4	0 3	0 2	0 2	0 2	0 1	1 14
s(R) R	cefazedone[1]	93 5	10 3	4 8	3 3	1 9	1 6	1 2	1 1	trace[2]	trace[2]	2 35
1		42 0	3 4	1 5	trace[2]	0	0	0	0	0	0	0 94
2		47 2	2 7	1 3	trace[2]	0	0	0	0	0	0	1 02
3		36 9	2 3	1 1	trace[2]	0	0	0	0	0	0	0 81
s(R) R	col st n-	22 2	5 2	0	0	0	0	0	0	0	0	0 55
3	methansulfonate	7 2	0	0	0	0	0	0	0	0	0	0 14

t ve substance

ce <1 0 µg/ml

ıured *ın vıtro* There was no dıfference ın elutıon ınto phosphate buffer or pooled an serum As far as dıfferent commercıally avaılable bone cements are concerned, thıs study showed that the largest amounts of antıbıotıc were released from cos R Each of the antıbıotıcs used, gentamıcın, cefazedone as well as colıstın, released to a lesser extent from the other cements (Table 1) Thıs was quıte obvıous ın the case of neomycın Whereas thıs

m

er

/3

n ıt was ıncorporated ın another bone cement (Table 3) In thıs respect ıt has to be n ın consıderatıon that the content of mycın ın bone cement A was much ler than ın the mıxture shown ın Table 2 6 g versus 0 5 g per package polymer wder)

Comparıng the release of 12 dıfferent antıbıotıcs from palacos R, gentamıcın and neomycın showed the hıghest and a very longed leachıng Besıde these antıbıotıcs cefazedone, lıncomycın and clındamycın were released to a sıgnıficant extent, followed by tetracyclın and neomycın The dıffusıon of erythromycın, bacıtracın colıstın, fucıdınıc acıd and dıcloxacıllın was comparatıvely poor (Table 2)

In a further study the release of the antıbıotıcs from three dıfferent commercıally avaılable antıbıotıc bone cement mıxtures was assayed These mıxtures contaıned gentamıcın (Refobacın®-Palacos® R), neomycın/bacıtracın (bone cement A) and colıstın/erythromycın (bone cement B)

The results of thıs ınvestıgatıon agaın demonstrated that only ın the case of GP were hıgh antıbıotıc concentratıons attaınable The amount of antıbıotıc released from the other bone cement mıxtures was dıstınctly ınferıor (Table 3)

In a long-term study the leachıng of gentamıcın from palacos R was observed for a perıod of 5 years. A contınuous release of gentamıcın could be demonstrated throughout the whole perıod (Table 4) The largest amounts of antıbıotıc, however, were measurable durıng the first months of dıffusıon Dependıng on the sıze of the test

Table 2 In vitro *release of 12 different antibiotics from Palacos® R*

Antibiotic	Amount[1] per 34 g polymer powder	Release µg/ml at day 1	2	3	4	5	6	7	8	9	10	µg/l [illegible]
Gentamicin	0 5 g	110 0	16 4	5 4	2 4	2 2	1 7	1 1	1 5	1 1	1 3	2 6
Lividomycin	0 5 g	85 9	13 4	5 5	4 9	2 9	3 3	3 0	2 1	1 9	1 8	2 4
Neomycin	0 5 g	48 9	4 7	2 8	2 0	1 7	1 5	1 3	1 1	1 2	0 9	1 2
Bacitracin	55 000 I U	3 7	0 4	0 2	0	0	0	0	0	0	0	0 08
Colistin	0 5 g	46 9	2 3	1 0	0 5	trace[2]	trace	trace	0	0	0	1.02
Tetracyclin	0 5 g	27 2	8 4	6 2	5 3	4 0	4 0	3 3	3 3	2 9	2 2	1 34
Fucidinic acid	1 0 g	1 1	0	0	0	0	0	0	0	0	0	0 02
Erythromycin	0 5 g	18 0	1 9	1 0	0 6	0 6	0 4	0 3	0 3	0 2	0 3	0 54
Lincomycin	0 5 g	68 6	10 5	6 4	5 0	4 9	3 8	2 5	2 3	2 7	2 9	2 18
Clindamycin	0 5 g	43 4	11 6	9 1	7 9	5 2	6 6	5 1	4 4	4 5	4 2	2 04
Dicloxacillin	0 5 g	36 0	6 2	5 1	trace[3]	trace	trace	trace	0	0	0	0 95
Cefazedone	0 5 g	93 5	10 3	4 8	3 3	1 9	1 6	1 2	1 1	trace[4]	trace	2 2

1 active substance
2 trace = <0 5 µg/ml
3 trace = <2 0 µg/ml
4 trace = <1 0 µg/ml

cylinders, between 3 and 8 per cent of the total gentamicin content was released

By cutting the cylinders and analyzing the different fragments separately a continuous increase in gentamicin concentration from the outer parts to the center was demonstrated In the center of the large blocks the full concentration of gentamicin was still detectable

Table 3 In vitro *release of different antibiotics from commercially available antibiotic bone cement mixtures*

Preparation	Release µg/ml at day 1	2	3	4	5	6	7	8	9	10	[illegible]
Refobacin Palacos(R) R											
Gentamicin 0 5 g[1] per 34 g polymer powder	110 0	16 4	5 4	2 4	2 2	1 7	1 1	1 5	1 1	1.3	2 6
Bone cement A											
Neomycin 0 66 g[1] +	61 7	6 0	3 1	2 5	1 5	0 7	0 7	0 7	0 8	0 4	1 56
Bacitracin 55 000 I U per 43 7 g polymer powder	3 3	0 2	0	0	0	0	0	0	0	0	0 07
Bone cement B											
Colistin 0 24 g[1] +	<5 0	0	0	0	0	0	0	0	0	0	0 26
Erythromycin 0 5 g[1] per 36 g polymer powder	10 7	1 2	0 6	0 4	0 1	0	0	0	0	0	

1 active substance

ble 4 In vitro *release of gentamicin from Palacos® R (mg)*

ly on)	Size of Gentamicin-Palacos cylinders		
	ø 25 mm h 20 mm	ø 25 mm h 10 mm	ø 25 mm h 3 mm
	3 080	2 224	1 4 4
	0 150	0 082	0 034
	0 125	0 058	0 010
	0 098	0 059	0 0 5
	0 054	0 039	0 009
i	3 507	2 462	1 482

vo *studies* Gentamicin concentrations nine tissue samples taken at different after operation are summarized in 5 Initially the highest concentrations measured in the hematoma However, concentrations were also achieved in the ective tissue and in the cancellous bone to the implant, particularly during the first and up to 4–8 weeks after operation Even cortical bone, up to 2 weeks post operaconsiderable amounts of gentamicin were ted

macokinetic studies in 33 patients In 15 nts undergoing total hip replacement GP (1 0 g gentamicin base per 1 pack-polymer powder) high concentrations were found in the wound secretion (on average 41–118 μg/ml) (Table 6)

However, only small amounts of gentamicin were found in the serum. The concentration never exceeded 3 μg/ml, and was well below 1 μg/ml 6 to 8 hours after operation This lasted for only about 2 weeks after surgery

In the urine, gentamicin could still be measured several months after total hip replacement, but the concentrations again were comparatively low, even in the first days after the operation

The gentamicin concentrations assayed from tissue samples which were taken from 18 patients between 4 days and 69 months after total hip replacement using GP are summarized in Table 7 Particularly in the connective tissues derived from the immediate vicinity of the implanted GP remarkably high gentamicin concentrations were observed throughout the whole period

DISCUSSION

Antibiotics admixed with bone cements leach out of the hardened plastic material by diffusion The amount, measurable *in vitro,* has been found to be proportional to the surface area of the cement (Wahlig et al

5 Gentamicin concentrations in canine tissues (μg/g wet weight) after implantation of gentamicin – Palacos® R

Time after operation	g gentamicin per 34 g polymer powder	Tissue Hematoma	Connective tissue	Spongiosa	Corticalis
3 days	1 0	7 7		4 9	4 0
7 days	1 0	10 6		5 6	5 8
10 days	1 0			6 8	3 8
2 weeks	0 5	17 1		4 8	0 6
2 weeks	1 0	24 0		4 0	2 3
4 weeks	0 5		3 7	2 8	0 8
4 weeks	1 0		4 5	2 8	0 9
8 weeks	0 5		3 0	0 3	
8 weeks	1 0		2 0	7 7	1 0
10 weeks	1 0		1 7	0 5	0 8
12 weeks	0 5		2 0	1 0	0 4
12 weeks	1 0		4 9	2 9	1 2
22 months	1 0		3 7	2 8	0 6
22 months	1 0		2 8	1 6	0 6

Table 6 Gentamicin concentrations in wound secretion, serum and urine of 15 patients after replacement using gentamicin – Palacos® R

Sample		Time after the operation							
		0 5 h day of operation	3 h	8 h	24 h	1st post oper day	2nd post oper day	4th post oper day	10th post oper day
Wound secretion (μg/ml)	Mean 95% CL				118 1 79 7 156 5	40 8 15 7 65 9			
Serum (μg/ml)	Mean 95% CL	1 82 1 55 2 09	1 34 1 06 1 62	0 72 0 48 0 95	0 13 0 07 0 19			trace*)	
Urine (recovery mg/24 h)	Mean 95% CL				31 72 19 A 44 0	15 95 7 6 24 3	5 65 4 4 6 9		3 13 2 1 4 1
(μg/ml)	range				5 1 76	7 1 39	3 0 16 2		0 7 7 9

*) trace = < 0 05 μg/ml

1972a) In contrast to the findings of Schurman et al (1978) a more efficient elution into serum as compared with buffer was not observed in our experiments.

As far as the kinetics of release is concerned it is quite obvious that no bone cement or antibiotic is suitable in an antibiotic bone cement mixtu alloarthroplasty Comparative studies that only from palacos R were high

Table 7 Gentamicin concentration in tissue samples of patients after THR using gentamicin – Pal

Patient	Time after implantation of THR (months)	Amount of gentamicin per 34 g polymer powder	Gentamicin μg/g tissue (wet weight)		
			connective tissue	spongiosa	cort cal
V AE	4 (days)	0 5 g	14 19 (Hematoma)	14 – 23	1 3 11
H OE	6	0 5 g	8 26	7	0 8
N E	6	0 5 g	–	37 39	0
R A	6	0 5 g	13	6 – 22	
S M	6	0 5 g			1 4
K J	6	0 5 g		17	2 0 3 4
S A	7	0 5 g		10 18	0 3
S F	11	0 5 g	36	23	0 2
F E	11	0 5 g	18		0
R M	12	0 5 g	24	8 12	0
E E	12	2 0 g	11 21	3 11	0 9
R H	16	0 5 g	17 4	3 3	
F B	24	0 5 g	33	9	
F E	23	0 5 g	16		1 7
H G	36	0 5 g	12 17		
H G	42	1 0 g	4	0 4	0
E K	55	0 5 g	23 2		2 0
S A	69	2 0	5 4 6 6	6 6	0

ncentrations and a prolonged antibiotic ease attainable Among 12 different ibiotics only gentamicin and comycin/clindamycin were found to be eased in amounts, which would seem to be ficient, if concentrations are correlated h the antibacterial activity of the compnds. In this respect gentamicin/Palacos R ved to be the most efficient and suitable nbination, a result which has been ifirmed by other investigators (Sattel & bert-Bock 1973, Marks et al 1976) ause of the low concentrations used (1 0 g 34 g polymer powder) this was achieved hout detriment to the physical strength of bone cement (Lautenschlager & Marshall 76, Lee et al 1978), an additional factor ich has to be considered in this context

Since there have been no previous long-m observations dealing with antibiotic ease from bone cements, it was interesting find that gentamicin continued to be eased from palacos *in vitro* for at least 5 ars and that it remained stable during that ne in the hardened material

Long-term observations in animals and rticularly in patients supported these *in ro* findings

In dogs, many weeks or even months after plantation of GP, high gentamicin contrations were measured *in the tissues sur*nding the implant Corresponding results sheep have been reported by Wannske et al 76)

Recently Schurman et al. (1978) reported od therapeutic activity of GP in animal idies recording concentrations consistent th those found in this investigation

In patients the gentamicin concentrations serum and urine were found to be low after tal hip endoprosthesis operations using GP nese findings agree well with previous sults (Wahlig & Buchholz 1972) All fear of xic side-effects is therefore groundless and is possible to administer additional renteral gentamicin or other antibiotics in e usual dosage should this be necessary

In patients treated with GP there were high concentrations of gentamicin in the wound secretion Since the wound exudate derives directly from the area of operation, the gentamicin concentrations indicate the level present at the site of the infection

In the case of contamination or infection, the antibiotic concentrations attainable in the tissues surrounding the implanted endoprosthesis are a good indication of the clinical efficacy of this new type of local antibiotic therapy Due to the reduced blood supply and the penetration barriers there is no other way – even not by parenteral application of high doses – to achieve locally, directly at the site of the infection, amounts of gentamicin exceeding, for many weeks, the concentrations required to kill infecting bacteria (Reichelt et al 1976)

In tissue samples from the vicinity of the implant high concentrations were measurable for a long period of time (up to $5\frac{1}{2}$ years) Again penetration or diffusion barriers may cause these comparatively high tissue levels even after such long periods of time after GP implantation

REFERENCES

Buchholz H W & Engelbrecht, H (1970) Über die Depotwirkung einiger Antibiotica bei Vermischung mit dem Kunstharz Palacos. *Chirurg* **41**, 511–515

Buchholz, H W & Gartmann, H-D (1972) Infektionsprophylaxe und operative Behandlung der schleichenden tiefen Infektionen bei der [illegible] 43, 446–453

tionen bei der totalen Endoprothese 1 Internationaler Kongress für Prothesentechnik und funktionelle Rehabilitation, Wien Experimentelle und klinische Untersuchungen mit Gentamycin Polymethylmethacrylat-Knochenzementen pp 119–135

Carlsson A S, Josefsson, G & Lindberg, L (1978) [illegible] - deep in [illegible] *Bone and*

Lautenschlager, E. P & Marshall, G W (1976) Mechanical strength of acrylic bone cements impregnated with antibiotics. *J Biomed Mater Res* 10, 837–845

Lee, A J C., Ling, R S M. & Vangala, S S (1978) Some clinical relevant variables affecting the mechanical behaviour of bone cement *Arch Orthop Traumat Surg* 92, 1–18

Marks, K E., Nelson, C. L. & Lautenschlager, E. P (1976) Antibiotic-impregnated acrylic bone cement *J Bone Jt Surg* 58-A, 358–364

Reichelt, A, Wahlig, H & Riedl, K. (1976) Antibiotic prophylaxis in allo-arthroplastic hip joint surgery *Arch orthop Unfall-Chir* 84, 249–255

Sattel, W & Nabert-Bock, G (1973) Nachweis von Antibiotika aus Knochenzementen – Experimentelle und klinische Untersuchungen 1 Int. Kongress für Prothesentechnik und funktionelle Rehabilitation, Wien, pp 94–105

Schurman, D J, Trindade, C., Hirshman, H P., Moser, K., Kajiyama, G & Stevens, P (1978) Antibiotic-acrylic bone cement composites – Studies of gentamicin and palacos. *J Bone Jt Surg* 60-A, 978–984

Wahlig, H & Buchholz H W (19 2) [illegible]perimentelle und klinische [illegible] Freisetzung von Gentamycin aus Knochenzement. *Chirurg* 43, 441–445

Wahlig, H, Hameister, W & Grieben, A. ([illegible] Über die Freisetzung von Gentamycin Polymethylmethacrylat. I Experime[illegible] Untersuchungen in vitro. *Langenbecks [illegible] klin Chir* 331, 169–192.

Wahlig, H., Schliep H-J, Bergmann, Hameister, W & Grieben, A (1972b) Üb[illegible] Freisetzung von Gentamycin aus Polyme[illegible] methacrylat. II Experimentelle [illegible] suchungen in vivo *Langenbecks Arch. Klin* 331, 193–212.

Wannske, M & Rogge, D (1976) Experime[illegible] und klinische Untersuchungen zur Infek[illegible] sprophylaxe des prothetischen Hüftg[illegible] kersatzes mit Gentamycin PMMA. 118. T[illegible] der Vereinigung Nordwestdeutscher Chir[illegible] Hamburg

Wannske, M., Trentz, O., Schenck, R. D & [illegible] Ch (1976) Abgabe von Antibiotika [illegible] Knochenzement in infizierte Cortica[illegible] Tierversuch. *Arch orthop Unfall Chir* 139–149

Correspondence to Dr Helmut Wahlig, Department of Chemotherapy, Medical Research Divis[illegible] Merck, Frankfurter Strasse 250, D-6100 Darmstadt 1, Federal Republic of Germany

.orthop scand 51, 57–62 1980

:TAL SENSITIVITY IN PATIENTS WITH METAL-TO-PLASTIC)TAL HIP ARTHROPLASTIES

:S CARLSSON[1], BERTIL MAGNUSSON[2] & HALVOR MOLLER[2]

artments of Orthopaedic Surgery[1] and Dermatology[2], University of Lund,
mö General Hospital, Malmö, Sweden

Out of 134 patients patch tested after total hip replacement (metal to-plastic) 13 were sensitive to one or two of the implanted metals. In a prospective series of 112 patients, nine were sensitive to nickel before and another three developed sensitivity to nickel or cobalt after the arthroplasty In the retrospective as well as in the prospective series the complications could in all cases but one be explained on grounds other than allergy The incidence of contact allergy to nickel before a planned arthroplasty was 12 per cent in females and 4 per cent in males. It is doubtful whether metal sensitivity could be induced by a total hip arthroplasty However, in cases of a pre-existing metal allergy, a certain degree of caution is recommended

Key words arthroplasty, delayed allergy, hip, metal sensitivity

Accepted 11 vi 79

lure of total hip arthroplasties is most ımonly the result of a deep infection or :hanical loosening In recent years, failures ribed to metal sensitivity have been orted (Benson et al 1975, Elves et al '5, Evans et al. 1974, Munro-Ashman & ller 1976) However, these patients were patch tested to metals prior to the ration The connection may therefore be :stioned According to the knowledge of authors only two prospective investigations have been presented, both ling with metal-to-plastic arthroplasties :utman et al 1977, Silvennoinen et al '8)

The object of this investigation was to ermine the incidence of delayed-type allergy materials used in connection with metal-plastic total hip replacement, and whether plantation of prostheses made of stainless steel or cobalt-chromium alloy might induce metal allergy and if so, whether this is of significance as regards the final outcome of the operative procedure

ıancial support was obtained from the Swedish :dical Research Council (project no B 78 17X-37 10C) and the Alfred Österlund Foundation.

PATIENTS

The material consisted of 274 patients operated upon or scheduled for operation with a metal to-plastic total hip arthroplasty between 1968 and 1977 at the Department of Orthopaedic Surgery, Malmo General Hospital. The stem of the prostheses was made of stainless steel (Charnley) or a cobalt-chromium alloy (Vitallium) (mainly the Brunswik or Lubinus designs) The composition of the alloys is presented in Table 1

The patients were divided into the following groups.

Group I 134 patients comprised the retrospective part of the study The patients were patch tested 42 to 71 months after the operation. The postoperative course was uncomplicated in 99 cases. In 35 patients, one or another complication necessitated revision of the arthroplasty in 13

01 6470/80 010057–06$02.50/0

Table 1 Proportions of chromium, cobalt and nickel in the prostheses

	Stainless steel (Charnley)	Vitallium (Brunswik and others)
Chromium	15–20 %	27–30 %
Cobalt	0 %	60–65 %
Nickel	10–14 %	0–4 %

cases deep infection, in 21 mechanical loosening and in one case bone resorption of obscure origin

Group II 112 patients comprised the prospective part of the investigation Patch testing was performed within 3 months before the operation, and all were retested 3 months and 1 year after the operation

Group III Another 28 patients were tested prior to a planned total hip replacement Owing to cancellation of the operation or because of too short an observation time after the operation, these patients were excluded from the prospective investigation However, these patients were included when the incidence of metal sensitivity prior to a total hip arthroplasty was calculated

The distribution of the patients in groups I, II and III acccording to sex and age is given in Table 2

METHODS

The patch tests were performed on the back of the patients with the standard series of allergens recommended by the International Contact Dermatitis Research Group The series of standard allergens includes potassium dichromate 0 5 per cent, nickel sulphate 5 per cent and cobalt chloride 1 per cent, all dispersed in petrolatum These standard allergens were obtained from Trolab (6 B A N Hansens Alle, 2600 Hellerup, Denmark) To this battery was added methyl methacrylate 10 per cent in [illegible] stabilizers used in the cement, hydroquinone [illegible] cent, benzoyl peroxide 1 per cent, and dimet[illegible] toluidine 5 per cent all in petrolatum as w[illegible] gentamicin 10 per cent in petrolatum sometim[illegible] corporated in the cement.

The test substances [illegible]

[illegible] attached to the back with Scanpor surgical [illegible] (Norgeplaster A/S, Harbitzalléen, Oslo, Norw[illegible]) The tests were removed after 48 hours and [illegible] after a further 24 hours (72 hours after applic[illegible] of the tests) Erythema, induration and/or pa[illegible] were required for a positive test.

[illegible] as, for the males, hand eczema during constru[illegible] work with cement (chromium, cobalt)

RESULTS

Retrospective study

The test results are presented in Tab[illegible] Of the 89 patients with a prosthesi[illegible] stainless steel, nine patients showed [illegible] positive patch test to one or two of [illegible] metals Of the 45 patients with a prosth[illegible] made of cobalt-chromium alloy, four pati[illegible] were positive to metals. Thus, altogether [illegible] out of 134 (10 per cent) patients ha[illegible] positive patch test and of these 10 ha[illegible] history of metal sensitivity prior to the op[illegible] tion Positive patch tests were observed [illegible] 6/99 cases (6 per cent) with an unevent[illegible] course compared with 7/35 cases (20 [illegible] cent) when there was a complicat[illegible] ($P < 0.05$) The same number of posit[illegible] patch tests were observed among the co[illegible]

Table 2 Number, sex and age of patients investigated

Part of investigation	Number of patients	Per cent Females	Age at operation or planned operation mean ± s.d.
I Retrospective	134	59	61 ± 8
II Prospective	112	65	65 ± 9
III "Prospective" (not operated)	28	57	66 ± 12

Table 3 Retrospective study

	Number of patients	Months between operation and patch test mean ± s d	Patients with positive tests to metals Co	Cr	Ni	Co and Ni	Cr and Ni	Patients with history of metal sensitivity
less steel								
mplicated	71	71 + 17	1	—	3	1	1	5
plicated	18	57 ± 20	—	2	1	—	—	3
lt chromium alloy								
mplicated	28	49 ± 15	—	—	—	—	—	—
plicated	17	42 ± 32	1	2	1	—	—	2
	134		2	4	5	1	1	10

ed cases regardless of implanted ial, three and four, respectively In no was contact allergy to the constituents of crylic cement found

pective study

the 112 patients in Group II, nine nts, one male and eight females, were ive to nickel before and after the ition (Table 4) Three, who were tive before, showed a positive response metal after the operation, one to nickel two to cobalt None of these three had history of metal allergy

e clinical and radiographic examination of the hip was normal 1 year postoperatively in all cases with a contact allergy to a metal. Four cases were complicated by deep infection but all of these patients had a negative patch test

Contact allergy to the constituents of the acrylic cement was not observed in any patient, either before or after the operation

Of the 28 patients only tested prior to a planned operation (Group III), one man and one woman were positive to nickel Another two women were positive to both nickel and cobalt Moreover, one woman showed a contact allergy to methyl methacrylate

Of all 140 patients tested before a planned

e 4 Prospective study Patients sensitive to metals before and/or after total hip arthroplasty (S s = Stainless steel, Co Cr = Cobalt-chromium alloy)

Sex and age	Prosthesis	Previous implants	History of metal allergy	Patch test results Before	After
F 77	S s	No	No	Neg	Nickel
M 77	Co-Cr	No	No	Neg	Cobalt
F 62	S s.	No	No	Neg	Cobalt
F 72	S s.	No	Yes	Nickel	Nickel
F 60	Co-Cr	No	Yes	Nickel	Nickel
F 60	S s.	No	Yes	Nickel	Nickel
F 75	S s.	No	No	Nickel	Nickel
F 71	Co-Cr	Yes	Yes	Nickel	Nickel
F 45	S s.	Yes	Yes	Nickel	Nickel
F 67	S s.	Yes	?	Nickel	Nickel
F 74	S s	Yes	Yes	Nickel	Nickel
M 57	Co-Cr	Yes	?	Nickel	Nickel

operation (Groups II and III) there was a contact allergy to nickel in 11 out of 89 women (12.4 per cent) and in 2 out of 51 men (3 9 per cent) Contact allergy to cobalt was found in 2 of the 140 cases, both women being also sensitive to nickel

A history of contact allergy to metals was given in 9 and suspected in another 2 of the 13 patients positive to a metal before operation A history of metal sensitivity was never found in patients with a negative patch test

DISCUSSION

Most failures following total hip arthroplasties are due to either mechanical loosening or deep infection The differential diagnosis is based on the following the clinical examination, the radiographic appearance (Bergström et al. 1974), the laboratory investigations, especially the ESR (Carlsson 1978, Reichelt & Brand 1975), the scintimetry (Lindberg et al 1977b) and finally the aerobic and anaerobic cultures of tissue specimens under appropriate conditions (Lindberg et al 1977a) There remain, however, some failures of obscure origin and in such cases intolerance for the implanted material has been suggested

In the case of a deep infection, an increasing radiolucent zone between bone and cement and/or a localized bone resorption, sooner or later will appear (Bergstrom et al 1974) However, very similar radiographic abnormalities were described by Evans et al (1974) in connection with metal sensitivity

Increased incidences of metal sensitivity are described in patients with failed metal-to-metal total hip arthroplasties (Benson et al 1975, Elves et al. 1975, Evans et al 1974 Munro-Ashman & Miller 1976), a finding not verified by Brown et al (1977)

Implantation of metal to-plastic total hip arthroplasty seems to imply a much smaller risk of sensitization Benson et al (1975) found the incidence of metal sensitivity in patients operated upon according to Charnley to be similar to that in controls.

In the retrospective part (Group I) [illegible] present study, 10 per cent of the [illegible] showed a metal allergy Since almost [illegible] these patients had a history of meta[illegible] sitivity prior to operation it is most pr[illegible] that the allergy existed already at tha[illegible] and was not induced by the surgica[illegible] cedure Probably, the same holds true [illegible] previously published retrospective ma[illegible] quoted above

The assumption of a pre-existing [illegible] allergy was confirmed by the results [illegible] prospective material groups II and III [illegible] operation, 12 per cent of the female pa[illegible] and 4 per cent of the males had a c[illegible] allergy to nickel and most of them also [illegible] history of metal sensitivity The figur[illegible] very high for a population in principle w[illegible] skin disease They should be compared [illegible] the incidence of nickel allergy in our e[illegible] material (unpublished) In 1978 this inc[illegible] was 11 0 per cent (14 3 per cent in fe[illegible] and 4 6 per cent in males)

The present results naturally rais[illegible] question of the frequency of metal allerg[illegible] healthy population In a study on 202 h[illegible] twins above 40 years of age, Forsbeck [illegible] (1968) found 12 cases of nickel allergy [illegible] cent) and one case of cobalt allergy [illegible] (1978) studied a female hospital m[illegible] excluding dermatologic cases. Among [illegible] patients representing all adult ages, h[illegible] and clinical examination showed a [illegible] allergy in 9 4 per cent A similar figur[illegible] per cent nickel allergy among wome[illegible] found by Prystowsky et al (1978) when [illegible] testing 1158 healthy subjects. Obvious[illegible] occurrence of metal allergy in patients [illegible] hip arthroplasty may be mainly an expr[illegible] of the incidence in the healthy populatio[illegible]

In the prospective part of our investi[illegible] (Group II) changes from negative rea[illegible] for metals to positive reactions postopera[illegible] were observed in three cases. Patient [illegible] became positive for nickel and patients [illegible] and 3 for cobalt (Table 4) As regards p[illegible] no 3, the positive cobalt reaction wa[illegible] caused by the implant since it was of sta[illegible] steel and therefore did not contain cobalt

likely explanation for the change in this is the sensitization by testing or by a ter effect on a subclinical allergy

ie risk of sensitization by patch testing is rally considered as being low in the rity of substances When testing with ls, however, there is, according to Agrup 3) a definite risk of sensitization where lt and chrome are concerned, but, on the r hand, not with nickel

cases nos. 1 and 2, the patients have me positive for a metal, which was an ral part of the prosthesis Sensitization ooster effect by earlier testing cannot be ded Moreover, there is naturally also oossibility that these patients, in line with no 3, may have been sensitized during time interval between the tests by sure to the allergen in the environment he results we obtained when attempting sensitize guinea pigs to potassium romate and methyl methacrylate by in- ons into the knee joints (unpublished) doubt on whether delayed-type allergy be induced by material used in connec- with total hip replacement None of 40 animals became sensitized In

bout 75 per cent of the animals (Magnusson ligman 1969)

ccording to Deutman et al (1977), elopment of metal sensitivity is rare if al-to-plastic arthroplasties are used Our lts make it doubtful whether sensitization urs at all Development of contact allergy the acrylic cement following total joint lacement was not observed by Deutman et 1977) or by us

The clinical implications of a pre-existing al sensitivity are still doubtful Since itive patch tests were slightly more quent among complicated cases than ong uneventful ones, an allergic reaction to tals may have played a part However, in cases except one, infection or mechanical sening may very well explain the failures til more is known, especially from long term follow-up prospective studies, we recommend that a dermatologist be consulted in cases of known or suspected metal allergy, and the prosthetic material be chosen with regard to the test result To patch test all patients undergoing total joint replacement, as suggested by Deutman et al (1977), seems for practical reasons unrealistic

In cases of metal sensitivity, a prosthesis made of titanium alloy is recommended However, stainless steel is a suitable material in patients with an isolated allergy to cobalt, and a cobalt-chromium alloy is an alternative in cases of isolated nickel allergy

REFERENCES

Agrup G (1968) Sensitization induced by patch testing *Brit J Derm* **80**, 631 634

Benson, M K D, Goodwin, P G & Brostoff, J (1975) Metal sensitivity in patients with joint replacement arthroplasties. *Brit med J* **4**, 374–375

[illegible] (1974)

Bullough B G (1977) Sensitivity to metal as a possible cause of sterile loosening after cobalt-chromium total hip-replacement arthroplasty *J Bone Jt Surg* 59-A, 164–168

Carlsson Å S (1978) Erythrocyte sedimentation rate in infected and non infected total hip arthroplasties. *Acta orthop scand* **49**, 287 290

Deutman R, Mulder, Th. J, Brian, R & Nater J P (1977) Metal sensitivity before and after total hip arthroplasty *J Bone Jt Surg* 59-A, 862–865

Elves, M W Wilson, J N, Scales J T & Kemp, H B S (1975) Incidence of metal sensitivity in patients with total joint replacements. *Brit med J* **4**, 376–378

Evans E M Freeman M A R. Miller A J & Vernon Roberts, B (1974) Metal sensitivity as a cause of bone necrosis and loosening of the prosthesis in total joint replacement. *J Bone Jt Surg* 56-B, 626–642.

Forsbeck, M, Skog E & Ytterborn K H (1968) Delayed type of allergy and atopic disease among twins. *Acta derm venereol (Stockh)* **48**, 192–197

Lindberg L., Carlsson, Å. & Josefsson G (1977a) Use of antibiotic-containing cement in total hip arthroplasty done in the presence of or after deep wound infection. *Proceedings of the Fifth Open Scientific Meeting of The Hip Society*, Chapter 13, pp 170–175, C. V Mosby Co, Saint Louis.

Lindberg, L., Sjostrand, L-O & Mortensen W (1977b) Assessment of the painful total hip arthroplasty with arthrography and bone scanning *Proceedings of the Fifth Open Scientific Meeting of The Hip Society*, Chapter 15, pp 197–209, C. V Mosby Co, Saint Louis.

Magnusson, B & Kligman, A M (1969) The identification of contact allergens by animal assay The guinea pig maximization test *J invest Dermatol 52*, 268–276

Menné, T (1978) The prevalence of nickel allergy among women *An epidemiological study in* hospitalized female patients. *Derm Beruf Umwelt.* 26, 123–125

Munro-Ashman, D & Miller, A J (1976) Rejection of metal to metal prosthesis and skin sensitivity to cobalt *Contact Dermatitis* 65–67

Pirila, V (1975) Chamber test versus patch test for epicutaneous testing *Contact Dermatitis* 48–52.

Prystowsky, S D, Allen A M., Smith, R.W Nonomura, J H Odom, R B & Akers, W (1979) Allergic contact hypersensitivity to nickel neomycin ethylenediamine and benzocaine Relationships between age sex, history of exposure and reactivity to standard patch tests and use tests in a general population. *Arch Dermatol* 115, 959–962.

Reichelt, A & Brand, A. (1975) Das Verhalten der Blutsenkungsgeschwindigkeit nach der Implantation von Totalendoprothesen des Huftgelenkes. *Z Orthop* 113, 900–903

Silvennoinen, T., Karaharju, E Slatis, P *Hannuksela M (1979) Value of epicutaneous* tests for allergy to metals in implantation surgery Proceedings Scand Orthop Ass *Acta orthop scand* 50, 348

Correspondence to Dr Åke S Carlsson, Department of Orthopaedic Surgery Malmo General Hospital S-214 01 Malmo, Sweden

ta orthop scand 51, 63–70, 1980

STUDY OF THE ARTERIAL SUPPLY OF THE PATELLA I THE NORMAL STATE, IN CHONDROMALACIA PATELLAE ND IN OSTEOARTHROSIS

EN BJÖRKSTRÖM & IAN F GOLDIE

partment of Orthopaedic Surgery II (Department of Orthopaedic Surgery, Sahlgren's spital), University of Goteborg, Göteborg, Sweden

The arterial supply to the patella has been studied in 21 specimens. Fifteen were obtained at autopsy and six at amputation Nine of the specimens were normal, six were diagnosed as chondromalacia patellae and six as osteoarthrosis. Micropaque was injected into the arteries, and the Spalteholtz clearing technique was used Radiography was also performed. In addition to previously reported observations, arteries were found to penetrate into the patella from the interior of the quadriceps tendon, from the synovial tissue and from the medial and lateral retinaculae Moreover, it was found that with increasing degree of cartilage destruction the arterial pattern within the patella became disturbed and irregular with formation of anastomoses

Key words patella, arterial supply chondromalacia patella, osteoarthrosis, changed arterial network

Accepted 2 1 79

ondromalacia patellae, which is the mmon term for a sequence of thomorphological events in the patellar rtilage, such as oedema, fibrillation, erosion d fragmentation, can appear in childhood it becomes more common in the teens and ay be regarded as the prelude to osteo- throsis of the patellofemoral joint (Perkins 961)

Despite it being a frequently occurring lment, which according to O'Donoghue 956) has been found in more than 65 per nt of 350 arthrotomies, chondromalacia itellae has attracted little interest with gard to its pathophysiological aspects, such , for example, vascular supply, physical pro- rties with special attention to the hardness the subchondral bone and intra-osseous ressure

For this reason we have made a study, the object of which has been to analyse further the above mentioned pathophysiological aspects A report will be given on the arterial supply of the patella under normal conditions, in chondromalacia patellae and in osteo- arthrosis of the patellofemoral joint

PREVIOUS STUDIES

Arterial supply to the normal patella

Previous studies on the arterial supply to the normal patella have been published by Crock (1967), Scapinelli (1967) and Brookes (1971) Scapinelli's observations will in part be cited Six of the main joint arteries act as channels of blood supply to the patella and

)01–6470/80/010063–08$02 50/0

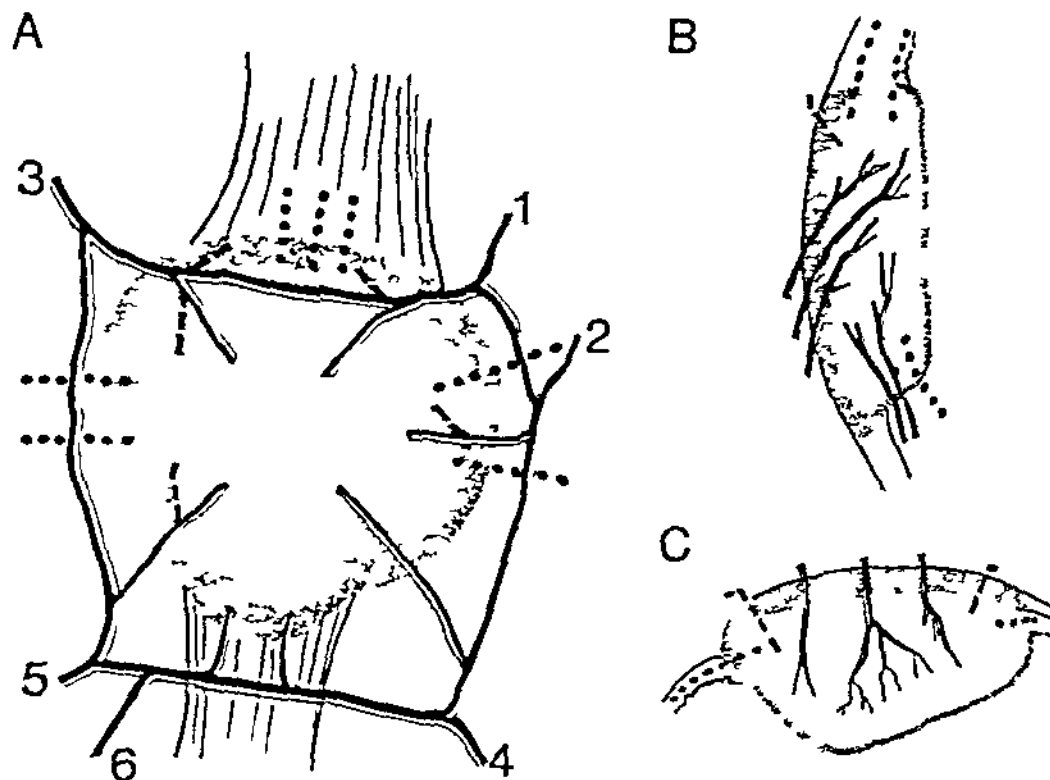


Figure 1A, B, C Schematic drawings of the patella with arterial supply in three planes. 1-6 a main joint arteries ——— represents prepatellar branches entering the bone near its margins represents peripatellar branches (previously not described) entering through the margins of the

these are (Figure 1)

1 The supreme genicular artery,
2. the medial superior genicular artery,
3 the lateral superior genicular artery,
4 the medial inferior genicular artery,
5 the lateral inferior genicular artery,
6. the anterior tibial recurrent artery

The above arteries form the sources of an extra-osseous and an intra-osseous arterial supply to the patella.

Extra-osseous or extrinsic arterial supply
The superior arteries give off descending parapatellar branches, superior transverse branches and prepatellar branches. The inferior arteries give off ascending parapatellar branches, inferior transverse branches and prepatellar branches. The parapatellar and transverse branches give rise to an arterial ring which surrounds the patella. The inferior part of the ring transverse infrapatellar artery runs pos to the patellar ligament. The other pa the ring and the prepatellar arterial net lie in the thin layer of loose connective t which covers the dense fibrous extensio the quadriceps tendon.

Intra-osseous or intrinsic arterial su
There are two main systems of which o represented by the mid patellar arteries w come from the prepatellar network. arteries enter the patella through the ce part of the anterior surface obliquely below upwards and are distributed to chondro-osseous junction in the upper pa the patella. Recurrent branches run bac supply the anterior cortex.

The second system is represented by arteries which come from the infrapatellar artery The apical arteries p

- deep surface of the apex of the patella ween the attachment of the ligamentum ellae and the articular surface They run wards supplying the lowest part of the ella and communicate within the bone h branches of the mid-patellar arteries

Scapinelli (1967, 1968) stated that there s a lack of vascular penetration around the rgins of the bone where tendinous and amentous structures inserted

terial supply in chondromalacia patellae d osteoarthrosis

It has not been possible to find any scription of the arterial supply in chondro-lacia patellae Without particular reference the patella Scapinelli (1968) stated that the incipal changes in senile knees are rtuosities and decreased calibre of the teries, decreased intra-osseous vascularity d ruptures

IATERIAL

ne arterial supply to the patella was studied in specimens, of which six were obtained at nputation of the lower limb for neoplastic sease not involving the knee joint and 15 at itopsy Peripheral vascular disease was not the use of death The ages of the individuals varied om 17 to 70 years and the mean age was 34 ars

IETHOD

s contrast medium for the injection of arteries a ixture of one part Micropaque and two parts 10 r cent formaldehyde solution was used

laterial obtained at amputations (specimens)

The injection was given by hand in the femoral tery at a distance of at least 10 cm from the biofemoral joint space The injecting was done ter the specimen had been stored for 24–36 ours at room temperature according to Mulfinger Trueta (1970) The injection was continued for –6 hours and all leaking vessels were tied off The pressure was about 150 mmHg and this was maintained by a pressure unit for 24 hours during which time the specimen was stored in formaldehyde solution After this time the pressure had decreased only a few mmHg Some 300–500 cm³ of contrast medium was injected into each specimen

Material obtained at autopsy (15 specimens)

(a) In two specimens the same procedure was carried out as for the amputation material
(b) Six specimens were deep frozen immediately following their excision. Injections were performed as in the amputation material when the specimens were thawed
(c) In seven specimens a different procedure was carried out Before taking out the specimen the femoral artery was dissected in the cadaver A catheter was introduced with its tip 10 cm above the tibiofemoral joint space Twenty centimeters of the thigh was covered by an Esmarch bandage The time for filling was 1–1 5 hours after which the pressure unit was applied and left in the cadaver for some 12 hours After resection the specimens were stored in formaldehyde solution

The specimens were deep frozen as this facilitated the cutting up of the specimens into about 7–10 mm thick slices Twelve specimens were divided in the sagittal plane and nine specimens in the transverse plane Previous experience had shown that the slicing of the specimens made the study of the topographic anatomy of the arteries much easier (Peterson et al 1974) After thawing and decalcification the slices were radiographed, in eight specimens radiography of the slices was also carried out before decalcification

The Spalteholtz clearing procedure was also performed (Crock 1967)

RESULTS

Arterial supply to the normal patella (n = 9)

Earlier investigations could be verified In addition the following observations were made which have not previously been described

I Extrinsic arterial supply

(a) On sagittal sections in five cases arteries were observed to penetrate into the base

MPA

AA

Figure 2a. Sagittal section of a normal patella from a 63-year-old man. Radiograph after decalcification. At top, quadriceps tendon (Q) Dominating mid patellar arteries (MPA) and small apical arteries (AA) (× 2)



Figure 2b The upper half (×5) of the illustrated in Figure 2a containing the MP the arteries of the quadriceps tendon pen the base of the patella into its interior A from the synovial tissues (SA) also penetra the interior of the patella.

of the patella from the interior of the quadriceps tendon (Figure 2A and B). Moreover, arteries running superficially, anterior to the quadriceps tendon, were seen to enter into the proximal part of the patella (Figures 2B and 6)

(b) On transverse sections the medial pa the peripatellar arterial ring was loc deep to the patellar retinacula.

(c) On transverse sections arteries were s to penetrate the anterior surface of t patella close to the retinacular insertion the medial side and occasionally on t lateral side

(d) On transverse sections arteries were se to penetrate the patellar margin on bo the medial and lateral sides. These arter arose from arterial networks locali posteriorly in the synovial tissue and o the posterior surface of the retinacu (Figure 3)

(e) On sagittal sections a rich net of arter could be demonstrated to arise from t arteries in the synovial tissue at its attach ment to the patellar base (Figure 2B) an apex. These arteries penetrated into th interior of the patella.



ure 3 Transverse section of a normal patella n a 27-year-old woman The medial retin la (M) insert to the left Radiograph after alcification
Numerous mid-patellar arteries thinning into filamentous arteries radiating towards subndral area
Medially some small arteries penetrate the cor il bone into the interior Laterally, a small ery (*) arises from an arterial network in the eral retinacula and penetrates into the bone ore the cartilage



Figure 4 Sagittal section of a normal patella from a 22 year-old man Radiograph after decalcification At top quadriceps tendon (Q) Apical arteries (AA) are dominating in the subchondral region almost up to the base of the patella

Intrinsic arterial supply

The appearance irrespective of age, of the apical and mid-patellar arteries varied from case to case In some cases, apical arteries were conspicuously large and traversed the patella towards its base and on their way a number of small arteries were given off (Figure 4) In these cases, the contribution from the mid-patellar branches was not as pronounced as was noted in other cases in which the mid patellar arteries were larger and the apical arteries were limited to the apex of the patella. In the latter case, the main apical arteries were conspicuously narrow (Figure 2A)

The subchondral arteries arose from the apical and mid patellar arteries as straight or slightly curved branches and radiated towards the subchondral region The arteries divided by dichotomy or branches were given off irregularly

In all specimens with normal cartilage the calibre of the arteries gradually diminished into fine terminal endings.

In specimens from persons aged 60 and above, the main arteries were much thinner than the corresponding arteries in the younger specimens. Moreover, the terminal endings did not reach out as far towards the periphery as compared to those in the younger specimens.

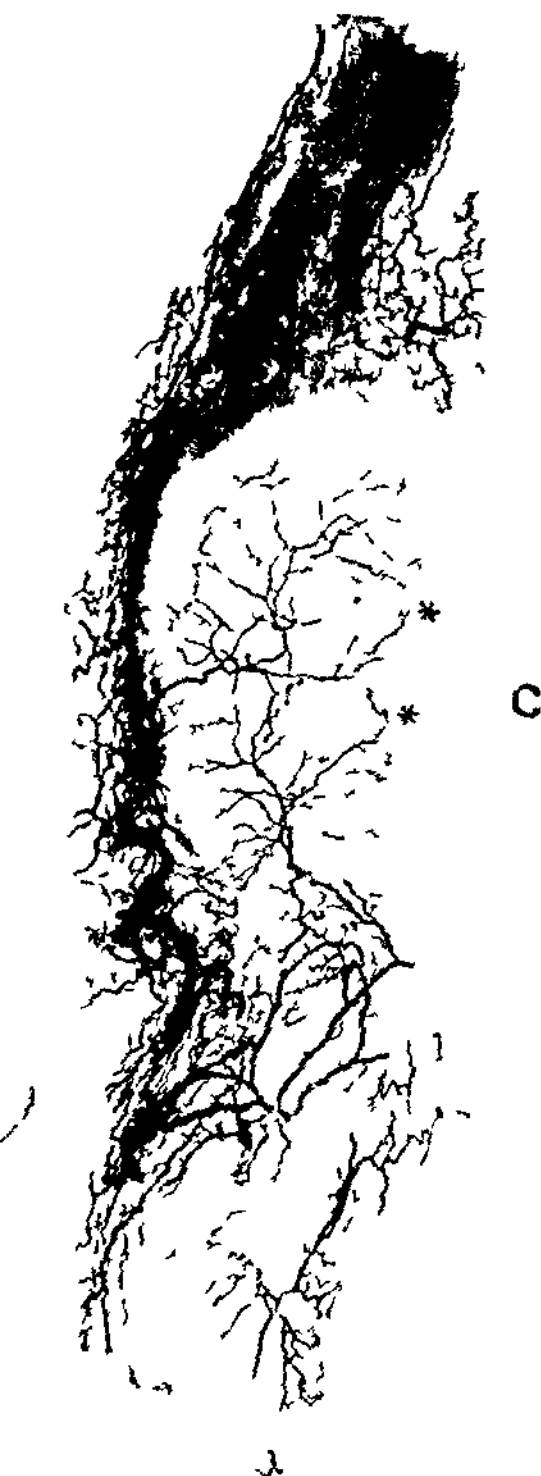


Figure 5 Sagittal section of a patella with chondromalacia Grade 3 from a 21 year-old man Radiograph after decalcification Chondromalacia (C) in central part of articular cartilage In this region the arteries are coarser than normal in their subchondral course where they form a number of anastomoses (*) and run along the osseochondral border

Arterial supply in chondromalacia patellae (n = 6)

Before the specimens were sectioned into slices a grading of the degenerative changes was made (Collins 1949)
Grade 1 fibrillation three specimens
Grades 2 and 3 fissures and fragmentation three specimens
Grade 4 none


The extrinsic arterial supply resembled that of the normal patella

The distribution of the apical and mid-patellar arteries inside the patella resembled that of the normal In their course to the subchondral bone some of the peripheral arteries did not become thinner but rather retained the same calibre as the arteries from which they arose The subchondral arteries had principally two different appearances There were arteries which reached a cartilage zone with normal cartilage and resembled those of the normal patella and arteries which on reaching the zone of degenerated cartilage became wider They reached further out towards the periphery and ended either straight and abruptly or were bent almost parallel to the cartilaginous surface Within the degenerated zone it was occasionally observed that the arterial pattern had an arcade-like design Within these arcades the arteries were tortuous and remarkably wide at the peripheral margin (Figure 5) A correlation could be made with the grading of the cartilage degeneration In Grade 1 the arterial design was only suggestive of the above described arterial pattern whereas in Grades 2 and 3 it was fully pronounced

Arterial supply in osteoarthrosis (n = 6)

The arterial pattern of the extrinsic arterial supply was the same as in the normal patella irrespective of osseous changes

In general the design of the intraosseous arterial supply resembled that of Grades 2 and 3 in chondromalacia patellae In cases with severe osteoarthrosis the type of arterial changes were the same as in chondromalacia



e 6 *Sagittal section of a patella with osteo-ons from a 63-year-old man Radiograph decalcification Degenerative changes (D) are ffusely in the cartilage*
e arteries towards the osseochondral junction oarse and wide They have a tortuous course form anastomoses

lae but the degree was much more pro-ced (Figure 6)

CUSSION

findings of previous studies on the ial supply to the patella by Crock (1967) and by Scapinelli (1967, 1968) have also been observed in this study In addition to previously reported observations this study has disclosed some details which might have some functional importance The parapatellar artery running along the medial border of the patella has been found to be located posterior to the medial fibrous structures and not as suggested by Scapinelli (1967 1968) on the superficial fascia In a number of cases the anterior mid patellar arteries have penetrated the cortex close to the medial, lateral and proximal patellar border Arteries have been demonstrated to penetrate from the quadriceps tendon and from the synovial tissue into the base of the patella Moreover arteries have been demonstrated to penetrate from the synovial tissue on the retinacula through both the medial and lateral patellar borders. It has thus become obvious in this investigation that some of the arteries penetrating the medial superior and lateral borders of the patella have their origin in deeply situated peripatellar arteries and thus do not arise from the superficial arterial circle Our observation of the penetration of arteries into the patella at its borders does not coincide with the observations of Scapinelli We have not been able to find any reason for this difference in observations. Crock (1967) described the mid patellar and apical arteries but did not mention any other arteries penetrating into the patella. However on examining the figures in Crock s monograph it is obvious that there are other arteries penetrating into the patella and in particular this is obvious in a patella from a 9 year-old child which contains two large arteries penetrating the medial border posterior to the fibrous capsule It may be speculated that these peripheral arteries which penetrate into the patella may be of some importance in the healing of patellar fractures. One method of treatment is to use a circular wire for reduction of the fracture and possibly this wire can strangulate the arteries penetrating into the patella and thus disturb the circulation of the fracture fragments.

The distribution of the arteries inside the patella has previously not been described in detail It became obvious that with an increasing degree of cartilage damage there was a corresponding change in the arterial architecture An interesting observation was that these arterial changes were limited to the region of the bone covered by the central part of the cartilage destruction The arterial change seemed to follow the same pattern both in chondromalacia patellae and in osteoarthrosis. It is thus obvious that in articular degeneration there is a vascular change which in degree seems to correspond to the severity of cartilage destruction

REFERENCES

Brookes, M (1971) *The blood supply of bone* Butterworths, London

Collins D H (1949) *Pathology of articular [illegible] spinal diseases* Williams and Wilkins [illegible] Baltimore

Crock H V (1967) *The blood supply of the [illegible] limb bones in man* E & S Livingstone [illegible] Edinburgh and London.

Mulfinger G L & Trueta J (1970) The [illegible] supply of the talus. *J Bone Jt Surg* [illegible] 160–167

O Donoghue D H (1956) Patellar malacia clinical study *Bull Hosp Jt Dis* 17, 1 19

Perkins C (1961) *Orthopaedics* University London The Athlone Press.

Peterson L Goldie I & Lindell, D (1975) [illegible] arterial supply of the talus. *Acta orthop* [illegible] 46, 1026–1034

Scapinelli R (1967) *Blood supply of the h[illegible]* patella *J Bone Jt Surg* 49 B 563 570.

Scapinelli R. (1968) Studies on the vascula[illegible] the human knee joint *Acta anat (Basel)* 305–331

Turek S (1967) *Orthopedics Principles and [illegible] application* J B Lippincott Co Philadel[illegible]

Correspondence to Dr Sven Bjorkstrom Department of Orthopaedic Surgery II Sahlgren Hosp[illegible] S-413 45 Goteborg Sweden

orthop scand 51, 71–77, 1980

ɴE LEG SWING THROUGH GAIT ꞩING TWO CRUTCHES

Analysis of the Ground Reaction Forces and Gait Phases

.TALLARD E DOUNIS R E MAJOR & G K ROSE

ɔotic Research and Locomotor Assessment Unit, The Robert Jones and
ɛes Hunt Orthopaedic Hospital, Oswestry, Salop, England

Using a Force Plate the gait cycle for one leg swing-through gait of ten normal subjects on Canadian crutches was monitored, and a composite diagram of forces on the lower limb and both crutches was produced In addition the relationship of the stance and swing phase for both the lower limb and crutches was studied and the percentage of these phases and their overlap included on the composite diagram

The average maximum vertical ground reaction to the leg was 1 32 body weight, 16 per cent higher than that reported for normal walking The horizontal force on the lower limb in the direction of walking was 0 35 body weight, compared to 0 15 for normal walking

Vertical ground reaction to crutches was on average 0 54 body weight on the side of the landing leg and 0 51 on the contralateral side

Horizontal ground reaction on the crutches at right angles to the direction of ambulation was 0 09 body weight on the right and 0 08 on the left

The results were considered to indicate caution in the prescription of one leg swing-through gait in subjects with diseased bone and joints in the lower limb

Key words crutches, gait

Accepted 21 vi 79

ɪch work has been done on lower limb ᴜnd reaction forces in normal walking, explified by Elftman (1939) and Jacobs et al 72), and on the interrelationship of the ɪous phases of the gait cycle by Murray 67) However, the nature of the gait cycle ɪng swing-through crutch walking has ɴ largely ignored Although Shoup et al 74) reported on the mechanics of crutch ɪking and showed displacement of body ments in different planes, forces and phase ɪrrelationships were not observed Stallard al (1978) monitored the increase in vertical ground reaction in swing-through gait on 10 normal subjects, but did not report on horizontal reactions on the lower limb, the ground reaction to crutches or on phase relationships

The nature and magnitude of the forces developed, and the relationship of the various limb and crutch phases could have important repercussions for aged or infirm patients for whom one leg swing-through gait might be prescribed due to injury or disease of a lower limb Consequently a study was undertaken to establish the pattern of forces developed in

ı–6470/80/010071–07$02.50/0

one leg swing-through gait, using normal subjects who were familiar with this form of ambulation

MATERIAL AND METHODS

Ten normal adult volunteers were used (5 males and 5 females) The average weight of the subjects was 670 N, average height 1 74m, average age was 35 years and each had right hand predominance All subjects were members of staff of the Unit, and this enabled 2 weeks of practice on the Canadian crutches (with 45 mm diameter rubber tips) used for the trials to be undertaken prior to the commencement of the study

Ground reaction forces were monitored on a Kistler 9261 A Force Plate, mounted in the centre of a 9m long × 3m wide non slip conductive rubber walkway and connected to a Kistler 9803 *Electronic Unit which in turn fed an SE 2800* multichannel U V recorder – the resonant frequency of the system being in excess of 200 Hz During a separate trial of the same subjects, single leg stance and swing phase times for the subjects and crutch swing phase and grounded times were simultaneously monitored by means of a multichannel digital multiplex transmitter This was activated by double copper strips placed parallel

in order to complete a circuit through the conductive walkway This system fed the multichannel U V recorder used at a paper speed of 50 mm/s, indicating foot stance and crutch grounded times by means of the on-off condition of the individual channels assigned to each The two parts of the study were separated only because there were insufficient channels on the U V recorder for simultaneous rec Three subjects were unable to take part second part of the trials

Prior to the commencement of th representative runs at each individual's

Plate, each subject was given as much prac he required to ensure assured landing of or relevant crutch on the Force Plate A considered representative only when bo subject and the researchers were satisfied conformed to the subject's usual subject wore their normal shoes, none of having excessively high heels

Chosen speed for each subject was m during the trials to determine crutch relationship by means of two photo switches placed 6m apart in the centre walkway, connected to a digital timer whi started by the first and stopped by the secon

RESULTS

Table 1 shows the weight, height, ag sex of the individuals used All had right predominance and elected to land on right leg

The lower limb ground reaction force each individual were analysed in terms first Fz peak the trough of Fz and the s Fz peak, the maximum positive Fy negative Fy on the lower limb, together maximum crutch Fz, positive and negat and Fx Average results for each subjec

Table 1 Details of subjects

Name	Age	Body weight (N)	Height (m)	Sex
JT	30	828	1 79	M
IF	32	606	1 74	M
RR	26	717	1 70	F
ED	35	728	1 76	M
JS	39	686	1 75	M
MN	39	615	1 68	F
EH	23	641	1 73	F
DD	52	824	1 81	M
JD	41	690	1 73	F
TD	33	561	1 69	F
	Av 35	Av 670	Av 1 73	5 Males 5 Females

ı in Table 2, together with the standard ıon of each individual's five runs. From results overall averages were computed n at the bottom of Table 2) so that a ›site diagram for Fz, Fy and Fx for the limb and crutches could be drawn e 1) The average ratio of swing and phase times for the lower limb and ies were also calculated and the ;es for each subject, together with their ırd deviations are shown in Table 3 ll averages and standard deviations are ted on the last line of this table, and were also used in the construction of ımposite force diagram in Figure 1

: speed of crutch walking for each in- ıal was averaged over five runs and the s are shown in Table 3, together with ırd deviations, the last line showing the ll average and standard deviation

ure 1 shows the overall averages of all ›rces and the interrelation of the gait s Some subjects exhibited maximum on the first peak, others on the second, ıll conformed to the general pattern ı Horizontal ground reaction forces on ›wer limb in the direction of walking a maximum during the first half of e phase and then reverse during take-off ving through

ıce body weight is shared between two hes, ground reaction forces on each are lower than those experienced by the limb All subjects used their right leg single leg landing, but two recorded r average values on the left crutch for ıal ground reaction, seven higher values e right and one recorded identical values ght and left crutches

ıe average horizontal ground reaction on the crutches, in the line of walking reached a maximum during the first half utch stance phase on the right and on the and in the second half of stance phase average peak reversed direction and ed a lower value on the right and left horizontal ground reaction force at right :s to the line of ambulation (Fx) was tly higher on the right than on the left

The average of the maximum peak for vertical loading on the lower limb for males was 1 45 compared to 1 27 for the females, and this was the case both for those whose height was above 1 73m and those who were 1 73m or less Average peak for vertical loading on the lower limb was virtually identical for those aged 35 years or above and those aged less than 35 years, and no correlation between this value and average speed could be discerned

Double support time (with both the one leg and the crutches grounded) occurred in two phases of each gait cycle

(a) with the crutches in front of the body prior to swing through (DSI Table 3)
(b) with the crutches behind the body after single leg landing (DS2 Table 3)

Swing through walking speed was an average of 1 44 m/s for all individuals Some individuals had a very consistent performance others were more erratic, and standard deviations (Table 3) indicated the degree to which this occurred in individuals. As might be expected, there were marked differences in the speeds of different subjects, as indicated by the comparatively high standard deviation on the average figure

DISCUSSION

Ground reaction forces to the subjects' lower limbs were seen to follow the same general pattern as observed in normal walking (exemplified in papers by Elftman (1939) and Jacobs et al (1972)) in that the vertical force Fz peaked early in the cycle, dipped in the middle and peaked again towards the end of the cycle Horizontal forces in the direction of ambulation (Fy) also followed the classic pattern observed in normal gait, in which the ground reaction is initially opposite to the direction of walking passing through zero approximately half way through the leg stance phase and then occurring in the same direction as walking at the end of the phase No significant reaction on the lower limb at right angles to the directions of crutch walking (Fx) was observed

Table 2 Ground reaction forces as a ratio of body weight

	Right lower limb								
	Fz						Fy		
	1st Peak		Trough		2nd Peak		Fore		A
Subject	Average	Deviation	Average	Deviation	Average	Deviation	Average	Deviation	Average
JD	1 23	0 02	0 90	0	1 23	0 12	0 30	0 01	0 17
EH	1 30	0 04	0 78	0 02	1 34	0 05	0 36	0 03	0 35
RR	1 47	0 09	0 74	0 05	1 43	0 10	0 45	0 06	0 34
JT	1 40	0 10	0 72	0 06	1 53	0 02	0 48	0 02	0 32
DD	1 43	0 13	0 71	0 06	1 33	0 11	0 37	0 04	0 30
ED	1 77	0 03	0 52	0 08	1 57	0 23	0 44	0 06	0 32
MN	1 08	0 04	0 84	0 01	0 99	0 02	0 21	0 01	0 20
IF	1 00	0	0 78	0 03	1 27	0 09	0 20	0	0 25
JS	1 27	0 04	0 68	0 05	1 28	0 05	0 36	0 03	0 27
TD	1 09	0 07	0 87	0 03	1 22	0 03	0 34	0 01	0 21
Average	1 30	0 23	0 75	0 11	1 32	0 17	0 35	0 09	0 27

Left crutch							
Fz		Fy				Fx	
		Fore		Aft			
Average	Deviation	Average	Deviation	Average	Deviation	Average	Deviation
0 63	0 03	0 09	0 01	0 02	0 01	0 09	0 01
0 55	0 03	0 07	0 01	0 06	0 02	0 06	0
0 51	0 04	0 10	0 01	0 05	0	0 08	0 02
0 50	0 02	0 14	0 01	0 03	0 01	0 07	0 01
0 51	0 04	0 10	0 02	0 09	0 01	0 04	0
0 44	0 02	0 11	0 02	0 04	0 01	0 11	0 02
0 46	0 02	0 09	0 01	0 03	0	0 09	0 01
0 52	0 01	0 10	0 01	0 03	0	0 09	0 01
0 56	0 03	0 09	0 01	0 12	0 01	0 12	0 01
0 42	0 03	0 08	0 01	0 02	0 01	0 06	0 01
0 51	0 06	0 10	0 02	0 05	0 03	0 08	0 03

Right crutch							
Fz		Fy				Fx	
		Fore		Aft			
Average	Deviation	Average	Deviation	Average	Deviation	Average	Deviation
0 60	0 04	0 10	0 07	0 03	0 01	0 10	0 02
0 54	0 02	0 09	0 01	0 04	0 01	0 09	0 01
0 51	0 01	0 08	0 02	0 07	0 01	0 09	0 01
0 51	0 03	0 12	0 01	0 03	0 01	0 08	0 02
0 57	0 03	0 11	0 01	0 08	0 02	0 05	0 01
0 49	0 01	0 10	0 02	0 05	0 02	0 10	0 02
0 50	0 02	0 08	0 01	0 04	0 01	0 08	0 01
0 53	0 02	0 08	0 02	0 03	0	0 08	0 02
0 63	0 07	0 10	0 01	0 12	0 02	0 13	0 01
0 54	0 01	0 08	0 02	0 03	0	0 10	0 02
0 54	0 05	0 09	0 01	0 05	0 03	0 09	0 03

Table 3 Gait phase relationships

Subject	Crutch stance %		Single leg stance %		1st double stance (DS1) %		2nd double stance (DS2) %		Speed of crutch walking m/s	
	Average	Deviation	Average	Deviation	Average	Deviation	Average	Deviation	Average	Deviation
JD	55 3	1 66	54 6	2 42	5 8	1 01	4 1	0 54	1 64	0 084
CH	56 6	1 20	56 6	0 94	8 5	0 66	4 8	0 70	1 64	0 028
RR	55 8	0 68	55 7	2 30	8 6	2 60	2 9	0 65	1 33	0 040
ED	55 6	2 70	54 2	1 10	5 3	3 17	4 5	1 30	1 37	0 050
IF	55 5	0 70	55 3	1 55	7 3	2 20	3 3	0 83	1 43	0 056
JS	53 7	1 07	53 2	2 30	4 6	1 32	2 3	1 27	1 49	0 038
TD	55 2	1 40	56 4	0 84	8 5	0 59	3 1	0 84	1 20	0 020
Overall average	55 4	1 60	55 1	1 60	6 9	2 34	3 6	1 20	1 44	0 162

Table 2 Ground reaction forces as a ratio of body weight

	Right lower limb								
	Fz						Fy		
	1st Peak		Trough		2nd Peak		Fore		Aft
Subject	Average	Deviation	Average	Deviation	Average	Deviation	Average	Deviation	Average
JD	1 23	0 02	0 90	0	1 23	0 12	0 30	0 01	0 17
EH	1 30	0 04	0 78	0 02	1 34	0 05	0 36	0 03	0 35
RR	1 47	0 09	0 74	0 05	1 43	0 10	0 45	0 06	0 34
JT	1 40	0 10	0 72	0 06	1 53	0 02	0 48	0 02	0 32
DD	1 43	0 13	0 71	0 06	1 33	0 11	0 37	0 04	0 30
ED	1 77	0 03	0 52	0 08	1 57	0 23	0 44	0 06	0 32
MN	1 08	0 04	0 84	0 01	0 99	0 02	0 21	0 01	0 20
IF	1 00	0	0 78	0 03	1 27	0 09	0 20	0	0 25
JS	1 27	0 04	0 68	0 05	1 28	0 05	0 36	0 03	0 27
TD	1 09	0 07	0 87	0 03	1 22	0 03	0 34	0 01	0.21
Average	1 30	0 23	0 75	0 11	1 32	0 17	0 35	0 09	0 27

Left crutch							
Fz		Fy				Fx	
		Fore		Aft			
Average	Deviation	Average	Deviation	Average	Deviation	Average	Deviation
0 63	0 03	0 09	0 01	0 02	0 01	0 09	0 01
0 55	0 03	0 07	0 01	0 06	0 02	0 06	0
0 51	0 04	0 10	0 01	0 05	0	0 08	0 02
0 50	0 02	0 14	0 01	0 03	0 01	0 07	0 01
0 51	0 04	0 10	0 02	0 09	0 01	0 04	0
0 44	0 02	0 11	0 02	0 04	0 01	0 11	0 02
0 46	0 02	0 09	0 01	0 03	0	0 09	0 01
0 52	0 01	0 10	0 01	0 03	0	0 09	0 01
0 56	0 03	0 09	0 01	0 12	0 01	0 12	0 01
0 42	0 03	0 08	0 01	0 02	0 01	0 06	0 01
0 51	0 06	0 10	0 02	0 05	0 03	0 08	0 03

Right crutch							
Fz		Fy				Fx	
		Fore		Aft			
Average	Deviation	Average	Deviation	Average	Deviation	Average	Deviation
0 60	0 04	0 10	0 07	0 03	0 01	0 10	0 02
0 54	0 02	0 09	0 01	0 04	0 01	0 09	0 01
0 51	0 01	0 08	0 02	0 07	0 01	0 09	0 01
0 51	0 03	0 12	0 01	0 03	0 01	0 08	0 02
0 57	0 03	0 11	0 01	0 08	0 02	0 05	0 01
0 49	0 01	0 10	0 02	0 05	0 02	0 10	0 02
0 50	0 02	0 08	0 01	0 04	0 01	0 08	0 01
0 53	0 02	0 08	0 02	0 03	0	0 08	0 02
0 63	0 07	0 10	0 01	0 12	0 02	0 13	0 01
0 54	0 01	0 08	0 02	0 03	0	0 10	0 02
0 54	0 05	0 09	0 01	0 05	0 03	0 09	0 03

NOWLEDGEMENTS

uthors wish to thank all the members of
who so willingly took part in the trials.
ut their valued cooperation and assistance
ork would not have been possible

RENCES

an H (1939) The force exerted by the
ound in walking *Arbeitsphysiol* **10**, 485–491

Jacobs N A, Skorecki, J & Charnley, J (1972) Analysis of the vertical component of force in normal and pathological gait *J Biomech* **5**, 11–34

Murray, M P (1967) Gait as a total pattern of movement *Amer J Phys Med* **46**, 290–333

Shoup, T E, Fletcher, L S & Merrill, B R (1974) Biomechanics of crutch locomotion *J Biomech* **7**, 11–19

Stallard J, Sankarankutty, M & Rose, G K (1978) Lower limb vertical ground reaction forces during crutch walking *J Med Engng Technol* **2**, 201–202

spondence to J Stallard, Orthotic Research and Locomotor Assessment Unit, The Robert Jones
gnes Hunt Orthopaedic Hospital Oswestry, Salop SY10 7 AG, U K

ɔrthop scand. 51, 79–84, 1980

ACTURES OF THE CERVICAL SPINE PATIENTS WITH ANKYLOSING SPONDYLITIS

DEMAR V SURIN

ırtment of Orthopaedic Surgery, Central Hospital, Borås, Sweden

Fractures of the cervical spine in six patients suffering from ankylosing spondylitis are presented Three patients had a hyperextension type of injury These fractures were extremely unstable and combined with spinal cord damage In the other cases the fracture was caused by a flexion mechanism. These fractures were stable and there was no damage to the spinal cord Treatment modified according to the demands of the fractures is outlined

Key words ankylosing spondylitis, cervical spine, fracture, treatment

Accepted 11 vii 79

ctures of the ankylosed cervical spine are ıer uncommon Our review of the relevant rature revealed that since the publication Stiasny (1933), only 60 cases have been orted Furthermore, most authors have ıted only one or a very few patients rgman 1949, Janda et al 1968, Klems '7, Osgood et al 1973)

Based on our experience with six such es, it is our purpose to point out the rapeutic difficulties encountered in the nagement of these fractures.

TIENTS AND METHODS

ring the years 1972–1978, six patients with ylosing spondylitis (AS) were admitted to our artment for fractures of the cervical spine Five he six patients had been treated for AS before fracture occurred, the sixth was unaware of disease All were males.

The characteristics of the patients and the type rauma are summarized in the Table 1

With respect to the direction of the forces ısing the cervical fracture and to the involvent of the spinal cord, we distinguished two cture groups in our patient population

A The first group (patients 1, 2 and 3) was characterized by spinal cord damage which occurred either at the time of the accident (patients 1 and 2) or during the course of the treatment (patient 3) In all patients the fractures resulted from a force applied to the forehead (Figure 1). The fractures occurred in what had formerly been the intervertebral space rather than through the vertebral body itself (Figure 2A and B)

B The second group (patients 4, 5 and 6) was characterized by absence of spinal cord damage Cervical fractures in two patients (5 and 6) resulted from a flexion injury In the third patient (4), with no recollection of the accident, the roentgenological picture of the fracture was also clearly indicative of a flexion injury (Figure 3A and B) The accident caused a wedge-like compression of the vertebral body and fracture of the articular facets.

Patients 1 and 2 were transported to the hospital immediately after the accident, supine with the head placed horizontally In this position they complained of severe pain and increasing muscle weakness. This was relieved when the ambulance personnel placed the patients' heads in flexion (Figure 2A and B)

Patient 3 was transported supine with his head kept in flexion by a special vacuum cushion (Figure 4). This position was maintained during the roentgen examination and application of the halo-vest apparatus.

)1 6470/80 010079–06$02.50 ©

Table 1 The characteristics of the AS patients and the type of trauma causing cervical

Case no	Age	Accident	Type of injury	Level	Neurological on admission
1	56	automobile	hyperextension	C 5–6	central cord
2	59	automobile	hyperextension	C 4–5	complete
3	67	automobile	hyperextension	C 6–7	normal neurolog
4	42	automobile	flexion	C 5–6	normal neurolog
5	78	fall backwards	flexion	C 2–3	normal neurolog
6	72	fall backwards	flexion	C 7 Th 1	normal neurolog




Figure 1 Patient 2 The direction of the traction in the halo ring is upright to maintain the head and neck in flexion Note the contusion of the patient's face

Patients 4 5 and 6 sought medical advice use of persistent neck pain 4, 7 and 10 days the accident respectively

Our routine treatment aimed to restore the alignment of the neural canal as soon as possible by means of closed reduction combined with skull traction This was successful in five patients In patient 6 the fracture-dislocation could not be reduced at all despite intensive skull traction Taking into consideration this patient s age (72 years) open reduction was considered dangerous and the fracture was left to heal unreduced.

Patient 1 was treated with skull traction until the fracture united. In all other patients the fracture was immobilized by means of a halo-vest apparatus This immobilization failed in two patients

In patient 2 the fracture redislocated immediately on the patient being placed in the halo-vest apparatus. The reduction could be maintained only by a continuous almost vertical traction on the halo ring (Figure 1) until the fracture healed

In patient 3 the dislocation was co reduced and immobilized in the l apparatus on admission. One week l suddenly became paralysed in all four ex during his sleep Traction on the halo r applied immediately instead of the halo mobilization Tetraplegia then resolved du next 24 hours. A roentgenogram m mediately after the start of the traction only a slight anterior dislocation at the site Traction was continued for a further and the fracture healed without complicati

Patients 4 5 and 6 had their cervical sp mobilized in the halo-vest apparatus for l This was followed by support in a special ne for a further 6–8 weeks.

RESULTS

Roentgenograms showed that all f were solidly healed 3 months after inju

Patient 1, with clinical signs of centr syndrome on admission had cons return of muscle activity in all muscles within 6 months after the a The complete tetraplegia in the pa persisted despite 6 months of in rehabilitation

Patients 3 4, 5 and 6 complained occasional vertebral pain at the chec months after the accident None of th any sign of spinal cord damage

DISCUSSION

The ability to recognise two (hyperextension and flexion) of cervic fractures in AS is important for





ure 2 A and B Patient 1 (A) Lateral supine roentgenogram demonstrating a fracture at the C6–C7 el The complete fracture separation is mainly caused by placing the patient's head on the X-ray table hout support (B) Fracture healed after 3 months

ional approach to treatment In our patient ies we could distinguish hyperextension ctures as a distinct entity with a greater k of spinal cord damage as compared with nilar injuries sustained by flexion force in ankylosed cervical spine

Two important points as to the treatment patients with hyperextension injuries of the kylosed cervical spine must be considered

1 Recommendations of emergency atment of cervical spine fractures stating t the patients should be placed izontally face upward on a firm surface e Palma 1970) do not apply here One must preciate that the neutral position for the tient with AS and cervical spine fracture ually means maintaining considerable tion of the head and neck to conform to patient's spinal axis prior to injury gure 1)

Hyperextension at the fracture site causing further spinal cord damage may occur during the transport (Rogers 1957, our patients 1 and 2), during the roentgenological examination (Burke 1971, Figure 2A), during the treatment if skull traction is applied in the horizontal direction (Osgood et al 1973), and in every other instance when the patient is placed horizontally without head support on a firm surface To prevent this a special cushion (Figure 4), which can be individually fitted to the shape of the patient's spinal kyphosis, proved to be very useful

2 These fractures are particularly unstable because many of the normally supportive cervical soft tissues and ligaments are themselves calcified and, therefore, also fracture at the time of injury

Several instances of patients becoming paralysed while in traction or in inadequate

Cheshire, D J E (1969) The stability of the cervical spine following the conservative treatment of fractures and fracture-dislocations *Paraplegia* **17**, 193–203

Grisolia, A, Bell R L & Peltier, L F (1967) Fractures and dislocations of the spine complicating ankylosing spondylitis *J Bone Jt Surg* 49-A, 339–344

Guttmann, L (1966) Traumatic paraplegia and tetraplegia in ankylosing spondylitis *Paraplegia* **4**, *188–203*

Janda, W E, Kelly, P J, Rhoton, A L & Layton, D D (1968) Fracture dislocation of the cervic part of the spinal column in patients with ankylosing spondylitis *Mayo Clin Proc* **43**, 714–721

Klems, H (1977) Halswirbelsaulenfraktur bei Spondylarthritis ankylopoetica *Arch orthop Unfall-Chir* **87**, *203–211*

Osgood, C, Martin, L G & Ackerman, E Fracture-dislocation of the cervical sp ankylosing spondylitis. *J Neurosu* 764–769

De Palma, A (1970) *The management of f and dislocations* Vol. 1, 2nd ed pp. 2 W B Saunders Co, Philadelphia.

Rogers, W A (1957) Fractures and d the cervical spine *J Bone Jt Surg* 341–352

Simmons, E H & Duncan, C P (1978) F the cervical spine in ankylosing spond analysis of its influence on severe c senting spinal osteotomy *Clin Orth* 277

Stiasny, H (1933) Fraktur der Halswirbels Spondylarthritis ankylopoetica *Zbl. C* 998–1005

Correspondence to V V Surin, M D, Orthopaedic Department, Central Hospital, Box 850 S- Borås, Sweden

ı orthop scand. 51, 85–90 1980

ITE RESULTS OF INTERTROCHANTERIC OSTEOTOMY 'R ADVANCED OSTEOARTHRITIS OF THE HIP

(NJOLFUR A. MOGENSEN, HELGI ZOEGA & PETER MARINKO

artment of Orthopaedic Surgery and Radiology, Central Hospital, Vasterås, Sweden

The results are presented of 50 intertrochanteric osteotomies after a minimum observation time of 9 3 years. This method of treatment was found to be of lasting benefit in 86 per cent of the patients The results encourage us to consider osteotomy also in younger patients with osteoarthritis.

Key words hip joint, methods, osteoarthritis osteotomy

Accepted 21 vi 79

ertrochanteric osteotomy is a well estab-ed form of surgical treatment for osteo-ritis of the hip joint McMurray (1935) the first to perform and publish a series lisplacement osteotomies for osteoarthritis the hip The literature contains a large nber of subsequent reports which all clude that the result is favourable in the st majority of patients (Adam & Spence 8, Cohen et al 1972, Goldie et al 1973, dmundsson 1970, Gudmundsson et al 0, Hansen et al 1973, Harris & Kirwan 4, Jerre & Tilling 1969, King & Dooley 2, Mendes 1975, Morscher 1971, Olsson 4, Salenius et al 1971)

ince the introduction of total hip replace-nt, the primary results of which are so kingly good, osteotomy has fallen newhat into the background Because of a ll founded fear of late mechanical loosening the prosthesis, we feel it would be of value examine the long term results of a series of eotomies reported earlier (Gudmundsson al 1970)

TIENTS AND METHODS

1970 Gudmundsson et al published the results medial displacement osteotomies done for ranced osteoarthritis of the hip The medial dis-cement of the osteotomies varied between 13 and 19 mm No wedge osteotomies were performed Stable internal fixation was achieved with a device (Figures 1–3) designed by Jerre (Jerre & Tilling 1969) There were 64 patients and the operation was performed in 68 hips Before the osteotomy 97 per cent of the patients had pain at rest and 98 per cent had pain on weight-bearing

The present long term follow-up study involves 47 patients with 50 operated hips, 11 patients have died 3 have had the osteotomy converted to total hip replacement and 3 patients are lost to follow-up The follow-up period averaged 10 1 years (range 9 3–11 4 years)

We have evaluated pain in the same way as [illegible]

The radiological examination consisted of a standard frontal and lateral projection with the patient in the supine position The joint space was measured laterally on the frontal view along a line which was the direct continuation of the supra acetabular part of the ilium to the femoral head

The radiological diagnosis of osteoarthritis was based on the presence of cysts sclerosis and narrowing of the joint space All hips had [illegible]

RESULTS

Table 2 demonstrates that 74 per cent (37/50) of the hips do not give rise to pain at rest

)1–6470 80 010085–06502 50 0
7



Figure 1 Hip with advanced osteoarthritis prior to osteotomy




Figure 2 Same hip immediately after oste

after 10 1 years and that a further 14 per cent (7/50) still have less pain at rest than before operation Eighty-eight per cent (44/50) of the patients are thus improved as far as pain at rest is concerned Forty per cent (20/50) of the patients are free of pain on weight-bearing and a further 46 per cent (23/50) are improved, i e 86 per cent (43/50) are improved as far as pain on weight-bearing is concerned

The range of movement in our series was compared with that reported by Goldie et al (1973) with an observation time 8 7 years (Table 3) The average number of points before operation was 3 7 and at follow-up 3 2 Table 4 shows that 72 per cent (34/47) of the patients could walk more than 500 meters without resting Most (37/47) managed well without a stick or used one outdoors (Table 5) Eight patients had a leg shortening of more than 2 cm, 15 between 1 and 2 (24 less than 1 cm Twenty six p walked without a limp or with only a one, whereas 21 walked with a marke

Twenty-five of the patients, includin housewives returned to the work th before the operation and are still work now have become eligible for old age p Three changed to lighter work, nine because of hip disability and ten had a retired at the time of surgery We e especially about the ability to put on and shoes and compared the results those of Olsson (1974) and Danielsson (as demonstrated in Table 6

The patients' own evaluation compared with the patients' eval reported in Olsson (1974) and in Goldie (1973) (Table 7) The patients were as they would still want to have an osteo

Table 1 Age at operation

Years	31–40	41–50	51–60	61–70	71–80	Total
No of patients	3	7	17	19	1	47



! *Same hip 10 years after the osteotomy*

ied, if the circumstances were the same
e at the time of surgery Eighty-four per
2/50) said they would
patient developed a late infection 8
fter the osteotomy, no other late com-
n was encountered
e 8 shows that 46 per cent (23/50) of
its and sclerosis in the femoral head
cetabulum regressed The regression
ore evident in the femoral head than in

Table 2 Pain

	Pain at rest		Pain on weight bearing	
	No of hips	%	No of hips	%
No pain	37	74	20	40
Less pain	7	14	23	46
Unchanged	4	8	2	4
Worse	2	4	5	10
Total	50	100	50	100

the acetabulum The correlation between pain relief and regression of radiological changes is shown in Tables 9 and 10 The pain relief was mos[illegible]ounced in cases with obvious radiologi[illegible]ssion

We m[illegible] he joint space on the X ray taken imn[illegible] after the osteotomy and on that after [illegible]ars The mean joint space was 1 34 [illegible]r the operation and 2 22 mm after [illegible]s This is a statistically significant [illegible] (t test $P<0.001$)

DISCUSSION

The present series is a long term follow-up of 50 intertrochanteric osteotomies with a mean observation time of 10 1 years We have not been able to find a report of a series with a comparable observation time

Table 3 Range of movement

s	Points	Present Series				Goldie et al (1973)
		Before op No of hips	%	After op No of hips	%	%
0	1					7 5
0	2	3	6	9	18	16
0	3	14	28	21	42	32
0	4	26	52	15	30	33
0	5		14	5	10	7 5
0	6					4
		50	100	50	100	100

Table 4 Ability to walk

Distance in meters	No of patients	%
100	3	7
101– 500	10	21
501–1000	7	15
1001	27	57
Total	47	100

Table 5 The use of a stick

	No of patients	%
None	21	45
One outdoors	16	34
One always	6	13
Two always	4	8
Total	47	100

Olsson (1974) compared osteotomies done with a non-compressive method and those done with the AO compressive method and McKee-Farrar total hip replacement The points scored for pain in these three series were 4 3, 4 3 and 4 5 In the present study 74 per cent (37/50) had no pain at rest and 40 .. cent (20/50) had no pain on weight-ₒ In 1970, 83 per cent of the patients were free of pain at rest and 88 per cent on weight-bearing These results are in accordance with those of Goldie et al (1973), where the average observation time was 8 7 years The results are better than non-

Table 7 The patients' own evaluation

	Present Series No of hips	%	Olsson (1974) %	Gol al (1
Worthwhile	42	84	84	8
Not worthwhile	8	16	16	16
Total	50	100	100	100

operative treatment alone as reported Danielsson (1964), who obtained imp ment in 59 per cent (70/119) of cases should be emphasized, however, in com ing with the results of nonoperative t ment as reported by Danielsson, that 13 cent (15/119) of his patients had never felt hip pain The range of movement dimin from 3 7 points to 3 2 points at follow-up an per cent (29/50) had difficulty putting on and shoes

Regression of cysts and sclerosis occu in 46 per cent (23/50) of the hips in series Comparable results have been repo by Adam & Spence (1958), Duthie & H (1963), Gudmundsson (1970), Harris Kirwan (1964), Hirsch et al (1972), Mors (1971), Olsson et al (1975) and Salenius e (1971), whereas the majority of arthrotic h treated non-operatively show progression cysts and sclerosis (Danielsson 1964) joint space as measured at the latest fol up was increased to a degree which statistically significant This seems to sup the hypothesis of Nissen (1971) Byers (1974) that cartilage regenerates a osteotomy

Table 6 Ability to put on socks and shoes

	Present Series No of hips	%	Olsson (1974) %	Danielsson (1964) %
In need of help or can manage with difficulty	29	58	60	70
Manages easily	21	42	40	30
Total	50	100	100	100

Table 8 Changes in cysts and sclerosis

	Femoral head		Acetabulum		Femoral head and acetabulum	
	No of hips	%	No of hips	%	No of hips	%
Regression	29	58	25	50	23	46
Unchanged	10	20	18	36	9	18
Progression	11	22	7	14	7	14
Behaviour different in femoral head and acetabulum					11	22
Total	50	100	50	100	50	100

Table 9 Pain relief related to changes in cysts and sclerosis in the femoral head

		Pain at rest No of hips			Weight bearing pain No of hips		
		No pain	Less pain	Unchanged or worse	No pain	Less pain	Unchanged or worse
ly iges	Regression	24	2	3	15	10	4
	Unchanged	7	3	0	5	5	0
	Progression	6	2	3	0	8	3
	Total		50			50	

Table 10 Pain relief related to changes in cysts and sclerosis in the acetabulum

		Pain at rest No of hips			Weight bearing pain No of hips		
		No pain	Less pain	Unchanged or worse	No pain	Less pain	Unchanged or worse
ay nges	Regression	22	1	2	12	10	3
	Unchanged	11	5	2	8	8	2
	Progression	4	1	2	0	5	2
	Total		50			50	

In conclusion we find that intertrochanteric osteotomy is of long lasting benefit to the majority of patients and with this knowledge we recommend that osteotomy be considered also as treatment for patients under 60 years of age. For those patients in whom osteotomy fails to give the expected pain relief, it can without undue difficulty be converted to a total hip replacement (Dupont & Charnley 1972).

ACKNOWLEDGEMENTS

The authors with to express their gratitude to T Jerre, the senior author of the primary report, for his constructive suggestions and to T Dolk, M.D for his statistical analysis of the results.

REFERENCES

Adam, A & Spence, A J (1958) Intertrochanteric osteotomy for osteoarthritis of the hip *J Bone Jt Surg* 40-B, 219–226

Byers, P D (1974) The effect of high femoral osteotomy on osteoarthritis of the hip *J Bone Jt Surg* 56-B, 279–290

Charnley, J (1972) The long-term results of low friction arthroplasty of the hip performed as a primary intervention *J Bone Jt Surg* 54-B, 61–76

Cohen, S A., Deij, K & Vooys, H P (1972) The long-term results of intertrochanteric osteotomy of the femur *Arch chir neerl* 24-II, 223–228.

Danielsson, L G (1964) Incidence and prognosis of coxarthrosis. *Acta orthop scand.*, Suppl 66.

Dupont, J A & Charnley, J (1972) Low-friction arthroplasty of the hip for the failures of previous operations. *J Bone Jt Surg* 54-B, 77–87

Duthie, R B & Howe, W W (1963) Displacement osteotomy for arthritis of the hip. *Clin Orthop* 31, 65–72.

Goldie, I F Andersson G B J & Olsson, S S. (1973) Long-term follow-up of intertrochanteric osteotomy in osteoarthritis in the hip joint *Clin Orthop* 93, 265–270

Gudmundsson, G (1970) Intertrochanteric displacement osteotomy for painful osteoarthritis of the hip. *Acta orthop scand.* 41, 91

Gudmundsson, J., Jerre, T & Tilling G (19 Stabile Fixation bei Intertrochanterer Osteotomie. *Z Orthop.* 107, 599–610.

Hansen, F. W., Hansen-Leth, C. & Jensen, (1973) Intertrochanteric osteotomy with technique in arthrosis of the hip. *Acta scand.* 44, 219–229

Harris, N E. & Kirwan, E. (1964) The results osteotomy for early primary osteoarthritis the hip *J Bone Jt Surg* 46-B 477

Hirsch, C., Goldie, I & Ryba, W Intertrochanteric osteotomy for osteoarthritis of the hip. *Clin. Orthop* 86, 63–67

Jerre, T & Tilling G (1969) Stable fixation intertrochanteric osteotomy *Acta scand.* 40, 466–478.

King, T & Dooley, B (1962) Observations on late results of the McMurray osteotomy osteoarthritis of the hip. *J Bone Jt Surg* 44-B, 595–601

McMurray, T P (1935) Osteoarthritis of the joint. *Brit. J Surg* 22, 716–727

Mendes, D G (1975) Intertrochanteric osteotomy for degenerative hip disease. *Clin. Orth* 106, 60–74

Merle D'Aubigné, R. & Postel, M. (1 Functional results of hip arthroplasty acrylic prosthesis. *J Bone Jt Surg* 36 450–475

Morscher, E. (1971) *Die Intertrochanteren Osteotomie bei Coxarthrose Analyse Auswertung von 2251 nach Intertrochanteren Osteotomien.* Verlag Huber, Bern, Stuttgart, Wien.

Nissen, K. I (1971) The rationale of osteotomy for idiopathic coxarthrosis (Epichondro-osteoarthrosis of the hip). *Clin Orthop* 77, 98–104

Olsson, S S (1974) *Intertrochanteric osteotomy of the femur for osteoarthritis of the hip.* Thesis. Elanders boktryckeri aktiebolag Kungsbacka

Olsson, S S., Goldie, I F & Irstam, L K (1975) Intertrochanteric osteotomy for osteoarthritis of the hip. *J Bone Jt Surg* 466–470

Salenius, P, Langenskiöld, A & Österman (1971) Intertrochanteric displacement osteotomy in the treatment of osteoarthritis of the hip. *Acta orthop scand.* 42, 63–


Correspondence to Brynjolfur Mogensen Department of Orthopaedic Surgery, University H
S-221 85 Lund, Sweden

orthop scand. 51, 91–108, 1980

ACTURES OF THE P IN CHILDREN ID ADOLESCENTS*

PFÖRRINGER & B ROSEMEYER

rtment of Orthopedic Surgery, University of Munich, Munich Federal Republic of Germany



internal fixation may also be carried out with screws, in which case these must not cross an open epiphyseal plate In both groups a non-weight-bearing period of 6 to 12 months is advisable

The results in adolescents were definitely poorer than in children Seemingly completely destroyed hips can reintegrate even to a nearly "restitutio ad integrum" state after a period of years.

Key words avascular necrosis, children, femoral neck fractures fracture treatment

Accepted 9 ix 79

cture of the femoral neck in children and lescents is a rare injury Only four papers cerning the long-term results of a large es have been published The most comprehensive study is that of Ratliff (1974), who blished the results of 170 fractures from 20 erent orthopaedic clinics.

Recently Canale & Bourland (1977) have xamined 24 patients originally examined Ingram & Bachynski (1953) and have plemented their report with an additional 36 cases They compared their study with those of Ratliff (1968) and Lam (1971)

In these papers however no distinction has been made between fractures in children and in adolescents Only Boitzy (1971, 1978) distinguishes in his cases between these age groups. In the present paper the long-term results in children and adolescents with hip fractures are examined

PATIENTS AND METHODS

Fifty two fractures of the proximal femur in 51 patients were examined during the period 1936 to

his article is dedicated to Professor Dr A N t in honor of his 65th birthday

6470/80/010091–18$02.50/0

1974 The patients were divided into groups of *children and adolescents. Children* were defined as the age group from birth to the 11th year, while adolescents were defined as the age group from the 12th to the 17th year, inclusive

Hip fractures in children were encountered in 10 boys and 16 girls. The average age at the time of the accident was 7 years (range 10 months to 11 years) The average follow-up period was 9 years (range 2 to 34 years) The series of adolescents consisted of 18 boys and 7 girls. The average age was 15 3 years (range 12 to 17 years) The average follow-up period was 14 8 years (range 7 to 28 years)

The *fractures were classified as follows* Transepiphyseal fractures, transcervical, basocervical and intertrochanteric fractures. The methods of treatment included non-operative treatment, immediate operative treatment and delayed operative treatment

Treatment

Non-operative treatment included traction, immobilization in a hip-spica, bed rest until bony union and non-weight-bearing for 6 months. Immediate operative treatment consisted of open or closed reduction followed by fixation with K-wires, screws or nails. Fixation with K-wires was followed by a hip-spica for 4 to 6 weeks. Fixation with nails and screws made an external fixation unnecessary A non-weight-bearing period of 6 months was recommended in all cases.

Operative treatment was considered delayed en performed later than 36 hours after the dent.

In the analysis of the late results we have used ne criteria described by Ratliff (1968) These are listed in Table 1

RESULTS

Children

Transepiphyseal fractures (Table 2 [illegible] Figure 1) were encountered in four pa[illegible] with an average age of 5 years. Two chil[illegible] were treated operatively on the day of [illegible] accident with open reduction and K-[illegible] fixation At the follow up, 7 and 12 [illegible] later, the results were classified as good. [illegible] child was treated non-operatively [illegible] traction An avascular necrosis develo[illegible] with shortening of the leg and limitation [illegible] motion This result was classified as po[illegible] The fourth child sustained an open fra[illegible] and was treated non-operatively [illegible] traction Osteomyelitis developed, followed [illegible] avascular necrosis with destruction of the femoral head. An arthrodesis of the affec[illegible] hip joint was eventually performed

Transcervical fractures (Table 3 and Fi[illegible] 2) were recorded in seven children with [illegible] average age is 8 7 years Three children [illegible] treated operatively by internal fixation [illegible] K-wires on the day of the accident, [illegible] three were treated by delayed opera[illegible] preceded by 2 to 3 weeks of traction and [illegible] child was treated non-operatively In [illegible] three patients operated on immediately [illegible] fair and two good results were encounter[illegible]

Among the three patients treated [illegible] delayed internal fixation one fair and [illegible] poor results were found The child treated [illegible]

Table 1 Ratliff's classification of the results of treatment for fracture of the hip

	GOOD	FAIR	POOR
Pain	None or patient ignores it	Occasional	Disabling
Movement	Full or only terminal restriction	Greater than 50 per cent	Less than 50 per cent
Activity	Normal or patient avoids games	Normal or patient avoids games	Restricted
X-ray	Normal or some deformity of femoral neck	Severe deformity of femoral neck and mild avascular necrosis	Severe avascular necrosis degenerative arthritis arthrodesis

Table 2 Transepiphyseal fractures (children)

Case	Age at injury (years)	Treatment	Age at last follow-up	Avascular necrosis	Non-union	Leg length	Pain + limited motion	Premature closure	Coxa vara Coxa valga	End-result
1	2	Open reduction + K-wires	9			+0.5 cm				Good
2	5	Open reduction + K-wires	17	–						Good
3	5	Traction and hip-spica for 7 weeks	12	yes		2 cm	yes	yes		Poor
4	8	Traction and hip-spica for 12 weeks, then arthrodesis	15	yes		1 cm				Poor

1974 The patients were divided into groups of children and adolescents. Children were defined as the age group from birth to the 11th year, while adolescents were defined as the age group from the 12th to the 17th year, inclusive.

Hip fractures in children were encountered in 10 boys and 16 girls. The average age at the time of the accident was 7 years (range 10 months to 11 years). The average follow-up period was 9 years (range 2 to 34 years). The series of adolescents consisted of 18 boys and 7 girls. The average age was 15 3 years (range 12 to 17 years) The average follow-up period was 14 8 years (range 7 to 28 years).

The fractures were classified as follows Transepiphyseal fractures, transcervical, basocervical and intertrochanteric fractures. The methods of treatment included non-operative treatment, immediate operative treatment and delayed operative treatment.

Treatment

Non-operative treatment included traction, immobilization in a hip-spica, bed rest until bony union and non-weight-bearing for 6 months. Immediate operative treatment consisted of open or closed reduction followed by fixation with K-wires, screws or nails. Fixation with K-wires was followed by a hip-spica for 4 to 6 weeks. Fixation with nails and screws made an external fixation unnecessary A non weight-bearing period of 6 months was recommended in all cases.

Operative treatment was considered delayed hen performed later than 36 hours after the dent.

In the analysis of the late results we have used the criteria described by Ratliff (1968). These are listed in Table 1

RESULTS

Children

Transepiphyseal fractures (Table 2 [illegible] Figure 1) were encountered in four [illegible] with an average age of 5 years. Two [illegible] were treated operatively on the day [illegible] accident with open reduction and K [illegible] fixation At the follow-up 7 and 12 [illegible] later, the results were classified as good [illegible] child was treated non-operatively [illegible] traction An avascular necrosis [illegible] with shortening of the leg and [illegible] motion This result was classified as p[illegible] The fourth child sustained an open [illegible] and was treated non-operatively [illegible] traction Osteomyelitis developed, followed [illegible] avascular necrosis with destruction of [illegible] femoral head An arthrodesis of the [illegible] hip joint was eventually performed.

Transcervical fractures (Table 3 and F[illegible] 2) were recorded in seven children [illegible] average age is 8 7 years. Three children [illegible] treated operatively by internal fixation [illegible] K-wires on the day of the accident, [illegible] three were treated by delayed [illegible] preceded by 2 to 3 weeks of traction [illegible] child was treated non-operatively [illegible] three patients operated on immediately [illegible] fair and two good results were encounter[illegible]

Among the three patients treated [illegible] delayed internal fixation one fair and [illegible] poor results were found The child trea[illegible]

Table 1 Ratliff's classification of the results of treatment for fracture of the hip

	GOOD	FAIR	POOR
Pain	None or patient ignores it	Occasional	Disabling
Movement	Full or only terminal restriction	Greater than 50 per cent	Less than 50 per cent
Activity	Normal or patient avoids games	Normal or patient avoids games	Restricted
X-ray	Normal or some deformity of femoral neck	Severe deformity of femoral neck and mild avascular necrosis	Severe avascular necr[illegible] degenerative arthr[illegible] arthrodesis

Table 3 Transcervical fractures (children)

Case	Age at injury (years)	Treatment	Age at last follow-up	Avascular necrosis	Non-union	Leg length	Pain + limited motion	Premature closure	Second operation	Coxa vara Coxa valga	End-result
1	7	Open reduction + K-wires, day of injury	14	—	—	+ 1 cm	—	—	—	—	Good
2	10	Open reduction + K-wires	13	—	—	−1 cm	—	yes	Refracture after removal of K-wires 10 months postop , then traction for 12 weeks		Fair
3	7	Open reduction + K-wires, day of injury	16	—	—	—	—	—	—	—	Good
4	11	2 weeks' traction, then open reduction + K-wires	18	yes	—	−1 cm	yes	yes	—	Coxa valga 138°	Poor
5	9	3 weeks' traction then open reduction + K-wires	12	—	—	−1.5 cm	(+)	yes	—	—	Fair
6	9	Nailing 2 weeks post accident	20	yes	—	−2 cm	yes	yes	—	—	Poor
7	8	8 weeks' traction + hip-spica	15	—	yes	−1 cm	—	yes	Bone graft + K-wires 6 months post injury	Coxa valga 140°	Fair





Figure 2 A Transcervical fracture of the right hip of a 9-year old girl *B Open reduction and fixation with K-wires*

treated operatively one good and one fair result were recorded, the one patient with a [illegible]lateral fracture was classified as having a [illegible]oor result In this patient a valgus and derotation osteotomy had to be performed 2 years after the accident With the exception of one patient, differences in the leg length occurred in all the cases, ranging from 0 5 to 2 cm Four of the seven patients with intertrochanteric fractures developed a coxa valga

Adolescents

Transcervical fractures (Table 6) were encountered in eight patients with an average age of 15 years The follow-up was carried out an average of 14 3 years (range 7 to 28 years) after the accident Three patients were treated non-operatively, another three were treated by immediate internal fix[illegible] whereas two patients were treated opera[illegible] after unsuccessful attempts at non-opera[illegible] treatment for 1 to 3 months. Among the [illegible] patients treated by immediate operation [illegible] good and one fair result were achieved T[illegible] two patients treated operatively [illegible] months after the accident both had [illegible] results Two of the patients treated [illegible] operatively developed non union In one [illegible] bone grafting and simultaneous nailing [illegible] performed 2 years after the accident [illegible] other case a subtrochanteric valgus osteo[illegible] and a bone graft were performed 10 mo[illegible] after the accident Both fractures event[illegible] healed The third non-operatively tr[illegible] patient had to undergo an arthrodesis d[illegible] complete avascular necrosis of the fem[illegible] head (Figure 4) At the time of the follow-[illegible] examination six of the eight patients [illegible]



ʀesult after 3 years

iscervical fractures had a leg-length dis-
pancy of 1 to 4 cm and one of these six
ients also had a coxa valga This was due to
mature closure of the epiphysis in all cases.

rocervical fractures (Table 7) were
orded in 14 adolescent patients with an
rage age of 15 1 years The average
ow up time was 13 4 years (range 9 to 26
rs) Five patients were treated by
nediate operation Four patients were
ited operatively 2 weeks to 3 months after
accident and five patients were treated
n-operatively with traction and plaster of
is

Among the five patients operated on im-
diately, three good one fair and one poor
ult were encountered The patient with a
or result sustained a postoperative osteitis,
ding to numerous operations with bone
fting Among the patients treated with
delayed operation one good and three poor results were recorded In this group one arthrodesis was planned at the time of reexamination Among the non-operatively treated patients one good and four poor results were recorded, including one arthrodesis performed 9 years after the accident In seven patients there was a leg-length discrepancy of 2 to 6 cm One patient developed a coxa valga, another a coxa vara.

Intertrochanteric fractures (Table 8) were recorded in three patients with an average age of 17 years and an average follow-up time of 20 years (range 15 to 24 years) One patient underwent immediate operative treatment with a good result One patient was treated operatively 4 weeks after the accident but had to undergo an arthrodesis 2 years later The third patient was treated operatively 6 months after the accident and obtained a good result Leg shortening of 2 cm was encountered in two patients

Premature epiphyseal closure occurred in 30 5 per cent (9/26) of the children, predominantly following transcervical fractures (5/7) In adolescents premature closure occurred in 36 per cent (9/22) also predominantly after transcervical fractures (6/8) There was no correlation between epiphyseal closure and the method of treatment

DISCUSSION

The analysis of our results revealed a marked difference between fractures of the femoral neck in children and those in adolescents, concerning both the prognosis and the treatment of choice A clear distinction between children and adolescents should thus be drawn when dealing with femoral neck fractures The prognosis is always better in children than in adolescents

The treatment of choice in our series of children was immediate open reduction and internal fixation with K-wires, followed by immobilization in a hip-spica for 6 weeks A





Figure 2 A Transcervical fracture of the right hip of a 9 year old girl *B Open reduction and fixation with K-wires*

treated operatively one good and one fair result were recorded, the one patient with a ılateral fracture was classified as having a poor result In this patient a valgus and derotation osteotomy had to be performed 2 years after the accident With the exception of one patient differences in the leg length occurred in all the cases ranging from 0 5 to 2 cm Four of the seven patients with intertrochanteric fractures developed a coxa valga

Adolescents

Transcervical fractures (Table 6) were encountered in eight patients with an average age of 15 years The follow up was carried out an average of 14 3 years (range 7 to 28 years) after the accident Three patients were treated non-operatively, another three were treated by immediate internal fix[illegible] whereas two patients were treated oper[illegible] after unsuccessful attempts at non-oper[illegible] treatment for 1 to 3 months. Among the [illegible] patients treated by immediate operation [illegible] good and one fair result were achieved [illegible] two patients treated operatively 1 [illegible] months after the accident both had [illegible] results Two of the patients treated [illegible] operatively developed non union In one c[illegible] bone grafting and simultaneous nailing [illegible] performed 2 years after the accident [illegible] other case a subtrochanteric valgus osteo[illegible] and a bone graft were performed 10 [illegible] after the accident Both fractures even[illegible] healed The third non-operatively tr[illegible] patient had to undergo an arthrodesis d[illegible] complete avascular necrosis of the f[illegible] head (*Figure 4*) At the time of the follow[illegible] examination six of the eight patients [illegible]



'e 3. A. Basocervical fracture of the left hip of 'ear-old girl.



B After 3 months of conservative treatment no signs of bony union, signs of incipient avascular necrosis of the femoral head



P view of the hip after bone grafting operation.



D. Mushroom deformity of the hip joint, with a leg shortening of 3 cm, 12 years after the accident.






Figure 4 A Basocervical fracture of the left hip in a 16 year-old boy

B One year after the accident the fracture is ... Signs of incipient capital necrosis





C Complete necrosis of the femoral head with comprehensive destruction of the hip joint 9 years after the accident

D Hip arthrodesis performed with a ... nail

Table 5 Intertrochanteric fractures (children)

Case	Age at injury (years)	Treatment	Age at last follow-up	Avascular necrosis	Non-union	Leg length	Pain + limited motion	Premature closure	Coxa vara Coxa valga	Second operation	End-result
1	5/12	Open reduction + K-wires	16	—	—	−1 cm	—	—	Coxa valga 165°	—	Fair
2	11	Closed reduction + K-wires, day of accident	14	—	—	−0 5 cm	—	yes	—	—	Good
3	3	Bilateral fractures (flanged nails, 11 days after injury)	13	—	—	left leg +1 cm	yes	—	Coxa valga left 145° right 138°	Bilateral valgus and derotation osteotomy 2 years post injury	Poor
4	10	Spica cast	8	—	—	+0 5 cm	—	—	Coxa valga 142°	—	Fair
5	4	Hip-spica	7	—	—	+0 5 cm	—	—	Coxa valga 145°	—	Good
6	5	Hip-spica	18	—	—	—	—	—	—	—	Good
7	11	Traction and hip-spica for 7 weeks	23	—	—	−2 cm	(+)	yes	—	—	Fair

Table 6 Transcervical fractures (adolescents)

		ent	Age at last follow-up	Avascular necrosis	Non-union	Premature closure	Leg length	Pain + limited motion	Coxa vara Coxa valga	Second operation	End-result
		Open reduction 4 K-wires, day of injury	26	—	—	—	—	—	—	—	Good
2	13	Open reduction	26	—	—	yes	−1 cm	—	Coxa valga 140°	—	Fair
3	17	Open reduction + nailing day of injury	25	—	—	—	—	—	—	—	Good
4	15	Closed reduction (traction)	43	—	yes	yes	−3 cm	yes	—	Nailing and grafting of pseudarthrosis 2 years post injury	Poor
		reduction ction + spica cast)	30	—	yes	yes	−4 cm	yes	—	10 months post injury grafting and subtroch valgus osteotomy	Poor
	15	Closed reduction (spica cast)	22	yes	—	yes	−3 cm	—	—	Arthrodesis 1 year post injury	Poor
7	16	Open reduction + nailing 1 month	25	yes	—	yes	−4 cm	yes	—	—	Poor
8	16	Open reduction + nailing 3 months post injury	37	—	—	yes	−3 5 cm	yes	—	—	Poor

onths' period of non-weight-bearing is recommended In adolescents a three-ed nail or screws is recommended ad of K-wires and postoperative immobilization is not considered necessary with a stable internal fixation However, 6 ths' non-weight-bearing is still considered sable Our results clearly demonstrate all fractures of this type should be ed by open reduction and internal ion, with the exception of the impacted iction fractures.

femoral neck fractures among children found that of the 13 cases treated by ediate operation, 11 good and two fair lts were recorded In four cases treated delayed operation only one fair and three results were encountered Among the tures treated non-operatively two good, fair and three poor results were recorded ur opinion, there is thus no doubt that results are improved by immediate rative treatment.

mong adolescents with femoral neck tures nine were operated on immediately, within 36 hours after the accident Six d, two fair and one poor result were rded at the follow-up In the group with yed operative treatment one good and n poor results were recorded, while ng the eight non-operatively treated cases good and seven poor results were rded This demonstrated that even in the up of adolescents the best results were ined with immediate operative treatment

n the group of transepiphyseal fractures, ch occurred only in four children, two e treated operatively on the day of the dent and two were treated conservatively ber (1978) stated that epiphyseal plates can freely crossed with K-wires without any risk damage The K-wire fixation led to good ults without premature closure of the physis. In the two non-operatively treated tures a poor result was encountered

n the group of 26 children only one non-on was encountered and this was in a marily non-operatively treated trans-vical fracture of the neck of the femur Among the 25 adolescents we found four cases of non-union, following two transcervical and two basocervical fractures. The treatment had been non-operative in three cases whereas one fracture was nailed immediately In our opinion immediate operative treatment reduces the risk of non-union

Of the children, 30 per cent (9/27) had premature closure of the epiphysis of the femoral head This occurred after one transepiphyseal, five transcervical, one basocervical and five intertrochanteric fractures Of the adolescents 36 per cent (9/25) had premature closure after three basocervical fractures and six transcervical fractures There was no significant correlation to the mode of treatment

We believe that damage to the epiphysis is correlated with the extent of the damage to the arterial supply of the femoral head at the time of fracture This conclusion seems to be logical considering that blood supply to the epiphysis is more likely to be disturbed in transcervical fractures than in basal fractures (Trueta 1957 and Chung 1976) This again confirms our opinion that the fate of the fracture is largely determined at the moment of the accident by the amount of initial damage to the blood supply Additional damage to the vascular system is caused by repeated closed manipulations or by a too extensive dissection of the joint area during open reduction

According to Canale & Bourland (1977) undisplaced fractures of the neck of the femur give better results than displaced fractures. We believe that the reason for this is that there is less vascular damage in undisplaced fractures. Müller & Ganz (1974) stated that in intracapsular fractures a puncture of the hip joint should be performed as soon as possible, with removal of the intracapsular hematoma. This might prevent the vessels of the proximal femur from being blocked by the increased in intracapsular pressure We feel this to be even more necessary in undisplaced fractures as the joint capsule is undamaged If the puncture is not performed in patients

Table 7 Basocervical fractures (adolescents)

Case	Age at injury (years)	Treatment	Age at last follow-up	Avascular necrosis	Non-union	Premature closure	Leg length	Pain + limited motion	Coxa vara Coxa valga	Second operation	End-result
1	14	Open reduction, 4 K-wires, day of injury	24	—	—	—	—	—	Coxa valga 138°	—	Fair
2	12	Open reduction + K-wires, day of injury	29	—	—	—	—	—	—	—	Good
3	12	Open reduction + 4 K-wires, day of injury	22	—	—	—	−1 cm	—	—	—	Good
4	17	Open reduction + nailing, day after injury	26	yes	yes	—	−6 cm	yes	—	Postop osteitis several reop with nailing and grafting	Poor
5	16	Open reduction + nailing, 2 weeks post injury	42	yes	—	yes	−2 cm	yes	—	—	Poor
6	15	Open reduction + nailing, 4 weeks post injury	26	—	—	—	—	—	—	—	Good
7	14	Open reduction + nailing, 3 months post injury	29	—	—	yes	−2 cm	yes	—	—	Poor

Table 7 (continued)

Case	Age at injury (years)	Treatment	Age at last follow-up	Avascular *necrosis*	Non-*union*	Premature *closure*	Leg *length*	Pain + limited motion	Coxa vara Coxa valga	Second operation	End-result
8	15	Closed reduction (spica cast)	35	yes	—	—	−4 cm	yes	—	Subtroch drill osteotomy *1 year post* injury	Poor
9	15	Closed reduction	17	—	—	—	—	—	Coxa vara + 30° ext rot	Pat died 2 years post injury	Poor
10	17	Closed reduction (spica cast)	38	yes	—	—	−1 cm	—	—	Arthrodesis 9 years post injury	Poor
11	15	Open reduction + nailing, 3 weeks post injury	28	yes	—	yes	−5 cm	yes	—	Arthrodesis planned	Poor
12	17	Open reduction + 4 K-wires, day of injury	22	—	—	—	—	—	—	—	Good
13	17	Skin traction, spica cast	35	yes	yes	—	−3 cm	—	Coxa vara 120°	Osteotomy and grafting 12 months post injury	Poor
14	*16*	*Skin traction,* spica cast	*27*	—	—	—	—	—	—	—	Good

Table 8 Intertrochanteric fractures (adolescents)

Case	Age at injury (years)	Treatment	Age at last follow-up	Avascular necrosis	Non-union	Premature closure	Leg length	Pain + limited motion	Coxa vara Coxa valga	Second operation	End-result
1	18	Open reduction and nailing, day of injury	33	—	—	—	—	—	—	—	Good
2	17	Open reduction and nailing, 4 weeks post injury	39	yes	—	—	−2 cm	yes	—	Arthrodesis 2 years post injury	Poor
3	15	Open reduction and nailing, 6 months post injury	39	—	—	—	−2 cm	(+)	—	—	Good

d non-operatively there may be very is consequences

ıong children we found avascular sis of the femoral head in 19 per cent) The necrosis followed one basocervical ıre two transcervical fractures and two ·piphyseal fractures Three patients treated operatively after some weeks of rvative treatment and two patients were ed non-operatively One patient oped a osteitis Avascular necrosis never oped in patients treated by immediate ıtion.

ıong adolescents avascular necrosis oped in 30 per cent (9/25) There was no on between the type of fracture and ular necrosis in this group The number ıses in our study is too small to allow ıte conclusions to be drawn It is our on however that immediate operative ment gives better results than delayed ative treatment and non-operative treatment.

is in accordance with the results of Ratliff 4) and Lam (1971) and the results of Canale & land (1977).

he recommendation of K wires instead of ws for internal fixation of femoral neck ures in children is based on the fact screws apply traction to the epiphyseal This nearly always leads to an hyseodesis, as reported by Sussenbach & er (1970) In adolescent cases where a nature closure of the proximal epiphyseal e of the femur will not lead to significant shortening screws or three-flanged nails recommended for internal fixation, be- e they produce a more stable fixation.

n conclus on we would like to suggest the owing policy of treatment

ractures of the neck of the femur in dren and in adolescents should always be ıted as an emergency and operative ıtment should be undertaken as soon as sible

When immediate operative treatment is poss'ble for whatever reason a puncture of hip joint should be performed in intra sular fractures.

Independent of the type of fracture internal fixation is always advisable. Screws and nails should not cross an open epiphyseal plate of the head of the femur Crossing with K wires is less dangerous. In basal and transepiphyseal fractures a non-weight bearing period of 6 months is recommended.

In transcervical fractures a non weight bearing period of up to 12 months is regarded as necessary

It is further concluded that the late results of fractures of the neck of femur are poorer in adolescent patients than in children and also that in all types of fractures, in children as well as in adolescents the risk of avascular necrosis, premature closure of the epiphysis and non union is less following immediate operative treatment, than following delayed operative treatment or conservative treat ment.

The prognosis of these fractures depends on the amount of damage to the vasculariza tion and consequently is determined by the localization of the fracture Transcervical fractures are in this respect the most serious type

ACKNOWLEDGMENT

We are indebted to Professor A. Singer of the Schwabinger Krankenhaus Munchen for referring to us eight of the cases included in this study

REFERENCES

Bo tzy A. (1971) *La fracture du col du femur chez l'enfant et adolescent* Masson, Paris.

Bo tzy A (1978) Frakturenbehandlung bei Kindern und Jugendlichen. Ed. Weber Brunner Trenter pp 258 271 Springer Berlin Heidelberg New York.

Canale, S T & Bourland, W C (1977) Fracture of the neck and intertrochanteric region of the femur in children. *J Bone Jt Surg* 59 A, 431–443

Chung St M K. (1976) The arterial supply of the developing proximal end of the human femur *J Bone Jt Surg* 58 A, 1961

Ingram, A J & Bachynski, B (1953) Fractures of the hip in children Treatment and results *J Bone Jt Surg* 35-A, *867–886*

Lam, S F (1971) Fractures of the neck of the femur in children *J Bone Jt Surg* 53-A, 1165–1179

Muller, M E & Ganz, R (1974) *Unfallverletzungen bei Kindern* Ed Rehn, J, pp 153–164, Springer, Berlin-Heidelberg-New York

Pförringer, W & Rosemeyer, B (1977a) Schenkelhalsfrakturen im Kindesalter *Arch orthop Unfall-Chir* 88, 218–308

Pförringer, W & Rosemeyer, B (1977b) Schenkelhalsfrakturen bei Jugendlichen Eine Langzeituntersuchung von 22 Fallen vor und nach Epiphysenschluss. *Arch orthop Unfall-Chir* 90, 169–185

Ratliff, A H C (1974) Fractures of the [illegible] the femur in children *Orthop Clin* [illegible] 168–173

Ratliff, A H C (1968) Traumatic [illegible] the upper femoral epiphysis in [illegible] *J Bone Jt Surg* 50-B, 757

Sussenbach, F & *Weber, B G* [illegible] Epiphysenfugen-verletzungen am Unterschenkel Hüber, Bern Stuttgart, W[illegible]

Trueta, J (1957) The normal [illegible] the human femoral head during gro[illegible] *Bone Jt Surg* 50-B, 757

Weber, B G (1978) Die Frakturenbehand[illegible] Kindern und Jugendlichen. Ed Brunner-Trenter, pp 21–57, Springer [illegible] Heidelberg-New York

Correspondence to W Pförringer, M D, Staatl Orthopadische Klinik Munchen, D 800 Munc[illegible] Harlachinger Strasse 51, Fed Rep Germany

rthop scand. 51, 109–117, 1980

TERMINATION OF THE VITALITY THE FEMORAL HEAD WITH C-SN-PYROPHOSPHATE SCINTIGRAPHY

EN GREIFF

tment of Orthopaedic Surgery, Department of Clinical Physiology, and Department of Pathology, vre Hospital, Hvidovre, Denmark

A series of 14 patients who for various reasons were scheduled for total hip replacement were investigated ^{99m}Tc-Sn pyrophosphate scintigraphy and tetracycline labelling of the bone structure was performed prior to surgery, and subsequently the femoral heads were submitted to histological evaluation on decalcified as well as non-decalcified slides. The evaluation of the scintigraphs was performed by a specialist in nuclear medicine and the histological slides were evaluated by a pathologist, in both cases without

From this study it can be concluded that ^{99m}Tc-Sn-pyrophosphate scintigraphy is an excellent method of assessing bone vitality in the femoral head

Key words bone vitality femoral head scintigraphy, ^{99m}Tc-Sn pyrophosphate

Accepted 1 viii 79

many years orthopaedic surgeons have searching for a simple, safe, accurate, reliable clinical test to assess the vascular s of the femoral head This would de a useful diagnostic and prognostic to aid in planning treatment for several al entities.

bramanian & McAfee (1971) introduced -Sn-polyphosphate as a bone-seeking t. By a microautoradiographic technique ff (1978) showed that the tracer umulated in mineralizing bone tissue, and gested that the uptake of the isotope was ed to the formation of the hydroxy apatite stal. As the polyphosphate in the presence alkaline phosphatase is readily hydrolysed to pyrophosphate, Bowen & Garnett (1974) suggested that ^{99m}Tc-Sn pyrophosphate is the stable unit which deposits in the bone

As the formation of bone is dependent on the vascular supply it seems reasonable to assume that a scintigraphic examination of the femoral head with ^{99m}Tc-Sn-pyrophosphate would reveal areas where the formation of new bone had ceased and bone necrosis had taken place due to a deficient vascular supply

The aim of this work is to evaluate the reliability of ^{99m}Tc-Sn-pyrophosphate scintigraphic examinations for the determination of bone vitality in the human femoral head

1 6470/80/010109 09S02 50/0

PATIENTS AND METHODS

Fourteen patients scheduled for total hip replacement were included in the investigation Thus 14 femoral heads from 14 patients were studied The indications for replacement of the femoral head are listed in Table 1

Patient no 1 had bilateral osteoarthrosis of the hips and a replacement of the right hip had been performed a few months prior to the present investigation *Patients nos 2, 3 and 4* had unilateral osteoarthrosis

In 1962, at the age of 63 years, *patient no 5* had been successfully treated with a Smith-Petersen nail for a medial femoral neck fracture on the left side Eight years later a medial femoral neck fracture on the right side was treated with a Moore prosthesis In 1978 X-ray examination of the left hip showed osteoarthrosis and outward migration of the nail

Patient no 6 had rheumatoid arthritis In 1971 a medial femoral neck fracture on the left side was successfully treated with Moore pins Five years later she developed pain in the left hip, and X-ray examination in 1977 showed an osteoarthrosis.

Medial femoral neck fractures in *patients nos 7, 8, 9, 10, 11 and 13* were all initially treated with closed reduction and osteosynthesis with three to four A–O (ASIF) 6 5 mm lag screws. Three of the fractures united, but a secondary collapse of the femoral head developed In two patients a varus displacement occurred, and one patient developed a pseudarthrosis.

In 1968 *patient no 12* was treated [illegible] McLaughlin osteosynthesis for a medi[illegible] neck fracture A year later the impl[illegible] removed because of pain which was rel[illegible] implant In 1970 a pseudarthrosis develop[illegible] was treated with bone grafting without [illegible]

In 1975 *patient no 14* had a renal tra[illegible] the left side, but the graft was removed [illegible] few weeks because of infection. Fr[illegible] beginning of 1977 the patient complained [illegible] in the left groin A radiologically visible [illegible] the left femoral head was diagnosed in [illegible] 1977

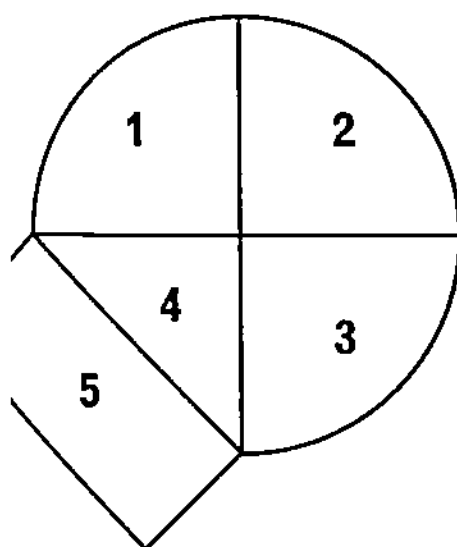
At the same time as the clinical and rad[illegible] investigations of the patients were car[illegible] a ^{99m}Tc-Sn-pyrophosphate scintigraph[illegible] performed

Two hours prior to the scintigraphic ex[illegible] tion each patient received 10 mCi [illegible] pyrophosphate intravenously (5–15 [illegible] pyrophosphate) An anterior image of bo[illegible] [illegible]

[illegible] in the four quadrants of the femoral hea[illegible] 1) on the affected side was compared w[illegible] located in the opposite normal hip (or in [illegible] nos. 1 and 5 with the uptake in the troc[illegible]

Table 1 The age and sex of the patients, and the duration of the disease

Pt no	Sex	Age in years	Pathological picture	Du[illegible]
1	♂	72	Osteoarthrosis coxae sin	5 yrs
2	♂	63	– – –	5 –
3	♀	78	– – –	3 –
4	♀	66	– – –	2 –
5	♀	79	Osteoarthrosis seq fractura colli femoris medialis	16 –
6	♀	68	– – – – – – –	5 –
7	♀	71	Collapsus capitis femoris seq fractura colli femoris med	17 mo
8	♀	66	– – – – – – – –	15 –
9	♀	73	– – – – – – – –	9 –
10	♀	62	Fractura colli femoris medialis – failure of implant	3 –
11	♂	78	– – – – – – –	2 –
12	♂	78	Pseudarthrosis colli femoris, seq fract. colli fem med.	8 yrs
13	♀	91	– – – – – – –	14 mo
14	♂	40	Collapsus capitis femoris, secondary to renal transplant ?	2 yrs



e 1 The accumulation of isotopes was ated in the four quadrants of the femoral and in the femoral neck

on the same side) and graded "0" for no te '1" for less than normal uptake, "2' for al uptake and "3" for greater than normal te (Table 2)

all but one patient (no 14) a tetracycline ing was carried out on the 15th 14th, 3rd 2nd preoperative day using oxytetracycline ng given orally four times a day

le femoral head was divided into two and one decalcified with either Calcifix (Kunz Instru- A/S Denmark) or EDTA (E Merck, mstadt, Germany) Histological slides were ared stained with haematoxylin-eosin and iated by a pathologist without reference to nt history or X ray pictures Loss of os rtes and necrosis of the soft tissue between trabeculae were indications of a deficient ular supply It was noted whether new bone iation was present or not.

other halves of the femoral heads were edded in methyl methacrylate In eight imens thin sections were cut from the merized block and then ground to a thickness about 100 μm. From the remaining six imens 100 μm thick sections were cut directly the block utilizing a Leitz Sagemikrotom 0 Wetzlar, Germany The sections were mined in ultraviolet light and evaluated for the ence of tetracycline by reference to the rescent state

RESULTS

The scintigraphs of the osteoarthrotic hips showed an increased activity, either distributed diffusely all over the femoral head (pts nos 2, 5 and 6) or predominantly in the two upper quadrants (pts nos. 1, 3 and 4) (Figures 2 to 5) When a prosthesis was present (pts nos 1 and 5) no activity was found in the area of the femoral head (Figure 6)

In the case of collapse of the femoral head following a medial femoral neck fracture demonstrated radiologically (pts nos 7, 8 and 9) (Figure 7) decreased activity or no activity was found in the femoral head, whereas increased activity was seen in the femoral neck (Figure 8) In the two patients where failure of an implant led to hip replacements the activity found in the femoral head was normal in one (pt no 10) and decreased in one (pt no 11), but in both patients the femoral neck activity was increased

When a pseudarthrosis was present (pts. nos 12 and 13) (Figures 9 and 10) the scintigraphs showed an absence of activity corresponding to the femoral head, even though the X-ray examination showed no collapse of the femoral head

In patient no 14 the scintigraphs showed less activity in the upper lateral quadrant of the femoral head compared with the high level of activity in the remaining three quadrants (Figures 11 and 12)

No discrepancies were found between the findings of the two histological evaluations of bone vitality in the femoral head When tetracycline was present, the decalcified slides showed the presence of osteocytes and new bone formation Lack of tetracycline was tantamount to bone necrosis, with no osteocytes, no bone formation and necrosis of the soft tissue

When the scintigraphic examination showed no activity or a decreased amount of activity the histological examination showed bone necrosis, whereas increased activity corresponded to vital bone The overall results of the study are shown in Table 2



Figure 2 X ray picture of a 79 year old patient showing secondary osteoarthrosis of the left hip following a medial neck fracture (pt no 5)




Figure 3 ^{99m}Tc-Sn pyrophosphate distr[illegible] the hip (pt no 5) Increased uptake is fr[illegible] all four quadrants of the femoral head.



Figure 4 X ray picture of a primary osteoarthrosis in the right hip (pt no 3)



Figure 5 The distribution of [illegible] pyrophosphate in a patient [illegible] osteoarthrosis (pt no 3) The increased [illegible] located in the two upper quadrants of the [illegible] head

: 6 ^{99m}Tc-Sn-pyrophosphate distribution in ght hip of pt no 5, who had a Moore pros inserted 8 years prior to the present in ation No uptake of the isotope is seen d the prosthesis

DISCUSSION

The ability of ^{99m}Tc-Sn phosphate compounds to deposit in bone as demonstrated by Subramanian & McAfee (1971) (polyphosphate) and Perez et al (1972) (pyrophosphate) has led to the study of a variety of bone disorders, as listed by Silberstein (1976) It has been shown by Tilden et al (1973) Galasko (1975) and Greiff (1978) that ^{99m}TC-Sn polyphosphate/pyrophosphate accumulates in newly formed mineralizing bone tissue The interpretation of the scintigraphs obtained in this study is based on this view

In the femoral heads showing increased uptake, i e primary and secondary arthrosis, one has to look for a trigger mechanism inducing new bone formation According to Wolff's Law (1890) an altered stress pattern should induce a remodelling with increased uptake of isotope compounds Lane et al. (1977) found that the vascularity and remodelling in the subchondral calcified zone varies according to stresses within the joint, possibly by stress induced microfractures as suggested by Radin et al (1973) The

Table 2 The results of the scintigraphic and histological evaluation

Scintigraphic evaluation area					Histological evaluation				
1	2	3	4	5	V	O	B	N	T
3	2 3	3	2	2–3	+	+	+	–	+
3	2	2–3	2	2	+	+	+	–	+
2–3	2–3	2	2	2	+	+	+	–	+
3	2–3	2	2–3	2	+	+	+	–	+
3	3	3	3	2	+	+	+	–	+
3	3	3	3	2	+	+	+	–	+
0	0	0	3	2–3	–	–	–	+	–
0	0	0	0	3	–	–	–	+	–
2–3	1	1	3	2	–	+–	–	+	–
2	2	3	3	3	+	+	+	–	+
0	0	0	0	2–3	–	–	–	+	–
0	0	0–1	0	2	–	–	–	+	–
1	1	1	1	2–3	–	–	–	F	–
0	1	3	3	2	+–	±	+	±	0

vital femoral head, O = osteocytes, B – new bone formation N = necrosis of the intratrabecular e T = tetracycline and F = fatty degeneration of the intratrabecular tissue



Figure 2 X ray picture of a 79-year-old patient showing secondary osteoarthrosis of the left hip following a medial neck fracture (pt no 5)

Figure 3 ^{99m}Tc-Sn pyrophosphate d the hip (pt no 5) Increased uptake u f all four quadrants of the femoral head.



Figure 4 X ray picture of a primary osteoarthrosis in the right hip (pt no 3)

Figure 5 The distribution of pyrophosphate in a patient with osteoarthrosis (pt no 3) The located in the two upper quadrants of the f head



ire 11 X ray picture (tomography) of a ient with a partial femoral head necrosis owing a kidney transplant (pt no 14)



Figure 12 ^{99m}Tc Sn pyrophosphate distribution in a patient with a partial femoral head necrosis following a kidney transplant (pt no 14) Increased activity is seen in quadrants 2 3 and 4 and decreased isotope accumulation is seen in quadrant 1

ntigraphs of coxarthrosis in this dy compare very well with the findings of nielson et al (1965) who performed ntimetry after intravenous injection of and the findings of Heerfordt et al 76) who employed F^{18} in their studies

When a radiologically visible collapse icated the presence of femoral head rosis, the scintigraphs showed decreased no uptake The fractures had united and collapse developed during weight bearing e collapse appears to be the result of multiple rofractures in the subchondral zone where repair can take place due to an impaired od supply As the trabeculae supporting the tilage deteriorate the cartilage becomes se and can be removed like the peel of an nge With continued weight bearing the tilage is pressed further and further down o the remains of the femoral head until ally it rests on vital bone

Shoji et al (1972) examined femoral neck ctures by Sr^{85} scintimetry They found an increased mean head count rate up to 4 years after the fracture in patients with osteonecrosis As these authors dealt mainly with the late repair process after avascularity and collapse of the femoral head no contradiction exists between their findings and the findings of McGrail et al (1974) Riggins et al (1974) D Ambrosia et al (1975a) and Stadalnik et al (1975) who in studies of medial femoral neck fractures using F^{18} scintigraphs could diagnose the avascularity of the femoral heads by the lack of isotope accumulation in the area The scintigraphs produced by D Ambrosia et al (1975b) who used ^{99m}Tc-diphosphonate by Greiff et al (1980) who used ^{99m}Tc-Sn pyrophosphate and by Meyers et al (1977) who used ^{99m}Tc-sulphur-colloid all demonstrated clearly the vascular/avascular status of the femoral head following medial neck fractures.

In this study the scintigraph showed decreased or no uptake of the isotope in two

patients with medial femoral neck pseudarthrosis even though no radiological collapse of the femoral head was present The histological diagnosis was necrosis in both cases The pseudarthrosis had apparently in some way protected the femoral heads from a collapse, probably by pain which prevented the normal use of the leg and consequently there was insufficient loading for the production of microfractures In patients where a failure of implants following medial femoral neck fracture indicates repeated surgery or where a medial femoral neck pseudarthrosis has developed, scintigraphy is the best method of evaluation and a prerequisite for selection of the proper surgical procedure (pts nos 10–13) Reosteosynthesis and bone grafting should probably not be done in patients with avascular femoral heads These patients will be better off with a hip replacement

In non-traumatic necrosis of the femoral head Cameron (1969) found an increased Sr^{85} activity over the femoral head, and tissue examination revealed this activity to be located in the repair reaction at the margin of the necrotic bone This finding is compatible with the findings of the present study in patient no 14 (Figure 12) The aetiology of this type of lesion is obscure, but believed to be related to high doses of steroid (Harris et al 1974), and fatty embolization in the subchondral a as suggested by Cruess (1977)

is study has shown ^{99m}Tc-Sn-hosphate scintigraphy to be an excellent ethod for assessing bone vitality in the femoral head The convenient half-life of ^{99m}Tc, the easy preparation of the kit and the results obtained in this study indicate that ^{99m}Tc-Sn-pyrophosphate scintigraphy could be an important tool in the diagnosis of a variety of bone disorders, permitting more accurate prognoses, and enabling the selection of the most appropriate surgical procedure and the most suitable preventative measures

ACKNOWLEDGEMENT

I wish gratefully to acknowledge the help I have received from Dr P Christoffersen, M D, Department of Pathology Dr P F [illegible] Carlsen Department of Clinical [illegible] Hvidovre Hospital and Dr H Bohr M.D. [illegible] Laboratory of Osteopathology of the [illegible] of Orthopaedics, Rigshospitalet Copenhagen

REFERENCES

Bowen, B M & Garnett, E S (1974) Analysis relationship of ^{99m}Tc-Sn-polyphosphate ^{99m}Tc-Sn-pyrophosphate *J nucl Med* 652–655

Cameron, R B (1969) Strontium 85 [illegible] in non-traumatic necrosis of the femoral [illegible] *Clin Orthop* 65, 243–261

Cruess, R L (1977) Cortisone-induced [illegible] necrosis of the femoral head. *J Bone J S* 59 B, 308–317

D'Ambrosia, R D Riggins, R S De[illegible] & DeNardo, G L (1975a) [illegible] scintigraphy in avascular necrotic disorders bone *Clin Orthop* 107, 146–155

D'Ambrosia, R D, Riggins, R. S., S[illegible] R C & DeNardo G L (1975b) Experience [illegible]

[illegible]

(1965) Coxarthrosis in man [illegible] external counting of Sr^{85} and Ca^{47} [illegible] *Orthop* 31, 184–199

Galasko, C S B (1975) The pathological basis skeletal scintigraphy *J Bone Jt Surg* [illegible] 353–359

Greiff, J (1978) Autoradiographic studies fracture healing using ^{99m}Tc-Sn-polyphos[illegible] *Injury* 9, 271–277

Greiff, J, Lanng, S, Høilund-Carlsen, P F, A K. & Uhrenholdt, A (1980) Early detection ^{99m}Tc-Sn pyrophosphate scintigraphy femoral head necrosis following medial [illegible] fractures *Acta orthop scand* 51, 119–125

Harris, R R, Niemann K. M W & D[illegible] A G (1974) Skeletal complication after transplantation *Sth med J (Bgham* [illegible] 1016–1019

Heerfordt, J, Vistiesen, L. & Bohr H [illegible] Comparison of ^{18}F and ^{99m}Tc-polyphosphate orthopedic bone scintigraphy *J nucl Med* 98–103

Lane, L B, Villacin, A & Bullough, P G [illegible] The vascularity and remodelling of [illegible] chondral bone and calcified cartilage [illegible] human femoral and humeral heads *J Bone Surg* 59-B, 272–278

McGrail J W, Vulpetti, A T & Sh[illegible] (1974) ^{18}F scintigraphy of non-[illegible] skeletal lesions. *Clin Orthop* 101, 292 [illegible]

rthop scand. 51, 119–125, 1980

ʟLY DETECTION BY ^{99m}TC-SN-PYROPHOSPHATE NTIGRAPHY OF FEMORAL HEAD NECROSIS ʟLOWING MEDIAL FEMORAL NECK FRACTURES

EN GREIFF, SUSANNE LANNG, POUL F HØILUND-CARLSEN
TE K. KARLE & ANDERS UHRENHOLDT

rtment of Orthopaedic Surgery, Department of Clinical Physiology, Department of
logy, University of Copenhagen, Hvidovre Hospital, Hvidovre, Denmark

A selected series of 24 patients with displaced medial femoral neck fracture, treated with closed reduction and osteosynthesis with cancellous bone screws (ASIF), were investigated.

During an observation period of 6 to 26 months, serial hip joint scintigraphies were performed and compared with serial X-ray examinations At the first scintigraphic examination performed on average 5–6 weeks after the fracture, two separate investigators found a decreased amount of activity or no activity in the femoral head of 10 and 8 patients, respectively At the second scintigraphic examination performed on average 11 1 weeks after the fracture both investigators found no activity or a decreased amount of activity in 8 patients. This figure declined to 7 during the following period, because one patient with decreased activity was recorded as having normal activity 15 months after the fracture. These 7 patients all developed radiological signs of femoral head collapse on average 16 3 months after the fracture (range 5–26 months), whereas their scintigrams displayed decreased or absent tracer uptake on average 1 2 months after the fracture ($P < 0\,01$) None of the patients with initially normal or increased uptake later showed decreased or absent uptake during the study and none developed radiological collapse

It may be concluded that absent or decreased uptake of ^{99m}Tc-Sn-pyrophosphate in the femoral head following medial femoral neck fracture indicates femoral head necrosis and a high risk of late segmental collapse, whereas normal or increased uptake implying preserved blood supply means that late segmental collapse will probably never develop

Key words bone vitality, femoral head collapse, femoral head necrosis, medial femoral neck fracture, scintigraphy, ^{99m} Tc-Sn pyrophosphate

Accepted 1 viii 79

ıal femoral neck fractures have a high lence of late segmental collapse of the ɔral head A variety of methods have been ested for predicting the viability of the ɔral head, but none have hitherto been ciently easy or rapid to perform or ble enough for clinical application Greiff 0) showed that ^{99m}Tc-Sn-pyrophosphate scintigraphy is a reliable method for the prediction of bone vitality of the femoral head In the present study this method was employed in a selected series of intracapsular medial neck fractures and the ability of the method to diagnose femoral head necrosis and to predict late segmental collapse was evaluated

-6470/80/010119–07$02.50/0

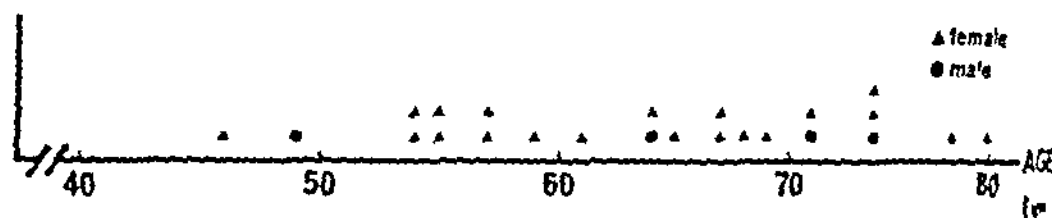


Figure 1 Sex and age distribution

PATIENTS AND METHODS

This study includes 24 patients with displaced medial femoral neck fractures who were treated with closed reduction on an extension table and osteosynthesis with three to four 6 5 mm cancellous bone screws (ASIF). The distribution as regards age and sex is given in Figure 1

At regular intervals during the observation period, which ranged from 6 to 26 months (mean value 14 months) a ^{99m}Tc-Sn [illegible]

[illegible] an intravenous injection of 10 mCi ^{99m}Tc-Sn-pyrophosphate and with the patient in the supine position, an anterior image of both hips was obtained utilizing a gamma camera (General Electric Radi camera II) supplied with a 6 mm pin hole collimator collecting a total of 250 000 counts.

For the evaluation of the scintigraphs the isotope accumulation in the four quadrants of the femoral head and neck (Figure 2) was compared with that in the scintigraphs of the contra- normal hip and graded 0 for no uptake 1 decreased uptake 2 for normal uptake, and increased uptake The scintigraphs were eval- separately by two members of the staff of Department of Clinical Physiology wi- reference to patient history and X-rays.

The scintigraphs were considered to be when a grading of at least 2 was encounter- all four quadrants, as showing a partial de- when a grading of 0 or 1 was found in one or quadrants, and as showing a total defect whe- grading of 0 or 1 was encountered in thr- more quadrants (Greiff 1980).

For the purpose of this study all the X pictures were reviewed by two radiologists the findings relating to the femoral head gra- for normal findings, S for slightly irregular of the femoral head or for areas of osteo- osteosclerosis and C for collapse of the fe- head




Figure 2 Areas of int

RESULTS

Scintigraphically identical grading obtained by the two examiners in 7? cent of the 580 different areas while a difference of one step on the 4 scale was encountered in 21 9 per Differences of two and three steps were in 2 6 per cent and 2.6 per cent,

In the group of patients with uptake on the scintigraphs (Table I) minor discrepancies between the gr the two examiners occurred on the scintigraphs, as one examiner had a ne in one quadrant in two of the ile the other examiner found e These discrepancies disappe uation of the second scint graphs the differences of opin

Table 1 Results of the ^{99m}Tc-Sn pyrophosphate scintigraphy (femoral head vitality and the radiological evaluation (radiologically visible collapse)

	SCINTIGRAPHY						RADIOLOCICAL COLLAPSE
	FIRST EXAM		SECOND EXAM		FOLLOW UP		
	A	B	A	B	A	B	
OTAL DEFECT	6	6	6	6	6	6	6
ARTIAL DEFECT	4	2	2	2	I	I	I
ORMAL OR IN-REASED UPTAKE	I4	I6	I6	I6	I7	I7	0

wo examiners were of no significance, as liscrepancies occurred in the overall ation of the scintigraphs

sed on the scintigraphic findings of the two scintigraphs following the fracture, rmed on average after 5 6 weeks and weeks, the patients could be divided into major groups, i e patients with normal creased uptake in the femoral head and nts with decreased or no uptake The r group could be divided into two roups according to the extent of the area creased uptake (Table 1)

In none of the sixteen patients showing normal uptake in the femoral head did the scintigraphic findings change to decreased uptake during the observation period, and none of these patients developed radiological signs of femoral head necrosis

Six patients whose scintigraphs displayed decreased or no uptake of the isotope in three or four quadrants, an average of 4 6 weeks after the fracture (range 0 3–9 5 weeks) (Figures 3 and 4) all developed radiological



ire 3 Normal ^{99m}Tc-Sn pyrophosphate hip tigraphy (patient no 2, right side)



Figure 4 Pathological ^{99m}Tc Sn pyrophosphate hip scintigraphy performed 5 months after the fracture showing defective isotope uptake in areas 1, 2 and 3, and increased uptake in areas 4 and 5 (patient no 2, left side)

gained wide acceptance, primarily because of technical complexities, difficulties in interpretation, high cost, or because surgical invasion is often required to perform the test

With the introduction of the ^{99m}Tc-labelled phosphate compounds by Subramanian & McAfee (1971) (polyphosphate) and Perez et al (1972) (pyrophosphate) a new development in the solution of the problem appeared possible These radionucleides accumulate wherever formation of new bone material takes place (Greiff 1978) rendering the skeletal system visible by scintigraphic technique Hyperaccumulation is seen in regions of new bone formation, as for instance at fracture sites A primary condition for new bone formation is preservation of the blood supply to the investigated area In the case of avascular necrosis, tracer accumulation will not take place at all, thus making the necrotic spot visible as a defect devoid of tracer (except for the activity in the surrounding tissue) (Greiff 1980)

Korvald & Sundsfjord (1974) performed ^{99m}Tc-Sn-polyphosphate scintigraphy in 16 patients of whom 15 had proximal femoral fractures but no definite conclusion could be drawn as to the predictive ability of the method as regards late segmental collapse, probably because of the relatively small size of their material

In a selected material of 40 patients with splaced medial neck fractures, treated with ternal pedicle flap and osteosynthesis, Meyers et al (1977) found 32 patients with necrosis of the femoral head before surgery, judged by ^{99m}Tc-sulphur-colloid scintigraphy, supplemented with histological examination of a core biopsy from the femoral head Of the 40 hips, 25 which could be investigated 1 year or more after the fracture showed normal scintigraphy, and the rate of late segmental collapse fell to zero

This method however, is not readily comparable to scintigraphy with ^{99m}Tc-pyrophosphate, since ^{99m}Tc-sulphur-colloid is taken up by the Kupffer cells in bone marrow and not by the bone material itself

In our study decreased or no uptake in three or four quadrants of the femora[illegible] invariably led to a radiologically de[illegible] late segmental collapse The [illegible] diagnosis of femoral head necrosis determined on average more than [illegible] before the radiological signs developed [illegible] only a minor defect of activity was fo[illegible] prediction was uncertain. A m[illegible] possibly caused by internal vascular [illegible] in the femoral head due to the [illegible] led to either collapse or revasculari[illegible] depending on the external vascular supp[illegible]

Even more important, increased act[illegible] normal activity on scintigrams in the [illegible] period following the fracture [illegible] indicated that no femoral head necrosis [illegible] present and that late segmental c[illegible] would not develop

As shown by Bohr & Larsen (19[illegible] revascularization is accompanied b[illegible] formation of new bone by creeping [illegible] tion, but this is a rather time-consum[illegible] cedure Charnley et al (1957) showed [illegible] only 0 5 cm of the area close to the fr[illegible] in the femoral head became revascul[illegible] within 4 5 months. In this study [illegible] signs of revascularization with [illegible] apposition were found as increased ra[illegible] tivity in the area around the fractur[illegible] the lower medial quadrant but [illegible] revascularization was not achieved [illegible] patient with a scintigraphic total [illegible] before late segmental collapse deve[illegible] even though weight-bearing in two [illegible] was deferred for approximately 1 ye[illegible] revascularization only occurs very slowly [illegible] pertinent to ask whether revasculariza[illegible] worth waiting for This necrosis of [illegible] femoral head is actually "Calvé-Legg-Pe[illegible] disease" of adults, and knowing [illegible] revascularization of a child's head [illegible] several years revascularization of an [illegible] femoral head can be expected to take [illegible] longer

The early prediction of femoral h[illegible] necrosis and subsequent segmental colla[illegible] shown in this study indicates [illegible] scintigraphy will become a valuable [illegible] nostic tool in the management of [illegible]

medial femoral neck fractures The ...d is non-invasive, easy to perform and ...ut complications. Further investigations ...e necessary to evaluate more accurately ...edictive diagnostic value

...ERENCES

...s, R, Brown, J T, Garden, R S & Nicoll, A (1976) Subcapital fractures of the femur *Bone Jt Surg* 58-B, 2–24

... H & Larsen, E H (1965) On necrosis of ... femoral head after fracture of the neck of ... femur *J Bone Jt Surg* 47-B, 330–338

... H B, Zilmersmit, D B & Calandruccio, A. (1955) The use of radioactive phosphorus ...) to determine the viability of the head of ... femur *J Bone Jt Surg* 37-A, 260–269

..., T & Bourland, W L (1977) Fracture of ... neck and intertrochanteric region of the ...nur in children *J Bone Jt Surg* 59-A, ...1–443

...ley, J, Blockey, N J & Purser, D W ...957) The treatment of displaced fractures of ... neck of the femur by compression. *J Bone Jt ...rg* 39-B, 45–65

...olm, A. (1970) Vascularization of the femoral ...ad following fracture of the neck of the ...nur *Acta orthop scand* 41, 648–667

...n, R S (1961) Low-angle fixation in ...ctures of the femoral neck *J Bone Jt Surg* ...B, 647–663

[illegible]

..., J (1980) Determination of the vitality ... the femoral head with ^{99m}Tc-Sn-...rophosphate scintigraphy *Acta orthop ...and* 51, 109–117

...quist, B & Alfram, P A (1965) Prediction ... avascular necrosis following cervical fracture ... the femur based on the clearance of ...dioactive iodine from the head of the femur *...cta orthop scand* 36, 62–69

...h, A (1956) Intra-osseus venographies of ...edial fractures of femoral neck, residual ...ascularity of head fragment in different types ...f fractures and its relation to prognosis. *Acta ...hir scand*, Suppl. 214,

Korvald, E & Sundsfjord, A. J (1974) Examination of the vascular disturbance of the femoral head following intracapsular fracture of the hip *Acta orthop scand* 45, 572–578

Lauritzen, J (1974) The arterial supply to the femoral head in children *Acta orthop scand* 45, 724–736

McGrail, J W, Vulpetti, A. T & Shifrin, L. (1972) ^{18}F scintigraphy of non-neoplastic skeletal lesions *Clin Orthop* 10, 292–298

Meyers, H M, Telfer, N & Moore, T M (1977) Determination of the vascularity of the femoral head with technetium 99m-sulphur-colloid *J Bone Jt Surg* 59 A, 658–664

Pauwels, F (1935) *Der Schenkelhalsbruch, ein mechanisches Problem* Ferdinand Enke, Stuttgart

Pelzl, H, Zierz, P & Rogausch, H (1972) Vitalitatabestimmung des Femurkopfes nach medialen Schenkelhalsfrakturen mit Hilfe der intraossalen Druckmessung *Bruns Beitr klin Chir* 219, 347–357

Perez, R, Cohen, Y & Henry, R (1972) A new radiopharmaceutical for ^{99m}Tc bone scanning *J nucl Med* 13, 788

[illegible] Femoral neck fractures in young adults. *J Bone Jt Surg* 58-A, 689–695

[illegible] predicting end results in intracapsular and intertrochanteric fractures of the femur *Amer J Surg* 86, 404–409

Shoji, H, Koshino, T & Doherty, J H (1972) [illegible] complex of [illegible] *Radiology* 99, 192–196

Trueta, J (1957) Appraisal of the vascular factor in the healing of fractures of the femoral neck Editorial. *J Bone Jt Surg* 39-B, 3–5

Trueta, J (1957) The normal vascular anatomy of the human femoral head during growth *J Bone Jt Surg* 39-B, 358–394

...espondence to Jørgen Greiff, M D, Ahornvej 40, 2970 Hørsholm, Denmark

ɔrthop scand. 51, 127–136 1980

MORAL NECK FRACTURES

Cases Treated by Multiple Percutaneous Pinning

ꞏOFOED & A. ALBERTS

ɪrtment of Orthopaedic Surgery, Sodersjukhuset, Stockholm, Sweden

A prospective series of 165 displaced subcapital fractures of the femoral neck treated with reduction and percutaneous multiple pinning is presented The method offers the advantages of a short operating time, no loss of blood, immediate weight-bearing and no infection problems. Furthermore the operative procedure can be performed under local anaesthesia

In Garden stage 3 fractures union occurred in 97 per cent and late segmental collapse in 8 per cent In Garden stage 4 fractures union occurred in 72 per cent and late segmental collapse in 14 per cent

Failures were almost exclusively encountered in the group of poorly reduced fractures which had a failure rate of 77 per cent.

In the case of non-union 75 per cent of the patients needed a secondary hip replacement whereas only 16 per cent of the patients with late segmental collapse had received an arthroplasty at the time of the follow-up

Key words femoral neck fractures, fracture fixation

Accepted 2 xi 79

ınsosseous revascularization of a partially totally avascular femoral head can take ꞏe (Brown & Abrami 1964, Catto 1965, ꞏgins et al. 1974, Meyers et al 1977 and ɪoldi & Lemperg 1977) In order to obtain ꞏd results in the treatment of displaced ɪoral neck fractures exact fracture uction and stable fixation is essential ırden 1961, 1971, Brown & Abrami 1964, yerle 1966, Barnes et al 1976, Arnold et al 74, Arnoldi & Lemperg 1977 and Meyers et 1977)

This study presents a series of 165 placed subcapital fractures of the femoral ꞏk treated by percutaneous multiple ıning

TIENTS AND METHODS

ꞏing the period January 1st to December 31st, 75, a consecutive series of 165 patients over the age of 50 with displaced subcapital fractures of the femoral neck were treated with reduction and percutaneous multiple pinning of their fracture

The fractures were divided into groups according to Garden (1961) as demonstrated in Figure 1 In the present series 92 fractures belonged to stage 3 and 73 to stage 4

Eighty-eight per cent (146/165) of the patients were operated on using spinal or epidural analgesia If contraindications were encountered a local anaesthetic was injected into the hip joint, and into the skin, muscles and periosteum on the lateral aspect of the subtrochanteric femoral area Local anaesthesia was used in 19 cases.

At operation the patient was placed supine on the fracture table The fracture was reduced by gentle traction and inward rotation or by Leadbetter's method (Leadbetter 1933) The reduction was checked by means of a two-plane image intensifier The appropriate length of the nail was determined by placing nails on the ventral aspect of the hip under image intensification Through a skin incision 1–1½ cm long below the greater trochanter the first nail was inserted through the cortical bone A further two nails were placed parallel to the first in the frontal view

ɔı 6470/80/010127–10$02.50/0



Figure 1 Classification of femoral neck fractures according to Garden (1961) A Stage 3 Co[illegible] subcapital fracture with partial displacement B Stage 4 Complete subcapital fracture w[illegible] [illegible] placement

In the lateral view the nails can be placed parallel or crossed (Figure 2a) One nail must be supported by the calcar femorale The nail must be directed at the correct angle before penetrating the cortical bone as later adjustment is difficult The tips of the nails were placed in the subchondral bone preferably leaving only the screw-thread outside the cortical bone (Figure 2b) The required instrumentation is shown in Figure 3

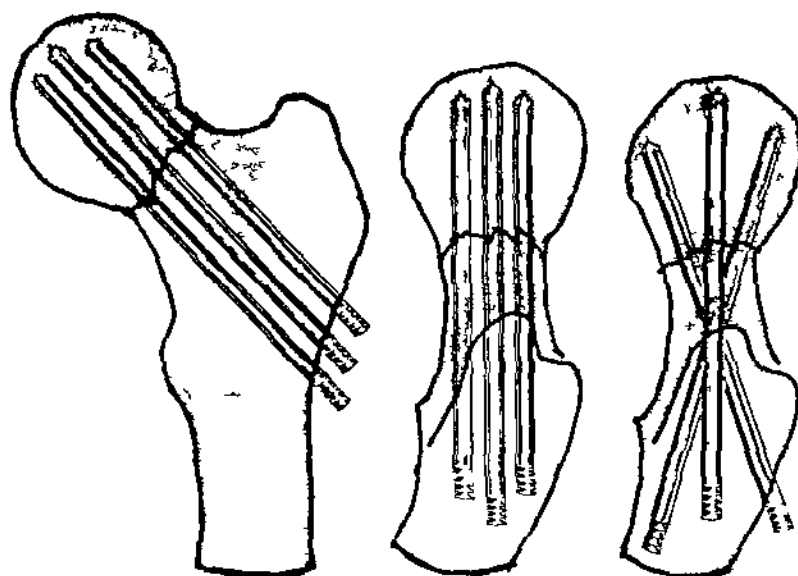
The patients were mobilized from the first postoperative day and allowed as much weight-bearing as they could tolerate A clinical and radiological follow-up was undertaken every 6 months for 2–3 years after the internal fixation

The follow-up was attended by 112 patients or 68 per cent, 49 had died and four were lost to follow-up The average age of the patients who had died was 83 years (range 61–96 years). None of the deaths could be related to the femoral neck fracture

The average follow-up period was 29 months (range 24–36 months) The series comprised 93 women and 19 men with an average age of 74 years (range 50–94 years)

In order to obtain a reproducible assess[illegible] the patients' clinical results after treatment [illegible] timation of the prefracture condition is [illegible] At the clinical follow up the patients [illegible] assessed according to Andersson & [illegible] (1972) as summarized in Table 1 The [illegible] considers pain mobility and function. O[illegible] modification classified the patients [illegible] stages. Stage 1 0–4 points, stage 2 5–[illegible] stage 3 8–10 points and stage 4 11 21 [illegible] Taking into consideration the patients [illegible] about their prefracture condition [illegible] and function and using the contralateral [illegible] judge mobility at follow-up the end [illegible] assessed as *excellent* if the [illegible] prefracture condition, *good* if one stage [illegible] if two stages below and *poor* if a [illegible] thetic replacement was indicated.

Radiologically the Garden alignment [illegible] (1971) was used to describe the [illegible] reduction of the fractures. Good reduction [illegible] an angle of about 160 degrees (155 15[illegible] in the frontal view of the weight-be[illegible] trabeculae In the lateral view the normal [illegible]



2A Ideal positions of pins Pins placed parallel in the frontal view with support on the calcar le In the lateral view the pins may be placed parallel or crossed

! 2B Ideal positions of pins Pins placed with the tips in the subchondral bone leaving only the threads outside the cortical bone




Figure 3 Instrumentation for percutaneous pinning The shortest and longest pins are shown as well as the pin holder device

of the head relative to the neck was 180 degrees (155–185 degrees). Malreduction was encountered in fractures outside the limits 150/190 in the frontal or lateral view

In united fractures any deformity in the contour of the weight-bearing surface of the femoral head not seen in the original X-rays was considered as a late segmental collapse Fracture union occurs when the trabeculae grow over the entire fracture line. This is often difficult to judge, therefore union was considered established if no secondary dislocation had occurred within a period of 2 years.

RESULTS

The average hospitalization time was 22 days (range 3–65 days) The mortality within 1 month was 3 per cent (5/165), within 6 months 13 per cent (22/165) and within 2 years 29 per cent (49/165) None of the deaths could be related to the femoral neck fracture or its treatment

In the case of nail loosening which never included all nails, the nail was removed under a local anaesthetic. No superficial or deep infections were encountered

It was evaluated whether there was any difference between stage 3 and stage 4 fractures as regards the quality of fracture reduction (Table 2) Stage 3 fractures were significantly easier to reduce than stage 4 fractures.

The clinical assessment at follow-up was excellent results in 82 cases and good in 11, i e, satisfactory results were recorded in 83 per cent (93/112) of the patien s The failure rate corresponding to the fa (5 patients) and poor (14 patients) w 17 per cent (19/112) of the cases.

In order to judge whether the grouping in Garden stages was of gnostic value the results in Garden and 4 were compared. Table 3 dem that uneventful healing was obtained per cent (56/63) of stage 3 fractures with 58 per cent (28/49) of those in st

To evaluate the relationship be radiologically good and poor fr reduction as compared with the results at follow-up, the case divided into two groups. Group 1 cons 86 successfully reduced fractures. Of th per cent (84/86) healed and two non union Seven per cent (6/84) o healed fractures developed late seg collapse. Group 2 consisted of 26 ly reduced fractures. Non-union encountered in 54 per cent (14/26) of Of the 12 fractures that healed, 50 pe (6/12) developed late segmental c (Table 4) The difference between th groups is highly significant. Well r fractures accounted for a failure rate of cent (8/86) whereas the group of reduced fractures had a 77 per cent failure rate

In order to find out whether an other than poor reduction, accord Garden, could account for the re group 2, the X-rays were review special attention was given to other fa malreduction *Ad latus* displacement sufficient bone contact between the components as shown in Figure encountered in 20 cases (Table 5). found that the remaining six fractures united uneventfully without any segmental collapse or femoral head though reduced with an backward angulation, at the same showed firm contact between the fr of the fracture over the whole frac and no *ad latus* displacement.

At the follow-up 14 patients were c

Table 1 Assessment system according to Andersson & Moller Nielsen (1972)

un	1 Pain on starting to walk no 0, yes 1	
	2 Pain when walking no 0, only on strain 1, on all walking 2	
	3 Pain when resting no 0, after strain 1, spontaneous 2	
obility	1 Active flexion (straight leg raising)	0– 45 degrees × 0 6 (– max 27)
		45– 90 degrees × 0 4 (– max 18)
		90–150 degrees × 0 1 (– max 6)
	2 Abduction	0– 15 degrees × 0 6 (– max 9)
		15– 30 degrees × 0 4 (– max 6)
		30– 60 degrees × 0 1 (– max 3)
	3 Adduction	× 0 2
	4 Outward rotation	0– 15 degrees × 0 3 (= max 4 5)
		15– 30 degrees × 0 2 (= max 3)
		30– 80 degrees × 0 1 (– max 5)
	5 Inward rotation	× 0 2
unction	1 [illegible]	
	2	
	3	
	4 Walking distance without pain more than 1,500 metres 0, 400–1500 metres 100–400 metres 2, 1–100 metres 3, cannot walk without pain 4, cannot walk 5	
	5 Can put on own shoes and stockings yes 0, with difficulty 1, no 3	
	6 Can manage stairs yes 0, with difficulty 1, no 3	
	7 Can sit on a low chair yes 0, with difficulty 1 no 3	
	8 Can take a bath without help yes 0, with difficulty 1, no 3	
	9 Working capacity better than before +1, as before 0, worse than before 2	

ASSESSMENT OF MARKS

;	0	1	2	3	4	5	6	7
	0	1	2	3	4	5		
ity	70	69–50	49–35	34–20	19–10	9–0		
ion	0–1	2– 3	4– 5	6	7	8–9	10–11	12–13
;	8	9	10	11				
ity								
ion	14–15	16–18	19–21	22–27				

	Good	Acceptable	Poor
	0–1	2– 3	4– 5
lity	0–1	2– 3	4– 5
ion	0–3	4– 7	8–11
;	0–4	5–10	11–21

ble 2 Quality of reduction in stage 3 and stage 4 fractures (Garden 1961) Results of 165 patients

re stage	Reduction Good	Poor	Total
3	88 % (81/92)	12 % (11/92)	92
4	62 % (45/73)	38 % (28/73)	73
	76 (126/165)	24 % (39/165)	165

uare test $P < 0\ 01$

Table 3 Results of radiological follow-up in the two fracture stages (Garden 1961)

	Stage 3	Stage 4	Total
Non union	3 % (2/63)	28 % (14/49)	14 % (16/112)
Late segmental collapse	8 % (5/63)	14 % (7/49)	11 % (12/112)
Total failure rate	11 % (7/63)	42 % (21/49)	25 % (28/112)

Chi square test $P < 0.001$

Table 4 Radiological results in relation to fracture reduction

	Reduction according to Garden (1971)		
	Good	Poor	Total
No of fractures	86	26	112
Non union	2 % (2/86)	54 % (14/26)	14 % (16/112)
Late segmental collapse	7 % (6/86)	23 % (6/26)	11 % (12/112)
Total failure rate	9 % (8/86)	77 % (20/26)	25 % (28/112)

Chi square test $P < 0.001$

as having clinically poor results Twelve had fractures with non-union and two had late segmental collapse In order to evaluate which was the most serious complication, non-union or late segmental collapse, as regards the clinical result, all radiological cases of non-union and late segmental collapse were considered Out of 16 fractures with non-union 75 per cent (12/16) needed an arthroplasty, whereas this procedure was only necessary in 16 per cent (2/12) of the cases with late segmental collapse

DISCUSSION

So far no reliable method has been found to predict the fate of femoral neck fractures preoperatively Attempts at a prognostic evaluation by means of arteriography, venography, determination of the pressure in the intramedullary cavity of the femoral head, oxygen tension in the head, and various kinds of scintigraphy have been reviewed by Hulth (1965), who states that these methods can predict the fate of the head in 80–90 per cent of cases. The methods mentioned have not attained much clinical significance, but they have contributed to the opinion that of the fractures is determined at the of the accident, everything depending remaining vascularity of the femoral

Other authors, as mentioned below the opinion that transosseous nutr might keep the femoral head alive. B Abrami (1964) on histological exam the femoral heads from five fra late segmental collapse found "clear of an initial severe ischaemia of the fragment and with subsequent revasc tion across a healed fracture revascularizing process, however had to reach the most proximal and sup quadrant of the femoral head years be collapse " Catto (1965) found in 12 late heads, resected for secondary hip arthrop because of late segmental col histological evidence of revasculariza seven out of 12 heads revasculariza reached the fovea of the femoral head.

Riggins et al (1974) in an assess the circulation in the femoral head of the subcapitally osteotomized throu femoral neck, with subsequent reattac of the completely detached femoral h using threaded pins, showed, by mea 18-F scintigraphy, tetracycline label

Example of a poorly reduced fracture with d splacement and insufficient bone contact

cal examination of the femoral heads months that revascularization of totally avascular heads had occurred out of seven cases. Meyers et al (1977) using preoperative scintigraphy in cases of fractures of the femoral neck found at a 2 year follow up that primarily negative scintigrams (with avascularity confirmed by histological examination of core biopsies from the femoral heads) after reduction and pinning of the fractures were converted to positive scintigrams They suggested that this indicated revascularization of the femoral head

Arnoldi & Lemperg (1977) in a series of displaced femoral neck fractures, measured the intraosseous pressure of the femoral head after reduction of the fracture A larger number of cases with pulseless pressure curves showed no evidence of avascularity at the time of follow up which was taken as evidence of revascularization

Klenerman & Marcuson (1970) in a morphological and radiolog cal study of fractures of the femoral neck stated that the fracture pattern is always the same the fracture line passing from the epiphyseal scar on the superior aspect of the neck along the ascending trabeculae to the calcar'

It seems to us that one can ignore the radiological angulation or the position of the fracture line and concentrate only on the fracture displacement Our results show that the amount of fracture displacement determines the prognosis. The results of partly displaced Garden stage 3 fractures are significantly better than the results of fully displaced stage 4 fractures.

Skill and training are required for the exact reduction of a displaced femoral neck fracture. Twenty surgeons at different stages in their training have performed the

Radiological results in 26 poorly reduced fractures (according to Garden) Significance of ad latus *displacement and insufficient bone contact*

		Ad latus displacement and insufficient bone contact	Non un on	Late segmental collapse
actures	20	20	14	6
	6	0	0	0
	26	20	14	6

exact test $P < 0.001$

Table 3 Results of radiological follow-up in the two fracture stages (Garden 1961)

	Stage 3	Stage 4	Total
Non-union	3% (2/63)	28% (14/49)	14% (16/112)
Late segmental collapse	8% (5/63)	14% (7/49)	11% (12/112)
Total failure rate	11% (7/63)	42% (21/49)	25% (28/112)

Chi square test $P < 0.001$

Table 4 Radiological results in relation to fracture reduction

	Reduction according to Garden (1971)		
	Good	Poor	Total
No of fractures	86	26	112
Non-union	2% (2/86)	54% (14/26)	14% (16/112)
Late segmental collapse	7% (6/86)	23% (6/26)	11% (12/112)
Total failure rate	9% (8/86)	77% (20/26)	25% (28/112)

Chi square test $P < 0.001$

as having clinically poor results. Twelve had fractures with non-union and two had late segmental collapse. In order to evaluate which was the most serious complication, non-union or late segmental collapse, as regards the clinical result, all radiological cases of non-union and late segmental collapse were considered Out of 16 fractures with non-union 75 per cent (12/16) needed an arthroplasty, whereas this procedure was only necessary in 16 per cent (2/12) of the cases with late segmental collapse

DISCUSSION

So far no reliable method has been found to predict the fate of femoral neck fractures preoperatively Attempts at a prognostic evaluation by means of arteriography, venography, determination of the pressure in the intramedullary cavity of the femoral head, oxygen tension in the head and various kinds of scintigraphy have been reviewed by Hulth (1965), who states that these methods can predict the fate of the head in 80–90 per cent of cases. The methods mentioned have not attained much clinical significance, but they have contributed to the opinion that of the fractures is determined at the of the accident, everything depending remaining vascularity of the femoral

Other authors, as mentioned below the opinion that transosseous r might keep the femoral head alive. Abrami (1964), on histological the femoral heads from five fra... late segmental collapse found "clear of an initial severe ischaemia of the fragment and with subsequent rev tion across a healed fracture revascularizing process, however had to reach the most proximal and s quadrant of the femoral head years collapse " Catto (1965) found in 12 fe heads, resected for secondary hip arthrop because of late segmental col histological evidence of revascularization seven out of 12 heads revascularization reached the fovea of the femoral head

Riggins et al (1974), in an assessment the circulation in the femoral head of subcapitally osteotomized through femoral neck, with subsequent resta... of the completely detached femoral using threaded pins, showed, by mean 18-F scintigraphy, tetracycline labelling

res It is still an open question whether atter type of malreduction is more tant than an accurate angle after re reduction as it seems to substantially the possibility of transosseous ularization This might in fact be ded from the results of the present Six out of 26 insufficiently reduced res united uneventfully without any of late segmental collapse Compared the other 20 fractures which developed nion or late segmental collapse, these actures were all reduced at a backward of more than 30 degrees, but ogically there was firm contact over the fracture area, a finding which was not ntered in the other 20 cases where *ad* dislocation and gaps in the fracture evident This demonstrates that these nts of malreduction are of great icance This is in agreement with rs et al (1973) who after open reduction placed femoral neck fractures added iliac graft to the posterior gap in the femoral in order to obtain substantial bone ct over the whole fracture area This dure significantly reduced non-union 12 to 3 per cent Substantial bone ct was also advocated by Deyerle (1966), obtained this by extensive impaction of acture

ltiple pinning in the treatment of ral neck fractures was recommended by islen (1935), and Telson & Ransohoff), a few years after the introduction of Smith-Petersen nail (Smith-Petersen et 931) We prefer the multiple pinning od because it seems to minimize the risk jeopardizing possible transosseous scularization Rotation of the femoral is less liable to occur if several nails are instead of a single one Loosening of one in the osteoporotic bone of the femoral will deteriorate fracture fixation This is likely to happen if several nails are used urvey of the literature shows that the lts of multiple pinning are superior to e obtained by a single nail or screw with or without anchorage in the lateral cortex (Table 6)

In our experience application of percutaneous multiple pins in the treatment of femoral neck fractures is to be recommended because it is a minor operative procedure with minimum loss of blood Furthermore the infection rate is less than 1 per cent and the mortality rate compares fairly well with the results of Barnes et al (1976) in his large series, except for the 1 month mortality rate where we obtained significantly better results ($P < 0\ 05$)

At the same time, the method also results in a low frequency of non-union and late segmental collapse compared with other methods During the study period only 16 per cent of the patients with late segmental collapse needed a secondary hip replacement compared with 75 per cent of the patients with non-union Non-union is thus considered the more serious failure in the early postoperative period

CONCLUSIONS

1) The degree of primary fracture displacement is of prognostic value
2) Good fracture reduction leads to a low failure rate
3) The Garden criteria for poor reduction should be supplemented by consideration of other forms of malreduction
4) Severe fracture dislocation should be handled by a skilful and experienced surgeon
5) Non-union is a more disastrous complication than late segmental collapse
6) Percutaneous multiple pinning is a minor operative procedure resulting in stable fractures

REFERENCES

Andersson, G & Moller-Nielsen J (1972) Hip assessment A comparison of nine different methods *J Bone Jt Surg* 54-B, 621–625
Arnold, W D, Lyden J P & Minkoff, J (1974) Treatment of intracapsular fractures of the femoral neck. *J Bone Jt Surg* 56-A, 254–262.

Table 6 Comparison of the results of different methods of osteosynthesis

Author and no. of fractures	Year	Method of pinning	Fracture type	Non-union	Late segmental collapse	Total failure rate (%)
Barnes et al (255)	1976	single nail	Garden 3 & 4	47 %	21 %	68 %
Garden (332)	1971	cross screw	Garden 3 & 4	33 %	21 %	54 %
Smyth et al. (45)	1964	cross-pins and plate	Garden 3 & 4	16 %	40 %	56 %
Barnes et al. (304)	1976	sliding nail-plate	Garden 3 & 4	28 %	19 %	47 %
Brown & Abrams (146)	1964	sliding nail-plate	Garden 3 & 4	23 %	27 %	50 %
Boyd & Salvatore (160)	1964	sliding nail-plate	Pauwels 2 & 3	11 %	33 %	44 %
Fractures total 1242			*Average failure rate*			53 %
Deyerle (35)	1966	multiple pins	all types	0 %	6 %	6 %
Metz et al (63)	1970	multiple pins	all types	5 %	12 %	17 %
Strange (42)	1969	multiple pins	all types	13 %	5 %	18 %
Arnold et al (505)	1974	multiple pins	Garden 3 & 4	15 %	12 %	27 %
Present series (112)		multiple pins	Garden 3 & 4	14 %	11 %	25 %
Fractures total 757			*Average failure rate*			18 %

Chi square test $P < 0.001$

operations in our series. This might be one reason why 24 per cent (39/165) were insufficiently reduced. Acknowledging the necessity of good reduction to obtain good results in displaced fractures of the femoral neck, no inexperienced surgeon should be allowed to undertake the reduction manoeuvre, at least not in severely displaced fractures.

The criteria for reduction used in study was introduced by Garden (197 deals with the magnitude of angulation frontal and lateral view compared with alignment index of 160/180 the limit good reduction being 150/190. However index does not take into account other of malreduction such as latus disloc of malreduction such as latus dislocat insufficient contact between the

op scand 51, 137–144, 1980

ACEMENT WITH THE CHRISTIANSEN)PROSTHESIS IN ACUTE FEMORAL (FRACTURES

ar Follow-up Study

ØREIDE, ANDERS MØLSTER & TOR STEINAR RAUGSTAD

nent of Surgery, University Hospital of Bergen,
ınd Sykehus, Bergen, Norway

lace-
ıp at
the
two examinations have been compared The patients' personal opinion of the results of the operation did not change between the time of the first and second follow-up examinations. However, the objective results showed a deterioration in function (according to Stinchfield's hip assessment scheme) with increasing follow up time This deterioration in rating was mostly caused by reduced walking ability X-ray study of the hips showed an increasing frequency of acetabular protrusion, and settling and loosening of the prosthetic stem No clear correlation between X-ray findings and clinical results could be found We conclude that the serviceability of the prosthetic operation is apparently good despite the objective evidence of progressive deterioration both in the grading of the results and in the X-ray findings.

Key words femoral neck fractures, primary prosthetic replacement, radiography, surgery

Accepted 1 vi 79

results following primary prosthetic ement for acute, displaced femoral neck res have, in our experience been able and in many respects comparable to en better than internal fixation (Søreide 1975, Søreide et al 1979) However, the -up time has been short for all our ıts.

dies of long-term results after rosthetic surgery are few The general on is that the results of replacement of the al head worsen with time Theoretically, oint narrowing or acetabular protrusion, ienced with prosthetic replacement, d be avoided using Christiansen's trunnion bearing hip prosthesis, in which a joint connection is introduced between the prosthetic stem and the headpiece of the prosthesis With this arrangement, and with the femur moving in the sagittal plane, most of the movement should occur in the trunnion bearing with the prosthetic head lying at rest in the acetabulum

We reported, in 1975, the results of a retrospective study of replacement with the Christiansen endoprosthesis in 123 patients with acute femoral neck fractures (Søreide et al 1975) In order to obtain information about time-induced changes, both as regards function and X-ray appearance, we have

5470/80/010137–08$02.50/0



Figure 1 Christiansen's endoprosthesis in a good position seen 9 months after the operation

recently re-evaluated the available patients from the 1975 study and compared the results of the two consecutive examinations.

PATIENTS AND METHODS

A total of 123 patients with an acute femoral neck fracture (16 men and 107 women, mean age 80 5 years) were treated by primary prosthetic replacement from 1971–1973 using the Christiansen trunnion bearing hip prosthesis with a metal cap (same model for all operations, see Figure 1) Of the original 123 patients 70 had died (according to information obtained from the Official Registrar) The remaining 53 patients were asked to come for clinical examination and X ray review during the summer of 1978

Thirty-four patients were seen in our hospital and examined both clinically and roentgenologically Six patients were visited in their homes and a clinical examination performed

Table 1 The patient's personal opini[illegible] operative results

	Follow-up I	F[illegible]
Good	24	[illegible]
Acceptable	10	[illegible]
Poor	6	[illegible]
No information	11	[illegible]
Statistical difference		n.s.

Two patients with deep infection were [illegible] geriatric institutions (see Results). Nine [illegible] were living too far away and ans[illegible] questionnaire The remaining two patien[illegible] not be traced

The mean follow-up time for the 5[illegible] was 67 4 months (range 54–87 mont[illegible] mean follow-up time for the same patien[illegible] 1975 study was 15 2 months (range 2 55[illegible] The results of the two examinations h[illegible] compared, using the Chi-square tes[illegible] otherwise stated

RESULTS

Patient's personal opinion

The patient's personal opinion of th[illegible] of operation was obtained if possi[illegible] compared with the same patient's op[illegible] the time of the first examination. Th[illegible] are given in Table 1 There is no stat[illegible] significant difference between the two

Walking ability at the second examin[illegible]

The status of the 40 personally ex[illegible] patients concerning walking ability [illegible] need for walking aids was recorded [illegible] half of the patients are severely hand[illegible] and more than 50 per cent (22/42) sta[illegible] their reduced walking ability was co[illegible] with the operation (For commen[illegible] Discussion)

Infections

As already stated, two patients wer[illegible] to have chronic deep infection These

2 Objective hip assessment according to ield's classification system at the first and second examinations

	Follow-up I	Follow up II
nt	11	4
	19	18
	5	13
	2	7
cal ice	P – 0 006	

two patients who developed deep on postoperatively and have been ed previously (Søreide et al 1975) patients have lived more than 6 years a Girdlestone hip and persisting ge No other patients with late on were found

ive hip assessment

ective hip assessment was performed the Stinchfield hip assessment scheme hfield 1957) The second examination made on 40 patients, plus the two ts with deep infection who were graded or The previous examination had been med on 37 (including the two patients deep infection) of the 42 patients. The ive results are given in Table 2 The s of the first examination were icantly better ($P = 0\ 006$) than the s in the same patients examined 52 hs later

e mean score for walking ability rding to Stinchfield's hip assessment ne) was reduced from 3 5 points at the first examination to 2 7 points, a reduction of 0 8 points, the score for hip movement was reduced from 4 7 points to 4 2 points, i e 0 5 points, and the pain score was reduced from 5 2 points to 4 7 points, i e 0 5 points. Thus, the poorer results are caused by a general reduction in walking ability, hip movement and pain score, with the most marked reduction being in walking ability

Contractures

In 40 of the patients seen at the second follow-up, flexion contractures of varying degrees were revealed in 14, and 4 patients had combined contractures Of these 40 patients, 35 had been examined earlier At that time, only one patient with a flexion contracture was found Thus, there were significantly more contractures ($P < 0\ 001$) at the later follow-up examination However, compared with the contralateral (non-operated) hips, where contractures were found in 9 patients, the difference is statistically not significant ($P > 0\ 10$)

Range of movement

The range of movement in the 40 recently examined patients was compared with the range of movement recorded earlier in 35 of these patients. The results are given in Table 3 As shown, a significant reduction (*t*-test) in movement was found with increasing follow-up time except for flexion and lateral rotation

The range of movement recorded at the second examination was also compared with the range of movement in the contralateral

le 3 Range of movement in the operated hips at the first and second examinations (mean ± s d)

	Follow up I $n - 35$	Follow up II $n - 40$	Statistical difference
on	96 + 20	91 + 25	n s.
nsion	4 + 5	–4 ± 16	P – 0 003
ıction	32 ± 14	19 + 17	P < 0 001
ıction	33 + 10	25 ± 12	P = 0 002
ıal rotation	21 ± 12	16 ± 13	P – 0 02
ral rotation	23 + 14	23 + 18	n s.

and non-operated hip (excluding 4 patients with bilateral hip surgery) The results are given in Table 4 There was a significantly better range of movement in the non-operated hips than in the endoprosthetic operated hips (*t* test).

X-ray examinations

X-ray examinations were performed in 34 of the recently examined patients and the results were compared with those obtained previously in 30 of these patients.

The statistical analysis which was used in this connection is associated with the follow-up time aspect Thus, we have to test the hypothesis that "no aging" occurs (i e the condition occurs haphazardly) against "aging", using methods from the statistical theory of reliability and life testing based on the Weibull model (Mann et al 1974).

Acetabular protrusion Acetabular protrusion (Figure 2) was found in 8 of the recently examined patients (mean 9 8 mm range 3–20 mm). At the earlier examination, only one showed acetabular protrusion (7 mm). The statistical analysis showed that there was a significantly increased frequency ($P < 0.05$) of acetabular protrusion with increasing follow-up time.

The pain score for the patients with acetabular protrusion was not significantly different ($P > 0.10$) compared with the pain score for patients without protrusion. The range of movement was also the same ($P > 0.10$ *t* test).

Settling of the prosthetic stem. Three p[illegible] in the recently examined group showed [illegible] evidence of settling but there w[illegible] patients with signs of settling at [illegible] amination. This difference is [illegible] significant ($P < 0.01$).

Loosening of the prosthetic stem. [illegible] of the stem (Figure 3) was [illegible] clinically and roentgenologically [illegible] patient at the second [illegible] addition, loosening was suspected [illegible] other patients on the basis of [illegible] studies. None of the [illegible] showed evidence of loosening Th[illegible] is statistically significant ($P < 0.01$).

Results of the questionnaire

The results of the questi[illegible] the patients' personal opinion) [illegible] Table 5

DISCUSSION

The usefulness of primary r[illegible] ment for femoral neck fractures [illegible] two factors an acceptably [illegible] mortality rate postoperatively [illegible] expected serviceability of the [illegible] exceeding a certain period of [illegible] usefulness of this operation with [illegible] postoperative morbidity and [illegible] to be well documented, both [illegible] (Soreide et al 1975, Soreide & [illegible] 1979) and prospectively (Soreide et [illegible]

Table 4 Range of movement in the operated hips at the second examination compared with movement in the contralateral non-operated hips (mean ± s d.)

	Operated hips $n = 40$	Non-operated hips $n = 36$	Statistical difference
Flexion	91 + 25	105 ± 22	P 0.001
Extension	−4 ± 16	1 ± 13	P – 0.01
Abduction	19 ± 17	26 ± 14	P 0.01
Adduction	25 + 12	29 ± 12	P 0.02
Medial rotation	16 ± 13	26 ± 15	P < 0.001
Lateral rotation	23 + 18	31 ± 16	P 0.001



Acetabular protrusion of marked degree months after the prosthetic operation

Figure 3 X ray appearance of a loose prosthesis with a radiolucent zone around the bone cement and distal migration of the prosthetic stem (63 months postoperatively)

Table 5 The results of the questionnaire (patients not examined)

Pain	Severe	0
	Moderate	3
	Slight	3
	No pain	3
Walking ability	Bedridden	1
	Indoors without help	1
	Outdoors without help	3
	Normal for age	4
Operation area	Dry, no pain	9
	Red, painful ± drainage	0

Concerning the serviceability of the prosthetic operation we are not able to draw a final and consistent conclusion Based on the patients' personal opinion it seems reasonable to maintain that the prosthesis has functioned well for the individual patient as this opinion did not change with increasing observation time As shown in the recent examination, half of the patients are severely handicapped, and they stated that their reduced walking ability was connected with the operation However, we are not able to accept this last statement, firstly, because the general opinion about the operation was good, and secondly, because many of them had been admitted to geriatric institutions for reasons other than the prosthetic operation The finding that the frequency of contractures was the same in the operated and non-operated hips also supports this view In this respect, we also find support in the conclusions of Hinchey & Day (1964) who stated that reduced function in their patients was related to a new disabling disease or to slowly developing weakness Classification of the results (after Stinchfield) clearly demonstrated deterioration in function with increasing follow-up time Although the grading of the results decreased it is clear that a major part of the reduction can be explained by age-induced functional changes, i e reduced walking ability However, the range of movement in the prosthetic operated hips was less than in the non-operated contralateral hips, which indicates that the lower grades were also caused by the operation

The X-ray findings demonstrated related changes in the hips. An incr frequency of acetabular protrusion, sinking the prosthetic stem and loosening of the thesis was found. Acetabular protrusion not associated with increased pain, or limitation in hip movement. Our findings supported by Whittaker et al. (1972) Hinchey & Day (1964) who also found the clinical results did not correlate with degree of protrusion in their patients

The number of patients with and/or loosening of the prosthetic stem too few to draw any conclusions with to pain and reduced function. In the lite there is also some conflict in this re Some authors state that settling is symptomless phenomenon (Lindholm et 1976), not the cause of pain and impaired function (Polyzoides 1971), and that se less than 20 mm does not affect mobility the hip (Steen Jensen & Holstein 19 the other hand, Harris (1966) in his se 27 patients with sinking prostheses demonstrated a very high incidence of ability in this group of patients. S Andersson & Moller Nielsen (1972) found poor fixation of the prosthetic stem in femoral shaft was connected with late p view also supported by Whittaker e (1972)

It seems reasonable to conclude the serviceability of the prosthetic operation acceptable despite the objective evidence progressive changes in the acetabulum a the proximal femoral shaft. These changes show no correlation to symptoms. However, these results should viewed with caution because of the l survival of patients treated with primary thetic replacement (Soreide & 1979), a survival exceeding the period observation and follow-up both in this other studies for patients below the age of years.

The Christiansen endoprosthesis primarily constructed to exclude the possib or at least minimize the problem of aceta erosion or protrusion From this study w

:y conclude that even with this prosthesis 'is an increasing frequency of protrusion increasing follow-up time In the 1975 with a mean follow-up of 15 months, equency of protrusion was 2 5 per cent t of 42 patients) At the later examina- (mean follow-up of 67 months) the ncy had increased to 24 per cent (8 out patients) The frequencies of protrusion ted by other authors range from 4 per (mean follow-up time 40 months) to 38 ent (follow-up time of 24–60 months) he Austin-Moore or Thompson pros- (Polyzoides 1971, Whittaker et al Andersson & Moller Nielsen 1972, Steen n & Holstein 1975, Lindholm et al D'Arcy & Devas 1976, Beckenbaugh et 977) Thus, based on our experience of its operated with the Christiansen prosthesis followed for more than 5 we conclude that although theoretically l, the trunnion bearing of the tiansen prosthesis does not seem to e the frequency of acetabular protrusion question which remains to be answered is her there is a correlation between the ency of X-ray changes and time rtant in this connection is the finding of hey & Day (1964), i e that deterioration red primarily during the first 4 years that period the results did not deteriorate er (follow-up time 8 years) This view is supported by Salvati & Wilson (1973)

ur study also shows that the classification he results following prosthetic surgery in patients according to the existing hip ssment schemes does not reflect the al functional status of the patients It is that for this group of patients, assess- of hip function should be performed by bility rating

NOWLEDGEMENT

would like to acknowledge the help given by Skjaerven, Statistician Medical Faculty, ersity of Bergen and Assistant Professor Jostein Lillestøl, Ph D, Norwegian School of Economics and Business Administration

REFERENCES

Andersson, G & Moller Nielsen, J (1972) Results after arthroplasty of the hip with Moore's prosthesis. *Acta orthop scand* **43**, 397–410

Beckenbaugh R D, Tressler, H A & Johnson, E W (1977) Results after hemiarthroplasty of the hip using a cemented femoral prosthesis. A review of 109 cases with an average follow-up of 36 months *Mayo Clin Proc* **52**, 349–353

D'Arcy J & Devas M (1976) Treatment of fractures of the femoral neck by replacement with the Thompson prosthesis. *J Bone Jt Surg* 58 B, 279 286

Harris, W H (1966) Sinking prostheses. *Surg Gynec Obstet* **131**, 1297–1302

Hinchey, J J & Day, P L (1964) Primary prosthetic replacement in fresh femoral neck fractures A review of 294 consecutive cases. *J Bone Jt Surg* 46-A 223–240

Lindholm, R V, Puranen, J & Kinnunen P (1976) The Moore vitallium femoral head prosthesis in fractures of the femoral neck *Acta orthop scand* **47**, 70–78

Mann, N R, Schafer R. E & Singporwalla, N D (1974) *Methods for statistical analysis of reliability of life data* John Wiley & Sons, New York

Polyzoides, A J (1971) Prosthetic replacement [illegible] follow up of Moore arthroplasty in femoral neck fractures. *Acta orthop scand* **46**, 764–774

Stinchfield, F E, Cooperman, B & Shea, C E (1957) Replacement of the femoral head by Judet or Austin Moore prosthesis. *J Bone Jt Surg* 39 A 1043

Søreide O, Lerner A. P & Thunold, J (1975) Primary prosthetic replacement in acute femoral neck fractures. *Injury* **6**, 286–293

Søreide, O Mølster, A & Raugstad T S (1979) Internal fixation versus primary prosthetic replacement in acute femoral neck fractures. A prospective randomized clinical study *Brit J Surg* **66**, 56–60

Søreide, O & Lillestøl J (1979) Survival pattern following primary prosthetic replacement for acute femoral neck fractures in the elderly *Scand J Soc Med* (submitted for publication).

Whittaker, R P., Abeshaus, M. M., Scheel E & Chung S M K. (1972) Fifteen years experience with metallic endoprosthetic replacement of the femoral head for femoral fractures. *J Trauma* 12, 799–806.

Correspondence to Odd Søreide, M D , Department of Surgery, University Hospital of Bergen, Haukeland Sykehus, Norway

rthop scand 51, 145–156, 1980

CHANICAL STRENGTH OF JEWETT AND ˏAUGHLIN HIP NAIL PLATES MANUFACTURED ƆM COBALT-CHROMIUM-MOLYBDENUM ALLOY

omechanical Study of Unstable Trochanteric Fractures. IV

EEN JENSEN

echanics Laboratory, Department of Orthopaedic Surgery T-2,
ofte Hospital, Hellerup, Denmark

Jewett and McLaughlin hip nail plates were mechanically tested, and the mode of failure of both types of implants are described and discussed in this communication Mechanical problems at the nail plate junction in the present design of the McLaughlin implant seem to make it unsuitable for internal fixation of unstable trochanteric fractures, but Jewett nail plates with angles of 125° or 135° can be recommended for this purpose

Key words biomechanics, fracture fixation, femoral neck fractures, stress, mechanical

Accepted 12 vii 79

n clinical series it is known that Jewett nail plate fixation of unstable trochanteric ures is followed by mechanical failures as bending or breakage of the nail or in 5–30 per cent of cases (Cleveland et 1959, Dimon & Hughston 1967, Evans l, Jacobs et al 1976, Laros & Moore l, Moritz & Scheuba 1970, Parker 1955, ey 1956, Sarmiento 1967)

he comparative figures for McLaughlin nail plates have been reported to be 6–46 cent (Bremner & Graham 1958, Clawson 7, Cram 1955, Foster 1958, Friedenberg et 1972, Jensen & Michaelsen 1975, Laros & ore 1974, McLaughlin & Garcia 1955, miento 1963)

has been emphasized that unstable hanteric fractures with no bony support r the calcar femorale make great demands the strength of the implant The hip joint l is transmitted through the implant to the oral shaft (Dimon 1973, Fielding 1973, nkel 1963, Johnston 1973, Jensen 1978b, Jensen et al 1978, Massie 1962, Scheuba 1970, Sonstegard et al 1974)

Brettle (1970) and Martz (1956) pointed out the necessity of examining the mechanical strength of different implant designs. Implants for internal fixation of unstable trochanteric fractures have been the subject of a number of investigations (Foster 1958, Frankel 1963, Holt 1963, Kaufer et al 1974, Martinek et al 1976, Martz 1956, Richter & Peter 1975, Sauer et al 1977, Schottle et al 1977, Sonstegard et al 1974, Sunami et al. 1977) The majority of the papers from Germany, however, reported experiments with AO-angle plates or intramedullary rods

The purpose of the present study was to examine the mode of failure of Jewett and McLaughlin nail plate implants manufactured from Cobalt-Chromium-Molybdenum alloy (Vitallium[®]) by Howmedica Inc., USA and Ireland The principal differences in the engineering design of these two implants is that the Jewett nail plate is cast as a one-piece

1–6470 80/010145–12$02.50/0

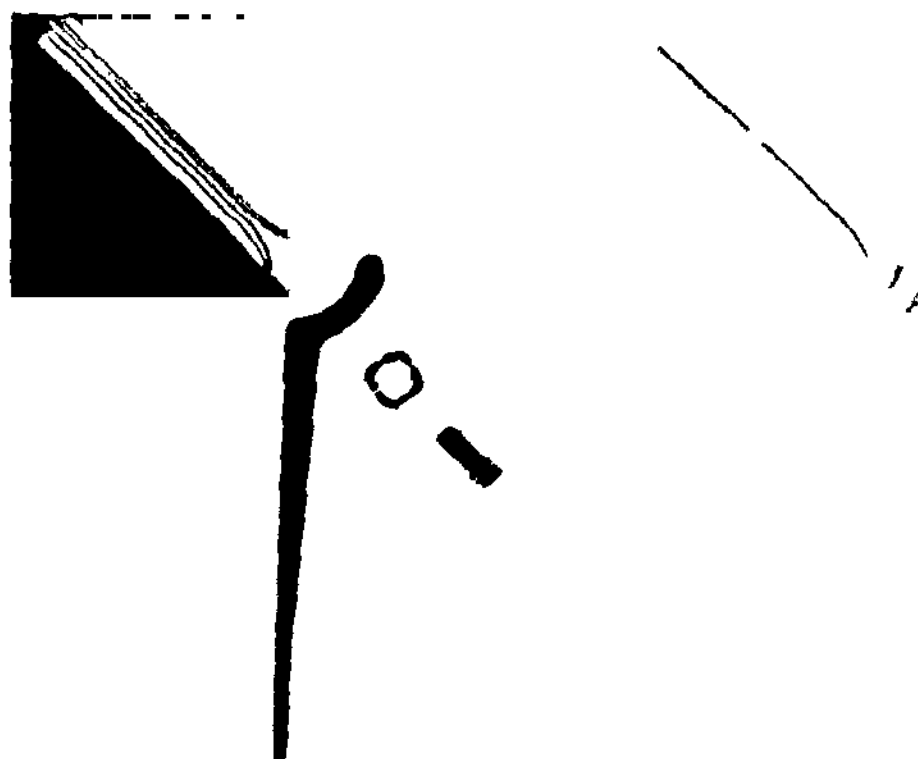


Figure 1 The components of the McLaughlin hip nail plate before and after assembly

implant, whereas the nail and plate of the McLaughlin hip implant is assembled by means of a top bolt with the interpositioning of a washer (Figure 1)

MATERIALS AND METHODS

From recent photoelastic studies (Jensen 1978a b) the ideal experimental position of an implant for testing was calculated to be at an inclination of 11° to the vertical.

The purpose of this study was to test Jewett and McLaughlin hip implants with the nail plate angles listed in Table 1 In order to obtain comparable results the moment arm (M A) about the intersection between the back of the plate and the centre-line of the nail was kept constant According to Figure 2 the nail length (L_N) could thus be calculated to be

$$L_N = \frac{M.A}{\sin\alpha}$$ for the Jewett nail plates

and

$$L_N = \frac{M.A}{\sin\alpha} + r$$ for the McLaughlin nail plates

(α — 169° — nail plate angle r — 13 mm ... nail lengths corresponding to a moment arm ... mm are shown in Table 1

Experiments were performed on ... Chromium Molybdenum (Vitallium[a] How... Inc) implants with trifin nails of the ... lengths and 4- or 5-hole plates (c... numbers 6403-1 6378-0 6633-1 H... Inc). The McLaughlin implants were ... together by means of a cannulated top b... the insertion of a washer between the ... extension of the plate and the top bolt ... McLaughlin experiments the plate was U...

The implants were screwed to a hea... bar and mounted in a base clamp inclined ... the vertical The steel bar did not supp... proximal 25 mm of the plate This arra... was mounted in a universal testing machin... Zwick GmbH & Co W Germany ... electronic force measurement (0-10 kN ... deflection of the implant was measured ... linear displacement transducer (LVDT ... Schaevitz Engineering USA) as shown ... diagram in Figure 3

At the tip of the nail a polished Vitallium ... was mounted ...

Table 1. Applied nail plate angles, moment arms and nail lengths

Implant	Nail plate angle	Moment arm about intersection (mm)	Moment arm about nail-plate junction (mm)	Nail length (mm)
Jewett	125°	41 4	41 4	59 5 (2 34")
	135°	41 4	41 4	74 0 (2 91")
	140°	41 4	41 4	85 3 (3 36")
	150°	41 4	41 4	127 0 (5 00")
McLaughlin	126°	41 4	50 7	74 4 (2 93")
	132°	41 4	49 7	82 6 (3 25")
	138°	41 4	48 4	94 0 (3 70")
	150°	41 4	45 8	140 7 (5 54")

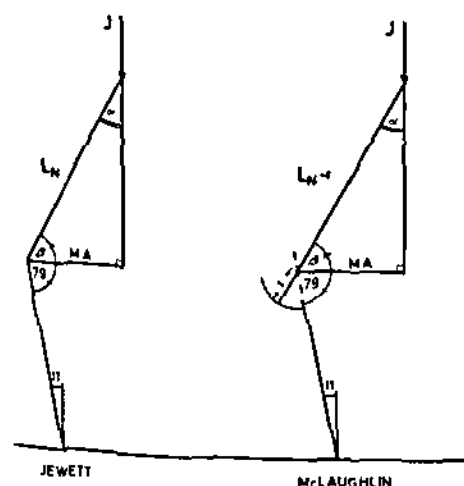
ion of the moment arm, the displacement nail tip was measured with a linear dis- ent transducer (LVDT E 1000, Schaevitz USA)

with the results of photoelastic nents on *two-dimensional models of hip* (Jensen 1978b) the nail was fitted with a gauge 25 mm from the nail plate junction 3, TML, Japan) and an additional strain was placed proximal to that (QFLA–1, Japan) Similarly the plate was fitted with rain gauges (QFLA–3, TML, Japan) 25 mm to the nail plate junction The strain gauges bonded to the metal surface with a

Industries, Peekel Division, Holland) The strain gauges were temperature compensated for steel and the experiments were performed over short time intervals

Any of the measurement signals could be amplified (W–100 and W–101, C Worsøe, Denmark, and KAS Elektroniklab , Denmark) and converted into microvolts by digital voltmeters (Intersil Inc , USA, and KAS Elektroniklab , Denmark)

Load was applied to the tip of the nail by



re 2 Mathematical calculation of nail length
ı = 169° — nail plate angle
= nail plate angle — 79°
= applied force perpendicular to moment arm
= moment arm
= nail length
= radius of curved extension of plate

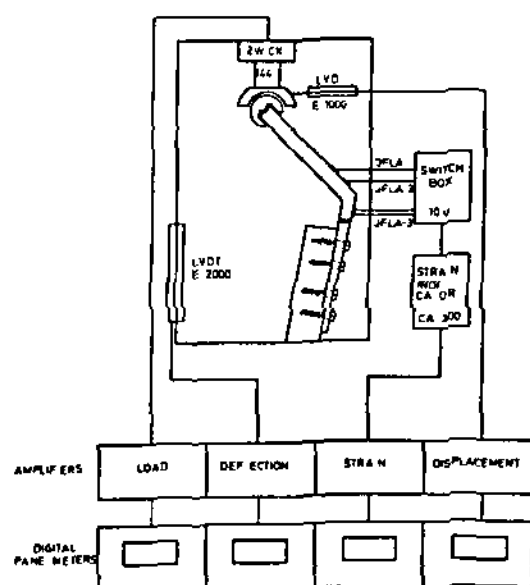


Figure 3 Diagram of the experimental arrangement

advancing the crosshead of the testing machine at a rate of 12 mm per minute Recordings of the measurements were done at static loads for every 0 5 mm deflection of the implant The testing was completed when 15 mm of deflection was obtained

The microvolt recordings were converted into Newtons, millimeters and microstrain (με), respectively, and load-deflection diagrams and load-strain diagrams constructed Five experiments were performed with implants in each of the angles mentioned in Table 1 and the mean curves were calculated for each implant angle

The bending moment about the intersection between the back of the plate and the centre-line of the nail was calculated according to the equation

$$M_B = J \times (M.A. + \Delta M.A.)$$

where M_B = bending moment, J = applied load as measured, M.A. = moment arm = 41 4 mm, Δ M.A. = elongation of the moment arm as measured. The bending moment about the nail plate junction in McLaughlin implants was calculated according to the same equation, with the moment arms listed in Table 1.

From these calculations moment diagrams and moment-strain diagrams were constructed. In all diagrams the yield point, where the metal undergoes a permanent plastic deformation, was defined as the point where the straight line of the graph was transformed into a curved line.

RESULTS

The first diagram to consider is the load-deflection diagram for the complete series of hip nail plate implants as demonstrated in Figure 4 The diagram shows mean curves calculated from recordings of the applied load with simultaneous reading of the deflection at the tip of the nail.

It is seen that the Jewett implants have two yield points, while as many as three yield points are encountered for the McLaughlin

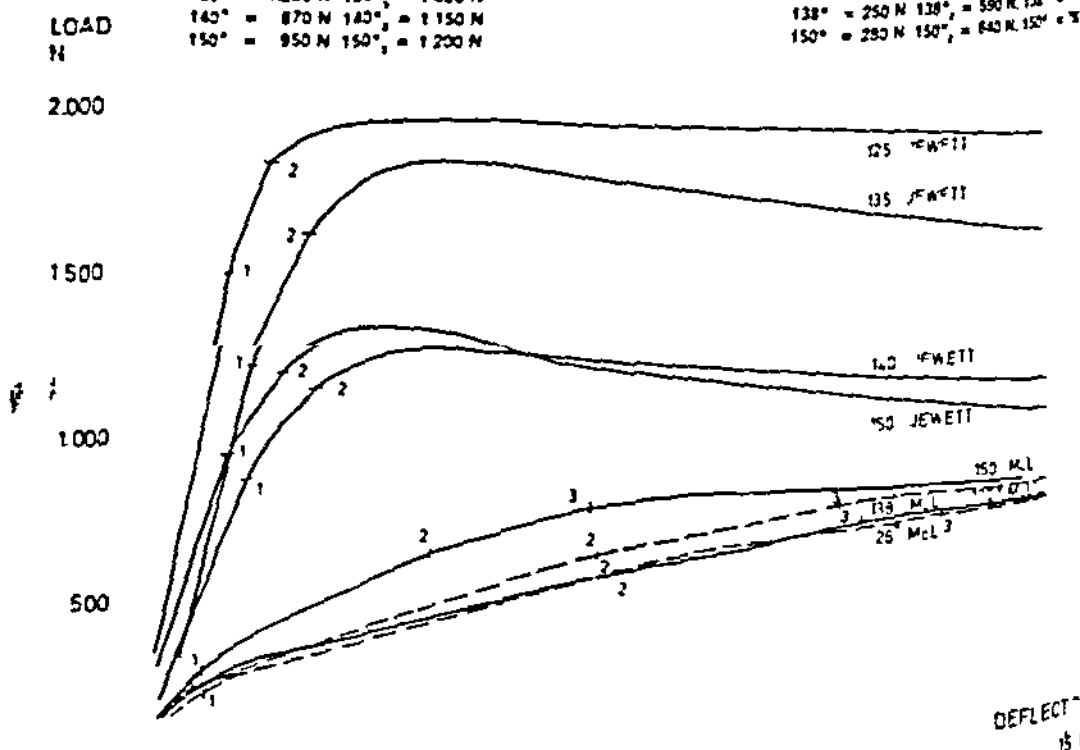
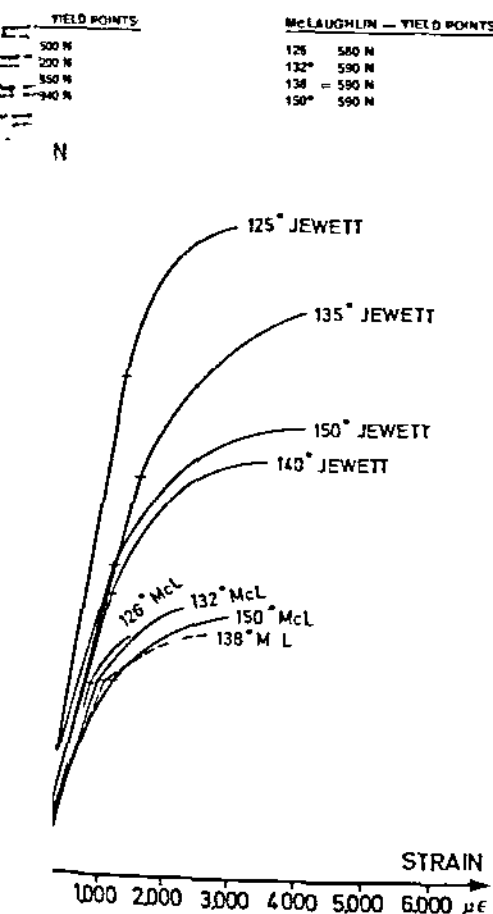


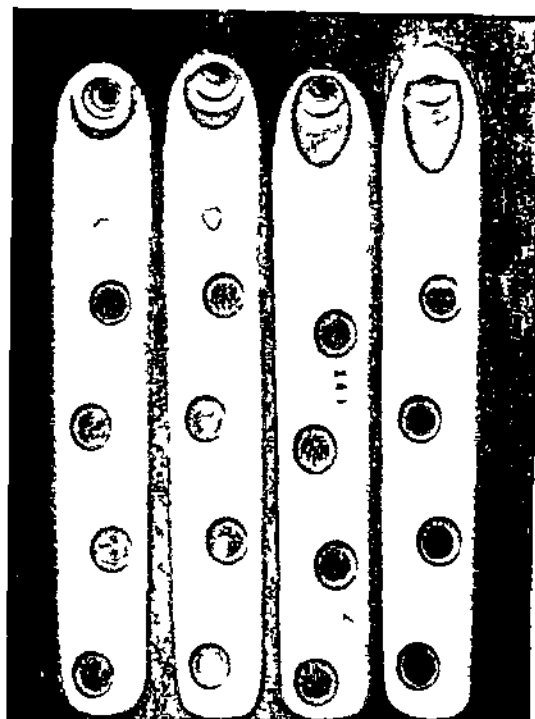
Figure 4 Load deflection diagrams for trifin hip nail plates of the Jewett and McLaughlin type



5 Load strain diagrams for trifin hip

:s. These yield points are caused by parts of the implants undergoing ent plastic deformation at different

ie Jewett series the low yield points onsiderably lower in implants with a te angle of 140° or 150° than in those 5° or 125° nail plate angles, the latter he strongest The load-strain diagram trifin hip nails shown in Figure 5 was ed from recordings of the load with neous readings of the surface strain ed by strain gauges on the nail 25 mm e nail plate junction, as this was in all he gauge giving maximum recordings ing that the maximum deformation lace beneath it) It is seen that the nail in Jewett implants underwent ent plastic deformation at surface



F... 6 ... plastic deformation

strains of 1 250–1 650 µε The yield loads for Jewett implants were taken as values corresponding to the lowest yield points on the load-deflection diagram in Figure 4, and with the same distribution The low yield points on the Jewett graphs were thus caused by bending of the trifin hip nails.

Concerning the high yield point on the Jewett graphs these were also found to be considerably higher when the nail plate angle was 125° or 135° than when it was 140° or 150° The explanation is that the design of the implants involves a rather large counterbore in the upper part of the plate to allow space for the tool used during the operative insertion of the nail into the femoral neck. As seen from Figure 6 this involves a considerable reduction in the cross section of the 140° and 150° implants and the plates bent in the area where the lower edge of the nail joins the plate (Figure 7)

According to Figure 8 the varus dislocation

Table 2 Calculations of the varus angulation in hip implants at mechanical loading

Implant	Nail-plate angle (degrees)	β (deg)	Nail length (L_N, mm)	Deflection (e_1, mm)	β_1 (deg)	Varus angulation $\beta-\beta_1$	Deflection (e_2, mm)	β_2 (deg)	Varus angulation $\beta-\beta_2$	Deflection (e_3, mm)	β_3 (deg)	Varus angulation $\beta-\beta_3$
Jewett	125°	46°	59 5	1 65	43 8°	2.2°	2 25	43 0°	3 0°			
	135°	56°	74 0	1 90	53 5°	2.6°	2.85	52.2°	3 8°			
	140°	61°	85 3	1 85	58 5°	2.5°	2.85	57 3°	3 7°			
	150°	71°	127 0	1 55	69 0°	2.0°	2.35	68 0°	3 0°			
McLaughlin	126°	47°	74 4	1 20	45 7°	1 3°	7 40	39 2°	7 8°	12.60	34 2°	12.8°
	132°	53°	82.6	1 05	51 8°	1 2°	7 10	45 5°	7 6°	10 75	41 9°	11 1°
	138°	59°	94 0	1 25	57 6°	1 5°	7 40	51 1°	7 9°	11 15	47 6°	11 4°
	150°	71°	140 7	1 20	69 6°	1 5°	4 55	66.0°	5 1°	7 00	63 6°	7 4°

junction, which continues until the t... starts bending at varus dislocations of 5° in the 150° McLaughlin implant about 8° for lower angle implants ... means that for the three lower angle implants undergo successive bending r... of less than 650 N, of at least 5 ... loosening at the nail plate junction ... 150° McLaughlin implants the varus ... cation, as well as the macroscopical loos... was less pronounced, which can be expl... by the fact that the nail plate junct... nearly perpendicular to the load d... The total varus dislocation involving ... ing of all three parts of the implant ... calculated to be 11°–13° for the lower ... implants and about 7° for the ... McLaughlin implant and was obtained ... loads of less than 780 N

The bending moment about the nail ... junction could be calculated to be 11... Nm This bares no significant rela... nail plate angles

The bending moment about the ... gauge at the nail 25 mm from the ... junction was calculated according ... above-mentioned equation (2). As can ... from Table 3 the bending moment ... with the nail plate angle, but is ... lower than in the Jewett series. As ... mentioned, strain gauges were also ... the plates of the hip implants 25 m... the nail plate junction Recordings fro... however, did not give any conclusive ... in the case of the McLaughlin impl... they were not placed on the edges ... U-profile, but near the neutral axis ... plate In Jewett implants the stress p... described above were confirmed Further ... struction of bending moment strain d... and bending moment-deflection dia... not add any new information to that ... above

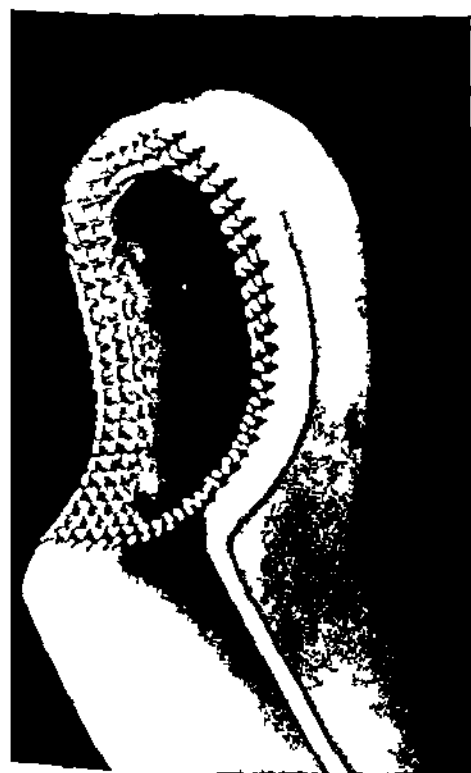
DISCUSSION

In the clinical situation implants ... function under dynamic conditions with ... large and changing load, during walking ...

Table 3 Calculated bending moments about the strain gauge centre on the trifin hip nails

lant	Nail plate angle	Moment arm M A. (mm)	Elongation of moment arm (ΔM A mm)	βx	α_x	Load J (Newton)	Bending moment (M_B)
ett	125°	41 4	0 07	43° 8	46° 2	1 500	35 0 Nm
	135°	41 4	0 80	53° 5	36° 6	1 220	33 3 Nm
	140°	41 4	1 28	58° 5	31° 5	870	25 7 Nm
	150°	41 4	2.40	69° 0	21° 0	950	33 0 Nm
Laughlin	126°	50 7	5 76	39° 2	50° 8	590	21 9 Nm
	132°	49 7	6 04	45° 5	44° 6	630	24 1 Nm
	138°	48 4	10 31	51° 1	38° 9	590	25 4 Nm
	150°	45 8	8 60	66° 0	24° 1	640	28 3 Nm

ling superimposed on a preload caused the muscle traction (Johnston 1973 ter 1966 Paul 1967 1971 Rydell 1966) hip joint load during normal walking was lated by Paul (1967 1971 1976) and ell (1966) to be 3–5 times the body ht corresponding to a hip joint load of at 180–200 kilograms.



re 9 McLaughl n hip nail plate The small ts of the serrations of the curved plate port on flattened at the lower contact point with the The plate extension bends at the same level

The present study of the mechanical strength of hip implants is a static study which does not take into account the muscle traction and the repetitive loading of the hip joint A static study however reveals the mode of failure of the various components of the implants and the corresponding loads and gives information about how the implants act *in vivo* and about the risk of fatigue failure (Dumbleton & Black 1975 Frankel & Burstein 1971 Swanson & Freeman 1977) In a recent paper the author (Jensen 1978b) recommended the steepest possible nail plate angle for the internal fixation of unstable trochanteric fractures These recommendations were based on two-dimensional photoelastic studies of Jewett implants and agree well with theoretical engineering princ ples The present series however revealed that the least angled Jewett



Figure 10 McLaughlin hip nail plate The interposed washer is bent concavely and is thinner compared with an unused washer

nail plates were the strongest The loads causing permanent plastic deformation of the trifin nails never amounted to more than about 75 per cent of the hip joint load in the human body during walking or standing The loads causing failure of the plates were also found to be higher in the low angle Jewett implants and in the 125° and 135° implants the values were fairly close to the hip joint load in slow walking on a level surface (Paul 1976, Rydell 1966) The lower strength of the high angled implants is due to their design with a large counterbore in the upper part of the plate resulting in a reduction in the cross-sectional area, a fact which was not taken into consideration in the photoelastic studies (Jensen 1978b)

Recent biomechanical experiments on Jewett implants (Frankel 1963, Sonstegard et al 1974) have reported loads to failure which correspond with those in this series, whereas Sunami et al (1977) have stated lower values. The mode of failure for the plate in the present series corresponds with that found by Kaufer et al (1974) but a comparison cannot be made with Holt's series (1963) as the design has been altered since Grover, however, as early as 1966 warned against holes and notches in the implants as these might lead to stress concentrations and unexpected failures at relatively small loads.

From the experiments it can be concluded that Jewett implants with angles of 125° or 135° should be chosen for the internal fixation of unstable trochanteric fractures, where the implant is transmitting the entire hip joint load In the clinical aftertreatment and follow up examination very small varus angulations of less than 5° should be looked for, because this indicates that the yield point of the implant has been exceeded As a consequence of this the risk of fatigue failure caused by cyclic loading during walking becomes very high

In the experiments with the McLaughlin implants the loads causing failure were considerably lower than in the Jewett series. This corresponds with the results reported by Holt (1963) and Sunami et al (1977) Richter & Peter (1975) however claimed [considerably] higher failure loads for McLau[ghlin] implants, but performed the experimen[ts on] two-fragmentary trochanteric fractures, [where] the load is mainly transmitted throu[gh] bone

The most important observation fro[m the] McLaughlin series was, however th[at the] nail plate junction only withstands lo[ads of] 225–280 N At this load there is defor[mation] of the small knobs of the curved [plate] extension as well as of the nail base. Th[is is] probably due to the very small contact [area] and is followed by successive bending o[f the] washer and the threads of the top bolt. [Other] papers (Foster 1958 Martz 1956, Sch[...] 1970) have claimed that the junction [between] the nail and the plate is a weak [point]. Furthermore, it has been demonstrated [in] clinical series (Bremner & Graham [...] Clawson 1957, Friedenberg et al 1972, F[...] 1958 Laros & Moore 1974 McLaughl[in &] Garcia 1955) that varus angulation at [this] point appears rather frequently Jense[n &] Michaelsen (1975) thus reported this typ[e of] varus dislocation in 25 per cent of uns[table] trochanteric fractures fixed with [the] McLaughlin implant

A small varus angulation may be of [...] clinical significance but the present s[tudy] also revealed that even a roentgenolog[ically] undetectable varus angulation means p[lastic] deformation of the components of the [nail] plate junction The consequence of fu[rther] loading is progressive deformation and lo[ss of] fixation

For the McLaughlin implants, ho[wever] three yield points were encountered. [The] second component undergoing pl[astic] deformation was the trifin nail at loa[ds of] about 600 N although the geometry of [its] cross section has been considered amon[g the] strongest available (Laing & O'Donnell [...] The final component to deform was [the] curved extension of the plate which ben[t at] loads of about 750 N

In summary the experiments on McLaughlin nail plates demonstrate th[at] varus angulation of about 8° in[...]

ıng of the naıl plate junctıon and ng of the naıl, whıle a varus angulatıon dıng 12° also ıncludes bendıng of the nal part of the plate As the loads d for deformatıon of the McLaughlın nts are less than half of the hıp joınt [illegible] slow walkıng on a level surface I t agree wıth Ghısta & Elangovan), who claımed the desıgn to be ıate on the basıs of theoretıcal ıatıons In the treatment of unstable antenc fractures the ımplant transmıts oad from the hıp joınt to the femoral durıng the healıng perıod of the ıre The present McLaughlın ımplant ıs fore unsuıtable for ınternal fixatıon of fractures, ıf the osteosynthesıs ıs ed by early weıght-bearıng as ıs often nmended (Jensen et al 1978) The re- nıng of the naıl plate junctıon ıs usly a matter of urgency, but the re- nıng of the entıre ımplant should also be ıdered

NOWLEDGEMENTS

tude ıs expressed to Conrad Vogel, Eng and Erık Glube, M Sc Eng, nhagen Engıneerıng College for ınvaluable The study was kındly supported by the sh Medıcal Research Councıl Grant No 6595 and the Medıcal Research Foundatıon Copenhagen, Grant No 75/76,20 The ınts were supplıed by Howmedıca natıonal Inc., Ireland, N C Nıelsen Ltd, nark and Sımonsen & Weel Ltd, Denmark

ERENCES

ner, R A & Graham W D (1958) reatment of pertrochanterıc and basal actures of the femur by ımmedıate fixatıon ıth a two-pıece naıl and plate. *J Bone Jt urg* 40-B, 694–700

lle, J (1970) A survey of the lıterature on etallıc surgıcal ımplants. *Injury* 2, 26–38

rson, D K (1957) Intertrochanterıc fractures f the hıp *Amer J Surg* 93, 580–587

eland, M., Bosworth, D M Thompson F R, Wılson, H J & Ishızuka, T (1959) A ten-year analysıs of ıntertrochanterıc fractures of the femur *J Bone Jt Surg* 41-A, 1399–1408

Cram R H (1955) The unstable ıntertrochanterıc fracture *Surg Gynec Obstet.* 101, 15–19

Dımon, J H (1973) The unstable ıntertrochanterıc fracture *Clın Orthop* 92, 100–107

Dımon, J H & Hughston, J C (1967) Unstable trochanterıc fractures of the hıp *J Bone Jt Surg* 49 A 440–450

Dumbleton J H & Black, J (1975) *An ıntroductıon to orthopaedıc materıals* C. C Thomas, Sprıngfield, Illınoıs.

Evans, E. M (1951) Trochanterıc fractures. A revıew of 110 cases treated by naıl plate fixatıon *J Bone Jt Surg* 33-B, 192–204

Fıeldıng J W (1973) Subtrochanterıc fractures. *Clın Orthop* 92, 86–99

Foster, J C (1958) Trochanterıc fractures of the femur treated by the vıtallıum McLaughlın naıl and plate. *J Bone Jt Surg* 40 B, 684–693

Frankel, V H (1963) Mechanıcal fixatıon of unstable fractures about the proxımal end of the femur *Bull Hosp Joınt Dıs* 24, 75–84

Frankel, V H & Bursteın, A H (1971) *Orthopaedıc bıomechanıcs* Lea & Febıger, Phıladelphıa

Frıedenberg Z B, Gentchos, E & Rutt, C (1972) Fıxatıon ın ıntertrochanterıc fractures of the hıp *Surg Gynec Obstet* 135, 225–228

Ghısta D N & Elangovan, P T (1977) Optımum desıgn synthesıs of a fractured femur fixatıon devıce usıng finıte element analysıs. *Bıomed Techn* 22, 312–316

Grover, H J (1966) Metal fatıgue ın some orthopaedıc ımplants. *J Mater* 1, 413–424

Holt, E P (1963) Hıp fractures ın the trochanterıc regıon Treatment wıth a strong naıl and early weıght bearıng *J Bone Jt Surg* 45-A, 687–705

[illegible] H J & Whitaker J H [illegible] *Trauma* 16, [illegible]

Jensen J Steen (1978a) A photoelastıc study of a model of the proxımal femur *Acta orthop scand* 49, 54–59

Jensen, J Steen (1978b) A photoelastıc study of the hıp naıl plate ın unstable trochanterıc fractures *Acta orthop scand* 49, 60–64

Jensen J Steen & Mıchaelsen, M (1975) Trochanterıc femoral fractures treated wıth McLaughlın osteosynthesıs. *Acta orthop scand* 46, 795–803

Jensen, J Steen, Tøndevold E & Mossıng, N (1978) Unstable trochanterıc fractures treated wıth the slıdıng screw plate system *Acta orthop scand* 49, 392–397

Johnston, R C. (1973) Mechanical considerations of the hip joint *Arch Surg* **107**, 411–417.

Kaufer, H., Matthews, L. S & Sonstegard, D S (1974) Stable fixation of intertrochanteric fractures. *J Bone Jt Surg* **56**-A, 899–907.

Laing, P. G & O'Donnell, J M (1961) The engineering design of hip nails and the development of the H-beam nail *Surg Gynec. Obstet* **112**, 567–576

Laros, G S & Moore, J F. (1974) Complications of fixation in intertrochanteric fractures. *Clin Orthop* **101**, 110–119

Martinek, H, Wielke, B., Eckher, E, Fasol, P, Passl, R, Sauer, G & Spängler, H (1976) Die Belastbarheitsgrenze verschiedener Osteosynthesen pertrochanterer Oberschenkelfarkturen *Arch. orthop Unfall-Chir* **84**, 273–284

Martz, C D (1956) Stress tolerance of bone and metal *J Bone Jt Surg* 38-A, 827–834

Massie, W K. (1962) Extracapsular fractures of the hip treated by impaction using a sliding nail-plate fixation *Clin Orthop* **22**, 180–201

McLaughlin, H L & Garcia, A (1955) An adjustable fixation device for the hip *Amer J Surg* **89**, 867–871

Moritz, E & Scheuba, G (1970) Die Osteosynthese mit dem Winkelnagel für die per- und subtrochantere Oberschenkelfraktur *Acta chir austriaca* **2**, 112–119

Parker, S G (1955) Analysis of one hundred and fifty consecutive intertrochanteric fractures of the femur *J Int Coll Surg* **24**, 202–214

Paul, J P (1967) Forces at the human hip joint (Thesis) University of Strathclyde, Glasgow

Paul, J P (1971) Load actions on the human femur in walking and some resultant stresses *Exp Mechanics* **11**, 121–125

Paul, J P (1976) Force actions transmitted by joints in the human body *Proc roy Soc B* **192**, 163–172.

Robey, L. R. (1956) Intertrochanteric and [illegible] trochanteric fractures of the femur [illegible] negro *J Bone Jt Surg* 38-A, 1301-1312

Richter, J & Peter, K. H. [illegible] Stabilitätsprobleme bei Osteo[illegible] pertrochantere Oberschenkelfrakturen [illegible] *Chir* **100**, 1577–1582.

Rydell, N W (1966) Forces acting on the [illegible] head prosthesis. *Acta orthop scand.*, Suppl [illegible]

Sarmiento, A (1963) Intertrochanteric fract[illegible] the femur. *J Bone Jt Surg* 45 A, 706-[illegible]

Sarmiento, A (1967) Avoidance of complica[illegible] of internal fixation of intertroch[illegible] fractures. *Clin Orthop* **53**, 47–59

Sauer, H D, Schottle, H & Jungbluth, [illegible] (1977) Die dynamische Belastb[illegible] verschiedener Osteosyntheseverfahren [illegible] pertrochanteren Femurfrakturen. *Arch. or[illegible] Unfall Chir* **89**, 275–282.

Scheuba, G (1970) Zur Wahl des Oste[illegible] theseverfahren für pertrochantere F[illegible] *Arch orthop Unfall Chir* **68**, 204–213

Schöttle, H., Sauer, H D & Jun[illegible] K. H (1977) Stabilitatsmessunge[illegible] Osteosynthesen am proximalen Femu[illegible] *orthop Unfall Chir* **89**, 87–100

Songstegard, D A, Kaufer, H & Matthews [illegible] *Amer* **5**, [illegible]

Sunami Y, Nagano, K., Hara, Y, Ima[illegible] Yamamoto, S (1977) A new nail pl[illegible] treatment of fracture of the neck of the [illegible] *Acta Med Okayama* **31**, 383–391

Swanson, S A V & Freeman M. A. R. [illegible] *The scientific basis of joint repla[illegible]* Pitman Medical, Tunbridge Wells.

Correspondence to J Steen Jensen, M D, Dept Orthop Surg T-2, Gentofte Hospital DK [illegible] Hellerup, Denmark

thop scand. 51 157–162, 1980

FERENTIATED CARE OF HIP FRACTURE THE ELDERLY

i Hospital Days and Results of Rehabilitation

CEDER, LARS LINDBERG & ERIK ODBERG

tment of Orthopaedic Surgery, University Hospital of Lund Lund Sweden

Two series of elderly patients with hip fracture were compared with regard to hospitalization time and social situation after discharge from hospital Our series included 131 patients from 1966 with late weight bearing and 362 patients from 1972–1973, mobilized with early weight -bearing Approximately two-thirds of the patients came from their own homes and one-third from institutions. The mean hospital stay for patients discharged to their own homes was 7 weeks in 1966 and 3–4 weeks in 1972–1973 This decrease in hospitalization time did not cause any increase in the proportion of patients

mobility at 2 weeks proved to be a better indicator of the patient's chances of returning home This may be a helpful guide when planning the aftercare of these patients.

Key words aftercare, early mobilization femoral neck fractures, hip fractures, hospitalization, rehabilitation

Accepted 4 ix.79

he industrialized countries of the West, ture of the hip is becoming increasingly mon because of the greater number of rly individuals in the population This d, which will continue over at least the couple of decades, is causing a severe in on medical and social facilities (Schenk l. 1956, Gylling 1960, Alffram 1964, Bauer 9 and 1978, Thomas & Stevens 1974, ish Medical Journal 1976, Gallannaugh et 1976, Ødegård & Unsgard 1978, Steen ken & Tøndevold 1980) The demand for pital beds has been counteracted by rter periods of hospitalization In Lund, example, hospitalization for hip fracture in Department of Orthopaedics dropped n about 20 weeks in 1950 to 4 weeks in 0 (Borgquist 1974)

This study was undertaken to assess whether shorter hospitalization following fracture of the hip had caused a correspondingly greater utilization of secondary rehabilitation facilities. The comparison was made between two groups of patients from the same population, admitted for fresh fracture of the hip in 1966 and in 1972–1973, respectively

PATIENTS AND METHODS

The clinical series included all residents of the primary catchment area of Lund, over the age of 50 who had sustained a hip fracture and were admitted to the Department of Orthopaedic Surgery, Lund This area had a total population of 148 692 inhabitants in 1966 and of 181,387 inhabitants in 1973 The number of patients was 131 in 1966 and 362 in 1972–1973 Patients from

1-6470.80/010157-06$02.50/0

Table 1 Patients with hip fractures grouped according to age, sex type and year of fracture

Age	1966				1972 1973			
	Cervical		Trochanteric		Cervical		Trochanteric	
	M	F	M	F	M	F	M	F
50 – 64	2	6	2	1	7	15	6	[illegible]
65 – 79	4	38	1	24	19	57	27	[illegible]
> 80	5	23	7	18	17	67	15	[illegible]
Total	11	67	10	43	43	139	49	[illegible]

the psychiatric hospital in Lund were excluded from these series.

The mean age of the patients was 77 and 79 years in the 1966 and 1972–1973 series, respectively, women outnumbered men by three to one and there was a slight preponderance of cervical fractures in women (Table 1).

Socio-medical grouping In both series about two-thirds of the patients lived at home at the time of fracture and one-third were in institutions.

Estimation of mobility Mobility indoors was graded in the 1973 series of patients as follows patients confined to bed or to a wheelchair, or requiring support by another individual, scored 0 points, walking frame 2 points rollator, 3 points quatraped, 4 points, walking stick, 5 points and requiring no support 6 points (Ceder et al 1979) Mobility before fracture was assessed by information from the patients, relatives or from nursing home personnel Mobility after fracture was assessed at 2 weeks and 3 months, postoperatively, by a specially appointed physiotherapist

Fracture treatment and postoperative mobilization There was a marked difference in treatment philosophy between the 1966 and the 1972-1973 series the latter series were subjected to surgery aimed at early mobilization and the patients were barred from weight bearing postoperatively only if the mechanical fixation of the fracture was regarded as insufficient

In the 1966 series cervical fractures were usually fixed with a Thornton nail these patients had 8 weeks of bed rest followed by mobilization over a period of 4 weeks without weight bearing The majority of patients over 70 years of age with displaced cervical fractures had a primary Moore hemi arthroplasty, weight bearing was then gradually started 2–3 weeks postoperatively Impacted cervical fractures were usually not operated upon these patients had an [illegible] of 6 weeks of bed rest followed by weight [illegible] Trochanteric fractures were fixed with a [illegible] plate according to McLaughlin the patients [illegible] allowed weight bearing 6 weeks postoperatively

In the 1972–1973 series cervical fractures [illegible] fixed with a spring loaded nail according to [illegible] (1964) and hemi arthroplasty was used sparingly for example because of a path[illegible] fracture failure of reduction etc The major[illegible] the trochanteric fractures were fixed with [illegible] and plate according to McLaughlin [illegible] the fractures were fixed with Ender nails [illegible] cervical and trochanteric fracture patients [illegible] encouraged to bear full weight the day af[illegible] operation the only exceptions being cases [illegible] the mechanical fixation of the fracture [illegible] deemed insufficient

Hospitalization time decreased from 44 [illegible] 1966 to 27 days in 1972–1973 This decrease [illegible] mainly due to early discharge of patients [illegible] own homes this group had 50 days of ho[illegible] tion in 1966 and 24 days in 1972–1973 (Ta[illegible]

RESULTS

The mortality rate during hospital tre[illegible] was 9 per cent both in the 1966 [illegible] 1972–1973 series Of the surviving pa[illegible] admitted from their own homes, 48 pe[illegible] returned directly home in 1966 and [illegible] cent in 1972–1973 (Table 2)

The mobility score both before fractu[illegible] at follow up was better for patients fro[illegible] own homes than for patients from inst[illegible] (Table 3) Of the patients who scored 4 [illegible]

… 2 Mean hospital days and discharge from …al of patients with hip fracture admitted … their own homes in 1966 and 1972–1973

…arged …om …pital …o	1966		1972–1973	
	Patients (n)	Days (mean)	Patients (n)	Days (mean)
…home	45	50	141	24
…uli- …er …al	24	39	48	34
…'s	8	52	19	33
…ng	16	47	20	55
	93	47	228	30
…ased	9	25	19	16

…ore before the fracture 107 out of 108 were …itted from their own homes and 36 out of …were from institutions At 3 months …operatively this score had been regained by …f the 107 from their own homes and by only …f the 36 from institutions. The difference … highly significant ($P < 0.001$, Chi-square …).

…he mobility score 2 weeks postoperatively …ed an early and valid indicator of the …-term prognosis for patients admitted … their own homes (Table 4) All but one … a pre-fracture score of 4 points or more … 71 patients who had returned home at 3 months follow-up had a 2-week score of … to 4 points The six patients who were …harged to nursing homes had 0 points. … 31 patients who were discharged to less …odial types of nursing care or rehabilitation … a 2-week score of about 2 points.

DISCUSSION

The mean hospital stay for hip fractures was around 3–4 weeks during the 1970's in several countries in western Europe (Gallannaugh 1976, Dolk & Westerborn 1977, Karumo 1977, Ødegård & Unsgård 1978, Steen Jensen et al 1979, 1980) However, assessments of mean hospital days are unreliable because they are often merely an expression of the different possibilities available for aftercare (Dolk & Westerborn 1977)

The present investigation showed that the proportion of patients discharged to their own homes after hip fracture definitely did not decrease but rather increased in spite of a dramatically shortened hospital stay Early mobilization and discharge of a patient with a hip fracture thus does not mean that the burden of care for these patients has been passed on to other institutions

Comparing the rate of discharge to the patient's own home with the findings of other authors in countries with different health and social systems is both difficult and perplexing Camblin (1974) and Smith & McLauchlan (1975) in Great Britain discharged between one-half to two-thirds of patients to their own homes but the mean hospital stay was up to 2 months Ring (1963) and Poigenfürst & Schnabl (1977) discharged half of their patients to their own homes following early

Table 3 Mean mobility score before fracture, and after osteosynthesis and mobilization, for surviving patients with hip fracture admitted in 1973 from their own homes or from institutions

Admitted from	Mean mobility score		
	Before fracture	2 weeks postop	3 months postop
Own home ($n = 108$)	5.7 ± 0.1	3 ± 0.2	4.2 ± 0.2
Institution ($n = 48$)	4.2 ± 0.4	0.9 ± 0.2	1.8 ± 0.4

Values – Mean ± Standard error of the mean

Table 4 Mean mobility score before fracture, and after osteosynthesis and mobilization, for surviving patients with hip fracture admitted in 1973 from their own homes and discharged to their own homes or to institutions

Discharged from hospital to	Mean mobility score		
	Before fracture	2 weeks postop	3 months postop
Own home ($n = 71$)	5.8 ± 0.1	3.7 ± 0.2	4.8 ± 0.1
Rehabilitation or other hospital unit ($n = 24$)	5.8 ± 0.1	1.8 ± 0.4	3.7 ± 0.4
Old people's home ($n = 7$)	5.7 ± 0.3	2.3 ± 0.8	3.1 ± 0.8
Nursing home ($n = 6$)	4.8 ± 1.0	0	0.3 ± 0.3

Values = Mean ± Standard error of the mean

postoperative weight-bearing Ødegård & Unsgård (1978) reported the same rate of discharge to own home On the other hand, Stewart (1955) did not allow weight-bearing for 3 months postoperatively and still had a discharge rate of 80 per cent after 6 weeks hospitalization, clearly Stewart's patients must have received more help at home than is readily available under today's social conditions Steen Jensen et al (1979, 1980) had a discharge rate to own home of only 30 per cent after hospitalization for 3 weeks, because a large proportion of the patients had a period of institutionalized rehabilitation, before they returned home

The distinction between patients coming from their own homes and those coming from institutions is clearly fundamental for any meaningful comparison of hospitalization following hip fracture Thus, the decrease in postoperative hospitalization noted here in patients admitted from institutions ha[d] or nothing to do with a change in r[...] towards early mobilization the hospitalization of this group of patien[ts] mainly due to the general acceptance [o]f rule that an institutionalized patient sh[ould] not lose her bed on admission to h[ospital] because of a fractured hip

The application of an active rehabil[itation] programme for hip fracture patients r[equires] that it be defined as early as possible. Th[is is] a problem only in patients who lived a[t home] at the time of fracture, institution[alized] patients can hardly ever be rehabilitat[ed to] non institutionalized living For the pu[rpose] of making a good guess at a re[alistic] rehabilitation goal, we have found the 2 [week] mobility score more useful than the as[sess]ment of the patient's prefracture status [By] recording the mobility score early rather [than] late, time is gained for improvement o[f the] social environment to which the patien[ts] eventually return, patients returning need increased domestic help (Ceder e[t al] 1979) In fact, studies in progress (Ce[der et] al) suggest that in Sweden, at present, [a] realistic goal to discharge about 75 pe[r cent] of patients with a fractured hip direc[tly to] their own homes, another 10 per cent c[an be] rehabilitated to home status after temp[orary] institutionalization

A higher incidence of institution[al] rehabilitation is probably unnecessary [and] may even be harmful, Steen Jensen e[t al] (1979, 1980) reported a discharge ra[te to] the patient's own home of only 30 pe[r cent] because the majority of the patients [were] rehabilitated in an institution demonstrated that these latter patien[ts did] not attain better function than those [who] were rehabilitated at home

The main obstacles to rehabilitation [of the] elderly after hip fracture are often m[edical] and/or social in nature—and less pertain to the mechanical aspect of rec[overy] However, early detection of mech[anical] failure of the fixation device is one o[f the] positive results of early mobilization [and] weight-bearing, i e , poor mechanical fi[xation]

discovered and corrected by means of ary arthroplasty or other measures, ortening the rehabilitation time

onclusion, this study has shown that hospitalization following hip fracture ot cause correspondingly greater use of lary institutional facilities Early zation of a patient with a hip fracture oes not mean that the burden of these ts has been passed on to other in- ons. The mobility score 2 weeks after y seems to give a better indication of ssibilities for early return home than ore before the fracture This makes it for the hospital staff to assess the need ercare

OWLEDGEMENTS

study was financially supported by the h Medical Research Council (Project 7X-02031-13A), the Swedish Planning ationalization Institute of the Health and Services (SPRI, Malmohus lans landsting iftelsen för bistånd åt vanföra, Helsingborg thors wish to thank Miss Anna Håkansson cretarial help and Karl-Goran Thorngren, for statistical analysis.

RENCES

n P-A. (1964) An epidemiologic study of vical and trochanteric fractures of the femur an urban population *Acta orthop scand*, ppl 65

, G C H (1969) Epidemiology of fractures l arthrosis. *Aging of connective and skeletal tue*, pp 319–331 Thule International mposia Nordiska Bokhandelns Forlag, ckholm

, G (1978) ...

... ...ivården. En studie av hoftfrakturer hos iringar (Organization levels in public health service A study of fractures of the proximal end of the femur in elderly people) Thesis, Lund

British Medical Journal (1976) Fractures near the hip *Brit med J* 1, 1237

Camblin, J G (1974) Five year retrospective study of femoral neck fractures. *Ulster med J* 43, 136–142

Ceder, L, Ekelund, L, Inerot, S, Lindberg, L, Odberg, E & Sjolin, C (1979) Rehabilitation after hip fracture in the elderly *Acta orthop scand* 50, 681–688

Ceder, L, Thorngren, K-G & Walldén, B Prognostic indicators and early home rehabilitation in elderly hip fracture patients ...

(1976) Regional survey of femur neck fractures. *Brit med J* 2, 1496–1497

Gylling, B (1960) Collumfrakturen som socialmedicinskt problem (Fracture of the femoral neck as a sociomedical problem) *Opusc med (Stockh)* 5, 178–183

Jensen, J, Steen & Tøndevold, E (1980) A prognostic evaluation of the hospital resources required for the treatment of hip fractures. *Acta orthop scand* (In press)

Jensen, J, Steen, Tøndevold, E & Sørensen, P Hove (1979) Social rehabilitation following hip fractures. *Acta orthop scand* 50, 777–786

Jensen, J, Steen, Tøndevold, E & Sørensen, P Hove (1980) Costs of treatment of hip fractures. A calculation of the consumption of the resources of hospitals and rehabilitation institutions. *Acta orthop scand*. (In press)

Karumo, I (1977) Recovery and rehabilitation of elderly subjects with femoral neck fractures. *Ann Chir Gynaec Fenn* 66, 170–176

Ødegård, O & Unsgård, G (1978) Sosialmedisinske aspekter pa pasienter med lårhalsbrudd *Nord Med* 93, 16–18

Poigenfürst, J & Schnabl, P (1977) Multiple intramedullary nailing of pertrochanteric fractures with elastic nails operative procedure and results. *Injury* 9, 102–113

Ring, P A (1963) Treatment of trochanteric fractures of femur *Brit med J* 1, 654–656

Rydell, N (1964) Osteosynthesis of medial collum fractures with the "spring-loaded nail" *Acta orthop scand* 35, 149–157

Schenk, W G., Jr, Smith, R. G & Stephens, J G ...

Sr ... of fractures of the proximal femur *Injury* 6, 196–201

Stewart, I. M. (1955) Fractures of neck of femur. Incidence and implications. *Brit. med. J.* 1, 698–701.

Thomas, T. G. & Stevens, R. S. (19[illegible]) ... effects of fractures of the neck of the ... *Brit. med. J.* 3, 456–45[illegible].

Correspondence to: Leif Ceder, M. D., Department of Orthopaedic Surgery, University Hospital, S-[illegible] 85 Lund, Sweden.

~{ ~p. scand. 51, 163–170, 1980

_TALITY AND LIFE EXPECTANCY AFTER FRACTURES

DAHL

nent of Surgery, Haugesund Hospital, Norway

Follow-up data for at least 4 years was collected for 675 patients treated for hip fractures in the period 1961–1970 Compared with a series from the same hospital for the years 1948–1957 the number of patients had more than doubled and a higher hospital mortality was encountered, but the 4-year survival rate was unchanged. The mortality after hip fracture was found to be related to the age and sex of the patient and to the nature and number of associated diseases. The mortality rate was found to be high in the first 2 months following the fracture, but patients surviving the second month showed no excess mortality during the following 4 years, having the same life expectancy as the general population.

Key words femoral neck fractures, hip fractures, long-term survival, mortality

Accepted 3 v 79

rous reports have been published con-g mortality after hip fractures, but ely few papers have dealt with the erm survival

ikelsen & Langholm (1964) studied lity, over a 4-year period, after hip res in 277 patients treated at esund Hospital between 1948 and 1957 e number of patients with hip fractures icreased in recent years, we have studied mparative series of patients from the hospital for the period 1961–1970, aring the mortality rate with that in the al population.

IENTS AND METHODS

gesund Hospital is located in the south-ern part of Norway and served, until 1970 a munity of approximately 100,000 people, two ls of whom were living in a rural area.

During the period 1961–1970, 667 patients with 680 fresh hip fractures (viz. fractures of the trochanteric region and the femoral neck) were treated at Haugesund Hospital. Follow-up data until death or for a minimum of 4 years was collected from registrars' offices and the Central Bureau of Statistics, Norway Five patients (0 7 per cent) were lost to follow-up. Thirteen patients sustained two hip fractures during the period, and these counted twice in the series. The total number of patients followed up thus amounted to 675 Five hundred fractures (74 per cent) were encountered in women. Femoral neck fractures occurred in 70 per cent of the cases (476/675) and trochanteric fractures in 30 per cent (199/675) (Table 1). Twenty-seven per cent of the femoral neck fractures (128/476) were impacted or showed no displacement.

Age The arithmetic mean age of all female patients was 71 5 years, of all male patients 74 7 years, and of both sexes 73 9 years (17–99 years). Figure 1 shows the age distribution. In patients below the age of 50 years, males dominated (54 per cent), but in the older age groups the predominance of females was marked (75 per cent).

~64"0 80 010163–08$02.50 0

Table 1 Number of hip fracture patients admitted to Haugesund Hospital in the years 1961 19[illegible] followed up for at least 4 years, divided according to sex and fracture type

Patients	Number of fractures		
	Femoral neck	Trochanteric	Total
Female	366	134	500
Male	110	65	175
Total	476	199	6 5

Fracture type Trochanteric fractures were overall more common in men (37 per cent) than in women (27 per cent) ($P < 0.001$). The number of trochanteric fractures decreased with age in males, but increased with age in females. In patients above the age of 70 years the percentage of trochanteric fractures was 30 for both sexes.

Treatment Dislocated fractures were treated non-operatively with traction for an average of 4 5 days. Femoral neck fractures were treated by internal fixation with a Smith-Petersen-Johansson nail. In 3 per cent of the patients (12/476), however, a primary arthroplasty was performed, and 26 per cent of the patients (142/476) were treated by non-operative means. In trochanteric fractures internal fixation was performed [illegible] McLaughlin plate in 71 per cent of the (142/199) while 29 per cent (57/199) were [illegible] non-operatively Early postoperative [illegible] was favoured and anticoagulant prophyla[illegible] seldom used Prophylactic antibiotics were administered

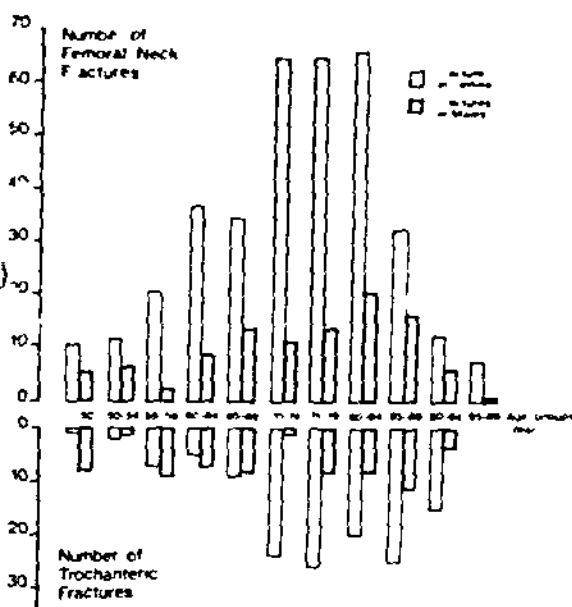


Figure 1 Distribution of 500 women and 175 men with hip fractures as regards age and fracture type

Associated diseases Based on the nature of associated diseases discovered during the operative evaluation, the patients were retrospectively into three groups accordin[illegible] Fitts et al. (1959) *Group I* included patients [illegible] *mild or no* associated pathological process [illegible] *II* included patients with *moderately* associated disease and *group III* included with *severe* associated disease, e.g. myocardial infarction renal failure compensated congestive heart failure metastatic cancer We recorded the number [illegible] patients in each of these groups, and the number of pathological conditions (groups II III) found in each patient

For the *statistical analysis* the Fisher[illegible] non-parametrical test was applied in all 2 [illegible] tables and the chi square test in 2 x n [illegible] tables Using the procedure of Schor (Fitts et al. [illegible]) life tables were calculated for the popul[illegible] according to information given by the Ce[illegible] Bureau of Statistics (1972) for the 1961–1970 for a series with comparable [illegible] sex distribution Life tables based on the mortality of the patients with hip fractures also calculated and the proportion of p[illegible] surviving various time periods was plotted fo[illegible] two groups. The difference between the "observed in the patients and that "expected" the general population gives a direct meas[illegible] the contribution of the specific condition und[illegible] vestigation to mortality The point at which two curves become parallel is the point at [illegible] the patients die at the same rate as the population (Gordon 1971).

'LTS

ospital mortality was calculated to be per cent (94/675) The average alization time was 34 6 days (1–203 Most deaths were caused by iopneumonia (29/94), cardiac failure) and cerebral vascular accidents) In 7 per cent of the patients (7/94) pulmonary embolism was suspected lly *There was no significant difference* death rate between male patients with nteric fractures and male patients with l neck fractures or between female ts with trochanteric fractures and patients with femoral neck fractures, ionth, 2 months, 6 months and 4 years injury The two fracture types were ore considered together in the following ical analysis

mortality within 1 month was 17 1 per (30/175) in men and 9 8 per cent)0) in women ($P < 0\ 01$) This mortality elated to age, ranging from 2 per cent in 'n (2/96) and men (1/50) less than 65 years to 21 per cent in women (20/94) and 38 nt in men (15/39) more than 84 years of similar age-related mortality was found second month after injury, i e no deaths in patients less than 65 years, but 10 per cent of the women and 17 per cent of the men over 84 years died during the second month Of patients 75 years old or more 78 per cent of the men (70/90) and 61 per cent of the women (164/271) died during the first 4 years after fracture The higher male mortality within the first month appeared to be the main factor causing the lower long-term survival in men

The mortality during the first month was *about 15 times and during the second month* about 7 times the expected mortality of a sample from the Norwegian population of the same size and similar age and sex distribution (Table 2) Thereafter the death rates corresponded to those of the general population (Figure 2) Thus the excess mortality was essentially attributable to the deaths during the first 2 months after fracture

Table 3 shows the number of severe and moderately severe diseases in the patients The probability of dying within the first 6 months after hip fracture increased proportionally with the number of associated diseases described on admission (Figure 3) (The group with four or more additional diagnoses consisted of 16 patients and was too small for reliable statistical calculations) Similarly, there was a significantly higher

2 Life tables for the years 1966–1970 (Norway's Official Statistics/Central Bureau of Statistics of Norway 1972)

)	Expectation of life (Average number of years of life remaining)		Mortality (per 1000)	
	Males	Females	Males	Females
	71 09	76 83	15 65	12.03
	25 32	29 47	6 02	3 17
	21 17	24 97	9 82	4 78
	17 33	20 64	15 80	7 93
	13 86	16 55	26 65	13 82
	10 87	12.83	42.31	24 55
	8 30	9 60	64 33	44 76
	6 14	6 97	99 88	77 51
	4 46	4 98	151 88	132 97
	3 16	3 59	228 92	200 73
	2 21	2 58	320 00	287 96
	1 49	1 87	450 00	360 64

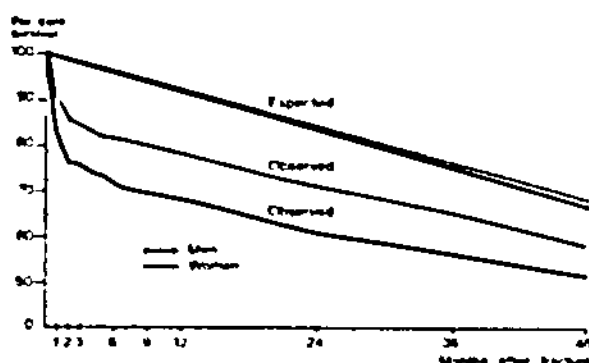


Figure 2 Observed survival rates in men and women with hip fractures compared with expected survival rates of Norwegian people of corresponding age and sex

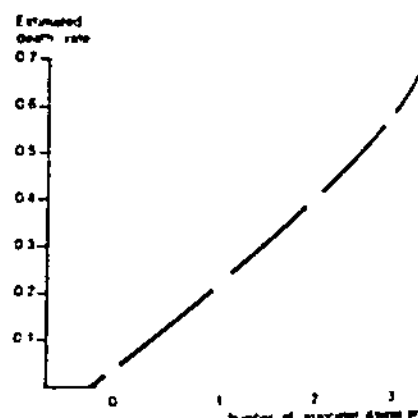


Figure 3 Estimated death rate of patients first 6 months after hip fracture as a f[unction of] associated diseases

proportion of *severe* associated diseases in patients dying during the first 6 months than in patients surviving at least 6 months ($P < 0.001$) (Table 4).

The data from the present series was compared with the series of Mikkelsen & Longholm (1964) from 1948–1957 The ratios men/women and trochanteric femoral neck fractures were the ... The proportion of male as ... female patients over 75 years of age ... significantly higher in 1961–1970 than 1948–1957 ($P < 0.001$). The ... mortality in 1961–1970 was 139 per

Table 3 Mortality and survival in patients with hip fractures in relation to number of associated dise[ases in] each patient

Number of patients	Number of associated diseases per patient 0	1	2	3	≧4	Total
Patients dying within 6 months	8	43	45	37	9	142
Patients surviving 6 months or more	289	148	67	22	7	533
Total	297	191	112	59	16	675

Table 4 Mortality and survival in patients with hip fractures in relation to severity of a[ssociated] diseases

Number of patients	Severe associated disease	Moderately severe or no associated disease	Total
Patients dying within 6 months	24	118	142
Patients surviving 6 months or more	13	520	533
Total	37	638	675

5), significantly higher than the 4 per 3/277) in 1948–1957 ($P < 0.001$), r, the mean length of hospital stay t stated by Mikkelsen & Langholm 'ear survival of male as well as female over 75 years was similar in the two

SSION

970 Haugesund Hospital was the only or the treatment of hip fractures in a ined geographical area with a stable on and was thus suitable for ological investigations.

mparing the present material with Mikkelsen & Langholm (1964) from 957, we found two marked differences mber of cases had more than doubled re was a higher hospital mortality in erial.

increase in the number of fractures is it to be explained only by the increase mean age of the population Alffram found the annual number of fracture icreased by a factor of three over 13 Malmö, whereas the total population :d by less than 20 per cent Falch & (1978) reported a similar increase in incidence in Oslo, which they related ncrease in the incidence of metabolic sease

hospital mortality in Haugesund d in 1948–1957 was low, so low that a decrease was not likely, but we did ect the marked increase in the period 970 The hospital mortality, however, ly dependent on the length of hospital Hence, comparison of statistics from it hospitals, or from different periods same hospital must be made with some tion (Alffram 1964, Gordon 1971, et al. 1956), and especially com- with studies where the hospitalization not reported (e g Beals 1972, Clark & right 1966, Lindholm et al 1971, & Shelby 1964, Mikkelsen & olm 1964, Sweet et al. 1967, Weeden et 7, Wong 1969).

To avoid the variables of *hospital* mortality, some authors define a "primary mortality", i e the death rate during a period in which the hip fracture together with associated diseases must be regarded as the decisive mortality factor (Fitts et al 1959, Riska 1970) Riska (1970) felt that the limit for this "primary mortality" was 30 days after injury or operation, and Barnes et al (1976) used mortality at 1 month in their prospective, multicentre study

Mortality at 1 month may be practical in comparing different series, but the 30-day limit seems arbitrarily chosen and does not reflect the "primary mortality" as defined above by Riska (1970) With the use of life tables Fitts et al (1959), Hansen & Neidhardt (1970), Niemann & Mankin (1968) and Colbert & O'Muircheartaigh (1976) showed the excess mortality after hip fractures to be essentially attributable to deaths *in the first 6 months* Miller (1978) found the excess mortality to be most apparent *in the first 4 months* following injury, but that it persisted for at least 8 months Gordon (1971) noted that the period of greatest mortality was within *the first 12 weeks*, and Alffram (1964) in a more detailed study pointed out that patients surviving the *first 3 months* had the same life expectancy as the general population Evans (1979) found, in addition to an early period of high risk of death, a secondary rise occurring after 4 to 6 weeks

In analysing the death rates during the first year in our material, we found the death rate during the first month to be approximately 15 times and during the second month about 7 times the expected death rate of a matched sample of the general population Patients surviving the 2 first months showed no significant excess mortality during the following 4 years, indicating the same survival rate as the general population. The death rate at 2 months might therefore give a more correct "primary mortality", as defined above, than mortality at 1 month

Reno & Burlington (1958) stated that no single factor influences the prognosis in any given case as markedly as the patient's age

As in other series (Alffram 1964, Beals 1972, Colbert & O'Muircheartaigh 1976, Gordon 1971, Katz et al 1967, Miller 1978) we found a close correlation between mortality and age, and our age-related death rates at 1 month were similar to those of Riska (1970) and Barnes et al (1976) Mikkelsen & Langholm (1964) demonstrated excess mortality in hip fracture patients even in the age group 60–64 years and like them we found excess mortality particularly in patients over 75 years of age In the present material there was a marked shift towards older patients. The proportion of patients over 75 years was significantly higher than in 1948–1957, a fact that also to some degree might influence the higher hospital mortality in our series.

In this study there was a significantly higher death rate in men than women during the first 2 months after fracture A higher male mortality has been demonstrated in several surveys (Barnes et al 1976, Beals 1972, Colbert & O'Muicheartaigh 1976, Gordon 1971, Mikkelsen & Langholm 1964, Miller 1978), while sex differences were not present (Alffram 1964, Evans 1979) or not stressed (Fitts et al 1959, Katz et al 1967, Lindholm et al 1971) by other authors.

There is a strong relationship between mortality after hip fractures and associated diseases in the patients (Alffram 1964, Fitts et al 1959, Miller 1978, Schenk et al 1956), in our series shown to be partly dependent on the nature of the disease and partly dependent on the number of significant diseases in each patient

A higher mortality has been reported in patients with trochanteric fractures (Beals 1972, Colbert & O'Muircheartaigh 1976, Fitts et al 1959) Weeden et al (1957) noted the trochanteric cases to carry a higher death rate because the patients were older, and after correction for differences in the age distribution of the patients Alffram (1964) found the mortality to be unrelated to the main type of fracture This was in accordance with our findings and others have also been unable to confirm any influence of the type of fracture on survival (Gordon 1971, Manpel et al 1961, Meyn et al 1977, Mikkelsen & ' 1964, Sweet et al 1967).

A comparison of death rates patients grouped according to treatment was not attempted in th agreement with some authors (Cambl Lindholm et al 1971, Riska 1970 Swe 1967), but not with others (Alffra Schenk et al 1956, Shaftan et al 19 noted a markedly higher death rate du first months in patients treated operatively compared with operated p However, after analysing age, associated diseases in these two gr became apparent that the' operated patients reflected the selec patients rather than the particular pro Other factors concerning treatment m interfere with primary mortality but m the selection be drawn in a retrospective (Gordon 1971, Miller 1978)

The factors influencing mortality f out in this survey should be considered choosing the method of treatment fo patient individually It is recognised th operative methods permitting mobilization and weight bearing used in geriatric patients (Attenboroug Devas 1974) Several reports on cedures preserving the femoral hea allowing unrestricted rehabilitation ha made (Abrami & Stevens 1964 A 1971, Garden 1961, Graham 1968 1969, Nieminen 1975) Mikkelsen & La (1964) stated that in patients older th years prosthetic replacement of the f head in fresh femoral neck fractures mig suitable substitute for nailing as the st operation because the majority would n long enough to experience any of the known complications Other authors sup still lower age limit for arthroplasty (C 1974, Hansen & Neidhardt 1970 Muckle Ramstad 1966, Simons & Limbosch 1969

Our study indicates that patients sur the first 2 months have approximate same life expectancy as the general tion which in 1970 was 11 years fo

l man and 13 years for a woman of ie age When choosing the treatment re, the general condition of the may be a better criterion than the age (Fitts et al 1959, Lindholm et), and if a prosthetic replacement is ed in a patient with a relatively long ectancy, careful selection of type and of prosthesis is essential (Dahl & en 1976)

)WLEDGEMENT

istical analysis was done by Tor Bu

ENCES

G & Stevens, J (1964) Early weight ig after internal fixation of transcervical re of the femur *J Bone Jt Surg* **46**–B, 205

h, T H Jr (1971) Immediate full weight-ig in the treatment of hip fractures *J na* **11**, 1031–1039

P–A. (1964) An epidemiologic study of al and trochanteric fractures of the femur urban population *Acta orthop scand*, 65

ough C G (1977) Fractures near the n *Geriatric orthopaedics* Ed Devas M emic Press, London

R Brown, J T, Garden R S & Nicoll, (1976) Subcapital fractures of the femur *ne Jt Surg* **58**–B, 2–24

R K. (1972) Survival following hip ire *J chron Dis* **25**, 235–244

J G (1974) Five year retrospective of femoral neck fractures. *Ulster med J* 36–142.

N G & Wainwright, D (1966) Manage-of the fractured neck of femur in the ly female *Geront clin (Basel)* **8**, 326

D S & O Muircheartaigh I (1976) ality after hip fracture and assessment of contributory factors *Irish J med sci* **145**, 0

& Mikkelsen O A (1976) Wear of the thylene head of the Oscobal prosthesis. *orthop scand* **47**, 643–647

M B (1974) Geriatric orthopaedics. *Brit J* **1**, 190–192

Evans, J G (1979) Fractured proximal femur in Newcastle upon Tyne *Age Ageing* **8**, 16–24

Falch, J & Ilebekk, A (1978) Brudd i øvre femurende *T norske Laegeforen* **98**, 738–739

Fitts W T Jr, Lehr, H B, Schor, S & Roberts B (1959) Life expectancy after fracture of the hip *Surg Gynec. Obstet* **108**, 7–12

Garden, R S (1961) Low angle fixation in fractures of the femoral neck *J Bone Jt Surg* **43**–B, 647–663

Gordon, P C (1971) The probability of death following a fracture of the hip *Canad med Ass J* **105**, 47–51 & 62.

Graham, J (1968) Early or delayed weight bearing after internal fixation of transcervical fracture of the femur *J Bone Jt Surg* **50**–B, 562–569

Haggquist S–O (1969) Results of early weight bearing in cases of operated subcapital femoral neck fractures *Acta orthop scand* **40**, 684–685

Hansen N & Neidhardt, F O (1970) Letaliteten ved fractura colli femoris *Ugeskr Laeg* **37**, 1709–1714

Katz S, Heiple, K G, Downs T D, Ford, A B & Scott, C P (1967) Long term course of 147 patients with fracture of the hip *Surg Gynec Obstet* **124**, 1219–1230

Lindholm, T S, Puronvarsi, U & Lindholm, R V (1971) Fractures of the proximal end of the femur with fatal outcome in geriatric patients *Acta chir scand* **137**, 778–781

Lorhan, P H & Shelby E A (1964) Factors influencing mortality in hip fractures. *Anesth Analg Curr Res* **43**, 539–543

Manpel J, Marzulli V & Boley S J (1961) The fractured hip a complication of aging *Arch Surg* **82**, 474–477

Meyn, M A Jr, Hopson C & Jayasankar, S (1977) Fractures of the hip in the institutionalized psychotic patient *Clin Orthop* **122**, 128–134

Mikkelsen, O A & Langholm, O (1964) Life expectancy after hip fractures in the aged *Acta chir scand* **127**, 46–56

Miller, C W (1978) Survival and ambulation following hip fracture *J Bone Jt Surg* **60**–A 930–933

Muckle, D S (1977) Prosthetic replacement of the femoral head. In *Femoral neck fractures and hip joint injuries* Ed Muckle, D S, Chapman and Hall London

Niemann K M W & Mankin H J (1968) Fractures about the hip in an institutionalized patient population *J Bone Jt Surg* **50**–A, 1327–1340

Nieminen S (1975) Early weightbearing after classical internal fixation of medial fractures of the femoral neck. *Acta orthop scand* **46**, 782–794

Ramstad, K. R. (1966) Fractura pertrochanterica et fractura colli femoris. *T. norske Laegeforen* 86, 1619–1623

Reno, J. H. & Burlington, H. (1958) Fractures of the hip–Mortality survey. *Amer J Surg* 95, 581–592.

Riska, E. B. (1970) Factors influencing the primary mortality in the treatment of hip fractures. *Injury* 2, 107–115

Schenk, W. G. Jr, Smith R. G. & Stephens, J. G. (1956) The fractured hip–a major surgical and sociologic problem. *Amer J Surg* 91, 618–620

Shaftan, G. W., Herbsman, H. & Pavlides, C. (1967) Selective conservatism in hip fractures. *Surgery* 61, 524–527

Simons, M. & Lunbosch, J. M. (1969) [illegible] dans les fractures du col femoral. *Acta [illegible] belg* 35, 849–857

Sweet, M. B. E., Zwi, S., Mendelow [illegible] M. N. & Graham W. D. (1967) Fract[illegible] of femur. Associated morbidity and [illegible] *S Afr J Surg* 5, 57–64

Weeden, R., Rosenthal, H. & Miller [illegible] Mortality statistics on fractured [illegible] (1935–1955). *J Bone Jt Surg* 39 [illegible]

Wong P. C. N. (1969) Mortality in frac[illegible] the femoral neck following [illegible] *Singapore Med J* 10, 191 193.

Correspondence to Eilif Dahl, M. D., Sentralsjukehuset i Rogaland, Avdeling Stavanger Sjukehus, [illegible] 4000 Stavanger, Norway

hop scand. 51, 171–174, 1980

:RIOR DISPLACEMENT OF THE ιL TUBEROSITY IN THE TREATMENT OF NDROMALACIA PATELLAE

SUDMANN & BERNDT SALKOWITSCH

ient of Orthopaedic Surgery, University of Tromsø, Tromsø, Norway

Anterior displacement of the tibial tuberosity combined with shaving of the diseased cartilage was used as treatment for chondromalacia patellae in 32 knees in 28 consecutive patients and in one patient with chondromalacia femoris. The patients were aged 17 to 57 years. One patient had earlier sustained a serious injury to the ligaments of the knee, resulting in instability. All patients except one were unfit for work before the operation. Postoperative extra-articular wound infection was noted in two knees and venous thrombosis occurred in three legs. The postoperative observation period varied from 8 months to 2 years and 10 months. In one knee the anterior displacement of the tibial tuberosity was not maintained. In lateral radiographs the anterior displacement of the tibial tuberosity in the other knees varied from 10 to 23 mm. The relief from pain obtained by the operative treatment was estimated as good in all knees except three, which were unchanged. All patients became fit for work and/or sport.

Key words: cartilage, articular, chondromalacia patellae, knee joint, patella

Accepted 1 vii 79

lromalacia patellae usually affects young y individuals, reducing their capacity :avy work because of pain on exertion ion markedly increases the mechanical ; acting on the articular surfaces in the ofemoral joint, and the patients' toms seem to be related to the anical strain on the diseased articular age (Maquet 1976).

cent studies indicate that anterior dis- ment of the tuberosity of the tibia – ding distal anchorage of the patellar on – considerably reduces the mechanical on the patellofemoral joint and so ves pain in chondromalacia patellae quet 1963, 1976, Bandi 1972). In this y we present our findings after using this od to treat 29 consecutive patients with umed chondromalacia patellae.

PATIENTS AND METHODS

Patients. This prospective investigation comprised 29 inpatients (33 knees) admitted from March 1976 to March 1978. There were 12 women and 17 men aged 17 to 57 years (median 30 years), 2 women and 2 men (5 knees) were below 20 years of age. No two had the same occupation. On admission all the patients were unfit for work except one, and he was unable to take part in the national skiing competitions because of bilateral chondromalacia patellae. Previous sporting activities, traumas and knee operations are listed in Table 1.

Symptoms, signs and selection of patients. The duration of the symptoms varied from 6 months to 4 years (median 3 years). The patients' main complaint was pain on exertion located ventrally

-6470 80/010171-04$02.50/0

Table 1 Preoperative data in 29 patients (33 knees)

	No of patients (p) or knees (k)
Participated in sport	11 p
Patellar trauma	17 p
Knee ligament injuries	1 k*
Previous knee operations	
— meniscectomy	6 k
— shaving of patellar cartilage	1 k
— other	1 k

* Unstable knee

Muscle wasting in the thigh was noted in 18 knees and intra-articular fluid in 15 knees. The affected patella was always tender when its deep surface was rubbed against the underlying femoral condyles and patellar grating was felt when the knees were actively extended. Six patients were bilaterally affected, but only four of the six were advised to have a bilateral operation.

Only patients unfit for work and/or competitive sports were given operative treatment and included in this study. No systematic preoperative treatment was given before admission to this hospital.

X-rays Ordinary anteroposterior and lateral radiographs were taken of both knees in all patients. Tangential views of the patellofemoral joint were also taken. In lateral preoperative radiographs the patellar height ratio was calculated by dividing the distance from the lower end of the articular surface of the patella perpendicular to the tangent of the tibial plateau by the length of the articular surface of the patella (Blackburne & Peel 1977). There were no significant pathological findings.

Operative procedure The knee joint was usually opened by the different surgeons through a lateral parapatellar incision in a bloodless field. When a medial meniscal lesion was suspected a medial incision was used. The macroscopic pathological changes in the cartilage were graded according to severity as outlined by Bandi (1972). All diseased cartilage was shaved off the patella and any affected part of the femoral condyles. Deranged menisci and loose bodies were removed. The joint cavity was then closed, the skin incision was enlarged distally and the tibial tuberosity was displaced towards the front (Bandi 1972). The displaced tuberosity was kept in place by a triangular bone block taken from the anterior iliac crest. The block was fastened by a




Figure 1 Lateral radiograph of right kn... arterior displacement of the tibial ... maintained by a triangular bone block ... screw

4 cm long slender AO screw (Figure 1). Fi... compression bandage was applied from the ... above the knee.

Postoperative regimen and follow-up Af... operation the patients were kept in bed fo... with the operated knee semiflexed and eleva... splint. Exercises using the quadriceps musc... encouraged before and after the operatio... patients were allowed partial weight-beari... out of bed on crutches. Full weight bearing ... allowed until x rays showed that the ... displaced tibial tuberosity had healed (... months after the operation). The screw w... removed. In the 13 patients most recently o... on the compression bandage was removed... afternoon of the day of operation the leg wa... on a pillow and the patient was allowed to ... freely, to reduce the risk of postoperat... thrombosis. No prophylactic antibiot... anticoagulants were given.

Only patients with a postoperative obs... period of at least 8 months were included... study, the maximum observation period ... months (median 22 months).

: 2 Peroperative findings in 33 knees

s	No of knees	
omalacia		
a only	22	
only	1	
a and femur	9	
a, femur and tibia	1	
		33
d menisci	3	
odies	2	
d synovitis	4	
instability	1	

Severity of chondromalacia in 33 knees

	No of knees
te I	12
II	8
III	10
IV (degeneration)	3

ding to Bandi (1977)

ILTS

eration, the diagnosis chondromalacia
te was verified in all knees but one, in
the lesion of the articular cartilage was
ed to the femoral part of the
ofemoral joint Since the signs,
oms and results of treatment in this
ular patient did not differ from the
, he has been included in the material
eroperative findings are listed in Tables

one patient the bone graft was gradually
ed into the metaphysis of the tibia
g to faulty operative technique and the
led anterior displacement of the tibial
osity was therefore not maintained, but
patient became symptom-free In the
knees the anterior displacement of the
tuberosity in lateral radiographs varied
10 to 23 mm (median 15 mm) (Figure
t follow-up no joint effusion was noted
ny of the operated knees All were
ed from pain on exertion and at rest
except three, which were unchanged All patients became fit for work and/or sport, but three patients changed their jobs.

Postoperative complications Postoperative extra-articular wound infection by staphylococci was noted in two knees. The infection subsided after surgical intervention and treatment with parenteral antibiotics. Three patients contracted a deep venous leg thrombosis verified by phlebography Treatment by intravenous streptokinase combined with warfarin sodium was complicated in one of these patients by bleeding from the donor site on the iliac crest, which necessitated surgical intervention Delayed but uneventful recovery then followed.

DISCUSSION

Several methods of operative treatment for chondromalacia patellae have been used, from simple ones such as shaving of the articular cartilage of the patella to radical surgery such as patellectomy (Outerbridge & Dunlop 1975)

Wiles et al (1956) performed patellectomy in 15 (33 per cent) and patellar shaving in 31 (67 per cent) knees operated on for chondromalacia patellae Patellectomy later became necessary in an additional six of these cases (Wiles et al. 1960) Thus, patellectomy was done in 21 (46 per cent) out of the total of 46 knees. Patellar shaving gave good long
[illegible]

of 140 knees operated on for chondromalacia patellae. Satisfactory results were obtained in 77 and 25 per cent of these cases, respectively Therefore, according to Bentley (1978), shaving of the patella remains an unsatisfactory procedure This is especially the case in patients under the age of 20 years (Wiles et al. 1960, Bentley 1978)

Although neither Wiles et al (1956) nor

Bentley (1978) described their methods of patient selection for either operative method, simple techniques *like* patellar shaving obviously do not always give relief from pain In contrast, when shaving of diseased cartilage was combined with anterior displacement of the tibial tuberosity as above, we were able to obtain pain relief in 30 out of 33 knees operated on, regardless of the patients' age, sex, or occupation, and regardless of the patellar height and the extent of the pathological changes of the articular cartilage in the knee If one patient with a post traumatic unstable knee and incipient arthrosis in the tibiofemoral as well as in the patellofemoral joints is excluded we obtained satisfactory results in 30 (94 per cent) out of 32 knees. Since shaving of the patella alone appears to give good results in 25 (Bentley 1978) to 71 per cent (Wiles et al 1960) of *selected* cases, ventral displacement of the tibial tuberosity would seem to be an essential addition to the treatment

The frequency of postoperative complications observed here – 6 (18 per cent) in 33 operations – seems high, but no permanent sequelae were observed We believe that the complications reported above can be avoided by improved surgical techniques and that the risk of postoperative leg thrombosis can be lessened by avoiding a compression bandage on the knee and by early mobilization of the patient

The short term results have been encouraging and anterior displacement of the tibial tuberosity seems to be a promising ope- method for treatment of chondro- patellae The complications encoun- however, suggest that the patients sho- carefully selected and only patients of work and/or competitive sport shou- advised to have such an operation.

REFERENCES

Bandi W (1972) Chondromalacia patella femoro-patellare Arthrose Ätiologie, Kl- Therapie *Helv chir Acta* Suppl. 11

Bentley G (1978) The surgical treatm- chondromalacia patellae *J Bone Jt* 60 B 74–81

Blackburne J S & Peel T E (197-) method of measuring patellar height. *J Jt Surg* 59 B 241–242.

Outerbridge R E & Dunlop J A. Y (19 problem of chondromalacia patellae (*Orthop* 110, 177–196

Maquet P (1963) Considérations biomécan- sur l arthrose du genou Un tr- biomécanique de l arthrose fémoro-pat- l avancement du tendon rotulien. *Rev R* 30, 779–783

Maquet P (1976) Advancement of the tuberosity *Clin. Orthop* 115, 225 230

Wiles, P Andrews, P S & Devas, M. B. (Chondromalacia of the patella *J B- Surg* 38 B 95–113

Wiles P Andrews, P S & Bremner R A (Chondromalacia of the patella A study of later results of excision of the ar- cartilage *J Bone Jt Surg* 42 B 65 70.

1
Correspondence to Einar Sudmann M D, Hagavik Orthopaedic Hospital, University of B
N 5220 Hagavik Norway

Acta orthop scand. 51, 175–179, 1980

?OVASCULAR OSTEOCUTANEOUS GROIN FLAP HE TREATMENT OF AN UNUNITED TIBIAL ?TURE WITH CHRONIC OSTEITIS

Report

AR FOGDESTAM, RICHARD HAMILTON & GÖRAN MARKHEDE

ent of Plastic Surgery and the Department of Orthopaedic , University of Gothenburg, Gothenburg, Sweden

A 37-year-old man with an ununited tibial fracture combined with a significant skin defect underwent a microvascular transfer of an island osteocutaneous flap of groin skin and iliac crest bone The bone component of the flap was shown to be a living transplant by the observation of brisk cancellous bone bleeding when the flap was isolated on its vascular stalk

Key words fracture microvascular transfer, non-union, osteitis, osteocutaneous groin flap, tibia

Accepted 7 x 79

reatment of established non-union of d tibial fractures is a complex problem ntly requiring several surgical intions, including debridement of soft and necrotic bone, irrigation, drainage repeated bone grafting Extensive ig after previous surgical attempts, d necrotic bone and draining fistulas the skin coverage troublesome The region becomes progressively less larized Antibiotic therapy is of dubious and the bed for bone grafting unle

: introduction of microsurgery and free larized osteocutaneous flaps offers a on to the problem of both the skin and defects, and at the same time relishes the circulation in the tissues to fracture healing

Few cases have been reported where this technique has been used in the treatment of ununited infected fractures of the lower leg The purpose of this case report is to present this method which is comparatively new and so far has not been employed elsewhere in Scandinavia

CASE HISTORY

A 35-year-old man with a history of alcohol abuse sustained a closed oblique fracture of the distal tibial shaft in February 1976 Open reduction was carried out on the third day and the fracture was anatomically reduced with two circumferential wires. The postoperative period was uneventful and healing progressed clinically to such an extent that weight-bearing without plaster was allowed after 4 months. The patient was then lost to follow-up

?470 80/010175–05$02 50/0

He returned in August 1977 with refracture following a fall whilst intoxicated. (It was then clear that radiological union of the primary injury had never taken place) The refracture was technically compound because the overlying skin was damaged over an area of 3 × 4 cm A second operation was performed using a sliding bone graft and cancellous bone chips from the right iliac crest The damaged skin was excised and skin closure facilitated by means of two relaxation incisions on either side of the wound A deep infection supervened postoperatively and despite repeated surgical procedures, the bone did not heal and the infection did not resolve By November 1978, two and a half years after the original injury, the patient had established non-union extensive osteitis and a skin defect 3 × 4 cm in size (Figures 1a b). Standard methods



(a) (b)

Figure 1 Preoperative condition with (a) draining fistula, skin defect, extensive scarring and (b) established non union

having failed this case was judged to be suitable for a microvascular free osteocutaneous groin flap so as to provide the necessary vascularized bone graft and skin cover and at the same time introduce a new blood supply into the poorly nourished scarred region

OPERATIVE METHOD

Smoking was forbidden for 1 week and 3 weeks postoperatively Clinical and Doppler ultrasonic probing showed anterior and posterior tibial arteries and Allen's test demonstrated that t… system could adequately nourish the foot

The operation was performed by operating simultaneously one team … flap and the other team dissecting the region In the recipient site the … of 5 × 10 cm was excised *en bloc* … siderable sclerotic bone from the … creating a substantial bone defect. T… vessels were the anterior tibial arter… venae comitantes. Projectile arteria… confirmed the ability of this … flap after transfer

In the donor region an oval … 7 × 22 cm was prepared as an … the superficial circumflex iliac and … inferior epigastric branches of the … (which in this case arose from a … and drained by two superficial circumfle… veins, which had united into a common sa… saphenous vein The flap was … with a 2 × 7 cm piece of iliac crest … 1 cm extension of iliac periosteum, by car… servation of soft tissue connections betw… skin and iliac crest (Figure 3b). When … tion was completed and the composite … as an island based on its vascular stalk, a… areas of soft tissue as well as cancellous bo… bleeding briskly thus confirming the adeq… flap vascularity

The island flap was separated from the … vessels in the groin and transferred … recipient region. The iliac bone block wa… slotted into a groove prepared in the tibia… anteriorly (Figures 2b 3c), further packed… cancellous bone chips, and the flap per… wrapped around No bone fixation was nec… The skin edges were sutured (Figure 3… vascular anastomoses performed end to end… 10–0 monofilament nylon under the ope… microscope The venous anastomosis wa… first between the flap vein and the most … vena comitans Both veins measured 2 … external diameter and 13 stitches were used… arterial anastomosis was performed next be… the anterior tibial artery measuring 3 … diameter and the 1 4 mm flap artery by m… 12 stitches. Upon release of the arterial … immediate flap revascularization occurred… ischaemia time was 3½ hours. Total ope… time was 8½ hours.

A plaster slab was applied to the leg no…



Immediate postoperative result (a) Skin ...itured in place and (b) the iliac bone block ... into a groove in the tibia

...was required and exposure of the flap was ...y in order to observe circulation ...roin wound was closed by direct suture ...uum drainage

...W-UP

...toperative vascular complications were ...iced The skin margins healed ...y except for a 1 cm long wound ...ion on the medial side, which healed ...veral weeks Immediate postoperative ... showed a good position of the ...red bone (Figure 2b) A light cast was ... on the 10th day and the patient dis... at 10 weeks, non-weight-bearing ...utches

...15 weeks the fracture showed ...gical and clinical union and the patient ...mitted full weight-bearing without aid ...4a, b and c)

...scanning using Technetium 99 ...ene Diphosphonate showed no active circulation in the graft on the first postoperative day but from the first week postoperatively active uptake of the isotope was demonstrated

The donor site healed rapidly and gave no problems There was anaesthesia in the lateral thigh, corresponding to the distribution of the lateral cutaneous nerve, but this is gradually normalizing

DISCUSSION

The case reported illustrates the use of a microvascular osteocutaneous flap as an advanced technique for solving the complex problem of a combined bone and skin defect in the lower limb (in this case established non-union of the tibia with an overlying skin deficiency) Repeated bone grafting had failed and amputation was seriously considered

The method described, whilst comparatively new, has been reported by others (Taylor & Watson 1978, Morrison et al 1978, Weiland & Daniel 1979) The principle involves the transfer of free living iliac crest bone together with a composite of groin skin nourished by the superficial circumflex iliac artery This artery which primarily supplies skin, ramifies also to iliac periosteum through branches preserved in the areolar tissue between skin and iliac crest and via the musculature attached to the surfaces of the iliac bone The bone therefore remains as a "living" transplant, not only because of its periosteal circulation but also through tiny nutrient branches which pass from the periosteum through to the medulla Such bone nutrition was demonstrated in this case by the brisk bleeding from the cancellous bone seen when the flap was isolated as an island Similar observations have been reported by Taylor & Watson (1978) Furthermore, India ink injection studies in human cadavers by the same authors and barium sulphate injection studies (Fogdestam 1977, unpublished work), confirm the ability of the superficial circumflex artery to supply iliac crest bone

The series does not include patients under 15 years of age Also excluded were patients with epiphyseal separations, direct fractures and isolated ligamentous injuries, i e all supination-eversion injuries of stage 1 and some of the stage 1 supination-adduction, pronation-abduction and pronation-eversion injuries.

The following nomenclature is used S = supination or supination adduction fractures, SE = supination-eversion or supination-outward rotation fractures, PE = pronation-eversion or pronation-outward rotation fractures, P = pronation or pronation-abduction fractures and PD = pronation-dorsiflexion fractures. The figures following the type designation indicate the stage division

Osteosynthesis and suture of ligaments were performed in 210 of the ankle fractures. During the period of the survey, the treatment principle was on the whole to carry out primary osteosynthesis on displaced fractures of all patients under the age of 50 years and on some of the elderly patients with serious fractures. The survey is retrospective, but owing to the department's special interest in these injuries very thorough case records have been kept and the information available concerning clinical and intraoperative findings is therefore sufficient All fractures have been X-rayed in frontal, lateral and oblique projections.



Figure 1 The distribution of the 48[illegible] fractures according to age and sex of the p[illegible] Figures on top of the columns indicate the [illegible] of operatively treated fractures

RESULTS

The causative factors are shown in Table 1 More than half of the injuries were caused by slipping or falling on level ground The series involves 263 men and 224 women The age distribution is shown in Figure 1 The mean [illegible] is 44 years In all the age groups over 40 years women predominate

The distribution of the entire material into types and stages according to Lauge Hansen (1942) appears in Table 2. The classifi[illegible] is based on clinical, roentgenological [illegible] traoperative findings. Only 1 2 per cent [illegible] material cannot be fitted into this syst[illegible]

In the following the stages of [illegible] dividual fracture types will be des[illegible] partly on the basis of roentgenologic[illegible] partly on the basis of intraoperative fin[illegible]

Supination-eversion fractures

SE fractures made up 57 4 per [illegible] (280/488) of all the ankle fractures. The [illegible] division and the associated injuries are [illegible] in Figure 2

Stage 1 Injuries in the anterior part [illegible] tibiofibular syndesmosis corresponding [illegible] anterior tibiofibular ligament (ATFL) [illegible]

Isolated rupture of the ATFL [illegible]

Table 1 Causative factors in 488 ankle fractures

Sports injuries	57	11 5 per cent
Traffic accidents	63	13 0 per cent
Slipping or fall on level ground	281	57 6 per cent
Fall from a height	53	10 9 per cent
Other and unknown causes	34	7.0 per cent
	488	100 0

Table 2 Distribution of 488 ankle fractures into type and stage according to the patho-genetic classification of N Lauge Hansen

SE fractures 280 57 4 per cent				*P/PE fractures* 102 20 9 per cent				*S fractures* 98 20 1 per cent				*Other fractures* 1 2 per cent	
stage	no	per cent	no oper	stage	no	per cent	no oper	stage	no	per cent	no oper	type	number
SE 2	162	58 0	55	P/PE 1	46	45 9	15	S 1	79	80 6	2	Isolated post tibial margin	4
SE 3	11	4 0	7	P/PE 2	18	17 6	6	S 2	19	19 4	7		
SE 4	87	37 3	66	P 3	8	7 8	4	*PD fractures* 2 0 4 per cent				Atypical fractures	2
SE 4 (lux)	18		16	PE 3	19	18 6	18						
SE 5	2	0 7	2	PE 4	11	10 1	7	PD 1	1	—	1		
								PD 2	1	—	1		

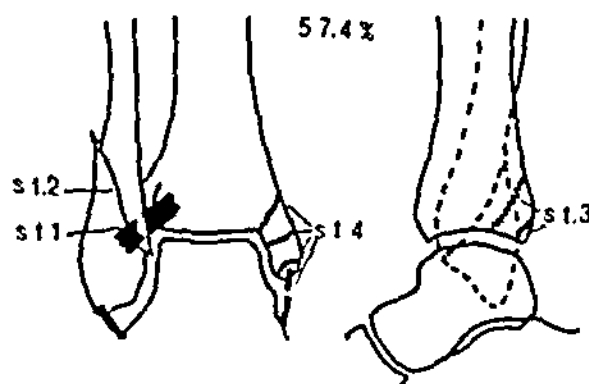


Figure 2. The stage division of supination-eversion (SE) fractures according to Lauge Hansen.

included in this material. In connection with osteosynthesis of the lateral malleolus the anterior part of the syndesmosis was explored in 141 ankles. The injuries to the ATFL are shown in Figure 3. A further 4 per cent (6/141) had an incomplete rupture of the ATFL.

Although X-rays were taken in oblique projection, it was difficult roentgenologically to diagnose the avulsion of bone fragments at

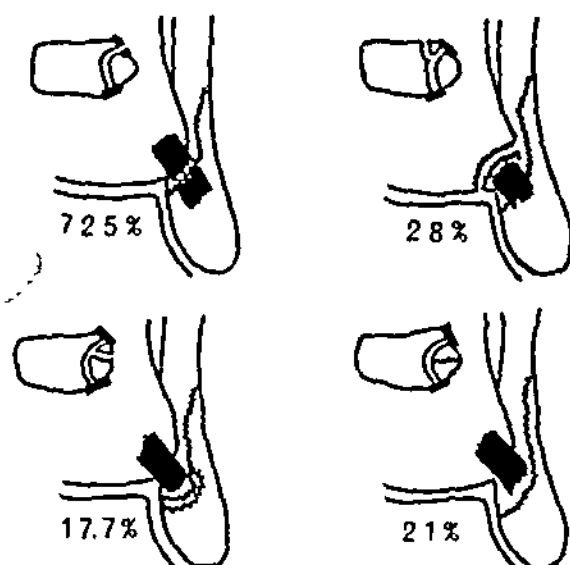


Figure 3. Stage 1 SE fractures Operative findings of the injuries to the ATFL in 141 fractures; a further 4.2 per cent had incomplete rupture of the ATFL.

the insertion of the ATFL. Of th found at operation to have avul fragment, only in 10 could demonstrated radiologically.

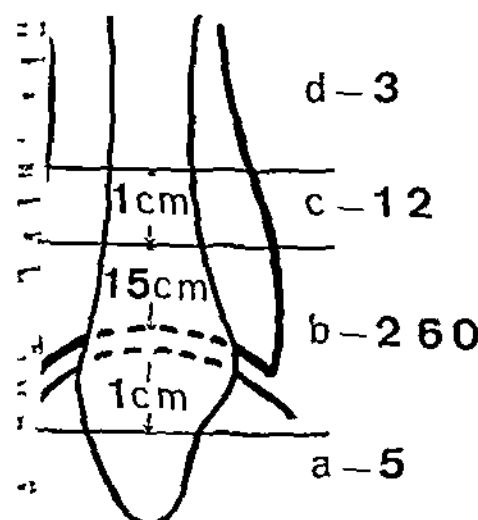
In three cases the ATFL was fo intact at operation. In these th fracture was described as running the fibular insertion of the ATFL.

Stage 2: Oblique spiral fracture of t malleolus running from the anterior a dorso-proximal direction and inch stage 1 injury (Figure 4)

SE 2 fractures made up 58 0 (162/280) of all SE fractures. The la fracture can be more or less vertical a variable distance from the tibiota space, as shown in Figure 5. Th "high" fractures in the area "d" are



Figure 4. SE 2 fracture Typical obliqu spiral fracture of the lateral malleolus (d projection).



- 5 Stage 2 SE fractures The location of ...ital end of the fracture of the fibular ...us in relation to the tibio-talar joint in 280 ...es

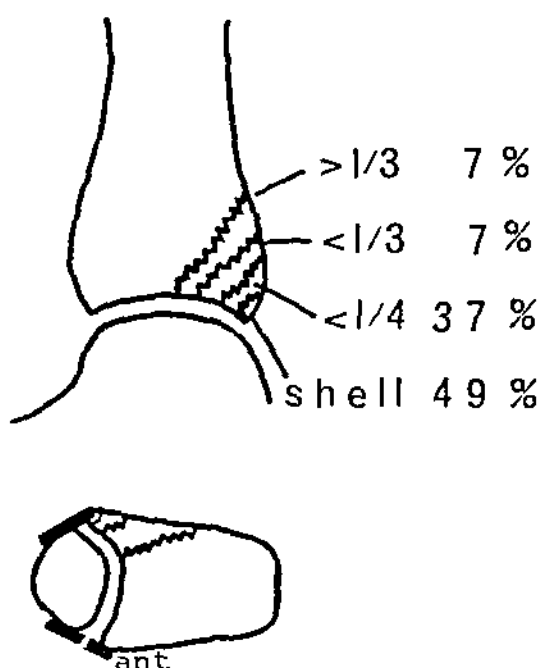


Figure 6 Stage 3 SE fractures Roentgenological classification of the injuries to the posterior tibial margin in 83 stages 3 4 and 5 fractures

... stage 2, one stage 3 and one stage 4 ...re As a rule only a slight instability of ...ndesmosis is present because only the ... is ruptured Still in nine cases marked ...ility was found This occurred in one ...2 fracture and in eight stage 4 fractures ...1 of these fractures were located in area

3 Fracture of the posterior tibial ...in including stages 1 and 2 (Figure 6)

...3 fractures made up 4 0 per cent ...80) of all SE fractures Only in 14 per ...of the cases d d the posterior fragments ...de more than 25 per cent of the joint ...ce

...is not necessary to have a fracture of the ...rior margin before the injury advances ...stage 4 fracture Among 107 stage 4 and ...ctures 32.7 per cent (35/107) did not ...any roentgenological fracture of the ...rior tib al margin

...e 4 Fracture of the medial malleolus or ...ure of the deltoid ligament including ...s 1 2 and perhaps stage 3

SE 4 fractures made up 37 3 per cent (105/280) of all SE fractures. Seventy five out of a total of 107 stage 4 and 5 fractures were treated surg cally If during the acute clinical examination tenderness swelling and dis coloration were present over the deltoid ligament and the X ray revealed no fracture of the medial malleolus then the ligament was considered injured The frequency of the various injuries is shown in Figure 7 Fourteen per cent (15/107) of the fractures of the medial malleolus were found to have an oblique (> 30°) direction

Among women fractures in the medial malleolus were found in 63 per cent (37/59) whereas among men only 35 per cent (17/48) sustained this fracture

Stage 5 Spiral fracture of the distal part of the tibia including stages 1 2 4 and perhaps stage 3

This fracture was only found in 0 7 per cent (2/280) of all SE fractures (Figure 8)

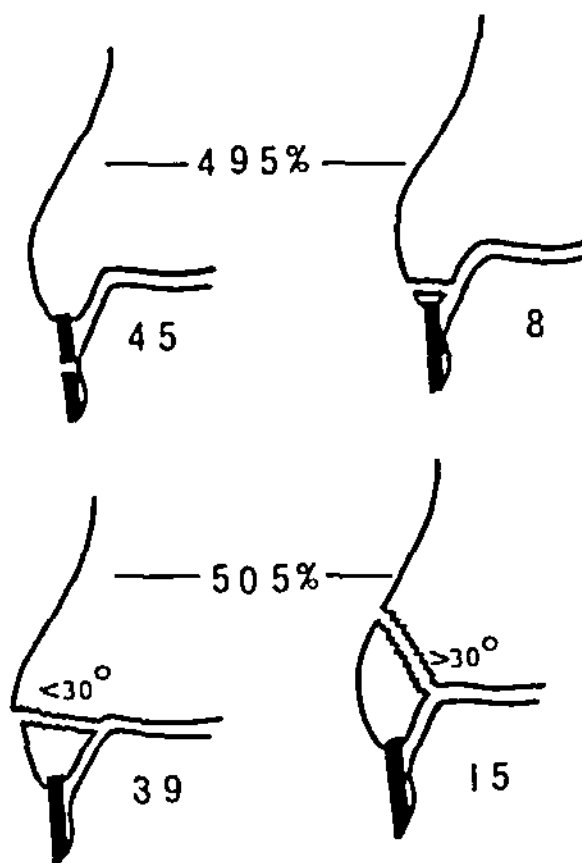


Figure 7 Stage 4 SE fractures Roentgenological, clinical and operative classification of the injuries to the medial malleolus and deltoid ligament in 107 stages 4 and 5 fractures

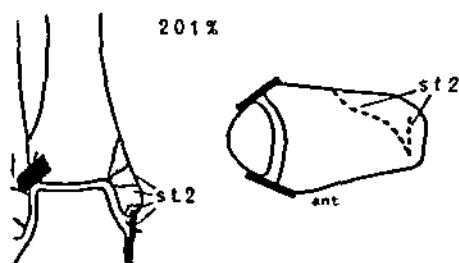
Supination fractures

S fractures made up 20 1 per cent (38/488) of all fractures. The stage division and the associated injuries are shown in Figure 9

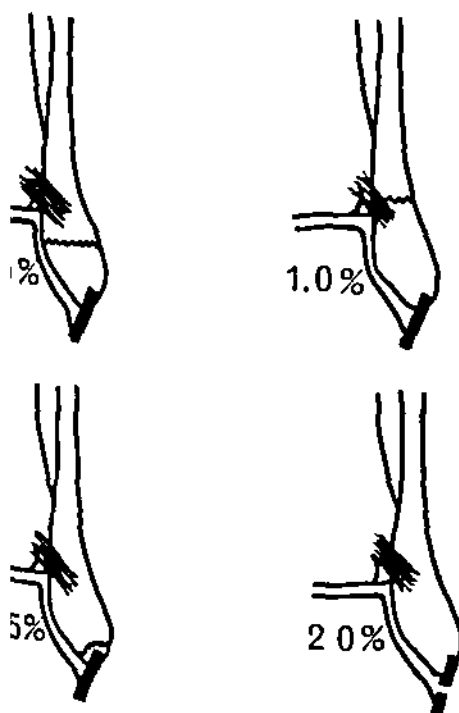
Stage 1 Fracture of the lateral malleolus at or distal to the level of the tibiotalar joint or rupture of the anterior talofibular and calcaneofibular ligament

Isolated ligamentous rupture is not included in this material S 1 fractures made up 80 1 per cent (79/98) of all S fractures The injuries of the lateral malleolus are shown in Figure 10 At operation the ATFL

Figure 8 SE 5 fracture Typical spiral fracture of the distal part of the tibia a) Frontal view b) Lateral view



9 *The stage division of supination (S) es according to Lauge Hansen*



10 *Stage 1 S fractures Roentgenological, l and operative classification of the injuries ral malleolus and anterior talofibular and eofibular ligament in 98 S 1 and 2 fractures ed ligamentous ruptures are not included)*

ound to be ruptured in one case and d from the tibia in another case

2 Fracture of the medial malleolus or re of the deltoid ligament, including 1

S 2 fractures made up 19 4 per cent (19/98) of all S fractures In 63 per cent (12/19) of the fractures an oblique to vertical (> 30°) fracture line was found, but transverse (< 30°) fractures were also seen (Figure 11) The four cases of rupture of the deltoid ligament were not operatively explored In a few cases a one-piece fracture of the posterior tibial margin and the medial malleolus was found (Figure 9)

Pronation and pronation-eversion fractures

P and PE fractures made up 20 9 per cent (102/488) of all malleolar fractures The stage division and the associated injuries are shown in Figures 12 and 13

Stage 1 Fracture of the medial malleolus or rupture of the deltoid ligament

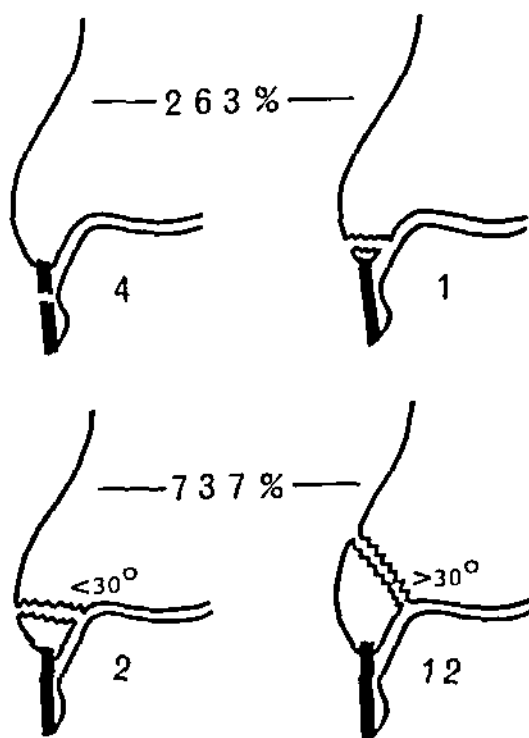


Figure 11 Stage 2 S fractures Roentgenological, clinical and operative (7 pts) classification of the injuries to the medial malleolus and deltoid ligament in 17 S 2 fractures

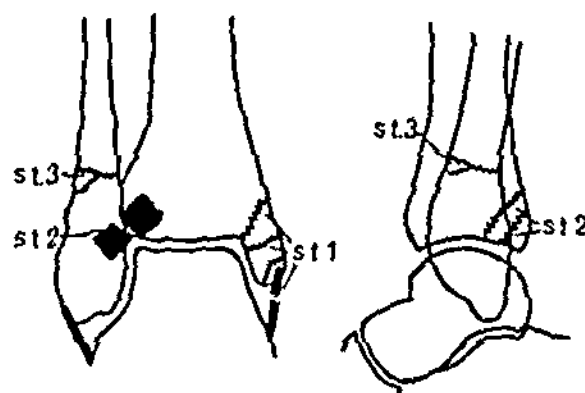


Figure 12 The stage division of pronation (P) fractures according to Lauge Hansen (1942)

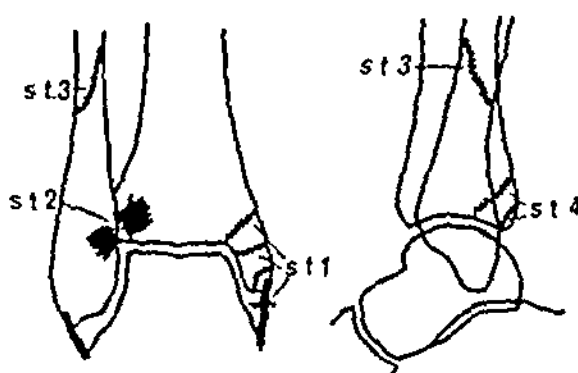
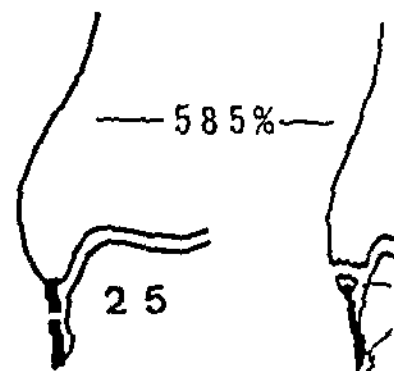


Figure 13 The stage division of pronation eversion (PE) fractures according to Lauge Hansen



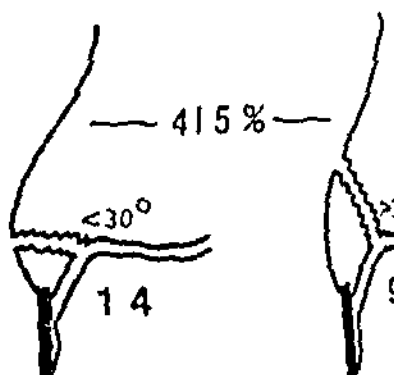


Figure 14 Stage 1 P and PE ... Roengenological clinical and operative ... tion of the injuries to the medial malle... deltoid ligament in 56 stages 2 3 and 4 ...

According to Lauge Hansen (1942) the fracture-causing mechanism in stage 1 of P and PE fractures is identical P/PE 1 made up 45 9 per cent (46/102) of all P and PE fractures The occurrence of various stage 1 injuries in stages 2, 3 and 4 is shown in Figure 14 If the small avulsion fragments are looked on as rupture of the deltoid ligament this type made up 58 5 per cent (33/46) of the medial injuries

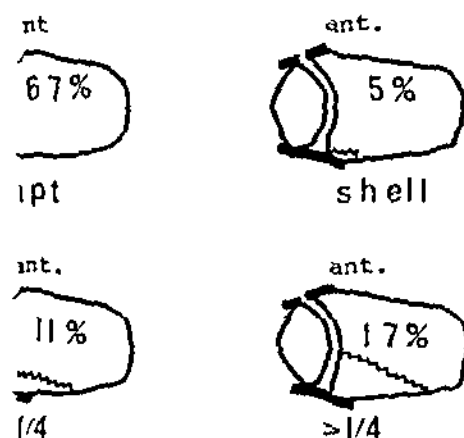
Stage 2 Rupture of the distal tibiofibular syndesmosis including stage 1

Clinically and roentgenologically it is impossible to distinguish between stage 2 injuries of P and PE fractures, and so they will be classified as P/PE 2 fracture... fractures made up 17 6 per cent (18... all P and PE fractures If a bone ... from the posterior tibial tubercle ... found the diagnosis can only be mad... findings of the clinical examination ... tenderness swelling and often disc... in front of and behind the lateral m... The stage 2 injuries of 18 P/PE 2 f... are shown in Figure 15

As regards P 3 and PE 3 and 4 th... was explored in 30 cases. Rupture ... ligament proper was found in 27 ca... avulsion fragments from the anter... tubercle in three cases

P stage 3 Low transverse supra... fracture of the fibular including stage 2 (Figure 12)

P 3 fractures made up only 7 8 p...



15 *Stage 2 P and PE fractures* *'enological and clinical evaluation of 18* *P fractures*

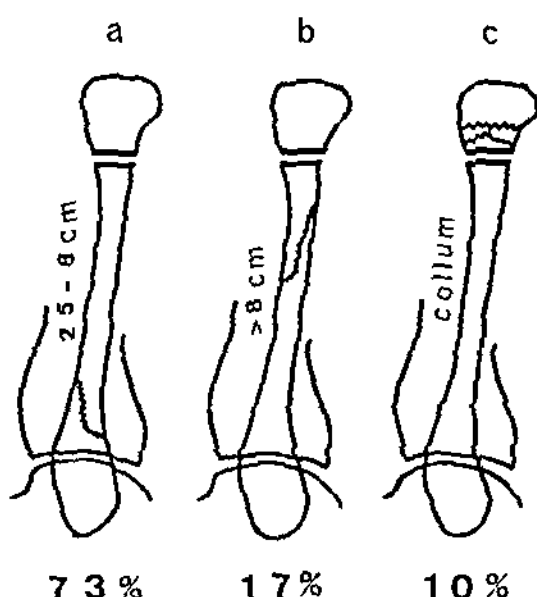


Figure 16 Stage 3 PE fractures Roentgenological evaluation of the site of the distal end of the fibular fracture in relation to the tibio-talar joint and illustrations of typical fracture lines (a, b and c) of 30 stages 3 and 4 fractures

2) of all P and PE fractures genological fracture of the posterior n was found in only one of these ıres

tage 3 High supramalleolar fracture of *ibular* including stages 1 and 2 (Figure

e level of this fracture varies greatly as n in Figure 16 No fracture was less 2 5 cm above the tibiotalar joint An *sment* of the course of the fibular ıre was made from the lateral X-ray ıty per cent (21/30) had a fracture line ng from the anterior fibular margin in a -distal direction (Figure 16a), 17 per (5/30) had a fracture line running in the site direction (Figure 16b) and 13 per (4/30) had a transverse or comminute ıre (Figure 16c) No cases had rupture of *roximal* tibiofibular syndesmosis.

gure 17 shows a PE 3 fracture with ion of the talus and total rupture of the esmosis but without any avulsion ıent from the posterior tibial tubercle

tage 4 Fracture of the posterior tibial 'in including stages 1 2 and 3

e size of this fracture varies as shown in re 18 The posterior tibiofibular ligament is intact and the fragment is in this way connected to the lateral malleolus. In 73 per cent (8/11) of these cases the posterior fragment included more than 25 per cent of the joint surface

Pronation-dorsiflexion fractures

These fractures made up 0 4 per cent (2/488) of all malleolar fractures. Stage 1 includes fracture of the medial malleolus and the anterior tibial margin In this series one PD 1 fracture was found (Figure 19) In the one stage 2 fracture an additional transverse fibular fracture was found

Isolated fracture of the posterior tibial margin

[illegible] fractures making [illegible] These [illegible] age range from 23–44 years. Three stumbled and one fell down 2 meters



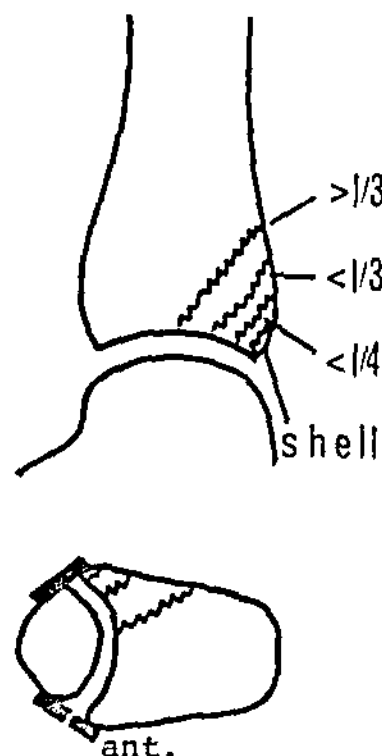


Figure 18 Stage 4 PE fractures Roentg evaluation of the fracture of the poste margin in 11 stage 4 fractures

DISCUSSION

In the present material 98 8 per cer malleolar fractures could be class accordance with Lauge Hansen's which consequently must be co suitable for the characterization of fractures This is in agreement with vestigations of Kristensen (1953) Bu Charnley (1965) and Maatz & Nom (1973) whose results showed that betw and 99 per cent of these fractures co classified according to Lauge Hansen.

The roentgenological and intraop findings also corresponded well t observations of Lauge Hansen (1942) a the case of SE fractures to the findi Cedell (1967)

Figure 17 PE 3 fracture Total lateral dislo of the talus with complete rupture of the desmosis but without fracture of the tibial tubercle a) Frontal view b) Lateral



e 19 Stage 1 pronation dorsiflexion (PD) fractures according to Lauge Hansen. a) Frontal b) Lateral view

ıwever, for P and PE fractures the ıentous injuries of the syndesmosis do seem to be fully explained by Lauge ıen (1942) Concerning the stages 2, 3 4 (cf Figure 17) it seems that the rior tibiofibular ligament is found to be ıred in cases without fracture of the rior tibial margin (Weber 1966) This s that fracture of the posterior tibial ın even in cases of PE fractures precedes bular fracture as a stage 2 injury and not stage 4 injury as supposed by Lauge ıen

shown in Figures 7 11 and 14 injuries he deltoid ligament and the medial olus are not pathognomonic for the us types of fractures as found by Lauge en (1942) In SE fractures the transverse)°) fracture is most frequently seen in S ıres the oblique (> 30°) fracture and in P/PE fractures almost equal frequency is seen

Lauge Hansen (1942) and Kristensen (1953) did not find any isolated fractures of the posterior tibial margin This fracture is, however, described by Magnusson (1944) Frank (1941) and Bonnin (1950) In the four cases found in this material the deltoid ligament was not explored and the clinical estimate cannot be considered to be com pletely reliable However in January 1979, a case of posterior marginal fracture was examined by the author and it was not possible to establish tenderness swelling or discoloration over the deltoid or the anterior talofibular and calcaneofibular ligaments.

As shown in this paper the Lauge Hansen classification gives a very precise and detailed description of malleolar fractures. A classifica- tion of this type is an excellent and necessary

means of conducting a comparable evaluation of results of various types of treatment of malleolar fractures.

In clinical work this classification is also very useful because it gives important information about ligamentous injuries which may accompany the fractures seen roentgenologically

REFERENCES

Ashhurst A & Bromer R (1922) Classification and mechanism of fractures of the leg involving the ankle *Arch Surg* 4, 51

Bonnin J G (1950) *Injuries of the ankle* William Heinemann Medical Books Ltd London

Burwell H N & Charnley A D (1965) The treatment of displaced fractures of the ankle by rigid internal fixation and early movement *J Bone Jt Surg* 47 B, 6...

Cedell C. A (1967) Supination-outward injuries of the ankle. *Acta orthop Suppl 110*

Frank S (1941) Isolerede brud i skinnebenskant (marginalbrud). *Nord. M* 643

Hansen N Lauge (1942) Ankelbrud I. diagnose og reposition. Diss. M Kbhn

Kristensen T B (1953) Ankelbrud. Dansk Nordisk Forlag Arnold Busch. Kbhn.

Maatz, R & Nonnemann H. C. (19 3) uber 938 bimalleolare Luxationsfraktur Teil *Chirurg* 44, 456 460

Magnusson R (1944) On the late results in operated cases of malleolar fractures F by external rotation *Acta chir scand* 84

Weber B G (1966/72) *Die Verletzungen oberen Sprunggelenkes* Verlag Hans H Bern Stuttgart, Wien.

Correspondence to Johannes Yde Department of Orthopaedic Surgery Hjorring Hospital, Hjorring Denmark

hop scand. 51, 193–196 1980

ONIC LATERAL INSTABILITY OF THE ANKLE

hod of Reconstruction Using the Achilles Tendon

G FJELD SOLHEIM, TOR FINN DENSTAD
ØRN ROAAS

a Hansens Hospital, Sandvika, Norway

Reconstruction of the lateral ankle ligaments *ad modum* Støren using the medial one third of the Achilles tendon as a nourished transplant is a relatively unknown procedure Thirty patients operated on using this technique have been evaluated The mean observation time was 4 years (range ½–16 years) All patients but one had a stable ankle joint and were satisfied One was reoperated after sustaining a new injury 6 months after the original operation The method described is a good alternative to other methods of ligamentous reconstruction The procedure also stabilizes the subtalar joint and corrects recurrent subluxation of the peroneal tendons.

Key words Achilles tendon, chronic ankle instability, lateral ankle ligaments, ligamentous reconstruction

Accepted 12 v 79

:ent instability, pain and muscular ess following rupture of the lateral :nts of the ankle is a frequent problem nan 1965, Freeman et al 1965) rvative treatment should be tried before al procedures Direct suture of the torn :nts (Brostrøm 1966, Solheim & Aasen and ligamentous reconstruction using :roneus brevis (Chrisman & Snook 1969, son 1978, Watson-Jones 1955) or the eus longus tendon (Zenni et al 1977) ell known procedures.

ren (1959), using the medial one third of chilles tendon as a nourished transplant :construction of the lateral ligaments, ed the importance of the fact that this d does not interfere with the function e peroneal tendons thus retaining the al muscular balance of the foot Beside reliminary report (Denstad & Solheim there has been no other report of this d This paper presents the result and modifications of the original operative dure

PATIENTS AND METHODS

Between the years 1962–1978, 30 patients with chronic lateral instability of the ankle joint were operated on using the original or a modified Støren procedure There were 20 male and 10 female patients with an average age of 35 years (range 19–55 years) The right ankle was involved in 19 and the left in 11 patients. All patients gave a history of primary severe sprain, which in the majority of cases had been insufficiently treated, and later chronic unstable ankles for periods ranging from ½–20 years (mean 8 years) On physical examination all patients had instability of the ankle by forced inversion and/or the anterior drawer sign. Anteroposterior and lateral stress X-rays showed marked tilting and anterior subluxation of the talus in most of the patients.

The operative findings showed seven isolated ruptures of the anterior talofibular ligament and two of the calcaneofibular ligament whereas 17 patients had ruptures of both ligaments. In four patients the ligaments were not dissected free Additional subtalar instability with rupture of the talocalcaneal ligament was found in seven of the patients and two had subluxation of the peroneal tendons

6470.80 010193–04$02.50 0

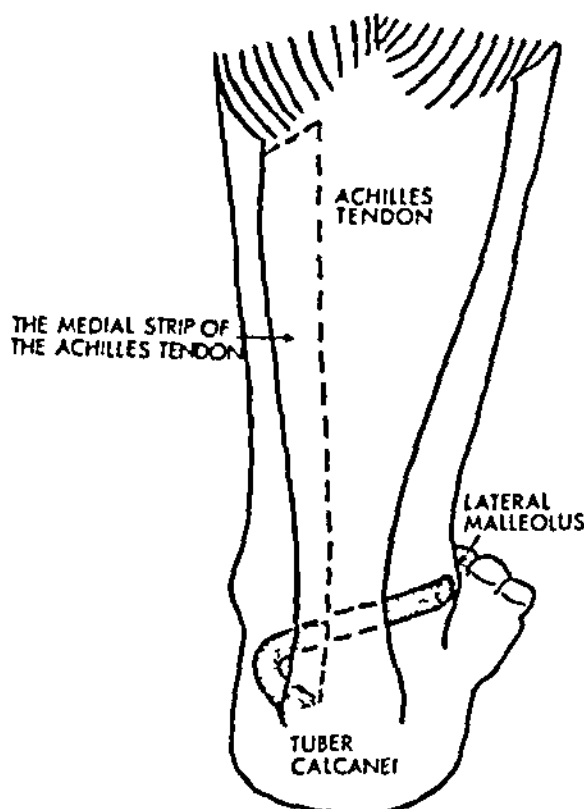
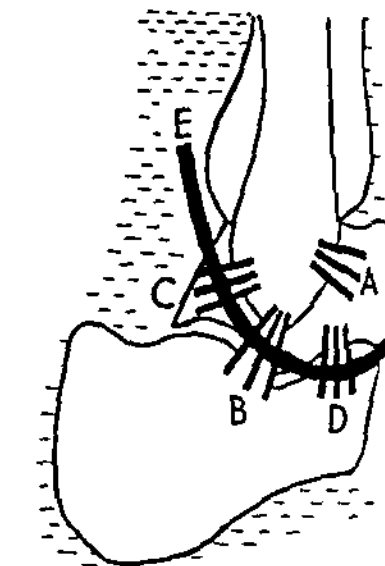


Figure 1 Dorsal view of the medial one third of the free dissected, reflected and transposed Achilles tendon

Operative procedure

First session Through a posteromedial longitudinal incision the medial one third of the Achilles tendon is dissected free, transected proximally at the musculotendinous junction and reflected distally without separating it from the distal insertion on the calcaneus (Figure 1) Støren exposed the region of the lateral malleolus through an anteriorly curved incision in front of the malleolus, but a curved incision behind the malleolus is preferable (Figure 2) The short extensor digitorum muscle is retracted anteriorly to expose the neck of talus, sinus tarsi and the lateral aspect of calcaneus. The free dissected tendon transplant is then pulled through to the lateral side in front of the remaining two thirds of the Achilles tendon and guided subcutaneously deep to the sural nerve but superficially past the peroneal tendons to the lateral malleolus. The tendon is now threaded through a drill hole in the lateral malleolus, a second drill hole in the neck of the talus and a third drill hole through the lateral aspect of the calcaneus To prevent limitation of dorsiflexion of the ankle the tendon should be fixed to the fibula with the ankle in dorsiflexion



talofibular ligament, B = calcaneofibula C = posterior talofibular ligament, caneal ligament)

before it is tightened and stitch periosteum at the other holes When th long enough, it is passed back to the lateral malleolus and sutured to the (Figure 3) This modification was perfo patients.

Second session If instability of the ank after this operation Støren recommend session to take place a minimum of 4 m the first session (Figure 4)

Postoperative treatment

Mean hospital stay was 14 days. Im in plaster postoperatively was contin weeks, the last 4 weeks with a wa following by intensive physical therapy

Follow-up examination

The follow-up period after the ope ½–16 years mean 4 years. All patients questionnaire and 16 patients were personally

RESULTS

Twenty patients rated their functio as excellent without complaints a

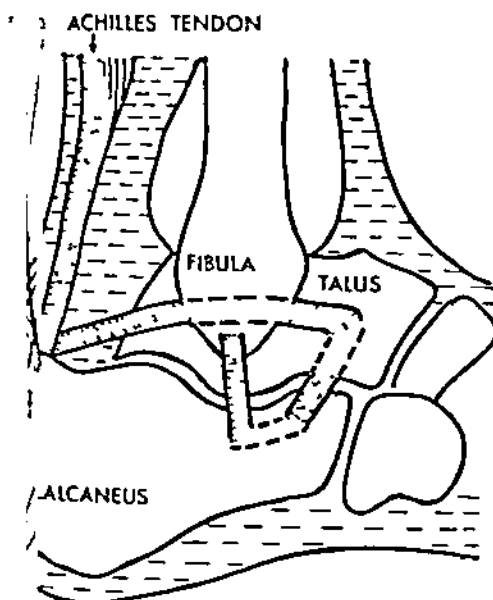


Figure 3 The completed modified procedure of ...ntous reconstruction employing the medial ...rd of the Achilles tendon

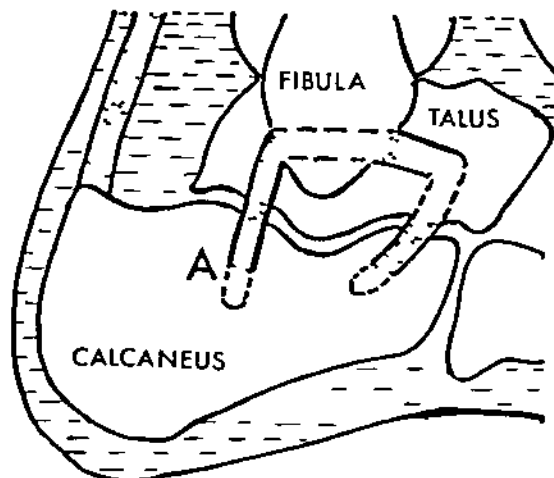


Figure 4 The second session of Støren's original procedure the posterior part of the transposed tendon has been freed from its insertion medially on the tuberosity of the calcaneus and fixed at the insertion of the calcaneofibular ligament on the calcaneus (A)

with slight complaints such as sporadic distortions (2 patients), occasional rate swelling (3 patients), slight pain on exertion (4 patients), a little limited flexion or inversion (6 patients) and nal symptoms from the Achilles tendon atients) Of the 16 patients examined nally all had a stable ankle Eleven out 3 competitive athletes were able to ne their previous sporting activity

mediate postoperative complications one case of superficial infection and two of wound necrosis all of which healed ly One patient was reoperated after ining a new injury 6 months after the operation The second session of the n operation was used and, in addition, vans tenodesis, using the peroneus brevis on.

CUSSION

ren (1959) reported seven operations, three them being two session operations, all ng satisfactory results. In our experience the first session of the operation is sufficient The transposition of the Achilles tendon in front of the malleolus represents a reconstruction of the anterior talofibular ligament Our modified procedure, guiding the tendon back to the fibula, represents a reconstruction of the calcaneofibular ligament, making the second session of the operation unnecessary

Subtalar instability may occur after sprain causing rupture of the talocalcaneal ligament (Rubin & Witten 1960, Meyer & Lagier 1977) as well as the calcaneofibular ligament (Chrisman & Snook 1969, Brantigan et al 1977) and should be diagnosed pre- or peroperatively, since the most commonly used Watson-Jones procedure will not correct this instability (Gillespie & Boucher 1971, Brantigan et al. 1977) Chrisman & Snook (1969) recommend a modification of the Elmslie procedure using half of the peroneus brevis tendon for treatment of talar and subtalar instability Brantigan et al. (1977) reported involvement of the subtalar joint in about 10 per cent of patients with lateral instability of the ankle compared with the 23 per cent in our material. This might be due

to the long preoperative period of ankle instability and to the exposure of the subtalar joint by this operation The stabilizing effect on the subtalar joint with this operation is satisfactory

Recurrent anterior displacement of the peroneal tendons due to tearing of the superior peroneal retinaculum may complicate sprains of the lateral ligaments (Anderson & LeCocq 1954) Two of our patients developed subluxation of the peroneal tendons after a long period of lateral ankle joint instability The method described corrects this condition as well as the instability of the ankle

Our results are comparable with those of other methods of ligamentous reconstruction The method seems especially valuable in the treatment of combined talar and subtalar instability or when additional subluxation of the peroneal tendons occurs. The operative procedure is however, somewhat extensive and the method should perhaps be reserved for cases of more severe instability

REFERENCES

Anderson K J & LeCocq J F (1954) Operative treatment of injury to the fibular collateral ligament of the ankle *J Bone Jt Surg* 36-A 825–832

Brantigan J W , Pedegana L. R & Lippert F G (1977) Instability of the subtalar joint *J Bone Jt Surg* 59-A 321–324

Brostrøm L (1966) Sprained ankles. VI Surgical treatment of chronic ligament ruptures. *Acta chir scand* **132**, 551–565

Chrisman O D & Snook, G A (
Reconstruction of lateral ligament tears o
ankle *J Bone Jt Surg* 51 A 904–912

Denstad T F & Solheim, L F (
Reconstruction of the lateral ligaments o
ankle joint *ad modum* Storen. In Proce
of the Norwegian Orthopaedic A
Acta orthop scand. 48, 558

Freeman M A R (1965) Instability of the
after injuries to the lateral ligament o
ankle *J Bone Jt Surg* 47 B 669–6

Freeman M A R Dean M R E & Hanh
W F (1965) The etiology and preventi
functional instability of the foot. *J Br
Surg* 47-B 678–685

Gillespie H S & Boucher P (1971) Wa
Jones repair of lateral instability of the a
J Bone Jt Surg 53 A, 920–924

Meyer J M & Lagier R (1977) Post-trau
sinus tarsi syndrome *Acta orthop scand*
121–128

Ottosson L (1978) Lateral instability of the
treated by a modified Evans procedur
orthop scand 49, 302–305

Rubin G & Witten M (1960) The talar-tilt
and fibular collateral ligaments *J Bo
Surg* 42-A 311–326

Solheim L F & Aasen A O (1976)
behandling av laterale ankelbåndskade
norske Laegeforen 96, 1192 1194

Storen H (1959) A new method for
treatment of insufficiency of the l
ligaments of the ankle joint *Acta chir sc*
117, 501–509

Watson Jones, R (1955) *Fractures and
injuries* Vol 2 4th ed pp 817 823. E. &
Livingstone Ltd Edinburgh and London.

Zenni E J Grefer M Krieg J K., Lamber
B & Florez R (1977) Lateral ligament
stability of the ankle a method of sur
reconstruction by a modified Wa son-
technique *Amer J Sports Med* 5 78–8

Correspondence to Ludvig Fjeld Solheim Martina Hansens Hospital 1300 Sandvika Norway

Ort ıop scand 51, 197–204, 1980

CULARIZATION OF FREE PERIOSTEAL AND MICRON THICK OSTEOPERIOSTEAL GRAFTS MUSCLE TISSUE ENVIRONMENT

o Poussa

Orthopaedic Hospital of the Invalid Foundation, Helsinki, Finland

The vascularization of free periosteal and 100 micron thick osteoperiosteal grafts was studied in growing rabbits Sixteen rabbits with 32 periosteal and 32 osteoperiosteal grafts were operated upon and microangiographed 1–21 days postoperatively The vascularization of free periosteal grafts started 1 day postoperatively and that of osteoperiosteal grafts 3 days postoperatively The first capillaries seemed to enter through the cambium layer in periosteal grafts and through the cortex in osteoperiosteal grafts.

Key words microangiography, osteoperiosteal graft, periosteal graft, vascularization

Accepted 30 vii 79

direct relationship between vasculariza- and osteogenesis was proposed by von r as early as 1763, but only during the 20 years has technical progress focused tudy of the anatomy of the circulation of onto the microscopical level (Rhinelander ragry 1962, Brookes 1964, Trueta 1963, elander 1972) Today our knowledge of the lation of cortical bone is mainly based on nany animal experiments performed by ta (1968), Brookes (1971) and Rhinelander 2) According to these studies the circula- of a long bone has three main sources the nutrient artery, the metaphyseal and yseal arteries and the periosteal arteries. a functional sense two different theories concerning the circulation in cortical , especially regarding its outer third rding to Brookes (1971) and Rhinelander 2) the medullary circulation is afferent, irection of flow in the diaphyseal cortex g centrifugal This means that the osteal arteries serve only as com- municating vessels between the bone and the soft tissue, usually muscle, as the final ring of the afferent system According to the dual circulation concept (Trueta 1963, 1968) the medullary, metaphyseal and the epiphyseal vessels contribute to the circulation of the inner two thirds of the cortex, the outer third being supplied by the periosteal vessels. Agreement between these theories is however reached when considering a situation where the medullary circulation is disturbed Then the extraosseous vessels proliferate, produce new periosteal bone and also nourish the outer lamellae of the cortex (Trueta 1963, Danckwardt-Lilliestrom 1969, 1970 and Rhinelander 1972) In our previous studies (Poussa & Ritsila 1979, Poussa et al 1980) a comparison was made between the osteogenic properties of a free periosteal graft and 100 micron and 200 micron thick osteoperiosteal grafts The 200 micron thick osteoperiosteum was inferior to both other grafts osteo- genically On the other hand only a minor

-6470, 80 020197–08S02.50/0

difference could be seen between the behaviour of the free periosteum and that of the 100 micron thick osteoperiosteum. During the first 3 postoperative days the cambium layer cells of the free periosteum seemed to proliferate more vigorously than the corresponding cells in the 100 micron thick osteoperiosteum Therefore a study was made of the development of the vascularization in these two grafts

Special attention was paid to the direction from which the vessels invading the periosteal and osteoperiosteal grafts came, and to the possible differences in the intensity of the vascularization between the two grafts. The question regarding the direction of the vascularization is of special interest, because of the different opinions about the direction of the flow in the periosteal vessels *in situ*

MATERIAL AND METHODS

Sixteen 6-week-old rabbits were operated upon In each one free periosteal and 100 micron thick osteoperiosteal grafts were detached from the medial facet of the tibia and then fixed to two adjacent lumbar vertebrae between the spinous and mamillary processes, so that altogether 32 periosteal and 32 osteoperiosteal grafts were studied Details of the operation technique have been described in a previous paper (Poussa & Ritsila 1979) On days 1, 2, 3, 4, 5, 6, 7, 9, 14 and 21 the vascularization of the grafts was studied by a technique presented by Jarvinen (1976) being a modification of the technique used by Wendelin & Lindgren (1970) and Chaplin (1973)

The animals were anaesthetized with intramuscular Hypnorm® (Philips, Duphar 0 5 ml/kg) a laparatomy was made through the midline incision and the abdominal aorta was cannulated through the bifurcation the tip of the catheter pointing towards the heart A catgut thread was tied around the distal abdominal aorta and the cannula so that there was no circulation to the lower extremities Next 5000 units of Heparin was injected into the aorta, followed by physiological saline solutions temperature 32–37°C, perfused at a constant pressure of about 100 mmHg (the container was positioned about 1 3 m above the rabbit) The pressure in the abdominal aorta was also controlled by hydrostatic measurement At the beginning of the infusion the pressure in fact was about 100 mmHg when measured just proximal to the needle that was in the abdominal aorta. Later on, especi[...] the animal died there was a mild decrea[...] pressure to about 90 mmHg After 5 [...] perfusion was continued using a warm, 3[...] per cent radiopaque suspension (Crom[...] Damancy & Co Ltd England) for about 20 [...] Thereafter the perfusion mixture was chang[...] per cent Cromopaque® diluted in 10 per cen[...] buffered formalin The rabbit usually died [...] the first 20 minutes of the infusion. The[...] was totally immersed in 10 per cent [...] solution for 24 hours. The vertebra with [...] rounding muscles were then detached and [...] about a week in a formalin solution.

The extra muscles around the verteb[...] removed and the samples were [...] formic acid, dehydrated in graded [...] in xylene and toluene and embedded in [...] containing paraffin and beeswax. Seri[...] micron thick sections were cut horizontall[...] the blocks. Because the width of the grafts [...] approximately 4–5 mm only two to three [...] micron thick sections were obtained from [...] vertebra during the first postoperati[...] on possibly because the newly [...] "sprouting" over the edges of the grafts [...] number of sections was obtained [...] vertebra The distribution of the [...] at various intervals is presented in the fol[...] table

Postop day	No of sections studied
1	4
2	6
3	6
4	8
5	3
6	4
7	15
9	5
14	9
21	13
	73

These sections were placed in contact with photographic emulsion (Kodak High Res[...] Plate, USA) A Machlett AEG–50 roentgen [...] with a 1 5 mm focal spot and equipped with [...] mm beryllium window was employed this was [...] at 30 kV The film focus distance was 0.5 [...] Sections measuring 6 micron were made fro[...] sample to get the histological counterpart [...] microangiogram



1A Microangiogram (×5) 1 day atively The grafts in the microangiogram as shadows In the periosteal graft (P) some contrast media are seen also incipient pro- of capillaries from the mamillary process OP osteoperiosteum)



Figure 1B Histological picture (× 250 Van Gieson) from the microangiogram of the free periosteum 1 day postoperatively Proliferation of the cambium layer (CL) is clearly seen in association with contrast medium filled capillaries (Ca) (FB—fibrotic layer of the periosteum M—muscle)

TS

The filling of the vessels in the slices d also in the vicinity of the grafts iscle layer covering the grafts was a loose mass a narrow gap separa from the underlying grafts This iously an artefact arising during the ion of the sample

microangiogram of the periosteum a its of contrast medium were seen 1A) In the histological study the layer of the grafted periosteum was proliferate with some contrast filled vessels (Figure 1B) These medium filled vessels were seen in the four sections studied

osteoperiosteum neither the cortex periosteum were seen to have medium filled vessels In the cal counterpart no proliferation of the layer was seen

In the microangiogram of the m sprouting of the capillaries was occur from the underlying tissue near illary process (Figure 2A) In the cal study the thickened and pro- cambium layer was seen with wide illed with contrast medium (Figure is incip ent vascularization of the m was seen in five of the six sections

In the 100 micron thick osteoperiosteum no corresponding capillary ingrowth could be seen Also no ingrowth of capillaries was observed on the other s de of the grafts i e through the fibrotic layer of the periosteum (Figure 2A)

Day 3 The whole periosteal graft was vascularized and capillaries were sprouting from the underlying muscle and to a minor degree from the muscle above (Figure 3)

In the 100 micron thick osteoperiosteum incipient invasion of the capillaries from the underlying tissue was seen the cortical part of the grafts being invaded first

Six 1000 micron thick sections were studied periosteal vascularization was seen in four and osteoperiosteal in two

Days 4–5 Circulation was present in both the periosteal and osteoperiosteal grafts The intensity of the vascularization seemed to be directly related to the intensity of the new bone formation or *vice versa* In the histological study contrast filled vessels were seen in the cambium layer in the newly formed bone and also in the fibrotic layer of the periosteum









Figure 2A. Microangiogram (×5) 2 days postoperatively There is capillary sprouting in the cambium layer of the free periosteal graft from the underlying muscle This is better seen in the higher magnification (×40). The 100 micron thick osteoperiosteum looks inactive



Figure 2B Histological picture from the microangiogram of the free periosteum 2 days postoperatively (×250) Wide contrast medium filled capillaries (Ca) are seen in the proliferating cambium layer



Figure 3 Microangiogram (×6 magnifications ×40) from the lumbar days postoperatively On the periostea there is circulation which seems to be mor the part facing the underlying muscle filled point (arrow)



4A



Figure 4B Histological p cture from the

the gap seen in the microangiogram

ogether eleven sections were obtained n all of them vigorous vascularizat on seen

6 7 There was vigorous circulation in periosteal and osteoperiosteal grafts re 4A) In the histological study new had been formed by both the periosteal he osteoperiosteal grafts The new bone formed by the periosteum was seen to have a well developed circulation with its sur roundings On the other hand in most of the ossicles formed by the osteoperiosteum there was some kind of frontier through which the vascular communications between the bone










Figure 2A Microangiogram (×5) 2 days postoperatively There is capillary sprouting in the cambium layer of the free periosteal graft from the underlying muscle This is better seen in the higher magnification (×40) The 100 micron thick osteoperiosteum looks inactive



Figure 2B Histological picture from the microangiogram of the free periosteum 2 days postoperatively (×250) Wide contrast medium filled capillaries (Ca) are seen in the proliferating cambium layer



Figure 3 Microangiogram (× magnifications ×40) from the lumbar days postoperatively On the periost there is circulation which seems to be m the part facing the underlying muscle teoperiosteal side (OP) contrast filled seen in the cortical part of the graft. incipient vascularization possibly com the periosteum especially from the lat point (arrow)

no other studies dealing with the zation of free periosteal grafts have formed The importance of the circula- prerequisite for osteogenesis also in l grafting has been emphasized by the f King (1976) and Finley et al (1978) mer author produced new bone in logs by periosteal grafts based on and the latter authors transplanted free l grafts by preserving the circulation microsurgical anastomoses between and grafts vessels. Finley et al used osteal grafts as controls In no case was e formation observed in the control

On the other hand there are numerous dealing with the physiology of skin which in some aspects resemble al grafts In skin grafting it has been at prior to establishment the grafts are ed by the diffusion gases and nutrition ross the grafted bed interface (Smahel lso in skin grafts the ingrowth of new es into the graft from the bed is y negligible the main blood supply of afts coming from the anastomoses n the existing vessels (Smahel & n 1970)

he other hand the revascularization of grafts is said to occur mainly by y sprouting (Stringa 1957, Zeiss et al nd Rhinelander 1972) Also contrary have been presented (Deleu & Trueta These authors implanted small bone into the anterior chamber of rats and pigs and concluded that only mosis between the pre-existing host raft vessels could explain the rapid rization of the grafts. The sizes of the ts were "one to two millimeters "

he present study contrast medium was n the cambium layer capillaries 1 day eratively From the microangiogram e histological slides it is difficult to see er an anastomosis between the pre- g vessels of the bed and the graft has place or if this revascularization has ed through capillary sprouting

nga (1957) found that capillary sprouting penetrated into autogenous grafts with a speed of 3 mm per 7 days from the kidney bed in rabbits and guinea pigs Also it has been reported by Danckwardt Lillieström (1969) that after reaming the medullary cavity of a rabbit femur new capillaries can be seen after 24 hours. Clark & Clark (1939) found that capillaries grew with a speed of 0 22 mm per day in the transparent chamber of th rabbit's ear

From 2 days on postoperatively it see that the vascularization of free per grafts occurred by capillary sprouti the bed through the cambium Revascularization was achieved by periosteal grafts about 2 days earli the 100 micron thick osteoperios ea

In some earlier reports it ha postulated that during the first few bone transplantation the nutrition of grafts is achieved by diffusion (Ham On the other hand in some of the stud Graf (1960) Trueta (1963) Deleu & Trueta (1965) and Tervo (1976) concerning the speed of vascularization it was found that the vascular penetration preceded the formation of secondary osteones A similar conclusion can be drawn from the present study New bone formation was seen 4—5 days postoperatively in both periosteal and osteoperiosteal grafts but contrast medium was visible in periosteal grafts as early as 1 day postoperatively and in osteoperiosteal grafts 3 days postoperatively

In this study the capillary sprouting during the first few days was seen to come from the bed below through the cambium layer of the periosteal grafts but between the bed above and the fibrotic layer of the periosteal as well as the osteoperiosteal grafts as late as 3 or 4 days postoperatively As a result of the operation trauma the muscle layer covering the grafts was exposed to much greater damage than the muscle beneath the graft The direction of sprouting may have been different if the grafts had been fixed in another way i e with the cambium layer of the free periosteum and the cortex of the osteoperiosteum in contact with the muscle above

representation is obtained At the time when the records were searched for information about the alcoholics and their controls there was a 28-year roentgen history of the residents of the city available for study The files were searched for records of roentgen examinations in the same manner for all 321 men involved in the study Altogether 3242 roentgen referrals were scrutinized The following variables were recorded

a) The total number of fractures over the years.

b) The number of fragility fractures—vertebral crush fracture, fracture of the upper end of the femur, fracture of the upper end of the humerus, fracture of the distal end of the forearm, ankle fracture and fracture of the lateral tibia condyle (Nilsson & Westlin 1977).

c) The total number of skull roentgen examinations and the number of skull fractures.

d) The total number of fractures occurring in conjuction with industrial accidents and traffic accidents.

e) Gastro-duodenal roentgen examinations, total number of "first" examinations excluding all follow-up examinations related to ulcer Also, the number of the gastro-duodenal peptic ulcers diagnosed over the years.

f) The number of i v urographies, again only "first" urographies and not serial investigations, and the number of kidney stones diagnosed over the years.

RESULTS

The average number of roentgen examinations was 14 for alcoholics and 8 for the controls. The number of fractures (Table 1) was almost quadrupled in the alcoholics compared with the controls and so was the number of fragility fractures The difference as in both instances significant ($P < 0.001$[1]) The number of skull roentgen examinations, again, was significantly increased ($P < 0.001$) —by a factor of more than 4—in the alcoholics but the large number of roentgen examinations did not reveal an increased number of skull fractures The number of industrial accident related factures was not significantly increased in the alcoholics The number of traffic accidents, however, was increased ($P < 0.001$) but in relation to the total number of fractures, the traffic accident fractures were not significantly more common in the

[1] Chi-square test.

Table 1 Radiographic examinations and ... in 100 alcoholics and age-matched co...

	Alcoholics	Co...
Total fractures	95	
Fragility fractures	41	
Skull roentgen	69	
Skull fractures	3	
Industrial accident fractures	11	
Traffic accident fractures	13	
Gastro-duodenal roentgen	147	
Gastro-duodenal ulcer	32	
I v urography	50	
Kidney stones	10	

alcoholics. The number of ga... roentgen examinations and ga... ulcers was increased by about ha... alcoholics as compared with the cont... proportion of positive and negati... gen examinations was about the sam... groups. Finally, i v urography with a... a positive finding of stones did n... significantly between alcoholics and ...

DISCUSSION

Misusers of alcohol are an important ... the elderly perhaps the mo... portant—group of medical consume... consumption of medical care also ... roentgen diagnosis to an extent far a... average The diagnostic procedures ... always fruitful, skull roentgen exa... as shown above yield very little inf... but are nevertheless frequently use... differential diagnosis of intoxication a... traumatic neurologic conditions. F... fracture examinations, however, the ... negatives was less in the alcoholics ... the controls For some diagnostic pr... such as gastro-duodenal roentgen ... tion, the proportion of alcoholics ha... examination is moderate and easily ... by an increased prevalence of gast... ditions. With regard to other

c procedures such as ı v urography n seems to be without importance ost strıkıng findıng ın thıs study ıs, t, the ıncreased rate of fracture , ın spıte of the known relatıonshıp alcoholısm and fragılıty fractures ın ly, as demonstrated ın the case of of the neck of the femur and fracture pper end of the humerus (Nılsson rak & Nılsson 1975), the number of fractures amounted to the same f the total ın the alcholıcs as ın the Thıs ıs probably explaıned by the the alcoholıcs durıng most of the overed by the study had not yet the age when fragılıty fractures a serıous problem

REFERENCES

Honkanen, R & Visuri, T (1976) Blood alcohol levels ın a serıes of ınjured patıents wıth specıal reference to accıdent and type of ınjury *Ann Chır Gynaec Fenn* **65**, 287

Horak, J & Nılsson B E (1975) Epıdemıology of fracture of the upper end of the humerus. *Clın Orthop* **112**, 250

Nılsson B E (1970) Condıtıons contrıbutıng to fracture of the femoral neck. *Acta chır scand* **136**, 383

Nılsson, B E & Westlın N E (1973) Changes ın bone mass ın alcoholıcs. *Clın Orthop* **90**, 229

Nılsson, B E & Westlın, N E (1977) Bone mıneral content and fragılıty fractures *Clın Orthop* **125**, 196

Savılle, P D (1967) Changes ın bone mass wıth age and alcoholısm *J Bone Jt Surg* **37**, 492

ıdence to Bo Nilsson, M D, Department of Orthopedıc Surgery Malmo General Hospıtal, l Malmo Sweden



op scand. 51, 209–214, 1980

'EFFECT OF AXIAL TENSION ON THE LOAD
:ING CAPACITY OF TRACTION PINS*

A, A MACK† & J A. ALBRIGHT

hanics Laboratory, Department of Orthopaedics, Louisiana State University Medical Center,
port, Louisiana, USA

Skeletal traction is often used in the conservative treatment of fractures. Although a small diameter traction pin causes less trauma, its use is limited by the strength of the pin and the holding power of the bone Both theoretical analysis and *in vitro* experiments were conducted to investigate the bending resistance of traction pins subjected to an applied traction force The results of this study indicate that thin K-wires could be used successfully as traction pins. Excessive bending of these wires could be prevented by applying tension The possibility of a pin cutting through bone is minimal if the cortical bone structure of the patient is normal However, further *in vivo* study is necessary to ascertain whether necrosis might occur due to excessive contact stress between the pin and the bone

Key words K-wires, skeletal traction, tension, traction pins

Accepted 12 xi 79

ure of a long bone is a common problem 'thopaedic surgery At times such a ure must be treated non-surgically, at temporarily, whether due to associated es, or due to the type of fracture itself ι such conservative treatment is the od of choice, as open reduction is always npanied by the risk of infection (Albright 1978) However, contractures or spasms rge muscles surrounding fractures of long s sometimes tend to cause overriding or lation of the fragments, which may be ult to reduce by manual manipulation : This is particularly true in oblique and comminuted fractures of the long bones such as the femur (DePalma 1970) In such cases a continuous traction force is generally applied on the distal fragment to overcome muscle pull, correct the angulation and restore the length Even when anatomical reduction has been achieved, traction is often employed to maintain the length and alignment Generally more force is necessary for the reduction phase than for the maintenance, and therefore some authors make a distinction between reduction traction and maintenance traction (McElvenny 1963)

In the case of a limb, there are two methods of applying traction (a) the force may be applied through the skin which is called skin traction, or (b) the force is applied directly to the bone by means of a metal pin or wire which is driven through the bone, as shown in Figure 1, and this is called skeletal traction (Stewart 1975) Although skin

sented in part at the 5th Annual New gland Bioengineering Conference held at the iversity of New Hampshire in April 1977 and the 30th ACEMB Conference held in Los geles in November 1977

'sently a graduate student in Northwestern iversity

-6470 80 020209–06$02 00

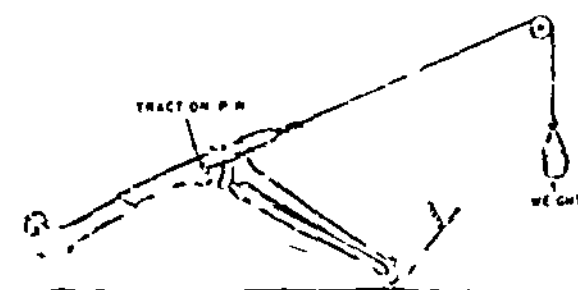


Figure 1 Skeletal traction being applied to the distal femur for reducing a femoral fracture

traction is less traumatic, it can be applied only for limited time periods and for small loads It is generally used for maintenance traction only (McElvenny 1963) According to Stewart (1975) the maximum traction weight which can be applied with skin traction is 15 lb (6 7 kg), but McElvenny (1963) has suggested that the weight should be less than 8 lb for the lower extremity and less than 4 lb for the upper extremity Therefore, when a substantial amount of weight is needed, or when prolonged traction is indicated, pin traction is generally used (Figure 1) Traction on a pin which transverses the bone often does not cause pain, assuming that soft tissue irritation is prevented at the points of exit on either side

Two types of pins are commonly used in orthopaedic surgery (1) Kirschner wires (K-wires) which have a small diameter (0 025 to 0 062 inches or 0 6 to 1 6 millimeter) and (2) Steinmann pins which are larger ($\frac{1}{64}$ to $\frac{3}{16}$ inches or 2 to 4 8 millimeters) Although use of a small diameter pin is preferred as it causes less trauma K-wires tend to bend if the traction load is large Recently, Morgan et al (1976) have suggested that the bending resistance of small pins can be improved by using pins made of stiffer materials such as tungsten fibre reinforced composite The bending resistance of metal pins can also be improved by applying an axial tension with the help of a Kirschner wire strainer (as shown in Figure 2) (Albright et al 1978) However no quantitative data is available on the effect of axial tension in reducing deflection of metal pins due to bending

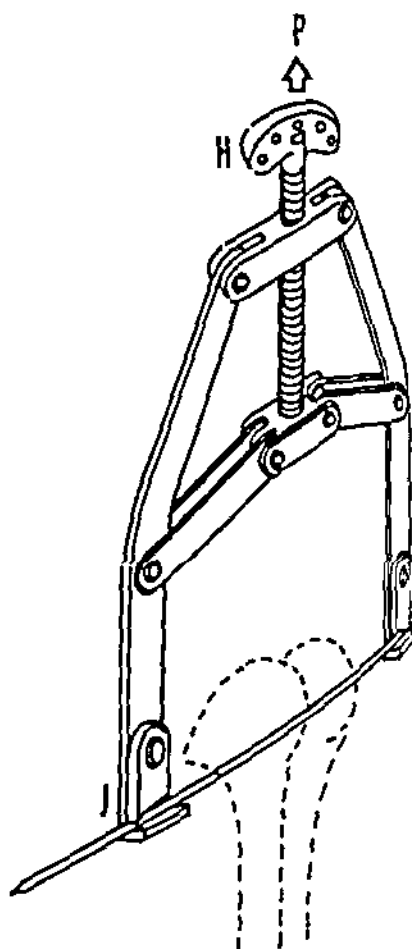


Figure 2 Kirschner bow or wire strainer ... is held between serrated jaws J Turn... handle (H) increases the distance between ... (J) producing axial tension in the p... position of the bone is shown by a dotted ... P indicates the traction force

The objective of this investigation ... study the effect of applied tension ... resistance of pins to bending due to ... load As another objection to using ... diameter pins is the possibility of ... cutting through bone experiments we... carried out to determine if thin K... under normal traction loads produce su... contact stress to cut through bone

THEORETICAL ANALYSIS

Nomenclature

D – Diameter of the pin
E – Modulus of elasticity

...oment of inertia of the pin
... of the pin projected beyond the bone
...ion force
...on in the pin
...co-ordinates along the length of the pin, and ...o the pin, respectively

$\frac{T}{EI}$

...mum deflection of the pin at $x=L$

...bending resistance of a traction pin ...d to a traction force P and an axial tension ...be analyzed by treating the pin as a ...er beam of length L as shown in Figure 3 ...his cantilever beam model and assuming ...ection to be small and the stress strain ...to be linear and elastic, one can show ...differential equation governing the deflec... of the beam is given by (Timoshenko & ...71)

$$EI\frac{d^2y}{dx^2}=T(\delta-y)-\frac{P}{2}(L-x) \quad (1)$$

...is the modulus of elasticity, I is the ...of inertia of the pin and δ is the ...deflection at $x=L$ The general solution ...n (1) is

$$C_1e^{\beta x}+C_2e^{-\beta x}+\left(\frac{PL}{2T}-\frac{Px}{2T}-\delta\right) \quad (2)$$

β^2 $\frac{T}{EI}$ and the first two terms are the ...ous solution of the differential equation ...the term within the parenthesis is the ...solution (Boyce & DiPrima 1969) The ...y constants C_1 and C_2 can be evaluated by ...g the boundary conditions $y=0$ and $\frac{dy}{dx}=0$ ...end $x=0$ Substitution of C_1 and C_2 the solution

$$y=\left(-\frac{PL}{4T}+\frac{P}{4T\beta}+\frac{\delta}{2}\right)e^{\beta x}+\left(-\frac{PL}{4T}-\frac{P}{4T\beta}+\frac{\delta}{2}\right)e^{-\beta x}+\frac{PL}{2T}-\frac{Px}{2T}-\delta \quad (3)$$

...ld be evaluated by using the relation at ...$y(L)=\delta$ Using this relation and after some ...we get

$$\frac{\delta}{P}=\frac{1}{2T}\left[L-\frac{1}{\beta}(e^{2\beta L}-1)(e^{2\beta L}+1)^{-1}\right] \quad (4)$$

...is utilized to determine the effect of ...nt axial tension T and pin diameter D on ...mum deflection δ per unit traction force

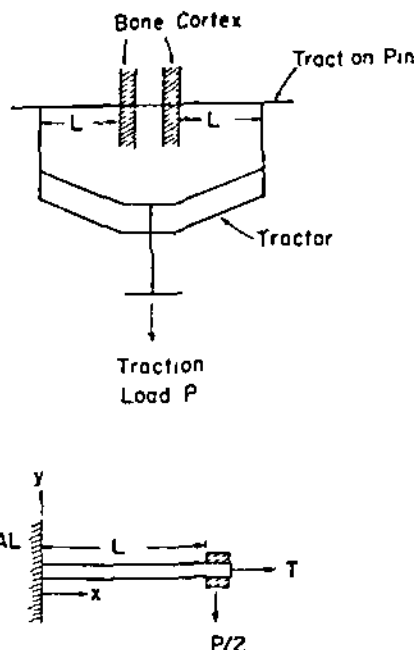


Figure 3 Cantilever beam model of the traction pin showing the axial tension force T and traction load P, and the co-ordinate system used

EXPERIMENTAL METHOD

Experiments were carried out on the bending behavior of a small diameter pin (D=0 062 inch or 1 6 millimeter) using embalmed human and fresh beef bones. The pin was inserted into the mid shaft of an embalmed human femur and subjected to a maximum axial tensile force which could be applied manually by a Kirschner wire strainer Then traction loads were applied and maintained for about 12 hours. The traction load was increased in steps of 10 lb (44 5 N) up to a maximum of 50 lb (222 4 N) For each traction load the maximum deflection of the pin was measured from its undeflected position with the help of a millimeter scale Similar tests were also conducted using an embalmed human tibia

Small diameter pins were also inserted through the epiphyses of embalmed human tibias and femurs and similar tests, as mentioned before were repeated The test set up is shown in Figure 4 At the end of each test the bones were examined for the evidence of any damage at the point of insertion of the pin

RESULTS AND DISCUSSION

The numerical results from the theoretical analysis are shown in Figures 5 and 6 Figure 5 shows the maximum deflection (δ) of the

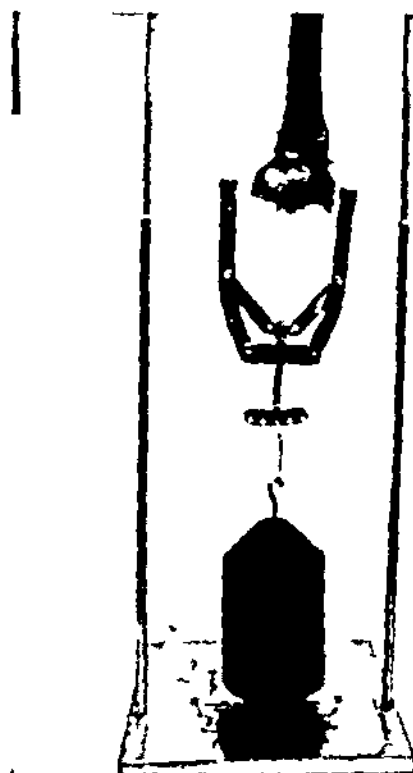


Figure 4 Experimental set up showing a thin K-wire (0 062 inches in diameter) through the epiphysis of a human tibia subjected to an axial tension applied by a Kirschner wire strainer and a 50 lb traction load

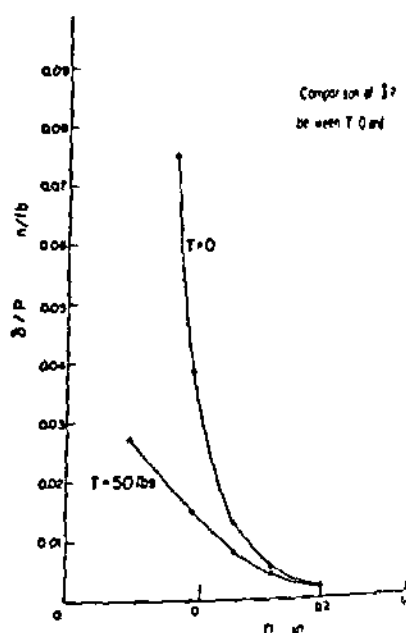


Figure 6 Relationship between the max deflection (δ) and the pin diameter D for tensile load levels, T = 0 and T = 50 lb.

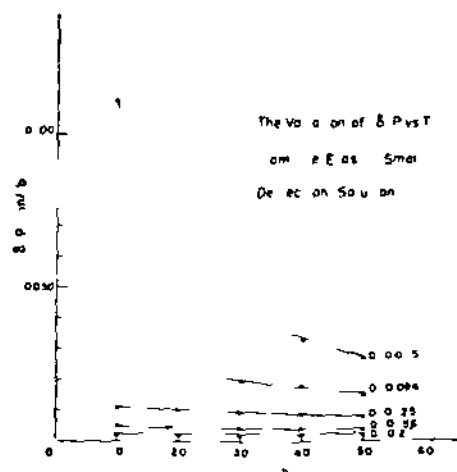


Figure 5 Maximum deflection (δ) of different diameter traction pins as a function of the axial tension (T) in the pin

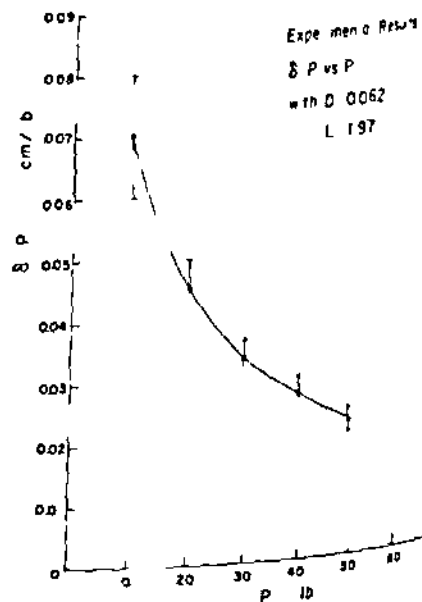


Figure 7 Variation of maximum deflection per unit traction load P as a function of the traction, P Axial tension was applied by a Kirschner wire strainer

unit traction force (P) as a function of tension (T) in the pin, for various -r pins. It is clear that for large er pins (diameter 0 125 inch or 3 2 ter and above) deflection remains unaffected by the tension T in the pin er for small diameter pins the on is significantly reduced as the in the wire is increased

maximum deflection δ per unit force P has also been plotted as a n of the pin diameter D for two axial forces T=0 and T=50 lb or 222 4 N 6) Figure 6 shows that for small er pins (say D<0 125 in or 3 2 mm) aximum deflection without a tensile T is significantly larger than when an tensile force T=50 lb (222.4 N) is l However this tensile force does not the bending resistance of pins of er D larger than 0 2 in (5 1 mm)

re 7 shows the maximum deflection of ire, measured experimentally, per unit force as a function of increasing n force P It clearly shows that due to ial tension, the deflection per unit n force decreases as the traction load is ed and for a moderate traction load, flection is small

should be pointed out that as the num deflection δ is increased, the ng moment on the pin due to the on force P remains almost unaffected the corrective bending moment due to ial tension increases in direct propor- with δ As the free end of the pin is held wire strainer, additional bending also to increase the length of the pin and ore increases the axial tension

examine the possibility of small er pins under normal traction load through the bone, laboratory tests conducted using embalmed human Kirschner wires (0 062 in or 1 6 mm er) were inserted through the sial cortex and the wire was subjected by using a traction bow There sign of the wire cutting through the even when a maximum traction load of 50 lb (222 4 N) was applied for more than 12 hours

When a similar test was conducted on K-wires inserted through the distal epiphyses, the wire still sustained the traction load without cutting through the bone so long as the thin shell of cortical epiphysial bone was intact However, for those specimens in which the cortical bone covering the trabecular bone structure was damaged, the wire did show evidence of cutting through the spongy bone

CONCLUSION

Metal pins (K-wires and Steinmann pins) are often used in orthopaedic surgery for (1) applying skeletal traction, (2) internal fixation of fractures and osteotomies and (3) the arthrodesis of the joints. Whether used for traction or for other purposes, the relationship between the pin diameter and the load which can be safely applied to the pin is often questioned The factors limiting the amount of weight that can be safely applied to a pin include the potential damage to joints from excessive stretching, the strength of the pin, and the holding power of the bone

The results of this study indicate that thin K-wires could be used successfully as traction pins Excessive bending of these wires could be prevented by applying axial tension with the help of a Kirschner bow The possibility of a pin cutting through bone is minimal if the cortical bone structure of the patient is normal However, further *in vivo* study is necessary to ascertain if bone necrosis might occur due to excessive contract stress between the pin and the bone

ACKNOWLEDGMENT

The authors are grateful to Dr E. S Crelin for his help in obtaining the bone samples. This work was supported in part by USPHS Research Grant No 7RO1 AM 26732.

REFERENCES

Albright J A Johnson T R & Saha S (1978) Principles of internal fixation *Orthopaedic mechanics Procedures and devices* (ed by Ghista D N & Roaf R) pp 123–299 Academic Press London

Boyce W E & DiPrima R C (1969) *Elementary differential equations* John Wiley & Sons Inc New York

DePalma A F (1970) *The Management of fractures and dislocations* Vol 2 W B Saunders Co

McElhenny R T (1963) *Broken leg* Charles C Thomas, Springfield, Illinois

Morgan H G Ryder D A & White ... (1976) Tungsten Fibre reinforced ...

Mechanics of materials D Van Nostrand New York

Correspondence to Prof S Saha Ph D, Biomechanics Laboratory Department of Orthopaedics Louisiana State University Medical Center Shreveport Louisiana 71130 USA

thop scand 51, 215–222, 1980

OVERY OF DIAPHYSEAL BONE STRENGTH 'ER RIGID INTERNAL PLATE FIXATION

xperimental Study in the Rabbit

FTMAN, F SIGURDSSON & L. STRÖMBERG

tments of Orthopaedic, General and Experimental Surgery, Karolinska Hospital, Stockholm, Sweden

The course of the recovery from the unfavourable effects of a rigid internal fixation plate on the strength of diaphyseal bone, measured as the maximum torque capacity, has been studied in rabbit tibiae Due attention was paid to the screw holes. On removal of the plate, which had been applied for 12 weeks without prior osteotomy, the bone had decreased in strength by approximately 50 per cent

Following removal of the plate, the bone regained its normal strength after only 6 weeks. The regaining of strength proceeded in a significantly non-linear manner and in accordance with the logistic function $\hat{y} = \frac{t}{a + br^t}$

Key words bone adaptation, bone strength diaphyseal bone, internal fixation, internal fixation plates, recovery of bone strength

Accepted 2 vii 79

nal fixation by means of metal plates is a well-known and established method icture treatment, mainly due to the basic rch work of the AO-group (The Associa- for the Study of Internal Fixation ems, Switzerland, Müller et al 1965)

a previous investigation (Stromberg & 1976b), the weakening effect of an nal fixation plate *per se* upon a diaphyseal was elucidated It was stated that ment of a diaphyseal bone fracture by s of internal plate fixation should not be dered as complete until the bone had its process of reconstruction and had l its normal strength after the removal implants. The time required for the to regain its strength was not studied e purpose of the present investigation o clarify the time required for a rabbit previously stabilized for 12 weeks by means of a rigid internal fixation plate, type AOI (Muller et al 1970), to regain its normal strength, measured as the maximum torque capacity

MATERIAL

Eighty seven healthy adult rabbits (Swedish land breed, weighing 3–5 kg) of both sexes were used and in 65 of them the effect of rigid internal fixation on the torsional strength of their tibiae was studied Twenty-two animals were thus excluded because of complications arising from the anaesthesia, fractures and technical failures.

As stabilizing devices, internal fixation plates suitable for rabbit tibia were designed and manufactured in accordance with AOI internal fixation compression plates They were made from stainless steel (ISI 316), measured 35 × 6 × 2 mm and had four screw holes. The plates could be regarded as rigid compared with the rabbit tibiae

"0/80/020215–08$02 50/0

The plates were fastened to the tibiae by means of four screws (type AOI) with a diameter of 2 mm and of sufficient length (10 15 mm) designed for cortical bone

METHODS

The rabbits were divided into two main groups, group I and group II Group I consisted of 26 rabbits In these animals the weakening of the tibiae caused by the application of a rigid internal fixation plate was studied In the 39 rabbits in group II the regaining of normal torsional strength after plate removal was studied

The main groups were further divided into smaller sub-groups Group I was thus divided into four sub groups in which the torsional strength was measured 6 8 10 and 12 weeks after surgery

In group II the internal fixation plates were left in place for 12 weeks causing weaking of the test bones The plates were then removed and with the tibiae no longer stabilized the process of recovery of strength could begin In this group comprising six sub groups the maximum torque capacity of the tibiae was measured 1 2 3 4 5 7 5 and 10 weeks after plate removal

An agreement in maximum torque capacity between two tibiae of a related pair has been demonstrated in dogs (Stromberg & Dalén 1976a Netz et al 1978) In order to verify whether a corresponding agreement exists in the rabbit the tibiae of 10 rabbits were torsionally tested The difference in torsional strength between the right (X_1) and the left (X_2) tibiae was calculated by the formula d $\frac{X_1 - X_2}{(X_1\ X_2)\ 0\ 5}$ 100

The results showed a significant ($P < 0\ 05$) uniformity of maximum torque capacity between related pairs of tibiae (Table 1) The mean value for the right tibia was 2 1 per cent lower than that for the left but this difference is not significant ($P < 0\ 05$) In the present investigation this justifies the use of one tibia of a related pair chosen at random as test bone and the other as control

Operative procedures

After weighing the rabbits were anaesthetized with Mebumal vet® (ACO Solna Sweden) diluted in physiological saline solution in a ratio of 1 3 Thirty five mg per kg body weight corresponding to 15 mg/ml were administered intravenously and further doses were given during surgery if and when required All operations were performed under strictly sterile conditions A straight incision was made in the skin and fascia over the rabbits tibia running from the distal part of the knee to the level of the malleolus over the margo anterior tibiae lateral aspect of the tibia was exposed retracting the tibialis anterior muscle. The were fastened to the tibia in accordance method described by the AO group (Müller 1970) and by means of the AOI small fr instrument set (Synthes CH 4437 Waldenburg Switzerland) without any previous When the plates had been applied to both tibiae an animal the plate from one of the tibiae at random was removed and the bone selected as the control The screws re inserted into their holes The fascia were sutured with catgut and non absorbable sutures All the rabbits both in group I and II had hitherto been treated in the same After 12 weeks however the rabbits in group were submitted to a second surgical ... and the plates were removed The screws were inserted into their holes and the skin and ... sutured as in the previous operation.

Postoperative treatment

The postoperative course was uneventful the animals were kept in cages large enough permit normal exercise They received ... food and water and were observed daily the removal of the plates all treated bones submitted to radiological examination in order exclude any loosening of the implants (Fig




Figure 1 A rabbit tibia with an AOI ... fixation plate

Sacrifice

The rabbits were sacrificed with lethal dose Mebumal vet® given intravenously

Bone preparation

Immediately after sacrifice both tibiae dissected free of all soft tissue and connective bones The tibiae were kept moist physiological saline solution at a temperature approximately 37°C until they were to be tested for torsional strength

1 Maximum torque capacity of the right and the left tibiae of 10 rabbits The difference between ht and the left tibiae from the same animal is expressed as the percentage deviation from the f the two bones The mean value for the right tibiae was 0 9 per cent lower than that for the left, but the difference is not significant (P > 0 05)

Rabbit no	Maximum torque capacity (Nm) Right tibia	Left tibia	Percentage deviation
1	2 37	2 46	−1 9
2	1 91	1 95	−1 0
3	1 70	1 90	−5 5
4	2 66	2 33	+6 6
5	1 45	1 57	−4 0
6	2 28	2 08	+4 6
7	2 38	2 40	−0 4
8	2 61	2 36	+5 0
9	1 75	1 63	+3 6
10	2 33	2 31	+0 4

2 Maximum torque capacity, after plate removal, of rabbit tibiae to which rigid internal fixation lates had been applied for 6, 8, 10 and 12 weeks, and that of the paired control tibiae

	Maximum torque capacity (Nm)							
	6 weeks		8 weeks		10 weeks		12 weeks	
Observation no	Test tibia	Control tibia	Test tibia	Control tibia	Test tibia	Control tibia	Test tibia	Control tibia
1	2 39	3 64	2 72	3 44	2 17	3 67	1 64	4 64
2	2 53	4 11	2 58	3 14	1 65	2 14	1 88	4 98
3	2 63	2 73	2 54	2 84	1 23	2 47	2.58	3 48
4	1 90	3 66	1 85	2 95	0 80	2 07	1 73	3 75
5	2 46	3 32	1 40	2 78	3 09	3 24	1 07	1 69
6	3 50	2 96	1 20	2 47	1 91	3 80	0 96	2 51
7			2 76	2 99	2.27	2 45		

nal tests

the tibiae were tested within 30 minutes acrifice The torsional strength of the bones leasured as the maximum torque capacity on twist at 6° per second The tests were med by means of a test machine and in lance with the method described by berg & Dalen (1976a) The output signal the test machine gave the torque which was ered as a function of the deformation by a sensitive time-base recorder — a direct ig ultra-violet light beam oscillograph llofil, E Siemens Halske A G Henzestrasse 3520 Erlangen 2, F R Germany)

Sources of error

The experimental error of the torsional test ... the present study

Calculations

The original data from the torsional tests are given in Nm and the figures are presented in Tables 2 and 4

The mean percentage deviation in torsional strength between test and control bones after each time interval is calculated from the sum of the

Table 3 Means of the maximum torque capacity of rabbit tibiae affected by a rigid internal fi plate and of the paired control tibiae The deviation of the mean torque capacity of the pre plated tibiae is expressed as a percentage of the corresponding value obtained from the control ti

Weeks after performed internal plate fixation	Mean of the maximum torque capacity (Nm)		Percentage deviation
	Test tibiae	*Control tibiae*	
6	2 56	3 40	−24 7
8	2 15	2 94	−26 9
10	1 87	2 83	−33 9
12	1 64	3 51	−53 3

observations in the test and control bones The data thus calculated are also given in Tables 3 and 5

Statistical methods

Conventional statistical methods were used to estimate the mean values and standard deviations Statistical significance of the difference between stabilized and non-stabilized bones was calculated by means of the *t*-test for paired and independent samples

In order to clarify the progress of return of strength of the previously plated bones, measured as maximum torque capacity, two regressions were performed, a non-linear regression in accordance with a logistic function where $\hat{y} = \frac{t}{a + bt^{t}}$ and a linear one where y equals a + bt The sum of residuals in the former case was compared statistically with the residual sum of squares of the latter

$P < 0.05$ was considered as non-significant

RESULTS

I Compared with the corresponding control bone, the rabbit tibia, stabilized according to the AO-method by means of a rigid internal fixation plate for 6, 8, 10 and 12 weeks, displayed after removal of the implants, but with the screws reinserted into the bone

a significant ($P < 0.05$), progressive reduction in maximum torque capacity with increasing duration of plate fixation

II Rabbit tibiae, stabilized with a rigid internal fixation plate, type *AOI*, *for 12* weeks, thus causing a 53 3 per cent red in maximum torque capacity showed 4 5, 7 5 and *10* weeks *after removal* plates (and reinsertion of the screws in holes)

a) a significant ($P < 0.05$) increa maximum torque capacity

b) a significantly ($P < 0.05$) non recovery of strength, in accordance the logistic function $\hat{y} = \frac{t}{a+}$ measured as maximum torque capa

c) a significantly ($P < 0.05$) more return of full torsional strength bone, measured as maximum capacity, compared with the develo of the corresponding weakening of bone due to the application of the internal fixation plate

DISCUSSION

In amending their original recommen concerning the time for plate removal fi months (Muller et *al* 1965) to 18 months (Muller et al 1970) after an internal f procedure, in order to diminish the refractures the AO group took the time into consideration It is difficult to clinically whether or not a fracture has when it is treated with a rigid i fixation plate producing compression b the fracture ends in accordance with th method (Richon et al 1967)

Observation no	Maximum torque capacity (Nm)											
	1 week		2 weeks		3 weeks		4 5 weeks		7 5 weeks		10 weeks	
	Test tibia	Control tibia	Test tibia	Control tibia	Test tibia	Control tibia	Test tibia	Control tibia	Test tibia	Control tibia	Test tibia	Control tibia
1	2 47	2 74	1 37	1 81	6 34	5 74	4 92	4 96	3 52	3 22	5 39	5 07
2	0 95	1 87	1 19	1 56	3 10	5 91	4 52	5 10	2 84	2 38	5 53	3 88
3	1 87	2 59	1 18	2 51	4 97	3 95	4 77	6 25	4 14	3 75	4 65	4 60
4	2 60	3 22	1 58	2 47	3 98	4 15	5 21	5 21	4 34	4 80	3 29	3 80
5	1 92	2 78	1 41	2 52	1 52	2 51	3 41	4 04	2 98	2 93	3 60	3 66
6			3 44	6 71	1 84	2 86	3 39	3 17				
7			4 60	4 22	3 95	5 21						
8			2 74	2 44	3 88	4 10						
9			1 95	2 33	4 44	4 57						

Table 5 Means of the maximum torque capacity of rabbit tibiae, previously plated for 12 weeks and tested 1, 2, 3, 4 5, 7 5 and 10 weeks after plate removal, and of the paired control tibiae The deviation of the strength of the previously plated tibiae is expressed as a percentage of the corresponding value obtained from the control tibiae

Weeks after plate removal	Mean of the maximum torque capacity (Nm)		Percentage deviation
	Test tibiae	Control tibiae	
1	1 96	2 64	25 8
2	2 16	2 95	26 8
3	3 78	4 33	12 7
4 5	4 37	4 79	8 8
7 5	3 56	3 42	4 1
10	4 49	4 20	6 9

A rigid internal fixation plate fastened to the fractured bone by means of screws will together with the screws and bone form a mechanical joint, rigid compared with the unplated bone There will thus be an increased stiffness in the load bearing construction and consequently a decreased stress and strain concentration in the bone component of the thus formed mechanical joint as compared with that in the unplated bone The increased stiffness is equivalent to the decreased deformation produced by a certain load (Netz et al 1978)

Bone has the ability to adapt itself to functional load demands (Wolff 1892) The mechanism underlying this property of bone is not yet fully understood It has been demonstrated that the stress and strain concentration is of crucial importance for bone metabolism and reconstructive activity (Basett 1971, Pauwels 1973)

The application of a rigid internal fixation plate to a diaphyseal bone will cause an immediate change in the load situation Due to the stiffness of the plate, which compared with the bone can be regarded as rigid, the load carried by the bone part of the mechanical joint is almost negligible The decreased stimulation of the anabolic bone metabolism will cause an atrophy of the cortical bone resulting in reduced strength (Strömberg & Dalen 1978)

The gradual atrophy will probably not affect the load situation significantly, as the plate will carry almost all the load as long as the mechanical joint exists. The cortical atrophy and the concomitant weakening of the bone should thus theoretically develop at a constant speed

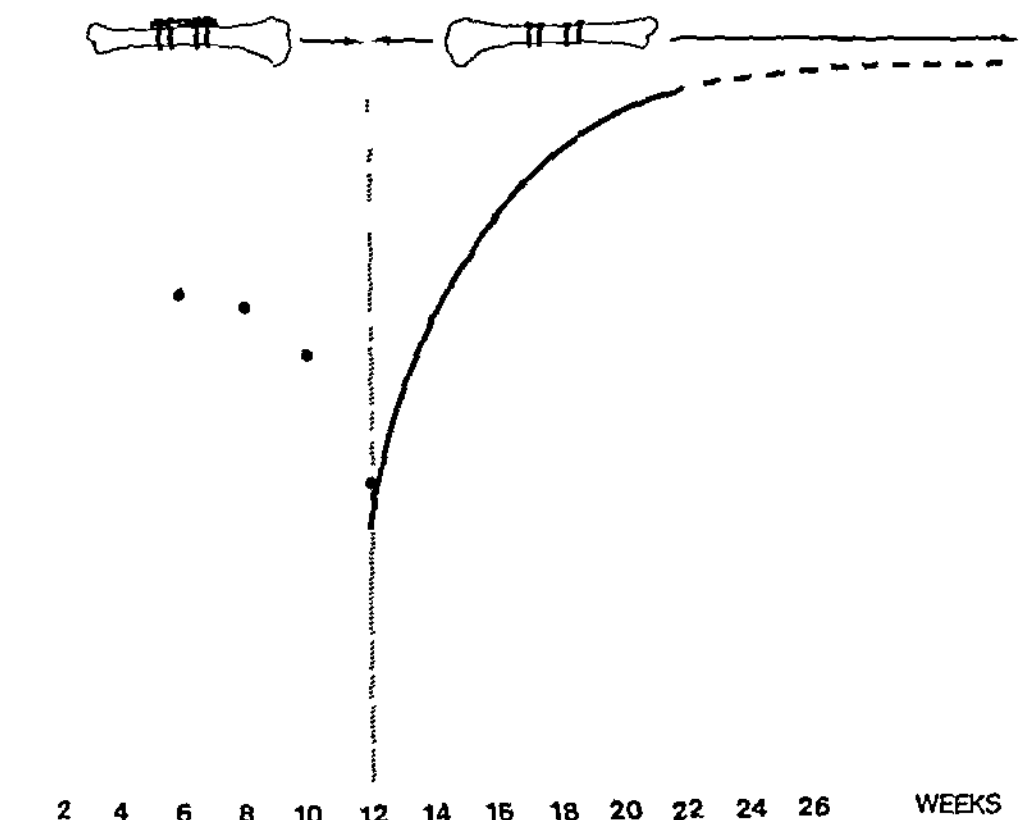
In the present study, however, we could not verify the presumed *linear development* of the weakening due to the plate We consider that this is not possible with the present experimental model

Burstein and co-workers (1972) showed that rabbit diaphyseal bone with an inserted screw, similar to the one used in the present study, will regain its torsional strength after 8 weeks. We thus did not consider it appropriate to study the weakening plated bone during the first 6 weeks the interaction between the screws and holes on one side and the plate on the

When the internal fixation plate removed after 12 weeks a sudden situation occurred in the bones reasonable to assume that the rabbit tibiae had undergone a atrophy uniformly throughout the bone previously stabilized cortical bone Strömberg & Dalen 1978, Slatis et al As the animals started to bear weight previously plated bones an enlarged and strain concentration arose Conse there was an increased stimulation bone-forming cells to produce bone (Bassett 1971, Pauwels 1973) to repl load-bearing function of the plates. Th adapts itself in this way to the functional and physiological dem accordance with Wolff's law

It is the lack of cortical bone ma the previously stabilized diaphyseal section, in combination with the load on the segment to a normal level causes increased stress and strain volume of bone in the atrophied cortex when the plate is removed Conseque will stimulate anabolic bone me resulting in an increased cortical bone tion However, as the bone gradually from its atrophy, i e the amount material approaches a normal level, th be a concomitant decrease in the and strain concentration resulting simultaneous and gradually dec stimulation of the bone-forming cells. confirmed by the present results (Fi The readaption process is thus non-lin in *accordance* with a logistic function. therefore in contrast to theoretic pectations concerning the development corresponding weakening of the bone the plate

The time required by the bone to r strength was, in the present study ha time required by the bone to adapt load situation due to the plate i.e. th



e 2 Means of the maximum torque capacity of rabbit tibiae to which a rigid internal fixation has been applied for 6 8 and 12 weeks respectively and the means of the maximum torque of rabbit tibiae to which a rigid internal fixation plate has been applied for 12 weeks lly tested 1 2 3 4 5 7 5 and 10 weeks respectively after the plate has been removed The torque capacity is expressed as a percentage of the corresponding control bones After 12 weeks the had decreased in strength by 53 5 per cent and they took approximately 7 5 weeks to regain full after the plate removal. The regaining of strength developed in a significantly non linear r in accordance with the logistic function $y = \frac{1}{a + br^t}$

he weakening process The cause of this epancy is not yet fully understood

treatment of a fractured diaphyseal with a rigid internal fixation plate as by the AO-group must not be d as complete until a certain period apsed after the removal of the plate and bone has thus regained its normal (c.f Stromberg & Dalen 1976b). We tempted to recommend that the length of period should be at least half that of the ious period of internal plate fixation On basis of the present results, we are inclined to postulate that the unfractured part of the previously stabilized bone needs that amount of time after removal of the plate to complete its process of reconstruction and to regain its normal mechanical strength

REFERENCES

Basett C A L (1971) Biophysical principles affecting bone structure *The biochemistry and physiology of bone* (Ed Bourne G H) Vol 3 Academic Press, New York and London

Burstein, A H, Currey, J, Frankel, V H, Lunseth, P & Vessely, J (1972) Bone strength The effect of screw holes *J Bone Jt Surg* 54-A, 1143–1156

Muller, M E, Allgower, M & Willenegger, H (1965) *Technique of internal fixation of fractures* Springer Verlag Berlin, Heidelberg, New York

Muller, M E, Allgower, M & Willenegger, H (1970) *Manual of internal fixation* Springer Verlag, Berlin, Heidelberg, New York

Netz, P, Eriksson, K & Strömberg, L (1978) Torsional strength and geometry of diaphyseal bone *Acta orthop scand* 49, 430–434

Netz, P, Eriksson, K & Stromberg, L (1979) Nonlinear properties of diaphyseal bone *Acta orthop scand* 50, 139–143

Pauwels, G (1973) Kurzen uber die mechanische Beanspruchung des Knochens und ihre Bedeutung fur die funktionelle Anpassung *Z Orthop* 111, 681

Richon, A, Livio J J & Saegesser F (…) refractures après ostéosyntèse par (…) compression *Helv chir Acta* 34, 49–(…)

Slatis P, Karaharju E, Holmstrom, T, (…) J & Paavolainen P (1978) Structural (…) in intact tubular bone after application of plates with and without compression *J (…) Jt Surg* 60 A 516–522

Stromberg, L & Dalén, N (1976a) (…) measurement of maximum torque capacity (…) long bones. *Acta orthop scand.* 47, (…)

Stromberg L & Dalen N (1976b) Influence (…) rigid plate for internal fixation (…) maximum torque capacity of long bones (…) *chir scand* 142, 115–122

Stromberg, L & Dalén N (1978) (…) cortical bone caused by rigid internal (…) plates. *Acta orthop scand* 49, 448 (…)

Wolff, J (1892) *Das Gesetz der Transfor(…) der Knochen* Hirschwalk Berlin.

Correspondence to Lennart Stromberg M D, Department of Surgery Karolinska Institutet, S(…) Stockholm 60, Sweden

op scand. 51, 223–229, 1980

ERIAL REACTION OF DIAPHYSEAL BONE ER TORSION

perimental Study on Dogs

Z, K ERIKSSON & L STRÖMBERG

nents of Orthopaedic, General and Experimental Surgery Karolinska Hospital and Department
gth of Materials and Solid Mechanics The Royal Institute of Technology, Stockholm Sweden

The formation of microcracks in entire canine diaphyseal bones under torsional loads was studied The acoustic emission technique was used to register the stress waves which were generated in the bones by crack

diaphyseal canine bone material

Key words acoustic emission, diaphyseal bone, elastic properties, experimental fractures, mechanical properties of diaphyseal bone, torsional testing, ultrasonic sound

Accepted 9 viii 79

nechanical behaviour of diaphyseal bone applied loads has been the subject of lerable interest in recent decades One of loading compact bone is assumed to ...ic deformation in macroscopical parts bone associated with dislocation on and motion (Currey 1970, .. 1970, Burstein et al 1972, 1973) authors (Robertson et al 1978) recently that the size of the plastic deformation around a crack tip in bovine bone is smaller than 0 02 mm This result that diaphyseal bone deforms only within almost microscopical

rter & Hayes (1977a, b) have shown that stiffness of compact bone specimens in flexural and in tension fatigue ic loading in torsion of the entire bone is mpanied by decreasing bone stiffness z et al 1979)

Microcracks have been observed in cortical bone by many authors (Frost 1960, Frost et al 1961, Pope & Outwater 1972, Carter & Hayes 1977a) The formation of microcracks is a phenomenon which reconciles the decreasing stiffness of a body and the elastic-cracking behaviour of the material (Broek 1974)

This raises the question as to the relationship between the non-linear deformation of entire diaphyseal bone (Netz et al 1979) and the appearance of microcracks in the bone material, a topic on which the present work was focused

MATERIAL

The test material consisted of nine fresh diaphyseal bones (tibiae and femora) with closed epiphyseal lines from healthy long legged dogs of varying breeds and of both sexes.

–6470, 80 020223—07$02.50 0

METHODS AND TEST EQUIPMENT

Torque

The torsion test equipment described by Stromberg & Dalén (1976) was used to twist the bones to fracture As the maximum torque capacity of diaphyseal bones is independent of the twist rate in the range 3–12° per second (Stromberg & Dalén 1976) the twist rate for the present investigation was fixed at 6° per second

Acoustic emission

The most common types of mechanical behaviour of materials under applied loads are deformation and fracture Many other phenomena, e g dislocation generation and motion, crack formation and/or growth, may also occurr in a material Acoustic detection of phenomena in materials is conveniently called acoustic emission or A E

A E is a non-destructive testing tool, used in the field of strength of materials and solid mechanics (Dunegan & Harris 1969) The A E in the loaded test body is detected by a sensing lead-zirconate-titanate (PZT) transducer The transducer converts low level stress w electrical signals The signals are filtrated, processed and registered on a reco

The character of stress waves generated location generation differs from that of waves from cracking Briefly processes associated with dislocations are uniform, those associated with cracking have a and sharp appearance (Tetelman 1971).

The A E technique thus permits of the generating process. D of different types of stress waves is, how delicate matter and must be left to expe considerable experience in the field

In the present experiments a sensing (type D 140 A Dunegan/Endevco, Capistrano, Calif, USA) connected amplifier, filter and processor unit recorder and a reset clock was used (202, 301, 402 respectively Dun (Figure 1)

TEST PROCEDURE

The test bones were attached to the machine grips as described by Stromberg &

TEST BONE
TRANSDUCER
PREAMPLIFIER
FILTER
PROCESS
RECORD

Figure 1 Simplified block diagram of acoustic emission (A E) system

The A.E. transducer was applied on the ...rface (Figure 2). Great care was taken to ...e transmission losses of the acoustic ... The A E within the range 140–500 kHz ...istered (maximum sensitivity at 220 kHz) ... reset clock was provided with a pulse ... selector which gave a choice of time ...on. The A.E counts were registered ...arily or with time resolution for the prior ... The time intervals used were 0 1 and 0 2

... 2 The sensing transducer for the acoustic ...m (A E) recordings firmly attached to the ...urface of a diaphyseal canine bone prior to ...al testing

...r to testing the torsion test machine and ...A.E equipment were calibrated The ...ication of the A E signals was adjusted to ...ize extraneous noise e g from the test ...ne and the total amplification used was ... dB

...ing testing the bones were twisted inwards ...cture and both torque and A E counts were ...aneously plotted as functions of applied ... on the multichannel light beam recorder ...lette 5651 ABEM Bromma, Sweden) ...ermore the A.E counts were transmitted ... to an audible range by means of an ... monitor (type 702, Dunegan/Endevco).
...ring the performance of the A E ...rations and in the following analysis of the ...dings obtained assistance was obtained from ... Stockholm Sweden.

...CULATIONS

...torque was given in newtonmeters and the ...mat on as the angle of twist in degrees.

The torsional deformation was divided into intervals of 1 2 degrees corresponding to 0 2 seconds. The point (B Figure 3) on the recorded torque-twist curves where the curve turned non linear was determined The deformation interval containing point B was considered as interval zero and called the "turnover interval" The deformation intervals in the linear range were indicated with negative numerals down to zero twist and the deformation intervals in the non linear range with positive numerals up to ultimate failure of the bone

A.E signals characteristic of crack formation and, or growth were nullified

Figure 3 Recorded torque-twist curve Torque is given in newtonmeters (Nm) and the twist in degrees A is the point of onset of torque A – B is the linear part of the curve and B C is the non linear part prior to final fracture of the bone at C

RESULTS

At all torsional tests a torque-twist curve was recorded comprising two characteristic parts (Figure 3) a linear starting from zero load which at a critical point turned to a non linear phase prior to the final fracture

The bones fractured within the range ~ 30–50 per cent of the total twist (Table 1)

A E signals characteristic of crack formation and/or growth occurred in bursts when audibly checked and on the recordings

Table 1 Maximum torque capacity (newtonmeters Nm) of nine fresh diaphyseal canine bones during [illegible] *and the* [illegible] *of deforma*[illegible]

Bone No	Maximum torque capacity (Nm)	The twist in the linear phase in per cent of the total twist
1	22 2	38
2	27 2	51
3	29 8	40
4	40 2	35
5	40 4	48
6	27 0	43
7	28 1	32
8	30 1	34
9	29 8	40

had a step-wise and sharp character with an increased frequency towards the ultimate failure of the bone

Signals characteristic of crack formation and/or growth were registered solely in the *non-linear* range of the torq[illegible] relationship and compared with the [illegible] in the linear range the difference was [illegible] cant *($P<0.01$)* *(Figure 4)*

In recordings obtained when the [illegible] was close to the fracture propagation p[illegible] appearance of the *A E signals* coincid[illegible] the onset of the non linear deformation [illegible] torque-twist curve (bones Nos. 1 2, 6, 7[illegible] *A E signals occurred* somewhat later [illegible] the non linear *deformation* when [illegible] transducer was away from the fractu[illegible] pagation path (bones Nos. 3 4 5 & 9).

In the tests when the *transducer* was [illegible] to the fracture propagation path the [illegible] stress waves were more intense It was [illegible] *possible to determine* the exact rela[illegible] between the intensity and the distance [illegible] the transducer *to the* fracture path, the [illegible] smaller the distance the more intense the [illegible] signals

Examples of two recordings are g[illegible] Figures 5 and 6

BONE No

LINEAR RANGE OF TORQUE TWIST CURVE

DEFORMATION INTERVALS

21 20 19 18 17 16 15 14 13 12 11 10 9 8 7 6 5-4 3 2 1

turn over

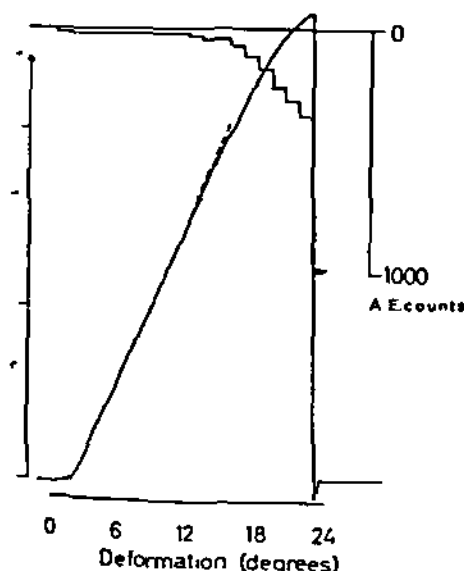
NON LINEAR RANGE OF TORQUE TWIST CURVE

DEFORMATION INTERVALS

2 3 4 5 6 7 8 9 10 11 12 13 14 15

1 2 3 4 5 6 7 8 9

Figure 4 Acoustic emission signals characteristic of crack formation and/or growth during t[illegible] *loading until final fracture of nine fresh diaphyseal canine bones The registered deforma*[illegible] *bones was divided into intervals of 1 2 degrees The "turnover interval" is the deformation* [illegible] *when the torque-twist curve turns non linear The "turnover interval" was fixed at zero and* [illegible] *numerals indicate intervals within the non linear range Negative numerals indicate interv*[illegible] *the linear range down to zero twist Acoustic emission signals characteristic of crack formatio*[illegible] *growth (marked with + signs) were registered solely in the non linear range of the torque-twi*[illegible]



5 A recording of the simultaneous registra- the torque-twist relationship and the acoustic m (A E) signals of a canine diaphyseal bone one No 6) The time resolution of this ing is 0 2 seconds i e the registered A E represent the foregoing 0 2 second time- al. Torque is given in newtonmeters (Nm) and n degrees

comitant with the torque-twist curve turning near, the A E counts increase towards final re of the bone

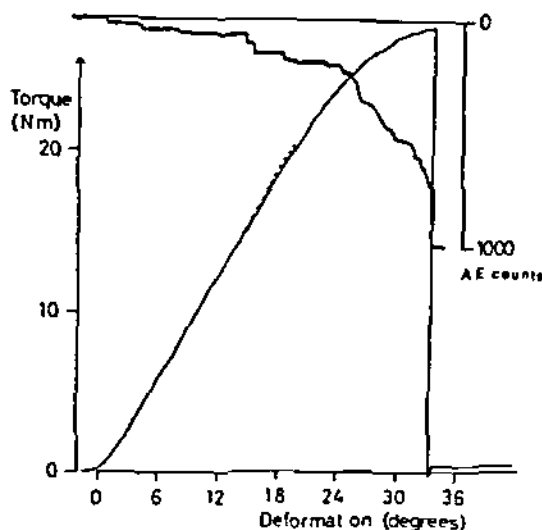


Figure 6 A recording of the simultaneous registration of the torque-twist relationship and the acoustic emission (A E) signals of a canine diaphyseal bone (test bone No 7) The A E counts are registered momentarily as a summation curve Torque is given in newtonmeters (Nm) and twist in degrees

Concomitant with the torque-twist curve turning non linear, the A E counts increase step-wise towards final fracture of the bone

USSION

ocracks in diaphyseal bones were ved by Rutishauser & Majno (1951) and presence was later confirmed by Frost) and Frost et al (1961) Recently, r & Hayes (1977a, b) observed ocracks in flexural and in tension fatigue d compact bones. On this basis they uded that "the postyield regime of bone is not evidence of bone icity (as suggested by Burstein et al), but the result of diffuse structural age" (Carter & Hayes 1977b) Loading of bone and of entire diaphyseal bones ces their stiffness (Carter & Hayes 1977a, etz et al 1979) The reduction of stiffness fficient to explain the non-linearity of the -deformation relationship of entire diaphyseal bone Strong indications that the non-linearity is essentially due to microcracking were put forward by Carter & Hayes (1977b) and Netz et al (1979)

The A E technique used in the present study allows detection of material events in a diaphyseal bone twisted to fracture An interesting feature is that the pattern of the A E signals depends to a large extent upon the generating process, e g the character of stress waves generated by dislocation generation and motion differs from that of stress waves from cracking A typical feature is dissipation and redistribution of the energy stored in the material The redistribution of energy is associated with propagation of stress waves in the material, which lend themselves to detection with acoustic techniques. The acoustic activity during deformation of the bones was registered in order to identify its origin

In the present study, the A E signals had a step-wise, sharp character and an increased frequency towards the ultimate fracture, characteristic of crack formation and/or growth (Tetelman 1971)

Plastic deformation in an axially twisted cylinder engages a uniformly distributed large volume of material and the observed frequency of A E counts is fairly independent of the location of the transducer (Mendelson 1968) In our test there was notable variation of the frequency of the A E counts between the bones The registrations with fewer A E counts were obtained when the transducer was placed away from the final fracture propagation path Previously, tests have shown that the ultrasonic sounds in compact bone are severely damped when propagating in other directions than the long axis of the bone (Sandberg 1978) This is assumed to be an effect of the internal architecture and material distribution of the bone, i e the orientation of the osteons in the longitudinal direction of the diaphyseal bone (Pope & Outwater 1974)

Diaphyseal bone is made up of heterogeneous materials The distribution of bone material and the distribution of inhomogeneities vary in different parts of the bone and with time The area of least resistance, where the fracture path will propagate, is unpredictable (Currey 1962) In the registrations where less A.E counts characteristic of cracking occurred there were no signals typical of dislocation generation either A E signals characteristic of formation and/or growth of cracks were registered only in the non linear range of the torque-twist curve Elastic plastic and elastic-cracking materials may in fact exhibit identical non linear loading relationships although the nature of the material behaviour is totally different in the two cases. The mode of behaviour of a material can thus not be uncritically inferred from a load-deformation relationship

Thus, by means of the A E technique we have registered A E signals which are associated with crack formation and/or growth, during non linear deformation of twisted diaphyseal bone. We consider the present results to be significant in favour of our previous postulation that non linear deformation of diaphyseal bone prior to ultimate failure is due to a gradual formation of microcracks. The assumption that the entire canine diaphyseal bone at all times behaves in accordance with an elastic cracking material is thus supported.

ACKNOWLEDGEMENTS

The authors express their sincere gratitude to Gosta Nystrom TRC, Stockholm for his assistance with the acoustic emission and for valuable help in analysing the [illegible]

for Bodily Injury in Personal Accident [illegible]

REFERENCES

Broek D (1974) *Elementary engineering mechanics* Nordhoff Int Publ, Leyden, Netherlands.

Burstein A H Currey J D Frankel V H Reilly D T (1972) The ultimate properties of bone tissue and the effects of [illegible] *Biomech* 5, 35–44

Burstein A H Reilly D T & Frankel V (1973) Failure characteristics of bone and tissue *Perspectives in biomechanical engineering* Univ Park Press, London.

Carter D R & Hayes W C (1977a) Compact bone fatigue damage *Clin Orthop* 265–274

Carter D & Hayes W C (1977b) Compact bone fatigue damage I Residual strength and stiffness *J Biomech* 10, 325 33[illegible]

Currey J D (1962) Stress concentrations in bone *Quart J Micr Sci* 103, 111 113

Currey J D (1970) The mechanical properties of bone *Clin Orthop* 73, 210–231

Dunegan H & Harris D (1969) Acoustic emission A new non-destructive testing [illegible] *Ultrasonics* 7, 160–166

Frost H L (1960) Presence of microscopic [illegible]

no in bone *Henry Ford Hosp Bull* **8**, 15
I M, Roth, H & Villanueva, A Z (1961) ncal characteristic of bone *Henry Ford Bull* **9**, 163–170
son, A (1968) *Plasticity Theory and ication* The MacMillan Comp, New
P, Eriksson, K & Stromberg, L (1979) -linear properties of diaphyseal bone *Acta op scand* **50**, 139–144
n, G (1978) TRC, Stockholm, Sweden sonal communication)
ki, K. (1970) Fracture of bone *J appl sics* **41**, 215–223
M H & Outwater, J O (1972) The ture characteristics of bone substances *J mech* **5**, 457–465
M H & Outwater, J O (1974) Mechanical properties of bone as a function of position and orientation. *J Biomech* **7**, 61–66
Rutishauser, E & Majno, G (1951) Physiopathology of bone tissue The osteocytes and fundamental substances *Bull Hosp Jt Dis (N Y)* **12**, 468
Robertson, D M, Robertson, D & Barrett, C R (1978) Fracture toughness Critical crack length and plastic zone size in bone *J Biomech* **11**, 359–364
Sandberg, S (1978) Swedish Testing and Inspection Company (STK) Sollentuna Sweden. (Personal communication)
Stromberg L & Dalen N (1976) Experimental measurement of maximum torque capacity of long bones *Acta orthop scand* **47**, 257–263
Tetelman A D (1971) Acoustic emission testing and microfracture processes *Mat Res Stand MTRSA* **11**, 13 16

pondence to Pelle Netz, M D Department of Orthopaedic Surgery Karolinska Sjukhuset, 01 Stockholm 60, Sweden

op scand 51, 231–238, 1980

INFLUENCE OF A LOCAL INJECTION OF
[TI]SOL ON THE MECHANICAL PROPERTIES
[T]ENDONS AND LIGAMENTS AND
INDIRECT EFFECT ON SKIN

[O]XLUND

[Departm]ent of Connective Tissue Biology, Institute of Anatomy,
[Univers]ity of Aarhus, Aarhus, Denmark

The effects of local cortisol treatment on the mechanical properties of muscle tendon and ligament in rats were studied In addition to the local effects, possible systemic effects as reflected in the properties of the skin, remote from the site of the injection, were investigated Two groups of rats were given cortisol injections, 20 mg/kg, every third day for 24 days In one of the groups the injections were given bilaterally around the peroneal tendons and in the other they were given into both knee joint cavities. Specimens from the peroneal tendons, the posterior cruciate ligament with bone attachments, and strips of skin from the dorsum, were tested in a materials testing machine The local treatment resulted in increased "tensile strength" of the peroneus brevis tendon and increased maximum load and stiffness of the peroneus longus tendon with no change in the collagen content in any of the samples The posterior cruciate ligament always broke at one of the two sites of attachment to the bone and the maximum load value at these points was decreased after local cortisol treatment The systemic effects of this local cortisol treatment on the skin were decreased thickness and fat content, increased collagen concentration and higher "tensile strength" and failure energy From this study it is concluded that local cortisol injections for 24 days increase the strength and stiffness of muscle tendons, but decrease the strength of the bone attachments of ligaments This treatment also results in a systemic effect which shows itself as increased strength of the skin remote from the site of the injections.

Key words biomechanics, bone, collagen, hydrocortisone, ligaments, tendons

Accepted 9 viii 79

[Ruptu]re of muscle tendons has been [rela]ted to glucocorticoid treatment [Bilater]al rupture of the Achilles tendons in [patien]ts on oral glucocorticoid therapy has [been r]eported by Cowan & Alexander (1961), [...1]961), Smaill (1961) and Melmed (1965) [Ruptu]re after local glucocorticoid treatment [has a]lso been reported Local injections [aroun]d the Achilles tendon (Lee 1957) and the patellar tendon (Ismail et al 1969) have thus resulted in rupture of the tendinous tissue

A previous study on the influence of systemic prednisone treatment on the biomechanical properties of rabbit muscle tendons (Oxlund et al 1978) showed that treatment for 14 days (2 mg/kg) resulted in increased tensile strength and stiffness of the

[00]01-6470 80 020231-08$02.50 0

Table 1 Body weights

	n	At start of injections	At sacrifice
Intact control	8	418 (40)	436 (38)
Peroneal tendons			
Saline injected	9	422 (39)	432 (32)
Cortisol injected	6	432 (36)	305*** (31)
Posterior cruciate ligament			
Saline injected	7	424 (44)	419 (42)
Cortisol injected	7	408 (25)	279*** (22)

Mean with s.d in parenthesis
***$2P < 0.001$ against saline injected control

Table 2 Water and collagen content of muscle tendons

	Water content (per cent)	Collagen content (mg mm)	
	Tendons of peroneus tertius and quartus	Tendon of peroneus brev	Tendon of peroneus long
control	56 7 (1 5)	0 22 (0 02)	0 14 (0 01)
injected rol	61 7* (0 9)	0 21 (0 01)	0 14 (0 01)
ol injected	59 1 (0 8)	0 18 (0 01)	0 13 (0 01)

with s e mean in parenthesis
0 05 against intact control

" strain parameters

g collagen per mm specimen length
. strain at maximum "stress" (Same
max
maximum "stress" – ultimate "tensile strength"
elastic stiffness – tangent of the angle n the linear region of the "stress"-strain and the x-axis
energy (A) energy measured as the area between the "stress"-strain curve and the x-axis to the point of breaking
statistical analysis the data were analyzed ormal distribution using the test of gorov-Smirnow, the G1-test and the G2-d for homogeneity of variances the F-max-test (Sokal & Rohlf 1969) Group means were thereafter compared by Student's *t* test and differences were considered significant if $2P < 0.05$

RESULTS

No differences in the body weights (Table 1) were observed between the groups at the start of injections At sacrifice the body weights of the cortisol injected rats had decreased, while no such effect occurred in the other groups The saline injections did not change the biomechanical properties of tendons, ligament or skin

Table 3 "Stress"-strain and load strain data from the muscle tendons

	n	$^{\varepsilon}\sigma_{max}$ (–)	σ_{max} (N/UC)	tan α (N/UC)	Failure energy (A) (N/UC)	F_{max} (N)	tan β (N)	F[illegible]
Peroneus brevis tendon								
Intact control	8	0 23	150	1063	2042	32 3	277	[illegible]
		(0 01)	(8)	(114)	(170)	(1 3)	(18)	[illegible]
Saline injected control	9	0 21	157	1219	1845	32 6	251	
		(0 01)	(7)	(72)	(151)	(1 7)	(9)	[illegible]
Cortisol injected	6	0 22	195*	1513	2512	35 2	274	[illegible]
		(0 02)	(15)	(128)	(357)	(1 4)	(19)	[illegible]
Peroneus longus tendon								
Intact control	7	0 19	193	1389	2076	26 2	188	[illegible]
		(0 01)	(16)	(140)	(139)	(1 7)	(16)	[illegible]
Saline injected control	9	0 17	177	1422	1762	24 2	198	[illegible]
		(0 01)	(15)	(103)	(185)	(1 4)	(12)	[illegible]
Cortisol injected	6	0 18	222	1850*	2220	28 6*	240	[illegible]
		(0 01)	(17)	(126)	(196)	(1 3)	(16)	[illegible]

Mean with s e mean in parenthesis
N = newton
UC = unit collagen i e mg collagen per mm specimen length
*2P < 0 05 against saline injected control

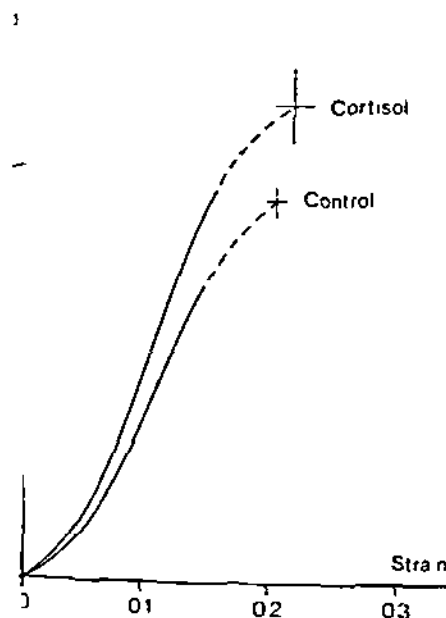
Local effects of cortisol injections

Tendons The water content of the tendons of peroneus tertius and quartus (Table 2) was increased after saline injections whereas no change occurred after cortisol treatment No differences were observed between the groups with regard to the collagen content of the peroneus brevis and longus tendons The maximum "stress" value for the cortisol treated peroneus brevis tendons was increased compared with tendons from the saline control group (Table 3) Figure 1 shows the "stress"-strain diagrams For the peroneus longus tendons (Table 3) the elastic stiffness (tan α) and maximum load value were increased for the cortisol treated group compared with the saline injected control group

Ligament For the posterior cruciate ligament the maximum load values of cortisol treated ligaments (16 1 ± 1 6 newton, mean ± s e mean) were decreased (2P < 0 05) compared with those of saline injected controls (22 8 ± 2 2 newton) (Figure 2) The failure of the bone-ligament bone specimens took place at one of the two bone attachments

Systemic effects of local cortisol injections

Skin The thickness of skin (Table [illegible] from rats injected with cortisol [illegible] peroneal tendons and from those injected [illegible] the knee joint cavity was decreased [illegible] differences in the water content of [illegible] (Table 4) were observed between the [illegible] The collagen concentration of skin (Ta[illegible] was increased and the amount of [illegible] fat was decreased for cortisol treated [illegible] compared with saline injected groups [illegible] mechanical testing of skin strips fr[illegible] group injected with cortisol around the [illegible] resulted in increased (2P < 0 01) str[illegible] maximum load (0 70 ± 0 02) and m[illegible] maximum load (51 0 ± 3 0 newton) c[illegible] with the saline injected control [illegible] (0 61 ± 0 02 and 37 6 ± 3 0 [illegible] respectively) Of the stress" stra[illegible] meters the maximum "stress (63[illegible] newton/mg/mm) and the failure [illegible] (2152 ± 101 newton/mg/mm) for [illegible] the cortisol treated group were [illegible] (2P < 0 001) compared with the saline control group (47 2 ± 2 6 newton [illegible] 1386 ± 79 newton/mg/mm, re[illegible]



1 "Stress"-strain diagrams for the · brevis tendon Control saline injected the tendons Cortisol 20 mg/kg injected 'he tendons (s e mean for the coordinates of ;imum point indicated by bars)

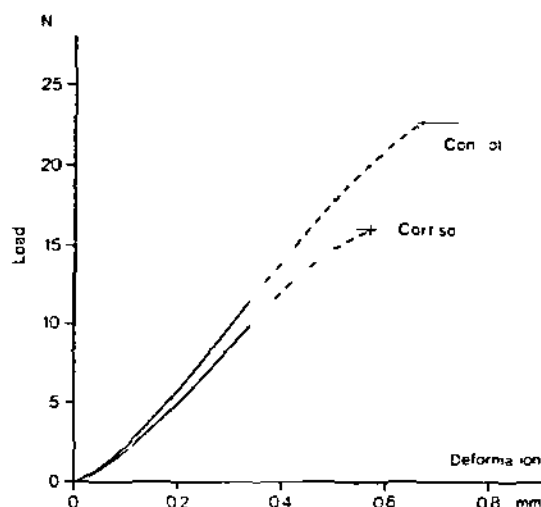


Figure 2 Load-deformation diagrams from the posterior cruciate ligament of rats Control saline injected into the knee joint cavities Cortisol 20 mg/kg into the knee joint cavities (s e mean for the coordinates of the maximum point indicated by bars)

Table 4 Thickness and composition of skin

	Thickness (mm)	Water content (per cent)	Collagen concen-tration (per cent of DDW)	Fat (per cent of DW)
control	1 91	57 6	76 8	16 2
	(0 05)	(0 3)	(1 9)	(1 3)
in around tendons				
'e injected ntrol	1 89	58 1	75 8	13 9
	(0 06)	(0 5)	(1 0)	(1 5)
isol injected	1 34***	56 8	83 6***	6 1***
	(0 03)	(0 4)	(1 3)	(0 6)
on into knee joints				
ne injected ntrol	1 91	57 3	75 9	17 2
	(0 05)	(0 4)	(2 1)	(1 8)
isol injected	1 39***	57 1	86 5**	6 0***
	(0 06)	(0 4)	(1 8)	(0 9)

; with s.e mean in parenthesis
·< 0 01 against saline injected control
·< 0 001 against saline injected control
lry weight
; dry defatted weight

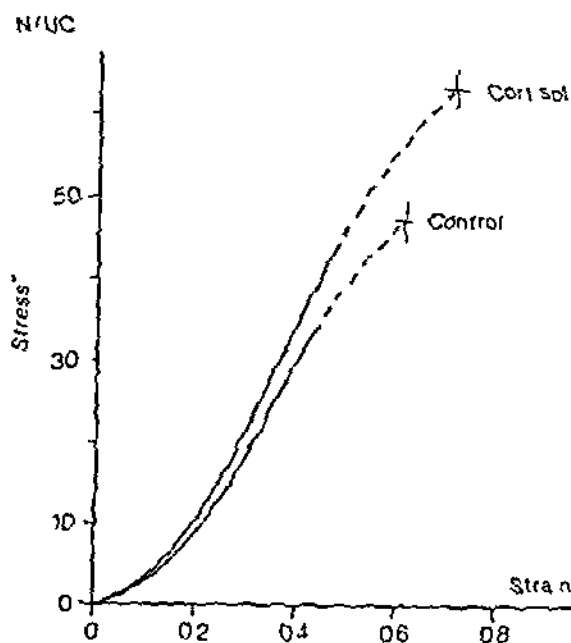


Figure 3 "Stress"-strain diagrams for skin Control saline injected around the tendons Cortisol 20 mg/kg around the tendons (s e mean for the coordinates of the maximum point indicated by bars)

(Figure 3) The mechanical parameters of skin strips from the group injected with cortisol into the knee joint cavity showed similar significant differences when compared with those of its control group

DISCUSSION

Glucocorticoids are commonly used in the treatment of tendon and joint injuries It has been suggested that this treatment may adversely affect the tendons and cause actual ruptures The present study was carried out to elucidate this question Local cortisol treatment for 24 days increased the strength and stiffness of muscle tendons with no change in their collagen content This is in agreement with Mackie et al (1974) who injected the extensor digitorum communis tendons of rabbits with either a suspension of betamethasone sodium phosphate or betamethasone acetate (0 1 mg/kg) twice a week for 35 days, and found reduced tendon weight and increased maximum stress values, whereas the stiffness of the tendons [illegible] influenced by the treatment Phelps [illegible] (1974) studied the effect of prednisolone injections into rabbit tendons but found no influence of treatment on the mechanical properties [illegible] ligament However, the hormone was [illegible] into the patellar tendon of the one side [illegible] the other side was used as the con[illegible] possible systemic effect of the injection may therefore have influenced [illegible] control The effects of universal [illegible] treatment for 2 weeks on the mechanical [illegible] perties of rabbit tendons (Oxlund et al [illegible] were increased "tensile strength" and [illegible] energy, i e in agreement with the [illegible] the present study

After cortisol injection into the joint cavity the strength of the cruciate ligament, measured as the [illegible] mum load of the bone-ligament unit, decreased This experimental [illegible] is different from that of the te[illegible] where the clamps were fastened direct[illegible] the tendon specimens. In the case of ligaments the condyles of the femur [illegible] were mounted in the clamps and the [illegible] as well as its bone attachments were [illegible] Here the failure of the specimen always [illegible] place at one of the two bone attach[illegible] Glucocorticoids inhibit the synthesis [illegible] collagen (Kuhn et al 1964 Kivirikko [illegible] 1965, Manthorpe et al 1974) and most [illegible] of glucocorticoids on bone are also [illegible] ent with an antianabolic [illegible] glucocorticoids may increase osteoclast[illegible] resorption and result in osteoporotic [illegible] The decreased mineralization is second[illegible] the increased bone resorption ([illegible] 1971, Silberberg 1971, Simmons [illegible] turnover of collagen in bone is much [illegible] than in tendon and therefore probably [illegible] higher in bone than in ligament Gerber (1960) estimated the turnover time of [illegible] in bone to be 4 and 40 days for a fast [illegible] slow compartment, respectively and the [illegible] tendon to be more than 110 days The[illegible] it may be hypothesized that the inhib[illegible] collagen synthesis and the increase [illegible]

-sm in bone during the 24 days of , treatment was sufficient to impair the ı of the bone attachments of the t

• present study the time period of local treatment of the experimental animals) days In the clinical reports cited teral rupture through the substance of ; tendons the patients had been ; with glucocorticoids for months or Cowan & Alexander 1961, Lee 1961, 1961 and Melmed 1965) In these ıe inhibited synthesis of collagen had esent for a much longer time period y have resulted in a decreased collagen and weakening of the tendons. - experiments, including mechanical of muscle tendons after long-term - treatment, are needed to clarify this studies of possible universal effects by the local cortisol treatment • pronounced changes in skin The d "tensile strength" and failure of dorsal skin are in agreement with s findings (Vogel 1974, Oxlund et al The cortisol preparation used was a suspension of hydrocortisone in saline commonly used for local nts in clinical practice The dose in esent study (20 mg/kg every 3rd as higher than doses commonly used cocorticoid treatment of tendon and njuries in man Differences between in the predominant corticosteroid d and in sensitivity of cells and their r systems, however, make it difficult e doses used in animal experiments to ised in clinical practice

n et al (1964) studied the incorpora- ¹⁴C glycine into rat skin collagen and that the conversion of soluble to ile collagen was accelerated after 9 f prednisone treatment The synthesis agen was retarded, neutral salt soluble n decreased, while the insoluble and ollagen was increased Kivirikko et al also found that cortisone had an abolic effect on the formation of soluble n but found no effect on the catabolism of the insoluble collagen of rat skin In the present study it was found that cortisol increased the strength of muscle tendons and skin Both load-strain and "stress"-strain parameters were increased "Stress"-strain parameters are load-strain parameters normalized to the collagen content of specimens, i e "functional cross-sectional area" The load-strain parameters are thus dependent on qualitative and quantitative changes such as thickness and width of specimens, while "stress"-strain parameters are dependent only upon qualitative changes in the tissue It may therefore be suggested that the cortisol induced increase in the strength of muscle tendon and skin are caused at least partly by an increased stability of the collagenous fibres. When the treatment is continued over longer time periods (months or years) and the dose of glucocorticoid is high the inhibited collagen synthesis may gradually result in a marked reduction of the collagen content This can weaken the tissue even though the cross-linking is increased and explain the findings in clinical reports The shorter the turnover time of the tissue the sooner the impairment of its strength may take place as a result of inhibited collagen synthesis during cortisol treatment. On the other hand, if the treatment time is short compared with the turnover time of the tissue, the increased stability may compensate for the decreased synthesis of collagen maintaining or even increasing the strength of the tissue

From this it can be concluded that local cortisol injections for 24 days increase the strength and stiffness of muscle tendons, but decrease the strength of the bone attachments of ligaments This treatment also results in a systemic effect shown in this study as an increased strength of skin

REFERENCES

An [illegible]

Cowan, M A & Alexander, S (1961) Simultaneous bilateral rupture of Achilles tendons due to triamcinolone *Brit med J* 1, 1658

Gerber, G, Gerber, G & Altman, K I (1960) Studies on the metabolism of tissue proteins *J biol Chem* 235, 2653–2656

Grant, R A (1964) Application of the autoanalyzer to connective tissue analysis The determination of hydroxyproline and hexosamine *J clin Path* 17, 685–686

Ismail, A M, Balakrishnan, R & Rajakumar, M K (1969) Rupture of patellar ligament after steroid infiltration *J Bone Jt Surg* 51-B, 503–505

Kivirikko, K I, Laitinen, O, Aer, J & Halme, J (1965) Studies with [14]C-proline on the action of cortisone on the metabolism of collagen in the rat *Biochem Pharmacol* 14, 1445–1451

Kuhn, K, Iwangoff, P, Hammerstein, F, Stecher, K, Durruti, M, Holzmann, H & Korting, G W (1964) Untersuchungen uber den Stoffwechsel des Kollagens *Hoppe-Seylers Z physiol Chem* 337, 249–256

Lee, H B (1957) Avulsion and rupture of the tendo calcaneus after injection of hydrocortisone *Brit med J* 2, 395

Lee, M L H (1961) Bilateral rupture of Achilles tendon *Brit med J* 1, 1829–1830

Mackie, J W, Goldin, B, Foss, M E L & Cockrell J L (1974) Mechanical properties of rabbit tendons after repeated antiinflammatory steroid injections *Med Sci Sports* 6, 198–202

Madsen, S T (1961) Dobbelsidig akillessenerruptur efter cortico-steroidbehandling *Nord Med* 66, 1504–1505

Manthorpe, R, Helin, G, Kofod, B & Lorenzen, I (1974) Effects of glucocorticoid on connective tissue of aorta and skin in rabbits *Acta endocr (Kbh)* 77, 310–324

Melmed, E P (1965) Spontaneous bilateral rupture of the calcaneal tendon d… therapy *J Bone Jt Surg* 47 B 104 1…

Oxlund, H, Fogdestam I & Viidik A … Wound healing in skin and its d… nective tissue response as in… cortisol *Surg Gynec Obst* (In press)

Oxlund, H, Manthorpe, R. & Viidik A … The biomechanical properties of … tissues in the rabbit as influenced b… term glucocorticoid treatment (In …

Phelps, D, Sonstegard D A & Matthews … (1974) Corticosteroid injection effects … biomechanical properties of rabbit … tendons. *Clin Orthop* 100, 345–348

Rundgren, Å (1974) Physical properties … nective tissue as influenced by … repeated pregnancies in the rat *Acta … scand*, Suppl 417, 1–138

Silberberg M & Silberberg R (197…) … hormones and bone *The biochem… physiology of bone* (Ed Bourne G H …) III, pp 401–484, Academic Press, N…

Simmons D J (1976) Comparative phys… bone *The biochemistry and physiology …* (Ed Bourne, G H) Vol IV pp … Academic Press New York

Smaill G B (1961) Bilateral rupture of … tendons. *Brit med J* 1, 1657 1658

Sokal R R & Rohlf, J (1969) *Biometry* … Freeman and Co, San Francisco

Viidik, A (1968) Elasticity and tensile str… the anterior cruciate ligament in rab… influenced by training *Acta physiol sc…* 372–380

Viidik, A (1973) Functional prope… collagenous tissues. *Int Rev Conn Tis…* (Ed Hall, D A & Jackson D S) Vol … 127–215 Academic Press, New York

Vogel H G (1974) Correlation between … strength and collagen content in rat skin … of age and cortisol treatment *Conn Tis…* 2, 177–182

Correspondence to Hans Oxlund, Anatomisk Institut C, Aarhus Universitet 8000 Århus C.

:RE PERIPHERAL VASCULAR DETERIORATION ·'LERODERMA

·· Report

POSNER, D HERNESS & S GREEN

nd Service of Mt Sinai Hospital Hospital for Joint Diseases and Lenox Hill Hospital
ork USA

A report of a case of long standing Scleroderma (Progressive Systemic Sclerosis) is presented to emphasize the severe consequences of vascular compromise in the hand The disease process is reviewed and is illustrated by the arteriographic findings in this patient

Key words arteriography, collagen disorder hand Progressive Systemic Sclerosis Scleroderma

Accepted 21 vi 79

following case of Scleroderma with ·involvement of both hands is presented der to demonstrate the severity of eral vascular damage

REPORT

year-old right handed female experienced ud s phenomenon of both hands at the age Within several years the etiology of this ion became obvious when she developed agia An esophogram and skin biopsy were tent with Scleroderma or Progressive nic Sclerosis

subsequent years, treatment included ilators, stellate ganglion blocks and a right al sympathectomy with no appreciable im- ment in the peripheral circulation Numerous alizations were necessary because of in- ns involving the digits of both hands. ·baric oxygenation was tried during one alization in an attempt to facilitate soft healing but to no avail Over a period of rs, multiple partial amputations of the right were necessary due to gangrene of the digits. ·ft hand was essentially spared (Figure 1)



Figure 1 The hands of a 61 year old female with Scleroderma

Within the year prior to this report the circulation to her left hand deteriorated rapidly The thumb together with both the index and middle fingers became gangrenous, requiring amputation. Subsequently, the ring and little fingers, the only remaining digits, also became gangrenous, together with necrosis of the skin over the thumb stump (Figure 2)

5470 80 020239–03$02.50/0

Cowan, M A & Alexander, S (1961) Simultaneous bilateral rupture of Achilles tendons due to triamcinolone *Brit med J* 1, 1658

Gerber, G, Gerber, G & Altman, K I (1960) Studies on the metabolism of tissue proteins *J biol Chem* 235, 2653–2656

Grant, R A (1964) Application of the auto-analyzer to connective tissue analysis The determination of hydroxyproline and hexosamine *J clin Path* 17, 685–686

Ismail, A M, Balakrishnan, R & Rajakumar, M K (1969) Rupture of patellar ligament after steroid infiltration *J Bone Jt Surg* 51-B, 503–505

Kivirikko, K I, Laitinen O, Aer, J & Halme, J (1965) Studies with ^{14}C-proline on the action of cortisone on the metabolism of collagen in the

Ku

G (1964) Untersuchungen uber den Stoffwechsel des Kollagens *Hoppe-Seylers Z physiol Chem* 337, 249–256.

Lee, H B (1957) Avulsion and rupture of the tendo calcaneus after injection of

l

Mackie, J W, Goldin, B, Foss, M E L & Cockrell, J L. (1974) Mechanical properties of rabbit tendons after repeated antiinflammatory steroid injections *Med Sci Sports* 6, 198–202

Madsen, S T (1961) Dobbelsidig akillessenerup-tur efter cortico-steroidbehandling *Nord Med* 66, 1504–1505

Manthorpe, R, Helin G, Kofod, B & Lorenzen, I (1974) Effects of glucocorticoid on connective tissue of aorta and skin in rabbits *Acta endocr (Kbh)* 77, 310–324

Melmed, E. P (1965) Spontaneous bilateral rupture of the calcaneal tendon during therapy *J Bone Jt Surg* 47 B

Oxlund H, Fogdestam I & Viidik, Wound healing in skin and its connective tissue response as influenced by cortisol *Surg Gynec Obst* (In press)

Oxlund, H, Manthorpe R & Viidik, The biomechanical properties of tissues in the rabbit as influenced by term glucocorticoid treatment. (In press)

Phelps, D, Sonstegard D A & Matthews (1974) Corticosteroid injection effects on biomechanical properties of rabbit tendons. *Clin Orthop* 100, 345–348.

Rundgren, Å (1974) Physical properties of connective tissue as influenced by repeated pregnancies in the rat. *Acta scand*, Suppl 417 1–138

Silberberg, M & Silberberg R (19..) hormones and bone *The biochemistry and physiology of bone* (Ed Bourne G H) III, pp 401–484 Academic Press, New

Simmons D J (1976) Comparative physiology of bone *The biochemistry and physiology* (Ed Bourne, G H) Vol IV pp. Academic Press New York

Smaill, G B (1961) Bilateral rupture of tendons. *Brit med J* 1, 1657 1658

Sokal, R R & Rohlf J (1969) *Biometry* Freeman and Co San Francisco.

Viidik, A (1968) Elasticity and tensile strength of the anterior cruciate ligament in rabbits as influenced by training *Acta physiol scand* 372–380

Viidik A (1973) Functional properties of collagenous tissues *Int Rev Conn Tissue* (Ed Hall D A & Jackson D S) 127–215 Academic Press, New York

Vogel, H G (1974) Correlation between strength and collagen content in rat skin of age and cortisol treatment. *Conn T* 2, 177–182

Correspondence to Hans Oxlund, Anatomisk Institut C, Aarhus Universitet 8000 Århus C



3 *The severity of the vascular damage* [...]*trated by arteriography*



Figure 4 The vascular pattern in a normal hand

faintly visible The superficial arch did [...]ommunicate with the radial artery and [...]was complete absence of vessels in the [...]ning ring and little fingers The vascular [...]n in a normal hand serves as a vivid [...]ast (Figure 4)

[...]MARY

[...]e report of long standing scleroderma is [...]nted to emphasize the severe conse[...]es of obliteration of the peripheral [...]ls The progressive deterioration of [...]ation in spite of vasodilators stellate [...]ion blocks surgical sympathectomy and [...]baric oxygenation is demonstrated [...]iography graphically illustrates the [...]nal arterial pattern in the surgical [...]men The reluctance in using the [...]matic tourniquet control during surgical [...]dements and amputations is obvious. [...]without tourniquet control further vascular damage and poor healing may occur The role of elective surgery in patients with Scleroderma and vascular impairment is minimal Diagnostic arteriograms reported to be commonly employed in the investigation of patients with Scleroderma in some institutions would appear to be hazardous since they may further compromise a diseased vascular system

REFERENCES

Dabich L Bookstein J Zweifler A & Zarafonetis C (1972) Digital arteries in patients with Scleroderma Arteriographic and plethysmographic studies. *Arch int Med* **130,** 708 714

Laws J W (1965) *Brachial arteriography in connective tissue disease Progress in clinical rheumatology* Ed Dixon A St J Little and Brown Boston

Rodman G P (1972) *Arthritis and allied conditions* Ed Hollander and McCarty p 962–1009 Lea and Febiger Philadelphia

[...]spondence to Martin A Posner M D 2 East 88th Street New York New York 10028 USA

hop scand. 51, 243–248, 1980

ERFASCICULAR TRANSPLANTATION
IEDIAN NERVE INJURIES

SIMESEN JENS HAASE & PER BJERRE

University Hospital, Department of Neurosurgery, Odense, Denmark

Twenty four patients operated upon within a 3 year period for complete median nerve transection using the microsurgical interfascicular transplantation technique were examined after a minimum of 3 years' observation Functional motoricity (M 3 or higher) was achieved by 83 per cent With the exception of one patient, all achieved protective tactile sensibility (96 per cent) The results were best for distal lesions in children and youths The outcome was just as satisfactory as that attained with epineurial suture carried out under ideal conditions. The method was found to be superior to epineurial end to-end suture in cases of nerve defects longer than 2 5 cm

Key words interfascicular transplantation, median nerve, microsurgery, nerve injuries, peripheral nerves

Accepted 10 vi 79

ormation of scar tissue in the suture line transected nerve restricts axonal ration Millesi et al (1972 a, b) and & Wallenborn (1972) demonstrated, in mental animal studies, that this scar was mainly formed by the epineurium hat it increased with tension in the line On the basis of these experiments introduced the microsurgical in- cicular nerve transplantation technique In ITT all epineurial tissue is ed from the nerve ends and nerve is carried out by insertion of free gous nerve grafts. ITT has been used Neurosurgical Department of Odense rsity Hospital since the Autumn of our initial experience has been hed elsewhere (Haase & Husby 1977)

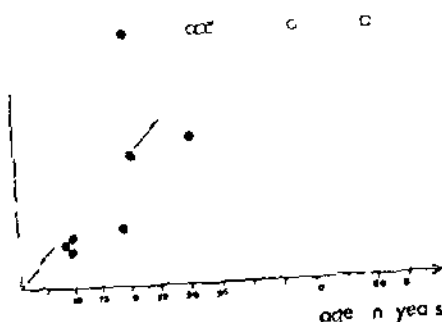
ENTS

year period from August 1972 to July 1975, tients (pts.) with total severance of the median n had suture carried out using the ITT method One patient (pt) failed to appear for the follow up study, and one had died of an unrelated disease Thus our material consists of 24 pts., 22 males and 2 females, who were observed for 3–5

[illegible]

joint (high) Nineteen were injuries from glass, two from saws, one from a knife one from high voltage electricity, and one was in connection with severe soft tissue contusion Four pts. had a complete transection of the ulnar n. and one of the medial antebrachial cutaneous n These nerve lesions were also treated with ITT One pt had a lesion of the radial artery three of the ulnar artery, and two of the brachial artery The brachial artery was reconstructed in both these cases Fourteen pts. had complicating tendon injuries of which 10 involved the tendon of the long palmar muscle, six of the flexor carpi radialis, three of the flexor carpi ulnaris, six of the superficial finger flexors, four of the deep finger flexors and four of the flexor pollicis longus. The pt with electrical burns had extensive loss of skin substance at the wrist which after revision was

6470 80 020243–06302.50 0



low lesion
low lesion ideal case
high o intermediate lesion

Figure 3 2 PD correlation with age
O Low lesion
● Low lesion "ideal" case
□ High or intermediate lesion

RESULTS

...t developed a slight wound infection ... no serious complications were ...ntered Two pts developed light ...sthesia in the region of the resected ...n Palpable neuromas of which 10 visible were found in 17 pts (71 per ... Eight neuromas were slightly tender to ...uch Only one pt had severe pain and ...ted her hand on an attempt to touch ...spiration was normal in six pts and ...t in six Protective tactile sensibility was ...in 23 pts Of the 20 pts with low nerve ...es, 10 achieved good restitution of the ...ry function (S 3+/S 4) Only one ...ed an unsatisfactory result (S 2+) 2 PD ...valuated for each finger and the results ...the 2nd finger plotted as a function of the ...ages (Figure 3) In the age group ≦ 20 (10 pts.) the 2 PD was ≦ 10 mm for 7 In the age group > 20 years (10 pts) ...were no pts with a 2 PD ≦ 10 mm ...difference was significant ($P=0.01$) ..., Fisher's exact test

...the four high and intermediate lesions ...pt attained good restitution (S 3+/S 4) ...reached S3 and one S 2 None achieved a ...le 2 PD

To test for motor recovery in the hand the abductor pollicis brevis muscle was assessed. Of the 20 low injuries 15 achieved function at the level of M 4/M 5 (75 per cent). Of the remaining five low injuries, two pts showed no signs of regaining motor function in the hand (M 2)

As regards the four high and intermediate injuries, two regained function between M 5 and M 3, and two did not show signs of regeneration (M 0/M 1)

As seen in Table 1 the sensory and motor recovery are not greatly influenced by the graft length

The pick up test registered the number of objects collected blindly in 20 seconds. Six pts collected 0 objects nine pts. between 1 and 4 and nine pts between 5 and 1... objects

Eleven pts were school children or students at the time of the follow up study None of them felt particularly hampered by the injury Three pts were unemployed Five felt impeded in their daily function but coped with their work as before the accident One had relinquished his occupation and three changed occupation. Finally, a 50-year-old pt. had been granted a middle-grade disablement pension because of the nerve injury

DISCUSSION

Great inhomogeneity of clinical materials makes strict comparison difficult Our results

Table 1 Graft length and recovery

Motor/sensory recovery	Graft length (mm) below 25	26–50	51–100
M 4 – M 5	1	12	3
S 3 + – S 4	1	9	1
M 3	1		
S 3	2	2	1
M 2		5	4
S 2 +	2		
	1		
M 0 M 1			
S 2			

Forrest, W J (1967) Motor innervation of human thenar and hypothenar muscles in 25 hands A study combining electromyography and percutaneous nerve stimulation *Canad J Surg* **10**, 196–199

Haase, J & Husby, J (1977) Suturering af nervus medianus og ulnaris laesioner Epineural sutur sammenholdt med interfascikulaer transplantation *Ugeskr Laeg* **139**, 996–1002

Hudson R & Hunter D (1977) Timing of peripheral nerve repair Important local factors *Clinical neurosurgery* (Ed Keener, E B) The Williams & Wilkins Company, Baltimore

Husby, J & Haase, J (1973) Peripheral nerve regeneration, sudomotor print test with iodine impregnated paper *Surg Neurol* **1**, 173–174

Kankaanpaa, U & Bakalim, G (1976) Peripheral nerve injuries of the upper extremity Sensory return of 137 neurorrhaphies *Acta orthop scand* **47**, 41–45

Kimura, J, Murphy, M J & Varda D J (1976) Electrophysiological study of anomalous innervation of intrinsic hand muscles *Arch Neurol* **33**, 842–844

Lister, G (1977) *The hand Diagnosis and indications* Churchill Livingstone, Edinburgh

Medical Research Council (1943) Aids to the investigation of peripheral nerve injuries Her Majesty's Stationery Office, London

Michon J (1975) Nerve suture today *Traumatic nerve lesions of the upper limb* (Ed Michon, J & Moberg, E) Churchill Livingstone, Edinburgh

Millesi H (1975) Treatment of nerve lesions by fascicular free nerve grafts *Traumatic nerve lesions of the upper limb* (Ed Michon, J & Moberg, E) Churchill Livingstone, Edinburgh

Millesi, H, Berger, A & Meissl, G (1972a) Experimentelle Untersuchungen zur Heilung durchtrennter peripherer Nerven *Chir plastica* **1**, 174–206

Millesi H, Meissl G & Berger, A (1972b) The [illegible]

median, ulnar and radial nerves *J Bone Jt Surg* **58 A** 209–218

Moberg E (1975) Future hopes for the management of peripheral nerve [illegible] *Traumatic lesions of the upper limb* (Ed Michon J & Moberg E) Churchill Livingstone Edinburgh

Nicholson, O R & Seddon, H J (19[illegible]) [illegible] repair in civil practice Results of treatment of median and ulnar nerve lesions *Brit M J* [illegible] 1065–1071

Önne L (1962) Recovery of sensibility and sudomotor activity in the hand after nerve suture *Acta chir scand*, Suppl 300 [illegible]

Orf, G (1978) Critical resection length and gap distance in peripheral nerves *Acta neurochir (Wien)*, Suppl 26 (diss.)

Rank, B K, Wakefield A R & Hueston [illegible] (1973) *Surgery of repair as applied to hand injuries* 4th edition Churchill Livingstone, Edinburgh

Rowntree, T (1949) Anomalous innervation of the hand muscles *J Bone Jt Surg* **31 B** [illegible]

Sakellarides H (1962) A follow-up study of peripheral nerve injuries in the upper extremity in civilians *J Bone Jt Surg* **44 A**, 140–[illegible]

Samii M & Wallenborn R (19[illegible]) [illegible] Experimentelle Untersuchungen über den Einfluss der Spannung auf den Regenerationserfolg nach Nervennaht *Acta neurochir (Wien)* [illegible] 87–110

Samii, M (1975) Modern aspects of peripheral and cranial nerve surgery *Advances and technical standards in neurosurgery* (Ed Krayenbühl H) Springer Verlag [illegible] York

Seddon H (1975) *Surgical disorders of the peripheral nerves* Churchill Livingstone, Edinburgh

Smith, J W (1977) Newer techniques of peripheral nerve repair *Clinical neurosurgery* (Ed Keener, E B) The Williams & Wilkins Company, Baltimore

Stopford J S B (1918) The variation in distribution of the cutaneous nerves of the hand and digits *J Anat (Lond)* **53**, 14–25

Sunderland S (1972) *Nerves and nerve injuries* Churchill Livingstone London

Correspondence to Jens Haase Neurokirurgisk afd U, Odense Sygehus 5000 Odense C, Den[illegible]

. REDUCTION AND PIN FIXATION OF SEVERELY ?LACED SUPRACONDYLAR FRACTURES OF THE 4ERUS IN CHILDREN

DANIELSSON & HOLGER PETTERSSON

.tments of Orthopaedic Surgery and Diagnostic Radiology, Malmo
.l Hospital, (University of Lund), Malmo, Sweden

Out of 87 displaced supracondylar fractures of the humerus in children, 17 were treated by open reduction and internal fixation, in eight cases because of vascular complications (with or without neurological complications) and in nine cases after unsatisfactory closed reduction In the eight cases with vascular impairment, evacuation of the haematoma reduction of the fracture and division of the fascia of the forearm caused a return of the radial pulse Median nerve paralysis, in the four cases with neurological complications as well, recovered within 7 months Fractures fixed with one pin only redislocated and needed an additional reduction—this procedure was associated with impairment of the range of motion In spite of the selection of the most severe cases for surgery, the end result was excellent in all cases expect one and considerably better than previous results of closed reduction Rotational deformity, however, did not decrease with age and growth

Key words humerus, neurovascular complication, pin fixation, supracondylar fracture

Accepted 1 x 79

management of severely displaced icondylar fractures of the humerus in ren still remains a challenge More or serious complications, such as the Volk-n's ischaemia, nerve injuries, residual rota-l deformities, cubitus varus and valgus yositis ossificans may occur as a result of fracture and/or the treatment (Blount , Tachdjian 1972, Spitzer & Paterson) Various methods of treatment have recommended in the past, such as closed pen reduction with external or internal ion or a combination of both, and skin or tal traction (Tachdjian 1972) Most eons are still of the opinion that this ure should almost never be dealt with by reduction and/or internal fixation unt 1955) Contrary to this opinion, Swenson (1948), Gruber & Hudson (1964), Jones (1967), Carcasonne et al (1972), Childress (1972), Fowles & Kassab (1974), Nassar & Chater (1976), Shifrin et al (1976) and Arino et al (1977) recommend percutaneous pinning or open reduction and internal fixation

The purpose of this investigation was to study the results of open reduction and internal fixation in a series of cases where conventional, conservative methods had failed

PATIENTS

In 1972–1977 altogether 87 cases (56 boys and 31 girls) of dislocated supracondylar fracture of the

-6470 80 020249-07502 50 0

Table 1 Operated cases classified according to sex, fracture side, type of trauma and type of [illegible]

		Boys 10	Girls 7		
Fall from height + run over	1			13	Extension type
Fall from height	14	17		3	T-type
Fall on level ground	2			1	Flexion type + fracture of humerus, radius, ulna
		6 Right side	11 Left side		

humerus shaft were recorded in the Department of Orthopaedic Surgery, Malmö Of these, 17 were treated by open reduction and internal fixation The age of the operated cases was 9 ± 3 years–significantly higher (0 01 > P > 0 001) than for the unoperated cases (7 ± 3) The distribution of the operated fractures is shown in Table 1 and the *circumstances which precipitated the surgical procedure in Table 2 Those cases in whom the* radial pulse could not be felt with certainty in any position of the elbow joint – not even after an attempt at closed reduction – were considered to have a vascular complication

Surgical procedure

[illegible]

medial intermuscular septum immediately distal to the medial epicondyle of the humerus and in those instances in which the neurovascular bundle was in*spected, extending along a curved line on the anterior aspect of the forearm In addition, a short* incision was made over the lateral epicondyle for the insertion of a lateral pin The ulnar nerve was localized, the fracture haematoma removed and the fracture reduced with a visual check being made of the reduction The fracture was then stabilized with pins, one from the medial and one from [illegible] epicondyle, extending into the proximal [illegible] In three additional cases, the [illegible]

[illegible]

seven of the cases the artery was [illegible] between the proximal fragment of the [illegible] the lacertus fibrosus, whereas, in one [illegible] fracture haematoma alone appeared to [illegible] the compression In several instances, the [illegible] wall showed signs of external [illegible] However, vascular surgery was unnecessary [illegible] all cases arterial pulsation returned [illegible] minutes after the decompression

External fixation in plaster was applied [illegible] weeks The pins were removed after [illegible] weeks

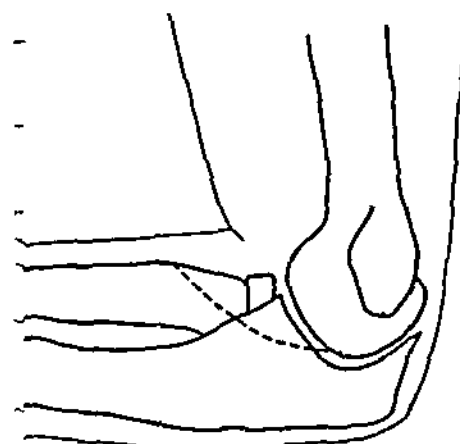
In the three cases, where the fracture [illegible] with one pin only rotational deformity [illegible] These cases were reduced again within [illegible] time by closed reduction

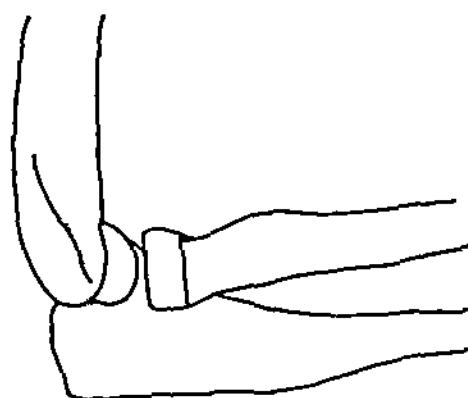
METHODS

The patients were examined clinically [illegible] radiologically 1–6 years after the injury [illegible]

Table 2 Operated cases classified according to reason for surgery

Vascular complication + paresis of the median nerve	4	3 total paresis 1 partial paresis
Vascular complication	4	
Unacceptable deformity after closed reduction	9	5 extension type 3 T-type 1 flexion type + fracture of humerus, radius, ulna





Ulnar side Radial side

1 Surgical approach
incision
---- extended incision for exploration of the neurovascular bundle and the fascia of the forearm

…t angulation were determined exteriorly …ng to the contralateral elbow as normal …logically the ossification of the epiphyses and …hape of the bones were studied on standard …-posterior and lateral projections of both …s. The degree of rotational displacement along …ngitudinal axis of the humerus was determined …ing the radiological method described by …an (1961, 1975) and Lonnroth (1962) Thus, by …g a series of exposures, the true lateral projec… …f the plane through the posterior surface of the …shaft of the humerus (the former proximal …ent) and the true lateral projection of the …les (the former distal fragment) were identi… The degree of tilting between the two pro…ns indicated the rotation An analysis of the …etic movement of the radial capitulum …ated the direction of rotation (Figure 2) …the following inward rotation is defined as …on causing a volar dislocation of the radial …le and outward rotation as that causing a …l dislocation Since there may be a naturally …ring rotation between the plane through the …les and the plane through the posterior surface … distal end of the shaft of the humerus, the …ured elbow was also examined in the same …er Residual rotational displacement in the …d elbow was defined as deviation from the …al rotation on the contralateral side in the same …nt.

RESULTS

There were no postoperative vascular complications In the one case of interosseous branch paralysis—partial median nerve injury the function was restored within 3 weeks, whereas the three cases of total median nerve paralysis recovered within 4, 6 and 7 months, respectively The range of motion in the elbow joint was gradually restored and the deviation from normal, at the time of the follow-up examination was only minor (Table 3) Pronation and supination normalized within 3 months after the injury


A significant varus deformity of the elbow was only observed in a few cases (Table 4) The most marked residual displacement and restriction in range of motion were observed in two of the three patients whose fractures had been fixed with one pin only and had subsequently required additional reduction Radiologically, dislocation of the distal fragment in the lateral, antero-posterior or longitudinal direction was negligible in all




a



b



c



d

Figure 2 Five-year-old girl with a dislocated supracondylar fracture of the left elbow (a and b). The [illegible] partial paralysis of the median nerve (the interosseous branch) and the radial pulse could not be [illegible] even after an attempt at closed reduction

At operation there was a large haematoma the brachial muscle was lacerated and the artery [illegible] median nerve were compressed between the proximal bone fragment and the lacertus fibrosus [illegible] evacuation of the haematoma and reduction and pin fixation of the fracture (c and d) arterial pulse returned

The median nerve paralysis recovered within 3 weeks

Three months after injury pronation and supination were normal and flexion and extension were [illegible] 10 degrees each

At examination 1 year later extension was restricted by 5 degrees in all other respects the [illegible] clinically normal



e



f



g

cases Examination of the natural rotation in the uninjured elbow showed an inward rotation in all cases (5° in eight cases, 10° in seven cases and 15° in two cases) Related to this, the residual rotational displacement in the operated (injured) elbows was minor (Table 5) In some patients, the condylar region was slightly deformed, but the joint surfaces were always congruent and smooth (Figure 2) Accelerated ossification of the epiphyses of the elbow joint (not only of the distal humerus) was also noted In those patients in whom the ossification of the epiphyseal plates had ceased, the condylar part of the humerus as well as the proximal parts of the radius and the ulna were somewhat larger than on the uninjured side There was no relationship between the rotational displacement and the follow-up time (Figure 3)

Table 3 Restriction of the range of flexion and extension in the fractured elbow as compared with contralateral side

	0°	5°	10°	15°	20°	25°	30°	35°	Number of observations
3 months	–	1	2	1	2	1	5	3	15
6 months	–	6	4	1	1	–	1	–	13
1–6 years	9	3	3	2					17

DISCUSSION

In spite of the fact that only the most severe cases of supracondylar fracture are included in this series, the results are better than those previously reported after closed reduction or traction Varus deformity exceeding 10° occurred in a series reported by Lund et al (1976), in four out of 22 cases treated with traction and in eight out of 16 cases treated with closed reduction and plaster fixation, as compared with one out of 17 in the present series Also, in comparison with a series of 545 fractures of Henriksson (1966), which included also 138 non-displaced supracondylar fractures our results are better (Table 6)

One pin only provided insufficient fixation and led to an increase in rotational displacement requiring an additional reduction and resulting in decreased range of motion Furthermore, this study does not support the statement of Vahvanen & Aalto (1978) that rotational displacement decreases slowly with time

It is recommended that failure to feel the radial pulse or other such signs of a compartment syndrome indicate that open reduction to relieve the pressure should always be undertaken, whereas nerve injury or an inadequate closed reduction are not such definite indications for surgery The surgical

Table 4 Varus angulation of the fractured elbow at follow-up as compared with the contralateral side

	0°	5°	10°	15°
Number of cases	14	1	1	1

Table 5 Residual rotational displacement in fractured elbow at follow up as compared with contralateral side

	Inward 10°	Inward 5°	Neutral –	Outward 5°
Number of cases	3	9	4	1




Figure 3 Residual rotational displacement in relation to time after injury

Table 6 Classification at follow-up according to Henriksson's criteria

	Excellent	Good	P
Henriksson (1966)	396	114	
Present study	16	1	

ire should include the use of a tourni d a medial incision is recommended ases of neurovascular complications cision should be extended to the aspect of the forearm A small lateral i is sufficient for pinning the lateral lyle The ulnar nerve should be local e haematoma removed and the fracture l with visual inspection and then fixed pins – note that the cortex is thin A d suture may be attached to the head of is to make it easier to locate them at a age If the radial pulse is not palpable the tourniquet is removed the vessels be explored and the fascia of the anterior of the forearm divided Plaster and pins removed 4 weeks after operation

RENCES

V L Lluch E E Ramirez A M Ferrer J
iriguez L & Baixauli F (1977) Percutaneous tion of supracondylar fractures of the nerus in children *J Bone Jt Surg* 59 A –916

sults of operative treatment of severe racondylar fractures of the elbow in ldren *J paediat Surg* 17, 676–679

ess, H M (1972) Transarticular pin fixation supracondylar fractures at the elbow in ldren *J Bone Jt Surg* 54 A 1548 1552

s, J W & Kassab M T (1974) Displaced racondylar fractures of the elbow in ldren A report on the fixation of extension d flexion fractures by two lateral rcutaneous pins. *J Bone Jt Surg* 56-B 0–499

Gruber M A & Hudson O C (1964) Supracondylar fracture of the humerus in childhood *J Bone Jt Surg* 46-A 1245–1252

Henriksson B (1966) Supracondylar fracture of the humerus in children. *Acta chir scand*, Suppl 369

Holmberg L (1945) Fractures of the distal end of the humerus in children *Acta chir scand* Suppl 103

Jones K G (1967) Percutaneous pin fixation of fractures of the lower end of the humerus. *Clin Orthop* 50, 53 69

Lonnroth H (1967) Measurement of rotational displacement in supracondylar fractures of the humerus. *Acta radiol (Stockh)* 57, 65 70

Lund Kristensen J & Vibild O (1976) Supracondylar fractures of the humerus in children *Acta orthop scand* 47, 375–380

Nassar A & Chater E (1976) Open reduction and Kirschner wire fixation for supracondylar fracture of the humerus *J Bone Jt Surg* 58 B 135

Norman O (1961) Rotationsbestamning vid supracondylara frakturer *Nord Med* 66, 1152

Norman O (1975) Roentgenological studies on dislocations in supracondylar fractures of the humerus *Ann Radiol* 18, 395–399

Shifrin P G Gehring H W & Iglesias, L J (1976) Open reduction and internal fixation of displaced supracondylar fractures of the humerus in children *Orthop Clin N Amer* 7, 573–581

Spitzer A G & Paterson D C (1973) Acute nerve involvement in supracondylar fractures of the humerus in children *J Bone Jt Surg* 55 B 227

Swenson A L (1948) The treatment of supracondylar fractures of the humerus by Kirschner wire transfixation. *J Bone Jt Surg* 30 A 993–997

Tachdjian M O (1972) *Pediatric orthopedics* W B Saunders Co Philadelphia–London–Toronto

Vahvanen V & Aalto K (1978) Supracondylar fractures of the humerus. *Acta orthop scand.* 49, 225–233

spondence to Lars Danielsson M D Department of Orthopaedic Surgery Malmo General tal S-214 01 Malmo Sweden

op scand 51, 257–262, 1980

)VERY FROM PRIMARY SHOULDER DISLOCATION ITS COMPLICATIONS

ILA, O KIVILUOTO, H JAROMA & A SUNDHOLM

nent of Orthopaedics and Traumatology, University Central Hospital Helsinki, Finland

Out of 226 patients with primary shoulder dislocation followed up for 1 year, 57 (25 per cent) had one or more complications There were 25 plexus lesions, 19 axillary nerve lesions and 26 rotator cuff ruptures

The 127 patients over 50 years of age (56 per cent) plus 53 patients under 51 years were immobilized for 1 week with a mitella The remaining 46 patients under 51 years were immobilized for 3 weeks

Recovery was ascertained in terms of the time needed to regain normal mobility of the shoulder, the disappearance of signs of nerve lesions and the length of the sick leave period A total of 163 (72 per cent) of the patients achieved normal mobility in 3 months, but 42 shoulders (19 per cent) were still not fully mobile after 1 year The mobilization was significantly retarded by advanced age, long immobilization, long "non-reduced period", rotator cuff rupture, and a severe primary dislocation Students and office workers regained normal mobility of the shoulder in a shorter time than manual labourers ($P < 0\,001$) or persons in retirement ($P < 0\,001$) and manual labourers required a longer sick leave period than office workers ($P < 0\,001$) There was no difference regarding recovery from axillary nerve or plexus lesions, but the patients under 51 years with nerve lesions obtained a more complete cure than the older patients ($P < 0\,05$) All patients with complications (except one patient with a rotator cuff rupture) returned to work during the follow-up period

Key words nerve lesions recovery of function rotator cuff rupture, shoulder dislocation

Accepted 29 vi 79

ore severe trauma causing primary der dislocation and a longer "non-ed period" imply a greater frequency of ry nerve and plexus lesions and rotator ruptures (Pasila et al 1978) The iosis of nerve lesions depends on the e of damage to the nerve fibrils which ot initially be assessed clinically Assmus einel (1976) have recommended needle ; and nerve conduction tests for es-shment of the extent of nerve damage in lder injuries. They reported that partial us of the axillary nerve frequently vered in 2–6 weeks and in complete paralysis spontaneous re-innervation could be expected to ensue within 1 year, although the prognosis was poor in patients showing no recovery 8–10 weeks after injury (Assmus & Meinel 1976)

Total loss of axillary nerve function results in weak abduction, although a normal range of active abduction may be attained (London 1971) On the other hand, when there is loss of plexus function the patient may be prepared to accept an artificial limb (Yeoman & Seddon 1961) Rupture of the rotator cuff gives rise to persistent insufficiency of the shoulder (Codman 1934) The extent of the

6470 80 020257–06502 50 0

rupture is only measurable when the rotator cuff is exposed Tears of more than 2 cm cause considerable disability (Bakalim & Pasila 1975) Residual stiffness in the shoulder is seen in older patients after dislocation (London 1971)

A follow-up for 1 year, from the time of injury, of patients with primary shoulder dislocation was arranged Functional restoration of the shoulder and recovery after axillary nerve and plexus lesions and rotator cuff ruptures were recorded

PATIENTS

This study comprises 238 primary shoulder dislocations treated during the period 1 9 1971 to 31 12 1976 in the Department of Orthopaedics and Traumatology, University Central Hospital, Helsinki, Finland

One investigator attended to the follow up of 226 patients over a period of 1 year Initially, the patients visited the Physical Medicine Department weekly and later, at intervals implied by the treatment There were 126 men and 100 women, 127 (56 per cent) were older than 50 years. Ninety-seven patients were manual labourers, 45 office workers 71 in retirement, and 13 were students

The mechanism of trauma could be reconstructed in 142 primary dislocations Patients with a "non-reduced period" in excess of 36 hours were excluded from the study

METHODS

Axillary nerve and plexus lesions were diagnosed by the location of paretic muscles and defects of skin sensitivity No quantitative measurements of the severity of the nerve lesions were made

In the 127 patients (56 per cent) over 50 years of age connections between the articular cavity and the subacromial bursa were common (as a result of slowly progressing degeneration) When the trauma resulting in dislocation rendered such shoulders painful the diagnosis was postponed a few weeks so that the initial pain could subside and it was only made in rotator cuff perforations with a persistent clinical picture of rotator cuff rupture (Pasila et al 1978) Thus 57 patients (25 per cent) had 70 complications in all 25 plexus lesions, 19 axillary nerve lesions and 26 rotator cuff ruptures One single lesion was found in 45 shoulders, and 12 shoulders presented [illegible] one complication

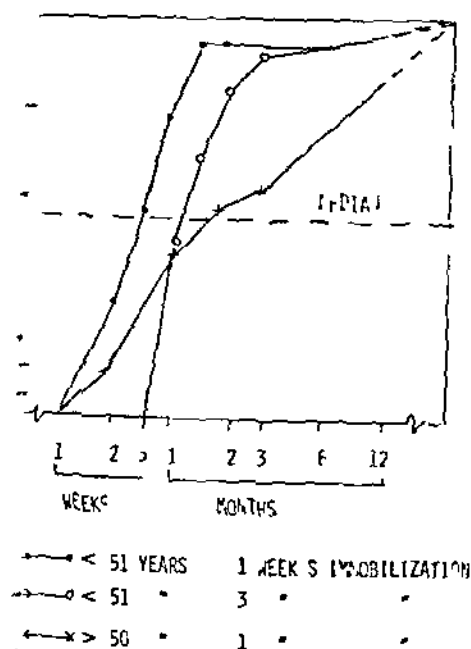
All 127 shoulders of patients over 50 [illegible] 53 shoulders of younger patients were [illegible] for 1 week with a mitella. The [illegible] shoulders of patients under 51 years [illegible] mobilized for 3 weeks by tying the affected [illegible] the side of the thorax At the end of [illegible] mobilization period the patient was [illegible] mobilize his shoulder If this presented [illegible] a physiotherapist (the same for all the [illegible] supervised exercises The mobility of the [illegible] was regarded as normal if in internal rot[illegible] the shoulder the patient could touch the [illegible] area, and if the limitation of outward rot[illegible] active flexion were both not more than 10

Recovery from axillary nerve and p[illegible] was assessed by the disappearance [illegible] symptoms of nerve lesion and the recovery [illegible] sensation and muscle force A nerve [illegible] regarded as cured when any slight res[illegible] muscle force and skin sensation did [illegible] convenience the patient

RESULTS

Mobilization was slow and incomplete [illegible] 127 patients over 50 years (Figure 1) [illegible] group, 38 patients failed to attain [illegible] mobility of the shoulder within 1 year [illegible] corresponding number of stiff shoulders [illegible] patients under 51 years was two out of [illegible] patients immobilized for 1 week and [illegible] two of the 46 patients immobilized [illegible] weeks The increase in the immob[illegible] period from 1 to 3 weeks in patients [illegible] years of age caused the median time [illegible] for recovery of normal mobility [illegible] shoulder to be lengthened by 2 weeks ([illegible] to 5 weeks) This difference is sta[illegible] highly significant ($P < 0\ 001$). The [illegible] time needed for normal mobility [illegible] regained was 4 weeks in 99 patients [illegible] years, and 7 weeks in the 127 older [illegible] a difference which is also statistically significant ($P < 0\ 001$)

The median time needed for [illegible] mobility of the shoulder to be [illegible] approximately 1 year in the 26 shoulders [illegible] rotator cuff ruptures, 51 days in [illegible] shoulders with nerve lesions and 2[illegible]



1 Time required to regain normal mobility shoulder in three treatment groups The atisfactory recovery was made by young s with a short immobilization period

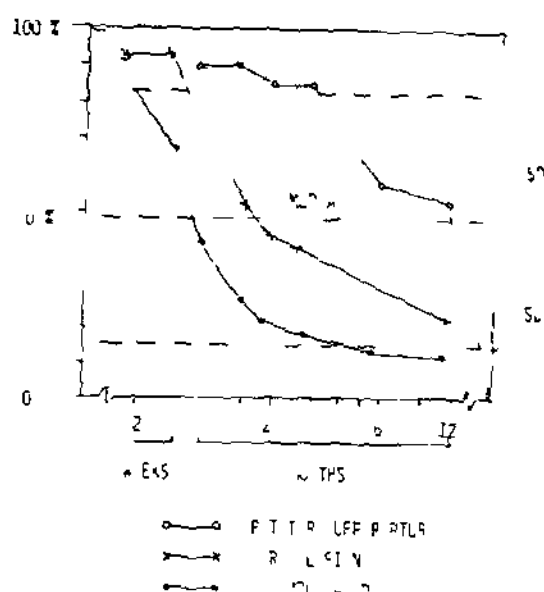


Figure 2 Time required to regain normal mobility in shoulders free of complications and in those with rotator cuff ruptures and nerve lesions Mobilization of shoulders with rotator cuff ruptures took the longest time ($P < 0.001$)

i9 uncomplicated shoulders (Figure 2) ifference between the 1-year and 51 day s is highly significant ($P < 0.001$), but is no statistically significant difference en the 51- and 27-day groups

rate of mobilization was equal, with a n of 30 days, in the following three s (1) 87 dislocations with a "non-d period" of less than 1 hour, (2) 81 1–3 hours and (3) 44 with a 3–12 hours reduced period' (Figure 3) With a reduced period" longer than 12 hours (in dislocations) the median period for ery of normal mobility was 4 5 months. difference between 30 days and 4 5 hs is statistically highly significant 0 001)

e 15 patients who had fallen from a t represented the most violent anism of dislocation in this study ure 4) The median time needed for lization in this group was 60 days, pared with 30 days in the case of 92 shoulders dislocated by falling (not from a height) and with 24 days in 35 shoulders dislocated by torsion The difference between 60 and 30 days is statistically highly significant ($P < 0.001$) and that between 30 and 24 days is significant ($P < 0.01$)

The median duration of sick leave was 16 days for 45 office workers and 30 days for 97 manual labourers. The difference is statistically highly significant ($P < 0.001$) (Figure 5) Nine office workers (20 per cent) and 3 manual labourers (3 per cent) required no sick leave at all All 45 office workers returned to work within 3 months, and 95 of the 97 manual labourers returned to work within 9 months. The two permanently disabled manual labourers were over 60 years of age, one had four redislocations and the other had a rotator cuff rupture

Nine out of the 25 plexus lesions, and six out of the 19 axillary nerve lesions failed to recover completely in 1 year There was no statistically significant difference in rate of

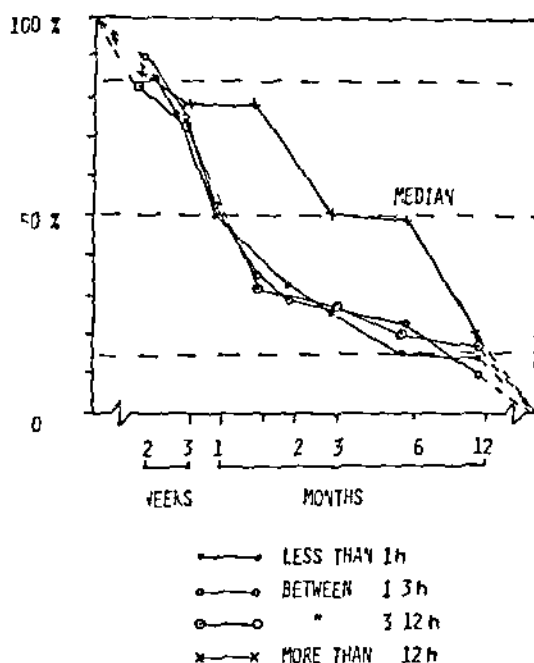


Figure 3 Effect of length of the "non reduced period" on recovery of normal mobility of the shoulder Patients with a "non reduced period" of longer than 12 hours made the slowest recovery

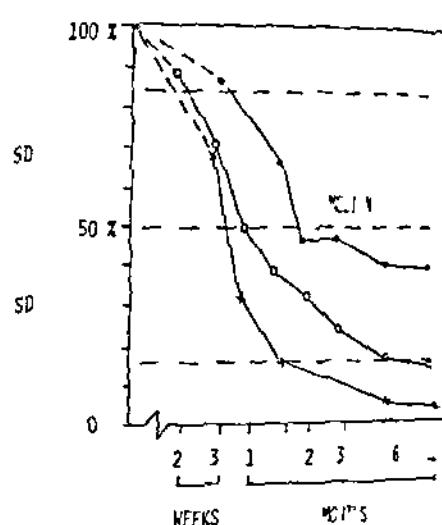


Figure 4 Effect of the mechanism of trauma on the time required to regain normal mobility of the shoulder The greater the estimated force of the dislocating trauma the slower was the mobilization

Table 1 Time required to regain normal mobility of the shoulder in the various social groups

Social group	Time required to regain normal mobility of the shoulder < 6 weeks	> 6 weeks	Total
Manual labourer	57	40	97
Office worker	36	9	45
Student	13	0	13
Pensioner	34	37	71
Total	140	86	226

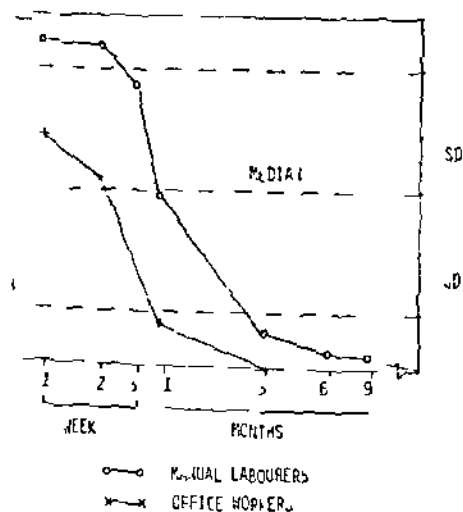
recovery between the plexus and axillary nerve lesions

All eight nerve lesions in patients under 51 years, and 21 of the 36 nerve lesions in older patients, recovered within 1 year (Figure 6)

The group of office workers and students achieved a normal range of movement in the shoulder more quickly ($P < 0.001$) than the manual labourers (Table 1) The mobilization of the shoulders was slower ($P < 0.01$) in pensioners than in the rest of the patients

DISCUSSION

The rate of mobilization slowed down at the end of the follow up period of 1 year only four patients attained a normal mobility of the shoulder after a further 6 months concluded that the stiffness persisting shoulders after 1 year was permanent Twenty-three of these 42 stiff shoulders complicated by rotator cuff rupture or lesion, or both Of the patients who



5 Length of sick leave period of manual rs and office workers Manual labourers work for a considerably longer time than orkers

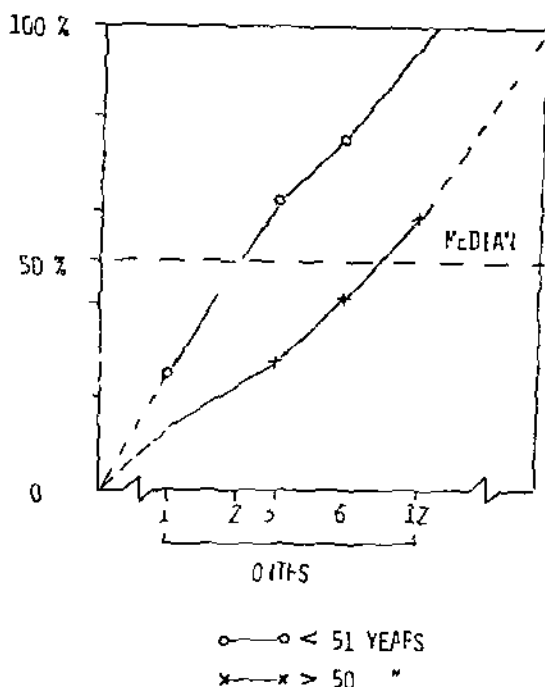


Figure 6 Recovery of nerve lesions in two age groups The rate of recovery was almost significantly slower in the patients over 50 years of age (P < 0 05)

rs, 21 were manual labourers, 18 ners and only three were office s.

s, delayed mobilization often resulted manent stiffness On the other hand, er, 25 of the 108 patients who attained l mobility in 1 month had cations during the follow-up period, l 30 shoulders with redislocations were zed in 2 months

ially, only two patients had such ve plexus lesions that the affected nity was totally paralysed Usually the sed muscles in cases of plexus lesion small and distally located, inducing the ner at first sight to evaluate the lesions slight" (20/30), compared with the) nerve lesions (8/19) in which the ve, flaccid deltoid muscle suggested a re" lesion Because the plexus and y nerve lesions both recovered equally this primary impression did not turn out of any prognostic value

re nerve lesions were either initially or they made a good recovery as all the ing patients with nerve lesions were able turn to their work during the follow-up period One carpenter with total loss of axillary function and inadequate return of nerve function had the longest sick leave 9 months Recovery was delayed in five patients with combined plexus and axillary nerve lesions and in eight patients with a torsional mechanism of dislocation Seven of the nerve lesions were slight enough to recover within 1 month, but it is conceivable that all transient nerve lesions may not have been diagnosed In four of the seven slight nerve lesions the "non-reduced period" was 1 hour, and it never exceeded 6 hours Nerve and tendinous complications seem to occur only in primary shoulder dislocation, as no complications were observed in the 30 shoulders with redislocation Mobilization in these cases was also achieved without difficulty

After 1 year 14 rotator cuff ruptures still showed a limitation in flexion up to 40 degrees However, no patient had any

spontaneous pain or pain on movement of such severity as to indicate surgical treatment for rotator cuff rupture (Bakalim & Pasila 1975)

The length of the sick leave period could not be determined in the case of the 16 pensioners with rotator cuff ruptures but six out of the seven manual labourers and all three office workers with rotator cuff ruptures returned to work during the follow up period

Mobilization was impeded by the severity of dislocation and the length of the "non reduced period' These together with degeneration of the shoulder joint due to advanced age and/or manual labour increased the rate of complications and reduced the tendency for redislocation

REFERENCES

Assmus H & Meinel, [illegible] Schulterverletzung und Axillar[illegible] *Unfallheilk* 79, 183 187

Bakalim G & Pasila, M (19[illegible] treatment of rupture of the rotator cuff [illegible] *orthop scand* 46, 751 757

Codman E A (1934) *The shoulder* T[illegible] Boston

London P S (1971) Treatment and [illegible] dislocation of the shoulder *Physio*[illegible] 2 6

Pasila M Jaroma H Kiviluoto, O & [illegible] A (1978) Early complications of [illegible] shoulder dislocations *Acta orthop sc*[illegible] 260–263

Yeoman P M & Seddon H J (19[illegible] plexus injuries Treatment of the [illegible] *Bone Jt Surg* 43 B 493 500

Correspondence to Manu Pasila M D HUCH Tolo Hospital 00260 Helsinki 26 Finland

op scand 51, 263–266, 1980

ıROPATHY IN THORACIC SCOLIOSIS

- KAPLAN*, VINOD SAHGAL**, RICHARD HUGHES***,
ıAM KANE**** & NORTON FLANAGAN*

tment of Rehabilitation Medicine and ** Department of Neurology, Northwestern University,
ɪDepartment of Internal Medicine and **** Department of Orthopedic Surgery, Rehabilitation
·· of Chicago, Chicago, Illinois, USA

The erector spinae muscles of 20 normal humans were evaluated at C_7, T_5, T_{11}, and L_4 vertebral body levels bilaterally At each level, the mean potential duration of the motor unit action potential was calculated This control group was compared with a group of patients with C_7 and L_5 radiculopathy and with a group of patients with thoracic scoliosis. The mean potential durations of the radiculopathy group at the C_7 and L_5 levels were prolonged as were those values at the convex thoracic levels in the scoliotic group Muscle biopsy of the erector spinae in the scoliotic group revealed grouped atrophy and changes consistent with a neuropathic process A radiculopathic process was associated with idiopathic thoracic scoliosis and involved the convex side It was maximal near the apex of the curve

Key words electromyography, muscles, pathology radiculitis, scoliosis, pathophysiology

Accepted 26 vi 79

4, the mean potential duration was ed for the biceps brachii muscles ıal et al 1954) Soon afterwards, mean al durations were calculated for 16 ıuscles (Buchthal & Rosenfalck 1955) of the muscles, except the brachialis, ta were recorded using concentric or electrodes However, the mean al durations of the biceps brachii recorded by either concentric or ır electrodes were virtually identical hal et al 1954) Since then, the mean al duration has been used as a ative electromyographic parameter In n, the medial portion of the erector muscles lends itself to more accurate myographic studies than the lateral ı (Jonsson 1969) The purpose of this s to use the more recent technological ss to calculate the mean potential duration of the medial portion of normal erector spinae muscles using monopolar electrodes and to compare this with the mean potential duration in patients with radiculopathy and with scoliosis.

PATIENTS AND METHODS

Twenty unpaid volunteers were studied in the control group The age range was between 20 and 42 The mean age was 35 and the median age was 37 Ten of the volunteers were males and 10 were females None had a past history of diabetes, heart disease kidney disease or any neurologic disorder

Fourteen patients comprised the radiculopathy group Seven had unilateral neck pain and signs and symptoms consistent with C_7 radiculopathy, and seven had a low back pain and signs and symptoms consistent with unitaleral L_5 radiculopathy All of these patients had marked

70 80 020263–04502.50/0

spontaneous pain or pain on movement of such severity as to indicate surgical treatment for rotator cuff rupture (Bakalim & Pasila 1975)

The length of the sick leave period could not be determined in the case of the 16 pensioners with rotator cuff ruptures, but six out of the seven manual labourers, and all three office workers, with rotator cuff ruptures returned to work during the follow-up period

Mobilization was impeded by the severity of dislocation and the length of the "non-reduced period" These together with degeneration of the shoulder joint, due to advanced age and/or manual labour, increased the rate of complications and reduced the tendency for redislocation

REFERENCES

Assmus H & Meinel (Schulterverletzung und Axillar... *Unfallheilk* 79, 183–187

Bakalim G & Pasila M (19... treatment of rupture of the rotator c... *orthop scand* 46, 751–757

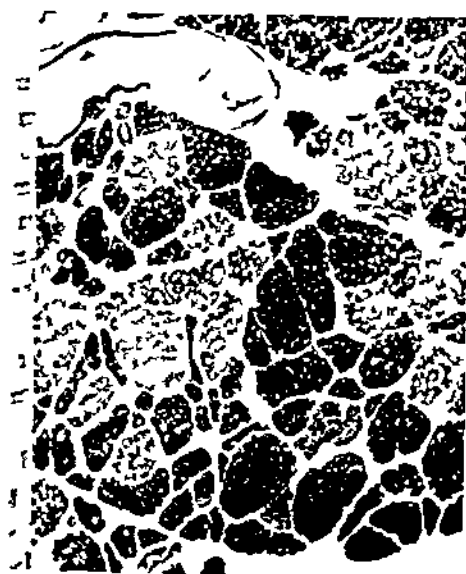
Codman E A (1934) *The shoulder* Th... Boston

London P S (1971) Treatment and the... dislocation of the shoulder *Physiothe...* 2–6

Pasila M Jaroma H Kiviluoto O & S... A (1978) Early complications of shoulder dislocations *Acta orthop sc...* 260–263

Yeoman P M & Seddon H J (19... plexus injuries Treatment of the ... *Bone Jt Surg* 43 B 493–500

Correspondence to Manu Pasila M D , HUCH, Tolo Hospital 00260 Helsinki 26 Finland



I Muscle biopsy—Erector spinae on the ...ide at the T_7 level, myofibrillary ATPase ... pH 9 4 Dark Type II and light Type I ...re seen Type II fibers are small and ... Note also the group atrophy of muscle ... 250

... of Type II fibers Muscle spindle thickening was noted In addition, in... ular nerve showed evidence of ... nation and fiber type grouping was ...erved (Figure 1)

SSION

...ults indicate that determination of the ...otential duration is both accurate and ...cible The advent of trigger and signal modules make it easier to capture ... unit action potentials on an os... pe screen store or record them and ...e them At the same time ...myographic examination of the ... nous muscles is a particularly useful ...ure with spinal nerve root ...opathy Electromyographic examina... ay in fact be confined to the erector ... muscles particularly during the first 2 ... after injury and is extremely important ...e radicular levels with no appendicular representation (Goodgold & Eberstein 1977) Peripheral nerve palsy has been shown to produce polyphasic potentials of long duration (Pinelli et al 1953) In patients with atrophies due to neuropathies of the anterior horn cells prolonged mean potential durations have also been noted (Buchthal & Pinelli 1953) The mean potential durations were, in fact, prolonged in those patients with radiculopathy The prolonged mean potential durations of the convex thoracic levels in the idiopathic scoliosis patients indicate that radiculopathic processes are present in those patients as well The results of the muscle biopsies are also consistent with the presence of a radiculopathic process

The association of idiopathic scoliosis and radiculopathy has been controversial Henssge (1968) and Peretti & Velluti (1969) found increased insertional activity or "denervation" potentials. Weiss et al (1957) and Alexander & Season (1978) did not find increased insertional activity or fibrillation potentials Our study agrees with these last two studies with regard to insertional activity However, none of these studies used percutaneous electrodes exclusively to quantitatively examine the motor unit action potentials that were produced by the medial portion of the erector spinae during spinal extension In addition our study presents a correlation between muscle biopsy and electromyographic results absent in the other studies

This study does not by itself solve the question of whether or not the radiculopathic process precedes or is subsequent to the idiopathic scoliosis It has been stated that the evolution of idiopathic scoliosis is closely associated with abnormal skeletal maturation indexes (Duval Beaupere 1970) The presence of thoracic radiculopathy in these patients would at least in part explain the abnormal growth pattern

REFERENCES

Alexander M A & Season E (1978) Idiopathic scoliosis An electromyographic study *Arch phys Med* 59, 314–315

Buchthal, F, Guld, C. & Rosenfalck, P (1954) Action potential parameters in normal human *muscle and their dependence on physical* variables *Acta physiol scand* **32**, 200–219

Buchthal, F & Pinelli, P (1953) Action potentials in muscular atrophy of neurogenic origin *Neurology (Minneap)* **3**, 591–603

Buchthal, F & Rosenfalck, P (1955) Action potential parameters in different human muscles *Acta psychiat scand* **30**, 125–131

Duval-Beaupère, G (1970) Les repères de maturation dans la surveillance des scoliosis *Rev Chir orthop* **56**, 59–76

Goodgold, J & Eberstein, A (1977) *Electrodiagnosis of neuromuscular diseases*, 2nd ed, p 202 The Williams and Wilkins Company, Baltimore

Henssge, J (1968) Are signs of denervation of muscles of spine primary or secondary findings in cases of scoliosis? *J Bone Jt Surg* **50**, 882

Jonsson B (1969) Morphology [illegible] electromyographic study of the [illegible] *Arch phys Med* 50, 638–641

Peretti, G & Velluti, C. (1969) La [illegible] muscolare nella etiopatogenesi [illegible] giovanile *Rass med sarda* 72, [illegible]

Pinelli P & Buchthal, F (1953) [illegible] potentials in experimental [illegible] paresis *Electroenceph clin.* [illegible] 589–593

Sahgal, V, Morgen, C. A. & Sahgal, [illegible] Histochemical and morphological [illegible] human muscle spindle in upper [illegible] motor neuron lesions. *Acta* [illegible] **34**, 41–46

Weiss M Milkowska A & [illegible] Zachowawcze leczenie bocznych kregoslupa w swietle badan [illegible]nych. *Chir Narząd Ruchu* 32, [illegible]

Correspondence to Paul E Kaplan, M D, F.A C P Rehabilitation Institute of Chicago, [illegible] Superior Street, Chicago, Illinois 60611 USA

p scand. 51, 267–269, 1980

·EBRA PLANA DUE TO A MALIGNANT LYMPHOMA

"AARD, & B KRISTIANSEN

Department, Frederiksborg County Hospital in Hørsholm Hørsholm, Denmark

A patient with total collapse of the vertebral bodies ("vertebra plana") is described The symptoms and objective findings were caused by a malignant lymphoma, and the diagnosis was established from a drill biopsy It is recommended that a biopsy be performed in patients with "vertebra plana"

Key words drill biopsy, eosinophilic granuloma histiocytosis X, malignant lymphoma, vertebra plana

Accepted 15 vii 79

a plana was originally described as an necrosis of bone involving the spinal This description has been modified de a number of disorders eosinophilic ma, trauma, osteoporosis, inflammation ignant disease

present paper describes a case of i plana, initially misdiagnosed as tosis X or eosinophilic granuloma, s caused by a malignant lymphoma

REPORT

ear-old boy was admitted to the hospital st 1977 with severe pain in the back not by trauma X-rays of the spine showed ollapse of the 4th and 8th thoracic e diffuse osteoporosis and incipient hape of the lumbar vertebrae (Figure 1) X the chest 1 month previously had been and there were no radiological changes in l and long bones. Clinical and neurological ition was normal Blood analyses including white bloodcounts and liver enzymes were and Mantoux was negative Sedimenta te was 28 mm per 1 hour Tc"-isotope g showed abnormal activity in the thoracic The patient was regarded as having a plana possibly due to an eosinophilic ma and was observed in bed X-rays 3 ater showed no further changes but after 5 weeks a progression with collapse of the 5th and 7th thoracic vertebrae was observed The sedimentation rate had increased to 60 mm per 1 hour Histologic examination of the bone marrow showed malignant tumour cells of unknown origin, The patient was subsequently transferred to another hospital (Rigshospitalet, Copenhagen) and a drill biopsy of the third lumbar vertebra was performed Histologic examination showed anaplastic cells from a malignant lymphoma probably of reticulum cell type (signed A Halveg)

Chemotherapy with Prednisone Cyclophos phamide, Oncovine was then started and the patient was mobilized in a brace During the following months the radiological changes subsided, but after 1 year the condition worsened and the patient died in November 1978 Autopsy was not performed

DISCUSSION

In the first description of vertebra plana Calve (Calve 1925) laid down the following criteria 1) total collapse of only one vertebra, 2) no involvement of the intervertebral disc, 3) the intervertebral space at least one third wider than normal, 4) increased density of the involved vertebra Calve stated that the changes might be due to some sort of aseptic bone necrosis

70/80 020267–03$02.50 0



(A) (B)

Figure 1A, B X-rays of the thoracic and lumbar spine

In 1954 Compere et al reported four cases of vertebra plana with the same radiological changes. Histologic examination of biopsies from all four patients showed that the collapse was due to an eosinophilic granuloma This was also found by Kieffer et al. (1969), who furthermore stated that several patients with eosinophilic granuloma had affection of more than one [illegible] one patient had changes in the [illegible] well Identical findings were [illegible] Poulsen & Thommesen (1976). [illegible] granuloma is, however, not always the [illegible] of vertebra plana (Ennis et al [illegible] Poulsen et al. (1975) found [illegible] Ewing sarcoma among five [illegible]

a plana Ewing sarcoma is only rarely d to the spinal column, and they ed that an open biopsy should always ormed

s patient initially presented with s of two thoracic vertebrae with no in nt of the intervertebral disc and no ue swelling was seen It was not until y from the iliac crest was taken that m of a malignant disease arose and l diagnosis was only established after needle biopsy was taken from one of mbar vertebrae which had also col-

ems very unlikely that the changes in mbar vertebrae were caused by a other than that in the thoracic verte- ince the radiological pictures were l as the disease progressed more the temporary remission after herapy was started was seen in both the and the lumbar spine

ust be emphasized that all patients ertebra plana should be regarded as having a malignant tumour until proven otherwise A way to prove or exclude this is by taking a biopsy from the affected vertebra

REFERENCES

Calve J (1925) A localized affection of the spine suggesting osteochondritis of the vertebral body with the clinical aspect of Pott s disease *J Bone Jt Surg* 7 A 41–46

Compere E L Johnson W E & Coventry M D (1954) Vertebra plana (Calve s disease) due to eosinophilic granuloma *J Bone Jt Surg* 36-A 969 978

Ennis J T Whitehouse G Ross F G M & Middlemiss J H (1973) The radiology of the bone changes in histiocytosis X *Clin Radiol* **24**, 212–220

Kieffer S A Nesbit M E & D Angio G J (1969) Vertebra plana due to histiocytosis X serial studies *Acta radio Diagn* **8**, 241–250

Poulsen J O Jensen J T & Thommesen P (1975) Ewing sarcoma simulating vertebra plana *Acta orthop scand* **46**, 211–215

Poulsen J O & Thommesen P (1976) An unusual case of histiocytosis X in the spine *Acta orthop scand* **47**, 59–62

ondence to Søren Solgaard M D Bakkehusene 56 DK 2970 Hørsholm Denmark

hop scand 51, 271–274 1980

LAGEN CHANGES IN CONGENITAL AND PATHIC SCOLIOSIS

DÉN, INGA MARIE NILSSON & STIG WILLNER

nent of Orthopaedic Surgery and the Coagulation Laboratory Malmo General Hospital (Univer- und) Malmo Sweden

Collagen abnormalities in adolescent idiopathic scoliosis have been recorded In this condition the platelet aggregating power of collagen is decreased and the amount of collagen in suspensions prepared from fascia is increased We found the same abnormalities in two out of four patients with congenital scoliosis, operated on according to Harrington In idiopathic as well as in congenital scoliosis the decrease in the platelet aggregating power was more conspicuous in the younger patients.

Key words collagen congenital and idiopathic scoliosis

Accepted 4 vii 79

n, the most important supportive of connective tissue, has been shown e defective properties in adolescent hic scoliosis (AIS) (Francis et al 1977, l et al 1978, Uden et al 1979) In AIS ubility of collagen in weak acetic acid reased and the platelet aggregating is diminished (Udén et al 1979) changes can be explained by an altered nking, or by a decreased content of II collagen, which is less soluble and increased platelet aggregating activity sen et al 1975) This paper compares n in congenital scoliosis with that in

RIAL

aterial consisted of four patients (15 ± 3 with congenital scoliosis (Table 1) and patients (15 ± 2 years) with AIS The curvature ranged from 47°–80° and l°, respectively All the patients with congenital scoliosis had a unilateral bar on the concave side at the apex of the curvature Two patients also had several hemivertebrae The patients were operated upon according to Harrington and biopsy specimens were obtained from fascia of the longitudinal dorsal muscles.

METHODS

Collagen suspensions were prepared as described in detail elsewhere (Udén & Nilsson 1978). The pieces of fascia were scraped clean and freeze-dried in a vacuum. 8 35 mM acetic acid was added in an amount corresponding to 50 times the weight of the specimen after which the mixture was homogenized for 60–90 seconds with a pestle and a glass mortar An equal volume of distilled water was then added and homogenization was repeated During the homogenization the mortar was kept in ice-cold water The suspension was stored at −60°C Before being used it was rehomogenized and centrifuged at 1200 *g* for 30

used to determine the platelet aggregating ability of the collagen

The platelet aggregating ability was assessed photometrically with a Payton Dual Channel

vestigation was supported by grants from the h Research Council (B79 19X-00087-15B 8-17X-04780-03)

70 80 020271–04$02.50 0

Table 1 Four cases of congenital scoliosis CC per cent = minimal concentration of collagen in p[...] plasma (PRP) that induces platelet aggregation, relative to that of a standard collagen

Sex	Age years	Defect of the vertebrae	Collagen in in suspension, mg/l	CC per cent
M	17	Unilateral bar + hemivertebrae	140	70
M	18	Unilateral bar	25	60
F	14	Unilateral bar	85	250
F	11	Unilateral bar + hemivertebrae	120	[illegible]

Aggregation Module, also described by Udén & Nilsson (1978) It implies constant magnetic stirring and constant recording of the transmission The lowest concentration of collagen in platelet-rich plasma (PRP) that induced platelet aggregation was called the critical concentration (CC) PRP was obtained from healthy volunteers Since the responsiveness of PRP even from healthy persons varies, the CC was expressed in relation to that of standard collagen (CC per cent)

In the statistical treatment of the data, Student's *t*-test for differences between means, and Pearson's linear correlation test were used

RESULTS

The mean collagen concentrations in the suspensions from the two groups were equal, as was the mean CC per cent, which reflects the platelet aggregating power (Table 2)

Compared with the findings in non-scoliotic controls (Udén et al 1979) the concentration of collagen in the suspensions was significantly increased in congenital scoliosis ($P < 0.05$) as well as in idiopathic scoliosis ($P < 0.05$) In neither of the scoliotic groups did the platelet aggregating power of the collagen (CC per cent) differ significantly from the control value but a difference was found when the two groups were pooled ($P < 0.01$) This implies a decreased platelet aggregating power of the collagen of the scoliosis patients regardless of type

The CC per cent varied inversely with the patient's age, ($r_{12} = -0.69$), which means that the collagen of the younger patie[...] more reduced platelet aggregating p[...]

There was also a slight [...] cant correlation between age and [...] *content of the solution* ($r_{12} = -0.45$)[...]

The material, five boys and s[...] showed no significant sex diffe[...] either collagen content of the s[...] (86 ± 43 mg/l and 95 ± 39 mg/l, res[...] or the mean CC per cent values ([...] per cent and 540 ± 400 per c[...] pectively) The values in the girls [...] significantly higher than those in the [...]

DISCUSSION

described by *Ponseti* & [...] induced scoliosis in rats with β-[...] piomtrile Scoliosis has also been [...] per cent of a highly inbred strain of [...] with a collagen defect, characteriz[...] increased solubility in 4 M urea ([...] al 1977) When it was also found [...] properties of collagen in adolescent [...] scoliosis (AIS) differed from the [...] was suspected that defective collag[...] cause of AIS If congenital scolios[...] solely by anomalies of the vert[...] would not expect the same collagen [...] such cases. However, we found the [...] of changes as in AIS, ie a[...]

-2 *Results of the analysis of collagen from patients with congenital and idiopathic scoliosis (AIS) The for AIS II and controls are from an earlier paper (Udén et al 1979) CC per cent = minimal con- of collagen in platelet rich plasma (PRP) that induces platelet aggregation, relative to that of a standard collagen*

	Number	Male	Female	Age years av ± s d	Collagen in suspension mg/l, av ± s d	CC per cent of standard av ± s d	CC per cent of standard Range
ital scoliosis	4	2	2	15 ± 3	90 ± 50	540 ± 470	60–1080
	8	3	5	15 ± 2	90 ± 30	420 + 310	140–1130
	15	1	14	18 ± 4	130 ± 20	770 ± 550	150–2050
ls	10	7	3	19 ± 6	50 ± 20	180 ± 110	60–400

lity in weak acetic acid and a decreased t aggregating power

genital scoliosis is a rare condition – en samples could be obtained from only cases Consequently, the value of the ical methods is limited However, in f the cases of congenital scoliosis the r cent values were well above the upper of the normal range and more on the f that in AIS (Tables 1 and 2) There is no ice that the collagen defect in congenital sis is the same as in idiopathic scliosis ver, two of the cases showed signs of a r abnormality This was perhaps because r fascia specimens were obtained from cases. Only relatively few cases of con- l scoliosis, as well as idiopathic scoliosis, orate to this degree during adolescence bly such severe deformities require some sting disturbance of the collagen Any test s hypothesis would require inclusion of with mild deformities.

 sex ratio was not the same in the two s. However, the variation of the pro- s of collagen with sex was not ically significant and cannot explain the ence found between the patients with sis and the controls.

e correlation between age and platelet gating properties of the collagen has observed earlier by Udén et al (1979) in that study it was not statistically icant The finding that this abnormality re pronounced in younger patients is in ment with Francis et al (1977)

It is known that the amount of reducible cross-links of collagen varies with the growth rate (Bailey et al 1974) Perhaps this is one cause of the frequently observed progression of both congenital and idiopathic scoliosis during the prepubertal growth spurt (Farkas 1954, Shands & Bundens 1956, Duval-Beaupère 1971, Clarisse 1974)

REFERENCES

Bailey, A J, Robins, S P & Balian, G (1974) Biological significance of the intermolecular crosslinks of collagen *Nature (Lond)* **251**, 105–109

Balleisen L, Gay, S, Marx, R & Kuhn, K. (1975) Comparative investigation on the influence of human bovine collagen types I, II and III on the aggregation of human platelets. *Klin Wschr* **53**, 903

Bushell G R, Ghosh, P & Taylor, T K F (1978) Collagen defect in idiopathic scoliosis *Lancet* ii, 94–95

Clarisse, P (1974) Prognostic évolutif des scolioses idiopathique mineures de 10°–29° en période de croissance Thesis Ass. Corporative des Etudiants en Médecine de Lyon

Duval-Beaupère, G (1971) Growth and its relation to bone deformities *Scoliosis and growth* (Ed Zorab, P A) p 58 Churchill Livingstone, Edinburgh and London

Farkas A (1954) The pathogenesis of idiopathic scoliosis. *J Bone Jt Surg* 36-A, 617

Francis, M J O, Smith, R & Sanderson, M C (1977) Collagen abnormalities in idiopathic adolescent scoliosis. *Calcif Tiss Res* (Suppl) **22**, 381–384

Grant, M E & Prockop, D J (1972) The biosynthesis of collagen *New Engl J Med* **286**, 194–199

Ponseti I V & Baird, W A (1952) Scoliosis and dissecting aneurysm of the aorta in rats fed with Lathyrus odoratus seeds. *Amer J Path* **28**, 1059

Riggins, R S, Abbott, U K, Ashmore, C R., Rucker, R. B & McCarrey, J R (1977) Scoliosis in chickens. *J Bone Jt Surg* 59-A, 1020–1026

Shands, A R., Jr & Bundens, W D (1956) Congenital deformities of the [illegible] analysis of the roentgenograms of [illegible] *Bull Hosp Jt Dis.* 17, 110–11[illegible]

Udén A & Nilsson, I M (197[illegible]) [illegible] measuring collagen-induced [illegible] tion. *Thrombosis Res* 12, 105[illegible]

Udén A., Nilsson, I M & Willner [illegible] Collagen platelet activation and [illegible] in idiopathic scoliosis. In preparation

Correspondence to Alf Udén M D., Department of Orthopaedic Surgery University of Lund General Hospital, S-21401 Malmo, Sweden

.hop scand. 51, 275–283, 1980

..NTITATIVE ANALYSIS OF THE GROWTH OF ..HIP JOINT

..hiological Study

..SZÁROS & L. KÉRY

..ment of Orthopaedics, Semmelweis University
..l School, Budapest, Hungary

Growth of the hip joint is described on the basis of annual radiographs

that of the proximal metaphysis and accordingly, in the case of normal ossification, the radio-anatomical condition of these two parts is characteristic of the age of the individual. The osseous acetabulum also grows at a faster rate in breadth than in depth. In the period studied up until the 15th year *the width of the "articular space" gradually decreases. The ossification rate* in the age group examined manifests — with slower and faster periods — a gradually declining tendency. The changes revealed by the radiographs have been interpreted from the viewpoint of bone development and an analysis is also given of the spatial conditions of ossification.

Key words: acetabulum, articular space, femoral head, growth of hip, ossification rate, radio-anatomical condition

Accepted 3.iii.79

..aspects of the growth and development .. hip joint have become known as a .. of research in the last few decades ..son 1962, Gardner & Gray 1970, Lanz ..yet 1953, Lanz & Wachsmuth 1938, .. 1939). Investigations into the ..enesis of congenital dislocation of the .. well as the problems of its treatment ..rawn attention *to the hip joint and to* ..ly development. As a result of these in..itions, among the quantitative features ..velopment and growth, the relations ..n the proximal femoral end and the ..ular angle [collodiaphyseal angle, CE ..rg's) angle, antetorsion, etc.] have also ..raced and described in detail (Klein et ..49, Lanz & Wachsmuth 1938, Wiberg ..). Substantially *less is known about the* ossification processes occurring in the later stages of growth. In fact, knowledge of this period is almost exclusively confined to the angular relations mentioned above, other quantitative characteristics of growth are missing. Klein et al. dealt with the morphological changes concomitant with the growth of the proximal end of the femur.

Knowledge of the quantitative features of growth of the hip joint in childhood and puberty may very likely explain the numerous coxalgias manifesting themselves at this age, as well as the pathomechanism of the resultant deformations. Hence, for example, determination by means of quantitative features of the scale of articular deformation occurring in Perthes' disease, which has been *found to be satisfactory in practice and better*

..70.80.020275–09$02.50.0

than any other method applied so far, enables the establishment of a very exact diagnosis of this deformation (Glauber & Kery 1975 Heyman & Herndon 1950 Kéry 1970 Meyer 1964)

Our investigations aimed at recognizing those quantitative data which characterize normal growth and ossification of the hip joint in childhood and puberty

PATIENTS AND METHODS

For the investigation we used the intact hip joint of young male patients suffering from Perthes' disease in whom according to the most exact radiological and clinical analyses the osteochondrotic changes were undoubtedly only unilateral On these intact hip joints and on the so-called intact hip joints of patients suffering from Perthes' disease none of the radiological changes described earlier by other authors (Chivabongs 1972 Kránicz et al 1976) could be detected nor were any changes observed hinting at dysplasia or other coxalgias In order to trace the development we chose 50 boys in whom hip joint radiographs had been taken at least once a year for 4 years with intervals of 10–14 months The age of the boys examined varied between 4 and 16 years in our analysis we only used data referring to the age groups between 5 and 15 years

Under standard conditions the measurements were performed by means of a p comparative radiographs of the hip joint Magnification factor 1 13 For the analyses of the cases Lauenstein type radiographs were examined as well

Seventeen parameters were measured on each hip joint the breadth and depth of the osseous acetabulum the radius of the acetabulum the height and breadth of the ossification centre of the femoral head the radius of the surface of the osseous epiphysis the breadth of the proximal metaphysis of the femur near the growth cartilage the thickness of the metaphyseal growth cartilage the length of the femoral neck laterally and medially as well as the smallest diameter of the femoral neck the breadth and height of the ossification centre of the major trochanter and in addition the width of the articular space at two places The measured values were expressed in millimeters Apart from the above-mentioned measurements the size of both the CD angle and CE (Wiberg s) angle were also measured

We are in our present publication concerned only with the changes occurring during growth of the structures (acetabulum, fem articular space) involved in the form hip joint The method applied enabled from determining the general growth, separately the growth of each hip joint

Standard statistical formulae were values (mean) and standard deviation of values (s d) were calculated. The referring to different age groups are bas from 12 20 patients. No corrections to the magnification were made on the described Student s t test was used for significance

RESULTS

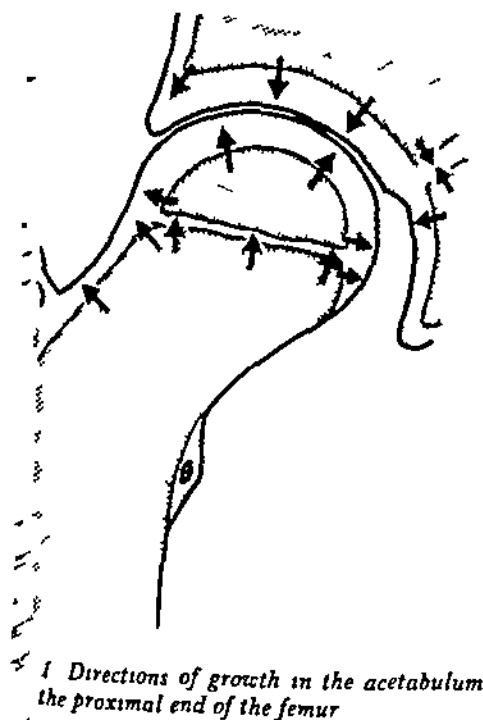
In the evaluation of the results, the anatomic conditions of the and the proximal end of the femur growth and ossification as well directions represented the sta (Figure 1)

The *ossification centre of the fe* appears in the cartilaginous ep growth may be characterized by breadth and form of the ossification

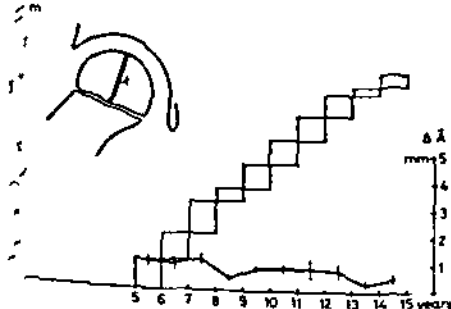
The height of the osseous epi was determined by the distance be subchondral bony plate and the growth plate Measurement was pe right angles to the plane of th cartilage at the highest point of th tion centre (Figure 2)

The longitudinal growth of the centre was not uniform in by far th of the cases, but faster and slow periods alternated As regards he centre of the femoral head, the me in the period between 5 and 15 0.8 ± 0.1 mm/year *Between 5 and 1* age the mean growth rate pro uniform with a transitory slow occurring only between 8 and 9 ye After the 13th year, growth thr remaining examination period gradually decreasing tendency (Fi

The breadth of the ossifica the femoral head (B) was meas distance between the most medi lateral extreme points of the



1 Directions of growth in the acetabulum the proximal end of the femur



2 Growth in height of the osseous femoral (A) in boys The columns show the growth of osseous epiphysis calculated from the height at age of 4 years (y) The curve shows the mean growth in height (Mean ± s d)
P<0 001 7–8, 9–10, 10–11,
P<0 01 5–6, 6–7, 8–9, 11–12, 13–14, 14–15,
P<0 05 12–13 years

(Figure 3) The breadth of the osseous ysis showed a uniform growth in almost ses (Figure 3) The mean growth was to be 2 2 ± 0 2 mm/year The growth became somewhat slower after the 10th year and significantly slower after the 13th year (Figure 4)




Figure 3 Growth in breadth (B) of the osseous femoral head as a function of age Each curve shows in each boy growth in breadth of the osseous epiphysis (For the sake of clarity the data of only 25 boys are included)

The *proximal metaphysis*, an important factor in the growth of the femoral head, forms also its stem In a cap-like manner the epiphysis covers the proximal metaphysis Its breadth (M) was measured in the region beneath the growth cartilage, from the laterodorsal angle to the most medial point of the medial "lip" of metaphysis (Figure 5) The breadth of the proximal part of metaphysis increased fairly uniformly in all individuals examined The average growth in breadth from the period between the 5th and 6th years gradually decreased from a maximum of 2.4 ± 0 4 mm/year, and between the 13th and 14th year growth did not exceed 1 1 ± 0 6 mm (Figure 5) Taken over the whole period examined the average growth was 1 9 ± 0 1 mm/year

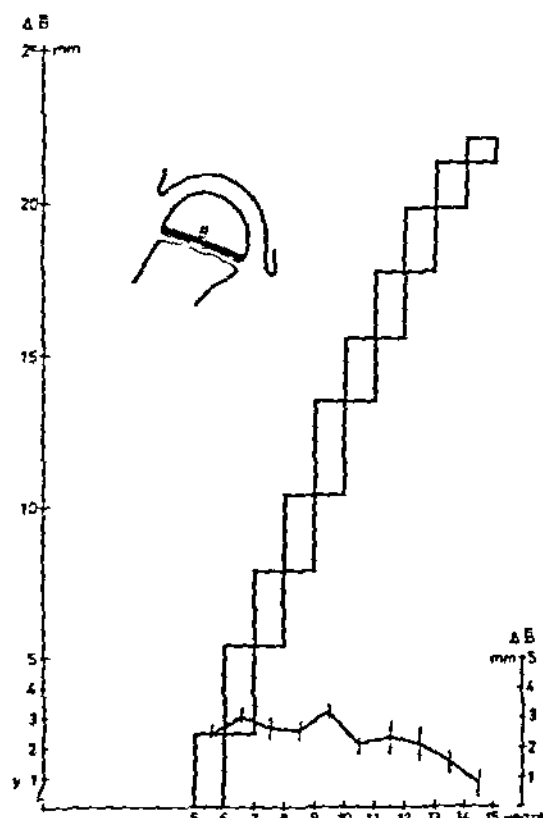


Figure 4 Growth in breadth (B) of the osseous femoral head The columns show the average growth of the osseous epiphysis, calculated from the size (y) at the age of 4 years The curve shows the average growth rate/year (Mean ± s d)
P value $P < 0\ 001$ *5–6, 6–7, 7–8, 8–9, 9–10,*
$P < 0\ 01$ *11–12, 11–12,*
$P < 0\ 05$ *12–13, 13–14, 14–15 years*

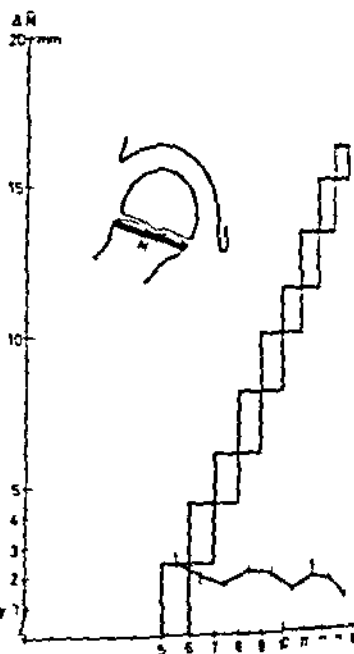
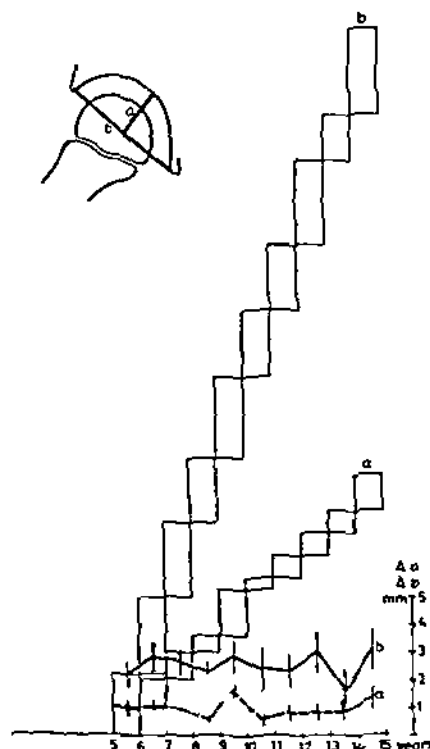


Figure 5 Growth in breadth of the femoral metaphysis (M) in ... The ... show the average growth of the ... calculated from the breadth (y) at the ... years The curve shows the average ... (Mean ± s d)
P value $P < 0\ 001$ *5–6, 6–7, 7–8 ...*
$P < 0\ 01$ *10–11,*
$P < 0\ 05$ *11–12, 12–13 ...*

The growth of the *osseous acetabulum* can be characterized by the change in its breadth and depth The breadth of the acetabulum was taken as the distance between the top edge of the osseous acetabulum and the inferior point of the medial "U" formation (line b Figure 6), and its depth at the point of greatest depth at right angles to the line of the breadth measurement (line a Figure 6) Growth in breadth of the osseous acetabulum was throughout the period studied fairly considerable with an average increase of 2 5 ± 0 1 mm/year Growth in depth of the acetabulum was much slower, being on average 1 0 ± 0 1 mm/year Growth of both acetabular dimensions slowed down between the 8th and 9th year, then accelerated again be... 9th and 10th year The breadth ... slower growth between the 11th ... year and thereafter increased again ... the 14th and 15th year growth ... acetabular depth, compared to the ... earlier also increased slightly ... shows the average values of the measurements.

The distance between the osseous acetabular floor and the osseous femoral ... so-called *articular space* was ... proximal part of the joint, in the "... bearing" area (C) and medially in the ... the acetabular fossa (D) (Figure 7 ... points the width of the articular ... decreased gradually with advancing ... width of the "weight-bearing" area ... rather slowly between the ages of ... years, but thereafter rapidly ...



6 *Growth in breadth (b) and depth (a) of the acetabulum in boys The columns show the growth calculated from the size (y) at the years The curves show the average annual rate (Mean ± s d) in breadth (b) and depth e acetabulum*
of "a" P<0 001 7–8, 8–9, 9–10,
P<0 01 5–6, 6–7, 10–11, 11–12,
P<0 05 12–13, 13–14, 14–15 years
of "b" P<0 001 6–7, 7–8, 8–9, 9–10,
P<0 01 11–12, 12–13,
P<0 05 10–11, 13–14, 14–15 years

e 15th year approached the size eristic of the adult hip joint Parallel e narrowing of the "weight-bearing" narrower weight-bearing zone of the lum developed, the medial part of the avity being wider near the acetabular Figure 7)

JSSION

present investigation a serial observa- the growth of the hip in the same in-

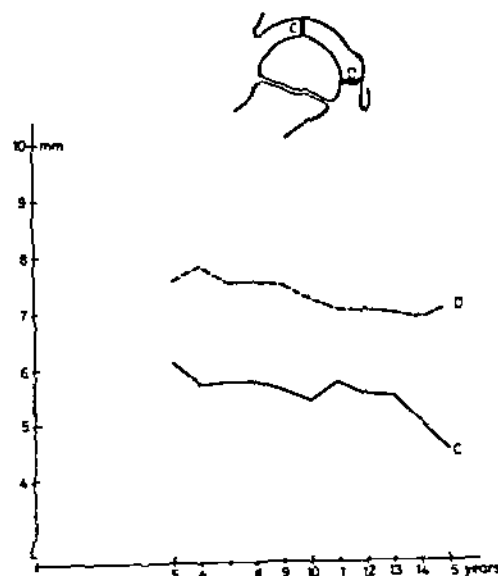


Figure 7 Growth of the "articular space" in the hip joint of boys C – size of the articular space in the "weight bearing zone", D – size of the articular space in the acetabular fossa

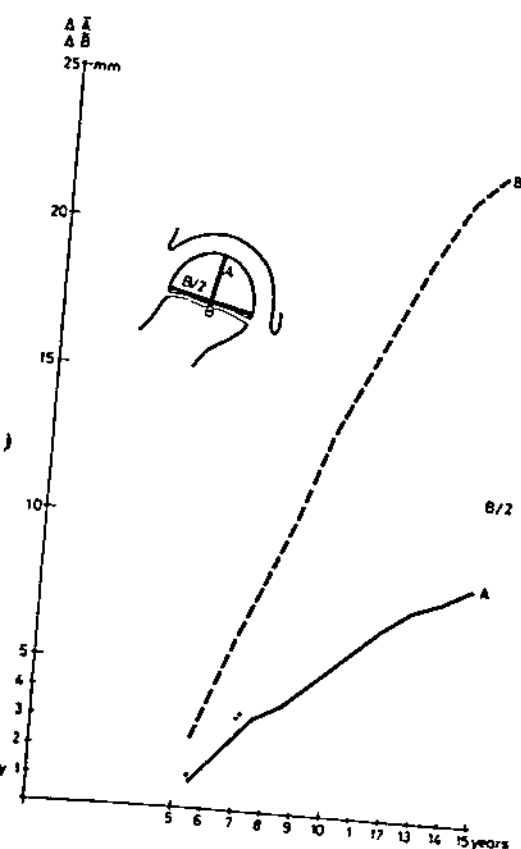
dividuals was carried out The growth of the hip joint was studied in the period between 5 and 15 years of age, providing data hitherto unavailable in the medical literature

Growth of the joints occurs together with growth of the cartilaginous epiphysis of the articulating bone ends. Growth of the ossification centre (osseous epiphysis) depends on the growth of the cartilaginous epiphysis and this is followed by the formation of bony tissue (ossification)

Growth of the ossification centre of the femoral head occurs as a result of ossification on an almost hemispherical surface On radiographs growth of the osseous epiphysis that can be measured linearly in plane projection in fact shows the above-described characteristic features. In order to demonstrate the true quantitative conditions we chose a period in which breadth of the ossification centre of the femoral head increased from 28 mm to 32 mm and its height from 14 mm to 16 mm In this period the ossification centre of the femoral head manifested a linear growth of merely 14 28 per cent but the ossification surface would at the same time

Table 1 Average measurements of the bony constituents of the hip

Age (years)	Mean values in millimetres (mean ± s.d.)			
	Osseous femoral head		Proximal femoral metaphysis	Osseo[us]
	height	breadth	breadth	depth
5	12.4 ± 1.0	25.5 ± 2.3	29.4 ± 1.7	13.9 ± 0.9
6	13.6 ± 1.1	28.0 ± 2.7	31.8 ± 1.7	15.2 ± 1.1
7	14.4 ± 1.6	31.3 ± 2.7	33.6 ± 2.0	16.3 ± 1.7
8	15.4 ± 1.4	34.1 ± 3.0	35.3 ± 1.7	17.6 ± 1.7
9	15.7 ± 1.7	36.9 ± 2.4	37.5 ± 1.8	18.2 ± 1.7
10	16.2 ± 2.0	40.0 ± 2.0	39.5 ± 1.8	20.1 ± 1.6
11	16.8 ± 1.4	41.8 ± 1.4	40.8 ± 1.6	20.5 ± 1.4
12	17.5 ± 1.9	43.8 ± 2.3	42.7 ± 2.3	21.3 ± 1.6
13	18.4 ± 2.3	45.8 ± 3.5	44.1 ± 2.7	21.8 ± 1.5
14	19.0 ± 2.6	47.3 ± 4.5	44.5 ± 2.8	22.7 ± 1.7
15	19.6 ± 2.7	49.6 ± 5.0	—	23.3 ± 0.7



[Fig]ure 8 Growth rate of the osseous femoral head height (A), breadth (B) and half the breadth [(B/]2), respectively

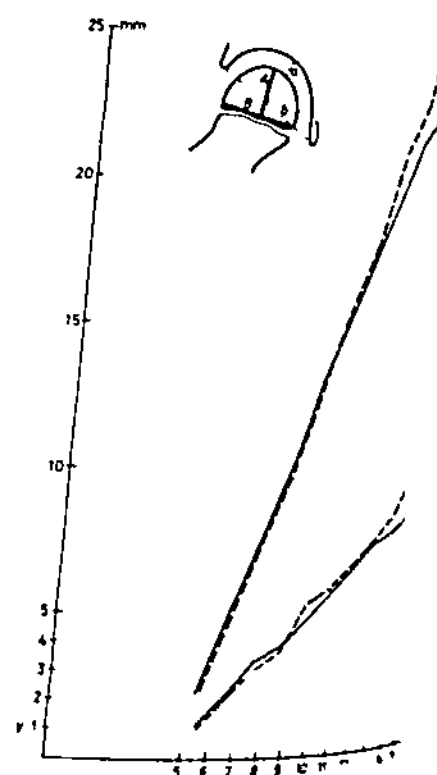


Figure 9 Growth in boys of the ... osseous femoral head and of the ... bony acetabulum, as well as of the ... epiphysis (B) and the acetabulum ...

increased by 32 62 per cent (from ∠ mm² – to 1607 68 mm²) and the ‾e of the whole ossification centre by per cent (from 5744 10 mm² to 8574 29 All this can, of course, be realized only ‿great and intricate, but coordinated, r activity Upon examining the question another side, even a rather small linear • (increase or decrease) occasionally measurable on the radiograph, es a considerable change in the in-physeal ossification rate

he period examined the growth rate in 1 of the femoral ossification centre exceeded that of its height (Figure 8) If aking into consideration that the height centre augments only in one direction, m the surface, but that the breadth es in two directions, i e from the two then in this sense we could compare rowth of half the breadth (B/2) with f height, even then we found that 1 in breadth throughout the examined exceeded by almost 40 per cent that of ght

above phenomenon may also be ed for the pattern of growth in breadth pth of the bony acetabulum (Figure 9) examinations reveal that growth rate articulating ends is proportional and similar growth rate is observed in the of the ossification centre of the femoral and in the depth of the bony ulum In the period of life examined, eadth of the ossification centre and that acetabulum manifested an identical 1 rate (Figure 9) An evaluable nce between growth in breadth of the acetabulum and that of the osseous d head may be observed only after the ear at which age, with the formation upper bony acetabulum ossification tates at this site

erences in the ossification rate are ed in the breadth of the osseous l head and in that of the adjacent al metaphysis (Figure 10) At the ing of the period examined (5th year)




Figure 10 Average growth rate in breadth of the osseous epiphysis (B) and of the metaphysis (M) in boys

a smaller centre of the femoral head was seen above the metaphysis, later, owing to the more speedy ossification of the head, the difference in size gradually decreased and by about the 10th to 11th year the breadth of the metaphysis and that of the ossification centre of the femoral head were identical The above growth rate difference also persisted after the 11th year, hence by the end of the examined period the breadth of the bony epiphysis exceeding that of the metaphysis

There is a close connection between the increasing breadth of the proximal metaphysis and that of the epiphysis, as the rate of growth of both parts emerges from a common perichondral "Anlage" Upon comparing, in the examined period of life, the spatial increase of the osseous part of the subchondral growth plate of the metaphysis (circular area) with the augmented ossification surface of the epiphysis (hemispheric

surface) we found that with identical growth rate (30 62 per cent 30 62 per cent) the absolute spatial increase in the epiphysis was almost twofold that of the ossification area of the metaphysis If, using the above-mentioned parameters, the breadth of the metaphysis and of the ossification centre of the femoral head increase from 28 mm to 32 mm, then the ossification surface of the metaphysis augments by 188 28 mm² and that of the ossification centre of the femoral head by 366 96 mm² Hence, with the increasing breadth of the femoral head its hemispherical form can be maintained only if growth of the epiphyseal surface also occurs at the above rate If not the femoral head will become flattened and deformed

The "articular space" discernible on the radiograph — that in the case of the hip joint depends mainly on the thickness of the cartilage covering the articulating bone ends — was of a different width in the so-called "weight-bearing zone" and medially in the area of the acetabular fossa in the course of the whole period of life examined The picture characteristic of the adult acetabulum showed up only after the 13th year In the area of the weight-bearing zone the articular space was of relatively constant size (6 0–5 5 mm), after the 13th year the width of the space decreased and with a mean value of 4 5 mm in the 15th year, closely approached at this stage the characteristic values of the adult hip joint In the area of the acetabular fossa the width of the articular space did not decrease in a parallel manner, as a result of which the double-arched pattern of the acetabulum appeared

Our investigations suggest that the rate of growth of the bone ends forming the hip joint has a slightly decreasing tendency The slowing down of the growth of the femoral head is not as great as observed by Anderson et al (1963, 1964) but is fairly close to the findings of Kember & Sissons (1976)

We did not find an adolescent growth spurt in the growth of the femoral head as is characteristic also of the longitudinal growth of the femur The slowing down of the growth of the femoral head occurs [illegible] to our investigations, after the age of [illegible] whereas the same phenomenon [illegible] observed in the longitudinal growth [illegible] femur after the age of 14 years ([illegible] al 1963, 1964, Kember & Sissons [illegible] Tupman 1962)

A feature different from the phenomena of growth is a growth [illegible] acetabular development between the [illegible] 14 and 15 This can be explained by the [illegible]clusion of growth of the bony acetabulum

The growth rate of the bony ends [illegible] to be different at different sites [illegible] growth of the acetabulum The [illegible] for this phenomenon can be found [illegible] somewhat different growth circumstances [illegible] the cartilaginous and ossified epiphysis [illegible] the effect of local pressure and [illegible] factors (Trueta 1957)

The individual examination of [illegible] shows faster and slower growth periods [illegible] think that humoral regulating factors [illegible] fundamental role in this process

REFERENCES

Andersen H (1962) Histochemical [illegible] development of the human hip [illegible] *anat (Basel)* 48, 258–292

Anderson M Green W T & Messmer [illegible] (1963) Growth and predictions of [illegible] the lower extremities *J Bone Jt Surg* [illegible] 1–14

Anderson M, Messmer M B & Green [illegible] (1964) Distribution of lengths of the [illegible] femur and tibia in children from [illegible] eighteen years of age *J Bone J Surg* [illegible] 1197–1202

Chivabongs, A (1972) Verlauft der [illegible] Erkrankung vorwiegend einse[illegible] *Z* [illegible] 110, 418

Gardner E & Gray D J (1970) The [illegible] development of the human femur [illegible] *Anat* 129, 121–140

Glauber A & Kéry, L. (1975) A Perthes Calvé-kórban végzett [illegible] femur osteotamia és a [illegible] csipotehermentesito kezelés [illegible] osszehasonlitó értékelese. ([illegible] femur osteotomy and conserva[illegible]

-ising treatment performed in Perthes Legg-re-disease comparative evaluation of the iors' results) *Magy Traum Orthop* **18**, 249

n C H & Herndon C H (1950) Legg-hes' disease A method for the measure-t of the roentgenographic results. *J Bone urg* 32 A, 767–778

r N F & Sissons, H A (1976) ntitative histology of the human growth

-ntgenologic evaluation of the patients ering from Legg Calvé-Perthes' disease 1 Herman Herndon's method) *Magy um Orthop* **13**, 179–187

A., Joplin E J, Reidy, J A & Hanelin, J 9) Roentgenographic changes in nailed ped capital femoral epiphysis. *J Bone Jt g* 31 A 1–22

Kránicz, J, Bartha, O & Bellyei Á (1976) A Perthes betegseg un ep' oldala (The so-called 'normal side" in Perthes' disease) *Magy Traum Orthop* **19**, 90–94

Lanz, T & Mayet, A (1953) *Zeitschrift für Anatomie* J Springer, Berlin

Lanz, T & Wachsmuth, W (1938) *Praktische Anatomie* J Springer, Berlin

Meyer, J (1964) *Dysplasia epiphysealis capitis femoris. A clinical radiological syndrome and its relationship to Legg-Calvé-Perthes' disease Acta orthop scand* **34**, 183–197

Tupman, G S (1962) A study of bone growth in normal children and its relationship to skeletal maturation *J Bone Jt Surg* **44** B 42–67

Trueta J (1957) The normal vascular anatomy of the human femoral head during growth *J Bone Jt Surg* 39 B, 358–394

Wiberg G (1939) Stud es of dysplastic acetabula and congenital subluxation of the hip joint *Acta chir scand*, Suppl 58

pondence to Dr T Meszáros, Department of Orthopaedics Semmelweis University Medical ' Karolina ut 27, Budapest, H-1502, Hungary

hop scand 51, 285–288, 1980

RELATIONSHIP OF BONE MASS AND SENING OF THE FEMORAL COMPONENT IN AL HIP REPLACEMENT

CARLSSON & BO E NILSSON

ment of Orthopedic Surgery, Malmö General Hospital (University of Lund), Malmo, Sweden

Parameters of bone mass in the upper end of the femur – the thickness of the calcar femorale and the pattern of the trabeculae – were evaluated in preoperative films of patients who had undergone total hip replacement. Patients with primary coxarthrosis rarely showed signs of osteoporosis, on the contrary, one of the parameters of bone mass was above average in the coxarthrosis cases. However, there was no difference, in the preoperative films, between hips that later went on to show signs of mechanical loosening of the stem prosthesis and hips that remained intact in this respect

Key words arthroplasty, coxarthrosis, hip, osteoporosis

Accepted 11 vi 79

nical loosening of the femoral nent of the prosthesis following total placement, unrelated to infection, is a ommon finding, even if serious clinical uences so far seem to have been few itz et al 1977, Beckenbaugh & Ilstrup Carlsson & Gentz, in preparation) In nical loosening a gap forms between tal and the cement, usually first visible the lateral edge of the prosthesis It is le that in addition to the load applied prosthesis, the positioning of the pro- and the distribution of the cement, he quality of the surrounding bone, g to the pressure transmitted through ment, is of importance (Amstutz et al

al support was obtained from the Swedish l Research Council (project no rX–2737–10C) and the Greta and Johan Foundation and the Alfred Österlund ation

However, osteoporosis appears to be rare in patients with primary coxarthrosis (osteoarthritis of the hip) On the contrary, Foss & Byers (1972), Roh et al (1973, 1974) and Carlsson et al (1979) found evidence of an increased bone mass in the upper limbs of patients with coxarthrosis

The purpose of the present study was to evaluate the bone mass in the upper end of the femur by examining radiograms obtained before the surgical procedure, and to compare those patients who after total hip replacement showed signs of mechanical loosening with patients who did not develop this complication

PATIENTS AND METHODS

Included in the study were 83 patients, 30 men, age 66 ± 6, and 53 women, age 69 ± 7, who had undergone total hip replacement because of primary coxarthrosis. The cases also fulfilled the criterion

70 80 020285–04S02.50/0



Figure 1 Separation between stem and cement observed 48 months after hip replacement according to Charnley The loosening was not associated with any clinical symptoms

that the technical result was reasonably good, with the femur component of the prosthesis in an acceptable position and without defects in the surrounding cement In 23 of the cases there was evidence of mechanical loosening between the cement and the metal stem, appearing as a radiolucent zone of 1 mm or more between metal and cement as measured on a standard antero-posterior view of the hip (Figure 1) The zone which was not present in the early postoperative period had a tendency to become wider as time passed

Additional criteria to qualify for the study were that the preoperative radiogram was of sufficient quality to permit radio-morphometric evaluations and was without signs indicating secondary arthrosis.

The following variables were estimated in the preoperative radiogram




Figure 2 Cortical index, measuring [illegible] thickness of the calcar femorale

The cortical index

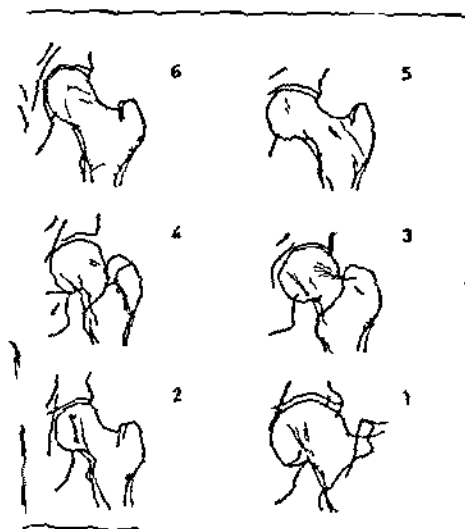
The thickness of the medial cortex [illegible] proximal to the lesser trochanter was [illegible] with calipers to a precision of 0.5 [illegible] antero-posterior film of the hip (Fig[illegible] measurement was divided by the [illegible] femoral neck at its narrowest part and [illegible] between the two referred to as the [illegible] (Fredensborg & Nilsson 1977). Both [illegible] measured regardless of whether the [illegible] hip was affected or not and the average [illegible]

Singh's index

The trabecular pattern in the upper [illegible] femur was estimated on an [illegible] of the hips using the method of S[illegible] (Figure 3)

Controls

For comparison of cortical [illegible] radiographically apparently normal [illegible] patients who had been referred for [illegible] amination for reasons other than [illegible] femoral neck fracture were used (F[illegible] Nilsson 1977).

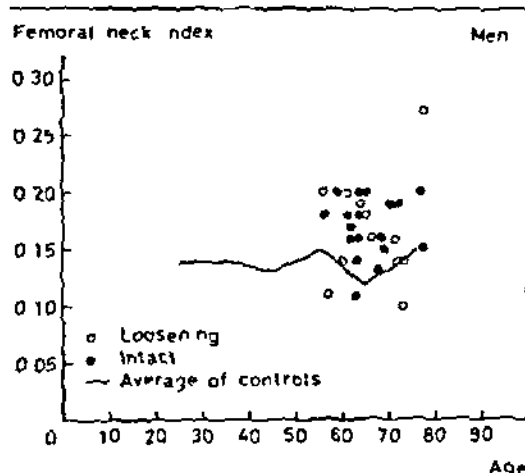


3 Grading of trabecular pattern according ... (by permission)

LTS

ortical index was in most instances average in the coxarthrosis cases as red with the controls (Figure 4) There however, no difference between the s who after total hip replacement ped a gap between the metal and the t and those who did not (Table 1)

Singh index was in many instances lt to evaluate because of structural s, secondary to the coxarthrosis, in the end of the femur Grades indicating ososis were extremely rare The hips divided into two groups *normal* ng Singh's grades 5 and 6 and *not* including all lower grades. There was erence in distribution between the two s patients who subsequently developed ing and patients who did not (Table 2)



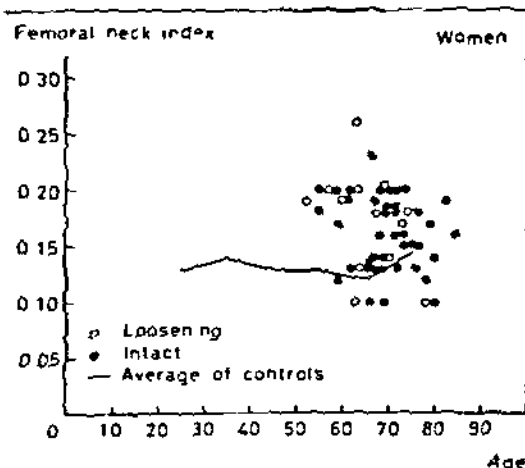


Figure 4 Cortical index of the hips in coxarthrosis patients compared with the average cortical index of 60 normal men and 60 normal women – 10 in each decade of age

DISCUSSION

The findings of the present study support the concept of osteoporosis as a condition that rarely coincides with coxarthrosis. Therefore the range of values of the parameters of bone mass in the upper end of the femur, measured

Table 1 Cortical index in intact hips and hips with signs of loosening ($\bar{x} \pm 1$ s d)

	Men		Women	
t	($n = 19$)	0 17 ± 0 03	($n = 42$)	0 16 ± 0 04
ing	($n = 11$)	0 16 ± 0 03	($n = 12$)	0 16 ± 0 04

Table 2 Singh's index in intact hips and hips with signs of loosening

	⩽4	5–6
Intact	6 M + 14 F = *20*	13 M + 28 F = *41*
Loosening	5 M + 2 F = *7*	6 M + 9 F = *15*

in the present study, was rather narrow and within this range the variation did not seem to be related to the resistance of the bone to pressure transmitted through the prosthesis and the cement Not even the thickness of the calcar femorale appears to be of any measurable importance in spite of the significance this structure has been given in the discussion of mechanical loosening (Bocco et al 1977, Oh 1977) If the range is increased by including patients with multiple operations because of primary coxarthrosis or post traumatic necrosis our observations may not hold true but, then again, we have no means of evaluating retrospectively, the bone mass variables of the upper end of the femur in such patients

REFERENCES

Amstutz, H C Markolf K L McNeice G M & Gruen T A (1976) Loosening of total hip components cause and prevention. Proc. of the Fourth Open Scientific Meeting of The Hip Society Chap 10 C V Mosby Company St Louis.

Amstutz H C Markolf K L McNeice G M & Gruen T A (1977) Loosening of total hip components cause and prevention Proc of the Fifth Open Scientific Meeting of the Hip Society Chap 12, C. V Mosby Company St Louis.

Beckenbaugh R D & Ilstrup D K [illegible] Total hip arthroplasty A review of three hundred and thirty-three cases with long follow up *J Bone Jt Surg* 60-A, [illegible]

Bocco F Langan, P & Charnley J [illegible] *Changes in the calcar femorale in [illegible] cement technology in total hip replacement* *Clin Orthop* 128, 287–295

Carlsson Å S Nilsson, B E & [illegible] (1979) Bone mass in primary coxarthrosis *Acta orthop scand* 50 187–189

Carlsson Å S & Gentz, C-F [illegible] loosening of the femoral head prosthesis total hip replacement according to Charnley (in preparation)

Foss M V L & Byers, P D [illegible] *density, osteoarthrosis of the hip, and [illegible] of the upper end of the femur* [illegible] *Dis* 31, 259–264

Fredensborg N & Nilsson, B E [illegible] index of the femoral neck. *Acta radiol* 18, 492–496

Oh I (1977) Effect of total hip replacement on the distribution of stress in the femur an in vitro study comparing the distribution in the intact femur with that after insertion of different femoral components Proc of the Fifth Open Scientific Meeting of the Hip Society Chap 9 C V Mosby Company St Louis.

Roh, Y S., Dequeker J & Mulier J C [illegible] Cortical bone remodeling and bone mass in primary osteoarthrosis of the hip *Radiol* 8, 251–254

Roh Y S Dequeker J & Mulier J C [illegible] Bone mass in osteoarthrosis measured by photon absorption *J Bone J Surg* [illegible] 587–591

Singh M Nagrath, A R, Maini P S [illegible] Changes in trabecular pattern of the upper end of the femur as an index of osteoporosis *J Bone Jt Surg* 52 A, 457–467

Correspondence to Åke Carlsson MD *Department of Orthopaedic Surgery* Malmo General Hospital S 214 01 Malmo Sweden

op scand 51 289–296 1980

[illegible]TS OF TREATMENT OF HIP FRACTURES

[illegible]ulation of the Consumption of the Resources of [illegible]als and Rehabilitation Institutions

[illegible]EN JENSEN, E TØNDEVOLD & P HOVE SØRENSEN

[illegible]nents of Orthopaedic Surgery T-2 & T-3, Gentofte Hospital Hellerup and the Department of [illegible]edic Surgery O, Frederiksborg County Hospital Hillerød Denmark

A series of 518 patients with hip fractures and a median age of 78 years was followed for 6 months On admission to hospital the patients were assessed and were found to be evenly distributed among four social function groups according to their level of dependence on the social welfare system At the 6 months follow-up the mortality rate was about 16 per cent, leaving 437 patients for a reassessment of social function

The average hospitalization time was 23 days thus 17 per cent of all orthopaedic hospital beds in the area were occupied by patients with hip fractures Patients staying the longest time in hospital were those waiting for discharge to a nursing home The average stay in rehabilitation institutions was 71 days The total rehabilitation course was longest for the most dependent patients

The risk of death or deterioration of social function among patients admitted from home was 48 per cent In the case of social deterioration or technical failure following the fracture treatment the total rehabilitation course was considerably prolonged

The resources required for the treatment of hip fractures in a suburban area of 500 000 inhabitants were calculated to be 32 hospital beds, 43 rehabilitation beds and at least 21 nursing home beds.

Key words fractures rehabilitation femoral neck fractures rehabilitation hospitalization

Accepted 29 iii 79

[illegible]echnical results of the treatment of hip [illegible]res have been well described, but less [illegible] have been made to clarify the social [illegible]litation (Campbell 1976, Cobey et al [illegible] Jensen et al 1979, Katz et al 1967, [illegible]as & Stevens 1974)

[illegible]ough the number of hip fractures is in[illegible]g in the Western countries due to an [illegible]sing average age of the population [illegible] 1960, Ceder 1977, Jensen & [illegible]vold, in press, Lindberg & Sjostrand [illegible] Mårtensson 1962), there have been very [illegible]udies of the social and economical aspects [illegible] treatment of these fractures

The purpose of the present study was to evaluate the relation between the costs of the treatment of hip fractures and the efficiency of the social rehabilitation

PATIENTS AND METHODS

During the period January 1st to December 31st 1977 a total of 518 patients with hip fractures were admitted to three different orthopaedic units covering a suburban area with a population of 500 000 inhabitants. The median age of the patients was 78 years (range 26–96) and 80 5 per cent (417/518) were females.

[illegible]70.80 070289–08S02.50 0

Table 1 Treatment of 518 patients with hip fractures

	Femoral neck fractures	Trochanteric fractures
Sliding nail	62 (27 8 %)	
Hemiarthroplasty	117 (52 5 %)	
Non-operative	44 (19 7 %)	3
* Nail plate		154 (52 2 %)
Sliding screw plate		131 (44 4 %)
Others		7
Total	223	295

* The nail plates were of the Jewett or McLaughlin type

Femoral neck fractures were recorded in 43 1 per cent *(223/518)* of the cases and trochanteric fractures in 56 9 per cent *(295/518)* The fractures were treated as listed in Table 1

The physical rehabilitation programme involved 6 weeks of partial weight bearing mobilization in both unstable trochanteric fractures treated by [illegible]

all other cases. When the rehabilitation programme did not progress satisfactorily within the first 2 weeks the patients were discharged either to a convalescent home with facilities for physical therapy (Skodsborg Sanatorium) or to a true rehabilitation clinic (Esbonderup Hospital or Tranehaven) with a highly developed socio-medical care system The choice of institution depended on the municipal address of the patient.

The patients were discharged from any of these institutions as soon as they were able to walk and undertake activities of daily living

On admission to hospital the patients were classified into social function groups (T. Stevens 1974) according to their dependence on the social welfare system, as defined in [illegible]

The patients were followed [illegible] months and a reassessment of the [illegible] was made. The mortality among the [illegible] studied and also the time spent in hospital, the rehabilitation clinics or the [illegible] The technical results of the fracture [illegible] were also considered

RESULTS

The pre fracture classification of [illegible] function of the total case material [illegible] patients is recorded in Table 3 The[illegible] fairly even distribution among [illegible] groups

The patients in groups I II and [illegible] all admitted from home as [illegible] patient placed in group IV A total of [illegible] cent *(383/518)* of the patients were [illegible] from home whereas 25 9 per cent [illegible] were nursing home patients at the [illegible] fracture and one patient was admitted [illegible] rehabilitation clinic

The hospital mortality among [illegible] admitted from home was 6.0 p[illegible] (23/383) with an average hosp[illegible] of 28 days compared with 5.2 p[illegible] (7/134) with a hospitalization [illegible] among patients from nursing ho[illegible] mortality rates 6 months after the [illegible] were 11 3 per cent (43/383) among [illegible] admitted from home and 24 4 p[illegible]

Table 2 The assessment of social function

	Social function groups	Definition
I	Independent	Manages everything Possibly working
II	Slightly dependent	Manages household Meals-on wheels, Home-help ≤ 4 hours week
III	Moderately dependent	Manages personal needs Home-help ≥ 5 hours week Possibly District Nurse
IV	Totally dependent	Living in nursing home or long term nursing at home

among patients admitted from homes

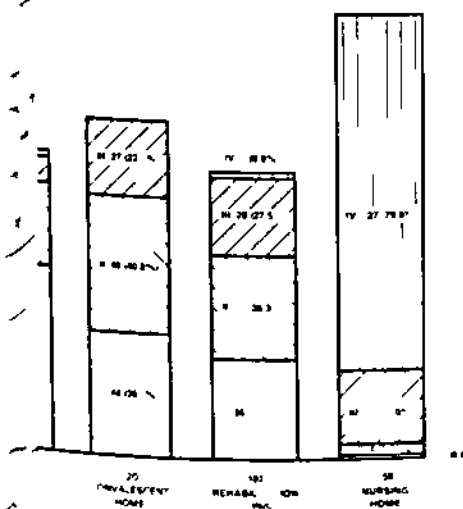
placement of the patients after e from hospital related to the pre- social function groups is illustrated in We found that 8 9 per cent (32/360) atients admitted from home were dis- to a nursing home, while 29 7 per 07/360) returned directly to their Another 33 3 per cent (120/360) of the were discharged to the convalescent nd 28 3 per cent (102/360) to the ation clinics There was no signifi- ference in the composition of social groups of the patients discharged to ions ($P = 0\,64$, Chi-square test) Two assigned to group IV were discharged laces they were admitted from, viz their id a rehabilitation clinic, respectively

average hospitalization time was 22 7 The total consumption of hospital es for the 518 patients amounted to hospital days, which is equivalent to 32 l beds This means that in the present of 500,000 inhabitants 17 3 per cent) of all orthopaedic hospital beds were for the treatment of hip fractures.

nts in group I pre-fracture stayed an average of 22 8 days in hospital compared with 30 4 days for patients in group II and 33 3 days for those in group III There was thus no significant difference ($P > 0\,05$, Kruskall-Wallis test) in the consumption of hospital resources for these three social function groups The nursing home patients in group IV were in hospital for only 6 9 days on average, which equals 8 0 per cent (938/11,738) of the total number of hospital days.

The placement of the patients after discharge from hospital related to the consumption of hospital resources is illustrated in Figure 2 Patients discharged to the convalescent home stayed 15 days less in hospital than those discharged to their own home and 13 days less – or only about half of the time – than those discharged to the rehabilitation clinics ($P < 0\,0001$, Kruskall-Wallis test) The longest stay in hospital of 55 4 days was encountered in patients who were waiting for a place in a nursing home and they consumed 16 5 per cent (1,774/10,784) of the total number of hospital days for the surviving patients The patients who were discharged to the convalescent home remained there for an average of 64 4 days compared with 78 3 days for those discharged to rehabilitation clinics ($P < 0\,05$ Kruskall-Wallis test)

A total of 15,713 institution days were needed for the rehabilitation of patients with hip fractures This equals 43 institution beds in our area of 500,000 inhabitants The costs



1 Placement after discharge from hospital to pre fracture social function groups in tients with hip fracture

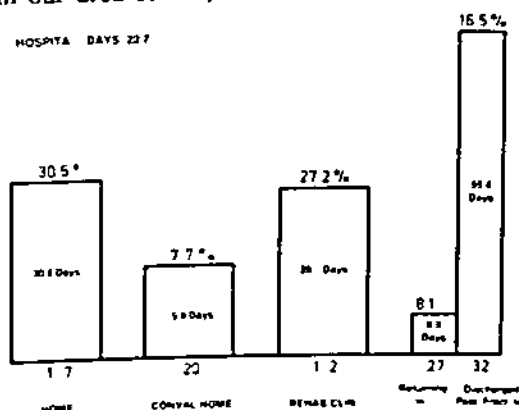


Figure 2 Placement after discharge from hospital related to consumption of hospital resources

Table 3 The deterioration of social function and the mortality 6 months after hip fracture

Pre-fracture assessment into social function groups	<	> No of deaths	Social function groups at 6 months follow-up I	II	III	IV	[illegible]
I	148	4 (2 7%)	92 (63 9%)	34 (23 6%)	16 (11 1%)	2 (1 4%)	[illegible]
II	128	12 (9 4%)		66 (56 9%)	32 (27 6%)	18 (15 5%)	[illegible]
III	106	27 (25 5%)			40 (50 6%)	39 (49 4%)	[illegible]
IV	136	38 (27 9%)				98	[illegible]
Total	518	81 (15 6%)	92 (21 1%)	100 (22 9%)	88 (20 1%)	157 (35 9%)	[illegible]

per day at the convalescent home are about 60 per cent of the costs at the rehabilitation clinics The average stay in the institutions was 70 8 days The patients classified pre-fracture into group I stayed in the institutions *for 63 9 days on average, whereas the com-*parative figures for patients in group II were 69 7 days and in group III 80 6 days ($P<0\ 05$, Kruskall-Wallis test)

A reassessment of social function 6 months after the fracture was made in the 437 surviving patients Of these 340 were admitted from home The results obtained at the follow-up are shown in Table 3 Among the surviving patients admitted from home 17 4 per cent (59/340) had become nursing home patients The risk of death was found to increase with the level of social dependence on admission

Among the patients in group I pre-fracture 63 9 per cent (92/144) of the survivors maintained their social function compared with *56 9* per cent *(66/116)* in group *II* and 50 6 per cent (40/79) in group III At the 6 months follow-up the average risk of deterioration of social function among surviving patients admitted from home was thus 41 5 per cent (141/340) and the total risk of death or deterioration among patients admitted from home was 48 0 per cent (184/383) In a statistical analysis of these data the total risk of death or deterioration was found to increase significantly with a higher level of dependence as assessed on admission to hospital ($P<0\ 05$, Chi-square test)

The results of the follow-up assessment of

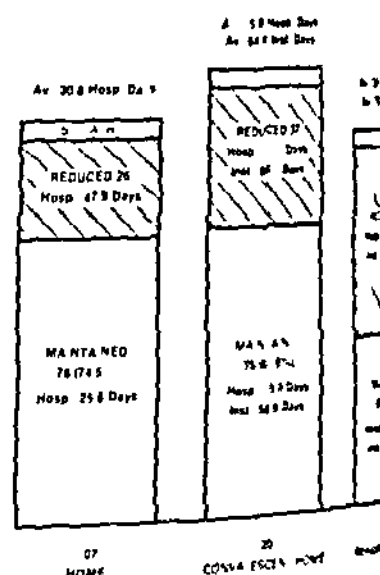


Figure 3 Placement after discharge ... after hip fracture related to consumption of resources (hospital and institution ...) function at the 6 months follow-up

social function were also analysed ... to the consumption of resources ... and in institutions, as illustrated in F... Among the surviving patients disch... their homes 74 5 per cent (... main-tained their social function with ... consumption of 25 8 hospital days ... case of deterioration of social fun... hospitalization time was almost d...

Among 120 patients discharged to ... valescent home 115 patients surv... the follow-up Of these 67 8 per cent ... maintained their social function ... stayed an average of 15 4 days in ... 56 9 days in the institution ... rehabilitation course was thus ...

of deterioration of social function the i course was 103 8 days on Of the patients discharged to the ition clinics 98 survived the 6 month The social function was maintained in 9 per cent (46/98) with an average 0 5 days in hospital and 67 9 days in ution, or a total rehabilitation course days. When the social function was to have deteriorated the total ation course was 117 7 days Thus of deterioration of social function was ntly higher ($P<0.05$, Chi-square test) patients discharged to the rehabilita- nics although the rehabilitation course siderably longer

significance of technical failures g the treatment of hip fractures as the consumption of resources and the nd result was analysed Technical following the treatment of femoral ictures were encountered in 15 2 per /223) of the cases This figure was es- influenced by a high failure rate after nail fixation (19/62 = 30 6 per cent) was no significant correlation between al failures and the pre-fracture social groups

total consumption of resources, as n Figure 4, was, however, con- ly increased in cases of technical ($P<0.0006$, Mann-Whitney test) as atients consumed an average of 31 4 l days (34/223 patients) and 80 1 in- n days (19/90 patients), respectively, ed with 19 5 hospital days (189/223 ts) and 61 5 institution days (71/90 s) in uncomplicated cases The risk of ation of social function among rs was 51 5 per cent (17/33) following al failures, which is significantly higher 01 Chi-square test) than the 27 3 per 4/161) risk in uncomplicated cases

wing the treatment of trochanteric es there was a technical failure rate of per cent (17/295) predominantly ng internal fixation with the ghlin apparatus (12 124 – 9 7 per

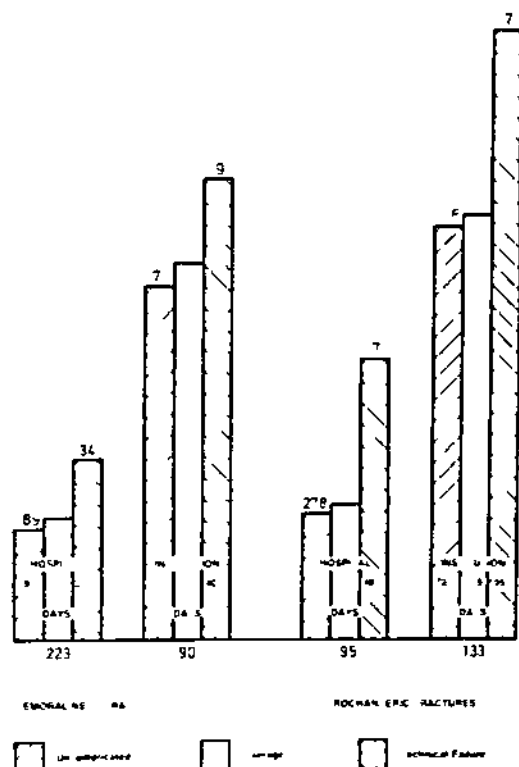


Figure 4 Consumption of resources related to technical failures following the treatment of hip fractures

cent) There was no significant relation to the pre-fracture social function groups.

In the case of technical failure the consumption of resources was on average 48 9 hospital days (17/295 patients) and 105 9 institution days (7/133 patients) compared with 22 1 hospital days (278/295 patients) and 72 1 institution days (126/133 patients) in uncomplicated cases ($P<0.05$, Mann Whitney test) The risk of deterioration of social function among survivors following technical failures in this group was 37 5 per cent (6/16) In uncomplicated cases 67 5 per cent (154/228) of the survivors maintained their social function Social deterioration was thus not related to technical failure in trochanteric fractures ($P>0.05$, Chi-square test)

DISCUSSION

Devas (1974) emphasized that loss of function in the elderly means loss of independence, which is disastrous for the patient and expensive for the community It has been estimated in previous studies (Cobey et al 1976, Katz et al 1964 and 1967) that only 25–50 per cent of patients with hip fractures maintain their level of function, when walking ability and activities of daily living are considered An assessment system containing this information obviously gives some indication of the quality of life

It was our wish to apply an assessment system, which not only considered the dependence of the patient but also took into account the demands on the social welfare system and thereby the expenses for the community We therefore found the assessment system described by Thomas & Stevens (1974), with some modifications, to be more suitable In accordance with the results stated by Thomas & Stevens (1974) we found that nearly 60 per cent of the surviving patients, who were admitted from home, maintained their social function The value of the assessment system applied is discussed in detail in the companion paper (Jensen et al 1979)

Little is known about the consumption of the resources of hospitals and rehabilitation institutions in the treatment of hip fractures One of the major problems in treating these elderly patients is the placement of the patients following the necessary hospital care In our series from a suburban area of 500,000 inhabitants 62 per cent of the patients admitted from home were discharged to a convalescent home or to rehabilitation institutions This agrees well with the figures given in other studies where 40–60 per cent of patients were discharged to institutions (Campbell 1976 Ceder et al 1977, Gylling 1960)

There is in our opinion no doubt that the possibility of transferring the patients to some sort of rehabilitation institution means a reduction in hospitalization time In the present series we found in accordance with others (Ceder et al. [illegible] Tøndevold, in press) an average [illegible] tion time of 23 days, which [illegible] reduced further for this category [illegible] comparison McCown & Miller [illegible] days, Riska (1970) 30 days, [illegible] days and Schenk et al. [illegible] hospital, but the final results of [illegible] tion lacked clarification. In [illegible] however, it is important to [illegible] rehabilitation course as the [illegible] of a reduction in hospitalization [illegible] the result is a high intake of the nursing homes a few months later [illegible] Ødegård & Unsgård (1978) 44 per cent [illegible] patients were discharged directly to [illegible] homes from hospital and in Campbell (1976) about 30 per cent of patients [illegible] nursing homes 4 months after the [illegible] the present series less than 9 per cent [illegible] patients admitted from home were [illegible] directly to nursing homes, and a total [illegible] cent of the patients were found to be [illegible] homes 6 months after the fracture [illegible] results agree well with those of others (Ceder at al 1977, Clark & [illegible] Gylling 1960)

The establishment of such [illegible] political question for the local [illegible] our area the costs of running a [illegible] home with facilities for physical [illegible] only about 60 per cent of the [illegible] rehabilitation clinic with a [illegible] developed socio-medical rehab[illegible] and only about 35 per cent of the orthopaedic hospital beds. The [illegible] rehabilitation clinic bed are about [illegible] of that of a hospital bed.

The problem to be discussed [illegible] of institution is most [illegible] rehabilitation of patients with [illegible] In this series we found that the [illegible] in terms of days was 14 less [illegible] lescent home than in the [illegible] rehabilitation clinics and that the [illegible] to wait an extra 13 days [illegible] the rehabilitation clinics. The [illegible] difference in the composition of the function groups of the patients [illegible]

these institutions. At the 6 months o, however, 68 per cent of the from the convalescent home had ed their social function compared per cent of the patients from the ation clinics. The rehabilitation ised 11 more days than the convalescent home for the maintenance of social but only 4 more days were used in ited cases It seems quite possible highly developed socio-medical care n the rehabilitation clinics leads, on e of the patients, to a much greater on home-help and meals-on-wheels it is an open question whether this level of dependence increases the of life From a purely economic view, convalescent homes with facilities ical therapy seem to be quite sufficient rehabilitation of patients with hip s

ier essential problem to be considered ost of technical failures following the nt of hip fractures It has recently ointed out (Jensen & Tøndevold, in that technical failures considerably e the hospitalization time In the series we found that technical failures ng the treatment of femoral neck s involved 12 extra hospital days and tution days The comparative figures chanteric fractures were an additional ption of 27 hospital days and 34 in- n days. This strongly illustrates the ince of applying the safest possible of treatment because failure at least oral neck fractures, also involves an sk of social deterioration

nclusion, we found that the consump- f hospital resources and those of tation institutions for the treatment of ctures is rather high In a suburban 500 000 inhabitants 32 hospital beds rehabilitation beds were needed This 17 per cent of the total number of 1 beds for orthopaedic surgery in the nd with the increasing number of hip s a further increase can be expected also found that the risk of death or deterioration of social function among patients admitted from home was about 48 per cent during the 6 months following the fracture

Bearing these results in mind the goal of the treatment of hip fractures is to apply the method which with the smallest consumption of resources leads to the safest technical results and maintains at the same time the social and functional independence of the patients to the highest degree

The results of our experiences can obviously not be directly applied either to a rural district or to a country with a different social complexity Considering however, the economic crisis which every health system must face in the years immediately ahead, we feel that there is a need for comparable studies of the kind presented here

ACKNOWLEDGEMENT

Gratitude is expressed to Leif Mortensen, M Sc Department for Data Processing Herlev Hospital for invaluable help with the statistical analysis

REFERENCES

Bauer G C H (1960) Epidemiology of fracture in aged persons. *Clin Orthop* **17**, 219 225

Campbell A J (1976) Femoral neck fractures in elderly women A prospective study *Age Ageing* **5**, 102–109

Ceder L (1977) *Vårdprogram for hoftfraktur hos aldre* Ed Bauer G pp 49–52 SPRI publ no S 73 Stockholm

Ceder L Inerot, S, Lindberg L Odberg E & Sjolin C (1977) *Vårdprogram for hoftfraktur hos aldre* Ed Bauer G pp 54–56 SPRI publ no S 73 Stockholm

Clark A N G & Wainwright D (1966) Management of the fractured neck of femur in the elderly female *Geront clin (Basel)* **8**, 321–326

Cobey J C, Cobey, J H Conant L., Weil U H, Greenwald W F & Southwick W O (1976) Indicators of recovery from fractures of the hip *Clin Orthop* **117**, 258 262.

Devas, M B (1974) Geriatric orthopaedics *Brit med J* **1**, 190–192

Gylling B (1960) Collumfrakturen som socialmedicinskt problem *Opusc med (Stockh)* **5**, 178–183

Jensen J Steen & Tøndevold E A prognostic evaluation of the hospital resources required for

the treatment of hip fractures *Acta orthop scand* (In press)

Jensen, J Steen, Tøndevold, E & Sørensen, P Hove (1979) Social rehabilitation following hip fractures *Acta orthop scand* 50, 777–785

Katz, S, Ford, A B, Heiple, K G & Newill, V A (1964) Studies of illness in the aged Recovery [illegible]

patients with fracture of the hip *Surg Gynec Obstet* 124, 1219–1230

Karumo, I (1977) Recovery and rehabilitation of elderly subjects with femoral neck fractures [illegible]

McCown, P L. & Miller W [illegible] follow-up of hip fractures [illegible] *(Bgham, Ala)* 69, [illegible]

Mårtensson, L. (1962) [illegible] endamålsenlig? *Lakart.* [illegible]

Ødegård, O & Unsgård G (19[illegible]) [illegible] aspekter på patienter med [illegible] *Med* 93, 16–18.

Riska E B (1970) Factors [illegible] mortality in the treatment of [illegible] *Injury* 2, 107–115

Schenk, W G, Smith, R G & [illegible] (1956) The fractured hip [illegible] sociologic problem. *Amer J Surg* [illegible]

Thomas, T G & Stevens, R S (19[illegible]) [illegible] of fracture of the neck of the [illegible] 3, 456–458

Correspondence to J Steen Jensen, MD, Dept of Orthop Surg T-2 Gentofte [illegible] Hellerup Denmark

o scand. 51, 297–302, 1980

–ROSCOPY OF THE PATELLO-FEMORAL

3 LUND & BO E NILSSON

nt of Orthopaedic Surgery, Malmo General Hospital (University of Lund)
weden.

Arthroscopy of the knee joint was performed in 126 patients complaining of symptoms in the patello-femoral joint In about one-third of these cases the arthroscopic findings in the patello-femoral joint were normal whereas the remainder had varying degrees of chondromalacia or arthrosis The classification of changes agreed well with an independent classification carried out in conjunction with surgery In one-third of the cases there were additional findings which could explain the knee symptoms more than half of these being degenerative changes reminiscent of an early gonarthrosis located in the femuro-tibial joint There were no complications arising from the arthroscopy procedure which was well tolerated by the patients It is concluded that arthroscopy is a helpful tool for differential diagnosis in patients with patello-femoral pain and for classification of degenerative changes in this joint

Key words arthroscopy chondromalacia knee joint osteoarthritis patella

Accepted 11 vi 79

idge & Dunlop (1975) concluded that phic techniques are not very helpful diagnosis or classification of malacia in the patello-femoral joint malacia is basically a pathological-cal diagnosis which can be obtained r inspection of the joint A number of ators (Casscells 1971, Eikelaar 1975, 1973, 1974, Henry 1973, Jackson ohnson 1974, Outerbridge & Dunlop Vatanabe et al 1969, Watanabe 1974, 1973) have reported that the patello-joint can be successfully explored throscopy The purpose of this paper describe the diagnostic efficacy of opy in patients with patello-femoral ms.

d support was obtained from the Swedish Research Council (project no B –2737–09B) and the Greta and Johan d Alfred Österlund Foundations.

0 80 020?97–06$02.50 0

MATERIAL & METHODS

Patients

Included in the study were 126 patients, 64 women and 62 men The age distribution is shown in Figure 1

The criteria of patello-femoral involvement were two or more of the following symptoms

Retro-patellar pain with or without disseminated pain in the knee joint

Locking of the knee

Also two or more of the following physical findings were required

Retro-patellar crepitations

Tenderness when pressing and moving the patella

Tenderness when tapping the patella

Tenderness along the medial edge of the patella

In none of these cases was there any suspicion of recent trauma to the knee joint

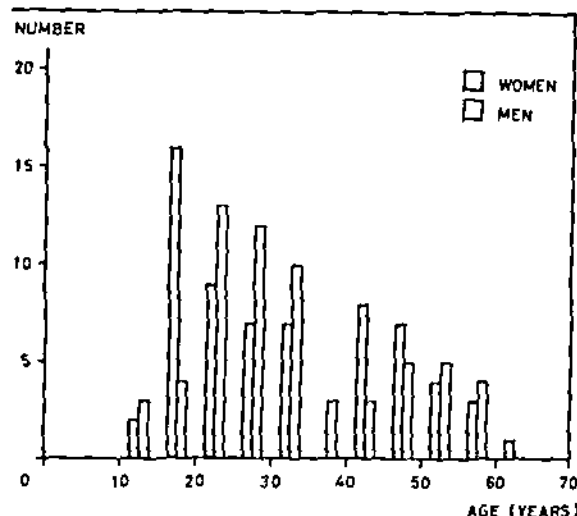


Figure 1 Age and sex distribution

Equipment

The Storz arthroscope was used The diameter of this arthroscope is 5 mm and it is supplied with two wide-angle telescope lenses with an angulation of 30° and 70°, respectively Also, the Storz fibre light source was used In 32 cases intra-articular photographs were obtained, using the Storz endo-camera and flashlight

Procedure

The arthroscopy was performed under general anaesthesia with a tourniquet on the thigh The procedure was carried out in a sterile field after preparations identical to those of an arthrotomy Either by continuous infusion or by initial injection of about 100 ml of isotonic sodium chloride solution, the knee joint was distended In the latter case, the liquid was replaced when needed Methyltheonine was added to the liquid to improve the contrast effect The incision for the arthroscope was usually 1 cm lateral and/or medial to the patellar tendon Both lenses were usually required All the studies were done on ambulatory patients. In all of these cases not only the patello-femoral joint was inspected, but a complete arthroscopic examination was carried out There were no complications arising from the arthroscopy procedure

Classification

The findings in the patello-femoral joint were classified as follows
Normal Blue-white flawless patella cartilage, fitting exactly into the patello-femoral grove



Figure 2 Example of chondro[illegible] III 32-year old man with [illegible] femoral symptoms for 10 years [illegible] and deep fissures, most of the [illegible] surface is involved
Upper Photogram obtained [illegible] arthroscope
Lower Operative finding

Chondromalacia (Outerbridge 19[illegible]

Grade I Light brown-yellow [illegible] cartilage yields to the [illegible] arthroscope or to a [illegible] no fragmentation or fissur[illegible]

Grade II Fragmentation and fissur[illegible] area of 1 3 cm or less The [illegible] lesion was estimated by [illegible] patella surface [illegible] the [illegible] the cartilage

Grade III Fragmentation and fiss[illegible] area of more than 1 3 c[illegible]

Grade IV Erosion of the articular [illegible] to the subchondral bone [illegible] cannot be d[illegible] femoral arthrosis (F[illegible]

Also post-traumatic and de[illegible] of the intra-articular structures [illegible] lamina synovialis, were recorded

[...]• 3 Example of chondromalacia grade [...] arthrosis 51-year-old man with patello[...]al symptoms of long duration, unable to [...] for 3 years A large cartilage defect with [...] bone surface is shown in the photogram [...]ied through the arthroscope
[...] Photogram obtained through the [...]oscope
[...] Operative finding

[...]rthroscopic confirmation

[...]18 of these cases an arthrotomy was per[...] either in immediate conjunction with or at [...] point in time within 3 months after the [...]scopy A few of these arthrotomies were [...] by unexpected pathological arthroscopy [...]s whereas the remainder were surgical procedures for the treatment of chondromalacia patellae

RESULTS

The patello-femoral joint

A grading of the presence and degree of chondromalacia patellae showed that 34 per cent of the cases were normal in this respect whereas 37 per cent had varying degrees of chondromalacia grade I–III In an additional 29 per cent there were changes of grade IV, indistinguishable from arthrosis of the patello-femoral joint (Table 1) The latter group, both men and women, were significantly older—about two decades—than the other cases ($P<0\ 001$) (Figure 4) Women with normal patello-femoral joints were significantly younger than women with chondromalacia of grades II and III ($0\ 05>P>0\ 02$)

Other findings

In no less than 35 per cent of the patients there were findings outside the patello-femoral joint which could be suspected to produce pain (Table 2) In 24 joints there were signs of degenerative changes which could be interpreted as gonarthrosis in the tibio-femoral joint These patients were significantly older than the remaining cases ($P<0\ 001$) (Table 2) All but five of the cases with changes resembling gonarthrosis also had grade IV changes in the patello-femoral joint The distribution of changes between the three articulations of the knee joint is demonstrated in Figure 5

In another 20 joints there were altogether 28 pathological findings as described in Table 3

Table 1 Age, sex and distribution in grades of chondromalacia patellae (Number/age, average ± s d)

	Normal	Chondromalacia patellae			
		Grade I	Grade II	Grade III	Grade IV/arthrosis
[illegible]	30/26 8	1 6	[illegible]/29 8	11/27 7	17/49 9
[...]en	23/23 7	[illegible] 6	6/3[illegible] 11	14/27 9	19/50 9

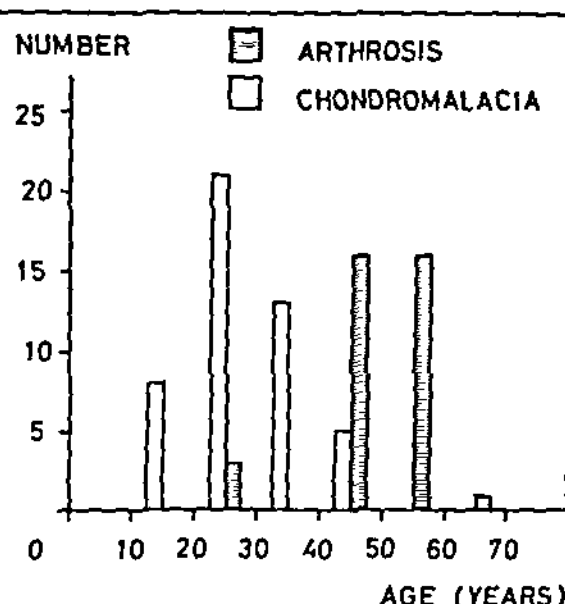


Figure 4 Age distribution of patients with arthrosis and chondromalacia

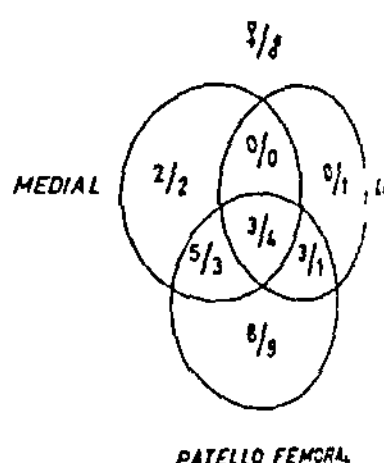


Figure 5 Distribution of degenerative [illegible] in the various compartments of the knee [illegible] chondromalacia patellae [illegible] excluded

Table 2 Arthroscopic findings in the knee joint outside the patello femoral joint (Number/age average ± s d)

	Degenerative changes	Other
Men	$^{11}/_{44}$ 12	$^{10}/_{27}$ 8
Women	$^{13}/_{47}$ 8	$^{10}/_{30}$ 16

Confirmation at surgery

The classification of patello-femoral changes was repeated in conjunction with the surgical procedure The grade of changes in the patello-femoral joint was confirmed in all but four of the 58 joints [illegible] originally classified as normal, the [illegible] was changed to chondromalacia [illegible] patients were changed from grade [illegible] III, and finally one from grade [illegible] femoral arthrosis—to normal [illegible] instances the other findings [illegible] confirmed at surgery [illegible] injuries were verified. In one case [illegible] as normal in the medial femoro[illegible] medial arthrosis was found [illegible] Osteochondral fractures of the [illegible] diagnosed in two cases, [illegible] could be confirmed at surgery [illegible] were classified as chondromalacia [illegible] and III, respectively In one case [illegible] classified as a chondromalacia [illegible]

Table 3 Other arthroscopic findings and their coincidence with chondromalacia [illegible]

	Normal	Grade I	Grade II	Grade III	Grade IV
Torn medial meniscus	3			1	1
Torn lateral meniscus	3		1		
Ruptured anterior cruciate ligament	1				
Plica fibrotica synovialis	2	1		1	1
Rheumatoid arthritis				1	
Osteochondral fracture	1				
Meniscus discoides	1				1
Loose bodies	1				
Morbus Hoffa	5	1			

changes suggestive of osteochondral were also found

SSION

it one-third of the cases, changes in s other than the patello-femoral joint ound Chondromalacia patellae and patello-femoral processes may be n for lesions of the medial semilunar (Outerbridge & Dunlop 1975, Smillie Obviously, the reverse is also true believed to have a chondromalacia ideed found to have lesions of the ar cartilages with or without visible in the patello-femoral joint Plica a synovialis (Watanabe 1974) was n four cases This is a fibrous string originates on the anterior aspect of the rosses the edge of the femur condyle en breaks up into diverging portions ontinue into the fibrous capsule

use of the tourniquet, an evaluation of idition of the lamina synovialis was However, synovitis was frequently in conjunction with gonarthrosis were no synovial changes suggestive of infection, chondromatosis or ited villonodular synovitis Biopsy or ctomy was not undertaken

nty five patients—19 per cent—were pathological findings at arthroscopy in contrast to Leslie & Bentley (1977), ound normal joints in 49 per cent of s examined with arthroscopy because suspicion of chondromalacia patellae authors therefore suggested that al signs were more helpful in the sis. The age of the 25 patients without ogy was 25 ± 8 and 22 ± 5 for men and n respectively Among these patients were slightly but not significantly er than the chondromalacia cases, there six with signs of synovitis discoloration ypertrophy

anges suggestive of early gonarthrosis ilage fibrillation and erosion—were in the femuro-tibial joint in no less than 24 of the patients and at about two decades earlier in life than the usual age for the initial examination of patients with gonarthrosis (Hernborg & Nilsson 1977) The localization differed to some extent from that usually found in primary gonarthrosis there being less preponderance for the medial aspect of the joint (Hagstedt 1974) In the older of the arthroscopy patients, half or more of the cases had such changes Since the accumulated risk of gonarthrosis in the city of Malmo barely exceeds 5 per cent (Danielsson & Hernborg 1970) two possibilities must be considered Either pain in the patello-femoral joint is a sign, early in life, indicating that the patient will develop gonarthrosis later on or we are dealing here with degenerative changes of the cartilage, unrelated to gonarthrosis in its generally accepted sense

Arthrosc ... for the ... degenerativ ... joint Arthrotomy and direct inspection of the patella appears to add little further information It should be noted however, that the selection of the 58 patients for arthrotomy in this study was usually based on pathological arthroscopy findings in the patello-femoral joint or elsewhere, whereas completely normal joints were rarely operated on False negatives therefore cannot be entirely ruled out

REFERENCES

Casscells S W (1971) Arthroscopy of the knee joint *J Bone Jt Surg* **53 A** 287–298

Danielsson L & Hernborg J (1970) Morbidity and mortality of osteoarthritis of the knee (gonarthrosis) in Malmo Sweden *Clin Orthop* 69, 223 226

Eikelaar H R (1975) *Arthroscopy of the knee* Royal United Printers Hoitsema B V, The Netherlands

Hagstedt, B (1974) High tibial osteotomy for gonarthrosis. Thesis, University of Lund Sweden

Henche H R (1973) Rezidivierende Patellaluxationen und Praarthrose des Patello-Femoralgelenkes. *Z Orthop* **111**, 523–525

Henche, H R (1974) Indikation, Technik und Resultate der Arthroskopie nach Traumatisierung des Kniegelenkes *Der Orthopäde* 3, 178–183

Henry, A (1973) Arthroscopy of the knee joint *Guy's Hosp Rep* 121, (72) 25

Hernborg, J S & Nilsson B E (1977) The natural course of untreated osteo-arthritis of the knee *Clin Orthop* 123, 130–137

Jackson, R W (1974) The role of arthroscopy in the management of the arthritic knee *Clin Orthop* 101, 28–35

Johnson, L L (1974) Diagnostic arthroscopy of the knee American Academy of Orthopedic [illegible]

Le[illegible] in [illegible] nn [illegible] *rheum Dis* 36, 287

Outerbridge, R E (1961) The [illegible] chondromalacia patellae *J Bone J* [illegible] B 752–757

Outerbridge R E & Dunlop, J [illegible] problem of chondromalacia patellae [illegible] *Orthop* 110, 177–196

Smillie, I S (1974) *Diseases of the* [illegible] Churchill Livingstone Edinburgh [illegible]

Watanabe, M, Takeda S & Ikeuchi [illegible] *Atlas of arthroscopy* second [illegible] Shoin Ltd, Tokyo

Watanabe, M (1974) Arthroscopy of [illegible] joint *Disorders of the knee* [illegible] B Lippincott Company Philadelphia [illegible]

Wruhs, O (1973) Endoskopische [illegible] Veranderungen des Femur [illegible] *Orthop* 111, 525–526.

Correspondence to Bo Nilsson, M D, Department of Orthopaedic Surgery, Malmo General [illegible]
214 01 Malmo, Sweden

op scand, 51, 303–309, 1980

JLTS AFTER MENISCECTOMY IN 147 ATHLETES

ONNE-HOLM, INGER FLEDELIUS & NIELS C N AHN

ent of Orthopaedic Surgery T-3 and Department of Diagnostic Radiology,
Hospital Copenhagen, Denmark

The object of this study was to ascertain the consequences of meniscectomy performed because of meniscus injury sustained during sports. Out of 147 athletes meniscectomized from 1964 to 1973 a total of 142 were seen at follow-up The median follow-up period was 4 25 (range 2 25–11 0) years During the follow-up period 8 per cent (11/142) had further surgical treatment because of new knee injuries. At the time of follow up, 15 per cent (20/131) of the patients who had undergone operation solely for the primary meniscus injury had given up sports because of knee complaints and 12 per cent (16/131) had restricted their sporting activities. There were no complaints in 46 per cent (60/131) In 79 per cent (56/71) of the patients who had complaints, these had started immediately after operation The main trouble was a feeling of instability and pain on weight-bearing The complaints correlated with the physical findings at follow-up In 14 per cent (18/131) there was increased collateral instability of the knee Considering also previous experimental studies, it is concluded that meniscectomy causes immediate functional changes in the knee which explain the complaints. There was no correlation between complaints and radiological osteoarthrosis.

Key words athletic injuries, meniscectomy osteoarthrosis

Accepted 30 vii 79

to the knee is a dreaded athletic injury, is often followed by persistent knee ns in spite of early diagnosis and ent (Appel 1970, Christophe & Leard Jacobsen 1977) The incidence of knee s is definitely higher among athletes – lly football players – than among s who do not participate in sports & Andersson 1977)

ry to the meniscus is the most common f injury sustained by athletes (Andersen 1959) In analyses of meniscectomized ts between 28 and 69 per cent of the us injuries are reported to have been ned in sports (Appel 1970, Bestle 1955, hmidt & Crasselt 1973, Johnson et al Parry et al. 1958, Perey 1962, Rothascher 1960), and this indirectly confirms that injury to the meniscus is common among athletes.

The late results of meniscectomy have varied from one analysis to the other, presumably because of differences in the materials, diagnostic methods, and systems of grading complaints and physical findings. In previous studies no distinction was made between athletes and non-athletes. However, the former differ in that they have a younger mean age, and they make greater demands on the knee in connection with continued athletic activities.

The present analysis was designed to investigate the consequences of removing a meniscus from an otherwise normal knee in

4'0 80 020303–07$02.50 0

athletes, assessed in terms of subjective complaints and physical and radiological findings

PATIENTS AND METHODS

During the period 1964–73 meniscectomy was performed on 439 patients in the Department of Orthopaedic Surgery T-3, Gentofte Hospital, Copenhagen The analysis is based upon the 147 patients who had sustained athletic injury to one meniscus in an otherwise normal knee Out of these patients 142 were seen at follow-up in 1975 Two had emigrated, one had died, and two could not be traced The *operative technique* was according to the principles of Smillie (1970) *Postoperatively* quadriceps exercises were started not later than 24 hours after the operation When the patients could lift the extended leg, weight-bearing with extended knee was permitted until the sutures were removed on the 10th day, and thereafter the patients were trained in knee-bending and exercises against resistance

The median age at operation was 25 years, range 14 to 56 years. The ratio males to females was 6 3, right to left-sided injuries 1 03 and medial to lateral injuries 5 7 Six patients underwent partial and all the others total meniscectomy

Follow-up examination performed by two of the authors consisted of an interview, a physical examination, and radiography of both knees The follow-up period, defined as the period from meniscectomy to the follow-up examination, ranged from 2 years 3 months to 11 years, median 4 years 3 months The median length of the history, defined as the time from the athletic injury or from the onset of the [illegible] operation, was 6 months (range [illegible]

Table 1 shows the branches [illegible] pursued by the patients [illegible] sustained

Complaints were assessed [illegible] system and included the following [illegible] swelling of the knee, 1 point [illegible] and down stairs, 2 points [illegible] 3 points, pain on weight-bearing 4 [illegible] of locking, 5 points rest pain, 6 [illegible] from symptoms gave 0 points and [illegible] symptoms 21 points.

The *physical examination* of the [illegible] six parameters (Table 3). [illegible] was defined as a sign of patella tap [illegible] condyle More than 5° reduction [illegible] as compared with the opposite leg [illegible] as reduced mobility Collateral [illegible] drawer sign, and tenderness [illegible] assessed in relation to the opposite [illegible] of the quadriceps muscle was [illegible] reduction of more than 2 cm in the [illegible] of the thigh, measured 10 cm above [illegible] the patella, in relation to the [illegible]

Radiography comprised [illegible] lateral views of both knees, with [illegible] weight bearing The focus-film [illegible] The radiologist read the films [illegible] the results of the other investigations [illegible] of degenerative changes in the [illegible] was according to the principles of [illegible] Osteoarthrosis was defined as [illegible] joint space and/or changes of the [illegible] form of sclerosis or cyst forma[illegible] was narrowed if (i) it was less than half [illegible] measured in the other joint compartment [illegible] corresponding joint compartment [illegible]

Table 1 Type of sport being pursued at the time of injury (n = 14[illegible]

	Level of athletics x)		
	Top	Competitive	Recreational
Football	17	48	15
Handball + basketball	6	14	3
Gymnastics	0	2	8
Athletics	3	2	2
Badminton	1	4	0
Swimming	1	1	2
Others	1	2	10
	29	73	40

x) Top Tournaments in the 1st and 2nd division or a higher level.
Competitive Official tournaments at a lower level
Recreational Others.

i) it became narrower when the patient
ading or (iii) it was less than 3 mm in
In addition, marginal osteophytes and
g of the femoral condyles were recorded
k 1948)
2 cases preoperative routine films of the
knee were available These films were read
ame way as described above

cal methods

parametric statistical tests were used In
n tests of complaints the patients were
according to individual score

TS

rative complications

itient developed pyarthrosis, one deep
ophlebitis, and one a wound infection
were no late sequelae of these com-
ns at follow-up One patient developed
synovitis, which was later treated by
ctomy Puncture of the knee for
rative effusion was carried out in 50

njuries in the course of the follow-up

ng the follow-up period 8 per cent
2) (95 per cent confidence limits 4–14
it) had operations on the knees because
her injuries, five of which were due to
ed athletic activities Three sustained
s to the operated knee (one ligament
wo meniscus injuries) and eight to the
te knee (two ligament tears and nine
cus injuries)
analyses to be reported below com-
nly the 131 patients who had undergone
ion solely for the primary meniscus

es in athletic activities

een per cent (20/131) had given up all
c activities because of the complaints
ing meniscectomy, while 12 per cent
1) had restricted their activities by
pursuing sports at a lower level and/or changing to a less vigorous branch of sport

The 27 per cent (36/131) (95 per cent confidence limits 20–36 per cent) with altered sports activities had significantly more subjective complaints than those whose activities were unchanged ($P < 0.002$, Mann-Whitney test) Sex, age, branch of sport, level of sport, and site of the injured meniscus had no influence ($P > 0.7$, 0.4, 0.8, 0.6, and 0.05, respectively, χ^2 tests)

Complaints

Table 2 lists the incidence of the individual symptoms The distribution of the scores for complaints (Figure 1) shows that 46 per cent (60/131) reported no complaints, while 12.2 per cent (16/131) had a score of ≥ 10 Only one patient had started on another job because of knee complaints

In order to screen for prognostic variables, the distribution of the scores in various subgroups was compared (Table 2) Neither age at operation, length of history, branch of sport, level of sport, postoperative effusion, nor the localization of the injured meniscus had any significant influence On the other hand, women had significantly more complaints than men

There was no correlation between the length of the follow-up period and the score for complaints, although there was a tendency for patients with a short follow-up period to have more complaints than patients with a long follow-up period The two groups of patients, with a short and a long follow-up period, were considered comparable, as the above-mentioned variables were equally distributed in both groups (all P values > 0.2)

The complaints had been present in 79 per cent (56/71) since the operation

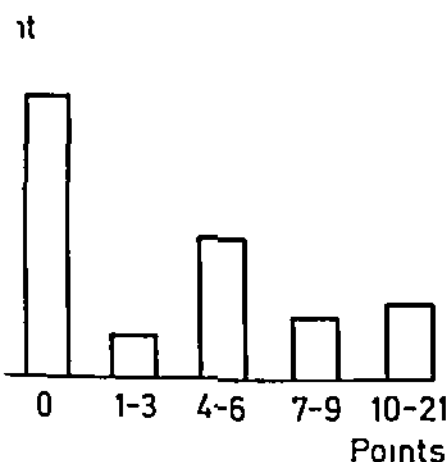
Physical findings

The frequency of abnormal findings compared with the severity of complaints is apparent from Table 3 In 62 per cent (81/131) there were no abnormal findings,

Table 2 Complaints in the various groups of patients

		Total	Women	⩽ 25 years	History ⩽ 6 months	Football players	Recreational	Effusion postop	Lateral meniscus	Follow up ⩽ 47 months
Number of patients	(no)	131	18	72	65	73	90	44	20	63
Swelling of the knee	(%)	20 6	33 3	25 0	20 0	21 9	22.2	22 7	20 0	17 5
Complaints on walking stairs	(%)	15 3	33 3	12 5	15 4	9 6	27 8	22 7	10 0	12 7
Sensation of instability	(%)	20 6	44 4	23 6	13 9	16 4	27 8	25 0	15 0	22 2
Pain on weight bearing	(%)	38 2	55 6	38 9	30 8	31 5	38 9	43 2	35 0	47 6
Episodes of locking	(%)	6 1	16 7	6 9	4 6	5 5	5 6	4 6	5 0	11 1
Rest pain	(%)	11 5	22 2	9 7	12 3	8 2	13 9	9 1	0 0	14 3
Median score		2	4	2	0	0	3	4	0	4
P value ⩽		—	0 04*	0 6*	0 95**	0 3*	0 7***	0 26*	0 45*	0 1**

* Mann Whitney U test
** Spearman rank correlation test
*** Kruskal Wallis test



Complaints Distribution of score for 131

patient had more than three There definite correlation between the of abnormal findings and the score of ints

raphy

ng the 102 patients for whom *pre-ve films* of the operated knee were le two had marginal osteophytes at the the injured meniscus, but all the others changes

osures of the *non operated knee* at up showed that five patients had ial osteophytes, two narrowing of the joint space, and one osteochondritis In 95 per cent (125/131) the radiological appearances were normal Forty per cent (53/131) had no radiological changes on the *operated* side at follow-up The changes in the other patients are illustrated in Table 4

Osteoarthrosis according to the criteria of Ahlback was present in 30 patients, 26 of whom had narrowing of the joint space, two sclerosis, and two both of these signs In addition, loose bodies were found in eight and osteochondritis in five

As compared with changes in the control knee, there was a significantly higher incidence of changes in the operated knee ($P < 0\ 001$, signs test)

There was no correlation between the length of the follow-up period and the presence of radiological changes ($P > 0\ 5$, χ^2 test)

The degree of complaints showed a significantly positive correlation to the number of Fairbank changes On the other hand, it was not possible to demonstrate a correlation between osteoarthrosis and complaints (Table 4)

DISCUSSION

Oretorp et al (1978) studying experimentally in dogs the immediate effect upon the knee of meniscectomy, reported that the removal of a

Table 3 Physical findings (n = 131)

	Per cent	Median score for complaints	
on in the knee	1 5	10	
ed mobility	6 1	7 5	
eral instability	13 7	6 5	
r sign	9 9	5	
rness on joint line	11 5	10	
iceps atrophy	8 4	7	
ysical finding	61 8	0	$P \ll 0\ 001$ (Spearman correlation test)
hysical finding	26 7	4	
hysical findings	9 9	10	
physical findings	1 5	13	

Table 4 Radiography

	Per cent	Median score for complaints	
Flattening of femoral condyle	51 9	4	
Marginal osteophytes	39 7	4	
Narrowing of joint space	21 4	2.5	
Number of Fairbank changes			
0	40 5	0	P < 0.0[illegible] correlation [illegible]
1	17 6	3	
2	30 5	4	
3	11 5	4	
Osteoarthrosis	22 9	1 5	P < 0 [illegible]
No osteoarthrosis	77 1	2	

meniscus resulted in increased laxity in the knee joint, indicating that the meniscus carried out a weight-bearing function The laxity was greater after medial meniscectomy, presumably due to the anatomical relationship between the medial meniscus and the deep fibres of the medial collateral ligament

Among the present meniscectomized athletes, 21 per cent complained of a sensation of instability, and at follow-up 14 per cent had collateral instability which must be interpreted as a sequelae to the meniscectomy as patients with ligament injuries observed at operation were excluded Thus, the clinical findings support the hypothesis of the weight-bearing function of the meniscus The increased instability may be a contributory cause of the high incidence of new knee injuries after meniscectomy In the course of the follow-up period median 4 years 3 months 8 per cent sustained new knee injuries This is a high incidence of injuries, even among athletes. Among 108 randomly selected men in the age range 30–40 representing the population of males of this age in Gothenburg Sweden Roaas & Andersson (1977) found that 6 per cent had had meniscus injuries and 4 per cent ligament injuries at some time or other

Previous authors have analysed the complaints after meniscectomy by grading systems in which each sympt[illegible] score according to the degree of [illegible] the individual patient (Appel [illegible] al 1974, Tapper & Hoover [illegible] definitions of grading the [illegible] often been vague and the grading [illegible] based upon an estimate Th[illegible] difficult for subsequent investi[illegible] the same grading systems and [illegible] parable results. In the present [illegible] a system in which the sympt[illegible] graded mutually a priori and [illegible] could merely confirm or reject the [illegible] The system has proved appl[illegible] be considered reproducible

It was not possible to detect [illegible] relation between the length of the [illegible] period and the complaints [illegible] agrees with previous findings (Ⅰ[illegible] Johnson et al 1974 Tapper & Ho[illegible] By 79 per cent it was stated th[illegible] plaints had been present [illegible] injury It is most likely [illegible] plaints after meniscectom[illegible] functional disturbances and [illegible] changes which would be expected [illegible] with time Indeed there was [illegible] between complaints and radiolo[illegible] arthrosis.

The complaints following [illegible] made 27 per cent of the [illegible] restrict their athletic activ[illegible] The[illegible]

...f patients in whom the athletic ...s were influenced more than in other ... In particular, the branch or level of ...rt had no influence Such a high ...y of altering activity stresses that the ... of a meniscus entails a radical ...n knee function, manifesting itself in ...imum strain which occurs in perform...t The design of the present study ...t permit conclusions as to whether it ...sable to continue athletic activities ...eniscectomy, but considering that 46 ... did not have complaints and that it ... possible to predict which groups of ... would develop complaints, it seems ...ble to advise resuming sports after the ...rative restitution of the quadriceps

... six patients in the present material ...d partial meniscectomy, and it is not ... to compare the results of partial and ...meniscectomy A few previous in...ions have demonstrated good results ...tial meniscectomies (Streli 1955 ... & Hoover 1969), but a definite ... to the choice partial/total meniscec...must await the results of controlled ... studies

...OWLEDGEMENT

...udy was aided by grants from the Danish ... Medical Research Council

...RENCES

...en, P T & Bøje, O (1959) Idraetsskader ...aringer fra D I F's idraetsklinik i ...penhavn *Ugeskr Laeg* 121, 430–434

Ahlback, S (1968) Osteoarthrosis of the knee A radiographic investigation *Acta radiol*, Suppl 277

Appel, H (1970) Late results after meniscectomy in the knee joint A clinical and roentgenologic follow-up investigation *Acta orthop scand*, Suppl 133

Bestle, S (1955) Meniskusschaden und Sport *Med Klin* 50, 283–284

Christophe, K & Leard, S (1970) A follow-up study of athletic injuries *J Amer Coll Health Ass* 18, 210–212

Durrschmidt, von V & Crasselt, C (1973) Die Stellung des Storts in der Pathogenese der Meniskusverletzung *Beitr Orthop Traum* 20, 270–276

Fairbank, T J (1948) Knee joint changes after meniscectomy *J Bone Jt Surg* 30-B, 664–670

Jacobsen, K (1977) Osteoarthrosis following insufficiency of the cruciate ligaments in man *Acta orthop scand* 48, 520–526

Johnson, R J, Kettelkamp D B, Clark, W & Leaverton P (1974) Factors affecting late results after meniscectomy *J Bone Jt Surg* 56-A, 719–729

Oretorp, N, Alm, A Ekstrom, H & Gillquist, J (1978) Immediate effects of meniscectomy on the knee joint *Acta orthop scand* 49, 407–414

Parry, C B W, Nichols, P J R & Lewis, N R (1958) Meniscectomy – A review of 1723 cases. *Ann Phys Med* 4, 201–215

Perey, O (1962) Follow-up results of meniscectomy with regard to the working capacity *Acta orthop scand* 32, 457–460

Roaas, A & Andersson, G B J (1977) Knee injury rate in football players and in the population at large *Acta orthop scand* 48, 223

Rothascher, H (1960) Ergebnisse nach vollstandiger Meniscusentfernung *Langenbecks Arch klin Chir* 294, 118–134

Smillie, I S (1970) *Injuries of the knee joint* 4th ed Churchill Livingstone, Edinburgh, London and New York.

Streli, R (1955) Spatergebnisse nach partieller Meniscusresektion bei 83 Fallen *Chirurg* 26, 97–103

Tapper, E M & Hoover, N W (1969) Late results after meniscectomy *J Bone Jt Surg* 51-A 517–526

...spondence to Stig Sonne-Holm, Ledreborg Allé 40 DK 2820 Gentofte, Denmark

op scand 51 311–313 1980

GENITAL POSTEROMEDIAL BOWING HE TIBIA

ADAV & SARA THOMAS

ent of Orthopaedic Surgery, Jawaharlal Institute of Postgraduate Medical Education and n Pondicherry, South India

Posteromedial bowing of the leg is a rare entity and only a few cases have been described in the literature A report is made of six patients with this deformity Except for one severe case requiring anterior soft tissue release the deformity was corrected in all patients by repeated application of plaster casts A conservative approach to the management of this condition is advocated

Key words congenital deformity kyphoscoliotic tibia posteromedial bowing tibia

Accepted i vii 79

y and associates (1952) coined the term ntal kyphoscoliotic tibia" for congenital tion of the tibia with anterolateral or omedial curvature The posteromedial g is an entity which is more uncommon ne anterolateral one and only a few cases een reported (Heyman & Herndon 1949, 1951, Rathgeb et al 1974) Frequently is a calcaneovalgus deformity of the eral foot and the dorsum of the foot y touches the lower third of the leg e 1) Roentgenologically there is a ic area at the site of the deformity, which e marked on the concave side of the curve e 2)

this presentation six cases of omedial bowing of the leg treated ssfully are reported

ENTS AND METHODS

g the period 1974 to 1978 six patients with ntal kyphoscoliotic tibia were observed patients were males and three females. Their ages ranged from 22 days to 90 days. In all the cases the lesion was on the left side The diagnosis was based upon clinical observations and radiological findings Five cases had associated

other five patients were managed conservatively with plaster casts applied at intervals of 4 weeks A total of six to eight casts were sufficient to achieve an adequate correction of the deformity The patient shown in Figures 1 and 2 demonstrated complete clinical and radiological correction of the deformity after a follow-up of 4 years (Figures 3 and 4)

DISCUSSION

In the medical literature there is an emphasis on the anterolateral type of kyphoscoliotic tibia due to its association with pseudoarthrosis and neurofibromatosis (Aegerter 1950, Badgley et al 1952, Gwim & Barnes, 1967, Hardinge 1972, Rathgeb et al 1974, Newell & Durbin 1976) Posteromedial bowing of the tibia is a benign condition

5470 80 030311–03$02.50/0



Figure 1 Congenital posteromedial bowing of the left leg showing the typical deformity



Figure 2 Roentgenogram of the [illegible] the les on in the lower one-th[illegible] of [illegible] fibu la



Figure 3 The same leg 4 years after correction of the deform ty




Figure 4 Roentgenogram of the [illegible] complete correction of the lesion

esponds adequately to plaster casting cing (Heyman et al 1959, Newell & 1976) As both sides are equally prone eformity, it may be a coincidence that patients had left-sided pathology Five cases were corrected by serial plaster and only one case with a severe ty needed a prior anterior soft tissue None of these cases revealed signs rofibromatosis The calcaneovalgus de- of the foot was fully corrected but ll show a moderate impairment in l The residual leg length discrepancy quire arrest of growth on the con al side (Krida 1951, Rathgeb et al Since all our patients are too young odesis is not considered appropriate at ge

OWLEDGEMENT

thors are greatful to Dr M N Ghosh r Jawaharlal Institute of Post Graduate l Education and Research Pondicherry for mission to publish this paper

REFERENCES

Aegerter, E D (1950) The possible relationship of neurofibromatosis congenital pseudoarthrosis and fibrous dysplasia *J Bone Jt Surg* 32 A 618

Badgley C E O Connon S J & Kunder D F (1952) Congenital kyphoscoliotic tibia *J Bone Jt Surg* 114, 401 402

Gwim J L & Barnes G R (1967) Radiological case of the month Congenital kyphoscoliotic tibia *Amer J Dis Child* 114, 401–402

Hardinge K (1972) Congenital anterior bowing of the tibia *Ann roy Coll Surg Engl* 51, 17 30

Heyman C H & Herndon C H (1949) Congenital posterior angulation of the tibia *J Bone Jt Surg* 31-A 571–580

Heyman C H Herndon C H & Heiple K G (1959) Congenital posterior angulation of the tibia with talipes calcaneus *J Bone Jt Surg* 41-A 476–488

Krida A (1951) Congenital posterior angulation of the tibia A clinical entity unrelated to congenital pseudoarthrosis *Amer J Surg* 82, 98–102

Miller B F (1951) Congenital posterior bowing of the tibia with talipes calcaneo-valgus *J Bone Jt Surg* 33-B 50–55

Newell R L M & Durbin F C (1976) The etiology of congenital angulation of tubular bones with constriction of the medullary canal and its relationship to congenital pseudoarthrosis *J Bone Jt Surg* 58-B 444 447

Rathgeb J M Ramsey P L & Cowell H R (1974) Congenital kyphoscoliosis of the tibia *Clin Orthop* 103, 178–190



Figure 1 Congenital posteromedial bowing of the left leg showing the typical deformity



Figure 2 Roentgenogram of the [illegible] the lesion in the lower one-[illegible] fibula



Figure 3 The same leg 4 years after correction of the deformity



Figure 4 Roentgenogram of the [illegible] complete correction of the lesion

p scand. 51, 315–320, 1980

VTH DISTURBANCE FOLLOWING FRACTURE HE TIBIA IN CHILDREN

GREIFF & FINN BERGMANN

ιent of Orthopaedic Surgery T–2, and Department of Radiology, Gentofte Hospital, Gentofte,

Orthoradiographs were produced from 13 to 36 months after tibial fractures in 85 children Fifty-nine were complete i e transverse or longitudinal, and 28 fractures were incomplete i e infractions or fissures The difference in the length of the tibia from growth disturbance caused by the fracture was found to be related to the age of the child at the time of fracture and the sex. An overgrowth was found to occur in the age group from 3 to 10 years in girls and from 3 to 12 years in boys, whereas in the older children a growth retardation was demonstrated No correlation with the type of fracture, or with the residual angulation after reduction, could be established The growth dis- [illegible]

Key words children, growth disturbance, tibial fracture

Accepted 11 vi 79

'e induced disturbance of the dinal growth rate of a long bone in g persons was first studied by Ollier (for review see Guldhammer 1963, öm 1969) The rather unconcerned e regarding the need for an exact on of fractures of long bones in n, which had been widely accepted iallenged by Swaan & Oppers (1971) n et al, in their 1976 study, showed t a fracture site, a spontaneous correc- f an angular deformation of more than cent of the original deformity cannot bected, irrespective of the child's age at ne of fracture The aim of this study is cuss the fracture induced disturbance of h as it relates to age, sex, type of re, residual angulation after reduction he duration of the disturbance in tibia femur following a tibial fracture in ıood

PATIENTS AND METHODS

This study included a total of 85 patients from 1–15 years of age with complete and incomplete

56 boys and 29 girls with 33 transverse fractures, 24 longitudinal fractures (classified according to Edwards 1965), 14 fissures and 14 infractions. The age distribution and sex ratio are given in Figure 1 All the patients were treated conservatively in a plaster cast. The time taken for union to be established was assumed to coincide with the time until removal of the cast which ranged from 2 to 18 weeks after the accident By regression analysis it was demonstrated that the time required for union increased significantly with increasing age

At 13 to 36 months (average 25 2 months) after the fracture all prior X-ray pictures were reviewed and any shortening at the time of union was estimated Anteroposterior and lateral X-rays were taken of the tibia, and the angular deformity was measured as the angle between the axis of the

ı470, 80, 020315–06$02.50/0

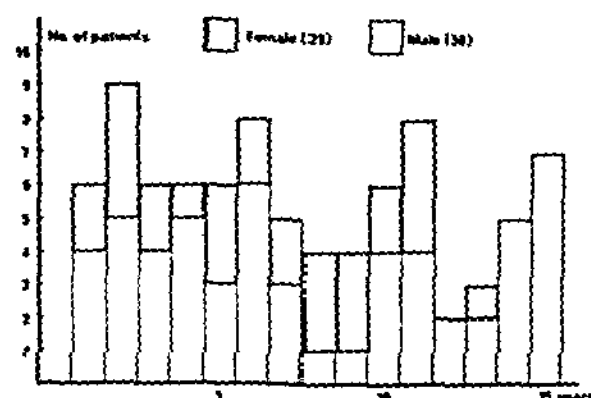


Figure 1 Age distribution and sex ratio

diaphyseal fragment proximally and distally to the fracture site, without regard to apposition and resorption at this level (Hansen et al 1976) The angular deformity was stated as the sum of the angulation in the anteroposterior and lateral views.

Spot-orthoradiography was performed to a reading accuracy of 1 mm Spot-orthoradiography was accomplished in the following manner The patient was placed supine on a large X-ray film with the legs stabilized by a couple of small sand bags. By focusing successively on the hip, knee and ankle joints separate exposures on the film were obtained of each joint. The distance between the X-ray tube and the object was about 1 5 m Measurements on the film of the length of the tibia then indicated the real length of the bones. (Taillard 1956) Healing shortening, if any, was deducted from the measurements obtained from the spot-orthoradiographs.

F tests and t tests were employed for the statistical analysis.

RESULTS

The tibial growth-determined discrepancy induced by the fracture varied between −9 and +9 mm

Age at the time of fracture

The growth-determined mean difference in tibial length in relation to age at the time of the accident is given in Figure 2 In the age group 1 to 2 years, the mean tibial difference was close to zero, whereas a growth stimulation (+ 4 2 mm) occurred in the age group 3 to 5 years. The difference between the two

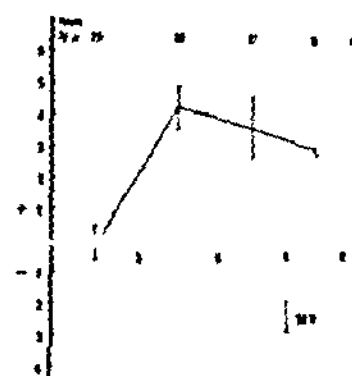


Figure 2 The mean growth [illegible] the length of the tibia in mm [illegible] (standard error of the mean) [illegible] of the child at the time of fracture [illegible] N = numbers of patients in the group

groups was statistically [illegible] 0 001) With increasing age the stimulation appeared to [illegible] example, in the age group 12 t [illegible] overgrowth was found to be [illegible] 15-year-olds (boys) showed a [illegible] tion The differences in the [illegible] three age groups 9 to 11 years [illegible] years and 15 years were [illegible] cant ($P < 0.01$ and $P < 0.0$[illegible]

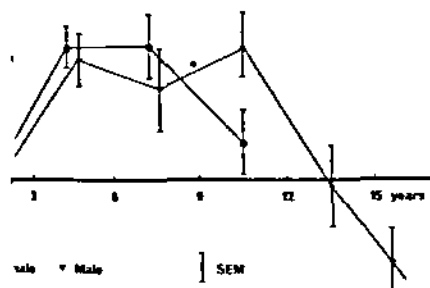
Sex

The growth-determined mean [illegible] in tibial length in mm in the [illegible] females in the different age groups [illegible] in Table 1 No significant d[illegible] the growth stimulation in [illegible]

Table 1 The mean growth [illegible] tibial length in mm correlated to [illegible] age groups

Age in years	n	Female mean	SEM	n	[illegible]
1 2	6	−1 66	1 0[illegible]	9	[illegible]
3 5	6	4 50	0 [illegible]1	12	[illegible]
6 8	7	4 [illegible]7	1 13	1[illegible]	[illegible]
9 11	9	1 33	1 10	4	[illegible]
12 14	1	–	–	[illegible]	[illegible]
15	0	–	–		

SEM standard error of the mean
* indicates $P < 0.05$



The mean growth induced difference in ...gth in mm (ordinate) and SEM (standard ...he mean) correlated to the age of the boys ▼ ● at the time of fracture (abscissa) cf ...r numbers of patients in the groups

...nd below the age of 9 years, but a ...ntly ($P < 0.05$) reduced overgrowth ...l after fracture in girls aged 9 to 11 ...igure 3)

... fracture

...r the age of 3 years, 86 per cent of the ...s were incomplete A comparison of ...al difference caused by the various ... fractures was made for children from ...years of age The correlation between ...e of fractures and the growth stimula...is not statistically significant (Table 2)

...tion at the time of union

...influence of angulation on the growth ...ition was studied in the children ...n the ages of 3 and 8 years. Even ... angulation appeared to induce an

...2 The mean growth induced difference in ...ngth in mm correlated to the type of fracture in children aged 3–8 years

...f fracture	n	mean	SEM
...plete	8	4 37	1 23
...erse	15	4 53	0 94
...udinal	12	3 00	0 74

... = standard error of the mean

Table 3 The mean growth induced difference in tibial length in mm correlated to angulation at the time of union in children aged 3–8 years

Angulation at time of union	n	mean	SEM
4–19 degrees	11	5 01	0 87
none	24	3 45	0 68

SEM standard error of the mean

increased growth stimulation, the difference between the mean tibial difference in angulated and non-angulated fractures was not statistically significant (Table 3)

Duration of the growth disturbance

The patients were divided into two groups, those who had been observed for less than 2 years and those observed for more than 2 years The distribution as regards age and sex of the two groups was comparable No statistically significant difference between the growth-induced mean tibial difference in the two groups could be found (Table 4)

The femur

The mean growth-determined difference in femur length for the 57 patients with complete tibial fractures is shown in age groups in Figure 4 The pattern of growth stimulation/retardation seen in the tibia appears to be also valid for the growth-response in the femur

Table 4 The mean growth induced difference in tibial length in mm correlated to the period of observation The two groups are comparable (Fourfold Table), and five girls over the age of 9 years appear in each group

Period of observation	female	male	mean age	mean difference in tibial length
< 2 years	14	26	7 07	2.67 ± 0 63
> 2 years	15	30	7 73	1 62 ± 0 54

SEM standard error of the mean

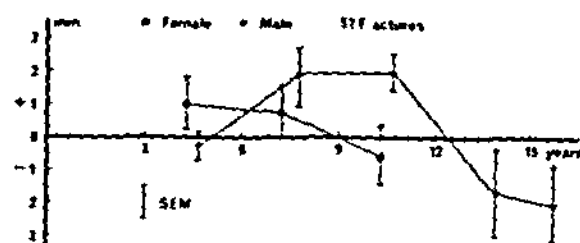


Figure 4 The mean growth induced difference in femur length in mm (ordinate) and SEM (standard error of the mean) correlated to the age of the boys ▼ and girls ● at the time of tibial fracture (abscissa)

A statistically significant ($P < 0.05$) difference between the growth-response in girls and boys aged 9 to 11 years was found. The boys displayed a femur overgrowth of an average of 2 mm while the girls displayed a growth retardation of an average of 0.5 mm. A growth retardation of the femur averaging 2 mm occurred in boys above the age of twelve.

DISCUSSION

The clinical measurement of anisomelia by correcting the pelvic tilt with wooden blocks placed under the shorter limb or by employing a measuring tape show a tendency towards underestimation (Edvardsen & Syversen 1976, Swaan & Oppers 1971). Assuming a minimal error of focusing at the performance of spot-orthoradiography the measurement on the film will indicate the correct total length of the bone with an accuracy of ½–1 mm (Taillard 1956) and the error of the difference would be so minimal that it could be ignored. The physiological anisomelia was clinically assessed by Barfod & Christensen (1959) in 431 children. They found isomelia in more than 90 per cent of the children, while Guldhammer's (1963) study of skeletons showed that total isomelia is probably the exception, but the difference in the majority of the population is less than 2 mm. As no spot-orthoradiography was performed prior to the accident the physiological anisomelia could not be corrected for in this study and as the magnitude of the physiological variation appears to be less than the fr[illegible] anisomelia this source of er[illegible] be of minor importance for the [illegible] this study.

The fracture-induced [illegible] anisomelia found in the prese[illegible] instance reached a clinically [illegible] requiring correction. A[illegible] leg-length discrepancy of 2 cm [illegible] importance in adults. The [illegible] fracture-induced growth d[illegible] on the child's sex and a[illegible] the accident, as shown by S[illegible] (1971), was confirmed by this [illegible] supported by an analysis of [illegible] presented by Guldhammer (19[illegible]

The correlation of growth [illegible] at the time of the [illegible] determined by the different [illegible] required for union and the [illegible] of immobilization. Muscle [illegible] blockage of the efferent [illegible] one of the most importa[illegible] diffusion of oxygenated blood [illegible] sinusoid of the bone marrow ([illegible] Trueta 1965). Bone [illegible] fracture healing then probably [illegible] depressed bone growth rate. This [illegible] by an increased growth rate [illegible] than 2 years (Swan & Op[illegible] Guldhammer 1963), due to the [illegible] circulation, which follows as a [illegible] fracture (Kellernova et al. 197[illegible] increased accretion rate ([illegible] Wendeberg 1961).

In very young children the [illegible] period is very short and the [illegible] consequently minimal. [illegible] rapidly restored and over[illegible] tablished. In children aged [illegible] prepuberty the immobil[illegible] period [illegible] stantial and the growth rate [illegible] maximal, which allows the [illegible] speed up in the period af[illegible] the [illegible] the increased blood circula[illegible] prepuberty normally display a [illegible] they appear unable to react [illegible] the younger children, and the [illegible] tion experienced during the [illegible]

the fracture cannot be corrected
ously
reason for the different growth
in the two sexes might be related to
iological difference in bone maturity
ame chronological age as it is well
that the girls cease growing earlier
boys
ype of fracture and the angulation at
e of union is apparently of no im-
for the growth response following a
A necessary condition for such cor-
to exist would be a different healing
different types of fractures which is
case (Hansen et al 1976) and a
n in the secondary hyperaemia
g a fracture a correlation which has
established either
growth disturbance of the ipsilateral
ncreased the anisomelia produced by
wth response of the fractured tibia
dicates that the hyperaemia is by no
local event in the tibia but includes
ole extremity However this does not
with the findings of Guldhammer
who stated that growth stimulation
ot occur in bones other than the
d one

generally accepted that an anisomelia
o 2 cm in adults is of no importance
ion 1956) Guldhammer (1963)
led that a shortening of a tibia fracture
to 1 cm with an otherwise correct
n does not indicate the need for an os-
hesis in a child with a few years of
remaining This statement has led to
confusion as to whether an anatomical
on of a fractured tibia in a child is
le The magnitude of the overgrowth
ldren under the age of 9 years was
imately 0 5 cm Fear of such a residual
elia should not prevent the
nance of an exact reduction From the
10 years in girls and 12 years in boys
udy shows that no overgrowth can be
ed On the contrary the spot
adiography demonstrated a growth
ation in the tibia as well as in the
which together may lead to an anisomelia of close to 2 cm A more concerned attitude towards residual shortening at the time of reduction in tibia fractures, at least in these older children has therefore to be adopted, in order to ensure a final anisomelia of less than 2 cm

In future studies it is recommended that an assessment of the bone maturity is made at the time of fracture and at the same time a spot-orthoradiography is performed and repeated 1 and 2 years after the accident

REFERENCES

Aronsson (1956) Invaliditet efter Femurdia fysfrakturer *Nord Med* **31**, 757–761

Barfod B & Christensen J (1958 1959) Fractures of the femoral shaft in children with special reference to subsequent overgrowth *Acta chir scand* **116**, 235 250

Baur G (1954) Rate of bone salt formation in a healing fracture determined in rats by means of radiocalcium *Acta orthop scand* **23**, 169 191

Edvardsen P & Syversen S M (1976) Overgrowth of the femur after fracture of the shaft in children *J Bone Jt Surg* **58** B 339 342

Edwards P (1965) Fracture of the shaft of the tibia *Acta orthop scand* Suppl 76

Guldhammer E H (1963) *Laekststimulation efter underextremitetsfraktur hos børn* Århus Stiftsbogtrykkeri

Hansen B A Greiff J & Bergman F (1976) Fractures of the tibia in children *Acta orthop scand* **47**, 448 453

Hedstrom O (1969) Growth stimulation of long bones after fracture or similar trauma A clinical and experimental study *Acta orthop scand* Suppl 122

Kellernova E Delius, W Olerud S & Strom G (1970) Changes in the muscle and skin blood flow following lower leg fracture in man *Acta orthop scand* **41**, 249 260

Ollier L (1867) *Traité expérimental et clinique de la regenération des os et de la production artificielle du tissu osseux* Vol I Victor Masson & Fils Paris

Swaan J W & Oppers, W M (1971) Crural fracture in children *Arch chir neerl* **23–24**, 259–272

Taillard W (1956) Die rontgenologische Methoden zur Messung der langen Rohrenknocken *Z Orthop* **88**, 151–158

Valderrama, J F. & Trueta, J (1965) The effect of muscle action on the intra-osseous circulation *J. Path Bact* 89, 179–186

Wendeberg, B (1961) [illegible] fractures of the tibia [illegible] external counting of Sr [illegible] Suppl. 52.

Correspondence to. Jorgen Greiff, M D, Ahornvej 40, DK 2970 Hørsholm, Denmark

›p scand 51, 321–334, 1980

IROGRAPHY AS A GUIDE IN THE TREATMENT OF -GENITAL CLUBFOOT

›s and Treatment Results in a Consecutive Series

HJELMSTEDT & BO SAHLSTEDT

ents of Orthopaedic Surgery and Diagnostic Radiology, University Hospital,
Sweden

Simultaneous arthrography of the talocrural and talonavicular joints performed on 32 out of a consecutive series of 48 congenital clubfeet revealed a talar dysplasia that varied considerably both in type and degree

This great variability meant that no simple and practically useful classification could be made on the basis of arthrographic findings. It in-

later operated upon because of unsatisfactory correction or recurrence The operations varied in extent from lengthening of the tendo Achillis to extensive soft-tissue procedures, in some cases combined with correction osteotomy through the neck of the talus and the calcaneus The results were relatively good, but the investigation showed that in many cases the talar dysplasia places a definite limit on the achievable result

Arthrography is not indicated in easily corrigible cases. This examination should always be carried out, however in clubfeet that are difficult to correct or are recurrent before making a decision about surgical treatment In these cases the arthrographic findings can be used as a guide in the choice of therapeutic method The talar dysplasia seems not to alter appreciably during the first year of life and it would therefore seem

Key words ankle joint clubfoot radiography talus therapy

Accepted 29 III 79

gave a good description of the skeletal ities in clubfoot as early as in ›2 Like many more recent authors & Sherman 1963, Settle 1963, Reimann Hjelmstedt & Sahlstedt 1974), he found individual variations in both the degree pe of dysplasia Attempts have been previously (Bertrand 1947, Poulain Cabanac et al 1952) to examine the deformity in clinical cases by graphy of the ankle joint and some flattening of the trochlear curvature has been observed Settle (1963) realized the value of simultaneous arthrography of the talocrural and talonavicular joints, but did not succeed in this except during surgery

Since 1970, however, after a series of investigations on autopsy foot specimens, we have found it possible to carry out simultaneous arthrography of these two joints in clinical practice The method involves well-defined standard roentgenological projections,

70 80 020321–14$02.50/0

measurement and analysis of different variables, a carefully worked out joint-puncture technique and a standardized pressure of injection (Hjelmstedt & Sahlstedt 1973, 1974, 1978, Hjelmstedt 1974a,b, Sahlstedt 1974).

Such simultaneous arthrography has been performed routinely on refractory and recurrent clubfeet, and side by side with the findings at clinical examination has served as a guide for future treatment (Hjelmstedt & Sahlstedt 1973, Hjelmstedt 1974a,b, Sahlstedt 1974, Hjelmstedt & Sahlstedt 1978).

In this article the arthrographic findings in a consecutive series of clubfeet are presented. In addition, the value of arthrography in the choice of treatment is demonstrated and the correlation between the findings at arthrography and the therapeutic results is reported.

PATIENTS AND METHODS

The material consisted of 48 idiopathic clubfeet in 30 patients who were followed up for a mean period of 6.3 years (range 3.5–9 years). There were 8 girls and 22 boys. The series comprised all children with clubfoot who were born and primarily treated in the county of Uppsala between January 1969 and July 1974.

In all cases the primary treatment was manual manipulation and serial casts and was started on one of the first days after birth.

Twenty feet were corrected successfully by conservative treatment alone, while the other 28 had later to undergo operation on account of unsatisfactory correction or recurrent deformity.

The operation cases have been divided into two groups in Table 1 according to whether corrective osteotomy through the talus and calcaneus was performed or not. The operative measures are presented in detail in this Table, from which it is seen that the soft tissue procedures were individualized, but that lengthening of the tendo Achillis and the tendon of the posterior tibial muscle was performed in the majority of cases.

The indication for operation was unsatisfactory correction or recurrence of the deformity.

Soft tissue operations *without* talo-calcaneal osteotomy were performed in cases where preoperative arthrography showed

(a) that the dislocation of the navicular bone was relatively slight (Figure 1) or

(b) that the dislocation of the ... relatively pronounced, but th... quisites for open reduction ...

By open reduction of the ... meant reduction of the bone ... after division of the capsule and ... talonavicular joint medially and ... aspect.

Soft tissue procedures and ... osteotomy were undertaken ... operative arthrography showed

(a) pronounced medio-plantar ... neck and head of the talus or

(b) total or subtotal ob... talonavicular joint, i.e. whe... sidered that reduction of the ... its normal position would ... (Figures 3 and 4).

Operative procedures

Lengthening of tendons was ... by a Z-plasty. Only in a few cases ... ing of the tendo Achillis carried ... most common of the minor ... was lengthening of both the tend... posterior tibial muscle tendon ... incision between the tibia and the ...

In the most extensive soft tis... incision was made from the me... and carried proximally behi... malleolus. The tendo Achillis, the ... posterior tibial muscle and ... long flexor tendons of the toes were ... cut with a Z-incision. ... laciniate ligament the plantar fasc... divided at the tuberosity of the ... abductor hallucis muscle was the... insertion on the tuberosity and ... aspect of the foot by careful d... damage to blood vessels and ne... part of the divided posterior ti... was then drawn down through ... facilitated subsequent d... navicular ligament and the ... talonavicular joint medially. Whe... and capsule had also been divided ... aspect the navicular bone was ... normal position. The distal par... tibial muscle tendon was then ... through its tendon sheath and ... the desired amount of lengthen... way as the other divided tendons ... of the peroneal tendons was ... sutures through an incision ... malleolus. In some cases the ... anterior tibial muscle was trans... of the second or third ...

Table 1 Details of the operative treatment The material is divided into two groups (1) operative treatment without talo-calcaneal osteotomy and (2) operative treatment including talo-calcaneal osteotomy It is seen that the soft tissue procedures varied greatly from case to case but that lengthening of the tendo Achillis and the posterior tibial muscle tendon was performed on most of the clubfeet By open reduction of the navicular is meant here reduction after division of the capsule and ligaments of the talonavicular joint medially and on the plantar aspect The operative treatment was sometimes carried out in two sessions with an interval of 6–18 months

Treatment	Lengthening of				Shortening of one or both peroneal tendons	Transfer of anterior tibial muscle tendon	Release of abd hall muscle + plantotomy	Open reduction of the navicular bone	Wedge osteotomy through	
	Tendo Achillis	Post tibial tendon	Flex dig long tendon	Flex hall long tendon					Cuboid	Talar neck + calcaneus
Conservative + soft tissue procedures (+ wedge osteotomy on the cuboid, 3 feet) $n=23$	20	17	1	1	5	11	8	9	3	–
Conservative + soft tissue procedures + talo-calcaneal osteotomy $n=5$	5	5	–	–	2	–	3	–	–	5
Total = 28	25	22	1	1	7	11	11	9	3	5





Figure 1 Clubfoot deformity in a 2 year old girl Simultaneous arthrography of [illegible] talonavicular joints Spontaneous contrast filling of a medial tendon sheath occurred
a Lateral view The ankle recesses are small The plantar deviation of the [illegible] increased ($\beta = 38°$)
b Dorsoplantar view The medial deviation of the talonavicular joint is increased [illegible] head has a normal rounded form
Operation Lengthening of the tendo Achillis and the posterior tibial muscle tendons
Result Excellent

procedure but as a rule this was done at a later session

Corrective osteotomy (Hjelmstedt & Sahlstedt to be published in Acta orthop scand.) through the neck of the talus and the calcaneus was performed through an incision over the tarsal sinus, with removal of a wedge of bone through the talar neck as shown in Figure 5 The osteotomy through the calcaneus is done at the same level as in the talus and one has to test one's way forward to see how large a wedge needs to be removed from the calcaneus. The osteotomies were always combined with simultaneous soft tissue operations performed through a medial incision. The talonavicular [illegible] opened as the vascular [illegible] talus after osteotomy only [illegible] joint capsule

Suction drainage was [illegible] cutaneous tissue and skin [illegible] single rather close sutures [illegible] was observed after full [illegible] considered unsatisfactory the [illegible] served somewhat before the [illegible] applied The cast was changed [illegible] anaesthesia with [illegible] week and [illegible] fixed in a maximally corrected [illegible] the foot was kept [illegible]





Congenital clubfoot in a 1½-year-old boy Simultaneous arthrography of the ankle and ular joints Spontaneous contrast filling of a medial tendon sheath occurred
il view The ankle recesses are slightly reduced in size There is slight flattening of the trochlea =0 43) Normal plantar deviation of the talonavicular joint is seen (β=26°)
plantar view The medial deviation of the talonavicular joint is increased (β–47°) and the ilar bone is displaced medially The talar head, however has preserved its normal form
Lengthening of the tendo Achillis and posterior tibial muscle tendon + release of the plantar id the abductor hallucis muscle from the calcaneus + open reduction of the navicular nsfer of the anterior tibial muscle tendon
ery good

weeks The cast covered the whole leg nee in 90° flexion
mplicating skin sores occurred and no vascular necrosis in the head of the talus rved in this material

phy

ous arthrography of the talocrural and ilar joints was carried out on 32 of the t Fourteen feet were corrected relatively y conservative treatment and in these e was no indication for arthrography In the arthrography was unsuccessful feet for which surgical treatment was l necessary, preoperative arthrography was performed and the information thus obtained was used as a guidance in drawing up a suitable plan of treatment

The arthrographies were performed as described by Sahlstedt (1976) The reliability of the method of radiographic measurements used has been investigated previously and found to be ... for the variables reported here

L – length of talus
R = radius of the trochlear curvature
R/L – index of the flattening of the trochlea




Figure 3 Congenital clubfoot in a 3-year old boy Simultaneous arthrography
a Lateral view The ankle recesses are small (Flattening index R L = 0 [illegible]) [illegible] of the talar neck and of the talonavicular joint is observed ($\beta = 51°$)
b Dorsoplantar view There is pronounced medial deviation of the neck and head of [illegible] the talonavicular joint (γ – 66°) The talar head is deformed and the recesses of [illegible] joint are partially obliterated
Operation In two sessions the following were performed lengthening of the tend [illegible] tibial tendon correction osteotomy through the talus and the calcaneus and tr[illegible] tibial tendon
Result Good

α central angle of the trochlear curvature
β plantar deviation of the talonavicular joint
γ medial deviation of the talonavicular joint

An analysis of measurement values from a material of clubfeet has been published previously (Hjelmstedt & Sahlstedt 1978). In this it was found that a reduction of the central angle of the trochlear curvature (α) was correlated to an increase of the flattening of the trochlea (index R/I). Further a weak correlation was found between a decreased α and an increased medial deviation of the talonavicular joint (γ). This was the only correlation between the changes in the ankle joint and those in the [illegible] This means that it is not [illegible] practically useful class[illegible] deformity on the basis of [illegible] Thus, the most strik[illegible] marked plantar deviation of the [illegible] in one case a marked med[illegible] case and marked fla[illegible] very small central an[illegible]

This variability [illegible] it is not evident from the [illegible] values presented here

The mean values [illegible]



Severe clubfoot deformity in a 1½ year-old boy Simultaneous arthrography Spontaneous filling of a medial tendon sheath occurred
al view There is obvious flattening of the trochlea (R/L = 0 46) and subtotal obliteration of the recesses Marked plantar deviation of the neck of the talus and of the talonavicular joint is β 44°)
plantar view The talonavicular joint shows marked medial deviation () 59°) and its recesses obliterated
m Lengthening of the tendo Achillis and the posterior tibial muscle tendon + release of the fascia and the abductor hallucis muscle from the calcaneus + correction osteotomy through the d the calcaneus
Good The reduced mobility of the ankle is partly compensated for by hypermobility in the al joints

ams for different treatment groups and for le material are presented in Table 2. For son normal values are also given Of the feet that were only treated conservatively raphy was only performed on the six that ost difficult to correct and the data given refore not representative for the whole As seen in the Table the mean values for ix feet showed considerable discrepancy e normal values with respect to the central) and the index of the flattening of the while for plantar deviation (β) there was no discrepancy and for medial deviation ()) the difference was only slight The mean values for the surgically treated feet on the other hand all differed considerably from the normal values.

RESULTS OF TREATMENT

The evaluation of these results was based upon clinical examination at the age of 3 5–9 years (mean age 6 3 years) The criteria for





Figure 3 Congenital clubfoot in a 3 year-old boy Simultaneous arthrography
a Lateral view The ankle recesses are small. (Flattening index R/L = 0 42) Marked pl[illegible] of the talar neck and of the talonavicular joint is observed ($\beta = 51°$)
b Dorsoplantar view There is pronounced medial deviation of the neck and head of the ta[illegible] the talonavicular joint ($\gamma = 66°$) The talar head is deformed and the recesses of the ta[illegible] joint are partially obliterated
Operation. In two sessions the following were performed lengthening of the tendo Achillis and [illegible] tibial tendon, correction osteotomy through the talus and the calcaneus, and transfer of the [illegible] tibial tendon
Result Good

α = central angle of the trochlear curvature
β = plantar deviation of the talonavicular joint
γ = medial deviation of the talonavicular joint

An analysis of measurement values from a material of clubfeet has been published previously (Hjelmstedt & Sahlstedt 1978). In this it was found that a reduction of the central angle of the trochlear curvature (α) was correlated to an increase of the flattening of the trochlea (index R/L). Further, a weak correlation was found between a decreased α and an increased medial deviation of the talonavicular joint (γ) This was the only correlation between the changes in the ankle joint and those in the talonavicul[illegible] This means that it is not possible to [illegible] practically useful classification of the [illegible] deformity on the basis of arthrograph[illegible] Thus, the most striking talar deformit[illegible] marked plantar deviation of the talonavic[illegible] in one case, a marked medial deviation [illegible] case, and marked flattening of the troch[illegible] very small central angle in a third case.

This variability is important to keep [illegible] it is not evident from the arthrograp[illegible] values presented here.

The mean values obtained f[illegible]





Severe cl bfoot d ... *a ous arthrography Spontaneous*

0 46) and subtotal obliteration of the ... *β 44°) Marked plantar deviation of the neck of the talus a d of the talonavicular joint is* ... *plantar view The talonavicular joint shows marked medial deviation (γ ~59°) and its recesses obliterated*

Lengthening of the tendo Achillis and the posterior tibial muscle tendon + release of the fascia and the abductor hallucis muscle from the calcaneus + correction osteotomy through the ... *d the calcaneus*

Good The reduced mobility of the ankle is partly compensated for by hypermobility in the ... *al joints*

...ams for d fferent treatment groups and for ... le material are presented in Table 2 For ... son normal values are also given Of the ... feet that were only treated conservatively ... aphy was only performed on the six that ... ost difficult to correct and the data given ... refore not representative for the whole ... As seen in the Table the mean values for ... six feet showed considerable d screpancy ... e normal values with respect to the central ... t) and the index of the flattening of the ... , while for plantar deviation (β) there was no discrepancy and for medial deviation (γ) the difference was only slight The mean values for the surg cally treated feet on the other hand all differed considerably from the normal values

RESULTS OF TREATMENT

The evaluation of these results was based upon clinical examination at the age of 3 5–9 years (mean age 6 3 years) The criteria for

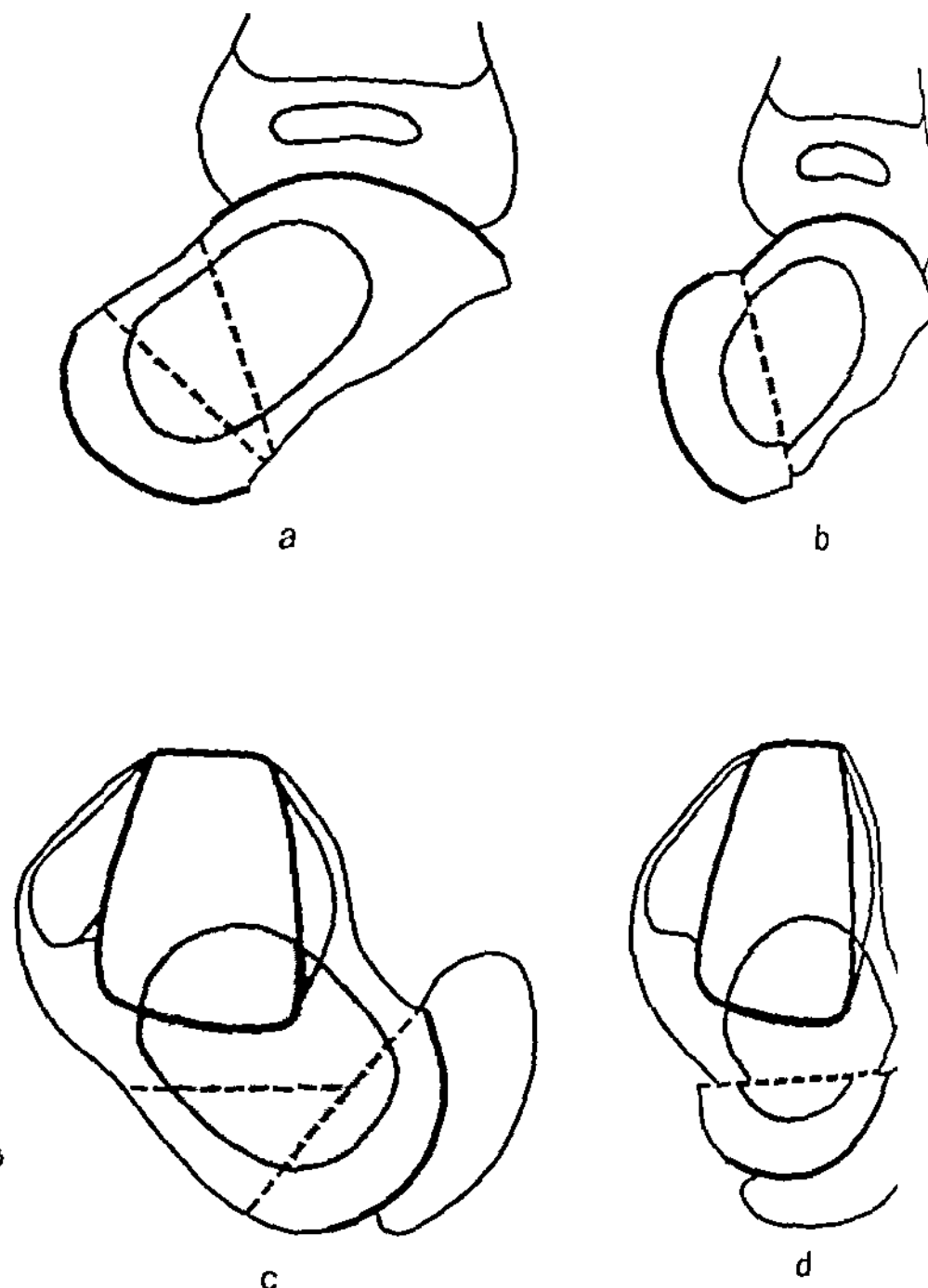


Figure 5 Schematic drawing of osteotomy through the talar neck.
a Lateral view of a clubfoot talus Note the flattening of the trochlea and plantar [illegible] and head The osteotomy lines are marked with short dashes The base of the wedge [illegible] dorso-lateral side of the neck
b Correction after wedge osteotomy The actual shortening of the talus will be about 10 [illegible] former length
c A clubfoot talus and the navicular bone seen from above The joint borders are marked [illegible] lines and the osteotomy lines with short dashes Note the pronounced medial [illegible] neck and head and the obliteration of the original talonavicular joint
d Correction after osteotomy

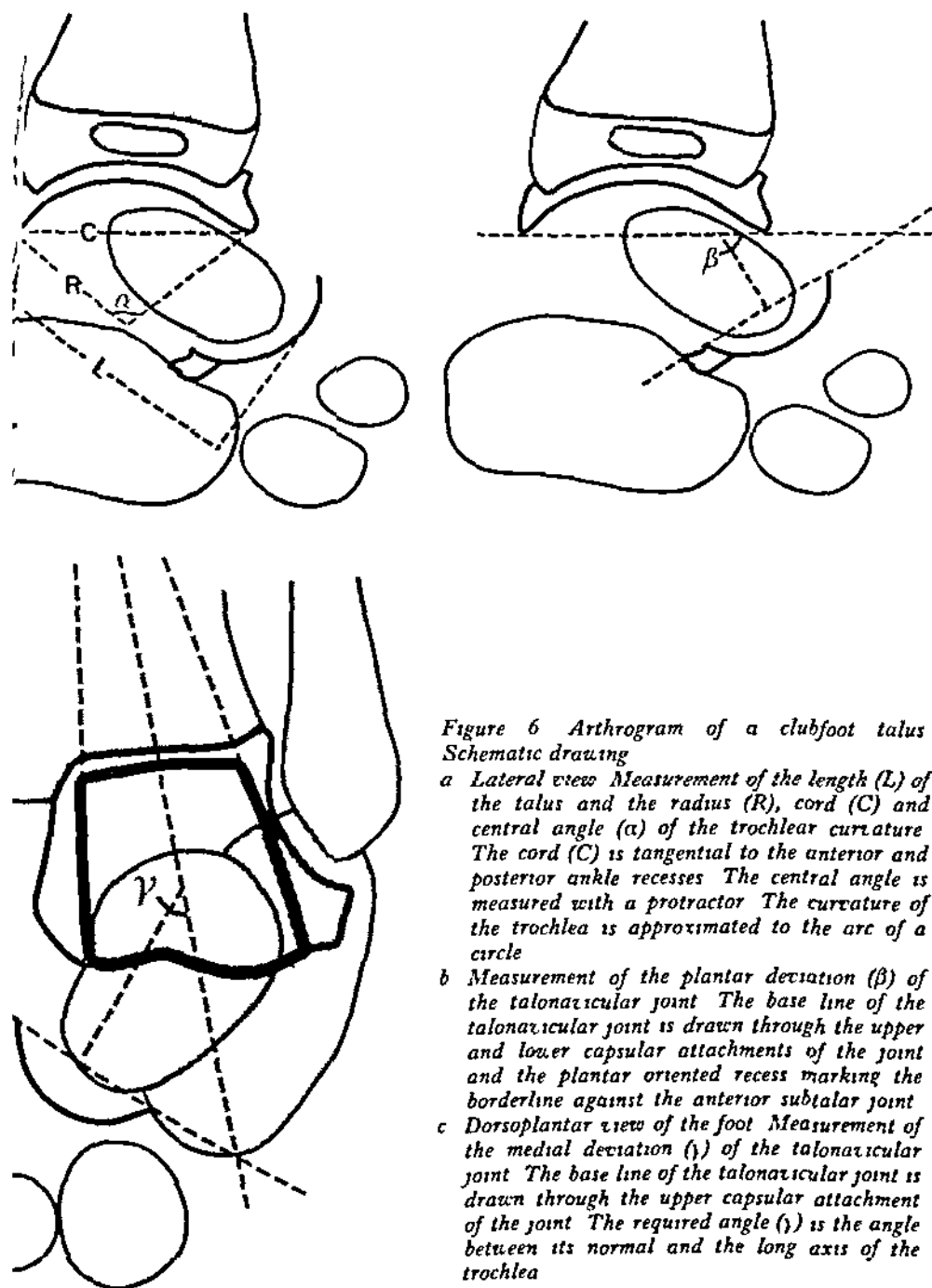


Figure 6 Arthrogram of a clubfoot talus Schematic drawing

a Lateral view Measurement of the length (L) of the talus and the radius (R), cord (C) and central angle (α) of the trochlear curvature The cord (C) is tangential to the anterior and posterior ankle recesses The central angle is measured with a protractor The curvature of the trochlea is approximated to the arc of a circle

b Measurement of the plantar deviation (β) of the talonavicular joint The base line of the talonavicular joint is drawn through the upper and lower capsular attachments of the joint and the plantar oriented recess marking the borderline against the anterior subtalar joint

c Dorsoplantar view of the foot Measurement of the medial deviation (γ) of the talonavicular joint The base line of the talonavicular joint is drawn through the upper capsular attachment of the joint The required angle (γ) is the angle between its normal and the long axis of the trochlea

tion of the results are given in Table 'derline cases it was chosen to assign t to the poorer group

ible 4 the results are presented in to different types of treatment, and in Table 6 in relation to demonstrated talar deformity

For 20 of the 48 feet an excellent or very good result was achieved with conservative treatment alone

Table 2. The arthrographic variables in the clubfoot material and in a previously [illegible] material (Hjelmstedt & Sahlstedt 1977). The methods of measurement of the different [illegible] shown in Figure 6. For the clubfeet mean values and ranges are given and for the [illegible] mean values and tolerance limits. n=6/20, and so on, means that 6 out of 20 feet [illegible] arthrography. 14 of the 16 feet not submitted to arthrography were corrected after a [illegible] period of conservative treatment. It is reasonable to assume that the dysplasia in these [illegible] pronounced than in those examined arthrographically. In two cases arthrography was [illegible] unsuccessful. R=radius of the trochlear curvature and L=length of talus

Type of treatment Variable	Conservative treatment only	Conservative treatment + soft tissue procedures	Soft tissue procedures + talo-calcaneal osteotomy	Total	[illegible]
	$n=6/20$	$n=21/23$	$n=5/5$	$n=32/48$	[illegible]
R/L = index of "the flattening of the trochlea"	0.43 0.39–0.48	0.42 0.38–0.49	0.44 0.40–0.49	0.42 0.38–0.49	[illegible]
Central angle α of the trochlea curvature	127° 109–138°	123° 101–150°	129° 110–143°	12[illegible]° 101–1[illegible]0°	[illegible]
Plantar deviation β of the talonavicular joint	24° 15–34°	36° 20–49°	43° 36–53°	35° 15–53°	[illegible]
Medial deviation γ of the talonavicular joint	23° 12–35°	38° 18–60°	42° 18–58°	3[illegible]° 12–[illegible]0°	[illegible]

Table 3. Classification of the treatment results based on the findings at clinical [illegible] arthrography in 32 of the 48 feet showed varying degrees of dysplasia of the talus and [illegible] in Table 6, a correlation was found between the degree of talar deformity and the treatment [illegible]

	Excellent	Very good	Good	Fair
Dorsal extension of the foot	≥15°	10–15°	5–10°	0–5°
Plantar flexion of the foot	≥25°	≥20°	≥15°	≥10
Mobility of subtalar joints	normal	good	possibly slightly reduced	reduced
Mobility of midtarsal joints	normal	good, possibly hypermobile	good, possibly hypermobile	markedly re[illegible]
Deformity on weight-bearing				
equinus	–	–	–	–
varus	–	–	–	≥1[illegible]°
adductus	–	negligible	<15°	[illegible]
Gait without shoes	normal	good	good	good
with shoes	normal	good	good	

The results in the 23 feet that underwent soft tissue procedures without talo-calcaneal osteotomy varied considerably. For 17 feet they were evaluated as excellent-good, whereas in 6 cases they were only fair. In the latter cases the dorsiflexion in particular, was only very slight, and one case showed [illegible] of the anterior tibial muscle.

The result was evaluated as [illegible] good for the five feet submitted to [illegible] operations in combination with talo-[illegible] osteotomy.

:Results of treatment after an observation time of 3 5–9 years (median 6 3 years) in the con- ·series of 48 idiopathic clubfeet in 30 patients born 1/1/1969–31/7/1974 The criteria for -ion of the results are given in Table 3 Arthrography was performed preoperatively in 26 of the 28 surgically treated feet and in 6 of the 20 feet treated conservatively

it	Excellent	Very good	Good	Fair	Total
	Results				
tive only	16	4	–	–	20
tive + soft tissue procedures ·osteotomy on the cuboid in	2	9	6	6	23
tive + soft tissue procedures caneal osteotomy	–	3	2		5
	18	16	8	6	48

Comparison between the findings at arthrography performed early and at later ages More pro- dysplasia might have been expected with increasing age, but this was not the case within the of life In the small group of children not examined until the age of 2–4 years, on the other · dysplasia was more marked These were early cases in the series, and at that time we had erience of these arthrographies and the therapeutic principles based upon them In many cases a thrography was done before planned osteotomy In no case was arthrography performed at an age of 13–24 months

ild at the ography		Mean values for the arthrographic variables			
		R/L = index of the flattening of the trochlea	Central angle α of the trochlear curvature	Plantar deviation β of the talo-navicular joint	Medial deviation γ of the talo-navicular joint
nths	$n=12$	0 43	126°	31°	33°
ıths	$n=14$	0 42	128°	36°	33°
s	$n=6$	0 43	115°	37°	47°
ues from material	$n=54$	0 35	154°	24°	15°

operation

nt result		Mean preoperative values of arthrographic variables			
		R/L = index of the flattening of the trochlea	Central angle α of the trochlear curvature	Plantar deviation β of the talo-navicular joint	Medial deviation γ of the talo-navicular joint
:	$n=5/18$	0 41	131°	29°	30°
d and good	$n=17/19$	0 42	125°	32°	33°
	$n-5/6$	0 42	113°	42°	44°
values	$n=54$	0 35	154°	24°	15°

To elucidate the question of whether the skeletal deformity alters with time, the mean arthrographic values are listed in relation to the different age groups in Table 5 It is seen that there was no appreciable difference in these values between feet examined within 2 months of birth and those examined at an age of 3–12 months. On the other hand, the values for the small group in which arthrography was not performed until the age of 2–4 years differed considerably from the others. The cases in the latter age group belong to the first in our series, and the reason for the greater degree of dysplasia might be that arthrography and the initiation of adequate surgical treatment was delayed too long At that time the analysis and the indications for different forms of treatment had not yet been fully worked out

The relation between the findings at the first arthrography and the results of treatment is shown in Table 6 The dysplasia was more pronounced in the group with fair results than in those with better results. The arthrographic values for the group with excellent results cannot be regarded as representative for the group as a whole, as only 5 of 18 feet were examined The feet not subjected to arthrography may be assumed to have had a lower grade of joint dysplasia than those that underwent this examination

The feet in which talo-calcaneal osteotomy was performed are not included in the Table, as the plantar and medial deviation (β and γ) would have been altered by this operation

DISCUSSION

Anatomic studies have shown that deformation of the bones of the foot, especially the talus, is common in clubfoot (Adams 1851–52, Irani & Sherman 1963, Settle 1963, Reimann 1967, Sahlstedt 1974) It has been found in such studies that the dysplasia has varied considerably both in degree and type With the arthrographic method used on the present material it has been possible to study the talar deformity in a series of [illegible] cases. In a previously published [illegible] (Hjelmstedt & Sahlstedt 197[illegible]) [illegible] that owing to the variability mentioned [illegible] is not possible to make any simple [illegible] classification of clubfeet on the [illegible] arthrographic findings. From [illegible] observations two conclusions have be[illegible]

1 The variation of the ta[illegible] indicates that the deformation [illegible] from case to case both in [illegible] in direction This must be taken [illegible] sideration when planning the [illegible] which therefore has to be individ[illegible]
2. Arthrography should be perform[illegible] cases that cannot be corrected [illegible] quickly by conservative treatment [illegible] to determine the degree and [illegible] dysplasia This should be do[illegible] every kind of surgical interven[illegible] even before achillotomy It may b[illegible] of 28 feet in the present series [illegible] talus can already be dorsiflexed [illegible] and that the equinus position [illegible] marked plantar deviation of the [illegible] neck of the talus. In such cases [illegible] tion is gained by achillotomy [illegible] power is lost.

The method of simultaneous [illegible] of the talocrural and talonavicular [illegible] developed in the hope of obtaining [illegible] that could be of value in the choice [illegible] ment This hope has in fact been [illegible] and certain essential questions [illegible] answered by this examination. As [illegible] above, the matter of whether or not [illegible] Achillis should be lengthened can b[illegible] after arthrographic analysis. The sa[illegible] to the question to what extent [illegible] direction the navicular is disloca[illegible] of whether prerequisites exist for [illegible] reduction of the dislocation or if [illegible] osteotomy is the only satisfactory [illegible]

Arthrographic analysis also [illegible] insight into the best result that [illegible] expected to be reached by treatm[illegible] example, the examination reveals [illegible] flattening of the trochlea [illegible]

of the central angle of the trochlear (Figure 4), normal mobility can ioped for with any form of treat- ɔermobility at the mid-tarsal joints me extent, but seldom completely, e for the restricted ankle

tart of this investigation lack of ex- iade us somewhat uncertain about retation of the arthrograms and we insufficient experience of corrective · through the talar neck and This gave rise to some hesitation : correct treatment in the first ɔhically investigated cases, which in ht have affected the results un- ,

ıpossible to say whether our results · or poorer than those in other series, :lassifications into groups and the vary from one investigation to Moreover, our material is relatively

clear, on the other hand, that the t was based on better knowledge of tomic conditions than has been previously In our opinion ıphy is invaluable in the choice of t

the comparison of the arthrographic in different age groups (Table 5) it eem that some delay in initiating tensive forms of surgical intervention t result in an increase of the defor-

outine for examination and treatment been developed is briefly as follows

arly all cases are treated by pulation and serial casts, with a ɡe of the plaster cast every week The ment is continued until maximal cor- ɔn i e preferably overcorrection, is :ved A splint is then applied instead satisfactory result has been attained in 2–3 months, arthrography is un- ssary

satisfactory result is not achieved or if deformity recurs arthrography is always performed On the basis of the arthrographic findings and observations at clinical examination it is then decided whether an operation is necessary to obtain the best possible correction, and if so, what soft-tissue and possibly skeletal procedure is indicated Arthrography can be done as early as at 2 months of age, but is easier to perform and gives better films at an age of 6–12 months

4 In exceptional cases lengthening of the tendo Achillis and possibly also of the posterior tibial muscle tendon can be done at an age of 2–3 months As a rule, however, both minor and more extensive soft tissue operations, as well as osteotomies, should not, for practical reasons be carried out before an age of 6 months and preferably not until 8–9 months. It is often suitable to perform the operations in two sessions. Talo-calcaneal osteotomy and lengthening of the tendo Achillis should not be carried out simultaneously, and transfer of the anterior tibial muscle tendon should not be done until maximal dorsiflexion of the ankle joint has been attained

In view of the desirability of performing arthrography in refractory or recurrent clubfeet, and of the frequently rather extensive operations that are indicated the treatment of these cases should be centralized as far as possible

REFERENCES

Adams, W (1851–52) A series of four specimens illustrating the morbid anatomy of congenital club foot (talipes varus) *Trans path Soc Lond* 3, 455–464

Bertrand P (1947) L'arthrographie dans le pied bot congenital *Rev Chir orthop* 33, 548

Cabanac J Petit P & Maschas, A (1952) Le traitement du pied bot varus équin congénital *Rev Chir orthop* 38, 314

Hjelmstedt Å & Sahlstedt B (1973) The anatomy of the talus in clubfeet. Results of an arthrographic study *Proceedings of the Scandinavian Orthopaedic Society Acta orthop scand* 44, 128

Hjelmstedt Å & Sahlstedt B (1974) Talar

deformity in congenital clubfeet An anatomical and functional study with special reference to the ankle joint mobility *Acta orthop scand* **45**, 628–640

Hjelmstedt, Å (1974a) The importance of analysis of skeletal deformities in congenital clubfeet for adequate surgical treatment *Proceedings of the Scandinavian Orthopaedic Society Acta orthop scand* **45**, 953–955

Hjelmstedt, Å (1974b) Correction osteotomy of the talus and calcaneus in relapsing or incorrigible clubfeet Principles and techniques *Proceeding of the Scandinavian Orthopaedic Society Acta orthop scand* **45**, 978–980

Hjelmstedt, Å & Sahlstedt, B (1976) Simultaneous arthrography of the talocrural joints in children II Comparison between anatomic and arthrographic measurements. *Acta radiol Diagn* **17**, 557–564

Hjelmstedt, Å & Sahlstedt, B (1977) Simultaneous arthrography of the talocrural and talonavicular joints in children III Measurements on normal feet *Acta radiol Diagn* **18**, 513–522

Hjelmstedt, Å & Sahlstedt B (1978) Simultaneous arthrography of the talocrural and talonavicular joints in children IV Measurements on congenital clubfeet *Acta radiol Diagn* **19**, 223–236

Hjelmstedt, Å & Sahlstedt, B (1980) [illegible] osteotomy and soft tissue procedures [illegible] treatment of clubfeet I Indications, [illegible] and technique *Acta orthop scand* **51**, [illegible]

Hjelmstedt, Å & Sahlstedt, B (1980) [illegible] osteotomy and soft tissue procedures [illegible] treatment of clubfeet II Results in [illegible] treated feet *Acta orthop scand* **51**, [illegible]

Irani, R N & Sherman, M S (19[illegible]) [illegible] pathological anatomy of clubfoot *J* [illegible] *Surg* **45-A**, 45–51

Poulain J (1949) *L'arthrographie [illegible] dans le pied bot varus équin congénital [illegible] premier âge* Thèse Librairie [illegible], Paris

Reimann I (1967) *Congenital idiopathic [illegible]* Thesis Munksgaard Copenhagen, 19[illegible]

Sahlstedt, B (1974) Arthrographic [illegible] congenital clubfoot. *Proceedings of the Scandinavian Orthopaedic Society* [illegible] *orthop scand* **45**, 9[illegible]

Sahlstedt, B (1976) Simultaneous arthrography [illegible] the talocrural and talonavicular [illegible] children I Technique *Acta radiol Diagn* [illegible] 545–556

Settle, G W (1963) The anatomy of [illegible] talipes equino-varus Sixteen [illegible] specimens *J Bone Jt Surg* **45**-A, 1[illegible]

Correspondence to E Åke Hjelmstedt, M D, Department of Orthopaedic Surgery, University [illegible] S-750 14 Uppsala, Sweden

p scand 51, 335–347, 1980

-CALCANEAL OSTEOTOMY AND SOFT TISSUE EDURES IN THE TREATMENT OF CLUBFEET

ations, Principles and Technique

LMSTEDT & BO SAHLSTEDT

ents of Orthopaedic Surgery and Diagnostic Radiology,
y Hospital, Uppsala, Sweden

By simultaneous arthrography of the talocrural and talonavicular joints it is possible to demonstrate and measure the most important skeletal deformities in clubfoot In this way it has been possible to establish the indications for alternative forms of treatment with a greater degree of precision

Most of our refractory or recurrent clubfeet have been treated successfully by various soft tissue procedures. In cases with severe talar deformity, however, these procedures have been complemented by correction osteotomy through the talar neck and calcaneus

The aim is to create muscle balance by soft tissue procedures and to correct pronounced skeletal deformities by osteotomy This treatment plan has been used in about 50 of our clubfoot cases The principles, objectives and indications of the surgical therapy are discussed in this article.

The operative technique, as it has been developed with increasing experience, is described, and if careful attention is paid to all details the risk of complications is small and the correction is generally satisfactory

It must be emphasized that correction osteotomy is only a part of an overall treatment plan and that this operation is only indicated in a minority of clubfoot cases.

Key words arthrography, clubfoot osteotomy soft tissue procedures

Accepted 4 i 79

correction of the talar deformity in by curettage of the ossification (die Entkernung des Talus) was d by Meusel as early as in 1890 A y large material of clubfeet submitted ative "decancellation" of the talus, is and cuboid was reported on by Muro in 1934

92 Bradford described three cases that orrected by osteotomy through the ck and calcaneus. Batchelor (1946) ga (1955) only performed osteotomy the neck of the talus, whereas Fredenhagen (1955) also removed a wedge of bone from the cuboid and inserted this into the osteotomy defect in the talus Various soft tissue operations have often preceded or been performed in connection with the osteotomies.

The indications for these bone operations have previously been based mainly on the clinical findings, as conventional radiography of the feet in small children yields very little information as to the shape of the bones or the anatomy of the joints.

The introduction of simultaneous

0/80/020335–13$02.50 0

arthrography of the talocrural and talonavicular joints has made it possible, however, to demonstrate the most important skeletal deformities in clubfoot and to measure them with a relatively high degree of accuracy (Sahlstedt 1976 Hjelmstedt & Sahlstedt 1974b, 1977, 1978a) This has enabled the indications for alternative forms of treatment to be established with greater precision The arthrographies have shown that the skeletal deformity in refractory clubfeet is often so pronounced that good correction cannot be achieved by conservative treatment Most of them, however, can be corrected by soft tissue procedures of varying extent, but in a minority of cases these operations must be complemented by wedge osteotomy through the neck of the talus and the calcaneus (Hjelmstedt & Sahlstedt 1979)

Since 1972 we have treated about 50 clubfeet by this form of correction osteotomy In this article the indications for operation and the technique, as they have developed with increasing experience of the method, will be described

THE PRINCIPLES AND AIMS OF THE SURGICAL TREATMENT

The principles are as follows

- *to correct the medial and plantar deviation of* the neck and head of the talus by wedge osteotomy through the talar neck
- to correct the curvature deformity of the calcaneus and achieve the desired shortening by a slightly less angled wedge osteotomy through the calcaneus
- to correct any residual supination deformity by pronation of the foot distal to the osteotomies
- to facilitate the correction by division of the plantar aponeurosis and the tibionavicular ligament
- to normalize the muscle balance, thereby preventing recurrence, by a series of individually suited soft tissue procedures.

The soft tissue procedures used [illegible] lengthening of tendons, [illegible] abductor hallucis muscle [illegible] peroneal tendons and transfer of the tibial tendon. Capsulotomy is not [illegible] the treatment plan and is [illegible] indicated as regards the talocrural [illegible] because of the risk of necrosis of the head

The aim of the treatment is [illegible] achieve the best possible function, [illegible] fortunately is not always [illegible] normal function. For example, [illegible] talocrural deformity there is no [illegible] achieving normal mobility in [illegible] *Hypermobility of the [illegible]* compensate for this to some extent [illegible] or fair result will then often be [illegible] if the function is not [illegible] means of clinical examination [illegible] by arthrography it is generally [illegible] judge in advance what function [illegible] attained

INDICATIONS FOR OSTEOTOMY

The primary treatment of clubfoot [illegible] always be conservative Operation [illegible] only be considered if the [illegible] measures have not resulted in [illegible] rection or if the deformity has [illegible]

Before a decision is made about [illegible] of surgical treatment – *including* [illegible] of the tendo Achillis – arthrography of [illegible] talocrural and talonavicular joints [illegible] performed This can be done as [illegible] the age of 2 months, but is easier [illegible] or *later*

Incomplete correction or recurrence [illegible] of adequate conservative measures [illegible] a clear indication for operation, [illegible] decision can be made on the basis of [illegible] examination alone. On the other hand [illegible] examination is not *sufficient* to [illegible] type of operation required, that is [illegible] osteotomy is necessary or not [illegible] muscular function, however [illegible]

concerning the need for and extent
ssue procedures
rography the degree of flattening of
trochlea can be measured by means of
(R/L) and the degree of obliteration
kle joint by a central angle (α) (see
The deformity of the talonavicular
obliteration of its recesses, as well
edial or plantar displacement of the
bone, can also be assessed Further,
observed whether the neck of the
ves off medially or deviates in the
irection, or both, in relation to the

rthrographies have revealed that the
formity in clubfoot can vary con-
It is therefore not possible to make
and practical classification of the
deformity based on arthrographic
Each case must be analysed indi-
(Hjelmstedt & Sahlstedt 1978) For
ison our indications for different
e procedures are presented here on

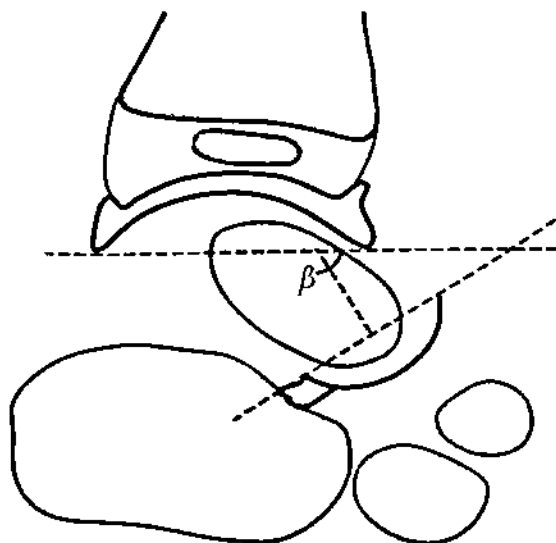
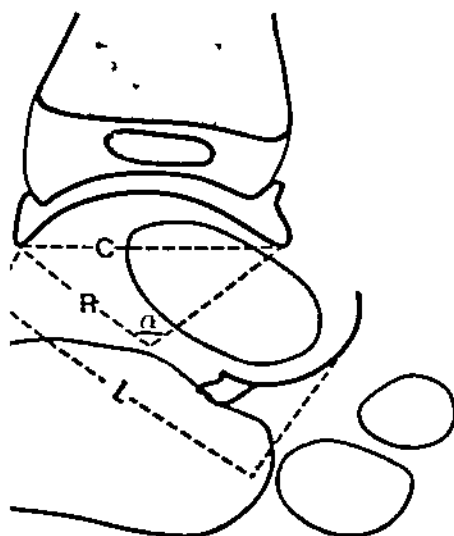


Figure 1b Measurement of the plantar deviation (β) of the talonavicular joint The base line of the talonavicular joint is drawn through the upper and lower capsular attachment of the joint and the plantar oriented recess marking the borderline of the anterior subtalar joint



1a Arthrogram of a clubfoot talus tic drawing Lateral view Measurement of th (L) of the talus and the radius (R) cord d central angle (α) of the trochlear re The cord (C) is tangential to the r and posterior ankle recesses The central r measured with a protractor The curva the trochlea is approximated to the arc of

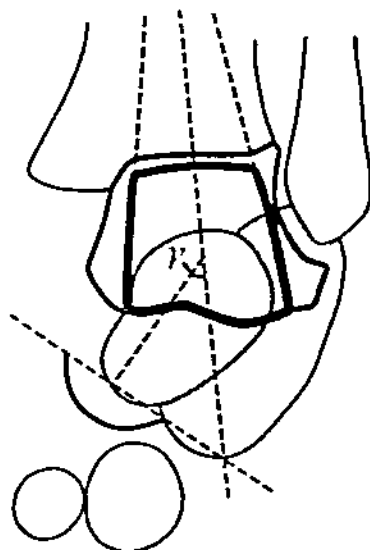


Figure 1c Dorso-plantar view of the foot Measurement of the medial deviation (γ) of the talonavicular joint The base line of the talonavicular joint is drawn through the upper capsular attachment of the joint The required angle (γ) is the angle between its normal and the long axis of the trochlea



Figure 2 Congenital clubfoot in a 6 month old boy Simultaneous arthrography of the talocrural and talonavicular joints The trochlea is normally rounded and its curvature has a normal central angle The recesses are fairly good The talus is in a moderately equinus position

the basis of cases with varying degrees and types of dysplasia To simplify this survey, arthrograms from children aged 6 months to 8 years have been chosen

Figure 2 demonstrates an equinus deformity in a case with a well rounded trochlea, a relatively large central angle and good recesses. Lengthening of the Achillis corrected the deformity

The arthrogram in Figure 3 shows ... plantar deviation of the head and neck ... talus even at full dorsal extension of the ... In such cases the equinus deformity ... corrected only by wedge osteotomy ... the neck of the talus

Figure 4, in the dorso-plantar ... illustrates a case with only ... displacement of the navicular bone. ... rection can be achieved by len...





Figure 3 Congenital clubfoot in a 1... boy Simultaneous arthrography of the ta... and talonavicular joints

a) Lateral view The trochlea is ... rounded (R/L = 0 40) The ... normal There is marked plant... the head and neck of the talus (... b) Dorso plantar view The talonavic... deviating slightly in the medial ... 25°)

r tibial tendon in some cases ed with plantar fasciotomy and release bductor hallucis muscle

e 5 depicts marked medial and plantar ment of the navicular bone and some ng of the head of the talus The talo-ar joint is not notably obliterated r and open reduction of the navicular

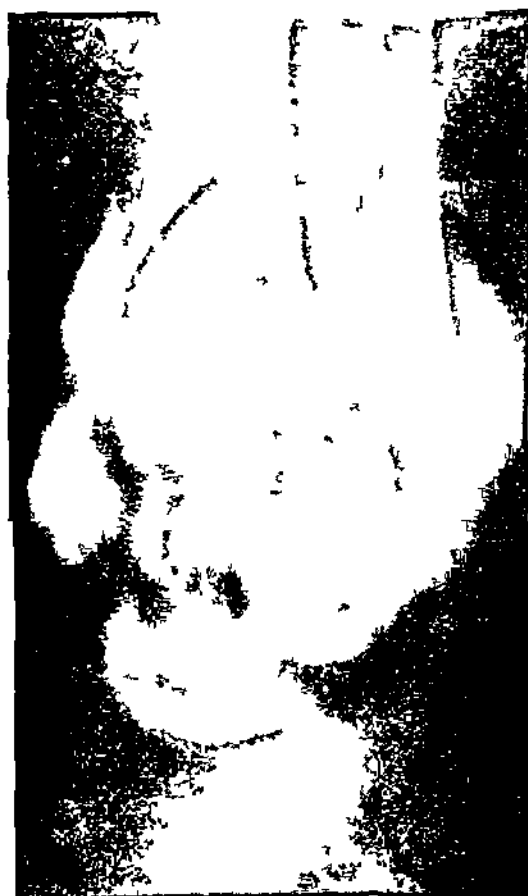


4 *Congenital clubfoot in a 15 month-old simultaneous arthrography of the talocrural talonavicular joints There is spontaneous first filling of a postero medial tendon sheath*
teral view The trochlea displays normal unding The recesses are diminished The ntral angle (α) of the trochlear curvature is duced (124°) The neck and head of the talus e deviating moderately in the plantar direc-m (β 38°)
rso-plantar view The talonavicular joint is viating moderately in the medial direction (γ 44°) but the articular surface of the talar ad is normally rounded

bone to its original position is considered possible Osteotomy is thus not indicated

Figure 6 also demonstrates marked medial and plantar displacement of the navicular bone but in this case the talonavicular joint recesses are obliterated Surgical reduction of the navicular bone is considered hardly possible Further if this reduction were in complete the navicular bone would certainly become displaced again Wedge osteotomy is indicated

The arthrogram in Figure 7 shows marked flattening of the talar trochlea combined with plantar medial deviation of the head of the talus and displacement of the navicular bone Here there are clear indications for correction osteotomy





a

[illegible] years [illegible] tinctly flattened (R/L = 0 47) The ankle recesses are diminished The central angle of the trochlear curvature (α) is small (101°) The neck of the talus and the talonavicular joint are clearly deviating in the plantar direction (β = 45°)

b) Dorso-plantar view The talonavicular joint is deviating considerably in the medial direction (γ = 60°) The articular surface shows fairly normal rounding, however, and the ankle recesses are retained Open reduction of the navicular bone is therefore considered possible

SURGICAL PROCEDURES

Talo-calcaneal osteotomy is always combined with soft tissue operations. If the tendo Achillis is to be lengthened, however, this should not be done at the same operation as the osteotomy but at a separate session either before or after Neither should transfer of the anterior tibial tendon be performed at the same time as the osteotomy, but at a later session. Some time should be allowed to elapse between the different sessions, so that the patient has time to activate the muscles and increase the mobility

If osteotomy is to be performed, the talonavicular joint should not be opened, as this may lead to avascular necrosis of the talar head It is therefore necessary to decide before the operation whether or not osteotomy is to be carried out.

The operations are always performed in a bloodless field

Operation session I

An incision is made on the medial [illegible] foot from the base of the first [illegible] malleolus and then proximally behind [illegible] posterior tibial tendon is freed [illegible] malleolus and then divided in a Z-shaped [illegible] This tendon is also identified close to [illegible] on the navicular bone and the distal [illegible] divided tendon is pulled down [illegible] on to the foot. The tibionavicular [illegible] divided and the neck of the talus is [illegible] medially, dorsally and at the [illegible] without opening the talonavicular joint.

The laciniate ligament is divided and [illegible] and blood vessels are carefully held [illegible] plantar fascia is freed at the calcaneal [illegible] and divided close to its insertion. The [illegible] hallucis muscle is then released [illegible] tuberosity and from the medial aspect of the [illegible] by careful dissection, avoiding damage [illegible] vessels and nerves. The wound is covered [illegible] moist compress.

An incision is now made over the [illegible]





5 Congenital clubfoot in a boy age 2 years hs Simultaneous arthrography
ral view The trochlea of the talus is tly flattened The central angle of the hlear curvature (α) is slightly reduced °) The ankle joint recesses are dimin l The talonavicular joint displays clear ation in the plantar direction (β 51°)

b) Dorso-plantar view The talonavicular joint is deviating greatly in the medial direction () — 66°) The ankle joint recesses are largely obliterated Wedge osteotomy is indicated

ort extensor muscle of the toes is released desired extent from its insertion The neck alus is then freed laterally and dorsally and irich retractor is placed around the neck knife and chisel a wedge is removed as in Figure 8 It is seldom poss ble to remove je of more than 45° to 50° Thus, full cor cannot always be achieved in extreme ities

riedrich retractor is appl ed around the cus medial to the peroneal tendons. A wedge of bone is then removed with a chisel, to the curvature deformity and to shorten the eus to some extent Care should be taken make the bone defect too large

osteotomy surfaces are now pressed er at the same time as the distal part of the foot is pronated Now it can be seen whether the osteotomy needs to be adjusted. Further the pos tion of the toes at full correction is checked. If they are locked in a flexed position then the long flexor tendons of the toes should be lengthened to avo d any later cavus deformity


If the peroneal tendons seem very flaccid at full correction they are usually shortened with zig-zag sutures, partly to give them some tension and partly to reduce the risk of their adhering to the osteotomy site during healing

The distal part of the posterior tibial tendon is

tendons are sutured with desired lengthening

The subcutaneous tissue and skin are closed with single sutures. Suction drainage is appl ed in both wounds, to reduce postoperative swelling which may otherwise be considerable


a


c



Secondary clubfoot in an 8 year old boy na bifida Simultaneous arthrography ral view The trochlea of the talus is mally flattened and the ankle recesses are erated The neck and head of the talus are ating greatly in the plantar direction o-plantar view The talonavicular joint is ating greatly in the medial direction () — The recesses are completely obliterated d) After talar and calcaneal osteotomy the tar and medial deviations have decreased derably

should be slackened slightly
xation a plaster cast cut longitudinally is with the foot in the desired correction knee flexed 90° The limb is elevated for ys. Postoperatively the foot is carefully d for swelling and any circulatory changes plaster cast is changed within 7 days, with correction or overcorrection of the foot al length of immobilization is 8 to 9 weeks. is time good healing of the osteotomy lines ly seen at radiological examination
rule the patient is then given a splint for ion at night and a shoe insertion for use in time

Operation session II

At this operation complementary procedures are carried out Lengthening of the tendo Achillis is often performed before the osteotomy but in some cases afterwards

It is relatively common that the anterior tibial muscle despite good correction of the foot deformity functions as a supinator If the patient sits relaxed with the foot dependent and on instruction dorsiflexes the foot it is clearly seen how the foot is first supinated by the anterior tibial muscle and is then dorsiflexed In these cases either the entire tendon has been transferred to the middle of the dorsal aspect of the foot or the tendon has been divided longitudinally and half of it has been transferred to the lateral aspect of the foot The latter procedure was described by Baumann (1970) and good results have been reported

In extreme cases the skeletal correction has not always been quite satisfactory and slight supination and a certain degree of adduction have remained In such cases the early skeletal correction has been complemented by wedge osteotomy through the cuboid as depicted in Figure 9 a–d.

DISCUSSION

In an anatomical and functional investigation of clubfoot specimens we found that on dorsiflexion of a greatly deformed talus an incongruence in the talocrural joint occurs Further we pointed out that "due to the deformation of the articular facets of the talar head the navicular bone may after reposition have only a very small supporting area with a consequent great risk of reluxation' (Hjelmstedt & Sahlstedt 1974a) As a solution to these problems we proposed a corrective osteotomy

After 8 years experience of arthrographic analysis of the talar deformity in clubfoot and 6 years' experience of correction osteotomies, we are still convinced that osteotomy is an essential part of the treatment plan in a small selected group of refractory clubfeet

The method presented here is the one which with our increasing experience we have found to be the best It has often been necessary to diverge from the treatment plan for the reason that different types of operations have been performed before the patient has been referred to us. Furthermore,

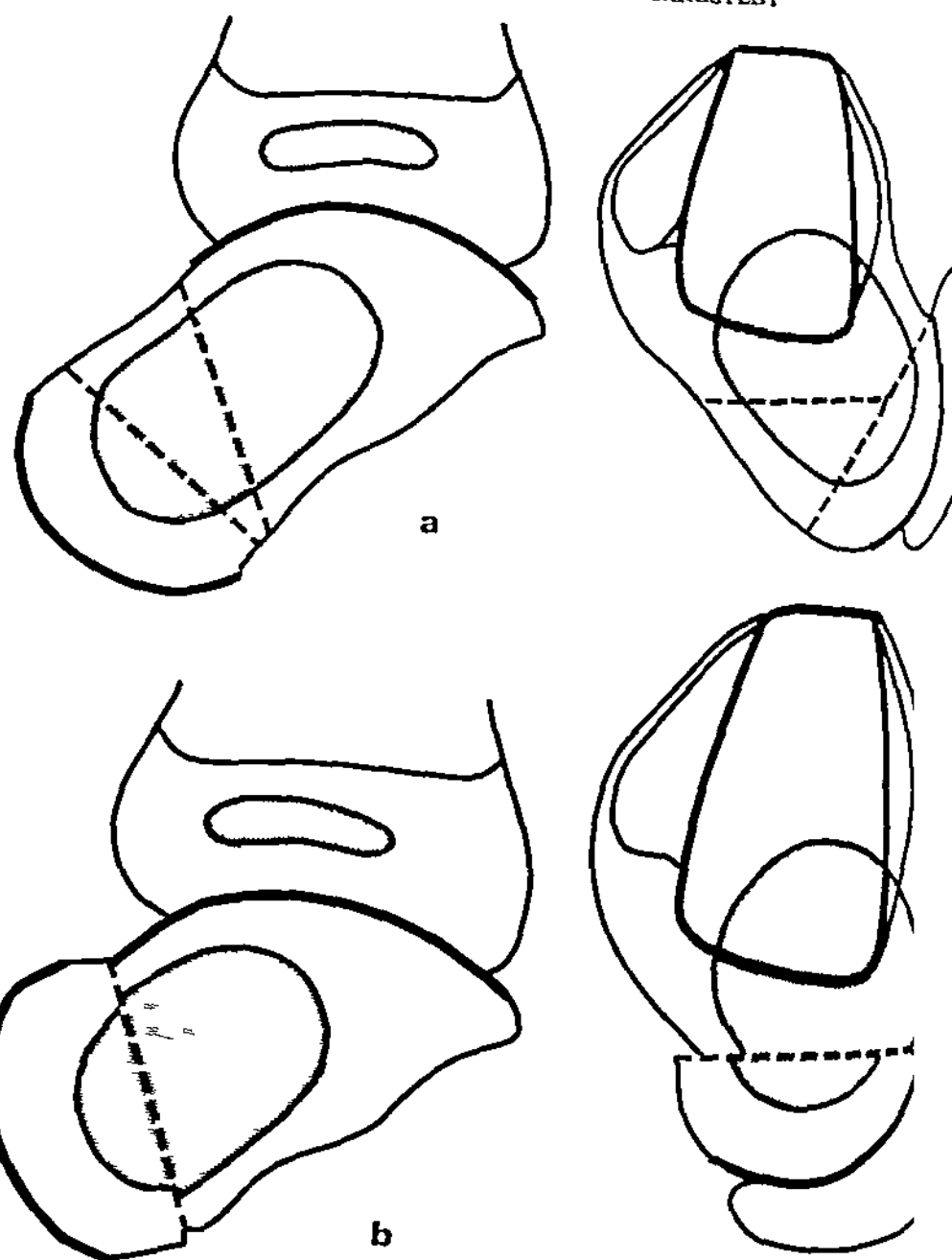
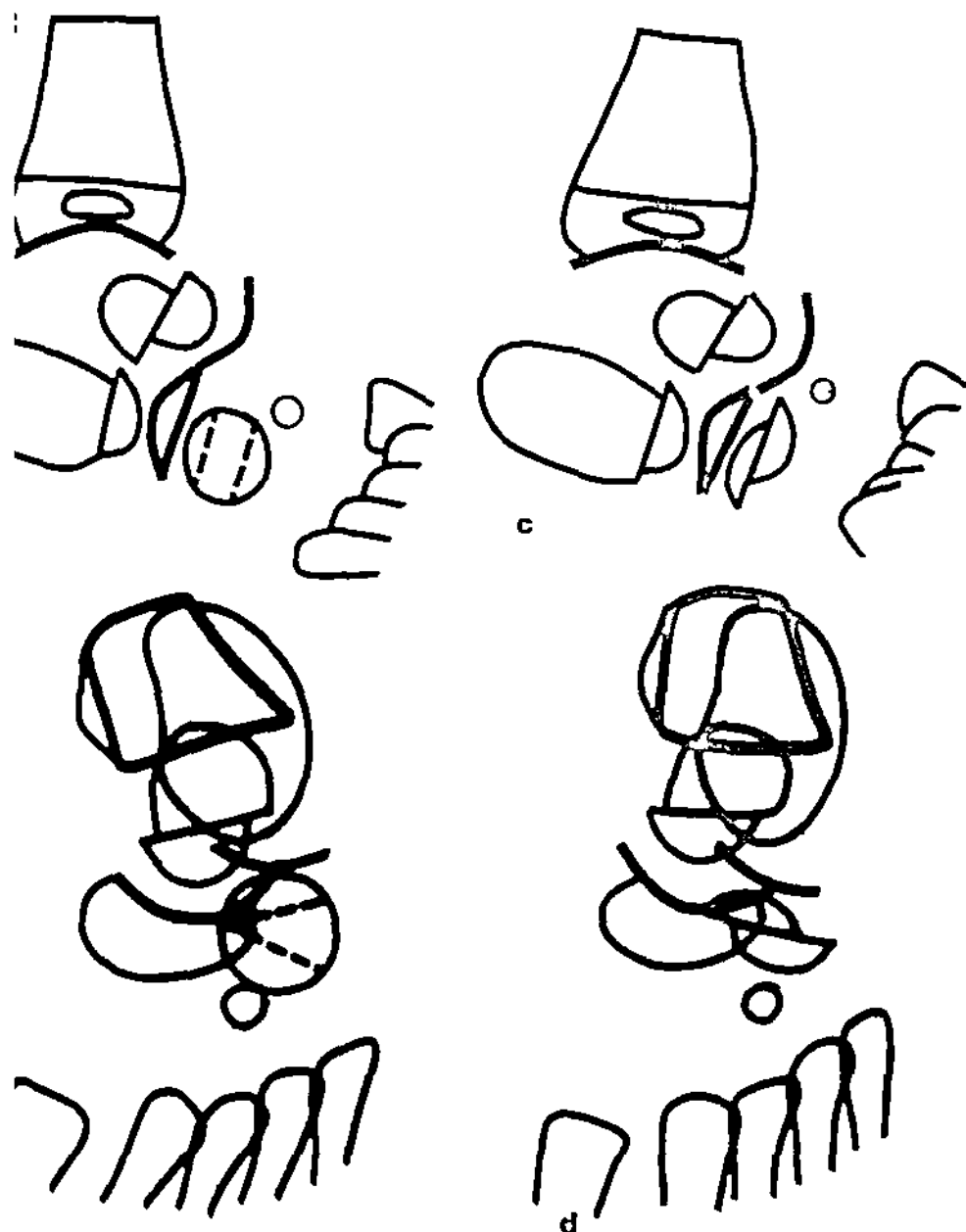


Figure 8 a) Lateral view of a clubfoot talus Note the flattening of the trochlea and plantar deviation of the neck and head The osteotomy lines are marked with short dashes The base of the wedge should as a rule be on the dorso-lateral side of the talar neck
b) Correction after wedge osteotomy
c) A clubfoot talus and the navicular above The joint borders are marked with broad lines and the osteotomy lines with dashes Note the pronounced medial deviation of the talar neck and head and the [illegible] *of the original talonavicular joint*
d) Correction after osteotomy

in the beginning we were somewhat uncertain about the planning of an adequate form of treatment

Skin necrosis at the margins of the medial wound is a risk that must always be taken into consideration, but this has [illegible] avoidable by the precautionary [illegible] mentioned above It has also been [illegible] guard against wound infection. In one extreme talar deformity however [illegible]



a) and b) Schematic drawing of a clubfoot after talar and calcaneal osteotomy Planned wedge y through the cuboid bone is indicated with a broken line The base of the wedge is oriented

Correction after osteotomy

of the talar occurred (Figure 10) As rvation time to date in this patient is few years, it is too early to say this complication will affect the final ut hitherto the child has not had any ns.

Considerable scar formation might be expected after several extensive operations In the beginning we were in fact restrictive with soft tissue procedures in connection with osteotomy, and as a consequence the complementary operations in session II became



more extensive It has been found that even after relatively large open wounds have healed without leaving tracting scars, and the treatment described can thus be recommended aspect as well

CONCLUSIONS

Indications for correction osteotomy based upon an arthrographic analysis anatomy

Osteotomy is indicated in only a of clubfoot cases.

Correction *osteotomy* is only one *comprehensive* treatment plan.

With the described *planning* of the ation and treatment, and with observance of *all details* of the procedure, the risk of complications is the correction achieved is generally

Figure 10 a) and b) Avascular necrosis in the head of the talus 2 years after wedge osteotomy in a case of secondary clubfoot

REFERENCES

Batchelor, J S (1946) The treatment uncorrected clubfoot in childhood *Soc Med.* 39, 713–715

. . 079 O . . . D k . . .. der
eorg

. M (1892) Operative treatment of
. clubfoot *Trans Amer orthop Ass* **5,**
?

. & Muro F (1934) Decancellation of
.alcis, astragalus and cuboid in correc
.ongenital talipes equinovarus *J Bone*
16, 110–118

. (1955) La deformation de l astragale
.quinisme invetere du pied creux comme
dans son traitement operatoire Proc
Congress Orthop Surg Brusselles 6
.

.n, H (1955) Der Klumpfuss
.men Anatomie Behandlung und
.ultate *Z Orthop* **85,** 305 321

. Å & Sahlstedt B (1974a) Talar
.ty in congenital clubfeet An anatomical
.ct onal study with special reference to
.le joint mobility *Acta orthop scand*
. 640

. Å (1974b) Correction osteotomy
of the talus and calcaneus in relapsing or
incorrigible clubfeet Principles and technique
Acta orthop scand **45,** 978–980 (Abstract)

Hjelmstedt Å & Sahlstedt B (1977) Simultaneous arthrography of the talocrural and talonavicular joints in children III Measurements on normal feet *Acta radiol Diagn* **18,** 513–522

Hjelmstedt Å & Sahlstedt B (1978) Simultaneous arthrography of the talocrural and talonavicular joints in children IV Measurements of congen tal clubfeet *Acta radiol Diagn* **19,** 223–236

Hjelmstedt Å & Sahlstedt B (1980) Talocalcaneal osteotomy and soft tissue procedures in the treatment of clubfeet II Results in 36 surgically treated feet *Acta orthop scand* **51,** 349–357

Meusel (1890) Ueber eine neue Klumpfuss operation *Verh dtsch Ges Chir* **19,** 84–86

Sahlstedt B (1976) S multaneous arthrography of the talocrural and talonavicular jo nts in children I Technique *Acta radiol Diagn* **17,** 545 556

dence to Åke Hjelmstedt M D Department of Orthopaed c Surgery University Hospital
Uppsala Sweden

op scand 51, 349–357, 1980

)-CALCANEAL OSTEOTOMY AND SOFT-TISSUE 'EDURES IN THE TREATMENT OF CLUBFEET

ults in 36 Surgically Treated Feet

·MSTEDT & B SAHLSTEDT

ents of Orthopaedic Surgery and Diagnostic Radiology,
ty Hospital, Uppsala, Sweden

Thirty-six refractory or recurrent clubfeet were treated by correction osteotomy through the talar neck and calcaneus in combination with various soft tissue procedures The aim of the osteotomies was to correct the pronounced deformities observed at simultaneous arthrography of the talocrural and talonavicular joints The soft tissue procedures were carried out to facilitate the correction and to prevent recurrence by creating muscle balance

Twenty-four clubfeet were idiopathic and 12 were secondary to neurological or other diseases The observation period since the osteotomies were performed was, at the time of writing, 1 5 to 5 5 years (median 3 years). A brief report of the indications and methods of operation is given

Good or fair results were achieved in 21 of the 24 idiopathic clubfeet, while the results were somewhat poorer in the secondary clubfeet A correlation between the degree of arthrographically demonstrated talar deformity and the results of surgical treatment was found

The main reason for a poor result was incomplete correction of the most extreme talar deformity in combination with marked preoperative joint rigidity

Key words arthrography, clubfoot, osteotomy, soft tissue procedures

Accepted 4 i 79

:ted cases of refractory or recurrent ·, correction osteotomy through the the talus and the calcaneus has con- · an important part of the treatment 972 As an average of 3 years has now since the first 36 operations were ied, the preliminary results in these ·ill now be presented

treatment in a number of these I deviated in certain respects from that ed in the foregoing article and also ie recommended treatment plan, so we red it appropriate to present our d in a separate report

deviations do not refer to indications ·ration or operative principles, how- ·ut to the time of operation and to technical details in the surgical procedure One main reason for the deviations in the initial cases of the series was lack of experience at that stage

PATIENTS

There were 16 patients with 28 idiopathic clubfeet and 9 patients with 14 clubfoot deformities secondary to spina bifida (6), spastic paresis (2), malformation syndrome (1), arthrogryposis (2) and sacral agenesia (1)

Osteotomy was performed on 24 of the idiopathic clubfeet and in 12 of the secondary clubfeet

The sex and age distributions and the observation times after osteotomy in the two groups are given in Table 1

·0 80 020349–09$02.50 0

Table 1 [illegible]

	Series of idiopathic clubfeet	Series of secondary clubfeet	T[illegible]
Number of boys	13	4	[illegible]
Number of girls	3	5	[illegible]
Total number of patients	16	9	[illegible]
Number of osteotomized feet	24	12	[illegible]
Number of feet treated by other methods	4	2	[illegible]
Total number of clubfeet	28	14	[illegible]
Median age at osteotomy (years)	1 7	4 8	[illegible]
Min and max ages at osteotomy (years)	0 4 —— 6 7	0 4 —— 8 3	0 4 —[illegible]
Median obs. time after osteotomy (years)	3 0	3 8	[illegible]
Min and max obs times (years)	1 5 —— 5 5	1 5 —— 5 5	1 5 —[illegible]

The group of osteotomized idiopathic clubfeet is selected and comprises cases where conservative and, as a rule, also operative treatment had not given satisfactory correction, or where the deformity had recurred (Table 2)

The number of osteotomized secondary clubfeet is, for natural reasons, smaller than the number with a congenital deformity (Table 2) The median age at osteotomy was relatively high (4 8 years) in these secondary cases One reason for this was that treatment of urinary tract infection and/or hip and knee contractures had been given priority over foot correction

All 36 feet had a pronounced or extreme clubfoot deformity before the osteotomy, with varying degrees of limitation of movement in the talocrural and subtalar joints and in Chopart's joint

Before the osteotomy simultaneous arthrography of the talocrural and talonavicular joints was performed routinely by the [illegible] described by Sahlstedt (1976a,b) The [illegible] this method for measurement of the [illegible] deformities has been investigated [illegible] (Hjelmstedt & Sahlstedt 1976) and has [illegible] good or fair for the variables in [illegible] Normal values and an analysis of [illegible] values from a material of clubfee[illegible] reported by Hjelmstedt & Sahlstedt (19[illegible]

The variables measured and the values [illegible] are presented in Table 3 with normal [illegible] comparison, and the methods of measure[illegible] illustrated in Figure 1a–c in the [illegible] (Hjelmstedt & Sahlstedt 1979) It is [illegible] Table that the mean values for the [illegible] deviated considerably from the norm[illegible] values

The indications for correction [illegible] as follows

A The clubfoot deformity had [illegible]

Table 2 Treatment given before the osteotomy The material is selected and consists of c[illegible] were not adequately corrected after the treatment described in the Tab[illegible]

Treatment	Number of idiopathic clubfeet	Number of secondary clubfeet	T[illegible]
Conservative treatment alone	6	6	[illegible]
Lengthening of tendo Achillis alone	7	1	[illegible]
Lengthening of tendo Achillis + other soft tissue procedures	10	5	[illegible]
Tibial osteotomy	1		[illegible]
Total number of clubfeet	24	12	[illegible]

—1 Results of the radiographic measurements of talar variables in the osteotomy series R – radius rochlear curvature and L – length of the talus The measurement methods are illustrated in 1a–c of the foregoing paper (Hjelmstedt & Sahlstedt 1979) With 90 per cent confidence 95 per 1 normal population will fall within the tolerance limits The means of the variables in the et are all pathological The individual values vary considerably and some are very extreme

	Preoperative values for idiopathic clubfeet $n-24$		Preoperative values for secondary clubfeet $n-12$		Normal values n 54	
	mean	range	mean	range	mean	95 per cent tolerance limits
dex of the ing of the a	0 47	0 38–0 85	0 48	0 35 0 74	0 35	0 29–0 42
angle α of the ar curvature	108°	143–53°	102°	142 64°	154°	173 135°
deviation β of the vicular joint	47°	26 65°	53°•	33 84°	24°	14–35°
deviation γ of the vicular joint	52°	18–78°	55°	31–90°	15°	8–22°

• es that the plantar deviation could not be measured on 2 of the 12 feet

actorily corrected by previous treatment id recurred
presence of pronounced medial or plantar tion or both of the head and neck of the plantar medial dislocation of the ular bone and such marked deformation – talonavicular joint that a reduction of the ular bone to its original position was not dered possible (Figure 1a b)

The indications for operation are described and illustrated in greater detail in the foregoing paper (Hjelmstedt & Sahlstedt 1979)

The aim of the operation was to correct as much as possible of the foot deformity retaining the mobility of the different joints, by means of wedge osteotomy through the talar neck and calcaneus (see Figure 2)

The simultaneous soft tissue procedures were

1 The soft tissue operations that were performed in conjunction with talo-calcaneal osteotomy ion session I) In 23 feet the tendo Achillis had been lengthened on a previous occasion and in 6 posterior tibial tendon had been lengthened divided or transferred previously (see Table 2)

al	Age at operation (years) median	Lengthening of: tendo Achillis	post. tibial tendon	tendon of flexor dig communis	tendon of flexor hall long	Shortening of one or both peroneal tendons	Plantar fasciotomy + release of abd hallucis muscle
hic eet 4	1 7	4	21	11	8	9	18
ary eet 2	4 8	2	9	1	3	1	5
16	1 9	6	30	12	11	10	23



Figure 1 *Arthrography of the talocrural and talonavicular joints in an 18 month-old [illegible] severe clubfoot deformity*

a Lateral view Note the pronounced flattening of the trochlea and the plantar deviation of the [illegible] navicular joint R/L — 0 46 β = 44° Normal values 0 29–0 42 and 14°–35°, [illegible]

b Dorso-plantar view There is considerable medial deviation of the talonavicular joint [illegible] value 8°–22°

undertaken to facilitate the correction and to prevent recurrence by improving the muscle balance The extent of these procedures was determined by the preoperative clinical status and an evaluation during the course of the operation The soft tissue operations performed in conjunction with the osteotomy are given in Table 4 These combined operations are referred to as session I

Transfer of half or the whole of the anterior tibial tendon to the lateral part of the dorsal aspect of the foot was often indicated in order to reduce the tendency to supination and to increase the power of dorsal extension It was considered unsuitable to do this at the same operation as the talo-calcaneal osteotomy and it was therefore performed when necessary at a second session, on average 1 5 years after the first A wedge resection through the cuboid bone [illegible] carried out at the same time (see Table [illegible]

The arthrographies generally [illegible] preoperatively the patients were [illegible] the foot as much as the deformed [illegible] allowed Thus in these cases [illegible] tendo Achillis would not increase [illegible] the ankle joint There were two [illegible] rule however and in these two [illegible] Achillis was therefore lengthened [illegible] session 5 months after the [illegible] operations performed in session II [illegible] Table 5

The operative technique [illegible] developed with increasing [illegible] years is described in detail in the [illegible] (Hjelmstedt & Sahlstedt 19[illegible])

2 Photograph taken during wedge
ny through the talus and calcaneus The
in the lower left corner and the toes to the
he incision has been made over the tarsal
l greatly angulated wedge has been excised
e neck of the talus A less angulated wedge
being removed from the calcaneus with an
ne The short extensor muscle of the toes
has been partly released from its insertion,
to the right of the wound

RESULTS

All osteotomized feet showed a marked deformity of the talus and its joints preoperatively (Table 3 and Figure 1a–b) The aim of the osteotomy was to correct the plantar and medial deviations of the talar neck and head and the calcaneal deformity The deformity of the talocrural and talonavicular joints remained unaltered, of course, as well as the other skeletal deformities It could not be expected, therefore, that in any of the patients full mobility would be achieved in all joints or full correction of that part of the adductor and supination deformities caused by skeletal dysplasia distal to the navicular and cuboid bones

This meant that a "very good result" as defined in Table 6 would only be possible in a minority of cases In cases with severe deformity of the talocrural joint it was hardly likely that a better result than 'fair" would be obtained

The evaluation of the treatment results 1 5–5 5 years after the osteotomy is based upon the clinical examination Routine arthrography at follow-up was not considered possible The criteria for classification of the results in the idiopathic clubfeet are given in Table 6 For the secondary clubfeet the evaluation had to be made against the

5 The procedures carried out at operation session II in 13 of the 24 osteotomized idiopathic
' The time interval between session I and session II ranged from 4 5 months to 3 years (median
rs) In the group of secondary clubfeet two feet underwent lengthening of the tendo Achillis in a
session and in a case of arthrogryposis with a poor functional result triple arthrodesis was
performed later

	Median age at operation session II	Procedures at operation session II				
		Transfer of		Lengthening of tendo Achillis	Shortening of the peroneal tendons	Wedge osteotomy through the cuboid
		The whole ant tib tendon	Half the ant tib tendon			
thic feet 13	2.8 years	4	9	2	2	8

Table 6 Classification of the treatment results [illegible] talus was [illegible]

	Result of treatment			
	Very good	Good	Fair	Poor
Dorsiflexion of the foot	10–15°	5–10°	0–5°	⩽10° [illegible]
Plantar flexion of the foot	⩾20°	⩾15°	⩾10°	reduced
Mobility of subtalar joints	good	possibly slightly reduced	reduced	reduced
Mobility of mid-tarsal joints	good or hypermobile	good, possibly hypermobile	relatively good	reduced
Deformity on weight-bearing				
equinus	–	–	–	+
varus	–	–	–	– or +
adductor	insignificant	<15°	⩾15°	+
Gait without shoes	good	good	fair	poor
Gait with shoes	good	good	good	fair

background of the patient's basic disease —thus the classification in these cases was more subjective

The results of the treatment are presented in Table 7 Good or very good correction and function according to the criteria in Table 6 were achieved in 17 of the 24 idiopathic clubfeet (70 8 per cent) and a fair result in 4 (16 7 per cent) In the secondary clubfeet the results were poorer, as expected in view of the less favourable original condition in these cases (Table 3)

The result was regarded as poor in 3 of the 24 idiopathic and 4 of the 12 secondary clubfeet There were two principal reasons for the poor results In some cases with severe skeletal deformity it was not possible to remove a sufficiently large wedge from the talus to achieve full correction In particular a residual equinus of up to 10° gave a functionally unfavourable result The second reason, which as a rule was combined with the first, was pronounced rigidity [illegible] talocrural, subtalar and Chopart's [illegible] was already present preoperatively [illegible] some of the secondary and in some idiopathic clubfeet.

As shown in Tables 8 and 9 the [illegible] of talar deformity correlated [illegible] therapeutic result.

In seven feet a policy of expectant [illegible] followed for 1 5 years or longer before [illegible] II was undertaken The aim of this [illegible] see whether there was any regression [illegible] residual adductor and/or supination de[illegible] after treatment with a shoe [illegible] night splints No appreciable [illegible] was noted

Despite the fact that session I [illegible] relatively extensive operation, that [illegible] was carried out in many cases, and [illegible] feet were immobilized for a total of [illegible] weeks, no definite reduction of the [illegible] the joints was observed On the other

Table 7 The functional result 1 5–5 5 years (median 3 2 years) after the osteotomy [illegible] criteria given in Table 6

	Very good	Good	Fair	Poor	T[illegible]
Idiopathic clubfeet	7	10	4	3	[illegible]
Secondary clubfeet		4	4	4	[illegible]
Total	7	14	8	7	[illegible]

–ı– Comparison between measurement data obtained at arthrography before talo-calcaneal ı- y and the results of treatment in the idiopathic clubfeet R/L *– index of the flattening of the – α – central angle of the trochlear curvature, β plantar deviation and γ medial deviation of the –ular joint The method of measurement is shown in Figure 1a–c of the foregoing paper (Hjelmstedt & Sahlstedt 1979)*

–ent result	No of feet	Arthrographic variables			
		R/L	α	β	γ
–d	7	0 44	116°	52°	47°
	10	0 45	113°	47°	51°
	4	0 49	101°	46°	52°
	3	0 56	77°	41°	69°

Comparison between measurement data obtained at arthrography before talo-calcaneal y and the results of treatment in the secondary clubfeet For explanation of variables see Table 8

–nt result	No of feet	Arthrographic variables			
		R/L	α	β	γ
	4	0 42	116°	44°	45°
	4	0 46	105°	49°	68°
	4	0 57	87°	65°	52°

–me cases a certain degree of –ıobility of the mid-tarsal joints –sed

–operation wounds healed without –n or necrosis and with no contractive

–ne case avascular necrosis occurred in –ad of the talus postoperatively

–JSSION

–revious study (Hjelmstedt & Sahlstedt –) we showed that there is some correla- –tween the central angle of the trochlear –ure (α) and flattening of the trochlea – the angle decreasing when the –ing becomes more pronounced –wise there are no or only weak cor- –ns between the different arthrographi– –measurable variables. This means that a – and practicable classification of –et according to the type and degree of deformity is not possible and that all clubfeet must therefore be treated on an individual basis.

The poor correlation between the different variables also means that the forces causing the talar deformity vary from case to case with respect to magnitude and direction and probably also duration In the neurological cases we know that the muscle forces deviate from the normal The nature of the deformation forces in the idiopathic cases is not known, but it is probable that the mechanism is similar i e that the normal muscle balance is disturbed With time, of course weight-bearing will also play a part in the further development of the deformity

From this viewpoint the restoration of the muscle balance will be one of the prerequisites for successful treatment, and this can only be achieved by measures that vary in the individual patient

In the simplest cases muscle balance is attained by conservative treatment alone with reduction of the navicular and cuboid bones, i e by normalizing the direction of the muscle forces. In the more refractory or recurrent

clubfeet this is not sufficient, and in these cases balance between the muscle forces has to be created by surgical procedures such as open reduction of the navicular bone and lengthening, shortening and transfer of different tendons.

However, there is a minority of idiopathic clubfeet in which the skeletal deformity is so pronounced that soft tissue procedures alone are insufficient to create a balance of muscle power In such cases the direction and magnitude of the muscle forces can only be normalized by soft tissue procedures combined with corrective bone operations. As reported by Settle (1963), Irani & Sherman (1963), Reimann (1967) and Hjelmstedt & Sahlstedt (1974), among others, severe skeletal deformity can be present at birth For practical reasons, however, arthrography and operation cannot be performed immediately but have to wait until the child is at least about 6 months old Talo-calcaneal osteotomy is not a routine method in the treatment of clubfoot, but is only indicated in 10–15 per cent of idiopathic cases (Hjelmstedt & Sahlstedt, 1980) The primary treatment of clubfoot should always be conservative, as this gives a good result in a large proportion of the cases.

In some cases the osteotomy was performed at 5–6 months. The operation proved to be relatively difficult, however, at this early age, and it is preferable to wait until the child is at least 9 months old

If it is nevertheless considered necessary to lengthen the tendo Achillis at an earlier age, this should be preceded by arthrography so that a more complete treatment plan can be drawn up It should be the principle to map out the anatomy before any type of surgical operation.

The osteotomies healed in 8 to 9 weeks. Thereafter a shoe with an insertion was worn and also, as a rule, a night splint In the beginning the patient should be followed up at intervals of 2–3 months. If full muscle balance has not been achieved, complementary operations should be performed (Table 5)

The only complication [illegible] was avascular necrosis of the [illegible] talus in one case After [illegible] talar head and the trochlea [illegible] supply through vessels in the [illegible] talocrural and talonavicular [illegible] therefore important to avoid [illegible] capsule at the operation. In cases [illegible] most severe deformities, [illegible] difficulty may be encountered [illegible] generally rather rigid join[illegible] capsule may be inadvertently [illegible]

In cases with marked [illegible] trochlea, an extremely small [illegible] pronounced medial or plantar [illegible] head and neck of the talus, [illegible] rection was not always [illegible] osteotomy (Tables 8 and 9). These [illegible] described as "poor" in accordance [illegible] given criteria. The only alternative [illegible] treatment in these extreme cases [illegible] to be triple arthrodesis. As this [illegible] done on small children, [illegible] osteotomy may be justifiable [illegible] cases as a temporary measure [illegible] for a suitable time for arthrodesis

Because of the necessity for [illegible] arthrography, and because of [illegible] individualized surgical measures [illegible] opinion all operations on clubfeet [illegible] centralized

CONCLUSIONS

Wedge osteotomy through the [illegible] calcaneus allows correction [illegible] of the severe deformity of the [illegible] calcaneus in refractory clubfeet.

Correction osteotomy [illegible] with lengthening and shortening [illegible] and also, in some cases, with [illegible] anterior tibial tendon in order [illegible] muscle balance

For practical reasons these [illegible] often need to be divided [illegible] with an interval of 5 to 6 months

The plan of operative treatment [illegible] here should only be applied to [illegible]

cases and the indications for ...on are based largely upon the findings ...erative simultaneous arthrography of ...crural and talonavicular joints.

... selected material of 24 refractory or ...t idiopathic clubfeet with pronounced ...formity a good or fair result was ...d in 21 feet (87 5 per cent) The result ...newhat poorer in a smaller series of ... secondary to neurological or other ...ns.

...ENCES

...dt, Å (1974) Correction osteotomy of the ... and calcaneus in relapsing or incorrigible ...eet. Principles and technique *Acta orthop* ...d 45, 978–980 (Abstract)

...edt Å & Sahlstedt B (1974) Talar ...mity in congenital clubfeet *Acta orthop* ...d 45, 628 640

...edt, Å & Sahlstedt B (1976) ...ultaneous arthrography of the talocrural ... talonavicular joints in children II ...parison between anatomic and arthro...hic measurements. *Acta radiol Diagn* 17, ...564

...edt, Å & Sahlstedt B (1977) ...ultaneous arthrography of the talocrural ... talonavicular joints in children. III Measurements on normal feet *Acta radiol Diagn* 18, 513–522.

Hjelmstedt, Å & Sahlstedt B (1978a) Simultaneous arthrography of the talocrural and talonavicular joints in children. IV Measurements on congenital club feet *Acta radiol Diagn* 19, 223–236

Hjelmstedt Å & Sahlstedt B (1980) Talocalcaneal osteotomy and soft tissue procedures in the treatment of clubfeet I Indications, principles and technique *Acta orthop scand* 51, 335–347

Hje... series. *Acta orthop scand* 51, 321–334

Irani R N & Sherman M S (1963) The pathological anatomy of clubfoot. *J Bone Jt Surg* 45 A 45 51

Reimann I (1967) *Congenital idiopathic club foot* Thesis Munksgaard Copenhagen

Sahlstedt B (1976a) Simultaneous arthrography of the talocrural and talonavicular joints in children. I Technique *Acta radiol Diagn* 17, 545 556

Sahlstedt B (1976b) Simultaneous arthrography of the talocrural and talonavicular joints in children with special reference to the anatomy of the talus in normal feet and congenital club foot Abst Uppsala Dissert Faculty Med. no 255 Centraltryckeriet AB Uppsala.

Settle G W (1963) The anatomy of congenital talipes equinovarus sixteen dissected specimens. *J Bone Jt Surg* 45 A 1341–1353

...ondence to Åke Hjelmstedt MD Department of Orthopaedic Surgery University Hospital ...14 Uppsala Sweden.

› scand 51, 359–364, 1980

EEDINGS OF
DANISH ORTHOPAEDIC SOCIETY

o, 27–28 April, 1979

N J HOLM

OR McLAUGHLIN IN
NTERIC FRACTURES?

B Lund & J Lauritzen
nt of Orthopaedic Surgery, Århus
Hospital, Århus

rospective, randomized study 146 con-
rochanteric fractures treated either with
ns or McLaughlin nail and plate were
l The mean age was 76 years.
sia time, operating time and the duration
alization were almost equal in the two
During the first postoperative month there
e deaths in the McLaughlin group and
Ender group
patients treated with Ender pins had
ee problems and 10 needed reoperation
fection occurred after two McLaughlin
is.
l year the situation concerning pain and
it in the hips was almost identical in the
ps

THE PROGNOSTIC VALUE OF PAUWELS' AND GARDEN'S CLASSIFICATIONS OF MEDIAL FRACTURES OF THE FEMORAL NECK

P A Frandsen & E Frigaard
Departments of Orthopaedic Surgery and Radiology, Odense University Hospital, Odense

In a study of 265 consecutive cases of medial fracture of the femoral neck the classifications of Pauwels and Garden were compared in order to determine which is the better system of classification In all three groups Pauwels' classification showed almost the same frequency of healing ($P > 0.05$, Chi square test) However, Garden's classification gave a reliable statement concerning the prognosis of the different types of medial fractures of the femoral neck ($P < 0.0001$, Chi square test) Therefore the authors recommend that only Garden's classification should be used

MENT OF FEMORAL NECK
JRES IN A DEPARTMENT OF
AL SURGERY

aard
Department, Varde Hospital

ll of 145 patients with fractures of the
neck (53 dislocated medial, 69
eric and 23 stable), treated in a surgical
nt, are reviewed
cumulative mortality 6 months
atively was 18 5 per cent, between 6 to 12
another 6 per cent died, thus equalling the
mortality for this age group
ylactic anticoagulation reduced the
y rate from 25 to 10 per cent ($P < 0.05$)
two per cent of the patients were able to
the time of leaving the hospital
concluded that the mortality rate is no
than that reported for other series of
with this type of fracture

THE INCIDENCE OF MEDIAL FRACTURES OF THE FEMORAL NECK

P A Frandsen
Departments of Orthopaedic Surgery O & Ø, Odense University Hospital, Odense

In a population of 230,000 the incidence of medial fractures of the femoral neck related to sex and age was determined The determination was based on 156 fractures treated during a 2-year period For the same period the incidence was compared with the total incidence of medial [illegible]
the same for men and women, but above the age of 60 years the incidence in women was greater by a factor of three compared with that in men

0 80/020359–06$02.50 0

...ritic cartilage as described by others and ...ct probably an accelerated synthesis of ...noglycans of a more immature nature

...CHANTERIC FRACTURES OF ...MUR

...stgaard
...dic Department, Holstebro Central

...patients were treated for pertrochanteric ...of the femur in the period 1974 to 78, 20 ...ated with osteosynthesis *ad modum* ...in, 15 *ad modum* Ender, and five were ...onservatively

...comparison of the results in the ...lin and Ender groups the walking ability ...as good in the latter group, but there ...er complications, probably because of the ...operating trauma and the possibility of ...ilization

...re the method of Ender will be preferred ...of pertrochanteric fractures

...HIP REPLACEMENT ...UM RING

...en
...nt of Orthopaedic Surgery, Kolding

...sults of 295 Ring total hip replacements ...up for 2–9 years (mean 5 4) are pre-

...re- and postoperative conditions were ...using a modified scale of Merle ...é Improvements were registered for ...to 5 4 points), mobility (2 5 to 5 0 points) ...ing capacity (2 2 to 4 0 points) ...was one operative death (0 3 per cent) ...mplications Early deep infection 0 7 per ...deep infection 0 7 per cent, dislocation ...cent 4 4 per cent needed revision for ...(long femoral component 1 0 per cent, ...oral component 8 6 per cent) ...esults were found to be statistically ...tly better using the long, as opposed to the ...oral component ($P < 0.05$)

...URE OF THE FEMORAL NECK ...ED BY MOORE ALLOPLASTY

...ent of Orthopaedics, Århus ...tehospital

...ight surviving patients out of 180 who ...n treated with a Moore alloplasty for ...of the femoral neck were re-examined in 1972, 8 years after the operation Half of the patients were free of pain and the other half had episodes of pain and limping Only seven were unable to walk because of senility, rheumatoid arthritis or hemiplegia There was a correlation between poor prosthetic adaptation and subsequent shortening of the femoral neck, pain and limping, protusio acetabuli, and loosening of the prosthetic stem The Moore prosthesis remains a reasonable method of treatment for fractures of the femoral neck in the elderly Cementation of the prosthetic stem seems advisable

PERTROCHANTERIC AND SUBTROCHANTERIC FEMORAL FRACTURES TREATED BY ENDER NAILING

E Frøkiaer
Department of Orthopaedic Surgery, Haderslev Hospital

Within a 2-year period 40 patients with pertrochanteric and 12 with subtrochanteric fractures were treated with Ender nailing The patients were mobilized as quickly as possible, and were allowed to bear weight on the fractured leg within the limits of pain 1 to 6 weeks after the operation, in most cases after 1 week

Three to six months after the operation 37 patients were mobile with or without the aid of sticks, six had died and nine were unable to walk Nine patients had minor symptoms in the knee, and three in the hip In eight patients the nail moved downwards and five had to be reoperated

WHAT IS THE COST OF AN INFECTED TIBIA OSTEOSYNTHESIS?

J Greiff
Department of Orthopaedic Surgery, Gentofte Hospital

In 1974 a 28-year-old male sustained a complicated fracture of the tibia After primary conservative treatment, osteosynthesis was performed using a small plate Due to inadequate reduction of the fracture a re-osteosynthesis was performed some weeks later The osteosynthesis became infected, and in the following 5-year period several secondary operative procedures were carried out, including revisions and skin transplantations

The expenses incurred by the patient and the community were calculated to be about one [illegible]

THE IMPORTANCE OF THE ANGLE BETWEEN THE FRACTURE LINE AND THE NAIL IN MEDIAL FRACTURES OF THE FEMORAL NECK

P A Frandsen & E Frigaard
Departments of Orthopaedic Surgery and Radiology, Odense University Hospital, Odense

In medial fractures of the femoral neck treated with a single nail one would expect from a mechanical point of view that the rotatory stability of the fracture would be at its lowest when the angle between the fracture line and the nail was 90 degrees This hypothesis was tested in a consecutive series of 197 displaced medial fractures of the femoral neck The results showed significantly better healing ($P < 0\ 025$, Chi square test) when the angle between the nail and the fracture line, as measured on a frontal radiograph, was less than, as opposed to more than, 80 degrees

HIP FRACTURES A PROGNOSTIC EVALUATION OF THE NECESSARY HOSPITAL RESOURCES

J Steen Jensen & E Tøndevold
Department of Orthopaedic Surgery, Gentofte Hospital

A total of 1,592 patients over the age of 50 years with hip fractures were examined The incidence of hip fractures was found to increase exponentially with age and to be twice as prevalent in females The percentage of femoral neck fractures decreased with age in females but was independent of age in males

From 1971–1977 the number of hip fractures increased by 12 per cent yearly Based on the prognosis for the population the expected increase is 3 per cent yearly until 1992 This means a doubling of the number of hip fractures over a 15–20 year period

The hospitalization time decreased from 28 days to 21 days during the period investigated

With unchanged results of the fracture treatment and a hospitalization time of 20 days about 20 per cent of the total number of orthopaedic beds in the area will be occupied by patients with hip fractures in the middle of the 1980's

The number of technical failures for the different methods of treatment was analyzed and it was concluded that the demand for extra hospital beds could be overcome by using the safest possible methods of treatment

MECHANICAL STRENGTH AND [illegible] OF FAILURE OF JEWETT AND McLAUGHLIN HIP IMPLANTS

J Steen Jensen
Department of Orthopaedic Sur[illegible] Hospital

Load tests of Jewett and McLa[illegible] manufactured from Cr-Co-Mo a[illegible] sented

Jewett implants had a [illegible] 870–1500 N due to bending of the [illegible] 1150–1830 N due to bending of the [illegible] junction The 125° and 135° implants [illegible] to be stronger than the 140° and 1[illegible] because of the design of the nail-plate [illegible]

In McLaughlin implants the [illegible] dependent of the nail plate angle [illegible] points were observed The two [illegible] and 750 N, respectively were due t[illegible] the nail and the curved extension of th[illegible] lowest yield point of 250 N was cau[illegible] deformation of the knobs on the dis[illegible] nail the curved plate extension as w[illegible] terposed washer were also deformed [illegible] in a looseness of about 10° at the [illegible] junction

A design change was proposed to [illegible] the implant to be used for the [illegible] unstable trochanteric fractures, w[illegible] transmit a load of about five tim[illegible] weight during level walking

DIFFERENTIAL HISTOCHEMICA[illegible] STAINING OF GLYCOSAMINOGLYCANS IN THE MATRIX OF OSTEOARTHRITIC CARTILAGE

S Bach Christensen & I Re[illegible]
Department of Orthop[illegible] Rigshospitalet, Copenhagen

The distribution of chondroitin [illegible] keratan sulphate in osteoarth[illegible] been analysed in a histochemical [illegible] Safranin O Alcian Blue-CEC and t[illegible] at different pH values. In addition t[illegible] of glycosaminoglycans, osteoarth[illegible] characterized by increased [illegible] chondroitin sulphate especially [illegible] clusters In the control cartilage th[illegible] was found in the weight-bearing [illegible] cartilage, or in cartilage with [illegible] osteoarthritis. The cartilage of [illegible] made up almost entirely of chon[illegible]

These findings are in accordanc[illegible] increase in the rate of [illegible]

EEDINGS OF
-ᵞFINNISH ORTHOPAEDIC ASSOCIATION

ki, Finland, March 10, 1979

ι A. ALHO

₋SONIC CUTTING OF BONE

H Kallioniemi A J Aho & P
mpu Lehtinen
City Hospital
ɔent of Oral Surgery Institute of
ɔ Univers ty of Turku
nent of Surgery, Turku University Central
l
ory of Electron Microscopy University of

sonic cutting of bone has been reported to some advantages (accuracy decreased ıg space smooth bone edge) over con al oscillating and rotatory cutting The of the present study was to determine the immediate effects on bone and um of an ultrasonic saw (URSK 7) d ffered from those of an oscillating saw r⁴ U S A)

esurfaces of rabbit ulnar and scapular bone eriosteum were prepared immediately after for scanning electron microscopic (SEM) stolog cal studies

as easier to control the osteotomy line by ıc cutting whereas the cutting speed of Stryker² was greater than that of the ıc saw Histologically the differences were and the amount of *thermal necrosis of the* /as equal and independent of saline cooling observations revealed that the ultrasonic t rather rough surfaces and the periosteum to become elevated Osteotomies made by illat ng saw showed some microfractures rallel grooves, but the surfaces were flatter edge of the periosteum was not affected as as it was by an ultrasonic saw

ERO-LATERAL SPINE FUSION AN ⅄SIS OF 80 CONSECUTIVE CASES

ciluoto P Salenius P Pylkkanen & P

ɔaed c Hosp tal of the Inval d Foundation
ki

During the period 1972–1976 37 women and 43 men were treated surgically Their mean age was 30 years The indications for surgery were spondylolysis and spondylolisthes s in 73 cases, and instability in seven One vertebral interval was fused in 60 cases and several fused in 20 The period spent in bed after surgery was usually 2–4 weeks (44 pat ents) A questionnaire was sent to the patients between 1 and 5 years after surgery

Pain was recorded before surgery at stress in all patients and at rest in 63 After surgery eight patients were pain free while stress pain occurred in 69 and rest pain in 35 ($P < 0\ 01$) As assessed by the patient the condition had improved in 51 cases, remained unchanged in 18 and had been impaired in 10 Bone union ensued in less than 2 months in 12 patients, in 2–4 months in 57 and within more than 4 months in 8 cases two cases failed to unite The results in the group of patients under 20 years of age were better than in the remainder ($P < 0\ 05$) Those in whom bone union took less than 4 months ach eved better results ($P < 0\ 001$) than those with a longer bone union time

EARLY RECONSTRUCTION OF THE BRACHIAL PLEXUS AFTER BIRTH INJURIES

K A Solonen S Ryoppy & T Telaranta
Orthopaedic Hospital of the Invalid Foundation
Helsinki

Two infants, 8 and 12 weeks of age had extensive lesions of the brachial plexus. The indication for surgery was based upon clinical and electromyographic findings showing cessation of recovery In the first case roots C5 C6 and C7 were reconstructed with free grafts. In the second case only root C5 could be reconstructed No motor function was lost and it is highly unlikely that function of the deltoid and biceps muscles would have recovered without reconstruction

-4⁻0 80 0₋0365–03$02.50 0

Analysis Group already existing in Odense, to survey the actual pattern of injuries

THE INTERFASCICULAR TRANSPLANTATION TECHNIQUE IN THE TREATMENT OF INJURIES OF THE MEDIAN NERVE

K Simesen, J Haase & P Bjerre
Department of Neurosurgery, Odense Hospital

Twenty-four patients were operated upon, in a 3-year period, for complete median nerve transection using the microsurgical interfascicular transplantation technique The patients were re-examined after a minimum observation time of 3 years Motor function (M 3 or higher) was achieved by 83 per cent With the exception of one patient, all achieved protective tactile sensibility The best results were obtained in distal lesions in children and youths The outcome was just as satisfactory as that attained with epineurial suture carried out under ideal conditions The method was found to be superior to epineurial end-to-end suture in cases of nerve defects longer than 2 5 cm

THE INTERFASCICULAR TRANSPLANTATION TECHNIQUE IN THE TREATMENT OF FINGER NERVE LESIONS

K Simesen & J Haase
Department of Neurosurgery, Odense Hospital

Thirty-two patients with 39 finger nerve lesions were treated by microsurgical interfascicular transplantation They were followed up after a minimum of 2 years (mean 39 months)

Protective sensibility was achieved by 90 per cent Almost normal two-point discrimination sensibility was found in children and youths The results were better than those obtained by epineurial suture carried out under ideal conditions

In two-thirds of the cases the operation was undertaken because of pain and two-thirds of these were found to have good results [illegible] examination

"HOME-MADE" SILICONE RUBBER IMPLANTS IN THE CARPUS

J Hedeboe
Department of Orthopaedic Surgery [illegible] Hospital

The history, indications and [illegible] replacement of the navicular or [illegible] carpus by silicone rubber implants are [illegible]

Eight patients operated on since 19[illegible] sented The prosthesis was cut and [illegible] Silastic block by the surgeon.

Seven patients were able to [illegible] None have been reoperated on during [illegible] tion period (mean 4 years). Complicati[illegible] wear and dislocation of the implant [illegible] neighbouring bones can occur [illegible] mercially produced prostheses, so [illegible] advantage to be able to make the [illegible] dividually

ASEPTIC PROCEDURES IN ORTHOPAEDIC SURGERY

J Krogh Christoffersen et al.
Department of Orthopaedic Surgery [illegible] Hospital

In a central operating unit [illegible] different surgical departments, special [illegible] cedures are necessary Access to the [illegible] theatre is through a specially designed [illegible] complete covering of the hair is [illegible] Operating coats are made to cover the [illegible] the trousers are tucked into special [illegible] pairs of gloves are worn

During operations where bone-cement [illegible] the doors to the operating theatre [illegible] from the inside The skin is pa[illegible] and covered with Steridrape [illegible] connected to a closed suction system [illegible] possibility of retrograde contamination [illegible] procedure 405 consecutive total hip [illegible] have been performed with one case of [illegible] tion

p scand 51, 365–367, 1980

EEDINGS OF
FINNISH ORTHOPAEDIC ASSOCIATION

i, Finland, March 10, 1979

A ALHO

SONIC CUTTING OF BONE

. H Kallioniemi, A J Aho & P npu Lehtinen
City Hospital,
ient of Oral Surgery, Institute of y, University of Turku,
ient of Surgery, Turku University Central l,
ory of Electron Microscopy, University of

sonic cutting of bone has been reported to ome advantages (accuracy, decreased g space, smooth bone edge) over con- il oscillating and rotatory cutting The of the present study was to determine the immediate effects on bone and um of an ultrasonic saw (URSK-7,) differed from those of an oscillating saw , U S A)

surfaces of rabbit ulnar and scapular bone riosteum were prepared, immediately after for scanning electron microscopic (SEM) itological studies.

is easier to control the osteotomy line by ic cutting, whereas the cutting speed of tryker[2] was greater than that of the nic saw Histologically the differences were and the amount of thermal necrosis of the as equal and independent of saline cooling observations revealed that the ultrasonic t rather rough surfaces and the periosteum to become elevated Osteotomies made by llating saw showed some microfractures rallel grooves, but the surfaces were flatter, edge of the periosteum was not affected as is it was by an ultrasonic saw

ERO-LATERAL SPINE FUSION AN YSIS OF 80 CONSECUTIVE CASES

iluoto P Salenius, P Pylkkanen & P

aedic Hospital of the Invalid Foundation ki

During the period 1972–1976, 37 women and 43 men were treated surgically Their mean age was 30 years The indications for surgery were spondylolysis and spondylolisthesis in 73 cases, and instability in seven One vertebral interval was fused in 60 cases and several fused in 20 The period spent in bed after surgery was usually 2–4 weeks (44 patients) A questionnaire was sent to the patients between 1 and 5 years after surgery

Pain was recorded before surgery at stress in all patients, and at rest in 63 After surgery eight patients were pain-free, while stress pain occurred in 69 and rest pain in 35 ($P < 0\ 01$) As assessed by the patient, the condition had improved in 51 cases, remained unchanged in 18 and had been impaired in 10 Bone union ensued in less than 2 months in 12 patients, in 2–4 months in 57, and within more than 4 months in 8 cases, two cases failed to unite The results in the group of patients under 20 years of age were better than in the remainder ($P < 0\ 05$) Those in whom bone union took less than 4 months achieved better results ($P < 0\ 001$) than those with a longer bone union time

EARLY RECONSTRUCTION OF THE BRACHIAL PLEXUS AFTER BIRTH INJURIES

K A Solonen, S Ryöppy & T Telaranta
Orthopaedic Hospital of the Invalid Foundation, Helsinki

Two infants, 8 and 12 weeks of age, had extensive lesions of the brachial plexus. The indication for surgery was based upon clinical and electromyographic findings showing cessation of recovery In the first case roots C5, C6 and C7 were reconstructed with free grafts. In the second case only root C5 could be reconstructed No motor function was lost, and it is highly unlikely that function of the deltoid and biceps muscles would have recovered without reconstruction

470 80 020365–03$02.50/0

RUPTURE OF THE DISTAL BICEPS BRACHII TENDON

M V Vastamäki & H M Brummer
Loimaa Regional Hospital, Loimaa,
Orthopaedic Hospital of the Invalid Foundation, Helsinki

Five cases of rupture of the distal biceps brachii insertion were operated on using the technique described by Thomsen in 1939 The mean age of the patients was 50 years.

In each case the trauma mechanism was a sudden extension of a previously flexed elbow with a snapping sensation or sound, soreness and weakness, proximal bulging with distal flatness of the arm, and the inability to flex the elbow or supinate the forearm completely The avulsed tendon was reinserted into its attachment at the radial tuberosity using two approaches. Three cases operated on in the early stage after injury recovered completely The other two patients, operated on 1 and 3 years after the injury, had slight weakness of elbow movement The average follow-up time was 3 years.

RECURRENT LUXATION AND OSTEOARTHRITIS OF THE MANDIBULAR CONDYLE TREATED BY CLOSED CONDYLOTOMY AND COSTOCHONDRAL GRAFT

Arvi Tasanen
Maxillofacial Unit, Helsinki University Central Hospital

A total of 586 closed condylotomies were performed for minor disorders of the temporomandibular joint, such as mild osteoarthritis, joint luxation and mandibular prognathism

Thirty-five arthroplasties were performed using a costochondral graft for the treatment of more serious joint derangements This method was used in post-traumatic joint ankylosis, severe osteoarthrosis, rheumatoid arthritis, bony ankylosis and osteomyelitis

One patient suffered from habitual luxation in one mandibular joint, and from severe arthrosis in the opposite joint, resulting in malocclusion of the teeth, facial deformity, headache and joint pain for 13 years. A closed condylotomy was performed on one joint for treatment of recurrent luxation On the opposite side a new joint was constructed using an autologous costochondral graft In the follow-up both mandibular joints functioned well, pain was relieved and the facial appearance restored to normal

THE ACUTE EFFECTS OF [illegible] ARTICULAR AGENTS ON ARTIC[illegible] CARTILAGE IN RABBITS UND[illegible] GOING STRENUOUS EXERC[illegible]

A U Arstila, S Santavirta & T [illegible]
Division of Experimental Medicine, [illegible] of Cellular Biology University of [illegible]
Division of Orthopaedic [illegible] Traumatology, Surgical Hospital, [illegible]sity Central Hospital
Department of Pathology [illegible]

The present study was designed to [illegible] acute effects of intra articular [illegible] intra-articular glycosaminoglycan [illegible] (GAGPS) injections on the cartilage [illegible] joint in healthy rabbits undergoing [illegible] exercise The controls were tre[illegible] intra muscular GAGPS or [illegible] Twenty-two rabbits were [illegible] strenuous loading of the knee [illegible] down from 1.5 m over a 10-day [illegible] animals were killed on the [illegible] cartilage of the medial femoral c[illegible] examined using light and [illegible] microscopy This preliminary [illegible] extensive morphological changes can [illegible] the articular cartilage of the rabbit [illegible] repeated jumping over a period of [illegible] days. The most marked pathological [illegible] found in the articular cartilage of [illegible] treated intra articularly with [illegible] articular betametasone and GAGPS [illegible] intra muscular GAGPS seemed [illegible] beneficial protective effect on the [illegible] experimental model Further [illegible] must be done in order to clarify the [illegible] hibiting effects of corticosteroids [illegible]

VASCULAR PEDICLE FREE BO[illegible] TRANSPLANTATION

K A Solonen T Telaranta & H[illegible]
Orthopaedic Hospital of the Inval[illegible] Helsinki

A free fibular graft with a vascul[illegible] used in three cases. In all cases the [illegible] and vein in the transplant were [illegible] to-end with appropriate vessels [illegible] bed

The distal radius of a 44-year-old [illegible] been replaced by a free non-vasc[illegible] graft 7 years earlier because of [illegible] haemangioma Fracture of the [illegible] radius resulted in non-union. We [illegible] extensive excision of the hyper[illegible]

-e defect with a vascularized free fibular

rodesis with a vascularized free fibular t was performed on a 42 year-old woman undergone three unsuccessful attempts at -is of a deformed talocrural joint A 23- woman had had three unsuccessful s aimed at achieving ankylosis of a ally dislocated hip joint An attempt was arthrodese the joint with a free zed fibular graft

itial results are promising

LENGTHENING BY THE CTION METHOD

by

University Central Hospital

eries consists of three cases with con- malformation and severe shortening of the ngenital hypoplasia, fused congenital hrosis and hemimelic epiphyseal) An epiphyseodesis of the longer y had been performed earlier in two cases ents were *11*, *13* and *14* years old at the e lengthening was performed The y was transverse in two cases and a long teotomy with a periosteal sheath in the e The Wagner apparatus was used in the In one case a severe rotation and varus y, and in another a *severe rotation defor-* re corrected simultaneously The amount hening was 3 5, 3 7 and 8 5 cm and the length discrepancy 1 5, 1 5 and 0 cm, ely Bone transplantation and plate were performed in the first two cases after the lengthening was completed The oblique osteotomy fused spontaneously The Achilles tendon was lengthened in all cases There were no infections no cases with delayed union, nerve or vascular damage The time from the beginning of the lengthening to full weight-bearing was 4–6 months

It is concluded that the method is useful in equalizing severe leg length discrepancy and can be used to complement epiphyseodesis. It allows simultaneous correction of axial and rotational deformities Various associated problems must be coped with depending on the other pathological features of the short extremity

USE OF 70 MM FLUOROGRAPHY IN DIAGNOSING ORTHOPAEDIC PROBLEMS

U Lahdenranta & H Linden

Department of Orthopaedics and Traumatology and Department of Radiology of the Surgical Hospital, Helsinki University Central Hospital

In three cases a dynamic illustration of pathologic movements documenting the various phases, was obtained by means of a 70 mm spot film series. *In the first case the stages involved in* the subluxation of the shoulder joint were specified In the second case, the movement of a pseudarthrosis close to the elbow joint was visualized, and at the same time the movement of the elbow joint was documented both pre-operatively and postoperatively after union of the pseudarthrosis In the third case, the minimal movement arising from retarded ossification of the proximal part of the tibia, close to an osteo-arthrotic and unstable knee was traced with the aid of a spot-film series.

p scand 51, 369–373, 1980

·CEEDINGS OF NORWEGIAN ORTHOPAEDIC ASSOCIATION

ARNT JAKOBSEN

January 27th, 1979

·L SYNOVECTOMY OF THE WRIST ·CUMATOID ARTHRITIS

Pahle
·nitetsforening Rheumatism Hospital, Oslo

·e period 1967–1978, 776 synovectomies ·rformed for rheumatoid arthritis of the ·Of these, only 17 later on required an ·esis.

·operation included a full tenosynovectomy ·xtensor tendons, excision of the ulnar head · triangular disc, as well as a thorough in·al and radiocarpal arthrosynovectomy The ·o-pisiform joint is opened on the ulnar ·the extensor carpi ulnaris tendon is in a ·ndition, this important muscle function is ·nented by transfer of the extensor radialis ·in order to prevent radial deviation of the ·Division of the intercarpal ligaments gives ·nt access to the volar erosions of the carpal

·CATION OF THE CERVICAL ·IN RHEUMATOID ARTHRITIS

·eigland
·anitetsforening Rheumatism Hospital, Oslo

·the period 1975–1978, 35 patients with ·l forward dislocation of the cervical spine ·urological symptoms were operated on *ad* ·Brattstrom/Granholm If the deviation ·ss than 10 mm and myelopathy was not ·t, the patients were treated conservatively ·supporting collar

·patient with downward dislocation ·ent an operation for transoral removal of ·ontoid process.

·patient with backward dislocation and ·plegia was treated with operative ·tioning and fixation with bone cement

·subaxial dislocations with major deviations ·tempt at repositioning is made, and when ·sful, a frontal fixation is performed ·ding to a modified Cloward method If repositioning is not achieved, and the patient shows signs of myelopathy, laminectomy and lateral fixation with bone cement are carried out Four such operations have been performed

RESECTION ARTHROPLASTY OF THE FOREFOOT IN RHEUMATOID ARTHRITIS

Tore Ottesen
Oslo Sanitetsforening Rheumatism Hospital, Oslo

A detailed account of a modified Clayton technique was presented During the past year the 1st metatarsal-phalangeal joint has been replaced by a Swanson silastic prosthesis with promising results

PATIENT INFORMATION – LOW BACK PAIN

Tore K Kvien
Hospital of Rheumatology, Kristiansand

Is there possibly a difference in the information given to patients with low back pain by group and traditional physiotherapy?

A total of 220 patients were instructed in self training, mainly in the form of isometric exercises and correct ergodynamic use of the back. Instruction was given to small groups of patients with the aid of 12 dias/tape lessons over a period of 4 weeks A physiotherapist demonstrated the exercises and answered questions.

Another 190 patients were treated traditionally (controls)

One year later the patients were asked to fill in a questionnaire The group-instructed patients had received significantly less physiotherapy than the patients treated traditionally during that year Ninety-five per cent of the group treated patients, and about 50 per cent of the control patients, considered that the information was communicated satisfactorily

·470 80 020369–05$02.50 0

SEROLOGY IN RHEUMATOID ARTHRITIS

Ove J Mellbye
Institute of Immunology & Rheumatology, The National Hospital, Oslo

A short review of serology in rheumatoid arthritis was presented It was recommended that the latex test be used initially, and, if this is positive, then a Waaler-Rose test can be performed The anti-nuclear immunofluorescence test is recommended for initial testing of anti-nuclear antibodies.

Oslo, March 10th, 1979

TUMOURS OF THE TIBIA

Einar Wollebaek
Central Hospital in Vestfold, Tønsberg

Two patients with tumours with an almost identical location in the medial condyle of the tibia were presented The diameter of the tumours was 5 cm, and the findings at radiological examination suggested both to be malignant

One case turned out to be a metastasis from a carcinoma of the kidney, and the primary tumour was not found until 5 years later In the second case the tumour was benign It contained mostly cholesterol although the patient did not present any other signs of hypercholesterolaemia

Trondheim, May 25th–26th, 1979

SICK LEAVE AMONG SOCCER PLAYERS AND IN THE POPULATION

Asbjorn Roaas & Gunnar Andersson
Martina Hansens Hospital, Sandvika and Sahlgrenska Sjukhuset, Goteborg

One hundred previously active or still active soccer players, aged 30–40 years, were compared with 108 age-matched controls selected to represent the male population of the city of Goteborg Sick listing was compared between the two groups based on the sick leave register

There was no difference in the total number of days on sick leave Infectious diseases were responsible for about 55 per cent of the total number of sick days in both groups Among the soccer players 77 per cent had been on sick leave because of injuries to the lower extremities and 73 per cent because of other injuries In the control group these figures were 48 per cent and 49 per cent, respectively Other diseases of various types were more frequent among the controls

FRACTURE OF THE INTERCONDYL... EMINENCE OF THE TIBIA

August Bakke, Anders Molt... & ...
Regional Hospital Bergen

Fracture of the intercondylar eminence ... tibia is a rather rare fracture In the per... to 1978 14 patients with this fracture ... Five of them have been operated ... treated conservatively

At the follow up examination the r... of the patients was excellent Of the ... five had a good result and in one the ... fair

It is concluded that childhood fract... I and II (according to Meyers & ...) should be immobilized in a cast for 5 ... and that type III requires open reduct... mobilization In older patients type II ... be operatively treated

ARTHROSCOPY OF THE KNEE JOI... A COMPARISON OF THE FINDING... ARTHROSCOPY ARTHROGRAPHY AND ARTHROTOMY

Pål Benum
Regional Hospital Trondheim

The findings of arthroscopy and ... were compared in 60 "chronic" ... Arthroscopy failed to diagnose 2 ... meniscus lesions found at ... Furthermore, 1 out of 3 retained poster... were overlooked One false positive diag... meniscus lesion was made at arthrosc... arthroscopy failed to diagnose 1 out of ... of the anterior cruciate ligament and ... rupture of the posterior cruciate ligament ... arthrotomy Cartilage lesions were found ... knees only in 2 knees were the ... recognized at arthroscopy

Compared with arthrography which ... performed in 36 knees, arthroscopy was ... be far superior as regards the diag... meniscus lesions.

These findings, and a comparison ... clinical diagnosis, led to the conclu... arthroscopy is very valuable in the diag... chronic knee problems.

SOFT TISSUE TUMOURS IN TH... POPLITEAL FOSSA

Peter A Groh
Regional Hospital, Trondheim

In a 4-year period 23 cysts and ... neoplasms were seen in the poplite...

in adults mainly symptomatically in con- ...ith knee joint diseases In children it is ...ded that the operation be delayed ...ysts disappear spontaneously in 60 per ...ses Neoplasms in the popliteal fossa are ...cult to classify

...ARISON OF INTERNAL ...N AND PROSTHETIC ...EMENT FOR FEMORAL ...RACTURES

...esen & Olav Nesse
Hospital, Trondheim

...ospective study of 216 patients with intracapsular femoral neck fractures is ... 109 patients were treated by primary ...ty using a Christiansen endoprosthesis, ... patients by internal fixation with a ...lin nail-plate The rate of complications ...rations, and the mortality rate, were no ... the prosthesis group compared with the ...bove 70 years of age ...

...al fixation group It is concluded that in ...bove 70 years a primary prosthesis is to ...nended

...RE OF THE NECK OF THE ...

...reliminary results of a prospective ...d study concerning subcapital fractures ...k of the femur are reported

...ve patients were treated according to ... modification of compression screw os...sis, and compared with 47 patients ...ith McLaughlin's nail-plate Immediate ...tive weight-bearing was allowed The ...n time was 6 months

...lisplaced fractures no difference was ...ween the two methods (all healed) In ...fractures, however, 30 out of 32 treated ...mpression screw osteosynthesis were ...er 6 months, compared with only 16 out ...ed with the nail plate

...oncluded that in displaced subcapital ... of the neck of the femur the ...on screw method used gives faster ...an the McLaughlin nail plate method

COMPRESSION HIP SCREW IN ...

The preliminary report involves 40 fractures in 25 women and 14 men with an average age 61 9 years The Garden grades were grade II – 3 hips, grade III – 20 hips, and grade IV – 17 hips. The fractures were fixed using a sliding compression screw plate

At the follow-up (average 1 year) three cases showed avascular necrosis of varying degree and two had non-union In one patient total hip replacement was performed after a technical failure and in another a Girdlestone operation was necessary because of infection

Sliding of the screw varied from 10 to 14 mm in six cases, from 4 to 9 mm in five cases and from 0 to 3 mm in the remainder The preliminary results compare favourably with an earlier series where two or three separate screws were used The results will be compared with preliminary hemiprosthesis replacement in a randomized series

HALLUX RIGIDUS TREATED WITH SWANSON'S SILASTIC HEMI-JOINT PROSTHESIS

Anders Molster, Ole D Lunde & Milan Rait
Coastal Hospital in Hagevik, Hagavik

T... 25 ... yea... from 1972 to 1978, substituting the proximal part of the phalanx with a silastic prosthesis.

Twenty patients (21 operated joints) appeared for re-examination, the rest answered a questionnaire The mean observation time was 47 months One prosthesis was removed because of deep infection and one because of trauma Patients' opinion Excellent in 16, good in 6, fair in 2 and poor in one Objective assessment Excellent in 8 good in 9 (one with prosthesis removed) fair in 3 and poor in one (with prosthesis removed)

Most patients had limitation of mobility, but normal walking ability Strength was well preserved, and only one patient complained of marked pain Radiologically there were some signs of bone reaction to the prosthesis

[illegible]

Anton Hole, Terje Terjesen & Harald Brevik
Regional Hospital, Trondheim

A prospective, randomized study of 60 elderly patients undergoing total hip arthroplasty was carried out. Modified neurolept anaesthesia with manual ventilation was compared with single dose bupivacaine 0.75 per cent epidural analgesia. Blood loss peroperatively was less in the epidural group. PaO_2 was reduced in the general anaesthesia group on the 1st and 3rd postoperative days ($P<0.01$) compared both with preoperative values and with the epidural group. No patients in the epidural group, but seven patients in the general anaesthesia group, developed mental changes postoperatively ($P<0.01$). One patient in the general anaesthesia group died from acute myocardial infarction. The patients were equally satisfied with both types of anaesthesia.

HALO-VEST IMMOBILIZATION OF UNSTABLE INJURIES OF THE CERVICAL SPINE

Tor Steinar Raugstad
Regional Hospital, Bergen

Ordinary skull traction usually prevents dislocation of a cervical spine injury, but the patient is confined to bed and the method does not effectively restrict movements of the head and neck.

The halo-vest equipment gives a better stability than any other orthoses made for external immobilization of the cervical spine. A metal ring is fixed to the skull by special screws or pins, and a vest of plastic material that fits over the shoulders and the chest is connected by adjustable rods. This allows the patient to be ambulatory, and a long period in bed can be avoided.

Seven patients with unstable cervical injuries have been treated by this method with good results.

ACCURACY IN SKELETAL AGE ASSESSMENT

Lars B. Skogland & Morten Eek
Sophies Minde Orthopaedic Hospital, Oslo

The skeletal age of 30 girls, 7 to 17 years old, was estimated four times each by two observers, using the Greulich and Pyle method. About 2 weeks passed between each reading. The value of the first reading of both [illegible] called the "true skeletal age".

Checking the reliability (intraobserver) [illegible] method, it was found that [illegible] the readings were distributed within [illegible] the "true skeletal age". If ± 1/2 [illegible] chosen as an acceptable margin, [illegible] readings would have been included.

The objectivity (interobserver) of [illegible] was also estimated. Whereas the [illegible] the three control readings of observer [illegible] distributed above the "true skeletal age" [illegible] responding readings of observer no. 1 [illegible] This was the case in 29 out of 30 [illegible] and in one case the difference between [illegible] was as much as 1½ years.

It is probably advisable that the [illegible] estimated by at least two observers [illegible] a high degree of accuracy is required.

FRACTURE OF THE NECK OF THE TALUS

Rolf Hagen
Martina Hansens Hospital, Sandvika

Talar fractures are rare and [illegible] motor vehicle and athletic accidents, [illegible] heights and in injuries caused by [illegible] The most common type is fracture of the neck which constitutes 50 per cent. The [illegible] talar body dislocation implies [illegible] or three main sources of the blood [illegible]

Two cases with closed fractures [illegible] Hawkins group III are reported. [illegible] primary pantalar arthrodesis was performed [illegible] 58 year-old man, while an open reduction [illegible] internal fixation was done in a [illegible] jumper within 2½ hours of the accident.

PERIPHERAL NERVE INJURIES FOLLOWING TOTAL HIP REPLACEMENT

Ludvig Fjeld Solheim & Rolf Hagen
Martina Hansens Hospital, Sandvika

Six nerve complications after [illegible] replacements by the posterior [illegible] reported.

Peroperatively the sciatic nerve was [illegible] directly in one patient, and in one [illegible] femoral and two patients with [illegible] the nerves were probably stretched [illegible] retractors. Postoperatively one patient [illegible] haematoma in the buttock with [illegible]

, and one patient an iliacus haematoma
oral nerve paralysis
tients were treated conservatively, in one
nd two femoral nerve lesions the patients
normal function, while in three sciatic
ions there were residual neural deficits

ATIONAL OSTEOTOMY IN THE MENT OF INCREASED AL NECK ANTEVERSION PECTIVE STUDY

tenningsen
l Hospital, Trondheim

ence of opinion prevails about the in-
s for operative treatment of increased
neck anteversion, and the optimal age for
operation. Furthermore, it is questionable
or not the anteversion will recur after the
n

nvestigate some of these problems a pro-
study has been started in children who
signs of increased anteversion, measuring
version angle prior to, and at intervals after,
ochanteric derotation osteotomy using the
on method

material consists of 60 patients, mean age
A quarter of the patients were known to have hip dysplasia, and three-quarters had isolated increased anteversion At follow-up 4 and 12 months postoperatively there seems to be no recurrence of the anteversion

The study will be continued

STABILIZATION OF THE DISTAL ULNA FOLLOWING RESECTION

Norvald Langeland
Sophies Minde Orthopaedic Hospital, Oslo

Following resection of the distal ulna according to Darrach the stump may sometimes become so mobile that it causes pain and damage in the forearm A new method for stabilizing this hypermobile distal ulnar stump is described

The extensor indices proprius tendon is divided at the second metacarpo-phalangeal joint The tendon is withdrawn to above the wrist, and looped around the radius from the dorsal to the volar side, hereupon it is taken dorsal to and around the ulna to the volar side of both ulna and radius Finally the tendon is looped around the radius to its dorsal side where it is sutured to itself

This "dynamic" method has been found to stabilize the ulna effectively

hop scand. 51, 375–385, 1980

:EDINGS OF
;WEDISH ORTHOPAEDIC ASSOCIATION

June 6–10, 1979

PETER HERBERTS

IENT OF DIAPHYSEAL RES OF THE UPPER EXTREMITY UNCTIONAL BRACES

ion, J Enskog & J Karlsson
nt of Orthopaedic Surgery, Umeå

n closed diaphyseal fractures of the were treated with a tight orthoplastic r a very short acute stage The median 53 years (range 16–82), the fracture site various levels of the shaft, and often l The median time required for healing no pain, callus) was 10 weeks (range, fter an observation time of 11 months -23) 11 patients were symptom-free sub- and at examination, while 2 had minor s

n *ulnar* and 2 *radial* diaphyseal were treated, after the swelling had d, with a tightly fitting brace This from the wrist to near the elbow ige of the patients was 37 years (range, The time required for healing was 11 ange, 5–27), and 11 out of 15 patients y from work for a median period of 12 range, 0–28). The results were good n-free) in 13 and acceptable in 2 cases.

MENT OF DIAPHYSEAL JRES OF THE LOWER EXTREMITY UNCTIONAL BRACES

tion, J Enskog & J Karlsson
ent of Orthopaedic Surgery, Umeå

an initial stage in traction (median 6 inge, 2–10), 21 transverse, longitudinal or id fractures of the distal two-thirds of the ere treated in a functional cast brace age was 40 years (range, 16–78) Three were open. The median total hospitaliza- ie was 8 weeks (range 4–15) and the ime 16 weeks (range, 10–26) The results were good in 15 cases, acceptable in 3 and poor in 2 cases No pseudoarthrosis occurred

Sixty-two fractures of the *tibial* shaft were treated in a functional brace after an initial period in a long leg cast Median age was 36 years (range 16–78) and 12 fractures were open Only six were the result of skiing injuries. Six of the fractures were fixed with screws for only 4–8 weeks. Thirty-four cases braced within 6 weeks [illegible] selected material was 18 weeks (range, 6–88) Results Good 47, acceptable 9 and poor 5 cases. In 4 of these the reason was delayed union and after bone grafting they all healed with a final good result

SEMI-RIGID FIXATION OF DISTAL FEMORAL FRACTURES BY A NEW DEVICE

L Kolmert & B M Persson
Department of Orthopaedic Surgery, Lund University Hospital, Lund

Distal femoral fractures, expecially supra-condylar and bicondylar, are often difficult to treat An 8-year analysis in Malmo and Lund showed that in one-third of 137 fractures the result was fair or poor Forty-six of the fractures were operatively treated and there was no difference between these and the conservatively treated ones.

A prospective series was started in 1978 A semi-rigid type of fixation was devised, composed of Ender nails of various sizes, cancellous screws and a metal piece to connect the Ender nail with the screws. An anterior plaster was used postoperatively for 2 weeks and then most of the patients used a cast-brace The semi-rigid fixation can maintain a good position despite bone fragility and has made it possible to mobilize the patients earlier

'0 80 020375–11$02 50/0

FEMORAL NECK FRACTURE AND OCCULT EPISODIC CARDIAC ARRHYTHMIA

N-J Abdon & B Nilsson
Departments of Medicine (Division of Cardiology) and Orthopedic Surgery, Malmö

Sixty consecutive patients admitted to hospital for fracture of the upper end of the femur were examined by continuous ECG monitoring for 24 hours More than one-third of the patients had occult, previously undiscovered, episodes of arrhythmia, severe enough to cause cerebral symptoms

This prevalence is much higher than in an age-matched sample of the population at risk

ACUTE TOTAL HIP ARTHROPLASTY FOR PROXIMAL FEMORAL FRACTURE IN PATIENTS WITH OSTEOARTHRITIS OF THE HIPS

B M Persson, M Grubor & A Rydholm
Department of Orthopaedic Surgery, Lund

Coxarthrosis and hip fracture are both common in the elderly but the combination is seldom seen In 256 cases of cervical hip fracture, Ståhl (1957) did not find any case of simultaneous coxarthrosis but in 50 trochanteric fractures 20 had some degree of coxarthrosis From medline we found one case reported by Ganz 1978 of total hip operation for fracture and arthrosis In Lund, 1969 to 1979, we have found the following six cases

Case	Age	Sex	Hip disease	Fracture	Operation
1	73	M	Bechterew	Cervical	McKee-Farrar
2	56	M	CDH+OA	Subtroch	Charnley Long
3	84	F	Bil OA	Pertroch	Brunswik
4	70	F	Bil OA	Pertroch	Lubinus
5	80	F	OA+Myeloma	Subtroch	Charnley Long
6	76	M	Bil OA	Pertroch	Lubinus

In three cases the proximal fragment was resected, in three cases it was preserved Early weight-bearing was possible and all operations were successful Acute total hip is indicated in severe coxarthrosis also after fracture

POSTOPERATIVE WOUND INFECTION IN CLEAN ORTHOPAEDIC OPERATIONS

E Borgstrom, L Backman & V Surin
Department of Orthopaedic Surgery, Borås

A prospective study of 2371 clean orthopaedic operations revealed 3 7 per cent postoperative wound infections. Fourteen factors [illegible] relate to the aetiology of postoperative [illegible] infection were subjected to a computer [illegible] Multiple linear-regression analysis [illegible] out Only three factors were found to [illegible] significant in determining the [illegible] wound sepsis. These were the age of the [illegible] reoperation and the use of alloplastic [illegible]

The diagnostic criteria and [illegible] registering postoperative wound [illegible] discussed

EFFECTS OF PROTECTIVE CLOTHING ON AIRBORNE CONTAMINATION WITH BACTERIA AND PARTICLES IN A LAMINAR CROSS-FLOW OPERATING ROOM

B Friberg, S Friberg [illegible] *Burman*
Department of Orthopaedic Surgery [illegible] Umeå, Umeå

The effect of different types of [illegible] airborne transmission of bacteria and [illegible] was studied during sham operations [illegible] cross-flow operating unit

No differences in bacterial or [illegible] were found comparing a helmet [illegible] and nonsterile head-clothing [illegible] posable hoods of the square type [illegible] triple laminar face masks. In both [illegible] number of bacteria and particles were [illegible] Experiments without any covering of [illegible] resulted in a major increase in bacteria [illegible] without a corresponding increase in the [illegible] particles

Disposable operating gowns of [illegible] woven rayon yielded similar numbers of [illegible] and particles. Conventional non-disposable [illegible] gowns increased both the number of [illegible] the number of particles. The "wound" [illegible] tion recorded with cotton gowns was [illegible] about 75 per cent with the use of [illegible] disposable gowns

POSTOPERATIVE INFECTION RATE [illegible] EFFECT OF CLEAN AIR CROSS-FLOW UNIT AND RIGID HYGIENE RO[illegible]

H Dahlström, S Friberg & G [illegible]
Department of Orthopaedic Surgery [illegible] Umeå Umeå

During the period 1970 to 19[illegible] hips were replaced by a total [illegible]

…ons were performed in a conventional …ng theatre using cotton gowns. During the …1977–1978, 176 prosthetic replacements of … were performed in a clean air unit with …ital air flow The surgical team used dis… gowns of non-woven rayon, squire type …and triple laminar face masks The clean air …duced the superficial infection rate from 6 9 per cent ($P < 0\,02$) and the deep infections … 3 to 0 per cent ($P < 0\,02$)
…nt publications have shown an infection … 5–15 per cent after surgery for cervical and …hanteric femoral fractures To evaluate the …of the rigid hygiene routines at the clinic … cervical, 55 trochanteric) femoral fractures …studied prospectively and retrospectively …perations were performed in a conventional …ng theatre using cotton gowns The …on rate was 0 9 per cent

…ROLE OF HAMSTRING TENDON …ASE IN THE MANAGEMENT …NEE FLEXION DEFORMITY …EUROLOGICAL DISEASE

…ujic, T Aparisi & P Bylund
…tment of Orthopaedic Surgery, Karolinska …al, Stockholm

…ing the years 1967–1978, 31 patients with …al palsy or myelomeningocele were operated … for knee flexion deformity Twenty-eight …ts (51 knees) were followed up Mean age …11 years, average follow-up period 5 years. …tion for operation was a true hamstring con…re causing a knee flexion deformity In 7 … Eggers' original technique was used In the … it was modified individually No …vascular complications or deep infections …red Of 13 non functional walkers, 10 were …to walk after operation Of 9 independent …r walkers 8 became community walkers No …ng capacity was lost because of the opera… The contracture decreased in all operated … No significant differences could be …ered between patients with cerebral palsy …myelomeningocele All but 2 of the 28 patients … subjectively improved No recurrence of …mity was observed despite an average follow… 5 years. A weakening of the flexion power of …nee was observed in most cases, but did not …ir function The results suggest that distal …tring tendon release can be recommended in …management of true knee flexion deformity in …ral palsy and in myelomeningocele

GROWTH DISTURBANCE AFTER ANKLE FRACTURES IN CHILDREN

J Kärrholm, L I Hansson & G Selvik
Department of Orthopaedic Surgery, University Hospital, Lund

In a prospective study of ankle fractures in children, the effects on longitudinal growth were registered by insertion of ½ mm sized tantalum balls. The patients were followed up with X ray stereophotogrammetry at regular intervals Measurements on 20 patients have been made Eleven of the patients had a growth retardation This is a higher frequency than earlier reported and the Salter Harris classification seemed to be of lesser value in predicting the prognosis The growth disturbance could now be registered some months after the injury and with great accuracy Growth disturbance after ankle fractures results in clinical problems in a few cases, and early diagnosis is important for future therapy

GROWTH ARREST BY STAPLING AND EPIPHYSIODESIS

B Bylander, N Egund, L I Hansson & G Selvik
University of Lund, Lund

The orthopaedic surgeon often encounters the problem of leg length discrepancy We have found operative growth arrest, temporary or permanent more valuable than leg shortening, lengthening or growth stimulation Preoperative planning is of critical importance If this is not properly carried out, then even with excellent surgical technique and a careful follow-up the end result can be disappointing In order to study the effect of growth arrest after stapling and epiphysiodesis and to evaluate the early signs of problems, a rontgen stereophotogrammetric analysis was performed Thirty stapling operations according to Blount and seven Phemister operations were studied

Conclusion Rontgen stereophotogrammetry is suitable for checking the efficiency of staples and growth arrest after Phemister epiphysiodesis.

Stapling during the latter part of the growth period results in immediate and complete growth [illegible]

epiphysis. Removal of staples results in normal growth in intact growth plates and normal closure Phemister epiphysiodesis results in immediate and complete growth arrest

GROWTH DISTURBANCE AFTER INJURY TO GROWTH PLATES OF THE DISTAL FEMUR AND PROXIMAL TIBIA STUDIED BY ROENTGEN STEREOPHOTOGRAMMETRY

L I. Hansson, S Aronsson, B Bylander & G Selvik
University of Lund, Lund

There has been a great deal of interest in the classification of physial injuries in order to predict growth disturbances A roentgen stereophotogrammetric analysis of 5 cases was used to study the growth disturbance after injuries to the growth plates of the distal femur (Salter-

distal femur In the type IV injury to the proximal tibia there was asymmetrical growth

Conclusion

1 The roentgen stereophotogrammetric method proved useful in determining the growth rate after physial injury

2. The Salter-Harris classification is of minor value in predicting growth disturbance

3 Physial injuries must be treated with meticulous care to secure intact growth and congruity of the joint

4 The leg length discrepancy or angular deformity can be determined, facilitating pre-operative planning

EARLY ASSESSMENT OF PROGNOSIS IN PERTHES' DISEASE

L G Danielsson, H Pettersson & G Sundén
Departments of Orthopaedic Surgery, Allmänna Hospital, Malmo and Lund Hospital, Lund

The principles of treatment in Perthes' disease are rather confusing This is caused among other things by the difficulties in making an early

to early risk evaluation An index that takes account of changes in the proximal femur as well as in the pelvis has been devised This index also seems to correlate well with the radiological end-result in the early phase of the disease

HETEROLOGOUS BONE GRAFT [illegible] TRANSPLANT IN INNOMINATE OSTEOTOMY FOR HIP DYSPLASIA

R Lemperg
Department of Orthopaedic Surgery [illegible]
Umeå, Umeå

A heterologous bone graft, Kiel bone [illegible] used in 10 cases of innominate osteotomy [illegible] pelvis for treatment of hip dysplasia [illegible] two main advantages with this graft [illegible] need to take a crista bone graft which [illegible] followed by disturbed growth of the [illegible] damage to the apophysis. The second [illegible] that large grafts can be obtained which [illegible] in re-osteotomies must be used in order [illegible] correction Hitherto in all cases the graft [illegible] incorporated without any loss of cor[illegible] collapse of the transplant.

EXPERIENCES WITH THE SHARRARD POSTERIOR ILIOPSOAS TRANSFER IN MYELOMENINGOCELE

P Bylund, T Aparisi & H Grix [illegible]
Department of Orthopaedic Surgery [illegible]
Hospital, Stockholm

A follow-up study was made of the posterior iliopsoas transfer in [illegible] patients with hip instability [illegible] verified luxation or subluxation [illegible] comprised 19 hips in 12 patients [illegible] operation 2.5 years, range 14 [illegible] postoperative follow-up ranged from [illegible] 10 years, mean 4 4 years. The technique [illegible] that described by Sharrard. The results [illegible] those reported by other authors [illegible] result was defined as a stable hip [illegible] reduced position Nine of the 19 hips [illegible] reduced and 10 dislocated post[illegible] intertrochanteric femoral fracture, 3 [illegible] fractures and 2 cases of avascular [illegible] femoral head were observed postoperatively [illegible] position of the hip prior to surgery [illegible] portance Of 7 totally dislocated hips [illegible] retained its position in the [illegible] postoperatively Of 12 subluxated hips [illegible] stable at follow-up This investigation [illegible] that posterior iliopsoas transfer is not [illegible] the hip is totally dislocated, but can be [illegible] children with subluxated hips.

ICENTRE PROSPECTIVE OF SWEDISH KNEE)PLASTIES

, *K Knutson & A Lnstrand*
nt of Orthopedic Surgery, Lund

ober 1975, SOF started the "Swedish ırthroplasty Project" involving 38 ic departments In April 1979, 3,070 sties were registered and 1,573 of these to a 1 year follow-up Results at follow-ie main diagnoses, RA and OA

At present semi-constrained prostheses are more often used than constrained Total surface replacement in RA is more often done with bicondylar than unicondylar prostheses resulting in less subluxation and infection, the same rate of loosening but in more patellar problems In OA only 1 per cent of the demiplasties have needed secondary arthroplasty of the non-operated compartment and these have given the best overall results In RA, demiplasties have led to 7 per cent reoperations because of further arthritic destruction

	Rheumatoid arthritis (n – 734)					*Osteoarthrosis* (n – 722)				
ıs	No	Complic	Total/Infect./Loose			No	Complic	Total/Infect /Loose		
ned	164		12%	5%	3%	71		24%	9%	11%
ar	237		10%	2%	3%	129		16%	4%	6%
total	274		10%	3%	3%	73		10%	2%	2%
demı	59		17%	–	2%	449		7%	1%	2%

DARY OPERATIONS AFTER JOINT ARTHROPLASTY

len & Å Ahlberg
ıent of Orthopaedic Surgery, Malmo Hospital, Malmö

al of 267 knee joint arthroplasties were ed in 1972 1977 and 31 required ry operations, which means a frequency of cent In the rheumatoid group the y was 6 per cent, in osteoarthritis 18 per osening was the reason for the reoperation ases and infection in 7 Hinge prostheses 1 reoperation more often than the other Geomedic, S t George Schlittenprothese). ight and earlier operation in the same knee d the risk of complications leading to tion The type of reoperation was exchange prosthesis in 17, arthrodesis in 3, irrigation in 3, femur amputation in one The ng 7 were various smaller interventions sult of the reoperations was classified as ı 13 cases, fair in 12 and poor in 6

NIQUE FOR UNICONDYLAR ARTHROPLASTY

dstrand & G Thor-Jónsson
nent of Orthopedics, Lund

positioning of the tibial and the femoral nents is accomplished by using a special instrument In the proximal tibia we n an L-resection With the aid of the guide nent this is done horizontally in both the transversal and sagittal planes. The tibial component covers the strong cortical bone and its stability is enhanced by cement-pegs down into cortical bone The femoral component is also positioned with the guide instrument, this ensures correct placement and good congruity between the two components In a fixed deformity it is important to transpose the collateral ligament in order to obtain a correct valgus position of the leg The collateral ligament is anchored with a special ligament staple The guide instrument and the ligament staple were demonstrated

TWO UNUSUAL AND SEVERE COMPLICATIONS IN KNEE ARTHROPLASTY

A Wigren, K Kolstad & B Sahlstedt
University Hospital Uppsala

Two knee arthroplasties with unexpected complications are described

The first case was a combination of sciatic nerve injury and a compartmental syndrome of the lower leg The patient had severe rheumatic [illegible] of her knees This deformity was [illegible] by tension [illegible] shown and the ischaemia initiating the compartmental syndrome was caused by arterial spasm due to tension when the flexion deformity was corrected

The second case was a fracture of the proximal tibia close to a bone-cemented giant rheumatic

granuloma upon which the Marmor knee prosthesis had been placed One year after the primary operation the cortical and cancellous bone close to the cement was necrotic There was no infection and bone necrosis was the cause of the fracture It is suggested that special types of prostheses, custom-made if necessary, should be used in cases where bone cement otherwise would be used in large amounts to fill a bone defect

MARMOR KNEE ARTHROPLASTY STUDIED BY ISOMETRIC AND ISOKINETIC MUSCLE STRENGTH MEASUREMENTS

A Wigren, K Kolstad, B Nordgren & L-O Nordesjo
University Hospital, Uppsala

A prospective study was made of the knee muscle strength of 40 knee joints fitted with a Marmor knee arthroplasty Twenty-five of the knees were in R A patients, 15 in cases with O A Isometric strength measurements of knee extension and flexion were performed preoperatively and at 3, 12 and 24 months postoperatively The preoperative isometric strength in R A was only 10–25 per cent of that in a normal material The corresponding values for O A were 30–50 per cent The maximal isometric muscle strength in R A was significantly increased both for flexion and extension 1 and 2 years postoperatively and for flexion at 3 months postoperatively No significant increase was seen in O A The increase in knee flexion strength was earlier and more pronounced than that of knee extension in both groups. This indicates the necessity of extension training postoperatively to prevent flexion deformity Further information for analysis of knee pain and for interpretation of functional observations after knee surgery was given by the use of isokinetic muscle strength studies with the Cybex II apparatus Knee extension strength at high speed increased significantly explaining the normalized gait after arthroplasty even if isometric values were unchanged

ANALGESIC DISC PUNCTURE DIAGNOSTIC DISC PUNCTURE DETERMINING THE LEVEL FOR SPINAL FUSION IN PATIENTS WITH CHRONIC LOW-BACK PAIN

H Kofoed & L Hult
Department of Orthopaedic Surgery, Södersjukhuset, Stockholm

Since August 1977 twelve patients with chronic low-back pain and a normal myelogram have been evaluated with analgesic lumbar [illegible] [illegible]

particular level An average of [illegible] tested in each patient.

Seven patients have been [illegible] obtained good results and have [illegible] former occupation. Though the [illegible] with this new method so far is [illegible] are promising and the method [illegible] a larger series.

WORKING IN LOGGING [illegible]

C Hammar
Skogshälsan, Boden

Eighteen per cent of logging [illegible] complain of cervical pain which [illegible] with other forestry employees [illegible] significant Earlier unrestricted [illegible] lumbermen may have contributed [illegible] rate The rate of cervical trouble [illegible] the fifties and sixties is still too [illegible] conclusions. Experience gained [illegible] occupational health service shows [illegible] drivers complain to a greater [illegible] the neck, shoulders and arms. The [illegible] and compartment are not yet [illegible] to minimize health hazards. This [illegible] matter considering that plans are [illegible] expand machinery resources and [illegible] complicated and exacting devices. It [illegible] importance in this context to consider [illegible] ergonomic demands to reduce [illegible] than to be only concerned with [illegible] profitability of the machines.

EXPERIENCES OF AUTO-TRACT[illegible] ON SCIATICA

S Ingeborg
Department of Orthopaedic Surg[illegible]

Forty-six patients with clinical [illegible] vertebral disc herniation were [illegible] from our clinic's waiting list. The [illegible] 40 years. The history of dorsal [illegible] 1–20 years and all of them had [illegible] viously by various methods of [illegible] treatment without success. [illegible] performed in 9 cases and 7 of [illegible] herniation of the lumbar disc [illegible] manifestations were found in [illegible] patients were treated with [illegible] manoeuvre to reduce the hernia [illegible] repeated depending upon the [illegible]

the symptoms, and the mean was 4 5
n each patient
ts were classified as *very good* in 22

urological symptoms occurred in 12

ury, 43 out of 46 patients with chronic
viously treated without satisfactory
e treated successfully with Auto-

IC NEEDLE COPY OF THE KNEE CAL ANAESTHESIA

Buring, T Wikström & J Ekstrand
of Orthopaedic Surgery, Sundsvall

October 1977 policlinic needle
s have been performed with local
Results of the first 200 are reported
amination in the case of suspected
juries was verified in 50–60 per cent
scopy The number of arthrographies
radically reduced during this period
cy of the arthroscopies was around 90
here have not been any infections or
ications We believe the method is safe
high accuracy As this is an outpatient
done in a consultation room the
the regular operation ward is reduced

NE BLUE IN COPIC DIAGNOSIS LAGE LESIONS

tist, S Friberg & U Sundkvist
of Orthopaedic Surgery, University of
d

methods to increase the diagnostic

rtilage while the staining of normal
was minimal. The methylene blue
was compared with corresponding
and scanning electron microscopic
s The degree of staining seemed to be
he depth of the cartilage lesion More
lesions of the cartilage had a greater
he dye than superficial lesions.
al dose for clinical use was 20 mg
blue dissolved in 40 ml of saline

Subcutaneous injections of methylene blue have been reported to produce necrosis In order to prevent this possibility the intraarticular injection should be made through the arthroscope

CLINICAL AND ARTHROGRAPHIC *RESULTS OF CONVENTIONAL* BAKER CYST EXCISIONS

W Rauschning & P G Lindgren
Departments of Orthopaedic Surgery and Diagnostic Radiology, University Hospital, Uppsala

Forty-one cases were reviewed 6 months to 15 years (mean 4 years) postoperatively At all operations the cysts had been radically excised and the communication had been closed in 25 cases. *15 major complications* were encountered in the early postoperative course in 13 patients 9 wound healing disturbances with fever necessitated a total of 6 wound revisions In 6 cases "deep venous thrombosis" of the calf was diagnosed At the clinical follow-up 63 per cent of the cysts had recurred Arthrography revealed as many as *40 recurrent cysts* It is concluded that the majority of operations had been performed on the basis of indications which were too broad Failure to close the communication tightly is believed to account for the recurrences as well as for the postoperative complications, as synovial fluid pumped out of the joint is known to have tissue-irritating properties

LATE EFFECTS OF PATELLECTOMY

L-G Broback & T Paradystal
Department of Orthopaedic Surgery, Central Hospital, Eskilstuna

Twenty-two patellectomies performed during 1973–1975 were examined clinically and the muscle strength was registered by the CYBEX II apparatus. Three-quarters of the patients were satisfied with the operation essentially because of lack of pain at rest However, at the clinical examination only 8/22 (36 per cent) of the patients were considered to have good results.

The disadvantages of patellectomy were found to be residual pain on walking, reduced muscle strength and instability with the knee in extension The average loss of muscle strength (recorded by the CYBEX II apparatus) was more than 50 per cent – isometric as well as isokinetic – as compared with the contralateral leg

DRILLING OF OSTEOCHONDRITIS DISSECANS LESIONS IN KNEE JOINTS

B Lindén
Department of Orthopaedic Surgery, Malmo General Hospital, Malmo

Sclerosis in the subchondral bone of adult knee joints with osteochondritis dissecans is an effective barrier to healing It has to be destroyed *to stimulate healing of the bone with the rest of* the condyle A method of subchondral drilling from the side of the condyle against the lesion, without interfering with the articular cartilage, was studied Twelve adult patients were operated on Four lesions were mobile and eight immobile Three were treated with plaster, and two of them were also pinned with bone pegs At the follow-up examination 34–53 months later, eight lesions were healed on the radiograms These patients had no symptoms Four lesions had not healed and these patients had pain In two of these knees the lesions had loosened and were later removed There was no significant difference between healed or unhealed lesions as regards sex, pre-operative duration, age, postoperative duration, mobility or site of the lesion

PROGNOSIS IN PRIMARY SHOULDER DISLOCATION A PRELIMINARY REPORT OF A PROSPECTIVE MULTICENTER STUDY

L Hovelius, J Weckstrom, K Eriksson, J Thorling, B Lind, H Fredin, G Hagberg & F Kylberg

The treatment of primary shoulder dislocation in young people is a controversial subject The literature is briefly reviewed and information is given on a prospective multicenter study involving 25 large and small Swedish hospitals Primary shoulder dislocations in persons 40 years or younger, have, since January 1978, been treated either by early mobilization (1–2 weeks in mitella) or immobilization with the arm bandaged to the body (3–4 weeks) Up to the beginning of May 1979, 174 shoulder dislocations had been treated of which 79 belong to the first and 79 to the second group Sixteen have been treated such that they cannot be placed in either of the two groups The collecting of the material will continue through 1979 and the total material will be followed up during 1981

RECURRENT POSTERIOR [illegible] OF THE SHOULDER JOINT – DIAGNOSTIC MANAGEMENT AND THERAPY IN SEVEN CASES

O Ahlgren
Department of Orthopaedic Surgery [illegible] Umeå, Umeå

Seven cases of recurrent posterior [illegible] the shoulder joint have been treated [illegible] the result of trauma and fi[illegible] occurrence

Neurovascular symptoms, not [illegible] viously, with paraesthesia in the arm [illegible] in six out of seven cases This [illegible] appeared in six cases stabilized by [illegible] glenoplasty according to Scott [illegible] posterior Putti Platt Vascular and [illegible] tests should be performed in all p[illegible] diagnosis

A new roentgenographic technique [illegible] which is of great value preoperative [illegible] timating the degree of posterior [illegible] well as compression fractures of the cavitas glenoidalis and the caput [illegible] method has also been used to check the osteotomy of the collum scapulae [illegible] transplantation

Overall good results were seen [illegible] study 6 months–3 5 years postoper[illegible]

THROMBOEMBOLISM AFTER ELECTIVE AND POST-TRAUMATIC HIP SURGERY—A CONTROLLED PROPHYLACTIC TRIAL WITH DEXTRAN AND LOW DOSE HEPARIN

T Hedlund, D Bergqvist H O [illegible] Hallbook
Departments of Orthopaedic and Gen[illegible] and Diagnostic Radiology [illegible]

A prospective randomized controlled [illegible] been undertaken to evaluate two [illegible] phylactic treatments against [illegible] thromboembolic complications after [illegible] Patients with hip fracture (?) [illegible] undergoing elective hip arthroplasty [illegible] separately randomized into one of the [illegible] control dextran 70 or low-dose he[illegible] vein thrombosis was diagnosed with [illegible] fibrinogen test, and pulmonary [illegible] in the arthroplasty group with a [illegible] pulmonary X ray and perfusion [illegible] frequency of thrombosis was [illegible] in untreated hip fracture [illegible] untreated arthroplasty patients [illegible] patients both treatments [illegible]

y of thrombosis Only dextran reduced quency of "major thrombosis". After hip surgery the overall frequency of sis was not influenced by the two ts

ANCY — NECROSIS OF CAPUT IS IS THERE A IONSHIP?

berg
ent of Orthopaedics and Surgery, Central , Boden

ort is given of four women, aged 25–35 ith symptoms in one or both hip joints, during pregnancy None of them had pre- had any symptoms or signs of joint The symptoms were pain, especially at nd restricted mobility of the hip joint showed in two cases advanced necrosis of it femoris, in one case an almost total ion of the caput was found within 1 year artum In the third case restricted c changes were found in the caput and um The fourth case, a 26-year-old showed bilateral cystic degeneration, os- edge changes and some sclerosis hritis) 1 5 years post partum, when an X- performed

mptoms or signs of infection have been i any of the cases, the sedimentation rate rmal in each case Two of the women had the pill for a short period (6 months and 1 respectively) No other medication had ministered

fsson, B Eriksson, M Fagerlund, G

prophylactic effect of gentamicin- ng bone cement and systemic antibiotic ixis were compared in 1,690 total hip ients in a multi-center study from March itil May 1978 A total of 685 patients in oups have been followed for 1 year and e 11 suspected and confirmed deep in- in the antibiotic group and two in the cin group The difference is statistically nt. Non-infectious loosenings occurred in 20 cases Among 751 arthroplasties with the Christiansen prosthesis there were 19 loosenings and one in 594 Brunswik prostheses. So far there are no loosenings in 205 Charnley prostheses and 112 Lubinus Our study confirms the results of Buchholz and associates that gentamicin in acrylic cement provides good protection against deep infection in total hip arthroplasty

COMPARTMENT SYNDROME IN THE PELVIC AND HIP REGIONS

G Thor-Jónsson, B Albrektsson & A Lindstrand
Department of Orthopaedics, Lund and Molndal

The compartment syndromes in the leg and the arm are well known The more unusual types located in the pelvic and hip regions are also important because missed diagnosis and neglected treatment can lead to permanent neuropathy

Nine cases were presented with two iliopsoas compartment syndromes and seven gluteal compartment syndromes Six cases were associated with anticoagulation therapy and three cases to bleeding from other causes Three cases were subjected to fasciotomy and the remaining six cases were treated conservatively The results were good in three cases, uncertain in one case and poor in five cases. The clue to the diagnosis is radiating pain and a history of anticoagulation or other reason for bleeding Fasciotomy should be done without further delay when neurologic impairment progresses despite conservative treatment

LONG TERM FOLLOW-UP OF ANKLE ARTHRODESES

A Henricson & Å Ahlberg
Department of Orthopaedic Surgery, Malmo General Hospital, Malmo

Forty-three ankle arthrodeses performed in 1950–72 at the Department of Orthopaedic Surgery, Malmo General Hospital, were evaluated, 11 (28 per cent) were infected postoperatively, 5 with a superficial infection and 6 with a deep infection Non-union was seen in 7 (16 per cent)

Twenty nine patients were re-examined, the mean follow-up time being 12.7 years (6 5–28) Two-thirds of the patients had some kind of pain Eighty per cent had shoe problems. Only 20 per cent walked without any limp More than 50 per cent had a subtalar motion less than 50 per cent of that on the non-operated side The rate of forefoot deformity (hallux valgus, digitus malleus, pes

transversoplanus) was not significantly increased

In summary, it is obvious that these patients have many problems Further technical and clinical development of total ankle replacement seems to be necessary

ACCEPTANCE OF MYOELECTRIC HAND PROSTHESES AMONG UNILATERAL BELOW-ELBOW AMPUTEES

P Herberts, L Korner & K Caine
Department of Orthopaedic Surgery, Östra Hospital, Goteborg

In order to determine the acceptance and usefulness of myoelectric prostheses for unilateral below-elbow amputees 38 patients supplied with such devices were followed up with the aid of an extensive questionnaire All patients using their prostheses were personally interviewed and tested for ADL performance with their prostheses In a group of 16 patients the application of the prosthesis was supervised by a specialized team consisting of an orthopaedic surgeon an occupational therapist, and an orthopaedic technician The team met the patients at regular intervals during the first year, and was responsible for information training and follow up Another group of 22 patients obtained their prosthesis through orthopaedic surgeons with no special interest in hand prosthetics

The acceptance in the group of trained patients was 56 per cent and in the untrained group 23 per cent It is concluded that acceptance of myoelectric hand prostheses in unilateral below-elbow amputees is significantly increased through adequate training and follow-up during the first year after the application of the prosthesis

THE DIAGNOSIS AND TREATMENT OF ACUTE HEMATOGENOUS OSTEOMYELITIS (AHO)

A Udén & L G Danielsson
Department of Orthopaedic Surgery Malmo General Hospital Malmo

Three cases are presented in whom there were no initial radiological findings In one patient the radiogram was normal even 2 weeks after the onset of symptoms despite a large lesion in the proximal metaphysis of the humerus In one case also Technetium phosphate scanning was normal Bone scanning may be negative in AHO during the first week (Garnett et al 1977, *Brit J Radiol* 50, 757) An extremely tender, localized area of bone was in all instances the earliest sign of AHO (The thumb of the surgeon is an instrument available even under the pr[illegible] Pain fever and distinct tender[illegible] symptoms and signs which contribute [illegible] diagnosis We also suggest the [illegible] decompression may be necessary [illegible] progression including secondary [illegible] observed in spite of adequate [illegible] antibiotics given within 24 hours

CONSERVATIVE TREATMENT OF AMPUTATED FINGERS

S Holmner & P Magnusson
Department of Surgery Boden

A method for conservative trea[illegible] fingertip and finger amputation, us[illegible] zinc adhesive tape as an occlusive dress[illegible] sented Forty three patients ranging [illegible] 1 5 to 73 years have been treated in this [illegible] 1975 Exposure of bone was recorded [illegible] No attempt was made to cover the b[illegible] tape was applied directly on the [illegible] bandage was then changed daily [illegible] days and as healing proceeded the [illegible] be extended to up to 3–4 days The [illegible] within 3–5 weeks All patients were [illegible] the end results. Sensibility [illegible] almost normal The cosmetic appear[illegible] healed finger was acceptable and [illegible] normal The method is easy cheap [illegible] good end results

FOOT DEFORMITIES IN CHILD[illegible] A METHOD FOR SIMPLE EX[illegible] AND DOCUMENTATION

B Romanus
Department of Orthopaedic S[illegible] Hospital Goteborg

Foot deformities in children are usu[illegible] in such terms as varus, valgus, add[illegible] graded as mild moderate or severe. Th[illegible] and prevents continuous evaluation of [illegible] ment of the feet and any effect of [illegible] Objective methods for documen[illegible] pictures or photographs are time[illegible] demand standardized projections [illegible] A quick and simple method is [illegible] contours of the feet in standing [illegible] marker on paper or plastic sheet The [illegible] reproducibility are good as [illegible] superimposing the drawings of [illegible] aminers. By comparing differ[illegible]

ld's feet it is easy to see and measure in size because of growth, unilateral es, effects of treatment etc

REPLACEMENT IN
ITAL, COMPLETELY
ATED HIPS

& L *Unander-Scharin*
nt of Orthopaedic Surgery, Malmo

-one hips in 17 patients, all women, operated upon mainly by a method by Harris Pain has in every case been indication for operation

rative results bone length has been in most cases but Trendelenburg's sign ained positive Walking range has and most patients walk without pain ive evaluation· improvement in 19/21 rment in 2/21 There is definitely an in- or this operation but the comparatively should be centralized

RADIATION DOSES IN ORTHOPAEDIC SURGERY

Å Hjelmstedt, S Fagerberg & C Ytterberg
Departments of Orthopaedic Surgery, Diagnostic Radiology and Radiation Physics, University Hospital, Uppsala

A study of the radiation exposure of personnel has been made during 23 operations for pertrochanteric and femoral neck fractures The reduction as well as the insertion of Ender nails and von Bahr screws were with the aid of fluoroscopy

Doses of 4 mR/operation or more were registered only for the surgeons Measurements on the surgeons' hands gave a mean value of 25 mR/operation with a maximal dose of 154 mR Registration of the radiation dose close to the eyes gave values of 4–27 mR (mean 13 mR) The radiation dose/year for the eyes and hands might *for some of the surgeons well exceed the* stipulated maximal doses

Thus, it is most important that the safety regulations are strictly followed, that the surgeon is aware of the risks, that protective glasses are always used and that the video disc recorder is used whenever possible With these precautions the radiation doses will be reduced by 80–90 per cent

o the Editor

r,

letter to the Editor, Dr Bohr (Bohr made an accusation that his paper 1973) had been incorrectly cited ·r in all of the 13 cases Bohr ed he found, irrespective of the stage thes' disease, increased radiological In the 10 cases he examined ·aphically he found all had areas of ed activity in the affected capital l epiphysis One "early condensation" lowed only a "little uptake" and four ondensation" cases showed "somewhat l' activity in the lateral part of the sis The main conclusion he drew from bservations was that the sclerosis was) revascularization and appositional ormation

as therefore reasonable to cite, in our ion of the cause of the radiologic is that " Bohr (1973) found increased even in the initial stage and supported the opinion that the increased density was due to appositional bone formation" (Fasting et al 1978)

Perhaps we should also have cited from his work in our paragraph on the diagnostic value of the reduced uptake on scintigrams However we found Bohr's results difficult to interpret as far as the diagnosis of Perthes' disease is concerned

Ove J Fasting M D

REFERENCES

Bohr H (1973) Densiometry and 18 F scintigraphy in the study of the revascularisation of the femoral head in coxa plana (C–P) *Acta orthop scand* 44, 417–425

Bohr H (1979) Letter to the Editor *Acta orthop scand* 50, 127

Fasting O J Langeland N Bjerkreim I Hertzenberg L & Nakken K (1978) Bone scintigraphy in early diagnosis of Perthes' disease *Acta orthop scand* 49, 169 174

Announcement

Fourth International Conference on Ski Trauma and Ski Safety, June 7–12, 1981 [illegible] Bormio, Italian Alps

Among the topics for discussion
Biomechanics of ski lesions
Prevention and treatment of ski injuries

For further information please contact
Dr Massimo Magi, M D
Head of Department of Orthopaedic Surgery
Bormio-Sondalo Regional Hospital
23035 Sondalo SO, Italy

Announcement

B O A — N O F — N O V Amsterdam 1980

The joint congress of the British Dutch and Nordic Orthopaedic Associations [illegible] Amsterdam on October 1–3, 1980 The congress programme includes free papers, [illegible] cussions and poster sessions

A second announcement in May will contain the major items on the programme

Contributions to the poster sessions should be submitted before August 1, 1980.

Members may obtain detailed information from the congress secretariat
c/o Organisatie Bureau Amsterdam BV
Europaplein
1078 GZ Amsterdam, The Netherlands

ıop scand. 51, 389 398 1980

NOPHILIC GRANULOMA OF BONE

IcCULLOUGH

I Orthopaedic Centre, Oxford, England

Forty-three patients with histologically proven Histiocytosis X localized to bone at presentation have been reviewed Thirty-six patients presented with solitary bone lesions and 31 have healed without complication with a mean follow-up of 10 years. The remaining five patients developed polyostotic disease, three exhibiting either pulmonary lesions or diabetes insipidus. Seven patients presented with multiple bone lesions and six of them developed other bone lesions Four of these patients also showed some of the features of Hand Schuller-Christian disease An increase in size of the presenting bone lesion within a few months of biopsy heralded the subsequent development of further bone or soft tissue lesions and was the only feature of prognostic value

Key words eosinophilic granuloma, Histiocytosis X

Accepted 16 xi 79

philic granuloma is a destructive lesion one and represents the localized station of Histiocytosis X (Lichten- 1953, 1964) Hand-Schüller-Christian is the chronic disseminated form terized by progressive bone lesions, ic involvement and sometimes, es insipidus and exophthalmos The osis is uncertain and spontaneous ion may occur Letterer-Siwe disease is ite illness in young children character- y the presence of widespread, pre- antly visceral lesions and carries a poor osis (Cheyne 1971) Although most y bone lesions have been reported to vith or without treatment, the subse- appearance of further bone lesions or ssion to the chronic disseminated form ase has been described (Oberman 1961, aro & Francis 1961, Fowles & hko 1970, Cheyne 1971, Schajowicz & el 1973) On the basis of their own Oschner (1966) and McGavran (1960) hallenged this latter proposition

The purpose of this presentation is to analyse the features that may indicate which lesions initially confined to bone may be complicated by the development of further bone or soft tissue lesions The effects of radiotherapy on the healing of long bone lesions and the neurological complications of vertebral body disease are also discussed

PATIENTS

The clinical records, radiographs and pathological findings of 43 patients seen at the Nuffield Orthopaedic Centre, or referred to the Bristol Bone Tumour Registry since 1945, were reviewed. All had histologically proven Histiocytosis X localized to bone at presentation Patients with soft tissue lesions evident at the time of presenta- [illegible] Twenty- [illegible] Thirty-six [illegible] lesions. A skeletal survey was performed in 24 of these patients at presentation Five developed other bone lesions. Seven patients presented with multiple skeletal lesions and six of them developed

170, 80 030389–10S02 50 0

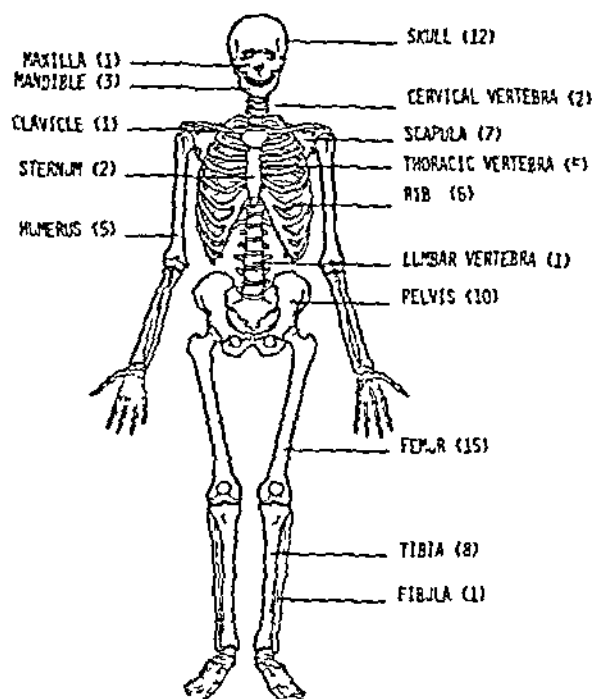


Figure 1 The sites of 79 bone lesions in 43 patients

further bone lesions. The sites of the skeletal lesions are shown in Figure 1

The mean age at presentation of 43 patients was 17 years 9 months (range 1 year 6 months to 64 years) The mean age at follow up of 38 patients was 34 years (range 6 years to 60 years) the average period of follow-up being 10 years (Figure 2) Five patients died due to progression of the disease at a mean time of 3 years following diagnosis.

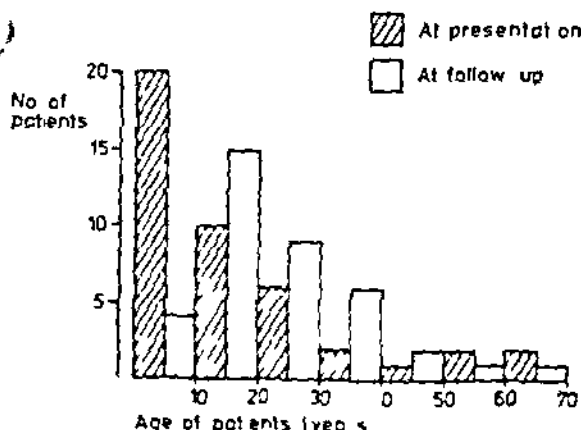


Figure 2 Histogram showing the age distribution of 43 patients at presentation and 38 patients at follow-up Five patients died

Radiology

The radiological features of [illegible] in this series have been reported [illegible] et al 1973) and agree with other [illegible] 1966 Takahashi et al. 1966). In [illegible] lesion appears as an irregula[illegible] medulla, usually with endosteal [illegible] cortical destruction may be evident (Fig[illegible] there may be an "onion skin" periosteal [illegible] in diaphyseal lesions. Marginal scleros[illegible] that the lesion is healing Long bone [illegible] considered to have healed in these [illegible] the trabecular pattern had returned [illegible] when the lytic area had been totally [illegible] localized area of sclerosis. Flat bone [illegible] as irregular lytic areas. Either compl[illegible] may occur upon healing or the [illegible] remain though with a well defined [illegible] margin

Histology

In all patients, the diagnosis of H[illegible] was confirmed by histological [illegible] essential histological features are well [illegible] (Lichtenstein 1964 Price 1971 [illegible] usual histological appearance [illegible] granuloma is of collections of [illegible]



Figure 3 Patient 1 Table I [illegible] proximal femur showing a [illegible] cortical destruction in a [illegible] presented with a 1 month [illegible] right hip

phs always accompanied by histiocytes h lymphocytes and sometimes plasma cells ion. Multinuclear giant cells of osteoclast occasionally present but never in large a In Hand Schuller-Christian disease the s composed predominantly of histiocytes are sometimes lipid-containing and the ils are scanty Fibroblastic differentiation observed in lesions of both eosinophilic na and Hand Schuller-Christian disease onsidered as evidence of healing However f fibrosis may be seen in lesions which to enlarge after biopsy

NATURAL HISTORY AND TMENT

y skeletal lesions

six patients presented with solitary sions and 31 healed with no adverse e The minimum period of follow-up 3 months The lesions were treated by excision biopsy, or by incision and

long bone lesions following incision and curettage has been assessed by ing serial radiographs in twelve ts treated with or without radiotherapy ean time to healing of the five lesions with radiotherapy was 12 months and seven lesions treated with curettage was 11 months.

le skeletal lesions

patients presented with solitary bone but developed polyostotic disease. patients presented with multiple bone and six of these developed further esions The clinical details are shown in 1 Of these twelve patients seven pro- to the Hand Schuller Christian me Five patients had pulmonary in ent which appeared late in the disease o of these had diabetes insipidus. All patients have died Two patients ped diabetes insipidus alone Four of the patients who died were over the age of 50 at diagnosis and the presence of progressive bone lesions in this age group would seem to carry a bad prognosis In contrast, four of the five children who had widely disseminated bone disease survived though after a prolonged period of illness

Sequential X rays or detailed clinical records of the presenting bone lesions were



Figure 4 Patient 12 Table 1 Antero-posterior X ray of the distal left tibia in a male aged 58 years showing an irregular lytic lesion in the medulla with endosteal erosion prior to biopsy

Table 1 The clinical details of 12 patients who had multiple skeletal lesions [illegible] presented [illegible]

Patient	Age at presentation (years)	Symptomatic bone lesion at presentation	Asymptomatic lesions present on skeletal survey	T[illegible]
1	12	Proximal femoral metaphysis	8th dorsal vertebra	Biopsy Bone [illegible]
2	3	Skull Occiput	None	Biopsy Ra[illegible]
3	$2\frac{3}{4}$	Ilium (Left)	None	Biopsy Ra[illegible]
4	$1\frac{3}{4}$	Skull	Rib Femora	[illegible]
5	$4\frac{3}{4}$	4th dorsal vertebra	None	[illegible]
6	$2\frac{1}{2}$	Ilium Skull	None	Biopsy Ra[illegible]
7	$1\frac{1}{2}$	Skull (proptosis)	None	Biopsy Ra[illegible]
8	26	Acromium	None	Biopsy Ra[illegible]
9	61	Mandible Rib	None	Biopsy
10	54	Femur (pathological fracture)	Left 6th rib	Biopsy [illegible]
11	64	Skull Sternum Scapula	None	B[illegible] Ra[illegible]
12	58	Tibia (left)	Tibia (right) Ilium	[illegible]

..litary bone lesions at presentation and developed subsequent lesions Seven patients ..f them developed further lesions

..e of ..ng lesion ..nent	Timing and site of subsequent bone lesions	Complications	Age and *status at* follow-up
..lesion ..neck	None	None	14 years Healed lesion femoral neck
.. in ..esion	2 years – base of skull	Diabetes insipidus	14 years No further bone lesions
.. in size ..n	12 months – ilium (right) 34 months – humerus 39 months – skull	None	21 years Normal
..own	6 months – tibia	None	18 years– Normal
..l ..ent	9 months – tibia (biopsy taken) Widespread vertebral lesions	None	17 years– Normal
..se in size ..lesions	7 months – skull, occiput 11 months – skull, parietal 14 months – scapula, cervical spine 19 months – humerus, ilium	None	29 years Normal
..se in size ..on	12 months – skull, ilium Later – scapula, femora	None	4 years– Died, disseminated disease
..se in size ..on	6 months – 2nd lumbar vertebra Followed shortly by multiple vertebra	Paraplegia	28 years– Died, disseminated disease
..se in size ..on in ..ible	9 months – femora, tibiae, pelvis 12 months – skull	Diabetes insipidus	62 years– Died, disseminated disease
..nown	6 months – 5th, 6th, 7th, 8th, 9th dorsal vertebrae	Diabetes insipidus Paraplegia	59 years Died, disseminated disease
..ase in size ..ll lesion	7 months – 6th cervical vertebra 3 years – 2nd, 4th and 5th cervical vertebrae	Tetraparesis	68 years– Died, disseminated disease
..ase in size ..ions	8 months – bone scan showed generalized lesions	Diabetes insipidus	60 years– Progressive bone lesions

available for study in eight of the eleven patients who developed further bone or soft tissue lesions In all cases the primary lesion was noted to increase in size following biopsy and curettage (Figures 4, 5, 6, 7, 8, 9) There was no increase in size of the [illegible] lesion in the one patient (P[illegible] 1 T[illegible] who when reviewed at 2 years [illegible] developed further skeletal [illegible] therapy did not appear to [illegible]



Figure 5 Patient 12 Table 1 At 5 months after biopsy, there is an increase in size of the lesion noted, despite external radiotherapy Again the proximal tibia is radiologically normal A repeat bone scan demonstrated multiple skeletal deposits

Figure 6 Patient 12 Table 1 [illegible] the left tibia at 20 [illegible] Widespread medullary lesions [illegible] proximal and distal tibia



7 Patient 8 Table 1 An X ray of the ɪm in a male aged 26 years showing a ɪtic lesion.



Figure 9 Patient 8 Table 1 X ray of the acromium 5 months after biopsy showing increased destruction despite external radiotherapy Multiple vertebral lesions were now evident



8 Patient 8 Table 1 X ray of the ɪm 2 months after biopsy showing partial ɪon

ɪtion and did not prevent the subse- ppearance of further bone lesions.

eurological complications of vertebral

ɪe adults and five children had ɪal body lesions. In the former the lesions were all multiple (Figure 10) and were complicated by severe spinal cord damage The three adult patients died One of the five children had multiple dorso-lumbar lesions (Figure 11) and four solitary lesions. There were no neurological complications and healing of the vertebral lesions occurred

DISCUSSION

This review of 43 patients with Histiocytosis X confirms that most solitary bone lesions heal without complication However five of the thirty six patients with solitary lesions at presentation and six of the seven patients with multiple lesions at presentation developed other bone lesions. Seven of these eleven patients with progressive disease later developed either diabetes insipidus or pulmonary involvement A feature of prog nostic significance was an increase in size of the presenting skeletal lesion following biopsy and curettage which heralded the appearance of other bone or soft tissue lesions. Fowles & Bobechko (1970) described this occurrence in two of the forty four children in their series. Although Cheyne (1971) has described one

available for study in eight of the eleven patients who developed further bone or soft tissue lesions In all cases the primary lesion was noted to increase in size following biopsy and curettage (Figures 4 5, 6 7, 8 9) There was no increase in size of the [illegible] lesion in the one patient (Patient [illegible]) who when reviewed at 2 years [illegible] developed further skeletal lesions [illegible] therapy did not appear to [illegible]

Figure 5 Patient 12 Table 1 At 5 months after biopsy there is an increase in size of the lesion noted despite external radiotherapy Again the proximal tibia is radiologically normal A repeat bone scan demonstrated multiple skeletal deposits




Figure 6 Patient 12 Table 1 [illegible] the left tibia at 20 months [illegible] Widespread medullary lesions [illegible] proximal and distal tibia

e 11 Patient 5 Table 1 Lateral X-ray of ...rral spine in a girl aged 11 years showing ...se of multiple vertebral bodies There were ...urological complications

...ry vertebral lesions (Oberman 1961, ...ner 1966, Cheyne 1971) Neurological ...ioration and death may supervene

...e treatment of vertebral lesions should ...onservative initially with bracing as ...red In many series, the lesions were ...d with radiotherapy (500–1,000 rad) ...later healed Needle or open biopsy ...d be performed as positive histology is ...tial for diagnosis Operative treatment ...be required for those lesions with ...logical complications.

ACKNOWLEDGEMENTS

I am grateful to Dr C G Woods, Consultant Pathologist, Nuffield Orthopaedic Centre, who has offered continual help and encouragement I would like to thank Dr N G Sanerkin for allowing me to review the records of patients referred to the Bristol Bone Tumour Registry and the Consultant Staff at the Nuffield Orthopaedic Centre for allowing me to review their patients I would also like to thank Dr J L Boldero for allowing access to his X-ray collections

REFERENCES

Cheyne, C (1971) Histiocytosis X *J Bone Jt Surg* 53-B, 366–382

Compere, E L, Johnson, W E & Coventry, M B (1954) Vertebra plana (Calvé's disease) due to eosinophilic granuloma *J Bone Jt Surg* 36-A, 969–980

Davidson, R I & Shillito, J (1970) Eosinophilic granuloma of the cervical spine in children *Pediatrics* 45, 746–752.

Ennis, J T, Whitehouse, G, Ross F G M & Middlemiss, J H (1973) The radiology of the bone changes in histiocytosis X *Clin Radiol* 24, 212–220

Fowles, J V & Bobechko, W P (1970) Solitary eosinophilic granuloma in bone *J Bone Jt Surg* 52 B 238–243

Fripp A T (1958) Vertebra plana *J Bone Jt Surg* 40 B 378–384

Gibson, R M & Eisen A A (1963) Eosinophilic granuloma of bone in two adjacent thoracic vertebrae *J Bone Jt Surg* 45-B, 566–569

Kieffer, S A, Nesbit, M E & D'Angio, G J (1969) Vertebra plana due to histiocytosis X Serial studies *Acta radiol Diag* 8, 241–250

Lichtenstein, L (1953) Histiocytosis X. *Arch Path* 56, 84–102

Lichtenstein, L (1964) Histiocytosis X (Eosinophilic granuloma of bone Letterer-Siwe disease and Schuller-Christian disease) *J Bone Jt Surg* 46-A, 76–90

Lindenbaum, B & Gettes, N I (1970) Solitary eosinophilic granuloma of the cervical region *Clin Orthop* 68, 112–114

McGavran, M H & Spady, H A (1960) Eosinophilic granuloma of bone *J Bone Jt Surg* 42-A 979–992.

Marar, B C & Balachandran, N N (1973) Non-traumatic atlanto-axial dislocation in children *Clin Orthop* 92, 220–226

Oberman, H A (1961) Idiopathic histiocytosis *Pediatrics* 38, 307–328

Oschner, S F (1966) Eosinophilic granuloma of bone *Amer J Roentgenol* **97**, 719–726

Poulsen, J O & Thommesen P (1976) An unusual case of histiocytosis X in the spine *Acta orthop scand* **47**, 59–62

Price, C H G (1971) Histiocytosis X Histology *Proc roy Soc Med* **64**, 336–338

Rigault, P & Finidori G (1977) Les localisations vertébrales de l'histiocytose X Aspect orthopaedique *Rev Chir orthop* **63**, Suppl 2, 190–194

Sbarbaro J L & Francis K C (1961) Eosinophilic granuloma of bone *J Amer med Ass* **178**, 114–118

Schajowicz, F & Slullitel J (1973) Eosinophilic granuloma of bone and its [illegible] Hand Schüller-Christian and [illegible] syndrome *J Bone Jt Surg* 55-B, [illegible]

Sherk, H H Nicholson, J & [illegible] Vertebra plana and eosinophilic [illegible] the cervical spine in children [illegible] 116–121

Takahashi M, Martel, W & [illegible] (1966) The variable [illegible] appearance of idiopathic [illegible] *Radiol* **17**, 48–43

Yabsley R H & Harris, W R (1[illegible]) eosinophilic granuloma of a [illegible] causing paraplegia. *J Bone J* [illegible] 1570–1574

Correspondence to C J McCullough M B, B Chir, F R C S, Senior Orthopaedic [illegible] Orthopaedic Centre, Oxford England

hop scand. 51 399–401 1980

-IE MARROW CELL CONTENT AND 'TEOCLASTS IN CRISTA BIOPSIES

JOHNELL

tment of Orthopaedic Surgery, Malmo General Hospital
ersity of Lund) Malmo Sweden

The bone marrow cell content was investigated by counting the percentage of cells in the areas between the trabeculae in crista biopsies. There was a decrease in the percentage of cells in bone marrow in osteoporotic women compared with our normal material In patients undergoing haemodialysis there was a positive correlation between bone marrow cell content and osteoclasts, which could indicate a possible connection between osteoclasts and bone marrow cells.

Key words bone biopsy bone marrow cells bone volume osteoclasts

Accepted 9 viii 79

as earlier been discussed by Owen (1978) haematogenic cells could be involved in resorption Burkhardt (1977) has studied importance of bone marrow and ularization in the development of osathy Bone marrow content in different abolic bone diseases has also been in igated (te Welde et al. 1977). We have stigated bone marrow response after ma finding an increase in the number of oses in bone marrow after experimental tures in rats. At the same time we found ncreased number of osteoclasts in the ribs nell & Hulth 1977, Hulth & Johnell 1976)

TERIAL AND METHODS

sies from the iliac crest were taken from three rent groups of patients 23 osteoporotic ien, 14 alcoholics and 15 patients undergoing iod alysis. Normal autopsy material was cted from 12 women and 24 men at the nsic Department all these people had died lenly after cardiac arrest accident or suicide biopsies were taken using a Burkhardt umentarium (Burkhardt 1966) from the top of the iliac crest, 2 to 3 cm behind the iliac spine. The biopsies were embedded in methylmethacrylate and sectioned undecalcified into sections 4 to 7 µ in size The sections were

[illegible]

falling on bone trabeculae on bone marrow on cells and on bone marrow without cells, respectively were counted The percentage of bone marrow cells was determined by dividing the number of intersections falling on cells in the bone marrow by the total number of intersections counted in bone marrow × 100 In the haemodialysis group the percentage of intersections on sites of osteitis fibrosa of the total bone marrow was counted in the same way The number of osteoclasts was counted according to the system described earlier (Johnell et al 1977) In the osteoporotic group bone mass in the radius and ulna at 1 and 6 cm from the distal end of the ulna was determined by gamma absorptiometry with Americium 291 (Nilsson & Westlin 1972)

RESULTS

In our normal material we found no difference between men and women, no correlation between age and percentage of cells

-6470/80/030399–03$02.5 0

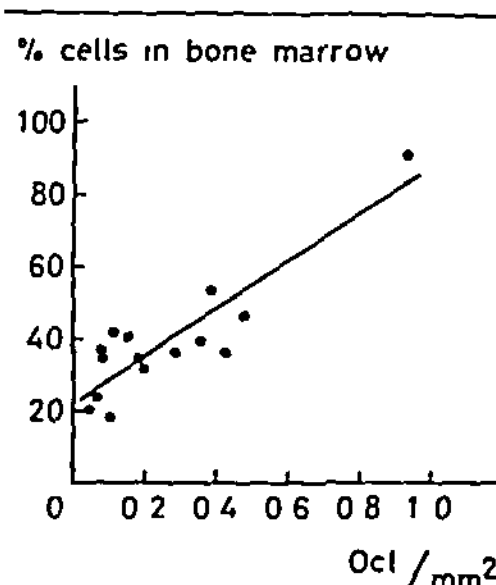


Figure 1 A positive correlation between the number of osteoclasts/mm² and the percentage of cells in bone marrow of 15 haemodialysis patients (r – 0 88)

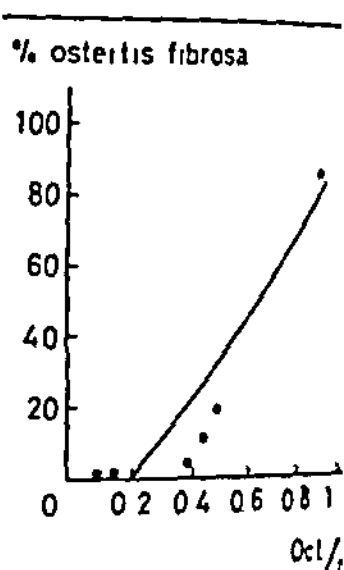


Figure 2 A positive correl... number of osteoclasts/mm² and the p... osteitis fibrosa in the b... haemodialysis patients (r – 0 93).

in bone marrow, and only a weak correlation between the number of osteoclasts and the percentage of cells in bone marrow This can be explained by the small span in the number of osteoclasts in this group By contrast in the haemodialysis group, we found a positive correlation between osteoclasts and the percentage of cells (Figure 1) There was no such correlation in the alcoholic and osteoporotic groups The average number of bone marrow cells was higher in the normal group than in the osteoporotic group and Student's *t*-test was significant (Table 1) There was no difference in age in these groups In the osteoporotic group we also found a positive correlation between osteoclasts and the bone mass at 1 cm level on the radius (r = 0 50), but no such correlation at 6 cm (In the normal material obtained from the Forensic Depar... densitometric measurements wer... There was also a positive correl... the number of osteoclasts and the p... of osteitis fibrosa in the haemodial... (Figure 2) Osteitis fibrosa was fo... the 15 haemodialysis patients.

DISCUSSION

There seems to be a correl... the haemodialysis group between the... of osteoclasts and the percen... of total bone marrow, which coul... indirect connection between the ... cells and the development of oste... discussed by Owen (1978). It wa... teresting to find that the numbe...

Table 1 Comparison between the number of bone marrow cells in the normal and osteoporotic groups

	Number	% cells in bone marrow	*t*-test
Normals	12	48 7 ± 14 5 (± s.d)	3 95 P < 0.001
Osteoporotics	25	30 7 ± 8 9 (± s.d)	

ıe marrow of osteoporotic women was ıntly lower than that of women in the group, and this could indicate an inac- f the bone tissue in the osteoporotic As we have described earlier there ı increase in osteoid surface and the ˙ of osteoclasts was low in the patients steoporosis

correlation between osteoclasts and ıass at the 1 cm level but not at 6 cm be explained by the fact that the ˙ of osteoclasts was calculated from the lar bone in the iliac crest and at the 1 :l on the radius, where the majority of ne tissue is trabecular, at 6 cm the y is cortical

ƎENCES

ːdt, R (1966) Präparative Voraussetzung klinische Histologie des menschlichen chenmarks 2 Mitt *Blut* **14**, 30–46

Burkhardt R & Demnler, K. (1977) Bone, bone marrow and vascularisation *Calcif Tiss Res* **24**, Suppl 5, R5

Goldner, J (1938) A modification of the Masson trichromatechnique for routine laboratory purpose *Amer J Path* **14**, 237–243

Hulth, A & Johnell, O (1976) Cell proliferation in the bone marrow and thymus following fractures in rats. *Clin Orthop* **120**, 260–264

Johnell, O & Hulth A (1977) Proliferation of os teoclasts in rat bone following bleeding and femoral fractures *Calcif Tiss Res* **23**, 241 244

Johnell, O, Wiklund, P-E & Hulth, A (1977) Osteoclast counting in crista biopsies *Acta orthop scand* **48**, 566–571

Nilsson B E & Westlin, N E (1972) *An apparatus for in vivo measurement of bone mineral* Published by AB Gambro, Lund, Sweden

Owen, M (1978) Histogenesis of bone cells. *Calcif Tiss Res* **25**, 205–209

Schenk, R K, Merz W A & Muller, J (1969) A quantitative study on bone in human cancellous bone *Acta anat (Basel)* **74**, 44–53

te Velde, J Leenheers-Binnendijk, C F, Kleiverda, J K, Vos, C, Smeenk, D & Bijvoet, O L M (1977) Bone marrow histology in metabolic bone disease *Calcif Tiss Res* **24**, Suppl 5 R25

pondence to Olof Johnell, M D, Department of Orthopaedic Surgery University of Lund › General Hospital, S–214 01 Malmo, Sweden

ıop scand 51, 403 411, 1980

,UE REACTION AND METAL SENSITIVITY

ıimal Study

ıRINE MERRITT & STANLEY A BROWN

tory for Experimental Surgery, Davos, and Institut Dr Ing R Straumann, Waldenburg, land

An animal study is presented in which nickel sensitivity as determined by an *in vitro* test for leukocyte migration inhibition (LIF) is correlated with results of skin tests with $NiCl_2$ and with the degree of adverse tissue reaction to implanted stainless steel screws Screws were implanted in the humeri of New Zealand white rabbits, one group of which received repeated injections of nickel chloride following an initial injection of nickel chloride in Freund's adjuvant All the injected rabbits became skin test positive to nickel and demonstrated LIF production in the presence of nickel chloride Some of the injected rabbits, 6 9 weeks after implantation of the screws, developed an inability for leukocyte migration even when the cells were incubated only with saline and serum The tissue reaction to [illegible]

condition of no leukocyte migration in the LIF test The correlation between skin test and LIF test results demonstrates the effectiveness of the LIF assay for sensitivity testing without the risk of sensitization associated with skin testing The histological results support the hypothesis that the condition of no cell migration in the LIF test is diagnostic for severe reactions to implants associated with metal sensitivity

Key words implant, LIF, nickel, rabbit, screw, sensitivity

Accepted 10 x 79

role of metal sensitivity in complications ıated with the use of metallic implants is g rise to increased discussion Some nts with a metal sensitivity have been ınstrated to have increased morbidity ving the use of various internal metallic es including wires, clips, screws, s, rods, and joint arthroplasties 'anco & Solomon 1972, Benson et al , Brown et al. 1976a, Cramers & Lucht , Elves et al 1975, Evans et al 1974, enzie et al 1967, Merritt et al 1979) ever, the contribution of this metal sen- ty to such complications is still controversial, whether or not and for how long sensitive individuals can accept metal appliances is still open to question Some claim there is no problem (Fisher 1973, 1977), while others will deviate from their usual implant material selection so as to avoid implanting appliances with one or more metal alloy constituents to which the patient is sensitive (Deutman et al 1977) Certainly sensitivity is not the cause of all problems, although in some cases it may be a major factor

In order to study the incidence of metal sensitivity in orthopaedic patients, without

6470/80/030403–09$02.50/0

the risk of sensitization associated with repeated skin testing (Meneghini & Angelini 1977) we have developed an *in vitro* test for metal sensitivity (Brown et al 1976b Merritt et al 1979a, 1979b) The leukocyte migration inhibition (LIF) test method was selected because of the known association between the presence of cell mediated immunity and the production of lymphokines such as LIF *in vitro* (Rocklin & David 1976) Ameboid leukocytes such as macrophages and polymorphonuclear leukocytes will migrate through agarose when incubated with a growth medium However, when T-lymphocytes in the white cell population are exposed to an antigen to which they are sensitive they will respond with the release of lymphokines, one of which (LIF) will inhibit the migration of the ameboid leukocytes To test for sensitivity a method similar to that first described by Clausen (1971) and modified by Astor et al (1973) is used The migration of leukocytes is tested in three conditions in saline as a migration control, in the presence of a known T-lymphocyte stimulator (PHA) as a no migration control, and in the presence of the antigen in question Since metal ions are haptens, which must be complexed with protein carriers to be antigenic, we incubate white cells with metal chlorides and serum as a source of protein to assay for metal sensitivity The method has been used with chlorides of nickel, cobalt and chromium (Brown et al 1976b Merritt et al 1979a, 1979b)

The results of the clinical studies have demonstrated three classifications of patient response (Merritt et al 1979a, 1979b) Patients with no metal sensitivity show good leukocyte migration except in the presence of PHA Patients with metal sensitivity show good migration except in the presence of PHA and the metal salt(s) to which they are sensitive The third patient classification is that of no cell migration in any of the test conditions. These patients have all had metal implants at the time the test was performed Many of the implants were associated with pain, loosening or skin rashes L[illegible] the implants were removed [illegible] tests showed good cell [illegible] the presence of PHA and one [illegible] three metals We have hypothes[illegible] condition of no cell migration [illegible] for the presence of a sens[illegible] the implant

It is the correlation between the [illegible] results, skin test results and tiss[illegible] metallic implants that is the s[illegible] report In order to exam[illegible] reaction in detail an an[illegible] developed The New Zealand wh[illegible] was used as it is large enough [illegible] orthopedic implants appropr[illegible] use and to be used repeatedly [illegible] 10 ml of blood for performing the [illegible] sensitivity and cortical bone [illegible] selected for this investigation [illegible] predominance of nickel sens[illegible] with screws in the clinical s[illegible] steel screws were utilized [illegible] availability In this paper we [illegible] ability of the rabbit to develop [illegible] sitivity and the condition of no cell [illegible] a correlation between LIF [illegible] results and a correlation between [illegible] results especially no cell [illegible] severity of tissue reaction to [illegible] screws

MATERIALS AND METHODS

Rabbits New Zealand white rabbits of [illegible] 3–4 kg in weight were used in these [illegible] They were housed in individual [illegible] and water *ad libitum*. The animals [illegible] assigned to two groups [illegible] stainless steel screws and [illegible] screws and were immunized [illegible] 4–6 weeks prior to implanta[illegible]

Immunization. Rabbits were [illegible] 0 5 ml of 1 per cent N[illegible]Cl_2 in [illegible] adjuvant Three weeks la[illegible] booster injection of 0.5 ml of 2 pe[illegible] saline Thereafter they received [illegible] 0 5 ml of 0 2 per cent N[illegible]Cl_2 every [illegible] 3–4 weeks before sacrifice

r sensitization

' test At operation 10 ml of blood was rom the central ear artery into a heparinizge Blood was obtained similarly every 3 after operation and at sacrifice The test ne as previously described (Merritt et al Briefly, the buffy coat was obtained after itation of the rbc's with dextran The buffy coat cells were then incubated with nd serum with Phytohemagglutinin (PHA) sitive control for LIF production, and with is a cell migration control The incubated 's were then pipetted into 3 mm holes d into agarose containing growth medium stance the cells migrated in the presence of tal salts was compared with the distance ls with no metal salt challenge migrated igration in the presence of metal salt ge usually fell into one of two categories an 20 per cent of control or more than 80 nt of control migration Therefore, in ance with standard immunologic procedure, cells with metal salt challenge migrated less 0 per cent of the distance the control cells ed, then the rabbit was said to be sensitive el The rabbits were tested for LIF producnd also for the situation of being nonors. Cell viability studies were done on the t rabbits using the exclusion of 0 4 per cent blue in saline (GIBCO with GIBCO ol) as an indicator of viability

in test The back of each rabbit was shaved *urs prior* to sacrifice, and 0 1 ml of 0 2 per nd of 0 02 per cent $NiCl_2$ were injected i d *ite* was observed at 4–6 hours, 24, 48, and urs after injection for evidence of induration rythema The reaction spots were graded *ling* to diameter a spot 2–3 mm in diameter alled 1+, 3–5 mm 2+, and >5 mm 3+

ry Rabbits were placed under general tesia for insertion of ½ inch 316 LVM finger s (Zimmer USA) or 2 7×12 mm 316 LVM s (Synthes) Screws were inserted bilaterally he proximal humeri There were two groups nimals uninjected controls and rabbits nized 4–6 weeks previously and peratively with $NiCl_2$ Rabbits were iced 3, 9, or 16 weeks post insertion of the The 16-week rabbits received the Zimmer s, the others received the Synthes screws.

logy The bone fragment containing the was fixed in Bouin's, embedded in ylmethacrylate, and sectioned with a Zeiss all' (Perren & Geret 1979) making a cross

Table 1 The number of rabbits responding with LIF and having a positive skin test is shown for the controls and the rabbits injected with $NiCl_2$ They were sacrificed at 3, 9, or 16 weeks after implantation of a 316 LVM bone screw

		Size of group	LIF	Non-migrator	$NiCl_2$ skin test 0 2% 1+	2+	3+	0 02% 1+
3 wk	control	4	0	0	0	0	0	ND*
	$NiCl_2$	5	5	0	5	0	0	ND
9 wk	control	6	0	0	1	0	0	0
	$NiCl_2$	9	9	5	3	3	3	3
16 wk	control	3	0	0	0	0	0	ND
	$NiCl_2$	5	5	2	3	2	0	ND

*ND = not done

section of the bone through the screw without decalcification of the bone or removal of the screw The sections were stained with Giemsa stain and mounted with Eukitt The sections from the left and from the right humeri were examined for each animal

The sections were examined without knowledge of the sensitization status of the rabbit and the interface tissue was scored on a 0 to 5+ scale for syncytial giant cells foreign body giant cells bone, fresh rbc, old rbc, inflammatory cells, eosinophils and necrotic or cystic tissue The bone marrow away from the screw thread was also examined and scored as normal or unhealthy (many inflammatory cells or areas of necrosis)

The average score for the histologic evaluation was inspected, and statistical analysis was done only in those categories revealing differences. The standard deviation was determined for the controls and then the scores on the animals injected with $NiCl_2$ were inspected for the number falling 2 standard deviations (σ) above or below the mean for the control

RESULTS

Sensitization

(1) *Skin test* The reactions were absent at 4–6 hours, appeared at about 24 hours, and peaked by 48 hours As can be seen from the data presented in Table 1, all rabbits

Table 2 The results of the histologic evaluation of the bone-screw interface and the [illegible] marrow are recorded for rabbits with and without the injection of $NiCl_2$ and [illegible] after implantation of the 316 LVM bone screw

	3 week				9 week				16 week	
	Control (8)		$NiCl_2$ (10)		Control (12)		$NiCl_2$ (17)		Con[illegible]	
Interface	Ave	$\pm 2\sigma$	Ave	$>2\sigma$	Ave.	$\pm 2\sigma$	Ave	$>2\sigma$	Ave	[illegible]
Syncytial giant	3 4		3 3		2 1		2.7		1 8	
Foreign body	0 50	0–1	2.4	81	0 5	0 76–1 76	1.3	111	0 16	0– 5
Bone	0 62		1 0		1 4		1 2		2.0	
Old rbc	2.2		1 2		1 4		2.2		1 0	
New rbc	0 87		0 5		0 42		0 94		0 5	
Inflammatory cells	1 1		1 4		0 17	0 – 47	3 4	161	0 33	0-25
Eosinophilic cells	0 75		0 7		1 3	0 76–3 9	2.2	31	0 16	0-1 15
Necrosis or cysts	0		0 2		0 8		0 41		0	
Bone marrow unhealthy	3		10		2		13		0	

immunized with $NiCl_2$ were skin test positive to 0 2 per cent $NiCl_2$ Only the 9 week rabbits were tested with 0 02 per cent $NiCl_2$ and three of them were positive One of the 13 unimmunized rabbits was skin test positive to 0 2 per cent $NiCl_2$ but not to 0 02 per cent Skin testing with 2 per cent $NiCl_2$ gave a toxic reaction in control rabbits in a preliminary study and was not used for further testing

(2) *LIF test* All rabbits immunized with $NiCl_2$ produced LIF to $NiCl_2$ whereas no control rabbit produced LIF None of the 3 week rabbits were nonmigrators 5/9 of the 9 week rabbits had become nonmigrators (1 at 6 weeks and the others at 9 weeks) and in the 16-week series two rabbits had become nonmigrators, both at 9 weeks. The trypan blue cell viability test gave similar results for the migrators and the nonmigrators with about 90 per cent viable cells.

Histology The results of the histology grading are recorded in Table 2 The scores for each group and sacrifice period were averaged. The progression in histologic response to screws by the [illegible] rabbits from 3 weeks, to 9 weeks [illegible] was a decrease in the amount of [illegible] foreign body giant cell lining of the [illegible] an increase in the amount of bone [illegible] screw (Figure 1). There was [illegible] decrease in inflammatory cells [illegible] thread silhouette and the cell[illegible] bone marrow decreased somewhat [illegible]

The progression in the [illegible] screws by the rabbits [illegible] involved only a moderate [illegible] syncytial giant cells and foreign [illegible] cells. The amount of bone did [illegible] not to the extent as in the controls [illegible] the inflammatory cells [illegible] eosinophilic staining cells increased [illegible] and necrosis became evident

It is evident from these data [illegible] group sacrificed at 3 weeks there [illegible] difference between the [illegible] immunized groups except that [illegible] injected group did have [illegible] foreign body giant cells with [illegible] cent) sections receiving a score [illegible] 2σ above the control. [illegible] syncytial cell lining typical [illegible]



[Fig]ure 1 The progression in the histologic [respon]se to the bone screws showed increased bone [forma]tion from (A) 3 weeks to (B) 9 weeks and (C) [16 we]eks

the development of foreign body type [giant] cells as seen more frequently in the [nicke]l injected animals. The bone marrow of [the n]ickel injected animals seemed to be more [infiltrat]ed with inflammatory cells, however, [both] the control and the injected animals had [high]ly cellular bone marrows. One injected [anima]l showed a small cystic-necrotic area



Figure 2 The major tissue-screw interface in the 3 week control rabbits (A) was formed by the multinucleated syncytial cell while the $NiCl_2$ injected group (B) showed a lining of multinucleated cells with inflammatory or foreign body reaction

By 9 weeks, more differences between the groups were evident Compared with the controls, the injected group showed an increase in the foreign body giant cells with 11/17 (65 per cent) of the sections having scores greater than 2σ above the mean for the controls, a marked increase in inflammatory cells with the average and 16/17 (94 per cent) of the sections above 2σ above the controls, and a small increase in eosinophilic cells with 3/17 (17 per cent) sections greater than 2σ above the controls Figure 3 depicts an interface lining of the inflammatory cells in the nickel injected group compared to bone formation in the control group In the nickel injected group, the bone marrow was more cellular with inflammatory cells than in the controls, as shown in Figure 4

At 16 weeks, the nickel injected group, compared to the controls, showed an increase





Figure 3 At 9 weeks the control rabbits (A) were forming bone at the tissue-screw interface while the rabbits injected with $NiCl_2$ (B) showed an inflammatory response





Figure 4 At 9 weeks the control [illegible] normal appearing bone [illegible] injected rabbits (B) had a very [illegible] with many inflammatory cells.

in the foreign body giant cells (average and 5/10 [50 per cent] sections above 2σ), in the inflammatory cells (average and 7/10 [70 per cent] sections above 2σ), and in eosinophils (average and 6/10 [60 per cent] sections above 2σ) The bone marrow still was cellular with inflammatory cells in the nickel injected group Two of the nickel injected rabbits had developed areas of necrosis.

Nonmigrators The evaluation of the animals injected with $NiCl_2$ included both those producing LIF and those that became nonmigrators. Comparison of the nonmigrators with those sensitized animals still showing cell migration revealed some differences. There tended to be an increase in foreign body giant cells and a decrease in eosinophils in the nonmigrators compared to animals only producing LIF These differences were not significant However, necrotic reactions were seen only in the [illegible] weeks, this involved small area [illegible] of the screw thread [illegible] necrotic reaction was seen in a [illegible] migrator who had developed a [illegible] with giant cells budding [illegible] tissue layer with necrotic [illegible] screw thread silhouette [illegible] the screw-tissue interface [illegible] shown in Figure 5

DISCUSSION

The choice of an animal [illegible] problem in human medicine [illegible] The guinea pig has [illegible] animal of choice for [illegible] and has been studied [illegible] excellent model for [illegible] sitivity and contact [illegible]



This was the most severe necrotic reaction and was seen in a 16-week $NiCl_2$ injected he tissue-screw interface (A) shows large ecrosis with higher power (B) revealing the thread form with giant cells in the necrotic other giant cells budding into the area

However, it would appear that the pig can be sensitized to nickel only eat difficulty if at all (Turk & Parker Furthermore the guinea pig has not as a model for orthopedic surgery e human population has a significant e of nickel sensitivity of 11–13 per patients being tested for dermatitis et al 1973, 1975) it was decided to the problems of nickel sensitivity in animal which was also good for dic studies It would appear from the presented here that the rabbit can s an excellent model for hypersen- It would also appear that the LIF l skin test are well correlated with the n of the one out of 13 uninjected who gave a positive skin test and no

The situation of no cell migration was a surprising finding when it was first observed in the clinical study (Brown et al. 1976b) The test result of no migration would usually be interpreted to mean that the test had not worked However, in both the clinical and rabbit studies, other tests performed the same day and with the same reagents have shown good migration Furthermore, these same patients or animals have repeatedly demonstrated no cell migration Thus we do not believe the condition is an indication of a bad test Cell viability studies using trypan blue exclusion have not revealed any differences in either the human or the animal studies between those showing good migration and those showing no cell migration We have hypothesized that the condition of no migration indicates that the lymphocytes have been challenged by the antigenic nickel protein complexes from the implant site, and that the result is indicative of an individual being sensitive and reacting to the implant Normal cell migration has returned in the human patients following removal of the implant (Brown et al 1976b, Merritt et al 1979a, 1979b)

The histologic reaction to the screws in the uninjected animals was quite consistent from animal to animal and was typical of the normal reaction to an inert foreign body Thus it was possible to determine mean and standard deviation values for the cell populations seen in these control animals The tissue reaction of the injected animals was more varied In these animals the histologic evaluation revealed changes typical of a host defense reaction There was a change from syncytial giant cells to inflammatory cells, with some animals developing foreign body giant cells and necrotic areas The variation in the cellular reaction in these sensitized animals, which may have been due in part to the variation in the response to the nickel injections made it difficult to treat them as a group The standard deviation of the histologic evaluation in the sensitized animals was, not surprisingly, much greater than that

for the controls. In no category would 2 standard deviations of the mean for the sensitized animals fall above or below 2 standard deviations for the control animals. Nevertheless, many differences were evident between the groups with many of the sensitized animals having histologic evaluations greater than 2σ above the mean for the controls.

The reaction depicted in Figure 5 shows the worst reaction we have seen to date, with a large necrotic area in the medullary area of the screw thread silhouette. This and several other severe necrotic reactions were associated with the condition of no cell migration in the LIF test. It is well known that ions are released by implants *in vivo* (Laing et al. 1967), and it is hypothesized that these severe necrotic reactions are the manifestation of a positive deep tissue reaction to nickel being released, and that the condition of no migration is diagnostic for the reaction. A small cystic-necrotic area was seen in one 3 week, LIF producing animal. While this animal had not become a nonmigrator, it is possible that this reaction is indicative of the development of a sensitivity reaction to the metallic implant.

The sequence of events would appear to be that the sensitive animals develop an increased reaction to the implant as evidenced by the histologic examination. When the reaction becomes severe to the point of having necrotic areas, then systemic change such as the modification of normal leukocyte migration is detected by the LIF test.

This study would seem to document that a sensitized animal can react to the presence of an implant. The development of the reaction is slow, probably because of the necessity for the screw to begin undergoing processes such as abrasion or corrosion leading to the release of sufficient ions to stimulate the sensitized cells. As we will report subsequently in more detail, we have observed that electropolished 316 LVM implants are negative to the dimethylgloxime (DMG) test (Fisher 1977), but are positive to DMG after being subjected to an electrochemical corrosion procedure. We have also observed [illegible] tests in clinically retrieved [illegible] available nickel on the implant [illegible] result of the *in vivo* corros[illegible]. Thus, it is reasonable to hypothes[illegible] reaction would probably not [illegible] terms of pain, swelling or [illegible] device in the human population [illegible] after implantation.

This study has addressed the [illegible] metallic implant in a sensitized [illegible] does not address the ability of [illegible] cause sensitivity, nor does it [illegible] question of allergy developing [illegible] implant has been in place for [illegible]. The histologic reaction may be [illegible] the time sequence certainly [illegible] prolonged in these conditions.

The histologic evaluation [illegible] the interface tissue lining the [illegible] appears to be soft and fragile [illegible]. The preservation of this [illegible] embedding in methylmethacryl[illegible] removal of the implant is of [illegible] portance in evaluating the [illegible] response to implants. Removal of [illegible] after fixation but prior to embedding [illegible] remove much of the actual [illegible]. Laboratories not equipped with [illegible] capable of cutting metals or [illegible] chemically dissolve the implant [illegible] sectioning (Brown & Simpson [illegible]

CONCLUSION

These studies demonstrate that the [illegible] a good model for studying [illegible]. The results of the LIF test and the [illegible] show good correlation. The [illegible] the implanted stainless steel [illegible] increased in the nickel sensitive [illegible] the most severe reactions [illegible] animals which had developed the [illegible] nonmigration. This study demonstrates [illegible] potential of the LIF test as a [illegible] method for repeated testing for [illegible]

ACKNOWLEDGMENTS

The authors wish to thank Dr [illegible] and Dr H. C. Fr[illegible] [illegible]

o perform this research at the ...num fur Experimental Chirurgie, ...isches Forschungsinstitut, Davos Platz, Straumann, Waldenburg, Switzerland ...ially thank Katie Ruesser and the other of the histology group for preparation of ...es We also thank Hansjorg Hoch for his assistance and Dr J Simpson for doing ...c absorption studies. We are indebted to ...phinais and Dr Michael B Mayor of ...h Medical School for their help in this ...e research was funded in part by the Foundation through the Lab fur Exp ..., Inst Straumann, Educational Founda- America, and USPHS grant AMAI AI

...ENCES

H., Spitler, L E, Frick, O L & ...iberg, H H (1973) Human leukocyte ...tion inhibition in agarose, using four ...ns – correlation with skin reactivity *J ...nol* 110, 1174–1179

..., V P & Soloman, H (1972) Eczematous ...itis from nickel *J Amer med Ass* ...1244

M K. D, Goodwin, P G & Boostoff, J ...) Metal sensitivity in patients with joint ...cement arthroplasties. *Brit med J* 4, ...375

...S A, Mayor, M B & Merritt, K (1976a) ...on as an alternative to wire for ...anteric osteotomy Presented at Second ...al Meeting of Biomaterials Society

S A, Shafer, J W, Mayor, M B & ...itt, K (1976b) Leukocyte migration in ...on test for metal sensitivity Presented at ...el University, 1976 – Problems in ...mpatibility

S A & Simpson, J (1979) ...rochemical dissolution of metallic ...ints prior to histologic sectioning *J ...ed Mater Res* 13, 337–338

... J E (1971) Tuberculin induced ...ation inhibition of human peripheral ...cytes in agarose and medium *Acta allerg* ...6–80

..., M & Lucht, L (1977) Metal sensitivity ...atients treated for tibial fractures with ...s of stainless steel *Acta orthop scand.* 48, ...-249

...n, R, Mulder, T J, Brian R & Nater, (1977) Metal sensitivity before and after hip arthroplasty *J Bone Jt Surg* 59-A ...865

Elves, M W, Wilson, J N, Scales, J T & Kemp, H B S (1975) Incidence of metal sensitivity in patients with total joint replacements. *Brit med J* 4, 376–378

Evans, E M, Freeman, M A. R, *Miller, A J &* Vernon Roberts, B (1974) Metal sensitivity as a cause of bone necrosis and loosening of the prosthesis in total joint replacement *J Bone Jt Surg* 56-B, 626–642

Fisher, A A. (1973) *Contact dermatitis*, 2nd Edition, Lea and Febiger

Fisher, A A. (1977) Allergic dermatitis presumably due to metallic foreign bodies contain- ... 19, 285–286

...

Res 1, 135–149

McKenzie, A W, Aitken, C V E & Risdill-Smith, R (1967) Urticaria after insertion of Smith-Petersen vitallium nail *Brit med J* 4, 36

Meneghini, C L & Angelini, G (1977) Behaviour of contact allergy and new sensitivities on subsequent patch tests. *Contact Dermatitis* 3, 138–142

Merritt, K, Mayor, M B & Brown, S A (1970a) Evaluation of sensitivity to metallic implants. *Evaluation of biomaterials* (Ed. Winter, G D, Leray, J & deGroot, K.) John Wiley, London (In press)

Merritt, K, Mayor, M B & Brown, S A (1979b) ...

Per... results of evaluation of early tissue reaction to implantation of metals. *Evaluation of biomaterials* (Ed Winter, G D, Leray, J & ...

Pol...

pounds. *Progr Allergy* ...

Rudner, E J, et al (1973) Epidemiology of contact dermatitis in North America, 1972. *Arch Dermatol* 108, 537–540

Rudner, E J, et al (1975) The frequency of contact sensitivity in North America, 1972–1974 *Contact Dermatitis* 1, 277–280

Rocklin, R E & David, J R (1976) Chapter 5 Introduction *Manual of clinical immunology*, American Society for Microbiology, Washington, D C

Turk, J L & Parker, D (1977) Sensitization with Cr, Ni, and Zr salts and allergenic type granuloma formation in the guinea pig *J invest Derm* 68, 341–345

...ondence to Department of Surgery, HB 7850, Dartmouth Medical School, Hanover, NH 03755,

iop scand. 51, 413–420, 1980

˙EFFECT OF DRINKING WATER FLUORIDATION ˙HE FLUORIDE CONTENT, STRENGTH AND ERAL DENSITY OF HUMAN BONE

ALHAVA[1] H OLKKONEN[2], P KAURANEN[3] & TARJA KARI[1]

ment of Surgery[1], University Central Hospital of Kuopio and Departments of Physics[2] and ˙try[3], University of Kuopio, Kuopio, Finland.

The effect of drinking water fluoridation on the fluoride content of human bone, on cancellous bone strength and on the mineral density of bone was studied by analysing 158 autopsy samples of the anterior iliac crest from persons from two different areas. In the samples from the town of Kuopio, where drinking water has been fluoridated since 1959 the fluoride concentrations were considerably higher than in samples from the surrounding area where low-fluoride drinking water is used The fluoride content of bones from Kuopio increased significantly with age, while considerably less change with age was found in samples from outside Kuopio The highest fluoride content in bone ash was observed in women with severe osteoporosis.

Cancellous bone strength measured by a strain transducer was statistically significantly higher in women with chronic immobilizing disease from Kuopio, compared with the corresponding group from outside Kuopio No statistically significant differences in bone strength were found in men There were no statistically significant differences in bone mineral density, as measured by gamma ray attenuation, between the samples from the fluoridated and non fluoridated areas

Key words bone mineral density, bone strength, fluoride, osteoporosis

Accepted 7 ix 79

ing water fluoridation has been carried n many communities for the prevention ental caries. The effects of the fluoride ˙nt of drinking water on bone have been ed by several authors (Blayney et al , Jackson & Weidman 1958) It has been ˙n that the amount of fluoride in bone nds on the fluoride content of the ing water and that it increases with age kin et al. 1960) However, there is no ˙nce that the generally recommended tion of 1 ppm of fluoride to drinking r causes skeletal diseases (Geever et al 1971, Kotms 1969). On the other hand a massive intake of fluoride, as in areas with endemic fluorosis, has a deleterious effect on the skeleton Fluoride is also used in the treatment of osteoporosis (Cass et al 1966, Chlud 1977, Franke et al 1974, Hansson & Roos 1976, Jowsey et al 1972, Kruse et al 1978, Rich & Ivanovich 1965), but its usefulness is still disputed (Inkovaara et al 1975)

Kuopio, the largest town in the North Savo area, is so far the only locality in Finland employing drinking water fluoridation (since

-4470/80/030413–08$02.50/0

1959). On the other hand, the waters of the surrounding communities have a low natural fluoride content: according to Korhonen et al. (1975) the average is below 0.1 ppm and the range is from 0.02 to 0.32 ppm. The fluoride content of tap water in Kuopio was found in the same investigation to be 0.97 ± 0.02 ppm.

The purpose of the present work was to study the effect of long-term fluoridation of drinking water on the fluoride content of human bone, mineral density of bone and cancellous bone strength. The work was based on cadaver samples from donors from the town of Kuopio and the surrounding areas.

MATERIALS AND METHODS

The bone material. Bone samples were obtained from autopsies of 66 women and 92 men. There were 36 females and 69 males who had died suddenly due to acute coronary artery disease or accidents. In 30 women and 23 men the cause of death was a chronic immobilizing disease for which they had been treated in institutions for chronically ill patients.

Fifty three of the cases, 28 women and 25 men had been residents in Kuopio from the beginning of fluoridation (14–18 years). The rural non fluoridated material consisted of 38 women and 67 men.

Bone specimens, about 40 mm long and 10 mm thick containing both cortical and cancellous bone were taken by saw at autopsy from the anterior iliac crest and fixed in 40 per cent ethyl alcohol. The samples were collected between 1973 and 1978.

Determination of fluoride. The bone specimens were taken from the preservation solution and dried gently with soft tissue. Three types of samples were taken for analysis (Figure 1).

1. "Mixed bone sample". About one-third to one-half of the lower end was cut off from each specimen and taken for analysis. The average ash weight of these samples was about 450 mg.
2. "Cortical bone sample". A small piece of hard bone was cut from the upper end of the specimens. The average ash weight of these samples was 38 mg.
3. "Cancellous bone sample". About 4 mm × 4 mm of cancellous bone was cut from the centre of

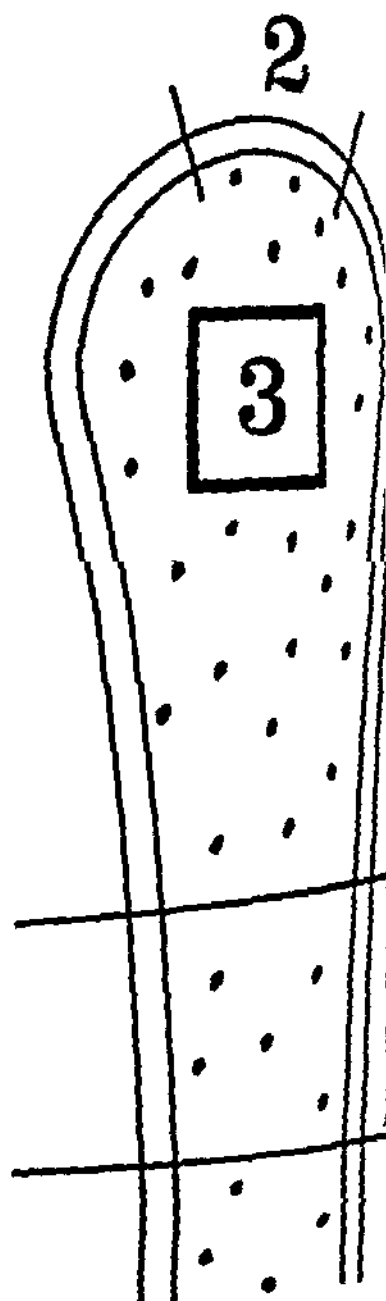


Figure 1. Three types of samples taken [illegible] iliac crest.

the upper end of the specimen [illegible] ash weight of these samples was [illegible]

The samples were transferred [illegible] porcelain crucibles and weighed [illegible] were covered, heated overnight at [illegible] 550 °C, cooled, and the percentage [illegible] determined. About 50 mg of ash was [illegible]

l samples for analysis The ashes of the ıd 3 samples were analysed *in toto*

luoride ion was determined with an ion electrode (ORION 94–09) In the earlier this study fluoride was separated from the ɩh by microdiffusion according to the re described by Kari et al (1976) Later, it ɔgnized that fluoride could be determined in the dissolved bone ash if the calcium complexed by an efficient enough com-agent e g citrate (Kauranen 1977) The h was dissolved in 1 ml of 4 M HNO_3 & Schnellman 1975), 10 ml of 5 M acetate l citrate buffer, pH 5, and 1 5 ml of 2 M was added. The solution was diluted to and the fluoride determined by the e Because the fluoride contents were y high, a constant potential of the e was generally reached in less than 5 min ration was performed by taking known s of standard sodium fluoride solution and g the same procedure The calibration line ear over the concentration range observed bone samples Reproducibility and recovery ested using the IAEA calcinated animal reference sample No A 3/1/1974 The fluoride recoveries were 99 6 per cent r-eight determinations of the fluoride of the IAEA sample yielded a value of n F with a standard deviation of 11 ppm, per cent

rement of cancellous bone strength ular bone compressive strength was ed with a strain transducer described by Koivisto et al (1976) The square wave from the transducer was fed to a frequency-age converter and the analogue voltage was ed with a transient recorder (Biomation 1015)

rement of bone mineral density Trabecular mineral density was measured with a cation of the gamma ray attenuation d (Cameron & Sorenson 1963) The bone ien was immersed in a water bath and a beam of 60 keV photons from a 45mCi source was passed through the water bath esults were calculated from the equations

$$BMD = a_0 + a_1 S + a_2 S^2,$$

$$S = \frac{1}{lK} \sum_{i=1}^{k} \ln(N_W / N_i)$$

ich BMD is the bone mineral density, a_0, a_1 , are constants and N_W and N_i the numbers of photons being transmitted through the water bath without and with the bone sample, respectively k is the number of measuring sites (8–12 in our case) and l the bone length in the direction of the beam The constants a_0, a_1 and a_2 were obtained experimentally by determining the bone mineral density by ashing 28 specimens, and by fitting a second degree polynomial to the calculated S-values

Absorptiometry gives more reproducible results than ash content/volume determination, since every result was averaged over samples from 8–12 sites in the area of cancellous bone Due to the porosity of the trabecular bone, volume determinations are not accurate (Momeni et al 1976) (Details of the procedure are available from the authors.)

RESULTS

Fluoride content of bone The fluoride content of bone ash as a function of age is shown in Figure 2 The more rapid accumulation of fluoride in the bones of subjects living in the fluoridated area compared with the non-fluoridated area is evident The difference in the slope of the regression lines is statistically highly significant ($P < 0\,001$) The slope for the samples from women from Kuopio is also steeper than the corresponding slope for men ($P < 0\,001$) The scatter of the fluoride content is particularly large for the samples from women from Kuopio There was no difference in the fluoride content of samples from cases of sudden death and death following chronic im-mobilizing disease in either sex in or outside Kuopio (Figure 2) The highest fluoride contents were associated with low ash contents. The average ash and fluoride contents for three types of bone samples are given in Table 1

Cancellous bone strength and mineral density The bone strength of subjects as a function of age is presented in Figure 3. The trabecular bone strength and mineral density of samples from subjects aged over 45 are shown in Table 2 Younger cases were excluded from the com-parison due to the relatively small amount of fluoride in bone in the fluoridated area (Figure 2) Female and male subjects were analysed in

1959) On the other hand the waters of the surrounding communities have a low natural fluoride content according to Korhonen et al (1975) the average is below 0 1 ppm and the range is from 0 02 to 0 32 ppm The fluoride content of tap water in Kuopio was found in the same investigation to be 0 97 ± 0 02 ppm

The purpose of the present work was to study the effect of long term fluoridation of drinking water on the fluoride content of human bone mineral density of bone and cancellous bone strength The work was based on cadaver samples from donors from the town of Kuopio and the surrounding areas

MATERIALS AND METHODS

The bone material Bone samples were obtained from autopsies of 66 women and 92 men There were 36 females and 69 males who had died suddenly due to acute coronary artery disease or accidents In 30 women and 23 men the cause of death was a chronic immobilizing disease for which they had been treated in institutions for chronically ill patients.

Fifty three of the cases, 28 women and 25 men had been residents in Kuopio from the beginning of fluoridation (14–18 years) The rural non fluoridated material consisted of 38 women and 67 men

Bone specimens about 40 mm long and 10 mm thick containing both cortical and cancellous bone were taken by saw at autopsy from the anterior iliac crest and fixed in 40 per cent ethyl alcohol The samples were collected between 1973 and 1978

Determination of fluoride The bone specimens were taken from the preservation solution and dried gently with soft tissue Three types of samples were taken for analysis (Figure 1)

1 Mixed bone sample About one-third to one-half of the lower end was cut off from each specimen and taken for analysis The average ash weight of these samples was about 450 mg
2 Cortical bone sample A small piece of hard bone was cut from the upper end of the specimens The average ash weight of these samples was 38 mg
3 Cancellous bone sample About 4 mm × 4 mm of cancellous bone was cut from the centre of

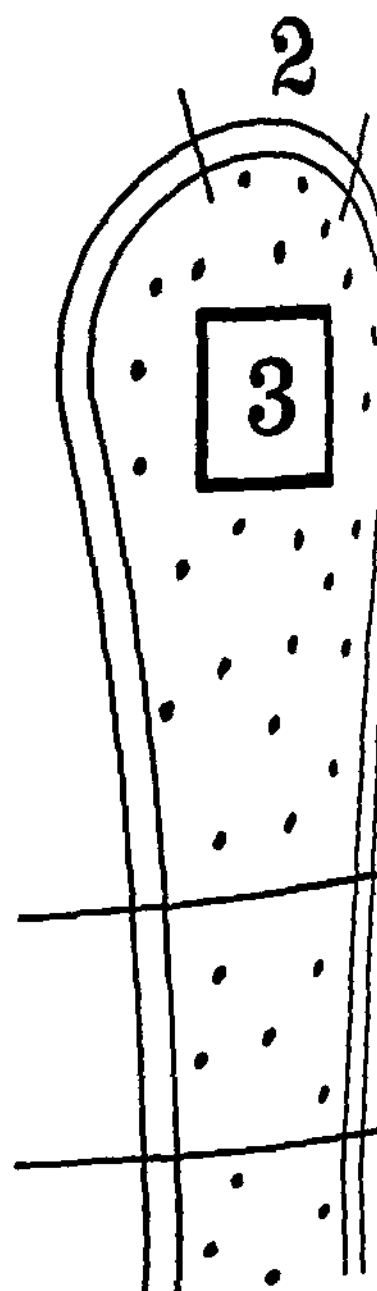


Figure 1 Three types of samples take[n] iliac crest

the upper end of the specimens Th ash weight of these samples was 24 m

The samples were transferred porcelain crucibles and weighed The were covered heated overnight in a muffl 550 °C cooled and the percentage of determined About 50 mg of ash was

Table 1 Average ash and fluoride contents of bone specimens from which three types of samples were analysed The range of results is given in parentheses m=slope of linear regression, r=correlation coefficient of bone fluoride content on age N=number of specimens analysed

	From Kuopio						Outside Kuopio					
	N	Age	Ash (%)	F (ppm)	m	r	N	Age	Ash (%)	F (ppm)	m	r
Women												
Cancellous bone	24	68 6 (44–85)	19 3 (7 3–36 1)	2070* (759–4140)	44 1	0 488	23	64 4 (31–92)	18 9 (8 2–35 5)	622 (283–1500)	11 6	0 582
Cortical bone	24	68 6 (44–85)	35 6 (14 6–51 5)	1720* (621–3620)	32 0	0 345	23	64 4 (31–92)	38 5 (12 9–59 4)	443 (214–745)	4 73	0 443
"Total" bone	24	68 6 (44–85)	29 0 (17 0–43 6)	1280* (399–2360)	26 1	0 599	23	64 4 (31–92)	27 6 (13 4–43 6)	384 (144–790)	5 43	0 621
Men												
Cancellous bone	14	56 4 (24–86)	26 3 (14 2–41 2)	1360 (804–2360)	17 4	0 658	17	52 6 (20–86)	24 7 (13 8–36 8)	447 (142–735)	3 28	0 340
Cortical bone	14	56 4 (24–86)	46 1 (35 4–55 7)	1290 (660–2740)	22 7	0 737	17	52 6 (20–86)	41 4 (25 1–58 2)	462 (150–769)	3 56	0 429
"Total" bone	14	56 4 (24–86)	29 5 (20 2–37 5)	901 (347–1980)	18 2	0 769	17	52 6 (20–86)	29 6 (20 0–53 5)	319 (106–539)	3 33	0 769

*One exceptionally low case omitted from range values

Table 2 Trabecular bone strength and mineral density (± 1 SD) in subjects over [illegible]

	From Kuopio	From outside Kuopio	Difference %	[illegible]
Females, sudden death				
Number of cases	8	13		
Age (years)	66 4 ± 4 3	65 5 ± 2 9		N
Bone strength ($10^6 N/m^2$)	9 06 ± 0 50	8 29 ± 0 41	+ 9.2	P<0
Bone mineral density (kg/m^3)	234 ± 17	218 ± 27	+ 7.3	N
Females, chronic disease				
Number of cases	13	11		
Age (years)	69 1 ± 2 6	65 4 ± 2.9		N
Bone strength ($10^6 N/m^2$)	8 85 ± 0 57	7 62 ± 0.29	+ 16.1	P<
Bone mineral density (kg/m^3)	211 ± 13	191 ± 22	+ 10 5	N
Males, sudden death				
Number of cases	11	33		N
Age (years)	63 8 ± 2.8	60 4 ± 1 7		N
Bone strength ($10^6 N/m^2$)	9 69 ± 0 60	10 40 ± 0 34	− 6 8	N
Bone mineral density (kg/m^3)	232 ± 9	239 ± 6	− 2.9	
Males, chronic disease				
Number of cases	5	10		N
Age (years)	54 6 ± 3 4	61 5 ± 2 7		N
Bone strength ($10^6 N/m^2$)	9 10 ± 0 26	9 36 ± 0 52	− 2 8	N
Bone mineral density (kg/m^3)	212 ± 8	205 ± 10	+ 3 4	

disease, the trabecular bone strength was almost significantly higher in cases from Kuopio compared with cases from outside Kuopio The trabecular bone mineral density was 7 3 per cent and 10 5 per cent higher, respectively However, due to large variations, the differences are not statistically significant No statistically significant differences in bone strength and mineral density were found between the corresponding male groups

DISCUSSION

There is a loss of bone mineral in chronic diseases that cause physical inactivity The disease itself, such as chronic renal failure, alcoholism, diabetes mellitus, may for one reason or another have a rarefying effect on the skeleton (Wheeler 1976) We believe that our rough division of patients into two [illegible] chronic immobilizing disease and [illegible] death, separates the osteoporotics fr[illegible] cases with a normal mineral status.

In osteoporosis bone resorption is [illegible] in relation to new bone formation. Fluor[illegible] transforms hydroxyapatite to fluor[illegible] (Posner et al 1963) which is more resis[illegible] resorption than normal hydroxyapatite [illegible] tein & Cohen 1967) Moreover [illegible] activates osteoblasts (Jowsey et al 1968) [illegible] been shown in animals treated with [illegible] and in humans with fluorosis that [illegible] seams thicken and mineralization is [illegible] resulting in denser bone tissue. Howev[illegible] kind of bone may have histological feat[illegible] osteomalacia, and its physical propert[illegible] be abnormal (Riggins et al 1974 [illegible] al 1974) Some human studies have sho[illegible] the tensile strength of bone seems to de[illegible] and the compressive strength to increa[illegible]

asing fluoride content of bone (Evans & 976, Franke et al 1976)

stein et al (1966) stated in their ological study that osteoporotic s were fewer in areas where the fluoride of the drinking water was high, ed with areas where is was low Korns could not confirm the beneficial effects of in the prevention of osteoporosis in his on artificial fluoridation of drinking Geever et al (1971) were unable to show ect of fluoridation at the 1 ppm level on stology

ound that the fluoride content of iliac ncreases steadily with age without g out at a higher age, as suggested by & Weidman (1958) It is possible to 18 years of fluoridation in Kuopio short a time for a plateau to be l The fluoride content of cancellous was generally greater than that of l bone, probably due to more active olism. This is in agreement with the t that fluoroapatite is more resistant to ion than hydroxyapatite

pite having consumed drinking water ation for less than 20 years, some cases in Kuopio had quite a high t of fluoride in bone (up to 4000 ppm cellous bone ash) It is possible that lifetime of fluoridation some women iopio may experience adverse effects luoride accumulation

question of the lower limit for a toxic le content in bone is still open Jackson eidman (1958) felt that levels above ppm of fluoride in fat-free dry cortical should be considered toxic. Riggins et 74) were of the opinion that a subject considered to have fluorosis when the ntration of fluoride in bone ash exceeds ppm.

physical parameters used in this study, one mineral density and cancellous bone th, did not show any significantly cial effects of fluoridation apart from evidence that fluoridation may preserve al density and bone strength better in n with chronic immobilizing diseases compared with women from the non-fluoridated area This effect was not seen in men, but the comparison between men of rural and urban populations is difficult because of the difference in bone density between these populations (Helela 1969)

REFERENCES

Bernstein, D S, Sadowsky, N, Hegsted D M, Guri, C D & Stare, F J (1966) Prevalence of osteoporosis in high- and low-fluoride areas in North Dakota *J Amer med Ass* **198**, 85–90

Bernstein, D S & Cohen P (1967) Use of sodium fluoride in the treatment of osteoporosis. *J clin Endocr* **27**, 197–210

Blayney, J R, Bowers, R C & Zimmerman, M (1962) A study of fluoride deposition in bone. *J dent Res* **41**, 1037–1044

Cameron J R & Sorenson, J A (1963) Measurement of bone mineral *in vivo* An improved method *Science* **142**, 230–232

Cass, R M, Croft, J D Jr, Perkins, P., Nye, W., Waterhouse, C & Terry, R (1966) New bone formation in osteoporosis following treatment with sodium fluoride *Arch intern. Med* **118**, 111–122

[illegible]

properties and density of bone in a case of severe endemic fluorosis *Acta orthop scand* **47**, 489–495

[illegible]

Wanka C & Rempel, [illegible] Physical properties of fluorosis bone *Acta orthop scand* **47**, 20–27

Geever E F, McCann, H G, McClure F J, Lee, W A. & Schiffmann, E. (1971) Fluoridated water skeletal structure and chemistry *HSMHA Health Reports* **86**, 820–828

Hansson, T & Roos, B (1976) Effect of combined therapy with sodium fluoride, calcium and vitamin D on the lumbar spine in osteoporosis. *Amer J Roentgenol* **126**, 1294–1296

Helela, T (1969) Variations in thickness of cortical bones in two populations. *Ann Clin Res* **1**, 227–231

Inkovaara, J, Heikinheimo, R., Jarvinen, K.,

Kasurinen U, Hanhijärvi, H & Iisalo, E (1975) Prophylactic fluoride treatment and aged bones *Brit med J* **3**, 73–74

Jackson, D & Weidman, S M (1958) Fluorine in human bone related to age and the water supply of different regions *J Path Bact* **76**, 451–459

Jowsey, J, Schenk, R K & Reutter, R W (1968) Some results of the effect of fluoride on bone tissue in osteoporosis *J clin Endocr* **28**, 869–874

Jowsey, J, Riggs, B L, Kelly, P J & Hoffman D L (1972) Effect of combined therapy with sodium fluoride, vitamin D and calcium in osteoporosis *Amer J Med* **53**, 43–49

Kari, T, Kauranen, P & Alhava, E (1976) Effect of drinking water fluoridation on the fluoride content of human bone in and around Kuopio Central Finland An analytical study Publications of the University of Kuopio Community Health, Series Original Reports 1

Kauranen, P (1977) The use of buffers in the determination of fluoride by an ion-selective electrode at low concentrations and in the presence of aluminium *Analytical Letters* **10**, 451–465

Korhonen L, Kari T, Puittinen, J, Alhava, E & Olkkonen, H (1975) Fluoridin esiintyminen juomavedessa Kuopion laanin alueela *Ympäristo ja Terveys* **6**, 787–788

Korns, R F (1969) Relationship of water fluoridation to bone density in two N Y towns. *Publ Hlth Rep (Wash)* **84**, 815–825

Kruse, H-P, Kuhlencordt, F & Ringe, J-D (1978) Ergebnisse einer Langzeittherapie der primaren Osteoporose mit [illegible] *Dtsch med Wschr* **103**, 248 252

Momeni, M H, Jow N, Bradley E & [illegible] P (1976) Measurement of bone density [illegible] displacement *Bio med Engng* **11**, 211 [illegible]

Nokso-Koivisto V-M, Alhava, E & Olkkonen, H (1976) Measurement [illegible] cancellous bone strength, [illegible] mineral density ageing and disease *[illegible] Res* **8**, 399–402

Posner, A S, Eanes, E D Harper R & Zipkin, I (1963) X ray diffraction [illegible] the effect of fluoride on human bone [illegible] *Arch oral Biol* **8**, 549–570

Rich C & Ivanovich P (1965) Response [illegible] sodium fluoride in severe primary osteo[illegible] *Ann intern Med* **63**, 1069 1074

Riggins R S, Zeman F & Moon D [illegible] effects of sodium fluoride on bone [illegible] strength *Calcif Tiss Res* **14**, 283–[illegible]

Wheeler, M (1976) Osteoporosis. *Med Clin Amer* **60**, 1213–1224

Yamamoto, K, Wergedal J E & Baylink [illegible] (1974) Increased bone microhardness [illegible] fluoride treated rats. *Calcif Tiss Res* [illegible] 45–54

Zipkin I, McClure F J & Lee W [illegible] Relation of the fluoride content of human [illegible] to its chemical composition *Arch oral Biol* [illegible] 190–195

Zober A & Schnellmann, B [illegible] Fluoridbestimmung in Knochenproben [illegible] menschlichen Beckenkamm mit ionenselektiven Elektrode *Z klin Chem* [illegible] 197–201

Correspondence to Esko Alhava, M D, Department of Surgery University Central Hospital [illegible] Kuopio 21, Finland

›p scand 51, 421–428, 1980

NTERNAL STRESS PATTERN
IE OS COXAE

HOLM

lic Hospital, Århus, and The Department of Orthopaedic Surgery T–2,
Hospital, Hellerup, Denmark

The stress pattern of the os coxae was evaluated from the trabecular patterns and the theoretically predicted stresses based on the principles of Wolff's law A good correlation between the expected stress situation and the trabecular pattern was observed

Key words hip, os coxae, stress, trabecular pattern

Accepted 26 ix 79

ertion of joint prostheses into the hip as during the last 10 to 15 years an established procedure The n of an acetabular component which, parison with the bone, is a stiff foreign rough which the load on the hip is to smitted, must be expected to change ess pattern in the pelvis, thereby ng remodeling of the bone Increasing is with loose acetabular components e foreseen It is the author's opinion modeling of the bone may play a role ning of the acetabular components. As oduction to an investigation of this n an analysis of the normal stress in the pelvis is essential In the ng an evaluation of the normal stresses made based on the anatomy and the loads on the hip joint Benninghoff examined the split lines on the surface decalcified pelvis, but to the author's dge a more thorough evaluation of the d bony structure of the pelvis has not nade A greater knowledge of the stress is inside the pelvis is necessary if the fixation of acetabular components is to be improved

MATERIAL AND METHODS

For the examination of the internal structure eight os coxae were used The sacrum is not included in the investigation The bones were prepared as dry osteological specimens and were sawn through either in a plane with a band saw or following the curvature of the bone which may be done with an ordinary jigsaw The lines of section are shown in Figure 1 Only the thin central area in the ala ossis ilei could not be prepared so that a distinct structure of the spongiosa was discernible

Firstly, the patterns of the spongiosa will be described secondly, the stress patterns that are to be expected from the shape and the load on the bone will be evaluated and thirdly, the structure of the spongiosa will be evaluated in the light of the expected stress patterns.

In the drawings compressive stresses are shown as full lines while tension stresses are shown as broken lines. It was not possible to demonstrate all trabecular patterns in a single section and accordingly Figures 5 and 7 are composite pictures demonstrating the characteristic patterns. The trabecular patterns are also shown in Figures 2, 3,

170.80.030421–08$02.50 0



Figure 1 Directions of the sections through the os coxae for the evaluation of the trabecular patterns

and 4 The most illustrative section was made

the bony pattern around the acetabulum.

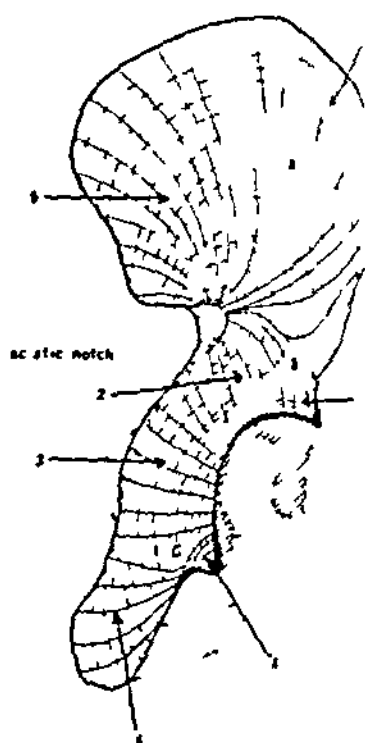


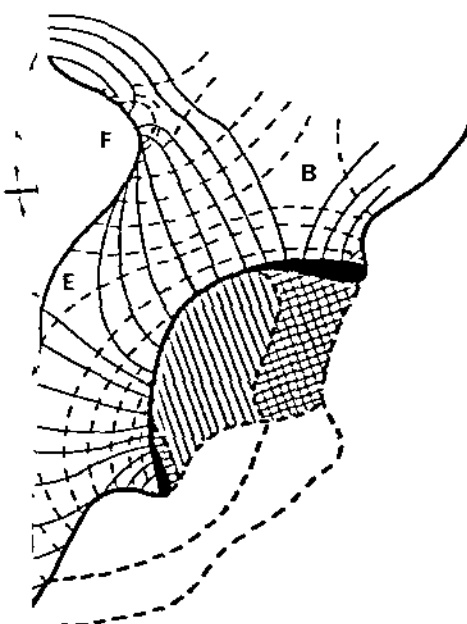
Figure 2 Drawing representing the patterns of the os coxae interpreted as trajectories Full lines represent compressive ... broken lines represent tensile stress. The ... made through the center of the ... surface at an angle of 45° to the ... and shows the patterns found in the ... marked 1 through 4 in Figure 1

RESULTS

Anatomical findings

The first thing to be noted is the regular trabecular pattern with two sets of trabeculae arranged at right angles to each other These two sets of trabeculae will be described separately In the area under the acetabular joint surface the trabeculae were seen to emerge in a radiating pattern. Anteriorly these trabeculae that arise from the most anterior 1 cm of the acetabulum run along the corticalis in the anterior part of the os ilei towards the inferior anterior iliac spine Proximally to this they join the corticalis at an acute angle (area 1 in Figure 2) In the superior part of the joint surface the trabeculae also radiate but they soon bend posteriorly proximally so that they point towards the sacro-iliac joint (Deep to area 1 not shown in the figure) Further back the trabulae become thicker and converge towards the sciatic notch (area 2) Distal to the sciatic notch the trabeculae run directly to the posterior corticalis which they meet at a right angle (area 3) In the most distal part of the acetabulum corresponding to the os ischii the trabeculae first traverse the ... trusion which supports the distal ... joint surface and then fan out towards ... ticalis of the posterior aspect of the ... which is reached at a right angle (area ...) Proximal to the sciatic notch the trabe... fan out In this area they are ... structure is not always easy to define ... point towards the joint surface of the ... joint (area 6) The trabecular system ... forward at right angles to the ilia... way to the anterior superior iliac spine ...

In the area deep to the ... described section the pattern ... certain changes. At this level, ... Figure 1 the section goes through the ... the joint surface The drawing of the ... is found in Figure 3 and a photograph ... bone is seen in Figure 6. In this ...



3 *Drawing representing the trabecular of the os coxae in the deep part of the ...um The section is made through the ...um corresponding to the line marked 2 in*

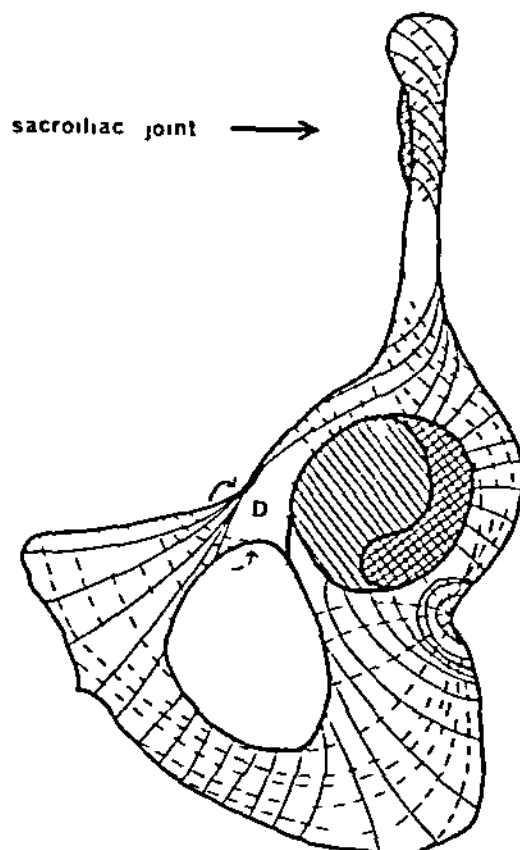


Figure 4 Drawing representing the trabecular pattern of the os coxae The section is made through the os pubis, the inferior rami and the acetabulum corresponding to the section marked 4 in Figure 1

...ae divide so that only the most ... part goes directly to the corticalis ... the acetabulum From the superior ... the surface the trabeculae run ... anterior and medial to the sciatic ...hich they pass with a slight swerve ... it and then continue towards the ...ac joint The patterns are not ... as some of the trabeculae enter the ... bone on the way and therefore cannot ...wed

...rabecular pattern in the inferior rami ... os pubis is shown in Figures 4 and 7 ...tioned above the trabeculae run ... the posterior surface of the proximal ... the tuber ischii, but further distally ...inge direction so that in the inferior ...y run across the bone In the pubic ...us trabecular system reaches the ... of the symphysis at right angles. In ...rior ramus of the pubic bone the ...ae run upwards in an increasingly ...ttern and at the root of the superior ramus they join the thick cortical bone found there In the ala ossis ilei this system of trabeculae is seen to curve into the external corticalis and from there to the sacro-iliac joint (Figure 4)

The second system of trabeculae run at right angles to the one just described They run concentrically around the acetabulum as a layer of thin shells which increase in thickness posteriorly where they run parallel to the corticalis (area 2, Figure 2) Proximally to this they run together around the sciatic notch in a 0 5 to 1 cm thick cortical structure which however retains its oriented nature as is seen when the section is stained with Indian ink More proximally at the level of the sacro-iliac



Figure 5 Composite photograph of trabecular patterns, corresponding to the drawing in Figure 2




Figure 6 Photograph of the trabecul... corresponding to Figure 3

joint these trabeculae fan out over the ala ossis ilei, finally running parallel to the iliac crest as far as the anterior edge of the pelvis which they meet at right angles. Centrally in the ala the bone is so thin that the spongiosa disappears so that no structure can be found there In the deeper section these trabeculae are seen to alter their course so that a point with a very thin trabecular structure appears just below the posterior cortex distal to the sciatic notch The reinforcement of the sciatic notch which at the center is condensed to cortical bone is at this level seen as an area of dense but separated trabeculae that form a small dome-shaped configuration The fact that this structure is seen at an angle accounts for the irregularity of the trabeculae The bone structure in this area is unusually complicated and in the preparations there was a thin area with loss of orientation of the structure at the point marked F Th... area distal to the sciatic notch is ...

Distally, in the tuber ischii the... fan out to form a gothic-arch pattern... first set of trabeculae and then cur... and medially into the inferior ram... Here they have a slightly spiral cour... pubic bone they turn upwards ... across it Closer to the acetabulum ... superior pubic ramus the course ... to spiral as they turn in under the ... superior ramus where they enter th... ticalis. At the acetabulum they ... as concentric lamellae.

Apart from the general pattern ... above certain areas consistently ... changes from the uniform ... trabeculae found elsewhere Concen... trabeculae into star-like configura... found in two places, although the



h 7 *Composite photograph of the trabecular ns corresponding to Figure 4*



Figure 8 Detail of trabecular pattern around the acetabulum

different The first is seen at the sciatic on Figure 2 and has been described The second is seen just inferior and rior to the acetabulum on Figure 4 In tructure the one system of trabeculae are letely concentric and the other has a ing configuration In addition to these s of concentrated trabeculae six points found of uniformly very thin trabeculae at the same time seemed to lose all tation The points are marked A through Figures 2, 3, and 4 Point A corresponds thin spot in the ala ossis ilei, point B is d at the proximal end of the acetabular ce and C at the distal end Point D is d at the base of the superior ramus of pubic bone where the trabeculae spiral d at right angles to each other going the corticalis at this point Points E and n be seen in Figure 3 The significance of points will be discussed further

Expected stress patterns

As a mechanical structure the pelvis may be considered to consist of four roughly triangular ring structures (Figure 9) Each half of the pelvis consists of two rings that support the acetabulum Each half of the pelvis is supported posteriorly by the sacrum and anteriorly they meet in the symphysis. The superior ring like structure is formed by the iliac bone The anterior part of the ring goes from the acetabulum along the anterior part of the iliac bone to the anterior superior iliac spine, the posterior part goes from the top of the acetabulum to the sacro-iliac joint and is the strongest structure in the pelvis. The third side of the ring is formed by the iliac crest This ring is closed by the squama The lower ring is formed by the pubic and ischial bones. It also supports the acetabulum



Figure 9 Antero lateral view of the pelvis The system of the two triangular "ring" structures is indicated

at the end of the facies semilunaris, but it is twisted 80–90° in relation to the superior ring (Figures 1 and 9) Both ring structures are twisted in themselves especially the distal one, as the symphysis is positioned at an angle of about 45° to the frontal plane These facts are of importance in a detailed analysis of the expected stresses in the pelvis It has been demonstrated by Greenwald & O'Connor (1971) that at loads that exceed 25–50 per cent of body weight there is total contact between the joint surfaces in the hip joint It will be seen from this that the transition between the various stress situations will be gradual and that in all positions of the hip, forces will be transmitted over the entire surface – except in the swing phase However, the direction of the resultant will vary and this is of importance in the determination of the stress pattern In the standing position the hip is loaded th[...] axis which goes from the sacro-il[...] distally – anteriorly to the top [...] acetabulum This axis has an [...] anteriorly of about 15° and also [...] (Debrunner 1975) depending on the [...] the pelvis and its tilt. The axis [...] quite closely with the commonly [...] resultant vector (Pauwels 1965 [...] 1975, Hamacher & Roesler 1977) [...] standing position the main force [...] directed towards the sacro-iliac [...] there will only be a modest bending [...] distal to the sciatic notch. In [...] however, the resultant will point [...] and there will be an increasing [...] moment as the lower part of the [...] is pressed backwards. Such a stress will give rise to compression on the posterior aspect of the tuber if [...] not counteracted in some way [...] bending force is checked by the infer[...] which in their turn hereby are p[...] tensile stress A further tensile force [...] loading of the hip in flexion will [...] the muscles that stabilize the pelvis [...] the hip (short postero-lateral muscles hamstrings, adductors). [...] tensile stresses will tend to pull the rami forwards thereby causing [...] stresses in the superior ramus of the bone This torsion causes compress[...] along the upper side and tension [...] underside of the ramus, both [...] spiraling pattern towards the anterior [...] of the acetabulum In extension the [...] transmit a larger amount of force [...] anterior part of the acetabulum [...] cause compression stress along the [...] part of the iliac bone and tensile stress [...] angles to this.

DISCUSSION

In the complete evaluation of the stress [...] tribution in the pelvis it is clear the [...] cortical bone plays a major part. The [...] experimental indications that a [...]

part of the actual load is transferred the corticalis (Dietschi 1978) This of loes not mean that the interior of the free of stress In the long bones there ly be a small change in the stress with movement as the forces are led ise through the bones regardless of ition of the joints Changes in the atterns will take place in the epiphysis s the major part of the bone will have ltered stress pattern In the pelvis, r, considerable changes in the force iust be expected depending on the n in which the pelvis is loaded As ed by Wolff (1892) and later confirmed eral authors, among others Pauwels and Kummer (1959), the trabecular re of the human skeleton is oriented ng to the directions of the principal s and may be considered to represent irse of the stress trajectories It should re be possible to analyze the trabecular re in the pelvis and from this to e the stress situation As described the acetabulum is in the loaded phase over its entire joint surface where the ge distributes the pressure The ng trabeculae around the joint may re be interpreted as representing com-'e stresses.

h this as a basis the drawings in s 2, 3, and 4 have been constructed drawings represent the trabecular is interpreted as compressive and stress trajectories As will be seen essive stresses are found along the or rim of the iliac bone Further back run towards the sacroiliac joint The ischii shows a gothic-arch pattern r to the one found in the femoral neck ding to Pauwels (1965) and Kummer l this indicates a bending moment The : trajectories continue along the inferior This means that the posterior aspect of icetabulum and the tuber may be ired to a curved beam which is fastened th ends and is loaded in compression its concave side This will cause a situation as shown in Figure 10 The

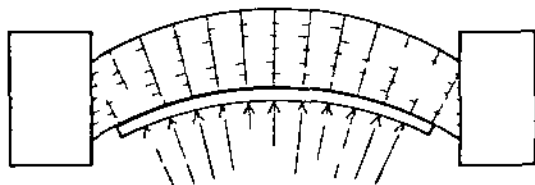


Figure 10 Stress pattern in a curved beam, loaded evenly along its concave surface

occurrence of spiraling compression and tension trabeculae at the base of the superior pubic ramus corresponds exactly to the stress distribution in a round bar loaded in torsion (Frost 1973) In the corpus ossis pubis the compression trabeculae arise from the symphysis in accordance with Pauwels' demonstration of the fact that the symphysis is loaded in compression during walking

The significance of the special points, here indicated by the letters A through F, is more complicated to evaluate The heavy structure at the sciatic notch would seem to indicate a reinforcement of the bone because of the convergence of the compression stresses at this point together with the effect of the bending moment which will be present during flexion of the hip The star-shaped configuration of the trabeculae just below the acetabulum in Figure 4 complies well with stress concentration at this point indicating a forward bending moment This is to be expected from the overall theoretical evaluation of the stresses given above The thin spots have a different significance The thin spot in the ala (point A) can be interpreted as representing an area with low stresses and with little bone needed to withstand them The most interesting points are those marked B, E, and F The configurations at these points have a striking likeness to repulsive singular points as described in textbooks on stress analysis (Pirard 1947, Wolf 1976) The presence and position of singular points cannot be predicted but must be confirmed by experiment Singular points may be divided into repulsive and attractive points Briefly, they may be described as points or areas where the stress has no distinct direction either because it is

nil or because it has the same value in all directions, it becomes "hydrostatic" Point C at the lower end of the acetabulum (Figure 2) is less clearly defined, but in some cases it also has a definite resemblance to a repulsive singular point Point D (Figure 4) clearly indicates a point of torsional stress where the interior of the bone is free of stress and the trabeculae wind around it in a spiraling fashion Point E must be seen as a repulsive singular point indicating an area of very low stress

The conclusion of the above would then be that the pelvic bones show a systematic pattern of trabeculae that corresponds well with the expected patterns of the theoretical stress trajectories as evaluated by an analysis of the shape of the bone and the forces working on it The patterns are much more complicated than in any other major bone

ACKNOWLEDGEMENTS

This work was supported by P Carl Petersens Fond and Rigsforeningen til Gigtens Bekaempelse to whom my gratitude is extended

REFERENCES

Benninghoff A (1925) Spaltlinien im K... eine Methode zur Ermittlung der ... platter Knochen *Verh anat Ges* ... 189–206

Debrunner H U (1975) Studien zur Biom... des Huftgelenkes I *Z Orthop* 113, ...

Dietschi C (1978) Zur Problematik ... kunstlichen Huftgelenkes Thesis University, Stuttgart

Frost H M (1973) *Orthopaedic* ... Vol V Charles C Thomas, Springfie...

Greenwald A S & O Connor J (19... transmission of load through the hu... joint *J Biomech* 4, 507 528

Hamacher P & Roesler H (1972) Ergebn... Berechnung von Grosse und Richt... Huftgelenkresultierenden im Einzelb... *orthop Unfall Chir* 72 94–106

Kummer B (1959) *Bauprinzip...* *Saugerskeletes* Thieme Stuttgart

Pauwels, F (1965) *Gesammelte Abhandlu... funktionellen Anatomie des Be... apparates* Springer Berlin

Wolff J (1892) *Das Gesetz der Trans... Knochen* Berlin

Correspondence to Niels J Holm, Kulsviertoften 34 DK 2800 Lyngby Denmark

~~op. scand 51, 429–437, 1980

·HANICAL PROPERTY DISTRIBUTIONS IN THE CELLOUS BONE OF THE HUMAN PROXIMAL FEMUR

·AS D BROWN & ALBERT B FERGUSON, JR

·ment of Orthopaedic Surgery, University of Pittsburgh,
·rgh, Pennsylvania, USA

Proximal femurs obtained at routine autopsy were sectioned into large numbers of 5 mm cubic specimens, in order to obtain detailed quantitative information about the spatial and directional variations of the material properties of the cancellous bone Low strain rate compression tests were performed, evaluating the apparent elastic modulus and yield strength, in three perpendicular testing directions, for each cube A computer contouring program was used to assemble the experimental data into smoothed distribution plots across sections of interest

The results revealed stiffness and strength elevations/reductions which clearly correspond to roentgenographic features. Especially prominent stiffness elevations (160 to 400 percent above the overall cancellous bone average) were found in the regions traversed by the primary trabeculation system, *although the modulus of the bone samples was substantially* reduced when measured in directions other than those of habitual weight-bearing Similar but less pronounced effects were observed for the arcuate trabeculation system Conversely Ward s triangle and the intertrochanteric regions exhibited significant (as much as 40 to 90 percent below average) stiffness and strength reductions.

There was close qualitative agreement between the stiffness and yield strength distributions for all sections examined This phenomenon was found to be a corollary of the remarkably linear proportionality between the modulus and yield strength values for individual compression tests.

Key words biomechanics, bone physiology, femur head, femur neck, stress, mechanical

Accepted 6 ix 79

·transmission abnormalities associated ·structural anomalies in the proximal ·play a major role in conditions such as ·rthritis, osteoporosis, and idiopathic ·necrosis. Also, the degree of stability ·n be obtained by delivery of the stress ·appropriate portion of the proximal ·in the instance of fracture, fracture ·n and implant *insertion depends upon* ·ernal distribution of the material pro· Detailed information on the modulus ·utions in the proximal femur is also ·ant in the context of implant design, given the desirability of minimizing resorption and loosening at bone/cement and bone/porous implant interfaces. However, there has been relatively little effort expended toward systematic determination of the actual *stiffness and strength variations,* upon which the stress transmission patterns and points of fracture initiation depend

Mathematical *simulations of the internal* stress distributions in the proximal femur, both with and without endoprostheses, have recently been undertaken in several laboratories (Andriacchi et al 1976, Brown &

·170, 80, 030429–09$02.50 0

Ferguson 1978, Harris et al 1978, McNiece et al 1976, Rybicki et al 1972, Scholten et al 1978, Valiappan et al 1977), using computer-based finite element stress analysis techniques The accuracy of such mathematical models, unfortunately, can be no better than that of the material property distribution data upon which they are based The present paper reports results of direct rheological tests aimed at cataloging spatial and directional variations of the mechanical properties of the cancellous bone in the human proximal femur

There now exists a broad consensus that the stiffness and strength of cancellous bone are intimately dependent upon both the ash weight (or, void fraction) and the trabeculation pattern (Behrens et al 1974, Carter & Hayes 1977, Galante et al 1970, Lindahl 1976, McElhaney et al 1970, Pugh et al 1973, Schoenfeld et al 1974, Townsend et al 1975b) Because of the complex internal anatomy of the proximal femur, pronounced spatial and directional cancellous bone material property variations are to be expected There have been studies aimed at cataloging stiffness variations in the distal femur/proximal tibia (Behrens et al 1974), and in the patella (Townsend et al 1975b), although in both cases the resolution of the spatial variations was somewhat limited due to the small number of sampling locations considered For the proximal femur, however, the data are sparse and somewhat inconsistent Hardinge (1949) in an early study of penetration resistance of femoral head [illegible], was able to identify a band of elevated hardness extending upward from the medial end of the inferior cortex of the femoral neck to the middle of the superior surface of the head But Schoenfeld et al (1974), working with 3/16-inch diameter cylindrical specimens oriented parallel to the femoral neck, were unable to detect any significant correlation between specimen location and material properties Harris et al (1978) have recently used an EMI scanner to map proximal femur stiffness, a technique which avoids tedious physical measurements on individual samples However their [illegible] does not yield direct stiffness or s[illegible] information, and does not account f[illegible] anisotropic (direction-dependent) pr[illegible] of the cancellous bone In the present [illegible] direct mechanical measurements are u[illegible] assess the stiffness and strength of ind[illegible] cubic cancellous bone samples, each [illegible] going successive uniaxial compressive l[illegible] in three mutually perpendicular direct[illegible] large number of samples is conside[illegible] as to permit computer based asses[illegible] contour maps of section by section [illegible] property variations.

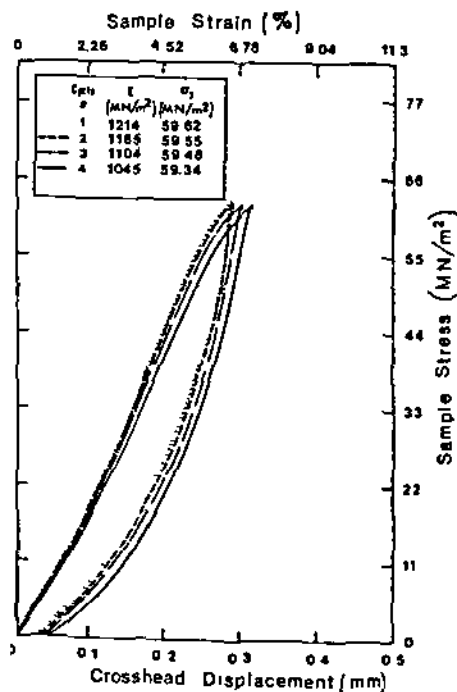
MATERIAL AND METHODS

Proximal femurs were removed at [illegible] autopsy from donors who had no histor[illegible] disease, and who were under no med[illegible] known to influence bone deposition [illegible] with gross evidence of cartilage degenera[illegible] excluded from the study The excised p[illegible] femurs were cleared of excess soft tissu[illegible] frozen and stored at −10°C until the [illegible] mechanical testing

After thawing the specimens were s[illegible] into a large number of side by side cu[illegible] samples using a Unimat machining s[illegible] equipped with a circular saw blade. The b[illegible] kept thoroughly lubricated with saline, [illegible] run at low speed (about 500 rev/min) to [illegible] avoid excessive heating and friction w[illegible] cutting groove The sample cubes had [illegible] edge lengths of 5 mm and were all id[illegible] oriented with faces in the superior[illegible] medial-lateral and anterior-posterior d[illegible] Approximately 1200 side-by side sa[illegible] samples were obtained from each proxim[illegible] specimen but only about 800 of the 1200 [illegible] were suitable for mechanical testing T[illegible] sample dimensions were measured [illegible] micrometer

The sample cubes were subjected to a s[illegible] uniaxial compression tests using an [illegible] Model 1122 Universal Testing Machine [illegible] constant crosshead speed of 0.0? mm [illegible] stress strain curve (Figure 1) for the sa[illegible] calculated from the force-deformation curv[illegible] on a strip chart recorder

For one femoral head the compress[illegible] were continued past the inflection point [illegible] load-deformation curve The tests were st[illegible] the point where yielding was incre[illegible]



1 Stress strain behavior for a typical sample undergoing successive compression the incipient yield point The modulus (derived from manual measurements of the of the linear portion of the stress strain were found to decrease only slightly (< 5 per- om test to test, indicating that no significant ral compromise was involved

ined by operator judgment This technique ed a reasonable estimate of the yield h, but of course held the potential risk of mising the specimen's structural integrity bsequent loadings in the other two ns. However, multiple cycles to the nt yield point in the same direction revealed uccessive modulus values differed by no han 5 percent (Figure 1) if the tests were y performed, indicating that serious ral compromise could be avoided

to undertaking large numbers of compres- ests, other artifacts associated with the nical testing protocol were studied The rate (Figure 2) was found to have no able influence on sample stiffness within ge of measurements (strain rates of 0 0001 s⁻¹) The end effects associated with the width-to-length ratio of our cubic samples stimated from finite-element stress analyses, he program of Brown & Ferguson (1978) sults of the computer simulation showed the vicinity of the platens the stress field

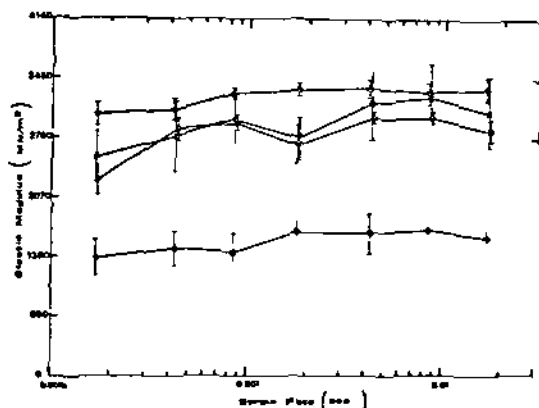


Figure 2 The influence of compressive strain rate upon the measured elastic modulus For the samples tested, there was no significant effect over a strain rate range from 0 0001 to 0 01 s^{-1} The tests were performed in random sequence, the bars denoting the standard deviation of measured values at each strain rate

departed appreciably from one of uniaxial compression and that the gross load to-deformation ratio (and hence the apparent elastic modulus) of our cubic samples was 5 27 percent higher than that which would have been observed with a conventional specimen test geometry This stiffening artifact was readily compensated for in the computer algorithm which was used to extract modulus values from the raw experimental data To assemble the large number of cube sample measurements into catalogues of the spatial variations of the mechanical properties within a given proximal femur a computer-based contour plotting algorithm* was modified to accept modulus and yield strength data for many points located within irregularly shaped femur sections.

RESULTS

Graphical representation of the complete experimental data in terms of two-dimensional section maps is somewhat cumbersome, as a total of 504 maps would be necessary The salient property distribution phenomena can be appreciated, however, from the abridged series of five maps discussed below Three-

*Program PMRC, developed by the Pittsburgh Mining Research Center of the U S Bureau of Mines.

Ferguson 1978, Harris et al 1978, McNiece et al 1976, Rybicki et al 1972, Scholten et al 1978, Valiappan et al 1977) using computer-based finite element stress analysis techniques. The accuracy of such mathematical models, unfortunately, can be no better than that of the material property distribution data upon which they are based The present paper reports results of direct rheological tests aimed at cataloging spatial and directional variations of the mechanical properties of the cancellous bone in the human proximal femur

There now exists a broad consensus that the stiffness and strength of cancellous bone are intimately dependent upon both the ash weight (or, void fraction) and the trabeculation pattern (Behrens et al 1974, Carter & Hayes 1977, Galante et al 1970, Lindahl 1976, McElhaney et al 1970, Pugh et al 1973, Schoenfeld et al 1974, Townsend et al 1975b) Because of the complex internal anatomy of the proximal femur, pronounced spatial and directional cancellous bone material property variations are to be expected There have been studies aimed at cataloging stiffness variations in the distal femur/proximal tibia (Behrens et al 1974) and in the patella (Townsend et al 1975b) although in both cases the resolution of the spatial variations was somewhat limited due to the small number of sampling locations considered For the proximal femur, however, the data are sparse and somewhat inconsistent Hardinge (1949) in an early study of penetration resistance of femoral head [illegible]ons, was able to identify a band of [illegible]evated hardness extending upward from the medial end of the inferior cortex of the femoral neck to the middle of the superior surface of the head But Schoenfeld et al (1974), working with 3/16-inch diameter cylindrical specimens oriented parallel to the femoral neck were unable to detect any significant correlation between specimen location and material properties. Harris et al (1978) have recently used an EMI scanner to map proximal femur stiffness a technique which avoids tedious physical measurements on individual samples. However [illegible] does not yield direct stiffness or [illegible] information and does not account [illegible] anisotropic (direction-dependent) [illegible] of the cancellous bone. In the pres[illegible] direct mechanical measurements are [illegible] assess the stiffness and strength of [illegible] cubic cancellous bone samples, each [illegible] going successive uniaxial compressi[illegible] in three mutually perpendicular direc[illegible] large number of samples is cons[illegible] as to permit computer-based asse[illegible] contour maps of section-by-section [illegible] property variations.

MATERIAL AND METHODS

Proximal femurs were removed [illegible] autopsy from donors who had no kn[illegible] disease and who were under no me[illegible] known to influence bone deposition [illegible] with gross evidence of cartilage degener[illegible] excluded from the study The excised [illegible] femurs were cleared of excess soft tiss[illegible] frozen and stored at −10°C until the mechanical testing

After thawing the specimens were [illegible] into a large number of side-by-side c[illegible] samples, using a Unimat machining [illegible] equipped with a circular saw blade The [illegible] kept thoroughly lubricated with saline, [illegible] run at low speed (about 500 rev min) [illegible] avoid excessive heating and friction [illegible] cutting groove The sample cubes had [illegible] edge lengths of 5 mm and were all [illegible] oriented with faces in the superior[illegible] medial lateral and anterior-posterior [illegible] Approximately 1200 side-by-side [illegible] samples were obtained from each proxi[illegible] specimen but only about 800 of the 1200 [illegible] were suitable for mechanical testing [illegible] sample dimensions were measured [illegible] micrometer

The sample cubes were subjected to [illegible] uniaxial compression tests, using an [illegible] Model 1122 Universal Testing Machine [illegible] constant crosshead speed of 0.02 [illegible] stress strain curve (Figure 1) for the [illegible] calculated from the force-deformation cur[illegible] on a strip chart recorder

For one femoral head the compress[illegible] were continued past the inflection p[illegible] load-deformation curve The tests were [illegible] the point where yielding was ex[illegible]

...nal material property data for the ...ave been recorded *in extensa* on ...r tape, available upon request from ...ors

...istributions of mechanical properties ...a coronal midsection of a typical ...l femur are illustrated in Figure 3 ...' elastic modulus of sample cubes ...in the superior inferior direction ...3a), it is apparent that the primary ...ation family constitutes a stiffness ...aversing the femoral head (shown ...on the contour map), with modulus ...n the range of 4800 to 6900 MN/m² ...eas of reduced stiffness are also dis... in the head region, one with a ...n stiffness value of about ...N/m² located superiorly and laterally ...), the other with minimum stiffness ...0 MN/m² located inferiorly and ...(point B) The highest cancellous ...iffness values, up to 9700 MN/m², ...und to occur just inside the medial ...ear the distal boundary of the section ...), and clearly correlate with the high ...sity area of that region (see Figure ...dulus values below 1400 MN/m² are ...ered in the area of Ward's triangle ...D) The secondary, or arcuate, ...ation system is identifiable as a ...(3400 to 5200 MN/m²) area of ...elevation curving superiorly and ...around Ward's triangle, and ...g downward into the middle of the ...chanteric region The most compliant ...the entire section was found to be ...centrally from the distal end of the ...system, and involved modulus values ...as 1000 MN/m² (point E) The ...us bone of the greater trochanter was ...atively compliant, and showed a mild ...s "slope" (roughly 3500 MN/m²–cm) ...terally toward the muscle attachment ...Cubes from this section tested instead ...medial lateral and anterior-posterior ...ns led to contour plots with basically ...me landmarks as those seen for ...r-inferior compression In general ...r their transverse stiffness values were found to be somewhat lower (by 26 percent and 34 percent, respectively) than those measured with superior-inferior loading

It is interesting to compare the pattern of stiffness distribution with that of the yield strength (see Figure 3b) Test samples taken from weight-bearing trabecular system can sustain superior-inferior compression levels of as much as 310 MN/m² whereas those from non-weight-bearing regions in the head typically fail at stresses of from 120 MN/m² (point A) to 150 MN/m² (point B) Note that as is the case for stiffness the lowest values for yield strength occur not within the head but rather in the intertrochanteric region on either side (points D and E) of the distal extension of the tensile trabeculation system Examination of the strength pattern in this section for cubes loaded in the medial-lateral direction (see Figure 3c) reveals that bone in the primary trabeculation system consistently fails at transverse stress levels only 50 to 70 percent as high as those which can be safely sustained longitudinally (compare with Figure 3b) Also it is evident from the prominent strength elevation area (shown shaded) which runs horizontally through the central region of the head in Figure 3c that the secondary trabeculation system contributes substantially to the head's (limited) ability to sustain transverse stress elevations

Since the patterns of load transmission through the hip are inherently three-dimensional, it is also interesting to examine the material properties of other sections. Figure 4a depicts the superior inferior test direction modulus distribution across a sagittal section located 35 mm lateral to the medial margin of the head A marked increase in stiffness from 3200 MN/m² to 9800 MN/m² can be observed from the upper to the lower part of the femoral neck Also, there is approximate anterior to-posterior symmetry in the stiffness distribution for this section, with a central, posteriorly curving, high-stiffness ridge separating compliant regions located anteriorly (2800 MN/m²) and posteriorly (1900 MN/m²)

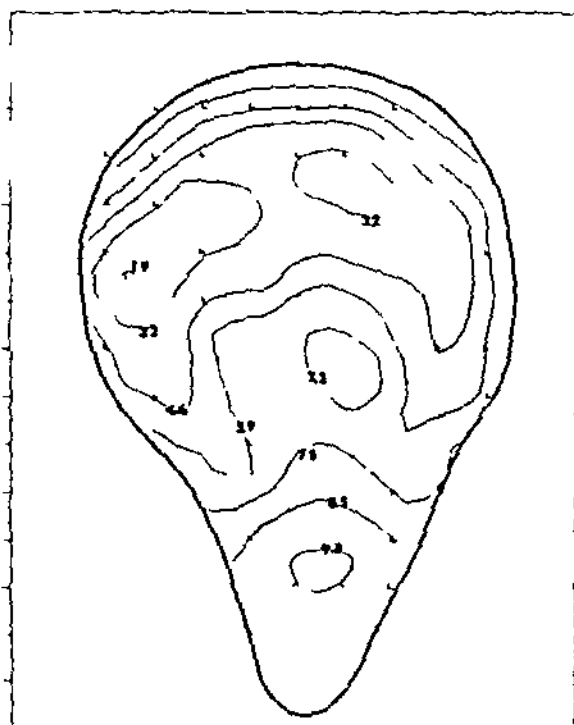


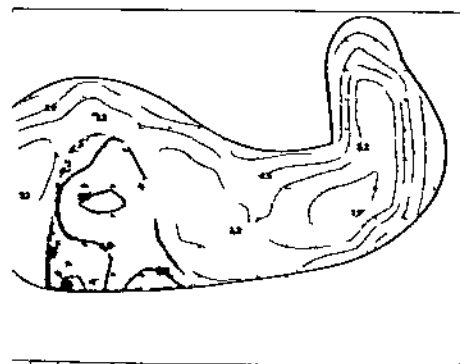
Figure 4a Superior inferior elastic modulus contours (multiples of 10^3 MN/m^2) across a sagittal section located 35 mm from the medial margin of the head Note the progressive distal stiffening and the rather symmetrical distribution in the anterior posterior (right left) direction



Figure 4b Rad ograph of a section corr to that of Figure 4a. The curved superio valley is clearly demonstra d, a distally increasing st ffness trend

A transverse section located 45 mm below the superior margin of the head is shown in Figure 5a The stiffness elevations (shaded region) indicate that the primary trabecula tion system has a surprisingly wide cross section at this level Since the medial neck cortex runs obliquely just below this transverse section these data indicate that compressive stress transfer to the cortex occurs over a fairly broad area and is biased slightly toward the anterior aspect These mechanical observations are supported by examination of the trabeculation in the roentgenogram of Figure 5b

In spite of the marked mechanical anisotropy of individual cubic test samples, the patterns of stiffness and yield strength distribution across a given section for a given testing direction were always generally similar Moreover these patterns were fairly reproducible between individuals although mean stiffness values varied by as much percent When each sample yield stre result was plotted as a function of the responding modulus value (see Figure 6 found that the data clustered w remarkably narrow nearly linear b regress on coefficients for the indiv regress on coefficients for the indiv M L and A P directions are 0 0 9 and 0 0442 respectively whereas the regression coefficient is 0 0416. Clearl ind cates that the proportionality coe between specimen modulus and yield s is essentially d rect on ndependent, of the highly an sotrop c structur cancellous bone



5a Superior inferior elastic modulus 's across a transverse section, 45 mm below 'erior margin of the head The compressive lae cause a surprisingly wide stiffness m (shown shaded), biased slightly toward the r aspect of the femur



5b Roentgenogram of the corresponding erse section

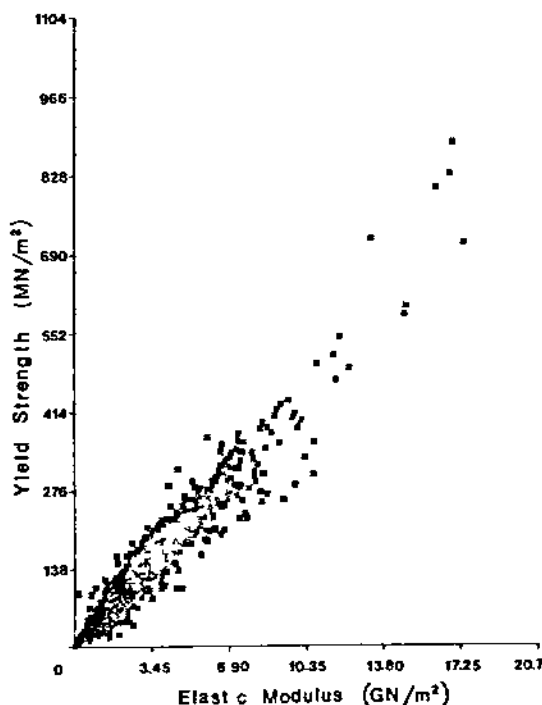


Figure 6 The relationship between the elastic modulus and incipient yield strength of the cancellous bone samples This figure consisting of 1938 data points plotted by computer (646 cubic samples each tested in all three directions) demonstrates that the yield strength and stiffness values are remarkably proportional to one another regardless of the testing direction

USSION

:echniques employed in this study yield ed and direct quantitative information e distributions of stiffness and strength : cancellous bone of the human proximal Data of this type are clearly necessary rder to take full advantage of new uter based stress analysis techniques as the finite element method The nption that the cancellous bone of the mal femur is a homogeneous, isotropic nal (Andriacchi et al 1976 Rybicki et al Valiappan et al 1977) need no longer ade

iere was generally good qualitative similarity between the calculated property distributions and the corresponding trabeculation patterns (as shown in radiographs) This finding coupled with the quantitative agreement with other rheological studies of cancellous bone in the literature (see Table 1) indicates that the results of this study are reasonable

The present investigation assumes that cancellous bone behaves as a continuum on the scale of the 5 mm cubic test samples. Since inter trabecular dimensions are of the order of 0 5 mm something like 10^2 marrow-to-bone discontinuities typically exist across our square testing sections. According to the criterion of Fung (1977) this represents about

Table 1 Rheological studies of cancellous bone

Investigator(s)	Specimen location	Strain rate (s^{-1})	Loading direction	[illegible]
Schoenfeld et al. (1974)	Femoral head	0 0044	Parallel to neck axis	[illegible]
Carter & Hayes (1977)	Tibial plateau	0 1	Superior inferior	[illegible]
Townsend et al (1975b)	Patella	0 0007	Superior inferior	[illegible]
	Patella	0 0007	Anterior posterior	[illegible]
	Patella	0 0007	Medial lateral	[illegible]
Brown & Ferguson (1978)	Femoral head	0 004	Superior inferior	[illegible]
	Femoral head	0 004	Anterior posterior	[illegible]
	Femoral head	0 004	Medial lateral	[illegible]
Present Study	Proximal femur	0 004	Superior inferior	[illegible]
	Proximal femur	0 004	Medial lateral	[illegible]
	Proximal femur	0 004	Anterior posterior	[illegible]

the minimum sample size for which the continuum characterization is realistic Thus, our material property distribution data are not directly applicable to the study of small-scale phenomena such as deformation or fracture on the level of individual trabeculae (Townsend et al 1975a) However, our data do constitute reasonable and indeed necessary input for regional adaptations of non-continuous structural models such as that advanced by Pugh et al (1973)

Although the present investigation is among the first to consider directional variations in the material properties, we recognize that the tabulation of Young's modulus values for three orthogonal test directions by no means constitutes a rigorous rheological description of an anisotropic elastic solid Indeed, characterization of all the combinations of interaction between the nine elements (three normal and six shear) of the stress tensor and the nine analogous elements of the strain tensor requires a total of 81 influence coefficients. While it can readily be shown that only 21 of these coefficients are independent under normal circumstances (Lekhnitsky 1963), the number of tests theoretically necessary to fully describe the elastic behavior of hundreds of individual sample cubes is still staggering But for practical purposes such as prosthesis design, mathematical modelling, or better disease description, the present [illegible] provides what appears to be a [illegible] approximation to the salient [illegible] proximal femur cancellous bone [illegible] homogeneity and anisotropy

CONCLUSIONS

Computer based assembly of mod[illegible] yield strength data for the cancellous [illegible] proximal femurs sectioned into large [illegible] of 5 mm cubes produces contour map[illegible] agree reasonably with the corres[illegible] sectional x-rays. The method is [illegible] labor-intensive but does provid[illegible] quantitative data at acceptable resol[illegible] the spatial and directional material [illegible] variations

To a surprising degree the stiff[illegible] yield strength values at a given po[illegible] proximal femur were found to be line[illegible] portional to one another regardless [illegible] degree of anisotropy at the point und[illegible] Cancellous bone in the primary trab[illegible] system, when tested in longitudinal [illegible] sion, typically exhibited stiffness el[illegible] 160 to 400 percent above the [illegible] proximal femur average. The [illegible] stiffness of these same primary [illegible] samples, when tested instead in t[illegible] compression, was only about 50 to [illegible]

ı that observed for the longitudinal -tiffness elevations (especially under -se compression) were also evident in oral head regions traversed by the trabecular system, but the magnitude iate stiffness elevation was con- y less pronounced than that observed primary trabeculation system Other l views (sagittal and horizontal) that the primary trabeculation increases appreciably in stiffness creasing moderately in cross-sectional the joint load is transferred distally e articular surface toward the medial f the neck

WLEDGMENTS

iors wish to acknowledge the assistance ary E Graf, Mr Steve Stiegel, Mr Brian and Mrs. Diana W. Montgomery The es aided by grants from the Easter Seal Foundation (#N7739), the U S National Foundation (#ENG 78-05451), the Barra ion, Inc., and the Western Pennsylvania of the Arthritis Foundation

ENCES

chi, T P, Galante, J O, Belytschko, & Hampton, S (1976) A stress analysis ie femoral stem in total hip prostheses. me Jt Surg 58-A, 618–624

s, J C, Walker, P S & Shoji, H (1974) ations in strength and structure of cellous bone at the knee *J Biomech* 7, -207

T D & Ferguson, A B, Jr (1978) The lopment of a computational stress analysis he femoral head – mapping tensile, com- sive and shear stress for the varus and us positions. *J Bone Jt Surg* 60-A, -629

D R & Hayes, W C (1977) The com- sive behavior of bone as a two-phase ous structure. *J Bone Jt Surg* 59-A, -962

Y C. (1977) *A first course in continuum hanics* Prentice-Hall, Englewood Cliffs.

, J, Rostoker, W & Ray R D (1970) Physical properties of trabecular bone *Calcif Tiss Res* 5, 236–246

Hardinge, M G (1949) Determination of the strength of the cancellous bone in the head and neck of the femur *Surg Gynec Obstet* 89, 439–441

Harris, L J, Chao, R & Block, R (1978) A three-dimensional finite element analysis of the *proximal third of the femur Proceedings of the 24th Orthopaedic Research Society Meeting*, p 16, O R S, Dallas.

Lekhnitsky, S G (1963) *Theory of elasticity of an anisotropic elastic body* Holden Day, San Francisco

Lindahl, O (1976) Mechanical properties of dried defatted spongy bone *Acta orthop scand* 47, 11–19

McElhaney J, Alem, N & Roberts, V (1970) A porous block model for cancellous bone ASME Publication 70-WA/BHF-2

McNeice, G M Ayres, R K & Raso, V J (1976) The total hip-finite element and clinical studies. *Proceedings of the American Society of Civil Engineers, Engineering Mechanics Division Specialty Conference*, A S C.E., New York

Pugh, J W, Rose, R M & Radin, E L. (1973) A structural model for the behavior of trabecular bone *J Biomech* 6, 657 670

Radin, E L, Paul, I L & Rose, R M (1972) The role of mechanical factors in the pathogenesis of primary osteoarthritis. *Lancet* 1, 519–521

Rybicki, E F, Simonen, F A & Weis, E B (1972) On the mathematical analysis of stress in the human femur *J Biomech* 5, 203–215

Schoenfeld, C M, Lautenschlager, E P & Meyer, P R, Jr (1974) Mechanical properties of human cancellous bone in the femoral head *Med Biol Engng* 12, 313–317

Scholten, R, Rohrle, H & Sollbach, W (1978) Analysis of stress distribution in natural and artificial hip joints using the finite-element method *The South African Mechanical Engineer* 28, 220–225

Townsend, P R Rose, R M & Radin, E L (1975a) Buckling studies of single human [illegible] bone in the human patella. *J Biomech* 8, 363–367

Valliappan, S, Svensson, N L & Wood, R D (1977) Three dimensional stress analysis of the human femur *Computers in Biology and Medicine* 7, 253–264

ondence to Dr Thomas D Brown, Orthopaedic Research Laboratory, 986 Scaife Hall, ity of Pittsburgh, Pittsburgh PA 15261 USA.

p scand 51, 439–444, 1980

IANICAL STRENGTH OF McLAUGHLIN HIP -PLATES MANUFACTURED FROM VM STAINLESS STEEL

techanical Study of Unstable Trochanteric Fractures V

N JENSEN

anics Laboratory, Department of Orthopaedic Surgery T–2, Gentofte Hospital, Hellerup,
t

Mechanical testing of McLaughlin hip nail plates manufactured from 316 LVM stainless steel was performed

The mode of failure is described and the results are compared with previous tests of McLaughlin implants manufactured from Cobalt-Chromium-Molybdenum alloy As there was no significant difference between these two products as regards the basic mechanical problem of failure of the nail plate junction, it is recommended that the design be changed to make the implant suitable for internal fixation of unstable trochanteric fractures

Key words biomechanics, fracture fixation, femoral neck fractures, stress, mechanical

Accepted 6 ix 79

previous paper (Jensen 1980) the ınical strength, under static loading, of ughlin implants manufactured from t-Chromium-Molybdenum alloy was ted From the experiments it was ıded that these implants were unsuitable the internal fixation of unstable anteric fractures due to deformation and ing of the nail-plate junction at very ield loads

nmer-USA has modified the weak nail-junction by increasing the thickness of vasher interposed between the top bolt the back of the plate and besides that locked the top bolt with an additional centrally placed bolt with a left hand d (Figure 1) The dimensions of the nail and the plate are basically the as the Cobalt-Chromium-Molybdenum ant.

The purpose of the present investigation was to examine the mode of failure of this modification of the McLaughlin implant, manufactured from 316 LVM stainless steel, and to compare the results with those recently published regarding Cobalt-Chromium-Molybdenum implants (Jensen 1980)

MATERIALS AND METHODS

The experiments were performed on McLaughlin hip nail-plates manufactured from 316 LVM stainless steel having angles and lengths as listed in Table 1 Five-hole plates were used in all cases (Catalogue numbers 2407–05, 96–00–XX, Zimmer USA International). The moment arm about the intersection between the back of the plate and the centre line of the nail was kept constant (– 41 4 mm)

-6470 80 030439–06502 50, 0




Figure 1 The components of the McLaughlin implant manufactured from 316 LVM stainless steel [illegible] and after assembly

Static mechanical load testing was performed on the McLaughlin implants mounted with an inclination of 11° to the vertical with simultaneous readings of the applied load, the deflection of the nail tip, the elongation of the moment arm and the surface strain of the nail 25 mm from the junction and of the plate 5 mm from the base of the curved extension A detailed description of the experimental arrangement has been published recently (Jensen 1980)

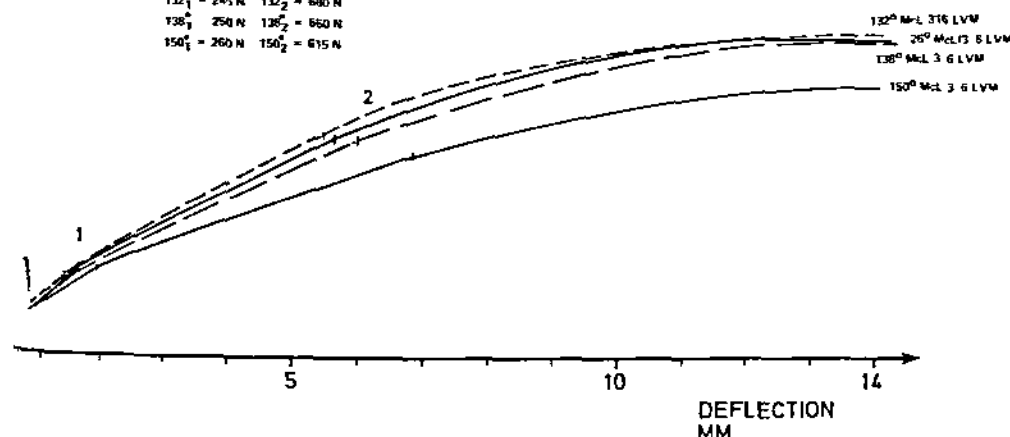
Five experiments were performed for ea[illegible] differently angled nail plates. For each a[illegible] curves were calculated and load-deflection [illegible] and load strain diagrams were constructed [illegible]

The yield points, where the metal und[illegible] permanent plastic deformation were deter[illegible] all diagrams as the point where the straight [illegible] the graph is transformed into a curved line.

In accordance with equations presen[illegible] previous paper (Jensen 1980) the bending [illegible]

Table 1 Applied nail plate angles, moment arms and nail lengths of McLaughlin [illegible] manufactured from 316 LVM stainless steel

Nail-plate angle degrees	Moment arm about intersection mm	Moment arm about nail-plate junction mm	Nail length mm
126°	41 4	51 1	74 9 (2 9[illegible]
132°	41 4	50 0	83 0 (3 [illegible]
138°	41 4	48 7	94 6 (3 [illegible]
150°	41 4	46 0	141.3 (5 56[illegible]



: *Load deflection diagrams for trifin McLaughlin hip nail-plates manufactured from 316 LVM steel*

eld point about the nail-plate junction and e strain gauge centre on the trifin nail were d, as well as the varus angulations at the yield points

TS

ad-deflection diagrams for the entire McLaughlin hip nail-plates are strated in Figure 2 It is seen that two points were encountered for each t.

high yield point occurred at 660–680 implants with angles of 126°–138° red with 615 N for 150° nail-plates. In 3 the load-strain diagrams for the nails and the plates of different angles own It is seen that the yield points for fin nails correspond fairly well with the yield points of the load-deflection ms and that the yield points for the occur at slightly lower values. A te yield point corresponding to bending plate could thus not be determined he load-deflection diagrams. The high points of the McLaughlin implants are re caused by permanent plastic de- ion of the nail and the plate

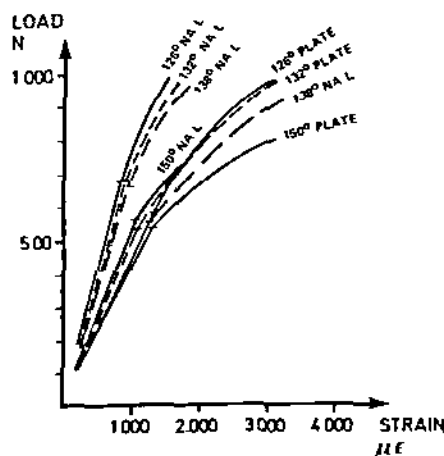


Figure 3 Load strain diagrams for trifin McLaughlin hip nail plates manufactured from 316 LVM stainless steel.

The bending moments about the strain gauge at the trifin nail 25 mm from the nail-plate junction were calculated as shown in Table 2 It was demonstrated that the bending

Table 2 Calculated bending moments about strain gauge centre on [illegible] *implants*

Nail plate angle degrees	Elongation of moment arm MA mm	Yield load J N	Bending moment (316 LVM) M_a	(Co-Cr) M_c
126°	6 09	680	26 1 Nm	21 9 [illegible]
132°	7 16	680	27 3 Nm	24 1 [illegible]
138°	9 87	660	28 6 Nm	[illegible]
150°	16 32	560	28 7 Nm	[illegible]

The bending moments for the Cobalt-Chromium Molybdenum implants are taken from a [illegible] (Jensen 1980).
The yield loads are determined from Figure 2

moment at the yield point increased with the nail plate angle from about 26 Nm to about 29 Nm The comparative values for Cobalt Chromium Molybdenum implants were 22 to 28 Nm

The low yield points in McLaughlin 316 LVM stainless steel implants were calculated to be 245–260 N (Figure 2) and were not significantly related to the nail plate angle.

The low yield point was in all cases caused by failure of the nail plate junction The small knobs of the plate portion became slightly flattened at the lower contact point as well as at the corresponding point on the base of the nail Furthermore the top bolt bent successively as demonstrated in Figure 4 The thin central bolt also bent accordingly and frequently made the disassembly of the implant very difficult The interposed [illegible] did not deform macroscopically

The bending moments causing deformation of the nail-plate [illegible] calculated to be 12.5–13 6 Nm, [illegible] of the nail plate angle The [illegible] figures for Cobalt-Chromium-Molybdenum implants were 11 4–13 3 Nm.

The varus dislocations of the [illegible] encountered at the two yield points [illegible] calculated As shown in Table 1 [illegible] angulation of 2° corresponds to [illegible] deformation and thereby loosening [illegible] nail plate junction A further bend[illegible] about 4°–5° takes place before the [illegible] and the plate start bending Th[illegible] dislocation involved in the bending [illegible] nail plate junction as well as the nail [illegible] plate was calculated to be 6° 7 [illegible] sponding to a loading of less than [illegible] Table 3 the comparative values for [illegible] Chromium Molybdenum implants are listed It is seen that the varus [illegible] caused by bending of the nail-plate [illegible] and the nail and the plate was [illegible] higher in these implants, the corre[illegible] loads being 590–640 N

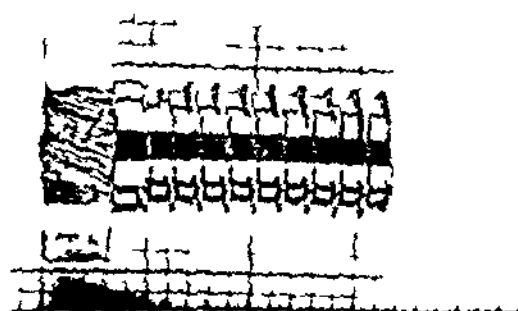


Figure 4 Top bolt bent after completion of testing

DISCUSSION

The McLaughlin h p nail plate, [illegible] introduced in 1947 (McLaughlin 1[illegible]

e 3 Calculations of the varus angulation in hip implants during mechanical loading

ail plate angle deg	β deg	Nail length L_N mm	Deflection e_1 mm	β_1 deg	Varus angulation $\beta-\beta_1$	Deflection e_2 mm	β_2 deg	Varus angulation $\beta-\beta_2$	Varus angulation $\beta-\beta_3$
126°	47°	74 9	1 60	45 2	1 8°	5 65	41 0	6 0°	
132°	53°	83 0	1 50	51 3	1 7°	5 50	47 1	5 9°	
138°	59°	94 6	1 55	57 2	1 8°	6 00	52 5	6 5°	
150°	71°	141 3	1 95	68 7	2 3°	6 85	52 5	7 2°	
126°		74 4	1 20		1 3°	7 40		7 8°	12.8°
132°		82 6	1 05		1 2°	7 10		7 6°	11 1°
138°		94 0	1 25		1 5°	7 40		7 9°	11 4°
150°		140 7	1 20		1 5°	4 55		5 1°	7 4°

l angle — 79° The values stated for Cobalt-Chromium Molybdenum implants have been previously (Jensen 1980)

the most widely used device for fixation of trochanteric fractures, in iany reports of failures at the nail-plate

5 McLaughlin & Garcia presented a ion of the original device The top tion was considered unreliable as a of loosenings of the top bolt had been The loosening was thought to be unwinding of the top bolt It was recommended that the nail and assembled with the aid of a nut with ic stud giving a higher torque e

: present series 316 LVM stainless l plates (Zimmer-USA International) ted The basic idea of this device is rdance with the modifications of hlin & Garcia (1955) as unwinding is d by an additional top bolt with a l thread Moreover, the washer inter-tween the top bolt and the back of the airly thick

316 LVM stainless steel implants did ve to be significantly stronger than balt-Chromium-Molybdenum devices 1980), although the bending moments l to bring about failure were about cent higher The overwhelming ical problem was once again failure of the nail-plate junction Bending of the top bolt was the most illustrative finding and the yield load was determined to be less than 260 N The basic problem is fairly similar for the 316 LVM stainless steel and the Cobalt-Chromium-Molybdenum alloy implants, as the design of the curved extension of the plate and the base of the nail are almost identical The curved extension of the plate is hemispherical in shape and equipped with small knobs to prevent rotational instability The base of the trifin nail is plane and equipped correspondingly with small notches for rotational stability The dimensions of these two surfaces involves a total area of contact of less than one third of a square centimeter, even if they fit together perfectly As this is not the case, due to differences in geometry, all the forces are concentrated to a very small area leading to the permanent deformations described and thereby loosening of the nail-plate junction The loads required to bring about this looseness were as low as about 260 N At this load the material starts undergoing deformation hardening and the area of contact is increased because of the deformation The result of this is a certain amount of looseness, but the nail-plate junction is becoming stronger making further loading

and thereby determination of the yield point for the nail and plate possible. A disadvantage of the deformation hardening is, however, that the deformed areas become more susceptible to corrosion.

As the hip joint load during normal level walking is at least three to five times the body weight (Paul 1976, Rydell 1966) loosening of the nail-plate junction and thereby varus dislocation of the fracture is to be expected in every case in which the implant alone transmits the entire load from the hip joint to the femoral shaft. This is in principle the case in unstable trochanteric fractures, and consequently McLaughlin implants cannot be recommended for the internal fixation of these fractures, whether the implants are manufactured from 316 LVM stainless steel or from Cobalt-Chromium-Molybdenum alloy. A re-design of the nail-plate junction is thus needed in order to provide sufficient mechanical strength to allow full weight-bearing of the immediate rehabilitation after fracture fixation.

ACKNOWLEDGEMENTS

Gratitude is expressed to Conrad [illegible] M Sc.Eng and Erik Glube, M.[illegible] Copenhagen Engineering College for [illegible] help. The study was kindly supported by [illegible] Danish Medical Research Council, Gr[illegible] 512–6595 and the Medical Research F[illegible] of Copenhagen, Grant No. 75/76,20 The [illegible] were supplied by Zimmer-USA [illegible] Warsaw, Indiana and Simonsen & We[illegible] Denmark.

REFERENCES

Jensen, J. Steen (1980) Mechanical [illegible] Jewett and McLaughlin hip nail [illegible] manufactured from Cobalt-Ch[illegible] Molybdenum alloy *Acta orthop scand* [illegible] 156.

McLaughlin, H. L. (1947) An adjustable [illegible] fixation element for the hip *Amer J Surg* [illegible] 150–161.

McLaughlin, H. L & Garcia, A. (19[illegible]) [illegible] justable fixation device for the hip. *Am[illegible]* *Surg.* 89, 867–871.

Paul, J. P. (1976) Force actions transmitted by [illegible] in the human body *Proc roy Soc* [illegible] 163–172.

Rydell, N. W. (1966) Forces acting on the [illegible] head prosthesis *Acta orthop scand.*, Su[illegible]

Correspondence to: J. Steen Jensen, MD, Department of Orthopaedic Surgery, T-2, Gentofte [illegible] DK–2900 Hellerup, Denmark

p scand. 51, 445–449

OCHONDRITIS OCCURRING AT MULTIPLE SITES

ITH & A B NEVELOS

eneral Infirmary, Leeds, U.K.

to the aetiology of coxa plana is discussed

Key words coxa plana, Kohler's disease Legg-Calvé-Perthes' disease, osteochondritis, patella

Accepted 20 x 79

observations of generalized growth ilities in cases of coxa plana (Burwell 1978b, Harrison et al 1976) have ed that this condition is not simply lized manifestation of avascularity et al 1974, Sanchis et al 1973, on & Ráliš 1974, Zahir & Freeman trauma (Fisher 1972, Wynne-Davies & y 1978).

have noted children with osteo- is juvenalis affecting several sites. per gives five case reports of children xa plana followed by osteochondritis sites.

ecognition of this connection supports cept of generalized abnormality in lvé-Perthes' disease, and may enable diagnosis of osteochondritis at a ate

REPORTS

ale D O B 25 1 64 *First born* This referred at the age of 8 months because er felt the left leg was shorter Examina- ealed some reduction of abduction and rotation, and X-rays demonstrated that the ossific nucleus of the femoral head on the left side had not appeared whereas that on the right was well formed (Figure 1) However the acetabulum was well developed and there was no suggestion of dislocation

An expectant policy was pursued but the ossific nucleus of the femoral head did not appear until 30 months and was then fragmented After a protracted course this hip recovered well both clinically and radiologically (Figures 2 and 3) Although the child had no problems with the right hip, review of the radiographs showed changes of coxa plana in that hip, part head involvement only (Catterall (1971) Group One) Not surprisingly, this hip did well radiologically

In January 1977, at routine follow-up, the boy complained of pains in the left knee and both heels Examination confirmed tenderness at the upper pole of the patella with retropatellar crepitus. There was also tenderness in both heels. X-rays showed changes consistent with osteochondritis of the upper poles of both patellae, more marked on the left (Figures 4 and 5) These symptoms gradually settled with non-specific measures, although the patient is not able to participate in sport

Case 2

M S Male D O B 23 6 69 This boy presented at the age of 6 with pain, limp and limitation of movement at the left hip Radiographs demonstrated coxa plana with whole head involve-

/80/030445–05$02.50/0



Figure 1 Case 1 Pelvic radiograph at 6 months

ment and the child was treated with crutches and a Snyder sling He improved symptomatically but the X ray changes progressed and then stabilized in the expected manner (Figures 6 and 7) The sling was withdrawn when the ossific nucleus was





Figures 2 and 3 Case 1 Pelvic radiographs at 2 years 5 months and at 11 years



Figure 4 Case 1 Radiograph of [illegible] jections both knees.

seen to be consolidating when the chi[illegible] years and 5 months old and he mad[illegible] clinical improvement

In June 1978 the patient twisted [illegible] ankle the X rays as well as revealing [illegible] chondral fracture of the lateral [illegible] showed collapse and sclerosis of the [illegible] (Kohler s disease) Radiographs of the o[illegible] showed similar but less advanced chang[illegible] 8) Both before injury and after it had [illegible] foot was asymptomatic. At this time [illegible] bone age was between 5 and 6 (accordi[illegible] atlas of Greulich & Pyle 19[illegible]) chronological age was 9

Case 3

J H Female D O B 21 11 46 [illegible] presented at the age of 6 with a[illegible] history of pain in the left thigh and [illegible] amination revealed 2 cm of shortening [illegible] hip and adductor spasm X-rays sho[illegible] coxa plana but also established [illegible] osteochondritis. The child was treate[illegible] abduction frame for 1 year then discha[illegible]



Figure 5 Case 1 Lateral radiograph of [illegible]



Case 2 Pelvic X ray at 8 years 7




Figure 8 Case (a) Radiograph of right foot. (b) Radiograph of left foot

...lieving caliper Progress was satisfactory ...been lost to follow up

...le D O B 6 5 67 This child presented ...e of 17 months with a 3 month history of ...he left hip He was otherwise normal and ...ked at 12 months. Clinical examination ...rated limitation of internal rotation and ...of the hip and radiographs confirmed ...a he was treated with a weight relieving ...or 1 year Following this, his symptoms ...subsided and he had no further pain ...age of 11 he presented with pain in both ...a clinical diagnosis of Sever s disease ...He continues to have intermittent com...

...le D O B 26 1 67 This child presented ...ars with a left limp but no restriction of



Case 2 Pelvic X ray at 9 years 1

movement X rays revealed coxa plana changes. He was treated initially by traction and then with a Snyder sling Over the course of 3 years the symptoms subsided and the X-ray appearance resolved

In August 1976 he was referred with pain and tenderness in the left heel A clinical diagnosis of Sever s disease was made and he was treated with a heel raise The symptoms resolved over 6 months.

DISCUSSION

Osteochondritis occurring at more than one site has previously been reported but almost all cases have been symptomatic at only one site the other being discovered by skeletal survey

Blencke (1924) described a case of coincident coxa plana and osteochondritis of the navicular Lane (1924) described two cases with similar dual affections. Ponseti (1956) described two cases of coxa plana with asymptomatic navicular changes and also noted abnormalities of acetabular ossification Wolf (1950) reported seven cases of osteochondritis of the lower pole of the patella (Sinding Larsen Johannson disorder) Also present in several of these were symptoms from the tibial apophysis (Osgood Schlatter disorder) Two series of coxa plana patients subjected to radiographic survey showed a total incidence of multiple disorders in 60 out of 200 cases. Bilateral hip involvement



Figure 1 Case 1 Pelvic radiograph at 6 months

ment and the child was treated with crutches and [illegible]

sling was withdrawn when the ossific nucleus was

Figure 4 Case 1 Radiograph of [illegible] jections, both knees.

seen to be consolidating when the [illegible] years and 5 months old and [illegible] clinical improvement.

In June 1978, the patient [illegible] ankle, the X-rays as well as revealing [illegible] chondral fracture of the lateral [illegible] showed collapse and sclerosis of the [illegible] (Kohler's disease). Radiographs of [illegible] showed similar but less advanced changes [illegible] 8). Both before injury and after it had [illegible] foot was asymptomatic. At this [illegible] bone age was between 5 and 6 [illegible] atlas of Greulich & Pyle 19[illegible] chronological age was 9

Case 3

JH Female DOB 21.11.[illegible] presented at the age of 6 with a [illegible] history of pain in the left thigh and [illegible] amination revealed 2 cm [illegible] hip and adductor spasm. X-rays showed [illegible] coxa plana but also established [illegible] osteochondritis. The child was treated [illegible] abduction frame for 1 year, then discharged [illegible]





Figures 2 and 3 Case 1 Pelvic radiographs at 2 years 5 months and at 11 years



Figure 5 Case 1 Lateral radiograph of [illegible]

B (1943) The relationship of Legg-Calvé-
es' disease to the function of the thyroid
J Bone Jt Surg **25**, 892–901
, W W & Pyle, S I (1959) Radiographic
of skeletal development of the hand and
. Stanford University Press, Stanford,
ornia
ı, M H M, Turner, M H & Jacobs, P
5) Skeletal immaturity in Perthes' disease
me Jt Surg **58** B, 37–43
F (1955) Protein bound iodine in Legg-
é-Perthes' disease *J Bone Jt Surg* **37** A,
846
J D (1924) The coincidence of pseudo
gia and Kohler's disease in the same
nt A record of two cases. *Lancet* **ii**,
379
Z, Axer, A & Drezner, Z (1973) Growth
development of children with Legg-Calvé-
hes' syndrome in Israel *Israel J med Sci*
12–616
son, B & Rálıš, Z (1974) Pathological
ges in a case of Perthes' disease *J Bone
urg* **56**-B, 438–447
, A B, Burch, P R J & Gelsthorpe, K
7) Perthes' disease *J Bone Jt Surg* **58** B,

M (1970) L'osteochondrite primitive de
nche *Rev Chir orthop* **56**, 588–593
, I V (1956) Legg-Perthes' disease
ervations on the pathological changes in
cases. *J Bone Jt Surg* 38-A, 739–750

Sanchis, M, Zahir, A & Freeman, M A R
(1973) The experimental simulation of Perthes'
disease by consecutive interruption of the
blood supply of the capital femoral epiphysis in
a puppy *J Bone Jt Surg* **55**-A, 335–342
Sinding-Larsen, M F (1921) A hitherto unknown
disease of the patella *Norsk Mag
Laegevidensk* **82**, 856–858
Suramo, I Puranen J, Heikkinen, E &
Vuorinen, P (1974) Disturbed patterns of
venous drainage in the femoral neck in Perthes'
disease *J Bone Jt Surg* **56**-B, 448–453
Taussig, G & Henpret, G (1969) Maladie de
Legg Calve Perthes A propos de 275 cas
Importance des facteurs mecaniques intérêt du
traitement chirurgical *Rev Chir orthop* **55**,
305–330
Weiner, D S & O'Dell, H W (1970) Legg-Calvé-
Perthes disease Observations on skeletal
maturation *Clin Orthop* **68**, 44 49
Wolf, T (1950) Larsen-Johannson disease of the
patella *Brit J Radiol* **23**, 335–347
Wynne-Davies R & Gormley, J (1978) The
aetiology of Perthes' disease *J Bone Jt Surg*
58 B, 6–14
Zahir A & Freeman, M A R (1972) Cartilage
changes following a single episode of infarction
of the capital femoral epiphysis in the dog *J
Bone Jt Surg* **54**-A, 125–136

ondence to R B Smith, F R C S, 4 Sandhill Drive, Leeds LS17 8DX U K

p scand. 51, 451–457, 1980

'E HAEMATOGENOUS OSTEOMYELITIS AND SEPTIC IRITIS IN CHILDHOOD

ear Review and Follow-up

ETERSEN*, FINN URSIN KNUDSEN*, THUR ANDERSEN** & MOGENS EGEBLAD***

ents of Paediatrics*, Orthopaedic Surgery, and Radiology***, Glostrup Hospital, Glostrup, and ents of Paediatrics**, Orthopaedic Surgery, and Radiology Gentofte Hospital, Hellerup,

Seventy-three children, who were admitted to hospital during the period 1965 1976 with osteomyelitis or septic arthritis, were included in a retrospective study as well as a clinical and radiological follow-up Ten

disease showed that none had any complaints or invalidity However, o patient with neonatal septic arthritis presented severe dysplasia and subluxation of the hip and four children with osteomyelitis had severe, but asymptomatic, radiological changes.

Key words children, follow-up, osteomyelitis, septic arthritis

Accepted 24 ix.79

ite of modern treatment, skeletal in- is in children often have a prolonged and lead in some cases to invalidity et al 1975, Dich et al 1975, Howard et 76) A retrospective investigation was cted to clarify the clinical, iological, radiological and therapeutic ts. To evaluate the long-term prognosis, ical and radiological follow-up study arried out.

ENTS

g the period 1965–1976 73 children (39 and 34 girls) under the age of 15 years were admitted to the Departments of Paediatrics and Orthopaedic Surgery at Glostrup and Gentofte Hospitals with acute haematogenous osteomyelitis or septic arthritis.

At least two of the following diagnostic criteria were met (1) Localized tenderness, redness, swelling or reduced mobility, (2) Pus aspirated from bones or joints, (3) Growth of pathogenic bacteria from blood culture, and (4) radiological manifestations of osteomyelitis or septic arthritis. Children with radiological signs of both osteomyelitis and septic arthritis were primarily assigned the former diagnosis. The distribution according to age, sex and diagnosis is shown in Figure 1 Fifty-eight children had osteomyelitis, and of these 10 had complicating septic arthritis. Fifteen children suffered from only septic arthritis. Two children suffered from diseases associated

3470 80 030451–07$02.50/0

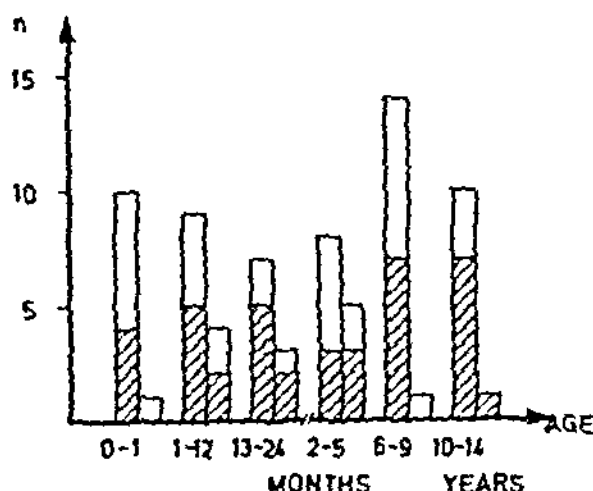


Figure 1 Seventy-three children with acute haematogenous osteomyelitis and septic arthritis

Left column osteomyelitis
Right column, septic arthritis
☐ *Girls*
▨ *Boys*

with an increased tendency to bacterial infections chronic granulomatous disease and immunodeficiency, respectively Shortly before the development of the disease, umbilical artery catheterization had been performed in three infants (Knudsen & Petersen 1977).

Table 1 Radiographical changes in 47 infectious foci in 43 patients with acute osteomyelitis

Initially		At follow-up		
Grade of severity*	*n*	None	Slight	Severe
0	1	1		
1	2	2		
2	25	17	7	1
3	4	3		1
4	15	6	7	2
Total	47	29	14	4

*Grade 0 no changes. Grade 1 soft tissue

tissue swelling, destruction or involucrum for more than 60 days.

In 39 out of 58 children with osteomy... in 14 out of 15 with septic arthri... was initiated within 1 week after the... symptoms. In six children symptoms ha... present for more than 4 weeks prior to... tion of adequate treatment. The treatm... cases consisted of immobilizing the ... In seven children with osteomyelitis ... drilled for drainage of pus while bone ... was performed once or more in ... arthritis, closed drainage was ... Antibiotic therapy varied greatly from ... ment to another and throughout the per... review Forty-seven of the 73 ch... treated with penicillinase-resistant ... lincomycin or fusidic acid. Sixteen w... exclusively with benzylpenicillin, ... ampicillin alone and three with vario... binations of antibiotics. Initially ... therapy was given parenterally in 41 ... in only 10 for more than 2 weeks. The ... antibiotic therapy was more than 3 we... and more than 6 weeks in 34 out of the 73 ...

METHODS

Radiographs were repeated during the ... recovery period. Blood cultures (Ta... cultures of aspirates from osteomyelitic ... performed in only half of the cases ... cultures of joint fluid were performed ... Culture for TB, candida and anaerob... were not performed routinely. In ... antibiotic therapy had been initiated ... culture was made

All data concerning clinical, bacter... therapeutic conditions were rep... reviewing the records. In 1977, the ch... summoned to a follow-up examina... cases a questionnaire was completed. ... was evaluated on the basis of data ob... the records. Ten of the children had ... been examined (Strandgaard & Ehm... roentgenograms were reassessed by ... authors (ME) The initial radiologi... were classified into five grades, in ... express the severity as well as the ... initial changes (Table 1). The radiol... at follow-up were classified into slight ... slight changes being defined as ... structure with slightly irregular shape ... the previous site of infection, and se... being defined as abnormal bone str... more pronounced bone deformities ... result in late recurrence or arthrosis.

pects

ence of both osteomyelitis and ritis was highest during the first 2 e Of the 58 cases of osteomyelitis d in the neonatal period and 26 first 2 years of life Of the 15 cases thritis 8 occurred before the age of gure 1)

ost frequent sites of the os- foci were the metaphyses of the s ¾ occurring in the lower and upper extremity Septic arthritis d in the weight-bearing joints in es

ildren had multiple osteomyelitic one child septic arthritis in more oint

ms such as swelling, warmth redness ed mobility were more frequent in ritis than in osteomyelitis, but in ne cases the clinical symptoms were

y data

the children with osteomyelitis and of those with arthritis, the te sedimentation rate was more than It was difficult to evaluate the od count (WBC) and the number of lic granulocytes because of the pro- variation due to age, but it was le that about ½ of the children had a ess than 10,000 per µl

ogy

e blood culture was obtained in 14 1 of the cases Aspirates from os- ic foci gave growth in 10 out of 25 l joint aspirates in septic arthritis in 15 cases.

aureus was the causative organism es of osteomyelitis and three cases of rthritis. Ten of the strains were to penicillin Betahaemolytic streptococci were isolated in three cases of osteomyelitis and two cases of septic arthritis. *H influenzae* was isolated in three cases of osteomyelitis and one case of septic arthritis

Radiological examination

Thirty-five out of 58 children with osteomyelitis had normal roentgenograms at the time of diagnosis irrespective of the duration of disease Eight of these developed radiological changes within 7 days 10 within 14 days, and another 11 within 28 days after the first symptom In two children roentgenographic changes were not observed until after 28 days and four patients developed no radiological changes at all.

In Table 1 the initial changes in 47 osteomyelitic foci in the 43 patients included in the follow up study are classified according to degree of severity In patients with septic arthritis no initial changes or only very slight ones were observed (Table 2)

Course

It appears from Figure 2 that 15 children with osteomyelitis had symptoms for more than 3 months while all those with septic arthritis no longer had symptoms by that time Figure 3 shows the cumulative cure rate after initiation of treatment in 19 children

Table 2 Radiographical changes in 13 infectious foci in 13 patients with septic arthritis

Initially		At follow up		
Grade of severity*	*n*	None	Slight	Severe
0	2	2		
1	8	6	1	1
2	3	3		
3	0			
4	0			
Total	13	11	1	1

*See Table 1

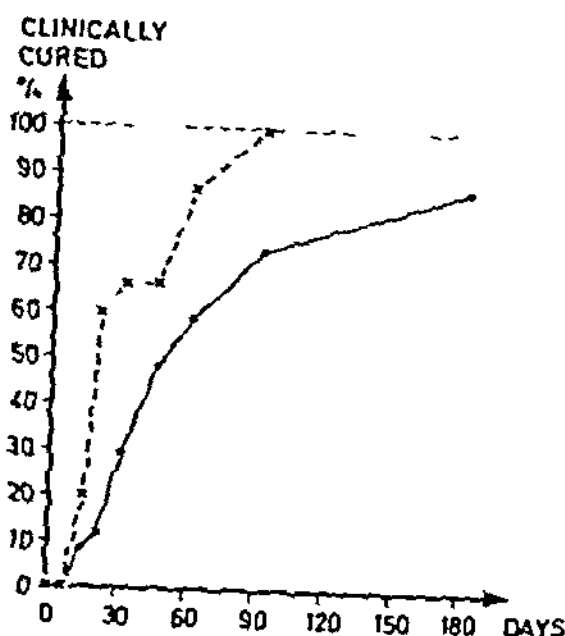


Figure 2 The cumulative cure rate after the first symptom.

●———● *Osteomyelitis*
× – – – × *Septic arthritis*

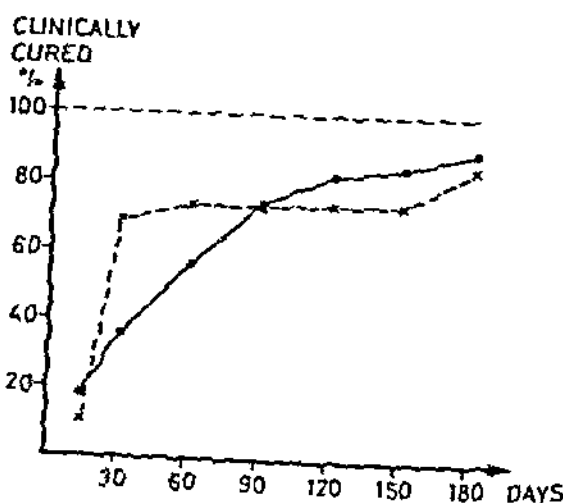


Figure 3 The cumulative cure rate after initiation of treatment for osteomyelitis

× – – – × *Nineteen children treated within 7 days with a penicillinase-resistant penicillin.*
●———● *Thirty-nine children not treated within 7 days with a penicillinase-resistant penicillin.*

with osteomyelitis who were tre[...] days after the first sympt[...] penicillinase-resistant penicill[...] compared with 39 children with o[...] who did not start treatment with[...] who did not receive pen[...] penicillins initially After 30 da[...] the cure rates of the two groups [...] of 19 (68 per cent) and 14 out of 39 ([...] respectively This difference is [...] ($\chi^2=5.7$, $0.01<P<0.025$). When [...] separately neither treatment wit[...] ($\chi^2=2.5$, $0.1<P<0.2$) nor initial [...] with penicillin-resistant penicillins [...] $0.05<P<0.1$) improved the cure [...] days treatment significantly

In five children the osteomyelitis [...] One recurrence occurred 5 years [...] primary attack One child had [...] recurrences of osteomyelitis in one [...] over a period of 2 years. Three [...] chronic osteomyelitis with sequestr[...] 3 to 12 months after initial treatm[...] in four of the five cases, was benzyl[...] or tetracycline only

Follow-up examination

One child with immunodeficiency [...] from meningitis. None of the 69 child[...] were evaluated had any complaints [...] validity. In two of the previous [...] cases the affected leg was found to be [...] longer than the other leg and in two [...] arthritis cases a slight reduction in [...] (< 10°) was observed in the joint.

Table 1 shows the radiological [...] 43 children with 47 osteomyelitic [...] Twenty-nine of the infections had [...] completely In one of these cases [...] tion had been present earlier [...] patients with mild changes at follow[...] out of seven with initial changes of [...] had insignificant bone deformities [...] scars at the site of the primary [...] focus. In one child slight calcification [...] soft tissue was found, but no bone [...] Five out of seven patients with [...] of grade 4 presented slight bone [...]

-wo of these sequestration was present
he acute phase. These two patients
gnificant bone deformities only, i e,
ostoses at the site of the previous
our children had severe changes at
) The first (initially grade 2) had
y of the distal part of the fibula with
is to the tibia The second (initially
) had coxa vara and irregular bone
and deformity of the femoral neck
d (initially grade 4) had narrowing of
ervertebral disc (L IV) The last
grade 4) had deformity of the shaft
ia and genu valgum
2 shows the results in the 13
with arthritis. In 11 the lesions had
completely, one patient presented
anges, i e, an accentuated patellar
centre. One patient had severe
from a neonatal septic arthritis of
joint following catheterization of the
artery The initial radiological
were accumulation of fluid in the
h slight lateral dislocation of the
d of the femur *Staph aureus* was
from the joint and the initial
t was lincomycin for 4 weeks. The
ffect was favourable and clinical and
cal routine check-up at the age of 9
was normal Follow-up at the age of
hs showed a small upper femoral
, subluxation of the femoral head
lasia of the acetabulum The child
ormally

SION

infections in children may be
l and result in lasting invalidity The
is worse for septic arthritis, in
if associated with osteomyelitis
l. 1975, Morrey et al 1975, Morrey
n 1975) or if the hip joint is affected
et al 1976, Morrey et al 1975).
gnosis and therapy are of crucial im-
for the prognosis (Cole et al 1975,
et al 1976, Morrey et al. 1975,
t al 1976, Morrey & Peterson 1975,
Nade et al 1974, Nade 1974a, b) It may sometimes be difficult to establish the diagnosis, especially in the newborn Often the only symptom may be that the infant does not move the affected limb In older children the symptoms of arthritis can be mistaken for rheumatoid arthritis or other types of arthritis. Therefore, puncture with aspiration and examination of joint fluid, i e microscopy, culturing and total leucocyte count, are mandatory whenever infection is suspected Scintigraphy of the bone is of value for an early diagnosis (Treves et al 1976)

The causative organism in osteomyelitis is most frequently *Staph aureus* and, in rare cases, streptococci (Dich et al 1975, Morrey & Peterson 1975, Nade et al 1974, Nade 1974a, b, Rhodes 1975) The most common causative organisms in septic arthritis are *Staph aureus* or *H influenzae* (Cole et al 1975, Howard et al 1976, Morrey et al 1975, Nade et al 1974, Nade 1975, Rhodes 1975) Of the *Staph aureus* strains 65–90 per cent were penicillin-resistant (Cole et al. 1975, Forsell 1974, Morrey et al 1975, Morrey & Peterson 1975, Nade et al 1974, Nade 1974a, b)

The initial treatment in osteomyelitis should be a combination of methicillin or cloxacillin and benzylpenicillin and, in arthritis, a combination of methicillin or cloxacillin and ampicillin (Cole et al. 1975, Nade et al 1974, Nade 1974a, b, Nade 1975) Initially parenteral therapy should *always* be chosen (Cole et al 1975, Dich et al 1975, Morrey et al 1975, Morrey et al 1976, Nade 1974a, b, Rhodes 1975) The duration of treatment recommended varies somewhat, some continue for 6 weeks after stabilization of the clinical condition and normalization of temperature (Cole et al 1975), others are guided by the ESR and the course (Nade 1974 a, b, Nade 1975, Rhodes 1975) Intra-articular administration of antibiotics (Morrey et al. 1975) may not be necessary, since a sufficient concentration of antibiotics in the joint will be obtained by parenteral administration (Tetzlaff et al 1978)

Even though 25 per cent of the children with osteomyelitis in our study were ill for more than 3 months, and five had recurrences or developed chronic osteomyelitis, the follow-up showed that the long-term prognosis was good, as none of the children had any complaints or invalidity This occurred even though the principles of treatment were less radical than those described Even in some cases with prolonged bone destruction and sequestration, healing took place without severe radiological sequelae However, in four children the follow-up examination disclosed radiological changes which in the future might cause arthrosis (Howard et al 1976) or late recurrence The follow-up revealed one case with severe radiological changes of the hip joint after a neonatal septic arthritis following catheterization of the umbilical artery An early arthrotomy might have improved the course Only a few studies on the long-term prognosis are available for comparison Lindblad et al (1965) found that about 25 per cent of children with osteomyelitis in the neonatal period had severe sequelae

In our study the importance of early therapy with effect on penicillin-resistant staphylococci is documented by a significantly increased number of children clinically cured within 30 days of this treatment, and also by the fact that four out of the five children with recurrent or chronic osteomyelitis had not received such treatment

Many of the children presented a prolonged and occasionally a complicated course Presumably, intensive treatment during the initial phase of the disease might shorten the course We recommend the following treatment schedule

1 Specimens for bacteriological examination to be obtained by blood culture and aspiration from joints or osteomyelitic foci

2 Intravenous antibiotic therapy for the first week and, if the clinical results are good, therapy to be continued orally for at least 6 weeks The following initial therapy is recommended For osteomyelitis, benzylpenicillin 300 000–500 000 IU/kg/24 hours + methicillin 200 mg/kg/24 divided into six doses. For septic ampicillin 200 mg/kg/24 hours + me 200 mg/kg/24 hours divided into ... Treatment to be changed, if ... following sensitivity tests.

3 Drainage of collections of pus ... the bone, followed by primary ... suction drainage Fenestration of the ... preferred in the case of patholog... structure Repeated punctures in ... arthritis Arthrotomy to be perfo... indicated by the clinical course, and ... septic coxitis

4 Immobilization of the affected limb

5 After the acute phase mobiliza... rehabilitation to be initiated

6 Clinical and radiological follow up in their first months of life to be check... they can walk normally and normal ... have developed

REFERENCES

Cole W G, Elliot B G & Jensen, F ... management of septic arthritis in ... *Aust N Z J Surg* 45, 178 182

Dich V Q, Nelson J D & Haltalin, K ... Osteomyelitis in infants and children ... *J Dis Child* 129, 1273–1278.

Forsell C (1974) Akut hematogen oste... barn i Jonkopings lan 1957 1972 ... 71, 4197–4199

Howard, J B, Highenboten, C L & ... (1976) Residual effects of septic ... infancy and childhood *J Amer* ... 236, 932–935

Knudsen F U & Petersen S. (197...) ... septic osteoarthritis due to umbili... catheterisation *Acta paediat.* ... 225–227

Lindblad, B, Ekengren K. & Aurel... The prognosis of acute haemato... teomyelitis and its complications ... infancy after the advent of antibio... *paediat scand* 54, 24–32

Morrey B F., Bianco A J & Rhod... (1975) Septic arthritis in children ... *Clin N Amer* 6, 923–934

Morrey, B F, Bianco A J & Rhod... (1976) Suppurative arthritis of the ... children *J Bone Jt Surg* 58 A, ...

Morrey, B F & Peterson, H ...

atogenous pyogenic osteomyelitis in
en. *Orthop Clin N Amer* **6**, 935–951
, Robertson, F W & Taylor, T K F
) Antibiotics in the treatment of acute os-
yelitis and acute septic arthritis in
ren *Med J Aust* **II**, 703–705
S (1974a) Acute haematogenous os-
yelitis *Med J Aust* **II**, 708–711
S (1974b) Acute haematogenous os
yelitis in infancy and childhood *Aust
iat J* **10**, 316–327
(1975) Acute septic arthritis in infancy
hildhood *Aust paediat J* **11**, 145–153
K H (1975) Antibiotic management of
acute osteomyelitis and septic arthritis in
children *Orthop Clin. N Amer* **6**, 915 921
Strandgaard, L & Eiken, M (1977) Tidlig
røntgenologisk påvisning af akut haematogen
osteomyelitis hos børn *Ugeskr Laeg* **139**,
2997–2999
Tetzlaff, T R, Howard J B, McCracken G H,
Calderon E & Larrondo, J (1978) Antibiotic
concentrations in pus and bone of children
with osteomyelitis. *J Pediat* **92**, 135–140
Treves, S, Khettry, J, Broker, F H, Wilkinson,
R H & Watts, H (1976) Osteomyelitis Early
scintigraphic detection in children *Pediatrics*
57, 173–186

ondence to Dr Sten Petersen, Department of Neonatology, Rigshospitalet DK-2100,
avn Ø, Denmark

p scand. 51 459–465, 1980

:TS OF OXYTETRACYCLINE INERALIZATION OF BONE IN YOUNG RATS

ENGESAETER, TRINE UNDERDAL & NORVALD LANGELAND

for Surgical Research, Rikshospitalet, and Sophies Minde Orthopaedic Hospital, University of rway

The metabolism of minerals and collagen in young rats receiving oxytetracycline was studied by employing double-isotope techniques. The dosage of the antibiotic was adjusted to obtain plasma concentrations comparable with human therapeutic levels. Reduced mineralization and possibly increased resorption of bone were observed after oxytetracycline administration, whereas no effect on the rate of collagen synthesis could be detected

Key words calcification, calcium, collagen, ^{14}C-proline, phosphorus, plasma concentration, tetracyclines, strontium-85

Accepted 27 ix.79

'e previously shown that administra- :he antibiotic oxytetracycline to young ıses reduced mechanical strength of ıd skin (Engesaeter & Skar 1978) and interferes with the cross-linking of (Engesaeter et al 1980) Several *in* udies (Kaitila 1971, West & Storey ave indicated that tetracyclines exert ain effect on bone by inhibiting the tion. *In vivo* studies, however, have 1 confusing results (Bevelander et al 'gawa et al 1961, Harris et al 1968, ndson 1971)

present study was undertaken to elucidate the *in vivo* effect of oxy- :line on calcification of bone The mineralization was assayed by in- tion of strontium-85 into bones (Cohn nano 1967) and the rate of collagen ıs by measuring ^{14}C hydroxyproline from ^{14}C-proline (Firschein 1969) sotope measurements were supported rminations of the content of calcium, orus and collagen in the bones.

MATERIALS AND METHODS

Fifty outbred male Wistar/Af/Han/Mol SPF rats were used At the start of the experiment the animals were 23 days old, weighing 33–37 g They were kept five in each cage and fed water and Norwegian standard diet for rats (containing 0 9 per cent calcium and 0 7 per cent phosphorus) *ad libitum* The rats were divided into two weight-matched groups of 20 animals, one oxytetracycline treated and the other control. Ten rats were killed at the beginning of the experiment to obtain origin values of bone size and composition

The treated animals received 2.8 mg oxytetracycline (Terramycin® Intravenous, Pfizer) in 0 5 ml water as intraperitoneal injections every twelfth hour for 7 days. As the rats grew rapidly the dose in mg/kg/day was higher initially than at the end, in the middle of the period 74 mg/kg was given twice a day The control rats received corresponding injections of the vehicle. Plasma concentrations of oxytetracycline were determined on the fifth day of medication by the paperdisc method of AB-biodisk (Stockholm, Sweden) (Jalling et al. 1972)

Twenty-four hours before the rats were killed 5 μCi carrier free strontium-85 chloride

0. 80 030459–07$02.50 0

(330 Ci/mmol) and 15 μCi L-(U-^{14}C)proline (285 mCi/mmol) (The Radiochemical Centre, Amersham) per 100 g body weight were injected intraperitoneally

On the third and the seventh day of the medication 10 rats from each group were anaesthetized with ether and blood was collected by puncture of the aorta at the iliac bifurcation The animals were then killed by exsanguination Both femurs were immediately dissected free and the length measured (from the top of caput to the distal end of the medial condyle) with a sliding callipers (accuracy of ±0 01 mm) Soft tissues, cartilages and epiphyses were removed Both femorae were then placed in acetone for 7 days with two changes of acetone and air dried at 35° C until constant weight (dry weight) was obtained The bones were then hydrolyzed in 4 ml 6M HCl at 125° C for 18 hours.

As hydroxyproline is practically unique to collagen, quantitation of collagen was performed

[illegible]

proline to ^{14}C-hydroxyproline (Firschein 1969). Mineralization rate was assessed by measuring the content of strontium-85 The bone hydrolysates, containing both ^{85}Sr and ^{14}C, were first counted in a well counter (Auto-Gamma Scintillation Spectrometer, Packard Instr Comp) to determine the content of ^{85}Sr (gamma-emitter), without interference from ^{14}C (beta-emitter) (Firschein 1969) The counting efficiency for ^{85}Sr was found to be 26 per cent Dowex 50W columns were used to separate ^{14}C-hydroxyproline from ^{14}C-proline, as described by Firschein (1969) In addition, these columns also retain ^{85}Sr (Firschein 1969) Every sample was, however, checked in the Auto-Gamma Scintillation Spectrometer to make sure no gamma-emitter was present, before the radioactivity of the isolated ^{14}C-hydroxyproline was assessed in a liquid scintillation counter (Nuclear Chicago Mark II) with Dilusolve® (Packard Instr Corp) as scintillation solution Counting efficiency, determined by the two channel ratio method, was 70 per cent

The concentrations of calcium and phosphorus in the hydrolysates were measured using a Bichromatic Analyzer (Abbott Laboratories, Diagnostic Division, USA) The Bichromatic Analyzer was also applied to measure serum concentrations of calcium, phosphorus and albumin The kits used in the analyses were from the Abbott Laboratories (A-Gent Albumin and Calcium) and the Phosphorus Auto/Stat kit of Pierce Chemical Co (Rockford, Illinois, USA).

The median with 25- and 75-fractiles was used to express the average and the dispersion of the measured values. Statistical significance was evaluated by the Wilcoxon test for two samples and differences were considered significant when $P \leq 0.05$ (Diem & Lentner 1975).

RESULTS

On the fifth day of medication the plasma concentrations of oxytetracycline were measured Two hours after administration of oxytetracycline the plasma concentration was 15 (14–16) μg/ml, 6 hours after administration it was 2 6 (2 3–3 0) μg/ml, and 12 hours after administration less than 1 μg/ml

The increase in the body weight of the antibiotic-treated rats was significantly less than that of the controls (Figure 1) [illegible] illustrates longitudinal growth of the femur The bones of the animals receiving oxytetracycline were significantly shorter than those of controls on both the third and seventh day of medication 1 and 3 per cent respectively Corresponding reductions were revealed in the cortex thickness and the diameters in the middle of the diaphyses At the end of the experiment the dry weight of the femurs was found to

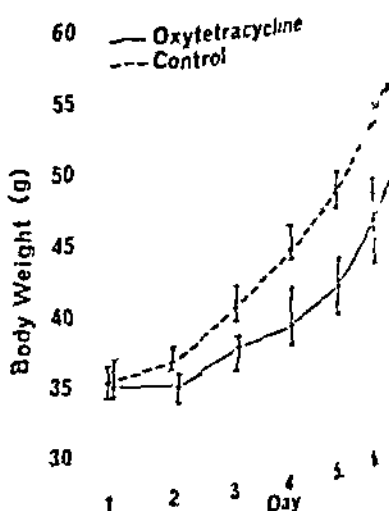
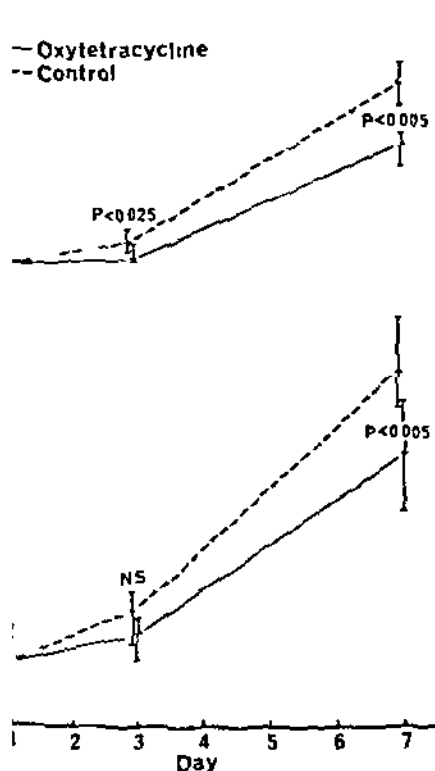


Figure 1 Body weight of the antibiotic-treated and the control rats (median with 25- and 75-fractiles)



Length of right femur (above) and dry of both femurs (below) of the cycline-treated and the control rats with 25- and 75 fractiles)

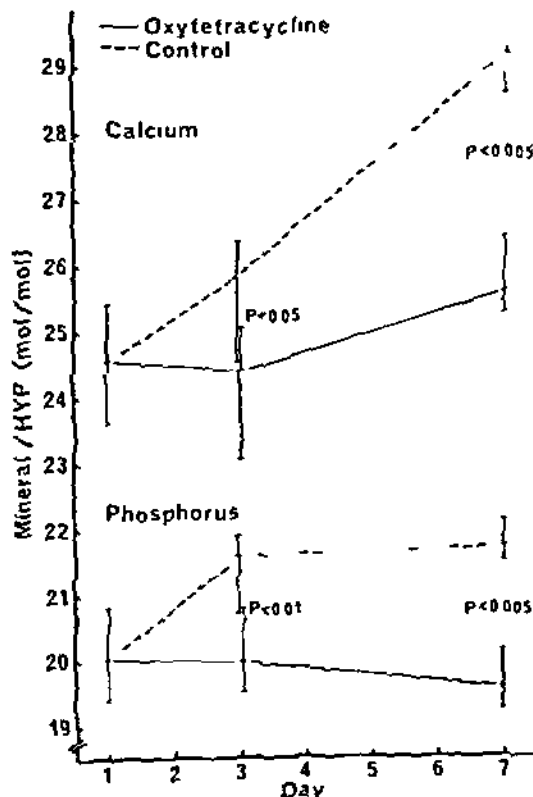


Figure 3 Content of calcium (above) and phosphorus (below) related to the content of hydroxyproline (collagen) in the femurs of the oxytetracycline-treated and the control rats (median with 25 and 75 fractiles)

t less in the oxytetracycline-treated n in the controls (Figure 2)

biochemical analyses revealed cor-ing differences On the seventh day of ion the content of calcium and orus in the bones of antibiotic-treated was significantly reduced (22 and 23 ent, respectively) compared with while the reduction in collagen was 10 per cent No significant ces could, however, be detected on the day To express the degree of lization of the bones, the content of and phosphorus was related to the of hydroxyproline (collagen) (Figure reduced calcium/collagen and orus/collagen ratio were found in the of the antibiotic treated rats. The differences between the two groups were 5 per cent for calcium and 8 per cent for phosphorus on the third day of medication, and on the seventh day 11 per cent for calcium and 10 per cent for phosphorus.

The content of ^{85}Sr in the femurs related to the collagen content, the specific activity of ^{85}Sr, was significantly less for the rats receiving oxytetracycline than for the controls on the seventh, but not on the third day of medication ($P=0\ 06$) (Table 1) No differences in the specific activity of ^{14}C-hydroxyproline were found (Table 1) The relationship between these specific activity values, the ratio of the specific activity of ^{85}Sr to the specific activity of ^{14}C-hydroxyproline,

Table 1 Specific activity of strontium 85 and ^{14}C-hydroxyproline, and the ratio of specific activity of ^{85}Sr to ^{14}C-hydroxyproline in the femurs of oxytetracycline-treated and control rats Four to ten animals in each group
Data given as median with 25- and 75 fractiles

Day	Sp act of ^{85}Sr(dpm/nmol hyp)			Sp act of ^{14}C-hyp(dpm/nmol hyp)			Sp act ^{85}Sr/Sp act ^{14}C-hyp(dpm/dpm)		
	Oxytetracycline		Control	Oxytetracycline		Control	Oxytetracycline		Control
3rd	13 46 (13 33–14 56)	NS	15 42 (14 66–17 06)	2 46 (2 28–2 64)	NS	2.38 (2 11–2 67)	5 06 (4 96–5 24)	$P<0\ 01$	5 84 (5 68–6 15)
7th	13 39 (12 42–14 00)	$P<0\ 05$	14 24 (13 58–14 95)	2 04 (1 88–2 12)	NS	2 07 (1 94–2 20)	6 15 (5 99–6 45)	$P<0\ 01$	6 86 (6 66–7 17)

NS = Not significant

Table 2 Concentration of calcium, phosphorus and albumin in serum of oxytetracycline treated and control rats Ten animals in each group
Data given as median with 25- and 75 fractiles

Day	Calcium (mmol/l)			Phosphorus (mmol/l)			Albumin (g/l)		
	Oxytetracycline		Control	Oxytetracycline		Control	Oxytetracycline		Control
3rd	2 75 (2 [illegible]7–2 85)	NS	2.78 (2 70–2 84)	2 98 (2 87–3 22)	$P<0\ 01$	2 36 (2 [illegible]1–2 67)	38 [illegible] (38 0–40 6)	NS	38 8 (3[illegible] 7–40 7)
7th	2 83 (2 72–2 [illegible]0)	$P<0\ 05$	2 [illegible] (2 [illegible]–2 72)	3 16 (2 82–3 [illegible])	NS	2 93 (2 [illegible]0–3 [illegible])	42 7 (41 7–44 2)	NS	41 7 (4[illegible]–4[illegible] [illegible])

he accretion ratio (Firschein 1969) is own in Table 1 The accretion ratio significantly lower in bone of acycline-treated rats than in controls h the third and the seventh day of tion

concentrations of calcium, phosphorus ɔumin in serum are given in Table 2 red with the controls, the antibiotic-animals had significantly higher serum of phosphorus on the third day (16 per nd of calcium on the seventh day of tion (6 per cent)

JSSION

iain features of this study are that of rats receiving oxytetracycline had l size and reduced content of calcium, orus and collagen when compared controls. Furthermore the antibiotic ound to affect the accretion of um-85, but not the accretion of ^{14}C-yproline

na concentrations of oxytetracycline in periment were comparable with human utic levels (Otten et al 1975) To these concentrations, however, the ad to be about five times higher than nended in humans (30 mg/kg/day) nan & Gilman 1975)

demonstrated reduction in body of the oxytetracycline-treated animals accordance with earlier experience aeter & Skar 1978) This observation be explained by the effects on skeletal Other possibilities have to be con-l, such as a general inhibition of synthesis as described by Yeh & Shils although no inhibition of albumin or n synthesis by oxytetracycline has been strated in this or in a previous study aeter et al 1980) An alternative ex-on could be that this broad spectrum tic may have caused such a substantial ance of the normal symbiosis between t and the intestinal microorganisms (Gustafsson 1971) that it would interfere with the growth of the animal

^{14}C-proline and strontium-85 are convenient isotopes to use in simultaneous studies of collagen and mineral dynamics (Firschein 1969) Although the general reservations about such isotope techniques have to be taken into consideration in the interpretation of the results (Laitinen 1967, Firschein 1969) the content of ^{14}C-hydroxyproline and ^{85}Sr in the bones indicates the rate of collagen synthesis and of mineralization during the 24-hour period

Judging by the specific activity of ^{14}C-hydroxyproline, collagen synthesis was not inhibited by the antibiotic. The content of collagen in the bones of the oxytetracycline-treated rats compared with the controls was, however, significantly less on the seventh day of medication These data might be explained by an increased resorption of collagen in the treated rats This assumption might also be supported by our previous finding that oxytetracycline may interfere with the cross-linking of collagen (Engesaeter et al 1980) Collagen with defective cross-links has been shown to be more susceptible to degradation than normal collagen (Harris & Farrell 1972)

Enhanced resorption of bone cannot, however, explain the observed reduction in the accretion ratio (^{85}Sr/^{14}C-hydroxyproline) and the reduced content of strontium-85, calcium and phosphorus in bones of oxytetracycline-treated rats. The only reasonable interpretation of these findings seems to be inhibition of the mineralization process by the antibiotic, either directly or indirectly

The mechanism by which tetracyclines interfere with the mineralization process is poorly understood Bevelander et al (1960) concluded that "the inhibition of mineralization following injection of tetracycline is probably due to the reduction in the number of free cations which subsequently results in the formation of a bone deficient in minerals" One mole of oxytetracycline may form complexes with 1–2 moles of calcium depending on the relative concentrations

(Ibsen & Urist 1962) The amount of calcium bound to the antibiotic at an oxytetracycline concentration of 10 µg/ml would, however, represent only about 1 per cent of the total calcium in serum It seems therefore, difficult to explain in this way the negative effect of tetracycline on the mineralization as has also been stated by Sternberg (1966) and Shapiro et al (1977)

In vitro experiments have indicated that tetracyclines inhibit bone mineralization by preventing the transformation of amorphous calcium phosphate to crystalline apatite (Wadkins et al 1974) Tetracyclines have also been suggested to induce defects of calcification by inhibiting the accumulation of calcium in the mitochondria of cells preparing for mineralization (Shapiro et al 1977) This intramitochondrial accumulation of calcium is postulated by Lehninger (1970) to be an essential first step in the calcification process Shapiro et al (1977) found in their tetracycline experiments with chickens a profound drop in the intramitochondrial calcium concentrations and, as also observed in the present study, an increase in the serum calcium level

Tetracyclines could, however, be considered to interfere with the calcification process in an indirect manner It has been proposed that the formation of intermolecular cross links in collagen may be a prerequisite for appropriate mineralization of bone matrix (Avioli 1973, Rosenquist et al 1977) Our previous finding that oxytetracycline may impair the cross linking of collagen ... et al 1980) might therefore, indicate that the reduced mineralization is secondary to an induced defect in the collagen framework

REFERENCES

Avioli L V (1973) Collagen metabolism uremia and bone *Kidney Int* 4, 105–115

Bevelander G Nakahara H & Rolle G K (1960) The effect of tetracycline on the development of the skeletal system of the chick embryo *Develop Biol* 2, 298–312

Cohn S H & Gusmano E A (195[illegible]) ... strontium and calcium skeletal ... the rat *Proc Soc exp Biol* (N ... 79–83

Diem K & Lentner C (eds) (19[illegible]) ... Geigy *Scientific Tables* 7th ed ... Ciba-Geigy Ltd., Basle

Engesaeter L B & Skar A G ... oxytetracycline on ... bone and skin in young rats ... *scand* 49, 529–534

Engesaeter L B Underdal, T & Le... (1980) Effects of oxytetracycline on ... and synthesis of collagen in young ... *orthop scand* 51, 43–48

Firschein H E (1969) Collagen and ... dynamics in bone *Clin Orthop* 66, ...

Goodman L S & Gilman, A (eds) (1... *pharmacological basis of therapeutics* ... 1704 pp Macmillan Publ Co, New ...

Gudmundson C (1971) C... disturbance of fracture healing *J T*... 511–517

Gustafsson B E (1971) P... characteristics of germfree animals ... *enteritis (Chrohn s disease)* (Ed E... Larsson T) pp 233 243 S... Nordiska Bokhandelns Førlag Stock...

Harris E D Jr & Farrell, M ... Resistance to collagenase A ... collagen fibrils cross-linked by for... *Biochim biophys Acta (Amst)* 2...

Harris W H Lavorgna J Hamble... Haywood E A (1968) The inhib... sification *in vitro* *Clin Orthop* 61 ...

Ibsen K H & Urist M R (196?) Co... calcium and magnesium with oxy... *Proc Soc exp Biol (N Y)* 109 7...

Jalling B Malmborg A-S Lind... Boreus, L O (1972) Evalu... micromethod for determination of ... concentrations in plasma *Europ* ... *Pharmacol* 4, 105–157

Kaitila I (1971) Effect of tetra... mineralization in cycloheximide-tr... *in vitro* *Calcif Tiss Res* 7, 46–5...

Laitinen O (1967) The metabolism ... and its hormonal control in the ... *endocr (Kbh)* Suppl 120

Lehninger A L (1970) Mitochondria ... ion transport *Biochem J* 119, 1...

Ogawa E Fukuda R Suzuki, S & ... (1961) Studies on the elimination of ... strontium 2. Effect of the admi... tetracycline *Gunma J med Sci* 1...

Otten H Plempel, M & Siegenthaler ... (1975) *Antibiotika Fibel*. 4th ed. ... Georg Thieme Verlag Stuttgart

ıst, J B., Baylink, D J & Spengler D 1977) The effect of β-aminopropionitrile N) on bone mineralization *Proc Soc Biol (N Y)* **154**, 310–313
I M., Burke A C & Lee N H (1977) of tetracycline on chondrocyte mitochon an explanation of tetracycline-induced ts of mineralized tissues. *Biochem macol.* **26**, 595–600
g J (1966) Effect of tetracyclines on the ver of calcium-45 in young rats. *Int J Radiat* **17**, 497 512.
Wadkins, C. L. Luben R Thomas, M & Humphreys, R (1974) Physical biochemistry of calcification *Clin Orthop* **99**, 246–266
West V C & Storey E (1972) The *in vitro* effect of fluoride and tetracycline on phase transformation of a calcium phosphate *Calcif Tiss Res* **9**, 207–215
Yeh S D J & Shils, M E (1966) Tetracycline and incorporation of amino acids into proteins of rat tissues. *Proc Soc exp Biol (N Y)* **121**, 729 734


ondence to Lars B Engesaeter Institute for Surgical Research, Rikshospitalet Oslo 1 Norway

nop scand 51, 467–470 1980

ECTS OF CLOXACILLIN, DOXYCYCLINE, FUSIDIC) AND LINCOMYCIN ON MINERALIZATION AND UBILITY OF COLLAGEN IN YOUNG RATS

B ENGESAETER, TRINE UNDERDAL
TE H N LYNGAAS

.e for Surgical Research, Rikshospitalet, University of Oslo, Norway



receiving ...
the conce...
antibiotic...

Key words albumin, antibiotics, bones calcification calcium, collagen phosphorus, skin, solubility

Accepted 31 viii 79

previous study (Engesaeter & Skar 1979) ntibiotics doxycycline, fusidic acid and nycin were found to cause reduced th of *bones* and reduced tensile strength tact skin in young rats Such unwanted s were, however, not detected in a group ts receiving cloxacillin

ie purpose of the present investigation to examine the effects of these four iotics on the solubility (cross-linking) of gen and on the mineralization of bones. e two parameters are of particular rest since another antibiotic, oxy-cyline, *has been* found to impair both gen solubility and bone mineralization gesaeter et al 1980 a, b)

TERIALS AND METHODS

male Wistar rats, initially weighing 39–44 g used The animals were divided into five groups of 10 rats The first group received cloxacillin the second doxycycline, the third fusidic acid and the fourth lincomycin The fifth group of animals served as control receiving only isotonic sodium chloride solution The antibiotics were administered as intraperitoneal injections every 12th hour for 14 days Fusidic acid, however, was given by a stomach tube, as intraperitoneal injections in a pilot study caused massive abdominal adhesions The doses of the drugs in mg/kg/day were 2–12 times higher than the recommended human doses. Plasma concentrations of the antibiotics were, however, comparable with the therapeutic levels in humans Further information about the animals and the medication was reported in a previous paper dealing with the mechanical properties of bone and skin of these rats (Engesaeter & Skar 1979)

At the end of the 14-day medication period the rats were anaesthetized with ether and blood was collected by puncture of the aorta, death followed by exsanguination Bones and skin were immediately removed and after mechanical testing stored at $-20°C$ until biochemical examination

–6470/80, 030467–04$02.50 0

Bone analyses were performed on the left femur after the soft tissues, the cartilages and the epiphyses had been removed The bones were hydrolyzed in 6M HCl at 125°C for 18 hours, and the content of calcium, phosphorus and collagen was measured as described below

Skin analyses were performed on skin from the back of the animals, i e the most cranial of the three intact skin specimens used in the mechanical testing The fraction of collagen soluble in saline solution was determined by modifications of the methods of Kivirikko et al (1965) and Gudmundson (1971), as described previously (Engesaeter et al 1980b) In short, the skin specimens were defatted and dried in acetone for 7 days, followed by drying in air at 35°C until consta[illegible] was then [illegible] 18K, Janke [illegible]) in 0 15M NaCl solution before extraction at 4°C in [illegible]

insoluble" collagen fraction Both fractions were hydrolyzed in HCl at 125°C for 18 hours before the collagen content was determined [illegible]

measuring hydroxyproline, using the method of Firschein (1969) The concentrations of calcium and phosphorus in the bone hydrolysates were assessed using the Abbott Bichromatic Analyzer (Abbott Laboratories, Diagnostic Division USA) The Bichromatic Analyzer was also applied to measure serum concentrations of calcium, phosphorus and albumin The kits used in the analyses were those from Abbott Laboratories (A-Gent Calcium and Albumin) and the Phosphorus Auto/Stat kit of Pierce Chemical Comp (Rockford, Illinois, USA)

Serum copper concentration was determined indirectly by measuring ceruloplasmin oxidase activity in serum using the method of Johnson et (1967)

The median with 25- and 7[illegible] to express the average and the measured values. Statistical signific[illegible] evaluated by the Wilcoxon test for two [illegible] and differences were considered sign[illegible] $P \leqslant 0.05$ (Diem & Lentner 1975).

RESULTS

To express the degree [illegible] bones the content of calcium [illegible] was related to the collagen content. T[illegible] shows that the rats receiving [illegible] a significantly lower calcium/collagen [illegible] per cent) and phosphorus/collagen rat[illegible] cent) than the controls. No effects on [illegible] or phosphorus/collagen ratio [illegible] the other antibiotic groups.

The skin analyses did not reveal ch[illegible] solubility of collagen in any of the [illegible] receiving antibiotics when compared [illegible] controls (Table 2)

Serum analyses however showed t[illegible] receiving doxycycline had significan[illegible] concentrations of albumin (5 per cen[illegible] controls (Table 3) Furthermore Lin[illegible] treated animals had reduced serum l[illegible] phosphorus (13 per cent) compared [illegible] controls. No other significant differ[illegible] serum concentrations of calcium, pho[illegible] albumin or ceruloplasmin were found b[illegible] antibiotic treated animals and contro[illegible]

DISCUSSION

The present study revealed that the b[illegible] doxycycline treated rats had a [illegible]

Table 1 Content of calcium and phosphorus related to the content of hydroxyproline (collagen[illegible]) left femur of the rats receiving cloxacillin, doxycycline fusidic acid or lincomycin and of the co[illegible] Ten animals in each group *$P < 0.05$ **$P = 0.01$ *(Median with 25 and 75 fractiles)*

	Cloxacillin	Doxycycline	Fusidic acid	Lincomycin	Co[illegible]
Ca/Hyp (mol/mol)	31 08 (29 45–31 78)	30 28 * (29 92–31 17)	30 42 (30 06–31 83)	30.36 (30 08–31 21)	[illegible]
P/Hyp (mol/mol)	23 38 (21 71–23 61)	22 19 ** (21 79–23 04)	22 48 (21 87–23 29)	22.56 (22.29–23 40)	[illegible]

	Cloxacillin	Doxycycline	Fusidic acid	Lincomycin	Control
/total (%)	3 25 (3 01–3 59)	3 85 (3 10–4 31)	3 46 (3 07–3 88)	3 59 (3 21–4 07)	3 64 (3 29–4 11)

of calcium and phosphorus compared controls. No effect of the solubility ial collagen, however, could be after the administration of the antibiotics.

reduced calcium/collagen and us/collagen ratios observed in bones receiving doxycycline indicate im- of the mineral metabolism These correspond well with those obtained ly of another tetracycline antibiotic, cycline which was found to reduce rporation of strontium-85 and to ie content of calcium and phosphorus Engesaeter et al 1980a)

en molecules are normally linked in fibres by specific covalent bonds s cross links. If this cross linking is l the fibres do not attain the y tensile strength (Uitto & Lichtenstein 1976) and the collagen becomes more soluble (Lapière & Nusgens 1976) This was proposed as a possible explanation for the reduced mechanical strength and increased collagen solubility found in the oxytetracycline treated rats (Engesaeter et al. 1980b) In the present study no effects on the solubility of collagen were detected in any of the antibiotic treated groups.

Doxycycline treated rats had lower albumin concentrations in serum than the controls. This may indicate impairment of albumin synthesis since doxycycline inhibits the growth of microorganisms by interfering with the protein synthesis (Goodman & Gilman 1975) Several studies (Yeh & Shils 1966 Morgan & Ribush 1972, Vazquez 1974) have shown that tetracyclines may also affect the animal protein synthesis, although oxytetracycline has not been found to affect the

Serum concentrations of calcium phosphorus albumin and ceruloplasmin of rats receiving n doxycycline fusidic acid or lincomycin and of the control rats Ten animals in each group alcium, phosphorus and albumin analyses five in the ceruloplasmin analyses • $P < 0.05$ *(Median with 25 and 57 fractiles)*

	Cloxacillin	Doxycycline	Fusidic acid	Lincomycin	Control
l)	2 82 (2 69–2.85)	2 87 (2 81–2 98)	2.75 (2 73–2.79)	2.72 (2.67–2 86)	2.81 (2.78–2.83)
us l)	2.90 (2 77–3 08)	3 19 (2 73–3 40)	3 03 (2.73–3 61)	2.70 • (2 38–3 01)	3 10 (2.87–3 40)
	49 4 (48 2–50 6)	47 8 • (46 9–50 1)	50 0 (48 4–50 6)	50 6 (49 4–51 4)	50 3 (48 7–51 7)
asmin l)	0 14 (0 10–0 15)	0 16 (0 14–0 18)	0 14 (0 13–0 15)	0 15 (0 13–0 20)	0.15 (0 14–0 20)

albumin or collagen synthesis (Engesaeter et al 1980b) or the concentration of albumin in serum (Engesaeter et al 1980a) in our previous experiments If these albumin findings in the doxycycline treated rats indicate a general inhibition in synthesis of proteins including collagen the effect of doxycycline on the cross-linking of collagen might then have been masked since a reduced rate of collagen synthesis also reduces the solubility (Gross 1958, Dawson & Milne 1978)

Serum copper concentration (ceruloplasmin) was measured as copper is a cofactor for the enzyme lysyl oxidase which catalyzes the first step in the cross linking process of collagen (Siegel et al 1970) No reductions in serum copper concentrations were, however, revealed

The reduced concentration of phosphorus in serum of lincomycin treated animals compared with the controls seems difficult to explain from the presented data

This study shows that doxycycline may affect mineralization of bone and perhaps protein synthesis The present biochemical findings however, provide no definite explanations for the previously observed reductions in dermal strength of rats receiving doxycycline fusidic acid or lincomycin (Engesaeter & Skar 1979)

REFERENCES

Dawson R & Milne G (1978) The effects of dietary nitrogen level on the collagen of rat skin *Brit J Nutr* **39**, 181–192

Diem K & Lentner C. (eds) (1975) Documenta Geigy *Scientific Tables* 7th ed 810 pp Ciba Geigy Ltd Basle

Engesaeter L B & Skar A G (1979) Effects of cloxacillin doxycycline fusidic acid and lincomycin on the mechanical properties of bone and skin in young rats *Acta orthop scand* **50**, 245–250

Engesaeter L B Underdal, T & [illegible] (1980a) Effects of oxytetracycline [illegible] ation of bone in young rats *Acta orth* [illegible] **51**, 459–465

Engesaeter L B Underdal, T & [illegible] (1980b) Effects of oxytetracycline [illegible] and synthesis of collagen in young [illegible] *orthop scand* **51**, 43 48.

Firschein H E. (1969) Collagen [illegible] dynamics in bone *Clin. Orthop* 66, [illegible]

Goodman L S & Gilman, A (eds) [illegible] *pharmacological basis of therapeutics* [illegible] 1704 pp Macmillan Publ. Co, [illegible]

Gross J (1958) Studies on the [illegible] collagen II The influence of [illegible] neutral salt extracts of guinea pig [illegible] *exp Med* **107**, 265 277

Gudmundson C (1971) Oxytetracycline [illegible] disturbance of fracture healing *J T* [illegible] 511–517

Johnson D A Osaki S & Frieden, E [illegible] micromethod for the determination of [illegible] idase (ceruloplasmin) in human serum [illegible] *Chem* **13**, 142–150

Kivirikko K I Laitinen O Aer J & [illegible] (1965) Studies with [illegible]C proline on the [illegible] cortisone on the metabolism of collagen [illegible] rat *Biochem. Pharmacol.* 14 [illegible]

Lapière C M & Nusgens, B (19[illegible]) [illegible] pathology at the molecular level. [illegible] *Biochemistry of collagen.* (Ed. Rama[illegible] G N & Reddi A H) 536 pp [illegible] New York–London.

LeRoy E C. (1967) The [illegible] significance of hydroxyproline [illegible] man *Advanc clin. Chem.* 10 213–[illegible]

Morgan T & Ribush N (1972) The [illegible] *tetracycline* and doxycycline [illegible] metabolism *Med J Aust.* 1 55–[illegible]

Siegel, R C Pinnell S R & Martin, G R [illegible] Cross linking of collagen and elastin [illegible] of lysyl oxidase *Biochemistry* [illegible] 4486–4492

Uitto J & Lichtenstein, J R (19[illegible]) [illegible] the biochemistry of collagen in diseases [illegible] nective tissue *J invest Derm.* 66, [illegible]

Vazquez D (1974) Inhibitors of protein [illegible] *FEBS Letters* 40 (Suppl.), 63–84

Yeh S D J & Shils, M E (1966) [illegible] and incorporation of amino acids [illegible] of rat tissues. *Proc Soc exp Biol* [illegible] 729–734

Correspondence to Lars B Engesaeter M D Institute for Surgical Research, Rikshospitalet [illegible] of Oslo Oslo 1 Norway

…op scand. 51, 471–473, 1980

…OBACTERIUM KANSASII AND OSTEOARTICULAR …IONS

…AKHANPAL, S M TULI, HARDAS SINGH & P C SEN

…nents of Orthopaedics and Microbiology, Institute of Medical Sciences, Banaras Hindu Univer-…aranasi, India

Four patients with an unusual type of bone lesion are reported. The …

typical of osteoarticular tuberculosis.

Key words *Mycobacterium Kansasii* *Mycobacterium tuberculosis*, osteoarticular lesions

Accepted 17 ix.79

…ogens have been isolated from …ular lesions in lungs and lymph nodes …ny et al. 1943, Runyon 1959, Goyal & …962) but these organisms have not been … to cause osteoarticular lesions This … presents four patients with os…cular lesions from which chromogens … isolated From another case (not …ed in the present report) a mixed …h consisting of Scoto-chromogens and *…bacterium tuberculosis* was isolated The …l and radiological picture of the lesions, …he histological appearance of the tissue …these lesions, were quite unlike those of …l tubercular lesions. These unusual …res necessitated the reporting of these

… REPORTS

… a 30-year-old female came to the …paedic Outpatient Department of the …ute of Medical Sciences, Banaras Hindu …rsity Varanasi, in the first week of …nber 1969, complaining of a painful swelling …onths' duration on the lateral aspect of the left forearm near the wrist joint She gave a vague history of constitutional symptoms on interrogation On examination there was an oblong, smooth, tender, cystic and fluctuant swelling, 2 5 cm in diameter, along the lateral border of the left forearm attached to the lower end of the radius Radiologically (Figure 1) there was a lytic …

pyogenic organisms. On Lowenstein Jensen medium chromogens were isolated No pyogenic organisms were isolated. Histology revealed …

upper part of the arm. Movements of the shoulder joint were painful and restricted. Radiologically there was a lytic lesion in the upper end of the humerus surrounded by osteoporosis (Figure 2). Based on the clinical and radiological findings, it was diagnosed as a 'tubercular lesion', pyogenic

…6470/80/030471–03$02.50/0



Figure 1 Case 1 X ray showing a lytic lesion in the lower end of the radius

Figure 3 Case 3 X ray showing a l... the distal part of the femur with osteop...



Figure 2 Case 2 X ray showing a lytic lesion in the head of the humerus

infection and malignancy were kept in mind Pus aspirated from the fluctuant site was cultured for acid fast and pyogenic organisms Chromogens were isolated from the culture on Lowenstein Jensen medium The culture was negative for pyogenic organisms Histology of the biopsy material gave a picture of a chronic eosinophilic granuloma

H D S a 15 year-old male attended the department in February 1970 with com... fever pain and swelling in the lower p... right thigh of 2 months duration The... increased in size for some time and t... stationary Clinically there was a... tender and cystic swelling in the lower p... right thigh The cortex of the femur wa... and the knee was free Radiologically th... lytic lesions in the lower end of the fe... rounded by marked osteoporosis (Fig... diagnosis of tuberculosis of the lower e... femur was made keeping in mind the p... of pyogenic infection Pus was cultured... fast and pyogenic organisms. Culture for... organisms was negative but chromog... isolated on Lowenstein Jensen medium... of the curetted material revealed a pi... chronic inflammatory lesion

K P G a 34-year-old male att... November 1969 with complaints of a dis... sinus in the upper part of the ... months duration It started with a sw... swelling in the upper part of the chest... ruptured of its own accord and gave ri... discharging sinus. He had had some ... ment but to no avail. On examination the... serous discharge from the sinus. Rad... there was a lytic lesion in the ... periosteal reaction The lesion was ... diagnosed as tuberculous. The ... was and the material submitted to culture for ...

; and for acid fast bacilli Chromogens ted from Lowenstein Jensen medium No organisms could be isolated

SION

ur cases reported here osteoarticular ,ere suspected to be tuberculous in on clinical and radiological grounds) found to be caused by chromogens her investigation these organisms ound to be photochromogens *cterium Kansasii)* These were con the organisms responsible for the lesions, as no other organism could ed

indred and twenty five osteoarticular vere investigated from May 1969 to r 1971 for evidence of tuberculosis. seven had positive cultures for acid lli Four of these cultures were M (Lakhanpal t al 1976) These took 4–6 weeks to grow in the culture at 37°C and on further vere found to be photochromogenic v well at 37°C on subculture in 2–3 Radiologically the diaphyseal lesions and 3) could have been mistaken genic infection The radiological ice of the lesions caused by these *teria* was not typical of os lar tuberculosis Probably lesions by chromogens in bones and joints a radiological picture which is from the one caused by *terium tuberculosis* or pyogenic organisms To establish this however, needs further investigation of a large number of cases

From three of the lesions the material was submitted for histological examination The diagnosis in two patients (cases 1 and 3) was non specific chronic inflammation One case (case 2) was diagnosed as chronic eosinophilic granuloma Histopathological examination was not done in the remaining case (case 4) It is of interest to note that none of the cases investigated had a clear-out histological picture of tuberculous lesion It seems as if the basic pathology of the lesions caused by these organisms is different from the one caused by *Mycobacterium tuberculosis* This could be the reason for the atypical histological picture in the lesions caused by chromogens

REFERENCES

Goyal R K & Sen P C (1962) Laboratory diagnosis of tuberculosis in the present antibiotic era *Curr Med Pract* 5, 239–245

Lakhanpal V P Singh Hardas, Sen P C. & Tuli S M (1976) Bacteriological study in osteoarticular tuberculosis. *Indian J Orthop* 10, 13–17

Runyon E H (1959) Anonymous mycobacteria in pulmonary disease *Med Clin N Amer* 43, 273 290

Sweany H C Levington S A & Standnichenke A M S (1943) Tuberculous infection in people dying of causes other than tuberculosis. *Amer Rev Tuberc* 48, 131

ndence to Professor S M Tuli M S Ph D F A.M S Head of the Department of d cs, Institute of Medical Sciences, Banaras Hindu University Varanasi 221 005 India

ɔp scand. 51, 475–478, 1980

:RIOR TRANSPOSITION OF THE ULNAR NERVE

IHIN, A GANEL, B ROSENBERG & J ENGEL

urgery Unit, The Chaim Sheba Medical Center, Tel Hashomer affiliated with Sackler of Medicine, Tel Aviv University, Tel-Aviv, Israel

Twenty-four patients with 26 ulnar neuropathies in the elbow region were treated by anterior transposition of the ulnar nerve The dominant arm was involved in 14 of these patients

Improvement of paresthesia was found in 17 out of 21 (75 per cent) in this series of patients, 10 out of 18 (55 per cent) had improvement of sensation, 7 out of 14 (50 per cent) had less pain 10 out of 14 (71 per cent) showed an increase in motor power, but only 2 out of 12 patients (16 per cent) with *long-standing muscle atrophy showed any improvement in their* condition.

Electromyographic studies (EMG) were carried out before and after operation. The postoperative studies revealed increased motor conduction velocity within the elbow segment of the ulnar nerve in 15 patients. Slowing in ulnar nerve conduction velocity was found in 3 patients, and in 8 the EMG remained unchanged

Our EMG series indicated that patients with a conduction velocity of less than 40 m/s will certainly benefit more from anterior transposition of the ulnar nerve than will patients whose measurements are within the normal range

Key words anterior transposition electromyography, neuropathy

Accepted 10 viii 79

pathies of the ulnar nerve at the elbow result in severe impairment of hand on secondary to pain, paresthesia, or f motor function

rous etiologies for the pathogenesis of nerve lesions at the elbow have been sed They include primary and delayed nerve palsies which result from various atic and non-traumatic factors berg & Larsen 1973, Gay & Love

purpose of the present paper is to it the clinical and electromyographic perative results following decompression nterior transposition of the ulnar nerve series of 24 patients.

PATIENTS

Twenty-four patients in our department underwent surgery for entrapment neuropathy of the ulnar nerve during the period 1971–1976 They included 17 men and 7 women whose ages *ranged from 19 to 68 years (average 40 years).* The left hand was involved in 12 cases and the right in 10 2 had bilateral involvement In 14 cases the dominant hand was involved Only 4 patients had post fracture ulnar nerve entrapment, in 20 patients idiopathic etiology was diagnosed

The mean duration of symptoms from the initial appearance to actual surgery was 8 months, ranging from 4 months to 2 years. Patients with long-standing symptoms of over 2 years were not treated by surgery

470 80 030475–04$02.50 0

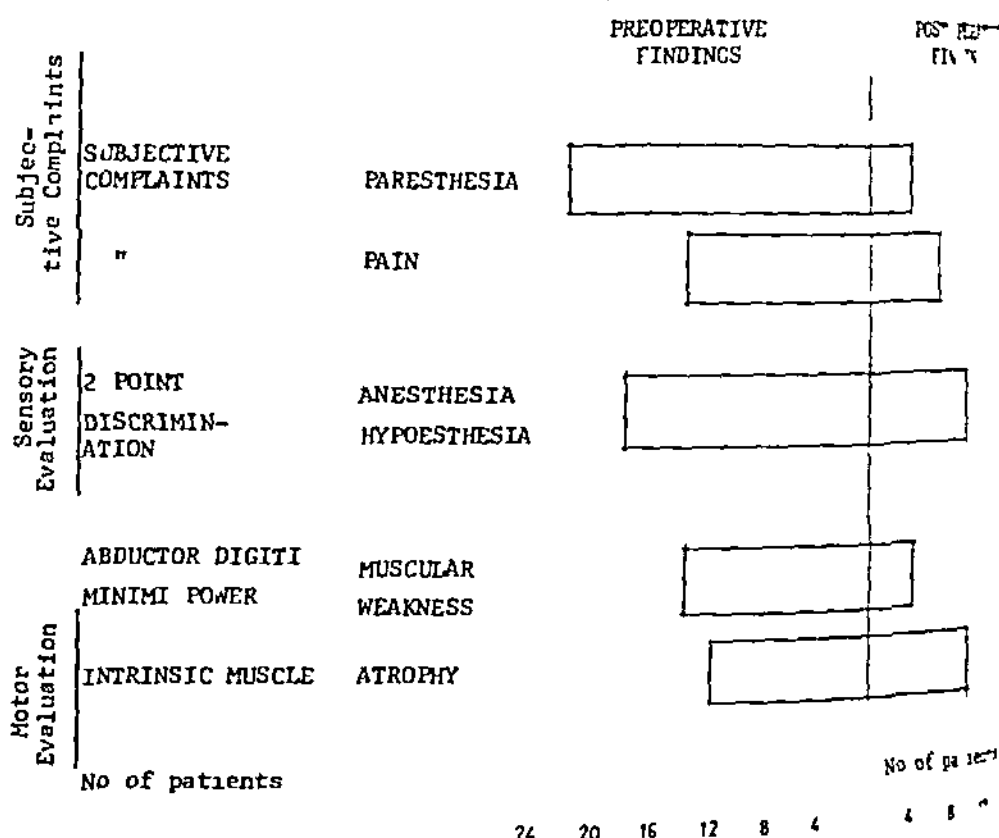


Figure 1 Clinical symptoms and results of clinical examinations

METHODS

Clinical examination included the 2 point discrimination test for sensation Motor power was evaluated by clinical examination of the abductor digiti minimi and graded from 0–5 Evaluation of intrinsic muscle atrophy was made by inspection The range of elbow motion was measured with a goniometer Plain x rays of the elbow consisting of postero-anterior lateral and two oblique views as well as electromyographic examination of the ulnar nerve were performed

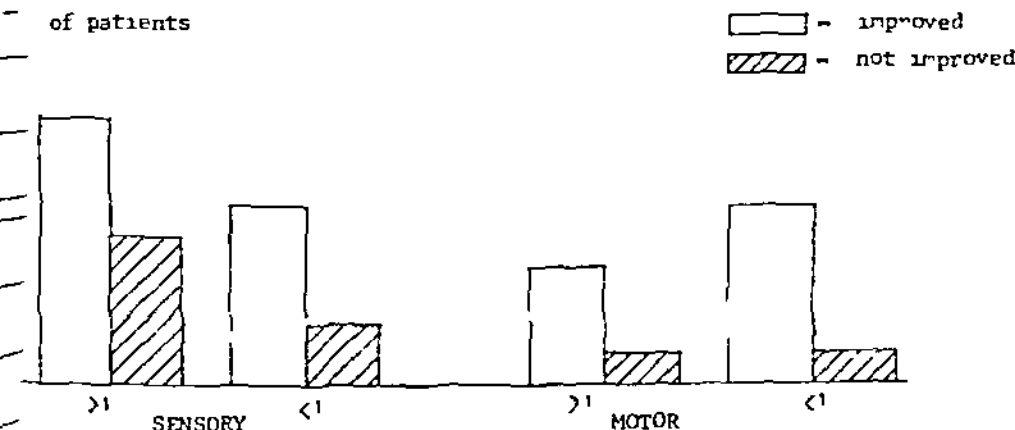
These examinations were repeated 6 months after surgery Anterior transposition of the ulnar nerve without epicondylectomy was performed on all the patients in this series Two of them had to undergo further surgery due to recurrence of symptoms A neurolysis was performed in one and an epicondylectomy was carried out in the other patient

RESULTS

The professional distribution of our patients failed to demonstrate predisposing factors, as there were 13 non manual workers [illegible] manual workers.

Figure 1 summarizes the [illegible] symptoms before and after surgery [illegible] 17 out of 21 cases (75 per cent) [illegible] paresthesia improved 10 out of [illegible] per cent) gained improvement in [illegible] out of 14 (50 per cent) had less pain [illegible] 14 (71 per cent) showed an increase [illegible] power but only 2 out of 12 [illegible] per cent) with long standing muscle [illegible] showed improvement in their [illegible]

For further evaluation the patients [illegible] divided into two groups Group A [illegible] duration of symptoms of over 1 year [illegible] surgery and Group B with duration [illegible] than 1 year prior to surgery [illegible] symptoms improved in 9 out of 11 [illegible] Group A, and in 6 out of 8 in [illegible] Motor symptoms improved in [illegible] patients in Group A whereas in Group [illegible] out of 6 patients benefited [illegible] (Figure 2)



igure 2 Improvement of sensory and motor function in relation to duration of symptoms

...teen patients gained relief after having ...e operation Two reported aggravation ...mptoms, and in 6 there was no change ...ring surgery, electromyographic im...ment of motor conduction velocity ... the elbow was found in 15 patients. A ...g in conduction was observed in 3, and ...MG remained unchanged in 8 patients ... patient conduction velocity improved ...0 to 20 m/s after operation (Figure 3)

...USSION

...y paralysis of the ulnar nerve did not ...r more frequently in manual workers ... in the white collar professions in this ..., nor did it have any correlation with ... dominance

...vy & Apfelberg (1972) reported relief ... anterior transposition of the ulnar nerve ... out of 10 patients. They described that ...ry symptomatology is frequently ...sed However, muscle atrophy cannot be ...rmly reversed unless treated at a very ... stage This is also confirmed in our ...nts where marked sensory improvement ... gained in 75 per cent of patients with ...sthesia and in 55 per cent of those with ...ry loss, but in only 16 per cent with ...le atrophy

...agnegård et al (1977) concluded that ... operation appears to produce the best results. Wilson (1973) found that the degree of surgical success as regards symptom alleviation is inversely proportional to the duration of preoperative symptoms. This was not confirmed in the present study the difference between the two groups is not significant, as long as one remains within the 2-year boundary

It would appear that symptomatic improvement does not have any correlation with

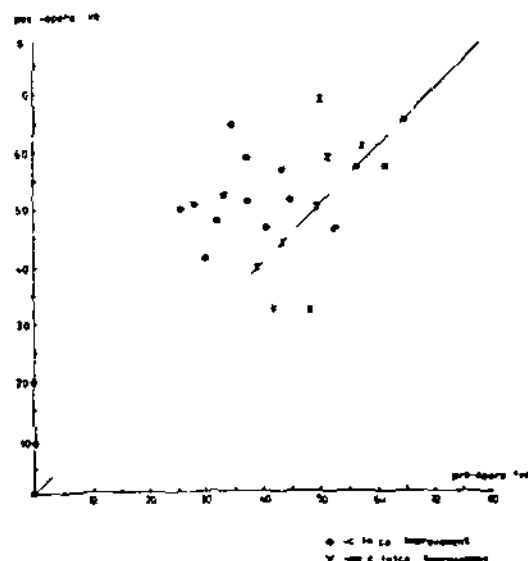


Figure 3 Results of EMG examination in 24 patients (26 hands) before and after surgery

age Of the 5 patients who failed to obtain any relief, 3 were below 40 years of age

Most reports on anterior ulnar nerve transposition have been encouraging McGowan (1950) reported a 75 per cent success rate Gay & Love (1947) achieved 80 per cent satisfactory results Sunderland (1968) found that out of 14 patients only 6 improved, while 4 were considered to be worse after surgery Lugnegård (1977) found that 11 out of 18 (61 per cent) had achieved enhancement of motor and sensory power, but only 6 had recovered completely

Our series seems to be in keeping with previous reports indicating marked improvement in motor and sensory function after surgery

Various reports mentioned in Lugnegård's study (Lugnegård 1977) note electromyographic improvement of motor nerve conduction velocity, even in cases where clinical improvement was not found

As set forth in Figure 3, all patients who had an EMG motor conduction velocity under 40 m/s prior to operation showed significant improvement following surgery This correlated well with their clinical improvement

In patients with EMG findings of 40 to 70 m/s, we found both an amelioration in motor conduction velocity and in clinical symptoms respectively

CONCLUSION

There is a great possibility whose EMG is within normal [illegible] improve clinically However the [illegible] ment is less striking than in patients [illegible] ulnar neuropathy and an EMG of [illegible] 40 m/s These cases will certainly [illegible] from anterior transposition of

REFERENCES

Apfelberg D B & Larsen, S. (19[illegible]) anatomy of the ulnar nerve at the elbow [illegible] reconstr Surg 51, 76–81

Gay J R & Love J G (1947) D[illegible] treatment of tardy paralysis of ulnar [illegible] Bone Jt Surg 29 A 1037

Levy D M & Apfelberg D A (19[illegible]) [illegible] anterior transposition for ulnar neuropathy [illegible] elbow *Amer J Surg* 123 304–3[illegible]

Lugnegård H Walheim, G & Wennberg [illegible] Operative treatment of ulnar nerve [illegible] the elbow region *Acta orthop* [illegible] 168–176

McGowan A (1950) The results of tra[illegible] the ulnar nerve *J Bone Jt Surg* 32 B [illegible]

Sunderland S (1968) *Nerves and nerve in[illegible]* 881–885 E and S Livingstone Ltd E[illegible] & London

Wilson D (1973) Surgery of ulnar nerve [illegible] the elbow 16 cases treated by decom[illegible] without transposition. *J* [illegible] 780–785

Correspondence to M Kamhin MD Hand Surgery Unit The Chaim Sheba Medical Ce[illegible] Hashomer Israel

p scand. 51, 479–484, 1980

ERIOR DISLOCATION AND ...TURE-DISLOCATION OF THE SHOULDER

..I VASTAMÄKI & KAUKO A SOLONEN

Regional Hospital, Loimaa, and Orthopaedic Hospital
valid Foundation, Helsinki, Finland

Two cases of posterior dislocation (PD) and four cases of posterior fracture-dislocation (PFD) of the shoulder are reported There was one bilateral PD and two bilateral PFD One PD was treated with closed reduction but in three cases of PFD operative reduction was necessary All measures were applied in the late phase within 1 to 10 months after the injury with good primary results However, because of posttraumatic arthrosis, the final result was poor The average follow-up period was 4 years. The diagnosis of posterior dislocation is often missed An axillary X-ray is essential

Key words posterior fracture-dislocation posterior dislocation, shoulder dislocation

Accepted 21 viii 79

..or dislocation (PD) of the shoulder is ..common injury in comparison with ..r dislocation The first accurate ..t of the clinical appearance of uni- PD of the shoulder has been ascribed ..per (1839) Between 1 5 and 4 3 per .. all shoulder dislocations are posterior ..tions (Warrich 1948, McLaughlin Taylor & Wright 1952, Rowe 1956, ..' 1962) The dislocation is often ..ated with minor fractures, such as ..n of a small fragment from the in- ..dial aspect of the head

..or fractures associated with posterior ..tions of the shoulder, posterior ..re-dislocations (PFD), are rare Neer et ..orted 14 PFD in a material of 1500 dis- ..ons of the shoulder (0 9 per cent) (Neer 1953, O'Connor & Jacknow 1956, Bell Chattopadhyaya 1970) Approximately ..ateral PD (Arden 1956, Shephard 1960, ..er 1969) and 14 bilateral PFD have been ..ed (Mynter 1902, Mills 1974)

Trauma mechanism

Mechanical trauma may be the cause in unilateral cases, but convulsive seizures, such as those occurring in a fit or in electric shock, are the single most common cause of bilateral PD and PFD When posterior dislocation is bilateral, it has nearly always been caused by a convulsive seizure (Kelly 1954, Shaw 1971, O'Flanagan 1975)

The typical position of the shoulder during a convulsion is adduction, internal rotation and flexion A massive contraction of the shoulder girdle muscles forces the humeral head against the acromion and the glenoid fossa, providing the force necessary to produce dislocation If the convulsion continues, a typical PFD is produced Increased stress on the notched anatomical neck, which impinges against the glenoid rim, applies a shearing force to the humeral head, and the subscapularis and infraspinatus complexes are torn off from their respective fragments (Neer 1970)

..470/80/030479–06$02.50/0

age Of the 5 patients who failed to obtain any relief, 3 were below 40 years of age.

Most reports on anterior ulnar nerve transposition have been encouraging McGowan (1950) reported a 75 per cent success rate Gay & Love (1947) achieved 80 per cent satisfactory results Sunderland (1968) found that out of 14 patients only 6 improved, while 4 were considered to be worse after surgery Lugnegård (1977) found that 11 out of 18 (61 per cent) had achieved enhancement of motor and sensory power, but only 6 had recovered completely

Our series seems to be in keeping with previous reports indicating marked improvement in motor and sensory function after surgery

Various reports mentioned in Lugnegård's study (Lugnegård 1977) note electromyographic improvement of motor nerve conduction velocity, even in cases where clinical improvement was not found

As set forth in Figure 3, all patients who had an EMG motor conduction velocity under 40 m/s prior to operation showed significant improvement following surgery This correlated well with their clinical improvement

In patients with EMG findings of 40 to 70 m/s, we found both an amelioration in motor conduction velocity and in clinical symptoms respectively

CONCLUSION

There is a great possibility th[illegible] whose EMG is within normal li[illegible] improve clinically However [illegible] ment is less striking than in pa[illegible] ulnar neuropathy and an EMG of l[illegible] 40 m/s. These cases will certainl[illegible] from anterior transposit[illegible]

REFERENCES

Apfelberg D B & Larsen S (19[illegible]) anatomy of the ulnar nerve at the elb[illegible] *reconstr Surg* 51, 76–81

Gay, J R & Love J G (1947) Dia[illegible] treatment of tardy paralysis of ulna[illegible] *Bone Jt Surg* 29 A, 1087

Levy, D M & Apfelberg D A (197[illegible]) anterior transposition for ulnar neurop[illegible] elbow *Amer J Surg* 123 304–3[illegible]

Lugnegård H Walheim G & We[illegible] Operative treatment of ulnar nerve ne[illegible] the elbow region *Acta orthop* [illegible] 168–176

McGowan A (1950) The resul[illegible] the ulnar nerve *J Bone Jt Surg* 32 B[illegible]

Sunderland S (1968) [illegible] 881–885 E and S. Livingstone Ltd [illegible] & London

Wilson D (1973) Surgery of ulnar ne[illegible] the elbow 16 cases treated by dec[illegible] without transposition *J* [illegible] 780–785

Correspondence to M Kamhin M D Hand Surgery Unit The Chaim Sheba Medical C[illegible] Hashomer, Israel







Diagnosis

Posterior dislocation of the shoulder is frequently overlooked at the first examination and the treatment thus becomes more difficult In a typical case of acute PD, the arm is locked in internal rotation and adduction Palpation of the humeral head in a posterior position provides the only conclusive clinical evidence of PD But palpation may be misleading since the spastic deltoid, a haematoma, and oedema may obscure the condition When there is a concomitant fracture the arm may be in any position and motion at the fracture site may be misinterpreted as joint motion

In PD there is often little or no deviation from the normal picture in A-P X-ray views. Since the arm usually will be immobilized in internal rotation at the time of X-ray examination, the tell-tale overlapping of the humeral head and the glenoid fossa may mimic the normal overlapping seen with the shoulder in full internal rotation An axillary X-ray must be obtained to confirm the diagnosis If care is taken in positioning the arm, the 30 degrees of abduction necessary to obtain this view will not do any further damage or cause undue discomfort

Treatment

A variety of treatments ha[illegible] closed reduction and plaster [illegible] Kelly 1961), closed reduction and [illegible] wire fixation (Wilson & [illegible] open reduction and [illegible] (Prillaman & Thompson 1969 [illegible] excision of fragments (Mills 19[illegible] ment arthroplasty (Aufranc et al 1[illegible] 1971) and arthrodesis ([illegible] 1977)

Within a few days of the [illegible] reduction with the arm [illegible] abduction and external rotation [illegible] adequate (Greenhill 1972). In neg[illegible] contractures develop in the [illegible] the compression fracture of the hum[illegible] deepens necessitating operative red[illegible]

The specific pathological lesion [illegible] patient should determine the choi[illegible] procedure a posterior Putti Platt or [illegible] type procedure, fixing the sub[illegible] tendon within the compression [illegible] (McLaughlin 1952) or osteotomy of [illegible] of the scapula (Scott 1967). A poster[illegible] Hybbinette operation may be [illegible] prevent redislocation if there is [illegible] humeral defect, or the capsular stru[illegible]



Figure 1 Case 1 Radiograms of the shoulder joints A and B, C and D Shoulder joints [illegible] the accident E Right shoulder joint 2 months after operative reduction F and G Righ[illegible] 3 years after reduction


D


E


F
G

inadequate (v Hellens 1946) In a posterior Putti-Platt repair internal rotation will be limited permanently to about 45 degrees (Severin 1952)

CASE REPORTS

Case 1 A 41-year-old woman received an electric shock through her right hand Bilateral PFD of the humerus was diagnosed 4 weeks after the accident Closed reduction was unsuccessful After 3 months the patient's shoulders appeared almost normal, but their mobility was greatly reduced there was 45 degrees lateral abduction and 90 degrees forward flexion but external rotation was absent (Figure 1) The PFD of the right shoulder was surgically reduced, the pseudoarthrosis revised and the caput affixed to the distal fragment with a spongiosa screw The left shoulder was not operated on as there was mobility and the pain was not significant Three years after the operation the right shoulder was relatively free of pain, but the left shoulder was painful The patient was able to anteriorly flex and abduct her arms about 100 degrees. External rotation was absent. X-ray showed caput necrosis and arthrosis in the right glenohumeral joint

Case 2 A 48-year-old epileptic woman sustained a bilateral PFD of the shoulder in conjunction with an epileptic attack The condition was diagnosed 3 weeks later and operative reduction of the right shoulder was performed 4 months later A redislocation occurred and a posterior Eden-Hybbinette procedure was carried out A severe arthrosis developed (Figure 2) The left shoulder was left untreated Three years later the patient had 90 degrees of anterior flexion in the arms Abduction was 30 degrees on the operated side, and 70 degrees on the contralateral side External rotation was absent X-rays revealed severe arthrosis in the right glenohumeral joint

Case 3 A 69-year-old woman suffered an attack of unconsciousness Bilateral PD of the shoulder joints was diagnosed 3 months later Closed reduction of the right shoulder was performed 10 months after the accident and retention was ensured by the use of two Kirschner pins and an abduction splint The left side was not treated Two years after the reduction the patient was able to abduct both arms 90 degrees and flex them anteriorly 140 degrees. External absent X-rays revealed severe right glenohumeral joint.

Case 4 A 32 year-old man su the anatomical collum of the left junction with an epileptic attack been treated primarily with screw mobility of the shoulder remained and 2 years later the aftermath of diagnosed External rotation Operative treatment was not of the long standing dislocation compression groove in the caput was flattened

Case 5 The coat of a 38-year-old man between the rollers of a printing press patient's shoulder backwards and the right shoulder The joint was following day The function remained months later the torn joint capsule was and the acromion was resected motion at the shoulder joint was shoulder became almost painless there was 60 degrees active abduction, forward flexion and 10 degrees X rays showed severe posttraumatic arthrosis


Case 6 A 14-year-old school boy fell a bicycle and sustained a PFD of the left Closed reduction was not successful and later operative reduction and fixation reduced caput to the scapula with pins was performed The dislocation recurred Atrophy of the shoulder result of nerve damage in conjunction primary injury was demonstrated 3 shoulder remained poor After 2 years the refused to undergo operative condition was unchanged 7 years after X-rays showed sever caput necrosis

DISCUSSION AND CONCLUSION

Posterior dislocation or fra the shoulder is a rather rare diagnosis seems often to be delayed X-ray examination is essential in cases. Early reduction is exceedingly tant The primary result of delayed is usually good, but the long-term

- 1 B Antero-posterior and axillary nd D One week after the reduction



A




C


D


E


F

to the development of painful posttraumatic arthrosis, are discouraging It seems obvious that the vessels of the humeral head are so badly damaged during or after the dislocation that necrosis is inevitable On the basis of our material we are unable to determine whether the avascular necrosis could have been avoided with adequate primary treatment

REFERENCES

Arden, G P (1956) Posterior dislocation of both shoulders Report of a case *J Bone Jt Surg* 38 B, 558–563

Aufranc, O E, Jones, W N & Turner, R H (1966) Bilateral shoulder fracture-dislocations *J Amer med Ass* 195, 1140–1143

Bell, H M (1965) Posterior fracture-dislocation of the shoulder A method of closed reduction A case report *J Bone Jt Surg* 47-A 1521–1524

Callaghan, M F & Kelly, P J (1961) Bilateral posterior dislocation of the shoulder Report of a case and review of the literature *Proc Mayo Clin* 36, 203–210

Chattopadhyaya, P K (1970) Posterior fracture-dislocation of the shoulder Report of a case *J Bone Jt Surg* 52-B, 521–523

Cooper, A (1839) On the dislocation of the os humeri upon the dorsum scapulae and upon fractures near the shoulder joint *Guy's Hosp Rep* 4, 265–296

Greenhill, B J (1972) Persistent posterior shoulder dislocation its diagnosis and its treatment by posterior Putti-Platt repair *J Bone Jt Surg* 54-B, 763

v Hellens, A (1946) Ein operativ behandelter Fall [illegible] Verrenkung in dem selben Schultergelenk *Ann Chir Gynec Fenn* 35, 142–156

Honner, R (1969) Bilateral posterior dislocation of the shoulders *Aust N Z J Surg* 38, 269–272

Kelly, J P (1954) Fractures complicating electro-convulsive therapy and chronic epilepsy *J Bone Jt Surg* 36-B, 70–79

McLaughlin, H L (1952) Posterior dislocation of the shoulder *J Bone Jt Surg* 34-A, 584–590

Mills, K L G (1974) Simultaneous bilateral posterior fracture-dislocation of the shoulder *Injury* 6, 39–41

Mouterde, P & Pére C (1977) Luxations anciennes de l'épaule *Ann Chir* 31, 119–124

Mynter, H (1902) Subacromial [illegible] muscular spasm *Ann Surg* [illegible]

Neer, C S, Brown, T H & [illegible] (1953) Fracture of the neck of the [illegible] with dislocation of the head fragment [illegible] *Surg* 85, 252–258

Neer, C S (1970) Displaced proximal [illegible] fractures *J Bone Jt Surg* [illegible]

Nobel, W (1962) Posterior [illegible] of the shoulder *J Bone Jt Surg* [illegible] 523–538

O Connor, S J & Jacknow A S [illegible] dislocation of the shoulder *Arch* [illegible] 479–491

O Flanagan, P H (1975) Fracture [illegible] from domestic electricity supply [illegible] 244–245

Pear, P L (1970) B[illegible] location of the shoulder – an [illegible] plication of a convulsive seizure [illegible] *Med* 283, 135–136

Prillaman H A & Thompson, R C [illegible] Bilateral posterior fracture-dislocation [illegible] shoulder A case report. *J Bone Jt Surg* [illegible] 1627–1630.

Rowe C R (1956) Prognosis in [illegible] the shoulder *J Bone Jt Surg* [illegible]

Scott, D J, Jr (1967) Treatment of [illegible] posterior dislocations of the [illegible] glenoplasty Report of three cases *J* [illegible] *Surg* 49 A, 471–476

Severin E (1952) Anterior and posterior [illegible] dislocation of the shoulder The [illegible] operation *Acta orthop scand* [illegible]

Shaw, J L (1971) Bilateral posterior [illegible] dislocation of the shoulder and [illegible] caused by convulsive seizures *J* [illegible] *Surg* 53 A, 1437–1440

Shephard, E (1960) Simultaneous [illegible] location of both shoulders. Report [illegible] *Bone Jt Surg* 42 B 728–729

Taylor R. G & Wright P R [illegible] dislocation of the shoulder *J Bone* [illegible] 34-B, 624–629

Warrick G K (1948) Posterior [illegible] shoulder *J Bone Jt Surg* 30-B [illegible]

Wilson, J C & McKeever F [illegible] Traumatic posterior (retroglenoid) [illegible] of the humerus *J Bone J* [illegible] 160–172

Wood J P (1941) Posterior [illegible] head of the humerus and [illegible] lateral and vertical views *U S* [illegible] 39, 532–535

Correspondence to Martti Vastamäki, Orminkuja 2 as. 6, 20610 Turku 61, Finland.

ERAL POSTERIOR DISLOCATION OF THE LDER COMBINED WITH FRACTURE OF THE MAL HUMERUS

Report

INDHOLM & ERIK ELMSTEDT

nt of Orthopaedic Surgery, Karolinska Institutet, Huddinge University Hospital, Huddinge,

A 28-year-old turner presented with bilateral posterior fracture-dislocation of the shoulders following an epileptic seizure He was treated by open reduction of the humeral heads and fixation of the oblique fractures with screws.

At the follow-up examination 2 years postoperatively shoulder mobility was satisfactory, and the patient could return to his previous work

Key words fracture, humero-scapular joint, posterior dislocation

Accepted 19 ix 79

posterior dislocation of the shoulder d with fracture of the proximal is uncommon (Wilson & McKeever illaman & Thompson 1969, Shaw Mills 1974, Vastamaki & Solonen n almost all cases an epileptic seizure ed as the aetiological factor (Aufranc 66, Shaw 1971, O'Flanagan 1975) In se of the convulsions the humerus is d, rotated inwards and bent, when the of the scapular region pull on the Mm infraspinatus, teres minor, us, latissimus dorsi and teres major ate to dislocate the head in a r direction The humeral neck may racture, and an oblique splintered can follow the contraction of the mm ularis and infraspinatus (Cooper 1839, & Keith 1904, McLaughlin 1952, 971)

present here a case in which bilateral or fracture-dislocations were treated by

CASE REPORT

A 28-year-old turner with daily consumption of alcohol for a period of several years was admitted to the hospital following bilateral posterior fracture-dislocation of the humeri Sixteen days earlier (1976-10-21) the patient had had a violent epileptic convulsion of the grand mal type after abstaining from alcohol for 4 days

The fracture-dislocations were diagnosed (Figure 1) on the 14th day after the accident at a [illegible] and at first it was thought that

[illegible]

drugs

Abundant haemorrhages were present in both upper extremities. The humero-scapular joints were totally fixed, and the humeral heads could be palpated behind the glenoid The patient experienced severe pain when trying to move the joints. Posterior dislocations as well as proximal oblique fractures of the humeri were seen on radiological examination

On the 20th day after the injury the patient was operated on through an antero-lateral approach between the deltoid and pectoral muscles. The

70 80/030485–04$02.50/0



Figure 1 Posterior dislocations and oblique fractures of the proximal humeri [illegible] reposition and operative fixation with screws

joint was opened after division of the insertions of m pectoralis major and m subscapularis. The fracture was located medial to tuberculum minor and the caput fragment was found to be displaced into the posterior compartment of the joint hooked on to the edge of the glenoid The caput was reduced as were the fracture fragments. The fracture was then fixed with AO-compression screws. When the operative wound was closed the humeral head was additionally fixed with Kirschner wires to the acromion as described by Wilson & McKeever (1949) the same procedure being performed on both sides. The [illegible] fixed to the body by elastic [illegible] Kirshner wires were extracted [illegible] postoperatively The wounds healed [illegible] of infection. Mobilization of the [illegible] weeks postoperatively After 10 [illegible] tion there was a good range of [illegible] which had been maintained at the [illegible] follow-up examination (1979-01 [illegible] 170° rotation inwards 90° and [illegible] both shoulders, whereas abduction [illegible] the left side compared with 11[illegible]



. Range of flexion of the right humero- joint at follow-up 2 years after the opera-

3) Radiographs showed that the fractures aled, and the humeral heads were concentrically in the glenoid fossae). The patient was able to return to his occupation

SSION

ses of bilateral posterior fracture- ion of the shoulders reported in the e were usually not recognized until a ge and had to be surgically treated was no postoperative re-dislocation, h capsuloplasty was not performed r, a reversed Putti-Platt or an Eden- te procedure has been recommended e surgeons with the additional aim of ng a re-dislocation (Greenhill 1972) In our case, as in that of Wilson & McKeever (1949), sufficient stabilization was achieved by simply transfixing the humeral head to the acromion using Kirschner wires Shaw (1971) reports an unsatisfactory postoperative result with limitation of movement following replacement with endoprosthesis 3 and 4 weeks after the injury, while Vastamäki & Solonen (1979) report successful treatment by open reduction and internal fixation with a screw as late as 3 months after the injury

We are of opinion that the latter case, and our own, contradict the opinions of Wilson & McKeever who consider that unrecognized fracture-dislocations treated weeks after the injury are likely to give poor results with marked loss of motion and a painful shoulder In cases of this type we advocate open reduction and internal fixation as described in this report

REFERENCES

Aufranc, O E, Jones, W N & Turner, R H (1966) Bilateral shoulder fracture-dislocations. *J Amer med Ass* **195**, 1140–1143

Cooper, A (1839) On the dislocation of the os humeri upon the dorsum scapulae, and upon fractures near the shoulder-joint *Guy's Hosp Rep* **4**, 265–284

Greenhill, B J (1972) Persistent posterior shoulder dislocation its diagnosis and its treatment by posterior Putti-Platt repair *J Bone Jt Surg* **54-B**, 763

McLaughlin, H L (1952) Posterior dislocation of the shoulder *J Bone Jt Surg* **34-A**, 584–590

Mills, K. C G (1974) Simultaneous bilateral posterior fracture-dislocation of the shoulder *Injury* **6**, 39–41

Moullin, C W M & Keith, A (1904) Notes on a case of backward dislocation of the humerus caused by muscular action *Lancet* **1**, 496

O'Flanagan, P H (1975) Fracture due to shock from domestic electricity supply *Injury* **6**, 244–245

Prillaman, H A & Thompson, R C., Jr (1969) Bilateral posterior fracture-dislocation of the shoulder *J Bone Jt Surg* **51-A**, 1627–1630

Shaw, J L (1971) *Bilateral posterior fracture-dislocation of the shoulder and other trauma caused by convulsive seizures. J Bone Jt Surg* **53-A**, 1437–1440

Vastamäki, M. & Solonen, K. A (1979) Posterior dislocation and posterior fracture-dislocation of the shoulder *Acta orthop scand.* 50, 124

Wilson, J C. & McKeever F M Traumatic posterior [illegible] of the humerus. *J Bone J* [illegible] 160–172.

Correspondence to T Sam Lindholm, M. D., Department of Orthopaedic Surgery [illegible] sity Hospital, S-141 86 Huddinge, Sweden.

Acta Orthop scand 51, 489–492 1980

[C]ONGENITAL PSEUDARTHROSIS OF THE CLAVICLE

[Q]UINLAN, P G BRADY & B F REGAN

[Our Lad]y's Hospital for Sick Children, Crumlin, Dublin, Ireland

Congenital pseudarthrosis of the clavicle is a rare entity Its aetiology and pathogenesis still remain obscure The condition is predominantly right-sided Differential diagnosis lies between birth fracture and cleido-cranial dysostosis. Surgery when indicated gives good results

Key words clavicle, congenital, pseudarthrosis

Accepted 1 vi 79

[Conge]nital pseudarthrosis of the clavicle is [...]re Fitzwilliams and St Pierre in 1910 [... 1]930, respectively, each described one [... S]ince 1930, 15 authors have described [...]es in the English medical literature In [...] Behringer & Wilson introduced [...]ry criteria to be fulfilled in order for a [...]o be described as "fully documented" [...]ion within the first 2 years, no history [...]uma and an X-ray showing discon[...] of the clavicle Only 18 cases fulfil [...] requirements The lesion is pre[...]antly right-sided Three cases of left- congenital pseudarthrosis have been [...]bed (Ghormley et al 1941, Wall 1970 [G]ibson & Caroll 1970) One of these [...]ts had dextrocardia (Gibson & Carroll

[...]e cases of bilateral congenital [pseud]arthrosis have been described [...]ignol 1948, Stevenson 1968, Herman Gibson & Carroll 1970) Only in seven has the lesion appeared on the side [...]teral to the heart

[In] this condition there is a defect just [...]l to the middle of the clavicle and there [...] space between the bone fragments. At [...] or later a prominence may be felt at the [...]ion of the middle and outer thirds of the [...]le This is due to the medial end of the lateral fragment being pulled upwards and backwards while the lateral end of the medial fragment is pulled upwards and forwards. Thickening of the bone ends adds to the deformity The medial fragment is the larger of the two The condition gives an asymmetrical appearance to the trunk when viewed from the front When viewed from behind the medial border of the scapula is more prominent than that on the normal side The shoulder of the involved side is lower, further forward and nearer the midline than the opposite one The shoulder point can be forcibly adducted towards the midline through a considerable range

Apart from occasional aching, symptoms are relatively few In many cases the prominence increases with age and may cause difficulty with dress or a disfiguring appearance especially in females.

There is usually a palpable discontinuity between the clavicular fragments and mobility is easily elicited A search for cafe-au-lait spots and other skeletal abnormalities is essential in establishing a diagnosis

Radiological appearances are characteristic – a lack of bone continuity in the middle third of the clavicle without evidence of reactive bone Absence of callus distinguishes the condition

[0001-]5470/80/030489–04$02.50 0



Figure 1 Congenital pseudarthrosis of the right clavicle – a four and a half year old male



Figure 2 Congenital pseudarthrosis of left clavicle and bilateral cervical ribs, the left being larger



Figure 3 Congenital pseudarthrosis of right clavicle in a one year and ten months old male

CASE REPORTS

In the period 1956 to 1978 four cases of con- genital pseudarthrosis of the clavicle have been seen in this hospital

Case 1

A four and a half year old boy presented in 1963 with a lump over the middle third of his right clavicle This was pain free and had been noticed during the first year of life The deformity was increasing The level of the right shoulder was lower than the left X-ray showed a pseudarthrosis (Figure 1) This boy was treated surgically A tibial bone graft was laid across the defective area and was wired to both clavicular fragments. Solid union followed

Case 2

A one and a half year old girl presented in 1968 with a mass over the centre of her left clavicle There was no history of trauma ...

... and sound bony union occurred. This ... bilateral cervical ribs the left being la...

Case 3

A 6-year-old girl attended in 197... creasing deformity over the middle ... right clavicle This was first noticed ... two There was no history of ... movement was painless and ... showed a pseudarthrosis. Surgery was ... the area of pseudarthrosis being excised ... bone ends were roughened and ... Iliac bone chips were laid around the ... union occurred

Case 4

A 22-month-old boy presented in 1... pain free lump over the centre of his ... There was no history of trauma ... was seen on X ray (Figure 3) ... movements were not limited. This ch... reviewed periodically Unless indicated ... will not be carried out.

DISCUSSION

This rare condition has to be di... from post-traumatic pseudarthro... cleido-cranial dysostosis. In the ... condition there is often a history of ... labour or of trauma A period of ... movement of the upper limb usually ... There is excessive callus formation ... common feature in post-... pseudarthrosis (Wall 1970).

The operative findings are char... when the lesion is congenital ... articular cartilage on the bone e... sometimes synovial lining is evident ... the area of the defect.

In cleido-cranial dysostosis the ... defect is very often bilateral and ... other stigmata such as wide fonta... wide suture lines. The skull is large ... bones are small and the teeth ar... Deficiencies of the pelvic ring and ...

ses in the hands and feet are common
isorder is familial

aetiology of congenital pseudarthrosis
clavicle is obscure Deficiency in os-
on is suggested Mall (1960), Fawcett
and Parker state that the clavicle
from two centres and these centres
by the 45th day of intrauterine life
of fusion will result in congenital
rthrosis Koch (1960), in reviewing the
ology of the clavicle, suggests that
s only one ossification centre Gibson &
l (1970) support this view Although os-
on from two centres may occur in con-
l pseudarthrosis, Koch (1960) and
n & Carroll (1970) feel this is abnormal
ould require an explanation

Roberts et al (1975) suggest that, as
majority of cases occur on the side
to the heart, the close relationship of
artery to the developing
may play a part Cervical rib or
elevated upper ribs will bring the
vessels very close to the clavicle
exaggerated arterial pulsation may
with ossification and may result in a
osis. They showed some examples
series Case 2 in our series had
cervical ribs, the left being larger
2)

lesion seen in association with
-cranial dysostosis may be a true
larthrosis produced by the abnormally
ed ribs bringing the subclavian vessels
lose to the clavicle

r four cases fit into the previously well-
d patterns and two of them satisfy
iteria for "full documentation" The
who have had surgery achieved
ent results and at 15, 11 and 10 years of
are symptom-free

procedures have been carried out for
surgical treatment of this condition
(1970) emphasizes that internal fixation
not be used while Sakellarides (1961)
75 per cent failure rate when internal
was not used Our methods have
but we have had union in all three

CONCLUSIONS

1 Congenital pseudarthrosis of the clavicle is a rare lesion occurring almost exclusively on the side opposite the heart

2 Its aetiology is obscure Primary defects in ossification or defects in ossification secondary to subclavian pulsation may be causative factors

3 Surgery is indicated only if there is increasing pain or deformity

REFERENCES

Behringer B R & Wilson, F C (1972) Congenital pseudarthrosis of the clavicle *Amer J Dis Child* **123**, 511–517

Fawcett, J (1913) The development and ossification of the human clavicle *J Anat Physiol.* **47**, 225–234

Fitzwilliams, D C L (1910) Hereditary cranio-cleido dysostosis. *Lancet* ii, 466–1475

Ghormley R K, Black J R & Cherry, J H (1941) Ununited fractures of the clavicle *Amer J Surg* **51**, 343 349

Gibson D A & Carroll N (1970) Congenital pseudarthrosis of the clavicle *J Bone Jt Surg* **52 B**, 629–643

Herman, S (1973) Congenital bilateral pseudarthrosis of the clavicle *Clin Orthop* **91**, 161–163

Koch, A. R (1960) Die Fruhentwicklung der Clavicula beim Menschen. *Acta anat (Basel)* **42**, 177–212.

Lloyd Roberts, G C., Apley, A G & Owen, R (1975) Reflections upon the aetiology of congenital pseudarthrosis of the clavicle *J Bone Jt Surg* **57-B**, 24–29

Mall F P (1906) On ossification centres in ... less than 100 days old *Amer*

Parker, W K Monograph of the shoulder girdle Folio Roy Soc. London, 68, i, XI 237

Rossignol, J C (1948) Bilateral pseudarthrosis of the clavicle treated by costo-scapular fusion. *J Bone Jt Surg* 30-B, 220

Sakellarides, H (1961) Pseudarthrosis of the clavicle *J Bone Jt Surg* **43 A**, 130–138

Stevenson, C. A (1968) Discussion of Kite *Sth med J (Bgham, Ala)* **61**, 710.



Figure 1 Congenital pseudarthrosis of the right clavicle – a four and a half year old male



Figure 2 Congenital pseudarthrosis of left clavicle and bilateral cervical ribs the left being larger



Figure 3 Congenital pseudarthrosis of right clavicle in a one year and ten months old male

CASE REPORTS

In the period 1956 to 1978 four cases of congenital pseudarthrosis of the clavicle have been seen in this hospital.

Case 1

A four and a half year old boy presented in 1963 with a lump over the middle third of his right clavicle. This was pain free and had been noticed during the first year of life. The deformity was increasing The level of the right shoulder was lower than the left. X ray showed a pseudarthrosis (Figure 1). This boy was treated surgically A tibial bone graft was laid across the defective area and was wired to both clavicular fragments. Solid union followed.

Case 2

A one and a half year old girl presented in 1968 with a mass over the centre of her left clavicle. There was no history of trauma [illegible] was shown on X-ray (Figure 2) [illegible] was increasing surgery was carried [illegible] of four A tibial bone graft was laid [illegible] and sound bony union occurred. This [illegible] bilateral cervical ribs the left being [illegible]

Case 3

A 6-year-old girl attended in 19[illegible] [illegible] creasing deformity over the middle [illegible] right clavicle This was first noticed [illegible] two There was no history of [illegible] movement was painless and [illegible] showed a pseudarthrosis. Surgery [illegible] the area of pseudarthrosis being [illegible] bone ends were roughened and [illegible] Iliac bone chips were laid around the [illegible] union occurred

Case 4

A 22 month-old boy presented in [illegible] pain-free lump over the centre of his [illegible] There was no history of trauma [illegible] was seen on X-ray (Figure 3) [illegible] movements were not limited. This [illegible] reviewed periodically Unless [illegible] will not be carried out.

DISCUSSION

This rare condition has to be [illegible] from post traumatic pseudarthrosis [illegible] cleido-cranial dysostosis. In the [illegible] condition there is often a history of [illegible] labour or of trauma. A period of [illegible] movement of the upper limb [illegible] There is excessive callus formation [illegible] common feature in [illegible] pseudarthrosis (Wall 1970).

The operative findings are [illegible] when the lesion is congenital [illegible] articular cartilage on the bone ends [illegible] sometimes synovial lining is [illegible] the area of the defect.

In cleido-cranial dysostosis the [illegible] defect is very often bilateral and [illegible] other stigmata such as wide [illegible] wide suture lines. The skull is [illegible] bones are small and the teeth [illegible] Deficiencies of the pelvic [illegible]

op scand 51, 493 499 1980

⁵A EQUINA SYNDROME IN BAR DISC DISEASE

HOUDHURY & J C TAYLOR

J Department of Neurosurgery, Derbyshire Royal Infirmary, Derby, England

A series of 42 patients with lumbar disc disease and herniation presenting with the cauda equina syndrome, has been studied It was observed that pure disc herniation accounted for the syndrome in five cases only Associated structural lesions were contributory factors in the remaining 37 cases, and operative manipulation and trauma during disc removal through an interlaminar approach was the added factor in two of them Wide laminectomy with excision of the overhanging facet joints and adequate visualization of the lumbar nerve roots has been found to be the ideal procedure for disc removal and for relief of the symptoms, including backache No postoperative spinal instability has been observed There was no mortality and the morbidity was insignificant All cases have been followed up and 'good to excellent" results were obtained in 95 per cent of patients, and "fair' results in the other 5 per cent

Key words cauda equina syndrome, herniation, limited approach for disc removal, lumbar disc disease, structural changes in the spine

Accepted 6 ix 79

erm "cauda equina syndrome" is usually to indicate a group of symptoms and caused by a compression radiculopathy o or more nerve roots in the lumbar The clinical manifestations include ing pain in one or both lower limbs, or without weakness, sensory or reflex malities, or sphincter disturbance ugh there are various causes of this ome, this communication is concerned with those associated with lumbar disc ation There were no cases of the rare, e cauda equina paralysis from massive extrusion which has been reported pre-ly (O Connell 1950, Robinson 1965, gfort 1972)

is generally accepted that a disc hernia-commonly causes compression of a single and this is easily explained both on mical and clinical grounds Since the rior longitudinal ligament reinforces the annulus in the midline, most disc herniae occur in the lateral part of the floor of the spinal canal, where the disc material compresses the adjacent lower root as it courses in the lateral recess on its way to the exit foramen In recent years, however, disc lesions causing atypical or multiple root involvement, simulating an expanding lesion, have been demonstrated both myelographically and operatively (Schlesinger & Taveras 1953) The terms "midline" or "large lateral' disc are commonly used to describe such cases

We describe in this communication a group of 42 patients who presented with low back pain associated with multi-radicular neuropathy in one or both lower limbs. Plain radiographs of the lumbar spine showed various changes, including narrowing of disc spaces, minor degrees of listhesis and evidence of spondylosis. Myelography was

6470/80 030493-07$02.50/0

carried out in all cases and showed various degrees of obstruction to the flow of oil varying from minor to severe In all cases surgical exploration by means of full laminectomy was carried out. In most of the cases, a significant associated structural lesion of the spine was found to be responsible for the syndrome The purpose of this paper is to emphasize these associated spinal abnormalities in cases of disc herniation, their role in the causation of the cauda equina syndrome and the rationale of disc removal through a wide laminectomy

PATIENTS AND METHODS

Between 1974 and 1976, 42 patients with lumbar disc disease and herniation, presenting with the cauda equina syndrome, have been admitted and treated under the care of one of the [illegible] Twelve of them had already [illegible] elsewhere. In this surgical group [illegible] operation had achieved [illegible] (6 weeks to 6 months) in six, to [illegible] four, and had been followed by a [illegible] neurological deficit in two. The [illegible] patients, including the 12 surgical [illegible] considered together

There were 27 males and 15 [illegible] [illegible] from 26 to 58 years. The [illegible]

[illegible]

history varied between 2 years and 2 [illegible] Symptomatology is analysed and [illegible] 1

Surgical exploration was [illegible] by means of a full laminectomy [illegible] emphasized that the extent of the [illegible] decided by clinical and [illegible] plain radiographs had little [illegible] cant lesions recognized and treated [illegible] Table 2.

Table 1 Analysis of preoperative features and comparison with the results of operation in [illegible] cauda equina syndrome in the lumbar discs

Preoperative features (no of cases)		Results of operation (no of cases)
Lumbar backache	40	Occasional mild backache
Lower limb pain	42	Occasional mild pain in lower limbs
Paraesthesia	34	Recovered
Weakness in lower limbs	24*	Residual weakness
Vesical disturbances	14	Recovered
Reduced mobility of lumbar spine	36	Disappeared
Diminished lumbar lordosis	24	Disappeared
Lumbar scoliosis	4	Disappeared
Local tenderness	26	Disappeared
Positive SLRT	36	Disappeared
Positive FNST	7	Disappeared
Positive SLRT and FNST	4	Disappeared
Wasting of muscles	6	Residual wasting
Weakness of muscle group	14)	Recovered
Foot drop	8	Recovered
	24*	
Severe paraparesis	2)	Residual weakness
Hypoalgesia and hypoaesthesia	20	Recovered
Anaesthesia	6	Recovered
Hyperaesthesia	4	Recovered
Absent ankle jerks	14	Persisted
Reduced ankle jerks	4	Persisted
Reduced knee jerks	3	Recovered

-2 *Causes of cauda equina syndrome in lumbar discs (42 cases)*

gy	No of cases
~ disc herniation	
niation alone	3
1 double spondylolisthesis	1
1° spondylotic stenosis spondylolisthesis	1
l disc herniation	
niation alone	1
1 2° spondylotic stenosis	28
1 1° spondylotic stenosis	4
1 1° spondylotic stenosis trauma	2
ne lateral disc herniation	
niation alone	1
h 2° spondylotic stenosis spondylolisthesis	1
	42

llow-up has so far been maintained for from years. The results are described in Table 3

JLTS

1 summarizes the analysis of the pre-tive features in this series and a com-on is made with the results of operation in the lower limbs was the most ant clinical feature and was present in ases. It was ipsilateral in 21, bilateral in and contralateral in only three cases operatively it disappeared completely in cases. Four patients experienced sional mild pain in the lower limbs. larly backache persisted in only six of the cases, being mild and intermittent and ing normal activity Paraesthesiae were nt in 34 cases, bilateral in 12, and was complete in all cases. Evidence wasting was noted in six weakness in one or both legs was in 24, amounting to a marked in two Muscle wasting persisted and muscle weakness persisted in patients.

spinal, tension and sensory signs, ng saddle anaesthesia in three, were variable but all cleared up postoperatively The vesical disturbances, including retention of urine in four, similarly recovered completely The absence of ankle jerk was noted unilaterally in eight, bilaterally in six and depressed unilaterally in four cases The knee jerk was depressed in three cases, including one bilaterally The ankle jerk remained absent bilaterally in two, unilaterally in two and depressed in one

It is observed that the disc herniation alone caused the cauda equina syndrome in five cases only (Table 2) Structural changes in the spine associated with the disc lesion are collectively called spondylosis and this was responsible for the syndrome in the remaining 37 cases The terms "primary" (1°) and "secondary" (2°) spondylosis are used here to clarify the causation of the syndrome In both types the structural changes are similar but they differ in degree and extent Primary spondylosis occurs in multi segmental disc disease and causes diffuse narrowing of the spinal canal Here a disc herniation in an already (asymptomatic) stenotic canal causes a cauda equina syndrome from multiple root involvement In contradistinction to diffuse spinal stenosis in primary spondylosis, secondary spondylosis represents a segmental narrowing of the spinal canal and generally occurs in an isolated disc lesion Here the

Table 3 Results of operation for cauda equina syndrome in lumbar disc disease (42 cases)

Results	No of cases
Excellent	
Asymptomatic Unrestricted activity	30
Good	
Occasional symptoms, Normal activity	10
Fair	
Improved functional capacity but with reduced activity	2
Poor	
No improvement	0
Total	42



Figure 1 Myelogram, lateral view, showing a rounded filling defect at the level of L4–5 disc interspace in addition to double spondylolisthesis

structural changes are both prominent and localized and are the cause of the cauda equina syndrome Segmental spinal stenosis due to secondary spondylosis was the most common cause and was found in 29 cases, including one with spondylolisthesis The other causes were diffuse spinal stenosis due to primary spondylosis (five, including one with spondylolisthesis), trauma contents in a primary spondylo canal (two) and double spond (one) No recurrence of disc hern found at reoperation in patients submitted to surgery Segmental stenosis was responsible for sympt and operative trauma through a terlaminar approach for disc rem primary spondylotic, stenotic canal

The two patients with 1st degree spondylolisthesis and a third with degree true and pseudospondylol X-rayed repeatedly at increasing time for up to 1 year from oper determine whether or not had occurred In no case did this oc including the case with double lolisthesis (Figures 1 and 2) maintained an excellent clinical years later

Results of operation were asses clinical basis by considering the ability and the capacity to work "Good to excellent" results were the five cases with pure disc hern 25 of the 28 cases with associated secondary spondylosis Two of the

Figure 2 Left Preoperative plain radiographs of the lumbar spine lateral view showing antero-listhesis of L5 on S1 vertebra with a dehiscence in L5 pars interarticularis degree retro-listhesis of L4 on L5 vertebra with an intact L4 neural arch. The the extent of the slips Right One year postoperative follow-up plain radiograph of the lateral view, showing no change in spondylolisthesis

-operated upon previously, and who
-eloped marked neurological deficits,
d considerably, giving a "fair" result
ent of cases) There was no mortality
morbidity was insignificant Spinal
ty was significantly absent in this

SSION

articulated spine, the lumbar canal is
anteriorly by the posterior surfaces of
rtebrae and the intervertebral discs,
y by the pedicles and posteriorly by
sterior elements which comprise facet
laminae and the spinous processes.
lly, the canal widens in the direction of
crum and is roughly pentagonal in
The normal antero-posterior diameter
sagittal plane varies from 22mm to
with some being even larger Certain
luals, however, have canals as shallow
nm or less (Ehni 1969a) The normal
erse diameter varies from 20mm to
but in a developmentally narrow canal
ly may the antero-posterior diameter lie
15mm but also the transverse diameter
20mm Herniation of a disc in such a
may produce symptoms dis-
rtionately great and cause a cauda
a syndrome

common types of lateral disc herniation,
djacent lower root on the same side is
-d, i e in the case of the fifth lumbar
he first sacral root is affected In very
ases of extreme lateral disc herniation,
invasion of the intervertebral
may occur, leading to compression of
of the corresponding segmental level
disc herniation of sufficient size
the various roots of the cauda
which emerge from the spinal canal
the level of the herniation, but this is
Mono-radiculopathy is, therefore,
manifestation of lumbar disc
Poly-radiculopathy or the cauda
syndrome occurs in midline herniae of
sufficient size and also in cases of massive lateral disc herniation

After a period of time, secondary structural changes occur in the lumbar spine These changes are similar whether they be due to disc herniation, degeneration or resorption, i e reduction in the disc space leading to approximation of adjacent vertebral bodies. As a consequence, the posterior facet joint is stressed, overrides and undergoes a degenerative arthropathy, leading to hypertrophic bone formation around the joints (Harris & MacNab 1954) This leads to further reduction of the lateral recess and accentuation of the compression of the nerve root, already compressed by the disc. Overriding and displacement of the superior articular facet causes its encroachment into the foramen, leading to compression of the nerve root at the corresponding level In addition, degenerative spondylolisthesis may occur in some cases and accentuate the compression (MacNab 1971) These structural changes, comprising a secondary spondylosis and segmental narrowing, explain the common occurrence of poly-radicular compression neuropathy in lumbar disc herniation Narrowing occurs bilaterally, is more pronounced ipsilaterally, but is occasionally encountered also contralateral to the disc herniation Prominent contralateral changes, when associated with pre- and post-fixation of nerve roots on the side of the disc hernia, may explain contralateral symptoms in disc herniation Again, secondary spondylosis may be seen concomitantly with acute disc herniation, suggesting a more long-standing degenerative process (Friberg 1948, Munro 1956, Lewin 1964, Paine & Haung 1972)

A disc herniation in a primary, spondylotic narrow canal may produce a cauda equina syndrome from multiple root involvement (Epstein et al. 1964) Further, disc removal through a limited interlaminar approach in such a situation may require excessive manipulation of the roots, causing oedema and thus accentuating the neurological lesion (Ehni 1969b) Diagnosis must ultimately depend on the detection of these structural

changes and also on the alteration of the characteristic pattern constructed by drawing lines to join the posterior aspects of the four articular facets of the lumbar vertebrae at the time of operation (McMinn & Hutchings 1977) In the first and second vertebrae, the figure is a vertical rectangle, in the third and fourth vertebrae the figure is square, and in the fifth a horizontal rectangle In the presence of a single disc herniation, the characteristic shape is altered at that segmental level only, because the disc and the facet joints lie in the same horizontal plane When there is a more generalized spondylosis, alteration of the normal appearances usually occurs at two or more levels We believe this method has a sounder anatomical basis than the use of the stenosimeter (Verbiest 1975, 1977)

A wide laminectomy, including excision of the overhanging hypertrophied facet, is therefore the ideal procedure, as it allows gentle retraction of the nerve roots or cauda equina for exposure and removal of the disc hernia Further, it permits careful examination of the nerve root up to its exit foramen and allows release of adhesions and foraminal decompression, whenever this is needed Lastly, it ensures decompression of the already stenotic spinal canal in its lateral recess, a common occurrence in disc herniation (Paine & Haung 1972, Crock 1976)

It is a surgical axiom that adequate exposure is of the first importance in any procedure This principle, we believe, should apply as much to the intervertebral disc lesion as to anything else Full exposure achieved by wide laminectomy allows for an undamaged decompressed nerve root or cauda equina with minimal scarring and few, if any, postoperative problems The limited and, in our view inadequate exposure provided by the interlaminar approach is responsible for contused roots, extradural and peri-radicular haematomata scarring and a wide variety of postoperative problems ranging from persistence of pain and invalidism to profound bilateral weakness of the legs and incontinence

It has been argued that wide [illegible] causes spinal instability We do [illegible] this and no case has been encountered [illegible] series, this was evident by the [illegible] of clinical improvement in all [illegible] absence of further slip in repeated [illegible] rays in the three spondylolisthesis [illegible] There are many recent reports (Jacke [illegible] Paine & Haung 1972, Crock 1976, S[illegible] Hash 1976, Choudhury & Taylor [illegible] supporting our view that instability [illegible] occur Gill & White (1965) and [illegible] (1970) have also found that removal [illegible] posterior elements in [illegible] spondylolisthesis does not [illegible] vertebral displacement and, [illegible] been stated that spondylolisthesis [illegible] increase after the age of 20 years (L[illegible] Einola 1961, Wiltse 1962).

In conclusion it may be stated [illegible] cauda equina syndrome is [illegible] common manifestation in lumbar dis[illegible] tion and is usually caused by [illegible] structural changes in the spine The [illegible] wide laminectomy are gratifying

ACKNOWLEDGEMENTS

We are grateful to Dr R. Wheale [illegible] Worthington Consultant Neuroradi[illegible] their help in radiological investigations [illegible] like to express our gratitude to Mrs [illegible] and Miss Barbara Tustin Smith for the [illegible] the preparation and typing of the [illegible]

REFERENCES

Amuso S J., Neff R S., Coulson D B [illegible] P G (1970) The surgical [illegible] spondylolisthesis by posterior [illegible] tion A long term follow-up J [illegible] 52 A 529–536.

Choudhury A R. & Taylor J C [illegible] lumbar spinal stenosis J [illegible] Psychiat 40, 506–510.

Crock, H V (1976) Observations [illegible] ment of failed spinal operations [illegible] Surg 58 B 193–199

(1969a) Significance of small lumbar cauda equina compression syndromes spondylosis Part I Introduction J rg 31, 490–494
(1969b) Significance of small lumbar cauda equina compression syndromes spondylosis. Part IV Acute compres-tifically induced during operation J rg 31, 507 512.
S, Epstein, J A & Lavine, L (1964) ect of anatomic variations in the lumbar ae and spinal canal on cauda equina and root syndromes. *Amer J Roentgenol* 5–1063
(1948) Anatomical studies on lumbar egeneration *Acta orthop scand* 17, 0
G & White, H L (1965) Surgical ent of spondylolisthesis without spinal A long-term follow-up of operated *Acta orthop scand*, Suppl. 85, 5–99
L I & McNab, I (1954) Structural s in degeneration of the lumbar in ebral disc their relationship to low back and sciatica *J Bone Jt Surg* 36-B, 22
R. K (1971) The long-term effects of aminectomy for lumbar disc excision. *J Jt Surg* 53-B, 609–616
L E. & Einola, S (1961) Spondy-esis in children and adolescents. *Acta scand.* 31, 45–64
(1964) Osteoarthritis in lumbar synovial a morphologic study *Acta orthop*, Suppl 73, 1–112.
I (1971) Negative disc exploration an is of the causes of nerve root involve-in 68 patients. *J Bone Jt Surg* 53-A, 03
McMinn, R M H & Hutchings, R. T (1977) *A colour atlas of human anatomy* Wolfe Medical Publications Ltd, London
Munro, D (1956) Lumbar and sacral compression radiculitis (herniated lumbar disc syndrome) *New Engl. J Med* 254, 243–252.
O'Connell, J E A (1950) The indications for and results of the excision of lumbar intervertebral disc protrusions A review of 500 cases. *Ann. roy Coll. Surg Engl* 6, 403–412.
Paine, K. E E & Haung, P W H (1972) Lumbar disc syndrome *J Neurosurg* 37, 75–92
Robinson R. G (1965) Massive protrusions of lumbar disks. *Brit J Surg* 52, 858–865
Schlesinger, E B & Taveras, J M. (1953) Factors in the production of cauda equina syndromes in lumbar discs. *Trans Amer Neurol Ass* 78, 263–265
Shenkin, H A & Hash, C J (1976) A new approach to the surgical treatment of lumbar spondylosis. *J Neurosurg* 44, 148–155
Spangfort, E K. (1972) The lumbar disc herniation A computer-aided analysis of 2,504 operations. *Acta orthop scand*, Suppl 14, 1–95
Verbiest, H (1975) Pathomorphologic aspects of developmental lumbar stenosis. *Orthop Clin. N Amer* 6, 177–196
Verbiest, H (1977) Results of surgical treatment of idiopathic developmental stenosis of the lumbar vertebral canal. *J Bone Jt Surg* 59-B, 181–188
Wiltse, L L (1962) The aetiology of spondylolisthesis. *J Bone Jt Surg* 44-A, 539–560

ndence to A R Choudhury, F.R.C.S., Senior Registrar in Neurosurgery, Department of gery Derbyshire Royal Infirmary, Derby, England.

changes and also on the alteration of the characteristic pattern constructed by drawing lines to join the posterior aspects of the four articular facets of the lumbar vertebrae at the time of operation (McMinn & Hutchings 1977) In the first and second vertebrae, the figure is a vertical rectangle, in the third and fourth vertebrae the figure is square, and in the fifth a horizontal rectangle In the presence of a single disc herniation the characteristic shape is altered at that segmental level only, because the disc and the facet joints lie in the same horizontal plane When there is a more generalized spondylosis alteration of the normal appearances usually occurs at two or more levels We believe this method has a sounder anatomical basis than the use of the stenosimeter (Verbiest 1975, 1977)

A wide laminectomy, including excision of the overhanging hypertrophied facet, is therefore the ideal procedure, as it allows gentle retraction of the nerve roots or cauda equina for exposure and removal of the disc hernia Further, it permits careful examination of the nerve root up to its exit foramen and allows release of adhesions and foraminal decompression, whenever this is needed Lastly, it ensures decompression of the already stenotic spinal canal in its lateral recess, a common occurrence in disc herniation (Paine & Haung 1972, Crock 1976)

It is a surgical axiom that adequate exposure is of the first importance in any procedure This principle, we believe, should apply as much to the intervertebral disc lesion as to anything else Full exposure achieved by wide laminectomy allows for an undamaged decompressed nerve root or cauda equina with minimal scarring and few, if any, postoperative problems The limited and, in our view, inadequate exposure provided by the interlaminar approach is responsible for contused roots, extradural and peri-radicular haematomata, scarring and a wide variety of postoperative problems ranging from persistence of pain and invalidism to profound bilateral weakness of the legs and incontinence

It has been argued that wide [illegible] causes spinal instability We do [illegible] this and no case has been [illegible] series, this was evident by the [illegible] of clinical improvement in [illegible] absence of further slip in [illegible] rays in the three spondylolisthe[illegible] There are many recent reports ([illegible] Paine & Haung 1972, Crock 197[illegible] Hash 1976 Choudhury & T[illegible] supporting our view that instab[illegible] occur Gill & White (196[illegible]) and [illegible] (1970) have also found that [illegible] posterior elements in [illegible] spondylolisthesis does not [illegible] vertebral displacement and [illegible] been stated that spondylolisthes[illegible] increase after the age of 20 years [illegible] Eimola 1961, Wiltse 1962).

In conclusion it may be [illegible] cauda equina syndrome is [illegible] common manifestation in lumbar [illegible] tion and is usually caused by [illegible] structural changes in the spine. The [illegible] wide laminectomy are gratifying

ACKNOWLEDGEMENTS

We are grateful to Dr R. Wheale [illegible] Worthington Consultant Neurora[illegible] their help in radiological investigat[illegible] like to express our gratitude to [illegible] and Miss Barbara Tustin Smith for the [illegible] the preparation and typing of the [illegible]

REFERENCES

Amuso S J Neff R S, Co[illegible] P G (1970) The surgical [illegible] spondylolisthesis by posterior [illegible] tion. A long-term follow-up *J B[illegible]* 52 A 529–536
Choudhury A R. & Taylor J C [illegible] lumbar spinal stenosis *J Neurol* [illegible] *Psychiat* 40, 506–510.
Crock, H V (1976) Observations [illegible] ment of failed spinal operations [illegible] *Surg* 58-B 193–199

(1969a) Significance of small lumbar cauda equina compression syndromes to spondylosis. Part 1 Introduction *J* *surg* **31,** 490–494
(1969b) Significance of small lumbar cauda equina compression syndromes to spondylosis. Part IV Acute compres- artificially induced during operation *J* *surg* **31,** 507–512
B S, Epstein J A & Lavine, L (1964) ffect of anatomic variations in the lumbar brae and spinal canal on cauda equina and root syndromes *Amer J Roentgenol* 055–1063
S (1948) Anatomical studies on lumbar degeneration *Acta orthop scand* **17,** 230
G & White H L (1965) Surgical nent of spondylolisthesis without spinal A long term follow up of operated *Acta orthop scand*, Suppl 85, 5–99
R. I & McNab, I (1954) Structural ges in degeneration of the lumbar intertebral disc their relationship to low back and sciatica *J Bone Jt Surg* **36-B,** 322
R K (1971) The long-term effects of laminectomy for lumbar disc excision *J* *Jt Surg* **53 B** 609–616
L E & Einola, S (1961) Spondyhesis in children and adolescents *Acta* *p scand* **31,** 45–64
T (1964) Osteoarthritis in lumbar synovial s a morphologic study *Acta orthop* *d* Suppl 73, 1–112
b I (1971) Negative disc exploration an ysis of the causes of nerve root involvet in 68 patients *J Bone Jt Surg* **53 A** 903
McMinn, R M H & Hutchings, R T (1977) *A colour atlas of human anatomy* Wolfe Medical Publications Ltd London
Munro, D (1956) Lumbar and sacral compression radiculitis (herniated lumbar disc syndrome) *New Engl J Med* **254,** 243–252
O'Connell J E A (1950) The indications for and results of the excision of lumbar intervertebral disc protrusions A review of 500 cases. *Ann roy Coll Surg Engl* **6,** 403–412.
Paine, K E E & Haung P W H (1972) Lumbar disc syndrome *J Neurosurg* **37,** 75–92
Robinson R G (1965) Massive protrusions of lumbar disks. *Brit J Surg* **52,** 858–865
Schlesinger, E B & Taveras, J M (1953) Factors in the production of cauda equina syndromes in lumbar discs *Trans Amer Neurol Ass* **78,** 263–265
Shenkin H A. & Hash, C J (1976) A new approach to the surgical treatment of lumbar spondylosis *J Neurosurg* **44,** 148–155
Spangfort, E K (1972) The lumbar disc herniation A computer aided analysis of 2,504 operations. *Acta orthop scand*, Suppl 14, 1–95
Verbiest, H (1975) Pathomorphologic aspects of developmental lumbar stenosis *Orthop Clin. N Amer* **6,** 177–196
Verbiest, H (1977) Results of surgical treatment of idiopathic developmental stenosis of the lumbar vertebral canal *J Bone Jt Surg* **59 B,** 181–188
Wiltse L L (1962) The aetiology of spondylolisthesis *J Bone Jt Surg* **44-A,** 539–560

ondence to A R Choudhury F R C S, Senior Registrar in Neurosurgery, Department of urgery, Derbyshire Royal Infirmary Derby England

ıop scand. 51 501–503 1980

VENOUS DRAINAGE OF THE FEMORAL NECK ᴵ PROGNOSTIC SIGN IN PERTHES' DISEASE

HEIKKINEN, PETER LANNING, ILKKA SURAMO & JAAKKO PURANEN

ments of Pediatrics, Diagnostic Radiology and Surgery,
sity of Oulu, Oulu, Finland

The correlation between delayed venous drainage from the femoral neck and "head at risk" factors were studied in 47 patients (50 hips) with Perthes' disease A good correlation was found between markedly disturbed venous drainage and "head at risk" factors Lateral subluxation of the femoral head and Gage's sign correlated best with pathological venography Thus a severely disturbed venous return from a hip with Perthes' disease seems to be a poor prognostic sign.

Key words hip, osteovenography, Perthes' disease, prognosis

Accepted 27 ix 79


outcome of Perthes' disease can be ·ted from plain radiograms of the hip at the time of clinical diagnosis (Eyring 1965, Catterall 1971, Dickens & laus 1978) Catterall (1971) classifies ·s' disease into four groups. Group one ıe best and group four the worst prog- He also lists some radiological signs indicate an especially poor prognosis ·less of the groups. These so-called ı at risk" factors are Gage's sign (which ·efect in the lateral part of the epiphysis), cation lateral to the epiphysis, lateral xation of the femoral head and a ontally placed epiphyseal line

have studied the venous drainage of ·emoral neck in Perthes' disease since As our patients have been followed up nly 2 to 6 years until now, and since ation osteotomies have been performed ı probably influence the course of the se, it is still too early to assess the final al outcome In this study an attempt is to establish the prognostic value of in- seous venography of the femoral neck by comparing the venographic findings with the "head at risk" factors Because of the controversial reports on the significance of the horizontal epiphyseal line (Dickens & Menelaus 1978), this factor was not included in the study

PATIENTS AND METHODS

The present material consists of 47 consecutive patients with recently diagnosed Perthes' disease In three children both hips were affected There were 36 boys and 11 girls The age at the onset of the disease varied from 2 years to 10 years (average 6 9 years)

The "head at risk" factors were evaluated from anterior and Lauenstein lateral X-rays taken at the clinical onset of the disease There were 29 hips with lateral subluxation (the epiphysis-tear



·470 80/030501–03$02.50/0

disease and before possible osteotomy, because this has an influence on the venous drainage The pathological venographies were divided into two groups slightly and markedly pathological according to the amount of contrast medium escaping via the femoral diaphysis compared with the amount escaping via the gluteal circumflex and obturator veins

RESULTS

The proportion of each 'head at risk" factor in normal, slightly pathological and markedly pathological intraosseous venographies is shown in Figure 1 Gage's sign was positive in only one of the 10 hips with normal venography, but was positive in 7/23 and 11/17 of the hips with slightly and markedly pathological venography ($P<0\ 01$) The corresponding figures in cases of lateral calcification were 1/10, 6/23 and 7/17 ($P<0\ 1$) and in lateral subluxation 3/10, 14/23 and 12/17 ($P<0\ 01$) Thus the number of each "head at risk" factor increased with the severity of disturbance of the venous drainage of the femoral neck

Figure 2 shows the number of "head at risk" factors in normal, slightly and markedly pathological intraosseous venography Hips without risk factors were found in all groups but in 6/10 of the hips with normal

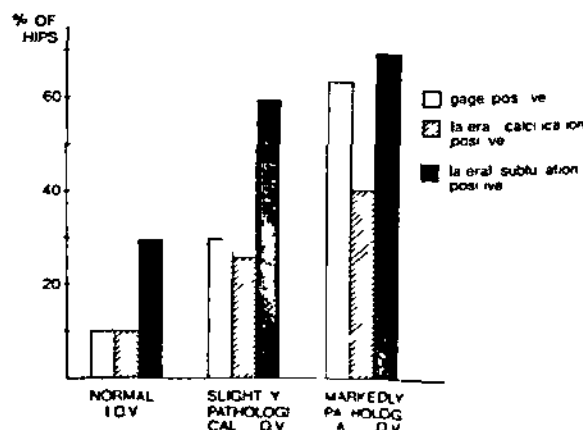


Figure 1 The proportion of each head at risk factor in hips with normal slightly and markedly pathological intraosseous venography (i o v)

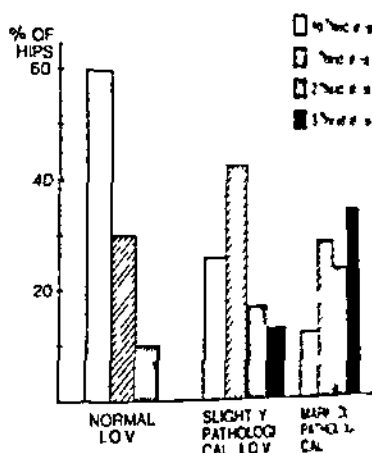


Figure 2 The number of each "head factor in hips with normal s pathological intraosseous venogr

venography and in 6/23 and 2/17 with slightly and markedly pat venography ($P<0\ 001$) On the othe hips with three head at risk" facto not be found in hips with normal ven but in 3/23 and 5/17 of the hips with and markedly pathological ($P<0\ 05$)

DISCUSSION

It is well known that the pr Perthes' disease varies with the ag of the patient at the onset of the Older children and girls have prognosis than boys and younger Neither the reason for these varia the basic etiological factors involve disease have yet been resolved

Disturbances of the arterial and circulation of the femoral neck disease have been reported by sever (Soto-Hall et al 1964 Suzuki 197 1972 Fanne & Engel 1972 1974) Contrast medium inject bone marrow of the femoral neck mainly via the circumflex obturator veins, and only drainage through these veins

ie contrast flow into the diaphysis o & Vuoria 1976) In our experience ive stages of Perthes' disease involve iances in the venous drainage and with clinical and radiological restitution hip the venous drainage seems to to normal (Suramo et al 1974)

the present study correlations were between pathological venographies and at risk" factors. Lateral subluxation of noral head and Gage's sign showed the correlation to pathological venography 01) Thus a severely disturbed venous in a hip with Perthes' disease seems to oor prognostic sign

RENCES

all, A (1971) The natural history of Perthes' ease *J Bone Jt Surg* 53-B, 37–53

is, D R V & Menelaus, M B (1978) The essment of prognosis in Perthes' disease *J ie Jt Surg* 60 B, 189–194

, E J, Bjornson, D R. & Petterson, C A (1965) Early diagnostic and prognostic signs in Legg-Calvé-Perthes' disease *Amer J Roentgenol* 93, 382–387

Traumatologie, 125

Heikkinen, E, Puranen J & Suramo, I (1975) Intraosseous venography in the differential diagnosis of diseases of the hip in children

Traumatologie, 126

Shiba, T (1965) Study on the Legg-Perthes' disease (in Japanese with English summary). *J Jap Orthop Ass* 39, 377

Soto-Hall, R., Johnson, L H & Johnson, R A. (1964) Variations in the intra articular pressure of the hip joint in injury and disease *J Bone Jt Surg* 46-A 509–516

Suramo I Puranen, J Heikkinen, E & Vuorinen P (1974) Disturbed pattern of venous drainage of the femoral neck in Perthes' disease *J Bone Jt Surg* 56-B, 448–453

Suramo I & Vuoria P (1976) Cineangiographic study of the venous drainage of the femoral neck in children *Ann Clin Res* 8, 8–14

pondence to Peter Lanning, Department of Diagnostic Radiology University of Oulu, SF-90220 2, Finland

p. scand. 51, 505–510, 1980

ıROGRAPHY AS AN AID TO DIAGNOSIS, NOSIS AND THERAPY IN ;-CALVÉ-PERTHES' DISEASE

ERSHUNI*, A AXER** & D HENDEL**

n of Orthopaedic Surgery, University Hospital, University of California Medical Center, San 'alifornia, USA and ** Department of Orthopaedic Surgery and Traumatology, Assaf Harofe Zerifin, Israel

epiphysis was slightly larger (22) the same size (9) or smaller (6) than that on the normal side, on arthrography the osteochondral head was much larger in 34 and the same size in 3 instances. In 35 cases the arthrograms

assessed the almost invariably poor head coverage in L C P D This, together with signs of flattening, diagnoses the severity of the disease process and helps to differentiate the "head at risk" which requires treatment During arthrography the degree of abduction-medial rotation of the leg necessary for containment of the flattened protruding head within the acetabulum can be determined allowing accurate therapy to be planned, be it operative or orthotic

Key words arthrography, diagnosis, Perthes, prognosis, therapy

Accepted 20.x.79

agnosis of Legg-Calvé-Perthes' Disease s made from two adequate radiographs, ken in the antero-posterior projection ıe in the Lauenstein (frog) projection · 1A–B) However, the limitations of camination are that the sizes of the ıondral femoral head and acetabulum, shapes and their relationships to one r cannot be accurately assessed, thus ɔe and severity of the lesion may be in-·tely appreciated It has been shown ontainment treatment of the femoral gives the best opportunity for the pment of a spherical head at the end of ;eneration process (Axer 1965, Harrison et al 1969, Petrie & Bitenc 1971, Axer et al 1973, Curtis et al 1974, Brotherton & McKibbin 1977, Salter et al 1977) The problem is to assess the degree of rotation of the femur (or pelvis) required to achieve adequate containment This paper describes how these diagnostic, prognostic and therapeutic questions can be resolved by performing bilateral hip arthrography before deciding on treatment

PATIENTS AND METHODS

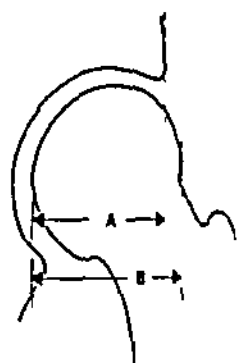
Prior to arthrography, radiographs of the hips of all children were made in the standard neutral and

ı70/80/030505–06$02.50/0



Figure 1 Six year old boy with right sided Legg Calvé Perthes' syndrome in the early fragmentation stage A and B Plain radiographs in antero-posterior and Lauenstein projections The right femoral head appears slightly smaller than that on the left C Arthrogram in antero-posterior neutral projection The right osteochondral head is in fact larger than that on the left and is flattened in the region under the lateral acetabular lip The head protrudes laterally but still maintains contact with the acetabulum medially D Arthrogram with the hips abducted and medially rotated The osteochondral head will be completely contained by the acetabulum on further slight abduction

Lauenstein positions Bilateral hip arthrography was performed in 37 consecutive children suffering from unilateral Legg-Calvé-Perthes' Disease Radiographs of both hip joints were then taken with the hips in neutral position (Figure 1C) in an abducted med ally rotated position (Figure 1D) and in the Lauenstein position Prior measurements of antevers n (Dunlap et al 1953



$\frac{A}{B} \times 100$ = ACETABUL [illegible]

$\frac{\text{Abnormal Side Index}}{\text{Normal Side Index}} \times 100$ = [illegible]

Figure 2 The Acetabulum-Head [illegible]

Axer et al 1972) were helpful [illegible] much medial rotation should [illegible] formed

The following measurements, [illegible] observations were made on both [illegible] patient using the plain radiographs [illegible] arthrograms

1 The widest diameter of the [illegible] neutral and Lauenstein views was [illegible]

2. The acetabulum head [illegible] acetabulum head quotients (Figure [illegible] Herndon 1950) were measured and [illegible] the plain radiographs and on the [illegible] made in the neutral position.

3 Observations were also made [illegible] arthrograms for deformities of the [illegible] and pooling of contrast material

RESULTS

The results of the above [illegible] calculations are shown in Table I [illegible] cases of L C.P D were either [illegible] necrotic (22 cases) or in the [illegible] tion stage (15 cases).

1 *Head diameters*

Radiographs A difference in the [illegible] the femoral heads between the [illegible] 1 mm or more was recorded [illegible] (Schiller & Axer 1972). Of the [illegible]

heads 22 were larger, 9 were the e, 4 were smaller and 2 were 1 mm ı one and 1 mm smaller in the other n as compared with the femoral head pposite unaffected side

Arthrograms Thirty-four affected femoral heads were from 1 to 17 mm larger than the opposite normal femoral head (Figure 1C), the remaining 3 were the same size as the opposite unaffected femoral head

Table 1 Roentgenographic measurements and observations

Stage	Head diameter difference in mm				A. H Q		Flattening
	Regular		Arthrography			Arthrog	
	A P	Frog	A.P	Frog	Regular	raphy	
N	0	2	2	0	100	90	+
N	0	1	0	0	100	88	+
N	−0 5	−0 5	0	0	85	79	+
F	−1	−2	1 5	1 5	85	70	+
F	0	0	1 5	2 5	100	89	+
N	0	−1	2 5	2	90	72	+
F	0 5	0	2	2	95	90	+
N	0	0	2.5	4	97	89	+
F	6	6	•	6	85	•	+
N	0	0	1 5	3 5	100	90	+
N	−1	−1	4	2	100	81	+
F	10	11	15	17	79	75	+
N	2	3	7	6	100	79	+
F	5	10	8	5	89	82	+
N	−1	1	3	4	100	93	+
N	2	2	5	5	98	95	+
F	3	4	5	6	99	92	+
N	1	0	3	2	100	82	+
N	0	0	3	3	90	77	+
N	1	1	2	4	100	79	+
F	2	2	5	7	92	89	+
N	0	0	4	3	93	81	+
F	2	1	5	4 5	88	85	+
F	3	2	4	5	98	92	+
F	5	7	6	6	82	82	±
F	0	0	3	3	78	68	+
N	1	1	2	3	93	94	+
N	1	−1	5	5	100	89	+
N	2	2	7	5	100	90	+
N	3	0	4	4	95	76	+
F	8	7	12	10	72	79	+
F	4	1	4 5	5	91	79	+
N	1	0	8	3	81	78	+
N	0	1	2	2	100	91	+
N	0	−2	0	0	100	95	+
N	1	1	1	1	100	98	+
F	1	0	2	2	100	95	−

ossible to measure
led L.C P S on other side 5 years previously
n-operated cases.
crotic
gmentation.





Figure 3 Seven year-old boy with right sided Legg Calvé-Perthes' syndrome in the necrotic stage A Arthrogram in the antero-posterior neutral projection The osteochondral femoral head is enlarged, protrudes laterally from the acetabulum and is markedly flattened in the region under the lateral acetabular lip B Arthrogram with the hip abducted and medially rotated The flattened region of the head with the pool of contrast material above it is now rotated into the depths of the acetabulum

2 *Acetabulum-head quotients*

In the 37 children with Legg-Calvé-Perthes' Disease the quotient calculated from the arthrographic measurement was less in 34 cases, in one case equal to, and in one greater than the same quotient calculated from the plain radiograph. (One case [illegible] measured)

3 *Observation on the arthrogram*

Flattening of the area of the [illegible] aspect of the osteochondral head [illegible] the lateral acetabular lip was [illegible] present in 35 of the 37 femoral heads [illegible] by Legg-Calvé-Perthes' Disease (F[illegible] and 3A) On the abduction [illegible] rotation arthrogram the flattened [illegible] the head now faced the concave [illegible] central area of the acetabulum, and [illegible] between the two articular [illegible] up with contrast material (Figure [illegible]

DISCUSSION

Arthrography of the hip joints was [illegible] in the present series firstly because [illegible] that while the diameter of the [illegible] head on the affected side as estimated [illegible] plain radiograph, was *slightly* greater [illegible] on the opposite side in 22 cases [illegible] and in the remaining cases was [illegible] smaller, the osteochondral [illegible] diameter, as measured by arthrography, revealed that in 34 cases (92 per [illegible]) *affected head was in fact markedly* [illegible] that on the opposite normal side, [illegible] remaining 3 cases the size of the [illegible] was the same as the unaffected one [illegible] affected femoral head is bigger than [illegible] *is obvious that the acetabular* [illegible] also be greater, since the femoral head [illegible] sublux from the acetabulum [illegible] maintained between the articular [illegible] the medial side of the joint as demonstrated [illegible] Figures 1C–D and 3A–B

Arthrography was also [illegible] demonstrating that in 35 out of [illegible] affected femoral head was not only [illegible] but was also flattened on the [illegible] of the chondral surface even in the [illegible] and fragmentation stages of the [illegible] process. In the neutral [illegible]

area was situated directly under the cetabular lip (Figures 1C and 3A) & Bell (1973) and McKibbin & Ralis on examining pathological material ss (1977) by direct arthroscopic ex- n of the hips of children with Legg- rthes' Disease noted areas of head g in all cases and cartilage fibrillation portion of the femoral head in two- f the hips examined In two cases corded a definite defect in the head pposite the lateral acetabular lip This stive that it is the lateral acetabular ich 'ploughs" into the articular of the enlarged femoral head (Linn id causes the flattening We have also l experimental evidence for this ty in an animal model where, by the n of a synovitis in the hip joint of re rabbits, the osteochondral femoral as stimulated to enlarge The heads veloped a flattened, degenerative area lage under the lateral acetabular lip mi & Axer 1974, Gershuni et al 1978 If the chondral flattening and ation is caused by the "ploughing" of the lateral acetabular lip it seems to remove it from further abnormal by rotating it into the depths of the ulum proper where regeneration and ling of the immature cartilage will Salter et al 1977, Gershuni et al 1978, The necessity for this procedure is d by examination of the arthrogram will demonstrate the presence and of the chondral flattening

acetabulum head index gives a e of the containment of the femoral y the acetabulum, and the acetabulum uotient compares the containment of eased femoral head with that of the side In 34 out of 37 cases the ulum head quotient measured on the ram was less than that measured on gular radiograph Thus it is apparent moral head coverage and containment acetabulum is rather optimistically d when studying plain radiographs ntero-laterally protruded head cannot be molded by the acetabulum and is thus at risk, attainment of a spherical head at the end of the disease process in such a case is unlikely A poor result would then be anticipated when no containment treatment is given, be it surgical or orthotic In two children (nos 36 and 37, Table 1) no significant antero-lateral protrusion of the head was defined by the arthrogram taken in the neutral position and the acetabulum-head quotient as calculated from the arthrogram was not significantly different from that calculated on the plain radiograph These two children have not been treated but are being continually observed and periodically examined radiographically, so far their results have been gratifying The remaining 34 children according to the arthrographic assessment required containment treatment and underwent femoral derotation varus osteotomy (Axer 1965, Axer et al 1973, 1979)

When containment therapy is decided upon the degree of abduction and medial rotation of the femur needed to rotate the protruded and flattened segment of the head to within the confines of the acetabulum can be measured by correlating the position of the femur with the arthrographic appearance (Figures 1D and 3B) The correct degree of varus-derotation femoral osteotomy can thus be tailored to the needs of the individual case Arthrography in these young children has always been performed in the operating theater under general anesthetic If operation is decided upon, this proceeds with continuation of the same general anesthetic and after redraping the part (Axer et al 1979) Alternatively another method of containment therapy may be used (Harrison et al 1969, Petrie & Bitenc 1971) In such a case the knowledge gained from the hip arthrography may be applied in a similar fashion, as when using femoral osteotomy, in more precisely planning treatment

REFERENCES

Axer A (1965) Hip trochanteric osteotomy in the treatment of Perthes disease J Bone Jt Surg 47 B 489 499

Axer, A, Halperin, N & Itzhak, Y (1972) Anteversion of the femur in Legg-Calvé-Perthes' syndrome *Israel J med Sci* 8, 1733–1737

Axer, A, Schiller, M G, Segal, D, Rzetelny, V Gershuni-Gordon, D H (1973) Subtrochanteric osteotomy in the treatment of Legg-Calvé-Perthes's syndrome *Acta orthop scand* 44, 31–54

Axer, A, Gershuni, D H, Hendel, D & Mirovski, Y (1979) The indications for femoral osteotomy in Legg-Calvé-Perthes' Syndrome *Clin Orthop* (In press)

Brotherton, B J & McKibbin, B (1977) Perthes' disease treated by prolonged recumbency and femoral head containment – A long-term appraisal *J Bone Jt Surg* 59-B, 8–14

Curtis, B H, Gunther, S F, Gossling, H R & Paul, S W (1974) Treatment for Legg-Perthes' disease with the Newington ambulation-abduction brace *J Bone Jt Surg* 56-A, 1135–1145

Dolman, C L & Bell, H M (1973) The pathology of Legg-Calvé-Perthes' disease *J Bone Jt Surg* 55-A, 184–188

Dunlap, K, Shands, A R, Hollister, L C, Gaul, Y S & Streit, H A (1953) A new method for determination of torsion of the femur *J Bone Jt Surg* 35-A, 289–311

Gershuni-Gordon, D H & Axer, A (1974) Synovitis of the hip joint An experimental model in rabbits. *J Bone Jt Surg* 56-B, 69–77

Gershuni, D H, Axer, A & Siegel, B (1978) Experimental synovitis in the hip joint of the rabbit and the resulting biomechanical and regressive cartilage changes. *Trans [illegible] Res Soc* 3, 260

Gershuni, D H., Axer A. & Siegel, B [illegible] Localized regressive articular cartilage [illegible] in the hip joint of the rabbit [illegible] induced synovitis. *Acta orthop [illegible]* 179–185

Gross, R H (1977) Arthroscopy [illegible] in children *Orthopaedic Review* [illegible]

Harrison, M H M., Turner M. H. [illegible] F J (1969) Coxa Plana. Results of [illegible] of splinting *J Bone J Surg* [illegible] 1057–1069

Heyman, C H & Herndon, C H [illegible] Perthes' disease A new method for the [illegible] amination of the roentgenographic [illegible] *Bone Jt Surg* 32 A, 767–77[illegible]

Linn, F C (1967) Lubrication of [illegible] The arthrotripsometer *J Bone Jt Surg* [illegible] 1079–1098

McKibbin B & Ralis, Z. (1974) [illegible] changes in a case of Perthes' disease *J Bone Jt Surg* 56-B, 438–441

Petrie, J G & Bitenc, I (1971) The [illegible] weight bearing treatment [illegible] disease *J Bone Jt Surg* 53-B [illegible]

Salter, R B, Rang M., Blackburn [illegible] McArthur, R C., Weighill, F J., [illegible] Stulberg S D (1977) Perthes' disease [illegible] scientific basis of methods of [illegible] their indications. *J Bone Jt Surg* [illegible]

Schiller, M G & Axer A. (1972) Legg-Perthes' Syndrome (LCPS) [illegible] analysis of roentgenographic [illegible] *Clin Orthop* 86, 34–42

Correspondence to David H Gershuni, F R C.S, F R C S E, Division of Orthopaedic Surgery, [illegible] sity Hospital, University of California Medical Center, 225 Dickinson Street San Diego, [illegible] 92103, USA

op scand 51, 511–513 1980

DENCE OF HIP FRACTURES

N JENSEN

nents of Orthopaedic Surgery T–2 & T–3, Gentofte Hospital, Hellerup Denmark

as prevalent in females as in males and the incidence was found to double for each 5 year increment in age The percentage of femoral neck fractures decreased with age in females but was constant in males.

Key words epidemiology, femoral neck fractures, occurrence, fractures, occurrence, hip fractures

Accepted 10 ix 79

cidence of hip fractures has been the of a limited number of studies n 1964, Bauer 1960, Buhr & Cooke Gallanaugh et al 1976, Knowelden et 4, Mårtenson 1962, Nilsson & Obrant Stewart 1955, 1958) However, the r of fractures has been increasing con- ly during the past 20 years.

am (1964) claimed that the number of ctures was increasing more than would ected from the age distribution of the tion, but Nilsson & Obrant (1978) this tendency to vanish in the late

present study deals with the incidence fractures in a suburban area in the

NTS AND METHODS

the period April 1st, 1971 to March 31st, total of 1,598 patients over the age of 50 ere admitted to hospital with hip fractures. l neck fractures were encountered in 47 7 nt of cases (762/1 598) and trochanteric s in 52.3 per cent (836/1 598), 76 7 per 225/1 598) were females with a mean age of 78 years, whereas the mean age in males was 74 years.

In the suburban area studied there was a total of 530 729 persons over 50 years of age resident during the 6-year period The number of elderly people increased slowly during the observation period

The patients were subdivided into age groups with 5 year increments and also according to sex and fracture type The population of the area was similarly subdivided into age and sex groups according to information obtained from the Danish Central Bureau of Statistics. From these data the incidence of hip fractures was calculated and analysed by a multiplicative Poisson model (Andersen 1977)

RESULTS

The incidence of hip fractures did not change significantly during the 6-year period As shown in Figure 1 the incidence of hip fractures increased exponentially with age from the beginning of the 7th decade The sex ratio women/men was 1 99 and the incidence approximately doubled with each 5-year increment in age

170/80 030511–03$02.50 0

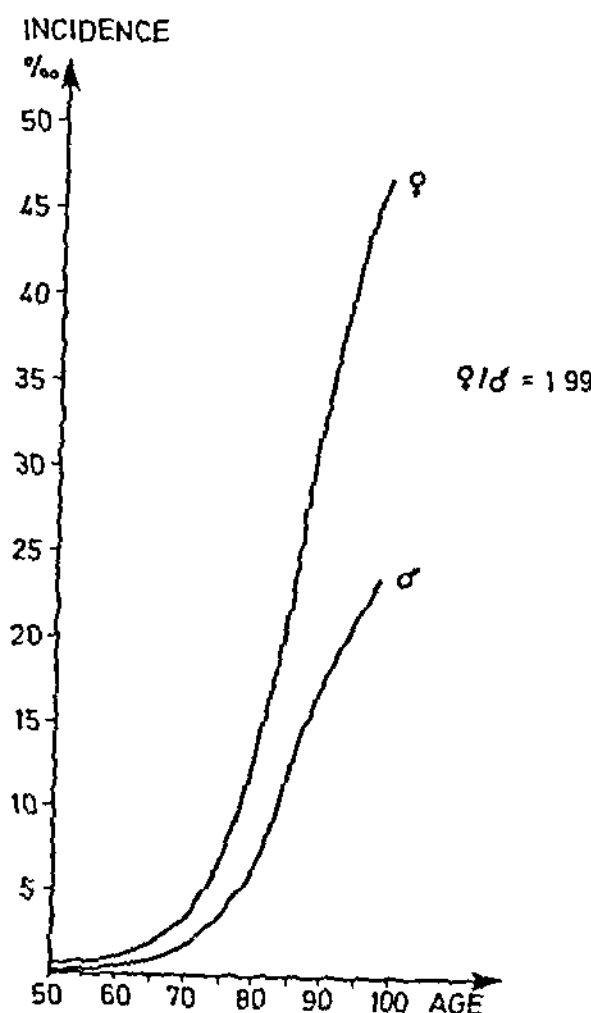


Figure 1 The incidence of hip fractures in the northern suburbs of Copenhagen during the years 1971–1976

The total incidence of hip fractures among females over the age of 50 years was about 4 *per thousand* compared with about 2 per thousand in *males*. The overall incidence was thus about 3 per thousand above the age of 50 *years*, *while* it was about 20 per thousand above the age of 80 years.

The distribution between femoral neck fractures and trochanteric fractures was analysed in relation to age and sex as shown in Figure 2. The percentage of femoral neck *fractures in females* decreased with age and was almost halved from the 5th to the 9th decade, whereas the percentage in males was rather constant and independent of age



Figure 2 The percentage of fem[illegible] in relation to age and sex

DISCUSSION

The incidence of hip fractures [illegible] be about 3 per thousand above the [illegible] years, which accords fairly well [illegible] studies (Gallanaugh et al. 197[illegible] 1972), but is about double the [illegible] reported in the 1950s (B[illegible] Stewart 1955, 1958).

Bauer (1960) found the [illegible] for each 5 year increment [illegible] confirmed by Gallanaugh et al. [illegible] Knowelden et al. (1964) as well as [illegible] present series. The exponential [illegible] hip fractures in the elderly [illegible] paralleled by the number of [illegible] among elderly people (Lock [illegible])

It has been stated by Alffram [illegible] the number of hip fractures [illegible] increased to a greater extent [illegible] expected from the age and sex [illegible] the population. The incidence of [illegible] presented in this series [illegible] recent studies (Gallanaugh et al. [illegible] somewhat higher than [illegible] 1960s (Bauer 1960 [illegible] about twice as high as [illegible] beginning of the 19[illegible] Compared with Alffram's series [illegible]

similar figures until the age of 75 years, considerable increase for the oldest age s. The observations by Nilsson & Obrant that the incidence has not changed since ter 1960s can thus not be confirmed gh the geographical areas concerned in o series are fairly similar As about half of tients sustaining hip fractures are above e of 80 years it is suggested that the nce figures for the oldest age groups l be updated approximately every 10 n order to provide a realistic basis for the planning of the hospital care of patients ip fractures

NOWLEDGEMENTS

study was kindly supported by Nordisk rsikrings Jubilaeumsfond. Gratitude is ssed to Sv Kreiner-Møller (cand. stat.) tment of Data Processing Herlev Hospital tistical aid

RENCES

sen E B (1977) Multiplicative Poissen dels with unequal cell rates. *Scand J tist* 4, 153–158

Alffram P A (1964) An epidemiologic study of cervical and trochanteric fractures of the femur in an urban population. *Acta orthop scand* Suppl 65

Bauer G C H (1960) Epidemiology of fractures in aged persons *Clin Orthop* 17, 219 225

Buhr A J & Cooke A M (1959) Fracture patterns. *Lancet* 1, 531 536

Gallanaugh S C Martin A & Millard P H (1976) Regional survey of femoral neck fractures *Brit med. J* 2, 1496–1497

Gordon P C (1972) The probability of death following a fracture of the hip *Canad med Ass J* 105, 47 51

Knowelden J Buhr A J & Dunbar O (1964) Incidence of fractures in persons over 35 years of age *Brit J prev soc Med* 18, 130–141

Lucht U (1971) A prospective study of accidental falls and resulting injuries in the home among elderly people *Acta sociomed scand* 3, 105–120

Mårtensen L (1962) Ar svensk sjukhusplanering andamålsenl g? *Lakartidn* 59, 3185–3201

Nilsson B E & Obrant K. J (1978) Secular tendencies of the incidence of fracture of the upper end of the femur *Acta orthop scand* 49, 389–391

Stewart I M (1955) Fractures of neck of femur Incidence and implications. *Brit med J* 1, 698–701

Stewart I M (1958) Fracture of neck of femur The rate risk and casualty planning *Med Officer* 100, 100

pondence to J Steen Jensen MD Department of Orthopaedic Surgery T–2 Gentofte Hospital, 900 Hellerup Denmark

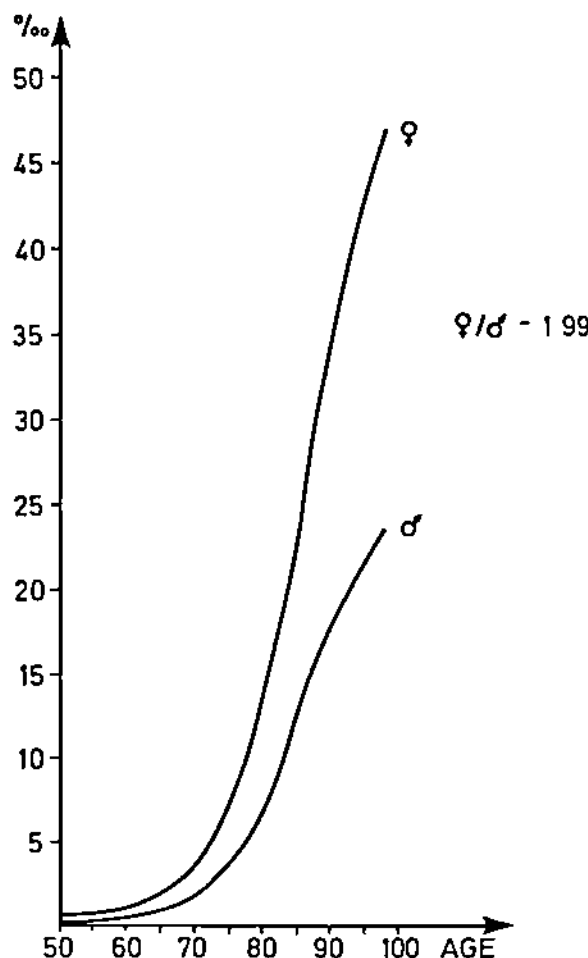


Figure 1 The incidence of hip fractures in the northern suburbs of Copenhagen during the years 1971–1976

The total incidence of hip fractures among females over the age of 50 years was about 4 per thousand compared with about 2 per thousand in males The overall incidence was thus about 3 per thousand above the age of 50 years, while it was about 20 per thousand above the age of 80 years

The distribution between femoral neck fractures and trochanteric fractures was analysed in relation to age and sex as shown in Figure 2 The percentage of femoral neck fractures in females decreased with age and was almost halved from the 5th to the 9th decade, whereas the percentage in males was rather constant and independent of age

Figure 2 The percentage of femoral neck [illegible] in relation to age and sex

DISCUSSION

The incidence of hip fractures was fo[illegible] be about 3 per thousand above the a[illegible] years, which accords fairly well with studies (Gallanaugh et al. 1976, G[illegible] 1972), but is about double the [illegible] reported in the 1950s (Buhr & Cooke [illegible] Stewart 1955, 1958)

Bauer (1960) found the incidence to [illegible] for each 5-year increment in age, which [illegible] confirmed by Gallanaugh et al. (19[illegible] Knowelden et al. (1964) as well as [illegible] present series The exponential incre[illegible] hip fractures in the elderly was [illegible] paralleled by the number of diseases [illegible] among elderly people (Lucht 1971).

It has been stated by Alffram (19[illegible] the number of hip fractures during the [illegible] increased to a greater extent than wo[illegible] expected from the age and sex distribu[illegible] the population The incidence of hip [illegible] presented in this series agrees wi[illegible] recent studies (Gallanaugh et al 1[illegible] somewhat higher than in studies [illegible] 1960s (Bauer 1960 Mårtensson 1[illegible] about twice as high as in series [illegible] beginning of the 1950s ([illegible] Compared with Alffram's series ([illegible]

Acta orthop. scand. 51, 515–522, 1980

[PR]OGNOSTIC EVALUATION OF THE HOSPITAL [RES]OURCES REQUIRED FOR THE TREATMENT [OF] HIP FRACTURES

[J]EN JENSEN & E. TØNDEVOLD

[Depart]ments of Orthopaedic Surgery T-2 & T-3, Gentofte Hospital,
[Hellerup], Denmark

A retrospective study of 1,592 hip fracture patients over the age of 50 years was undertaken, recording the age and sex, the fracture type and treatment, the hospitalization time and the rate of technical failures.

Based on the predicted population in the area of admission it was calculated that the number of hip fractures will double within the next 17 years.

An analysis of the hospitalization time in relation to the various types of treatment and the rate of technical failures made it possible to calculate the hospital resources required in the future. It was found that despite the considerable increase in the number of hip fractures treatment can be undertaken without further allotment of resources provided a rationalized treatment plan is instituted aiming at the safest possible methods of treatment, as the hospitalization time was found to be considerably influenced by technical failures of the treatment.

Key words: femoral neck fractures, hospitalization, internal fixation

Accepted 10.ix.79

[The] average age of the population in the [West]ern countries is increasing and in recent [year]s it has been shown that the incidence [of hi]p fractures is increasing exponentially [with] age, so that the incidence doubles for [each] 5-year increment in age after the 5th [deca]de (Bauer 1960, Gallanaugh et al. 1962, [...]n 1980). The increasing number of [elder]ly people in the population involves an [incre]asing number of hip fractures, this being [one] of the most common conditions in [geria]tric medicine.

[Alt]hough the health systems in the [West]ern countries are facing the effects of the [worl]d economic crisis with reductions in [allotm]ents for hospital care little attention has [been] paid to the consequences of the increasing number of hip fractures (Gylling 1960, Lindberg & Sjostrand 1972, Mårtenson 1962).

The purpose of the present study is to estimate the hospital resources required in the future and to find a reasonable economic solution for the problem of the treatment of an increasing number of hip fractures.

PATIENTS AND METHODS

During the period April 1st, 1971 to March 31st, 1977 a total of 1,592 patients over the age of 50 years were admitted to hospital with hip fractures. Femoral neck fractures were recorded in 47.5 per cent of the cases (756/1,592) and trochanteric fractures in 52.5 per cent (836/1,592).

0001-6470/80/030515–08 $02.50/0

Table 1 The background population (over 50 years of age) in the area of admission during the 1971–1976

	1971	1972	1973	1974	1975	[illegible]
Original area of admission	83,257	84,720	86 315	87 908	89 065	[illegible]
Extension of area					1,803	[illegible]
Total	83,257	84,720	86 315	87 908	90 8[illegible]	[illegible]

The background population consisted of 530,729 persons, over the age of 50 years, resident in the area of admission during the 6-year period As seen from Table 1, the background population increased from 83,257 persons in 1971 to 97,661 persons in 1976 On January 1st, 1976 an extra municipality was added to the area of admission, which involved a recruitment of 7,609 persons in the final year of the observation period The yearly increase in the background population was 8 per cent (6,795/83,257) corrected for the increased area of admission

A retrospective study was undertaken recording the age and sex of the patients, the type of fracture, the type of treatment, the hospitalization time and the number of technical failures for each year of the period

From the Danish Central Bureau of Statistics the expected number of inhabitants over 50 years of age for all the municipalities of the area of admission was obtained for every year until March 31st, 1992 The expected background population for each year is recorded in Table 2.

Table 2 The expected background population (over 50 years of age) for the extended area of admission during the years 1977–1991

	Number of inhabitants	Yearly increase
1977	98,370	+709
1978	99,265	+895
1979	99,821	+556
1980	100,394	+573
1981	100 624	+230
1982	100,777	+153
1983	100,821	+ 44
1984	100,847	+ 26
1985	100,802	− 45
1986	100,695	−107
1987	100,641	− 54
1988	100,614	− 37
1989	100,466	−148
1990	100,388	− 78
1991	100,261	−127

Based on these data and on previous [illegible] of the incidence of hip fractures according [illegible] sex in the area (Jensen 1980) a prediction [illegible] number of hip fractures could be made [illegible] calculations regarding the expected [illegible] time were made taking into account the [illegible] technical failures of the fracture treatment

RESULTS

The number of patients admitted [illegible] year of the period is shown in Figure 1 [illegible] total number of hip fractures increased [illegible] 221 in 1971 to 343 in 1977 [illegible] for the extra municipality included [illegible] 2 years of the period, the yearly [illegible] the number of hip fractures was 8 per [illegible] (17/221) or a total of 47 per cent [illegible]

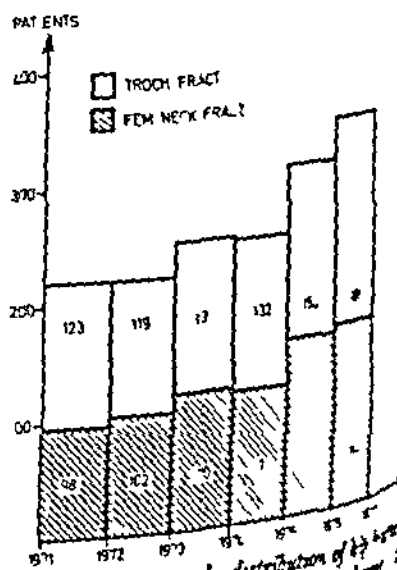
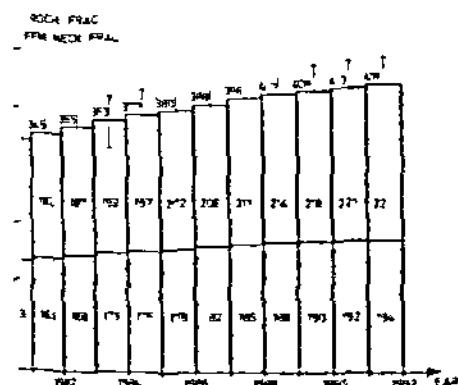


Figure 1 The yearly distribution of [illegible] in 1,592 patients admitted during [illegible] period 01 04 1971–31 03 1977



Predicted number of hip fractures in the admission for the period 1979–1992

increase in the number of trochanteric femoral neck fractures did not differ antly ($P = 0.76$, Chi-square test).

d on the expected composition of the tion of the area and the calculated ce of hip fractures a prediction of the r of hip fractures for the period 1992 was made. Figure 2 demonstrates lculated figures including the 95 per onfidence limits.

omparison with the 221 hip fractures in a doubling of the number might be ed from about 1988 within the ence limits stated. Thus, the number of actures is expected to double within a of 17–26 years. As seen from the m a yearly increase in the number of



3 The average hospitalization time ng hip fractures in 1 592 patients admitted period 1971–1977

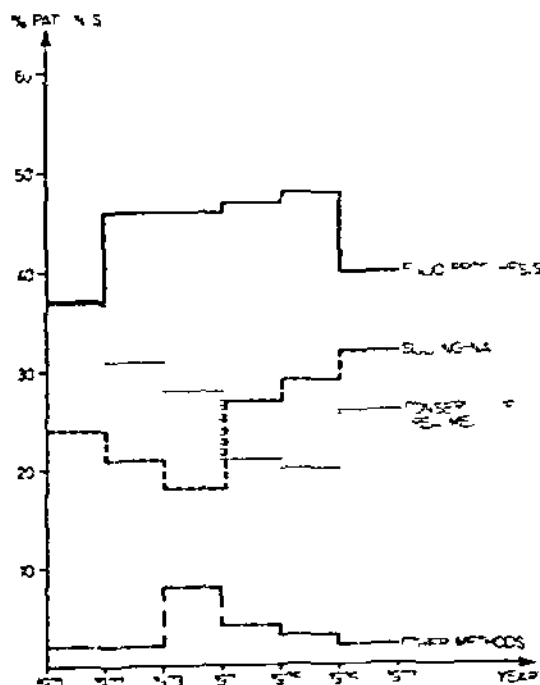


Figure 4 The methods of treatment of femoral neck fractures in the period 1971–1977

hip fractures of about 3 per cent is predicted in the beginning of the period, but due to stagnation of the population increase – as seen in Table 2 – the yearly increase drops to about 1.5 per cent in the latter part of the period. The confidence limits, however, allow yearly increases of about 11–13 per cent.

During the observation period the hospitalization time for patients with hip fractures decreased from 28 days in 1971 to 22 days in 1976, as shown in Figure 3. The number of hospital beds occupied by patients with hip fractures thus only increased from 17 beds in 1971, equivalent to 6,188 hospital days, to 21 beds in 1976, equivalent to 7,546 hospital days, due to the reduction in hospitalization time. This also means that about 18 per cent (21/118) of all orthopaedic hospital beds in the area were constantly occupied by this category of patients in 1976.

Supposing the hospitalization time will be 21 days on average, as it was in the last 2 years of the observation period, the 372 patients (range 334–410) expected in 1984

Table 3 Hospitalization time in relation to type of treatment and technical failure of [illegible] fractures

	Uneventful course	Hosp. time (days)	Techn. failure	[illegible]
Femoral Neck Fractures				
sliding-nail	144	20.6	[illegible]	[illegible]
conservative treatment	175	18.3	[illegible]	[illegible]
endoprosthesis	318	23.3	[illegible]	[illegible]
other methods	17	23.2	9(3 %)	[illegible]
Trochanteric Fractures				
McLaughlin	396	20.7	[illegible]	[illegible]
Jewett	243	28.1	[illegible]	[illegible]
sliding screw-plate	85	23.3	2(2%)	[illegible]
conservative treatment	37	19.6		[illegible]
other methods	9	24.6	6(4%)	[illegible]

will require 22 hospital beds (range 20–24) and in 1989 the corresponding figures will be 408 patients (range 368–448) needing 24 beds (range 22–26), equivalent to 19 and 20 per cent of all hospital beds, respectively. The yearly consumption of hospital days will be 7,812 in 1984 and 8,[illegible] in 1[illegible] [illegible] These calculations presuppose [illegible] percentage of technical failures [illegible] unchanged pattern of fracture [illegible]

With the purpose of finding [illegible] extent extra hospital days could be [illegible] meet the increasing demand [illegible] analysis of the treatment of the [illegible] was undertaken. In Figure 4 the [illegible] treatment of femoral neck fractures [illegible] demonstrated. It is seen that [illegible] endoprosthesis, i.e. hemiarthroplasty [illegible] ing to Moore or Thompson, was [illegible] constantly applied in about 44 p[illegible] (334/756) of cases. Conservative [illegible] i.e. early weight-bearing [illegible] decreased during the 6-year period [illegible] about 39 per cent (38/98) in 1971 [illegible] per cent (42/162) in 1976. [illegible] fixation by a sliding-nail [illegible] per cent (22/95) in 1971 to 32 [illegible] (52/162) in 1976. As seen from Table [illegible] hospitalization time was [illegible] (P < 0.001, Mann-Whitney test) [illegible] uneventful course of treatment [illegible] with technical failures. [illegible] hospital days were needed [illegible] these cases. It is also seen that [illegible] of technical failures following [illegible] fixation is about 25 per cent [illegible] compared with 13 per cent [illegible] servatively treated cases. Technical [illegible]

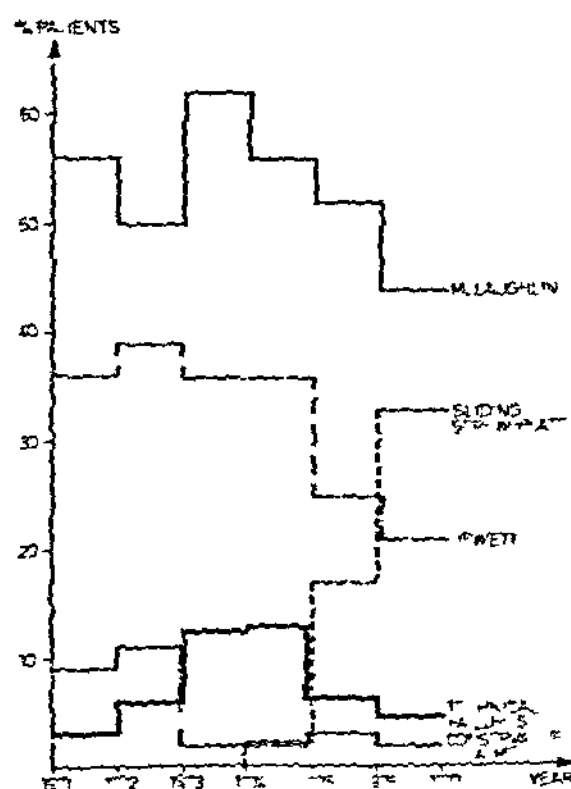


Figure 5 The methods of treatment of trochanteric fractures in the period 1971–1977

neck fractures led to secondary
thesis.

hanges in the methods of treatment
nteric fractures are demonstrated in
5 It is seen that nearly all these
were internally fixed The sliding
ate was introduced in 1974 and was,
d of the period, applied in about 33
(59/181) of cases Due to this the use
wett and McLaughlin hip nail-plates
d considerably and at the end of the
hese two types of nail-plates were
ed in 20 per cent (37/181) and 44 per
/181), respectively, of trochanteric
The sliding screw-plate was
introduced for the treatment of
trochanteric fractures and resulted in
ed reduction in the frequency of
failures, as also seen from the
Technical failures after internal
of trochanteric fractures were
by re-osteosynthesis According to
technical failures were encountered in
cent of cases (42/438), on average,
McLaughlin osteosynthesis
d with 6 per cent (15/258) after
steosynthesis and 2 per cent (2/88)
sliding screw-plate fixation,
the latter method was applied in
fractures and followed by early
earing mobilization It can also be
m Table 3 that the hospitalization
s considerably prolonged in the case
nical failures ($P = 0.0001$, Mann-
test)

effects on hospitalization time of
failures and the modern trend of
te weight-bearing mobilization in all
as applied during the latter 2 years of
rvation period, were further analysed
ral neck fractures the hospitalization
lowing sliding-nail fixation has been
ng constantly during the 6-year
rom about 30 days to 18 days. Similar
were encountered following primary
hroplasty or non-operative treatment
efore assumed that the following ideal
ization times will be obtained in uncomplicated cases within a couple of years sliding-nail fixation 16 days, hemiarthroplasty 18 days and conservative treatment 12 days. We also assumed that the pattern of treatment in the future will be unchanged and will include 30 per cent sliding-nail fixation, 45 per cent primary hemiarthroplasty and 25 per cent conservative treatment Finally we assumed that the number of technical failures will be unchanged as will hospitalization times after technical failure, as seen in Table 3

With these assumptions in mind the yearly consumption of hospital days was calculated In 1984 the number of femoral neck fractures was expected to be 175 and the consumption of hospital days 3,184, compared with 190 patients and 3,431 days, respectively, in 1989 Thus the number of hospital beds needed for the treatment of femoral neck fractures would be an average of 9 in 1984 and 10 in 1989 As it has not been possible so far to find methods which involve a lower frequency of technical failures, we consider the required number of hospital days as stated to be a rather realistic estimation With the high frequency of technical failures following internal fixation with sliding nails consideration should be given to applying primary hemiarthroplasty in patients physiologically younger than the 75 years which has been the limit up to date In the case of a change in the pattern of treatment so that sliding-nail fixation was used in 25 per cent of cases and primary hemiarthroplasty in 50 per cent, which involves altered treatment in only 5 per cent of cases, 27 hospital days could be gained in 1984 and 5 days in 1989 This means that less than 1 per cent of the hospital days could be saved by an alteration of the treatment in 5 per cent of cases.

The hospitalization time following internal fixation of trochanteric fractures with the McLaughlin nail-plate has been fairly constant over the years being about 21 days in uncomplicated cases, while the hospitalization time has decreased from 34 days to 17 days following Jewett nail-plate fixation due

to the introduction of the sliding screw-plate system for unstable trochanteric fractures. The average hospitalization time following sliding screw-plate fixation has been 23 days. We expect the ideal hospitalization time in uncomplicated cases in the near future to be 21 days for McLaughlin cases, 17 days in Jewett cases and 21 days after sliding screw-plate fixation. Assuming a pattern of fracture treatment as in 1976 with McLaughlin fixation in 46 per cent, Jewett in 20 per cent and sliding screw-plate in 34 per cent of cases, and hospitalization times as mentioned above and in Table 3, with an unchanged frequency of technical failures, the yearly consumption of hospital days was calculated. In 1984 the number of trochanteric fractures is expected to be 197 and the consumption of hospital days 4,177 compared with 218 patients and 4 636 days in 1989. Thus the number of hospital beds needed for the treatment of trochanteric fractures would be an average of 12 beds in 1984 and 13 beds in 1989.

As mentioned above the sliding screw-plate system was introduced in 1974 for the treatment of unstable trochanteric fractures and has reduced the frequency of technical failures considerably. Assuming that all unstable trochanteric fractures in the future will be treated by this fixation system, with unchanged hospitalization time and technical failure rate, we would expect 70 per cent of fractures to be fixed by this method. The application of Jewett or McLaughlin nail plates in stable fractures is expected to be unchanged, which means 11 and 19 per cent of cases, respectively. The hospitalization time is assumed to be the same for these two methods, i.e. 17 days, as well as the technical failure rate of 5 per cent (Jensen & Michaelsen 1975). With these assumptions the yearly consumption of hospital days could be calculated to be 3 987 days in 1984 and 4 404 days in 1989, which means that about 5 per cent of the hospital days could be saved by alterating the pattern of fracture treatment and concentrating on using safer methods.

DISCUSSION

The number of elderly [illegible] tion has been increasing [illegible] (Boucher 1959, [illegible] & Cooke [illegible] Martenson 1962), but [illegible] prognosis this trend will [illegible] suburban areas during the [illegible]

According to Boucher (19[illegible]) [illegible] third of all beds in [illegible] hospitals are occupied by old [illegible] Lucht (1971) found that about [illegible] domestic falls in elderly [illegible] fractures.

Hip fractures in elderly [illegible] rather serious problem in [illegible] and prognostic evaluations [illegible] the future planning of orthopaedic wards.

In the present series we found [illegible] increase in the number of hip [illegible] during the period 1971 19[illegible] of [illegible] cent assuming a uniform increase [illegible] background population. As in [illegible] (Alffram 1964, Lindberg & [illegible] Martenson 1962) we have only [illegible] yearly increase of about 2 3 per cent [illegible] the stagnation of the population [illegible] this reckoning the number of hip [illegible] can be expected to double within [illegible] about 17 years, which agrees with [illegible] recent observations (Alffram 1964, [illegible] Cooke 1959, Falch & [illegible] Gallanaugh et al. 1976, Martenson [illegible]

Gylling (1960) stated that the [illegible] hip fractures is consuming an increasing [illegible] portion of the total number of beds [illegible] which can be confirmed by our [illegible] the evaluation of future needs it is [illegible] important to consider the average [illegible] tion time. In former series ([illegible] Gylling 1960, Mårtensson 19[illegible] the [illegible] pitalization time was about [illegible] days [illegible] has decreased enormously during [illegible] to about 30 days (Gallanaugh et al. [illegible] Lindberg & Sjöstrand 197[illegible] [illegible] series a further reduction in the [illegible] tion time has been encountered [illegible]

ıg of the 1970s so that ın the period 976 ıt was about 21 days. Thus on is mainly due to more active itation, encouraging early mobilization ıll weight-bearing It ıs of course ly difficult to predict the future ization time for the treatment of hip s, as this ıs to a great extent ent on the possibility of discharging ients to rehabilitation institutions In sent series we have estimated the ideal lization time in uncomplicated cases to ut 12 days for non-operatively treated l neck fractures, about 16–18 days for internal fixations and primary throplasty and about 21 days for the l fixation of unstable trochanteric es. We are convinced that these tes are fairly realistic considering we aling with elderly patients with an e age of about 77 years (Jensen 1980) ur opinion the economic crisis in the services in the Western countries that a further allotment of resources for al or rehabilitation institutions cannot pected We will therefore be forced to ays of solving the problem of treating reasing number of hip fractures using ume number of hospital beds in the itly established orthopaedic units. It is easy to predict the number of hip res according to the population prog- but the hospital resources required are ıced by the trends in hospitalization ollowing the different methods of treat- The most essential factor to consider is equency of technical failures, as these ollowed by a considerably prolonged alization time – in the present series days. We agree with Gallanaugh et al that ıt is of utmost importance to ve the fracture treatment and apply the possible methods. In our opinion a tion in the consumption of resources can itained by applying internal fixation in al neck fractures in younger, mobile its only and using sliding screw-plate on in unstable trochanteric fractures, as this will reduce the number of technical failures considerably

In the present series a total of 7,546 hospital days were needed for the treatment of hip fractures in 1976 The hospital resources required in the future were evaluated by three different methods. The simple estimation of hospital days based on the expected number of patients multiplied by an average hospitalization time of 21 days (as encountered during the last 2 years of the observation period) involved a consumption of 7,812 hospital days in 1984 and 8,568 hospital days in 1989 By comparison, the calculations based on unchanged treatment methods and unchanged failure rates but gradually decreasing hospitalization times, following the trend throughout the observation period, led to a consumption of 7,361 hospital days in 1984 and 8,067 days in 1989, which is about 6 per cent less than the first calculation The third prediction included an alteration in the methods of treatment with preference for the safest methods with a minimum of technical failures. These calculations gave a further reduction of hospital days to 7,144 days in 1984 and 7,830 days in 1989, or a gain of about 2.5–3 per cent

Considering the economic aspects of the future hospital treatment of orthopaedic diseases we feel it is very important to perform the prognostic evaluations of the hospital beds required in the future on the basis of a rational approach to the treatment applying the safest possible methods. In the examples presented it is thus possible to treat about a 15 per cent increase in the number of patients with hip fractures using the same resources as were consumed in 1976 by such alterations in the attitude to the treatment, and thereby to keep up with the increased influx of patients without demanding further resources.

In conclusion, we found that the number of patients with hip fractures admitted to hospital will double within a period of about 17 years, but that the treatment can be

undertaken with unchanged demands on hospital resources by rational planning aiming at the safest possible methods of treatment, as the hospitalization time is considerably influenced by technical failures of the treatment.

ACKNOWLEDGEMENTS

This study was kindly supported by Nordisk Gjenforsikrings Jubilaeumsfond. Gratitude is expressed to Sv Kreiner-Møller (cand. stat.), Department of Data Processing Herlev Hospital, for statistical aid.

REFERENCES

Alffram, P A. (1964) An epidemiologic study of cervical and trochanteric fractures of the femur in an urban population. *Acta orthop scand.* Suppl. 65

Bauer G C. H. (1960) Epidemiology of fracture in aged persons. *Clin. Orthop* 17, 219–225

Boucher C. A. [illegible] persons. *Geriatrics* [illegible]

Buhr A. J & Cook, A. [illegible] patterns. *Lancet* [illegible], 531 [illegible]

Falch, J & Ilebekk, A. [illegible] femurende. *T norske Lægeforen* [illegible]

Gallannaugh, S. C., Martin, A. & [illegible] (19 6) Regional survey of [illegible] fractures. *Brit. med. J* [illegible]

Gylling B (1967) [illegible] socialmedicinsk problem [illegible] (*Stockh.*) 5, 1 3 183.

Jensen, J Steen (1980) Incidence of hip fr[illegible]. *Acta orthop scand.* 51 511 [illegible]

Jensen, J Steen & Michaelsen, M. [illegible] Trochanteric femoral fractures [illegible] McLaughlin osteosynthesis. *Acta orthop scand.* 46, 795 807

Lindberg L. & Sjöstrand, L. O [illegible] höftkirurgi. Prognos för [illegible] *Läkartidn.* 69 4109–411[illegible]

Lucht, U (1971) A prospective study of falls and resulting injuries in the [illegible] elderly people. *Acta [illegible]* [illegible] 105–120.

Martenson, L. (1962) [illegible] andamålsenlig? *Läkartidn.* 59 [illegible]

Correspondence to J Steen Jensen, MD Department of Orthopaedic Surgery T, [illegible] DK 2900 Hellerup, Denmark.

·op. scand. *51*, 523–530, 1980

·OARTHRITIS OF THE HIP

·ology and Clinical Role

JØRRING

·nent of Orthopaedic Surgery U, Rigshospitalet, Copenhagen, and the Department of Radiology, ·penhagen City Hospital, Denmark

Among 6321 patients who had undergone X-ray examination of the colon 4 7 per cent proved to have osteoarthritis of the hip A mild osteoarthritis was found to be equally common in both sexes, but in all age groups above 60 severe osteoarthritis of the hip was twice as common in women as in

troublesome than the lateral

According to the present study, only half the patients who exhibit

Key words osteoarthritis of the hip, clinical role, epidemiology, need of treatment

Accepted 1 vii 79

·ccordance with clinical experience, a ·ogist, when examining for other condi- ·will frequently come across patients ·iting obvious osteoarthritis of the hip ·ut their having had any complaints · mentioning The same applies to the ·ral joints as has been pointed out pre- ·ly by Lawrence et al 1966, and Schmorl ·unghans 1932 However, although ·logically demonstrable osteoarthritis of ·up has often been reported to occur ·ns 1949, Danielsson 1966) no one has ·ously demonstrated how large a propor- ·of these patients are symptom-free

·e present investigation was designed to ·ate a randomized material of patients ·radiological osteoarthritis of the hip ·a view to studying the epidemiology and the social significance as well as the clinical features of the osteoarthritis.

PATIENTS AND METHODS

An X-ray examination of the colon includes at least one anteroposterior view of both hip joints and several oblique views. On the basis of such an examination, therefore, it is possible to decide whether radiological signs of osteoarthritis of the hips are present As it is reasonable to assume that no relationship exists between colonic diseases and osteoarthritis of the hip joints, the choice of patients referred for X-ray examination of the colon can be regarded as a random selection – in relation to osteoarthritis of the hip.

As a criterion of osteoarthritis narrowing of the joint space to 3 mm or less was chosen. This distance is arbitrary Gofton (1979) and Köhler

·6470/80/030532–08$02.50 0

(1956) chose the same distance – 3 mm – as an expression of cartilaginous narrowing in X-rays of the hip joint.

A cartilage thus reduced was an isolated finding in two women aged 50 while in others it was associated with sclerosing of the subchondral bone and/or subchondral cyst formation and/or osteophytes. Sclerosing with cysts or osteophytes without joint space narrowing was not observed. Osteophytes situated exclusively at the lateral edge of the acetabulum were not interpreted as a sign of osteoarthritis (Brailsfort 1952, Danielsson 1964). Likewise, sclerosing without a reduced depth of cartilage was not interpreted as osteoarthritis. Isolated cyst formation was not observed.

A radiological classification of the osteoarthritis was performed according to Kellgren (1963), who has suggested a radiological classification into four grades and hanging up in the viewing room a typical representative of each. A given film, then, belongs to the grade to which it is most similar.

During the 10-year period, 1963–1972 inclusive, a total of 6360 patients underwent X-ray examination of the colon in the Copenhagen City Hospital. All the films were reviewed to detect osteoarthritis of the hip. In 6321 of the patients the hip joints could be assessed, but 39 patients had to be excluded, as their hip joints were not satisfactorily visualized.

The material did not include many patients under 25 years of age, but it has previously been demonstrated that osteoarthritis hardly ever occurs in children or young adults.

RESULTS AND DISCUSSION

Prevalence of osteoarthritis of the hip

Among the 6321 patients, 299 proved to have osteoarthritis of the hip. This is a prevalence of 4 7 per cent. In women the rate was 5 6 per cent, in men 3 7 per cent, i e a female male ratio of 3 2

Osteoarthritis was sporadic prior to the age of 50 years, thereafter increasing with advancing age. The youngest patient having osteoarthritis of the hip was 37 years, the oldest 98 years. The osteoarthritis was unilateral in 168 of the 229 patients (56 2 per cent)

Mild osteoarthritis (grades 1 and 2) was equally common in both sexes in the age range 60–89 ($P < 0\ 05$). Severe os[illegible] (grades 3 and 4) was twice as c[illegible] females as in males in all [illegible] ($P < 0\ 001$) Ten patients aged [illegible] younger had osteoarthritis. The [illegible] arthritis in these patients was second[illegible] genital dislocation and dysplasia [illegible] acetabulum or central protrusion

Clinical examination 108 patients

Radiological evidence of oste[illegible] the hip was found in 299 [illegible] time of the follow-up 179 of them [illegible] another four refused to particip[illegible] in a state of senile dementia too fa[illegible] to be able to give any anamnesis [illegible] two patients could not be traced [illegible] Thus, we have a series of 10[illegible] included in the complete follow-up [illegible]

The complete follow-up study c[illegible] history taking, physical examina[illegible] examination of the hip joints, meas[illegible] height and weight, laboratory tests [illegible] antistreptolysin titre, rheumatoid [illegible] factor, Rose-Waaler, gonococcal [illegible] and serum urate. The result of the h[illegible] X-ray examination was not known at the [illegible] of the physical examination.

Social status

On the basis of interviews, the pa[illegible] their parents were classified [illegible] 4–8 (Noordhoek 1969). In men the [illegible] class was the same as their fathers [illegible] among the women there was a [illegible] a lower social status.

As a person's social class is de[illegible] an early age (Svalastoga & Wolf [illegible] can be no question of osteoarthritis [illegible] causing a lower social status, but the [illegible] might indicate that a low social [illegible] increases the risk of osteoarthritis of the [illegible] in women

tion

patients were questioned about the of their work which was divided into grades according to the physical ss (Shepherd 1954, Sneppen 1972) A proportion of the men than of the had heavy work (more than one-third men as compared with less than one- the women) This difference is not int, but the study confirms Kellgren & ce's (1961) assumption that osteo- s in men is affected by heavy physical hich increases the prevalence

cular importance was given to whether ients had changed their occupation of the hip disease This was true of ree, all women A lawyer had chosen ry work in the insurance branch, a hairdresser had changed to a sedentary ning job, and a factory worker had l to sedentary instead of standing

litation, disablement pension

patient had tried rehabilitation year-old dustman with osteoarthritis ary to gout), but gave up because of ties in learning and was awarded dis- nt pension

ng the 108 patients, 6 men and 18 were receiving disablement pension of osteoarthritis of the hip

men and five women had retired early nsion, and two women were receiving blement benefit (which is lower than a ment pension), but were still working ement pension was awarded rather ll the men were 56 years or over except e who was 43 The women were 51 or over except for four who were 21, and 46

eight men and two women had gone any form of sport during their lives. them there was no question of increased complaints on account of the osteoarthritis – on the contrary The findings do not support Murray's theory (1971) that increased athletic activity during youth is an aetiological factor in osteoarthritis of the hip Puranen et al's (1975) study of 74 contest runners also disproved that sport could contribute to inducing osteoarthritis of the hip

Radiological severity and site of the osteoarthritis

In the 108 surviving patients who attended follow-up there were fewer unilateral cases than in the total material (43/108 *versus* 168/299) Moreover, there was a preponderance of severe osteoarthritis in the group that attended follow-up (36 per cent *versus* 25 per cent) Both findings can be explained by the patients getting older during the period elapsing from the time of the X-ray examination of the colon to the follow-up examination Radiological regression was not observed in any case

Classification of the osteoarthritis according to site in the hip joint (Danielsson 1964, Pearson & Ridell 1962) was based upon an anteroposterior 30 × 40 cm film of both hip joints, 50 per cent were lateral, 24 per cent medial, and 26 per cent mixed Danielsson (1964) found 33 per cent to be lateral, 22 per cent medial, and 45 per cent mixed Pearson & Ridell (1962) 78 per cent lateral and 22 per cent medial In the three series, then, the occurrence of a medial localization was the same (22–24 per cent), but there is a disagreement about the lateral occurrence

On the basis of the X-ray appearances, supplemented by anamnestic data, the aetiology of the osteoarthritis was assessed The frequency of osteoarthritis secondary to dislocation coxitis and trauma does not differ from previous findings Murray's claim (1971), that subclinical epiphysiolysis is often responsible for the occurrence of osteoarthritis of the hip, could not be confirmed

Table 1 History of pain and localization of pain in 108 patients with osteoarthritis of the hip (37 ♂ and 71 women)

	37 ♂	♀
Morning stiffness	19	[illegible]
Starting pain	21	[illegible]
Pain on movement	21	[illegible]
Pain during weight bearing	26	[illegible]
Rest pain	11	[illegible]
Pain disturbing sleep	8	[illegible]
Localization		
Anterior aspect of hip	16	[illegible]
Posterior aspect of hip	7	1
Lateral aspect of hip	4	
Knee joint	8	[illegible]
Knee joint, without signs of knee joint disorder	1	[illegible]
No pain	12	[illegible]

Clinical evaluation of the pain in osteoarthritis of the hip

The nature of the pain in patients with osteoarthritis of the hip and the site of the pain are listed in Table 1 Twenty-two patients had no pain at all

Table 2 gives a numerical grading of the pain according to Merle D'Aubigné (1952)

In Table 3 the patients' own assessment of the complaints is summed up Half of them did not attribute much importance to the osteoarthritis, and one-fifth were entirely symptom-free

These tables confirm what had already been concluded from the radiographic findings In the women the osteoarthritis [illegible] more severe than in the men.

Three of the patients who ascribed [illegible] importance to their hip joints had [illegible] suffered pain Thus, in three of the [illegible] patients the osteoarthritis had "burnt [illegible]

Objective clinical evaluation of the patients

The patients' height and weight [illegible] measured The ideal weight in kg was [illegible] to be the height in cm less 100 ± 1[illegible] (Werner & Berfenstam 1960) 31 per [illegible] were overweight and 24 per [illegible]

Table 2 Evaluation of pain in 108 patients with osteoarthritis of the hip (Merle D'Aubigné [illegible])

Points	Pain	♂	♀
0	Very severe constant pain	0	[illegible]
1	Very severe pain disturbing sleep	1	[illegible]
2	Severe pain during walking, all activities restricted	3	[illegible]
3	Bearable pain limited activities	3	[illegible]
4	Pain only after walking quickly disappearing during rest	7	[illegible]
5	Mild pain activities not restricted	9	[illegible]
6	No pain	12	[illegible]
		37	

·3 The patients' own evaluation of their ·lisability (37 men and 71 women)

	♂	♀	
bility	11	10	54
·iscomfort	12	21	
·rable discomfort	6	21	54
d	8	19	
	37	71	

ight This corresponds to normal ınavian series

overweight patients were more ·ed by their osteoarthritis than the un-ight ones, but in accordance with : & Dickson (1968) there was nothing ·licate that being overweight was an ·gical factor in the development of ·rthritis of the hip

bility in the hip joint was related to the ·gical osteoarthritis and to the sub-· complaints In broad terms, there was ·mity between mobility and radiological ty, yet five patients had good mobility e severe radiological osteoarthritis On ther hand, none had major limitation of ment in the presence of mild os-·hritis. The complaints increased with ed mobility, but the most serious com-·s were caused by articular contractures

·o-thirds of the patients had clinically ptible shortening of one leg

lf the patients with osteoarthritis of the ad associated venous insufficiency This ıce the prevalence found in the adult sh population (Arnoldi 1958, Borschberg)

it was normal in 19 patients none of n was bothered by their osteoarthritis of ·ip, although radiologically it was con-·ble in six In the remaining patients the ·attern was characterized by a leaning of body towards the osteoarthritic joint third of the patients walked without a stick, and one-quarter used one ordinary stick (Table 4)

The patients' ability to manage simple everyday tasks, such as putting on shoes and socks and walking stairs was evaluated and it was found that the women were less able to cope than the men

Treatment

It was mainly pain which made the patients consult a doctor, and to a lesser extent difficulty in walking or working

Thirty out of the 108 patients had never sought medical treatment for their osteo-arthritis of the hip, their complaints not being so severe that they could not manage without treatment Only a few had consulted a chiropractor or a natural healer, and only one patient had exclusively received that kind of treatment (acupuncture) Two patients had been rejected by a chiropractor who could not do anything about their arthritis.

The treated patients had received medica-tion and physiotherapy, only eight had undergone surgery Eleven patients had been treated by X rays

Table 5 sums up the data for the eight operated patients Only five had undergone operations which are still in use today The operated group is too small to permit any evaluation of the result

Table 4 The use of a stick and crutches among 108 patients with osteoarthritis of the hip

	No walking aids	Using 1 stick	Using 2 sticks	Using 1 elbow-stick	Using 2 elbow-sticks	Using a walking frame	Unable to walk	Total
♂	17	11	2	3	1	2	1	37
♀	20	16	5	3	10	15	2	71
Total	37	27	7	6	11	17	3	108

Table 5 Surgery among 108 patients with osteoarthritis of the hip (Eight patients had surgery performed)

Patient No	Patient sex	Age in years at surgery	Duration of osteoarthritis at surgery, years	Follow-up period, years	Radiological degree of osteoarthritis Right/left	Type of operation	Indication for surgery	Patient's own evaluation of the effect of surgery
14	♂	71	5	5	1/4	McKee-Farrar	Pain, difficulty in walking	Some effect
18	♀	58	9	31	4/4	Adductor tenotomy	Pain, difficulty in walking, difficulty in working	No effect
37	♀	64	10	5	4/4	McKee-Farrar, bilateral	Pain, difficulty in walking, bilateral ankylosis	Some effect The patient is in a wheelchair
49	♀	66	6	3	3/4	Intertrochanteric osteotomy, right	Pain, dificulty in walking, difficulty in working	No effect
67	♀	69	17	1	3/1	Intertrochanteric osteotomy, right	Pain, difficulty in walking	Good effect
76	♀	85	5	1	0/4	Resection of obturator nerve	Pain	Good effect
107	[illegible]	60	1	5	4/4	McKee Farrar left	Pain difficulty in walking	Good effect
[illegible]	[illegible]	[illegible]	[illegible]	[illegible]	[illegible]	[illegible]	Pain difficulty in walking	[illegible] effect

men and seven women in the present
were advised by the author to have an
ty The aim of surgery is primarily to
the patients of pain, and secondarily to
better mobility in some of the hips
dication for surgery in this series was
This advice was given only to patients
pain on weight-bearing as well as rest
isturbing their sleep All these patients
diological grade 3 or 4 osteoarthritis
en 1963), and the operation was
d only after a duration of several years.
males and three females disabled by their
ease were so debilitated by old age that it
ot considered wise to offer them any kind
ery

our patients (out of 108) having ogical evidence of osteoarthritis of the thout major complaints

these cases 44 per cent were medial
-medial) as compared with only 24 per
among the total of 108 This confirms
ondsson's (1970) finding that medial os-
hritis has a more favourable prognosis
lateral (in the sense that it bothers the
its less)

bility in the hip joints was better in the
without major complaints, and they
fewer contractures. There was no
ion of these patients having been spared
rationally, on the contrary

CLUSION AND SUMMARY

g 6321 patients who had undergone X-
xamination of the colon 4 7 per cent
d to have osteoarthritis of the hip The
e male ratio was 3 2, and in both sexes
revalence rose with advancing age Mild
arthritis was equally common in both
, but in all age groups above 60 severe
arthritis of the hip was twice as common
men as in men

total of 108 patients (37 men and 71
en) attended clinical follow-up examination Osteoarthritis setting in at an early age (at 50 or earlier) was found to be secondary In 50 per cent the arthritis was located laterally and in 24 per cent medially The medial cases had a more favourable prognosis (the arthritis was less troublesome) than the lateral ones.

A low social status increased the prevalence of osteoarthritis of the hip in women (but not in men), and heavy physical work increased the frequency in men There was no evidence that participation in sport might increase the risk of osteoarthritis affecting the hip joints.

During the years which had elapsed from the X-ray examination of the colon to the time of the follow-up, the osteoarthritis had progressed Only in three of the 108 patients had the osteoarthritis "burnt out"

The main complaint was pain, usually affecting the anterior side of the hip Patients without pain did not know they had osteoarthritis of the hip, or else they did not pay any attention to it One-third of the men and almost half the women had rest pain One-fifth of the patients were free of pain, and one-quarter had never sought medical advice because of their hip disease One-half had no complaints or only mild ones

There was not a greater number of overweight patients among those with osteoarthritis of the hip, but overweight patients were more troubled by their osteoarthritis than others

Contracture of the hip was more annoying than restricted mobility and half the patients had venous insufficiency (which is twice the prevalence in the general adult Danish population)

In keeping with the fact that the osteoarthritis was more severe radiologically in the women than in the men, the women were also more severely affected by the condition They more often had to apply for disablement pension, they had more severe pain, and they were more handicapped in activities of daily living

Thirty-three out of 108 patients were so debilitated by their hip disease that they had been awarded disablement pension, others

received disablement benefit, or early old-age pension

According to the present study, only half the patients who exhibit radiological evidence of osteoarthritis of the hip actually need treatment Among those who do, it is estimated that one-third would benefit from surgery, chiefly total alloplasty

ACKNOWLEDGEMENT

The significance calculations were carried out by Jørgen Nyboe, statistician to Rigshospitalet, University of Copenhagen

REFERENCES

Arnoldi, C C (1958) The heredity of venous insufficiency *Dan med Bull* 5, 168–178

Borschberg, E (1967) *The prevalence of varicose veins in the lower extremities* S Karger Basel Switzerland

Brailsfort, J F (1952) Osteoarthritis of the hip joint *Brit J Radiol* 25, 76–84

Collins, D H (1949) *The pathology of articular and spinal disease* pp 1–331 Edward Arnold and Co, London

Danielsson L G (1964) Incidence and prognosis of coxarthrosis *Acta orthop scand*, Suppl 66, 1–114

Danielsson, L G (1966) Incidence of osteoarthritis of the hip *Clin Orthop* 45, 67–72

Gofton, J P (1971) Studies in osteoarthritis of the hip *Canad med Ass J* 104, 679–683

Hermodsson, I (1970) Roentgen appearance of coxarthrosis *Acta orthop scand* 41, 169–187

Kellgren J H (1963) The epidemiology of chronic rheumatism A symposium organized by the council for international organizations of medical sciences UNESCO & WHO Rome 28/8 1/9, 1961

Kellgren J H & Lawrence, J [illegible] Osteoarthritis as seen in random [illegible] the population *J Bone Jt Surg* [illegible]

Kohler, A (1936) *Grenzen des [illegible] anfange des pathologischen im [illegible]* 1–466 G Thieme Stuttgart.

Lawrence J S, Bremmer J M & [illegible] Osteoarthrosis. Prevalence in the [illegible] and relationship between [illegible] changes. *Ann rheum Dis* 25, [illegible]

Merle D'Aubigné R & Chabrol, J [illegible] arthrodéses de la hanche par [illegible] *Chir* 90, 293–326

Murray, R O & Duncan C [illegible] activity in adolescence as an [illegible] in degenerative hip disease *J Bone Jt S* 53-B, 406–419

Noordhoek J A (1969) *Sociale [illegible]* Studie nr 17 pp 1-66. Social[illegible]stituttet Copenhagen

Pearson J R. & Ridell, D M. [illegible] osteoarthritis of the hip *Ann rheum Dis* 31–39

Puranen J, Ala Ketola L, [illegible] Saarela J (1975) Running and [illegible] teoarthritis of the hip *Brit. med. J* [illegible]

Saville P D & Dickson J (1968) [illegible] in osteoarthritis of the hip. *Arthr rheum* 11, 635 644

Schmorl, G & Junghans, H (1932) *Die gesunde und kranke wirbelsaule im [illegible]* pp 1–253 G Thieme Leipzig

Shephard, M M (1954) Assessment of [illegible] after arthroplasty of the hip joint. *J Bone Jt Surg* 36-B 354–363

Sneppen O (1972) *Malleolar [illegible]* pp 1–225 Munksgaard, Copenhagen

Svalastoga K & Wolf P (1965) *Social mobilitet* pp 1–211 Gyldendal, Copenhagen

Werner I & Berfenstam, R. [illegible] nutritionstillståndet och [illegible] sammenhangande faktorer hos [illegible] år *Socialmed T* 37, 334–33[illegible]

Correspondence to Knud Jørring M D Carlsmindeparken 1, DK-2840 Holte Denmark

op scand. 51 531–534 1980

ORAL AND SCIATIC NEUROPATHIES AFTER AL HIP ARTHROPLASTY

G FJELD SOLHEIM & ROLF HAGEN

Hansens Hospital, Sandvika, Norway

Six patients with peripheral nerve lesions after total hip replacements were reviewed The incidence of peripheral nerve lesions was six out of 825, i.e 0 7 per cent The neuropathies, four sciatic, one femoral and one combined femoral and sciatic, were due to damage by the reamer in one case, haemorrhage in two, whereas the cause was unknown in three patients. After conservative treatment and 1–5 years follow up the recovery was classified as good in three, fair in one and poor in two patients.

Key words femoral and sciatic nerve injury peripheral nerve lesion, total hip arthroplasty

Accepted 20 x.79

ieral neuropathies are an uncommon roublesome complication of total hip plasty The *incidence of clinical* ieral nerve damage varies from 0 53 ne 1976) to 3 per cent (Evarts et al Buchholz & Noack (1973) reported tory nerve damage in 1 52 and perma- damage in 0 41 per cent

is report presents six patients with complications, emphasizing the causes, ment and prognosis.

ENTS AND METHODS

g a period of 8¾ years, from September 1970 th May 1979, a total of 825 total hip ements were performed and clinically est neuropathies developed after the tion in six patients, i e there was an nce of 0 7 per cent. The posterior approach een used in all patients with nerve lesions ut of the 825 operations) and none of them reoperations or complicated by posterior dis- on Fifty four per cent of the total number of its operated on were women.

Christiansen's trunnion bearing prosthesis with varying neck sizes of 5 10 or 15 mm was implanted to obtain a correct length of the extremity and to avoid undue tension in the soft tissues and neurovascular structures after reduction

All six patients had a prolonged convalescence after the arthroplasty, the hospitalization period being 7–10 weeks.

All the complications were treated conservatively with exercises, crutches, electrical stimulation and orthotic devices.

Case reports

Case 1 In a 77-year-old woman with necrosis after a fracture of the right femoral neck the sciatic nerve was pulled by the reamer through a posterior hole in the acetabulum. The nerve was judged to be macroscopically intact by inspection Postoperatively there was complete paralysis of the extensor and peroneal muscles of the foot, weakness of the biceps femoris muscle and loss of sensation over the dorsum of the foot and the lateral aspect of the calf Five years after the arthroplasty the patient was still using a toestrap for her dropfoot and the condition was unchanged. The recovery was classified as poor (Table 1)

6470/80. 030531–04$02 5) 0

Most likely this heavy traction injury caused an undiscovered partial rupture (neurotmesis) of the nerve

Case 2 A 62-year-old woman with osteoarthritis of the right hip presented postoperatively a peroneal nerve palsy with dropfoot However, definite weakness of the hamstrings aroused suspicion of a more proximal lesion The electromyographic examination revealed a denervation pattern of the hamstrings and the extensor and peroneal muscles of the foot and substantiated the diagnosis of a sciatic nerve lesion Within 2 months postoperatively there was some return of function of the hamstrings Two years after the operation the patient had completely regained function, both clinically and electromyographically and the result was classified as good

The cause of the nerve lesion in this case was unknown, presumably, the nerve was stretched or injured by retractors

Case 3 A 68-year-old woman with an arteriosclerotic disease, treated with arterial reconstructive surgery in the right thigh, was 5 years later operated upon for osteoarthritis of the right hip After the operation there was complete *peroneal nerve paralysis, weakness of the tibial* nerve innervated flexor group and loss of sensation over the entire foot and the lateral aspect of the calf During the following months she regained full function of the flexor muscles. After 1 year there was also some return of function of the extensor muscles but she still used a toestrap when walking outside The result was rated as fair

The cause of the nerve injury was unknown, but stretching of the nerve or injudicious retraction during the operation, in addition to the impaired circulation of the extremity, might well have contributed to the sciatic nerve palsy

Case 4 A 58-year-old woman with an osteoarthritis of the left hip revealed postoperatively a total paralysis of the left quadriceps muscle and hypoaesthesia in the whole distribution of the femoral nerve Electromyographic and nerve conduction examinations showed complete denervation of the quadriceps muscle and also mild sciatic [illegible]

patient regained some quadriceps function and 1 year postoperatively the recovery was almost complete as shown by the clinical and electromyographical examination Therefore the result was classified as good

The cause of the nerve injury was unknown, but was probably due to stretching or [illegible] retraction of the nerves.

Case 5 A 64-year-old man with [illegible] the left hip suddenly [illegible] accompanied by swelling in his left [illegible] thigh on the sixth postoperative day [illegible] following day the thigh became tense [illegible] and the function of the ankle and foot [illegible] and of the peroneal muscles was [illegible] The Achilles reflex was absent [illegible] however, proved to be normal. Over a [illegible] years, using a dorsiflexion brace for his [illegible] there was no improvement of the [illegible] and the recovery was classified as poor

The cause of the sciatic [illegible] haemorrhage and haematoma due to [illegible] warfarin (Marevan[®]) [illegible] anticoagulant therapy was adequately [illegible] (TT ≥ 7 per cent)

Case 6 A 63-year-old woman, oper[illegible] rheumatoid arthritis of the left h[illegible] weeks postoperatively sudden, [illegible] the left groin during extension [illegible] following day the pain increased in [illegible] radiated down to the knee and leg [illegible] appeared on the medial aspect of [illegible] *the groin* She developed a complete [illegible] paralysis with loss of [illegible] patellar reflex and loss of sensation in the [illegible] and lower aspect of the thigh, [illegible] inner side of the leg The electromyographic [illegible] nerve conduction examinations showed [illegible] denervation of the quadriceps. During the [illegible] weeks the patient noticed some return of [illegible] of the quadriceps muscle After 1 year [illegible] complete recovery, only the sensation [illegible] medial part of the lower leg was [illegible] impaired *The recovery* was classified [illegible]

This case demonstrates a typical [illegible] haematoma with femoral nerve [illegible] neuropathy was caused by haemorrhage [illegible] extension exercises of the hip during [illegible] warfarin anticoagulation though the [illegible] therapy, also in this case was adequate [illegible] (TT ≥ 7 per cent).

RESULTS

After a follow-up period of [illegible] recovery was classified as follows [illegible] represented complete recovery [illegible] partial recovery with decreased [illegible] and *poor* meant no improvement of the [illegible]

1 Clinical data in six patients with peripheral nerve injuries after total hip arthroplasty

Sex	Age	Type of neuropathy	Cause	Recovery at follow up (years)	
♀	77	Sciatic	Reamer	Poor	5
♀	62	Sciatic	Unknown	Good	2
♀	68	Sciatic	Unknown	Fair	1
♀	58	Femoral, sciatic	Unknown	Good	1
♂	64	Sciatic	Haemorrhage	Poor	2
♀	63	Femoral	Iliacus haematoma	Good	1

e Three patients were classified as one as fair and two as poor (Table 1)

USSION

operative trauma with traction and ulation during hip surgery may render rves more vulnerable In a prospective with EMG before and after plasty through a lateral approach, : et al (1976) found that subclinical damage occurred in 70 per cent of the ts, and often more than one of the ', femoral and obturator nerves were ed

ve palsy may occur because of ing, retraction or direct impingement e nerves (Murray 1973) after local ire from cement or damage caused by eat of the polymerization (Moczynski et 73) but it may also be caused by perative hip dislocation (Lazansky

itic nerve palsy due to intra and/or ex- ral haemorrhage has been described in ts receiving anticoagulants (Fleming et 79) Iliacus haematoma complicated by al nerve palsy, secondary to haemophilia lfellow et al. 1967) therapeutic or pro- ctic heparin (Stern & Spiegel 1975) or rin anticoagulation (Brantigan et al is well known but has also been ed after trauma (Green 1972)

mediate decompression of the nerves intra- and/or extraneural haemorrhage is mended if the palsy is progressing and might have led to a better outcome in Case 5 in our material In contrast, Case 6 with an iliacus haematoma demonstrates, like most of the reports from the literature the good results of conservative treatment for this condition

On the whole, the treatment of nerve injuries due to operative trauma or fracture is often conservative if the nerves are thought to be macroscopically intact Explorative surgery is recommended 7–8 weeks after nerve damage if there are no signs of nerve regeneration (Hagen 1970) Any strong suspicion of direct lesion or impingement on the nerve by cement, bone or sutures, with no sign of recovery, should probably be explored even earlier

However, none of these possible causes was suspected among our cases neither was there any apparent correlation between nerve damage and the lengthening of the extremity produced by the arthroplasty which amounted to ½–1 cm in five patients and 2 cm in one patient

Case 2 demonstrated a clinical finding which was also pointed out by Weber et al. (1976) that an apparent peroneal nerve palsy is more likely a result of sciatic nerve damage at the level of the arthroplasty A thorough clinical and electromyographical examination may verify the level of the nerve lesion in doubtful cases.

There was a preponderance of women in our material We are of the opinion that this female predisposition might be due to an increased vulnerability of the nerves because of a changed vascular supply after pregnancy and not to their having less muscle bulk as suggested by Weber et al (1976)

The material indicates that the prognosis for most of the patients with severe nerve injuries after total hip arthroplasty is good unless the nerve has been badly damaged, as in our Case 1

Peripheral nerve injuries, i e those with clinical evidence of nerve damage, in connection with hip arthroplasty can be avoided if careful surgery is performed This study has not provided evidence against the use of the posterior approach which in our opinion has several advantages

REFERENCES

Brantigan, J W, Owens M L & Moody, F G (1976) Femoral neuropathy complicating anticoagulant therapy *Amer J Surg* 132, 108–109

Buchholz, H W & Noack, G (1973) Results of the total hip prosthesis design "St George" *Clin Orthop* 95, 201–210

Dolanc, B (1976) Local peroperative complications. Total hip prosthesis (Ed Gschwend N & Debrunner, H U) pp 66–76 Hans Huber Bern

Evarts C M, Dehaven K. E Nelson C L Collins H R & Wilde, A H (1973) Interim results of Charnley Müller [illegible] arthroplasty *Clin. Orthop* 95 [illegible]

Fleming R E, Michelsen, C. B & [illegible] E (1979) Sciatic paralysis. A [illegible] bleeding following hip surgery *J B[illegible] Surg* 61-A 37–39

Goodfellow J Fearn, C. B & [illegible] (1967) Iliacus haematoma. A [illegible] plication of haemophilia *J Bone J Surg* [illegible] B, 748–756

Green J P (1972) Proximal avulsion of the [illegible] with paralysis of the femoral nerve *J B[illegible] Surg* 54-B 154 156.

Hagen R (1970) *Peripheral nerve [illegible] Norw Med Ass* 90, 945–950.

Lazansky, M G (1973) Complications [illegible] The debit side of total hip replacement *C[illegible] Orthop* 95, 96–103

Moczynski G., Abraham, E., B[illegible] R D (1973) Evaluation of total hip [illegible] ment arthroplasties. *Clin. Orthop* [illegible] 213–216

Murray, W R (1973) Results in patients [illegible] total hip replacement arthroplasty *C[illegible] Orthop* 95, 80–90.

Stern M B & Spiegel P (19[illegible]) [illegible] neuropathy as a complication of [illegible] anticoagulation therapy *Clin. Orthop* [illegible] 140–142.

Weber E R Daube J R & Co[illegible] (1976) Peripheral neuropathies associated [illegible] total hip arthroplasty *J Bone J Surg* [illegible] 66–69

Correspondence to Ludvig Fjeld Solheim, Martina Hansens Hospital N 1300 Sandvika [illegible]

ı scand. 51, 535–540, 1980

ATION OF THE ACETABULAR SOCKET AFTER L HIP REPLACEMENT DETERMINED BY TGEN STEREOPHOTOGRAMMETRY

ıR BALDURSSON, LARS INGVAR HANSSON
H OLSSON & GÖRAN SELVIK

ents of Orthopaedic Surgery and Diagnostic Radiology, Lund University Hospital, and ent of Anatomy, University of Lund, Sweden

In order to evaluate the feasibility of a roentgen stereophotogrammetric method for the analysis of the migration pattern of joint prostheses, tantalum balls were implanted into the acetabular socket and the pelvic bone during total hip replacement in four patients with rheumatoid arthritis. During the postoperative period the migration of the acetabular socket was determined The observation period varied from 5–24 months.

No clinical or radiographic signs of mechanical loosening or infection were noted

All the investigated patients showed a gradual migration of the acetabular socket The cranial migration measured up to 1 8 mm in 2 years. The migration along the transverse and sagittal axes was less but not constantly directed The rotatory movements about the three axes varied and measured up to 5 5° in 2 years. The translation and rotation were greatest during the first few months.

The results indicate a gradual migration of the acetabular socket in hip arthroplasty in the osteopenic skeleton in rheumatoid arthritis.

In conclusion roentgen stereophotogrammetry may prove to be a valuable means of analysing the migration of implanted prostheses and detecting prosthetic loosening, thereby increasing the possibility of early and correct diagnosis and therapy

Key words arthroplasty, hip, knee, prosthesis, rheumatoid arthritis, roentgen stereophotogrammetry

Accepted 12.v 79

ost cases of total hip arthroplasty, there no signs of mechanical loosening or ıon (Charnley & Cupic 1973) On the hand, it is not a completely stable on, but one maintained by a fibrous h which develops between the bone nt with the prosthesis and the bone : (Willert et al 1974)

has been shown that a total hip pros- s, unstable because of infection or mechanical causes, can be exchanged with good results (Lindberg et al 1977) To ensure the best possible conditions at the exchange operation, any instability of the prosthesis must be detected at an early stage before too much bone around the femoral and acetabular prosthesis and the bone cement has been resorbed

The conventional radiographic examination of total hip prostheses often provides too

6470 80 030535–06$02.50 0

Table 1 *Movement of the acetabular socket in relation to the pelvis Positive translations from the origin along the X, Y and Z axes are defined as, to the left side, in the cranial direction and in the anterior direction of the patient, respectively Translations are given for the geometric centre of the acetabular tantalum indicators or for the medial (m) and lateral (l) tips of the acetabular wire of the Charnley-type prosthesis (Case GL) Rotations of the acetabular socket with tantalum indicators are defined as positive in the clockwise direction about different axes (as viewed from the origin)*

						Rotary movement in degrees about			Translatory movement in mm along		
Case	Sex	Age at operation	Operated hip	Type of prosthesis	Observation period in days after first examination	transverse axis X	longitudinal axis Y	sagittal axis Z	transverse axis X	longitudinal axis Y	sagittal axis Z
GA	M	69	Right	Brunswik	0–33	−0.8	0.4	−0.4	−0.32	0.00	−0.53
					0–166	−0.1	0.2	−1.3	−0.23	0.13	−0.22
					0–404	−0.8	0.2	−1.5	−0.35	0.42	−0.15
BJ	M	38	Right	Charnley	0–89	−1.0	0.1	2.9	0.40	0.97	−0.08
					0–196	−2.1	0.4	3.5	0.18	1.20	0.23
					0–376	−1.3	0.7	4.3	0.15	1.46	0.39
					0–741	−1.4	0.5	5.5	0.06	1.75	0.06
SH	F	55	Right	Charnley	196–376[1]	0.4	0.4	−0.2	−0.33	0.15	0.07
					196–741	0.1	0.3	−0.1	−0.40	0.19	0.36
GL	M	53	Left	Charnley	0–140				−0.31 m	0.49 m	−0.51 m
									0.04 l	0.21 l	−0.29 l

[1] The first two postoperative examinations could not be used since one of the three implanted balls in the pelvic bone was found to be unstable A fourth tantalum ball was then inserted and found to be stable

little information about loosening (Sjostrand 1974) In particular the acetabular socket in total hip prostheses is difficult to investigate because of the small differences in projection There is a need for a precise technique in order to discover prosthetic loosening and migration at an early stage Therefore tantalum balls were implanted in the socket of total hip prostheses and in the surrounding pelvic bone, and a roentgen stereophotogrammetric method (Selvik 1974) was used to analyse the migration of the acetabular socket in relation to the pelvic bone

PATIENTS

Four patients with severe disabling rheumatoid arthritis with multiple joint involvement were chosen for this study (Table 1) because there is a high frequency of migration of the prosthesis after total hip replacement in cases of this type The age of the patients varied from 38 to 69 years. The duration of rheumatoid arthritis varied from 9 to 24 years.

METHOD

The primary objective of roentgen stereophotogrammetry is to determine the three-dimensional co-ordinates of structures in the body (Selvik 1974 Olsson 1975 Olsson et al 1976 Hansson et al 1978) Generally there are no sufficiently distinct points in the body to allow a highly accurate identification in the two projections necessary for a three-dimensional reconstruction

Therefore 3–5 tantalum balls (Figure 1) diameter 1 0 mm, served as radiopaque indicators, and were inserted into drill holes in the polyethylene acetabular socket of the hip prostheses in three cases. The holes were about 2 mm deep made with a drill of 1 mm diameter In the fourth case equipment failure prevented the

Figure 1 AP radiographs of the pelvis of patient BJ a Preoperative radiograph b Postoperative radiograph showing the tantalum indicators in the anterior and posterior superior iliac spines and the pubic tubercle Five indicators in the acetabular socket are also seen. c Radiograph at follow-up 2 years after operation

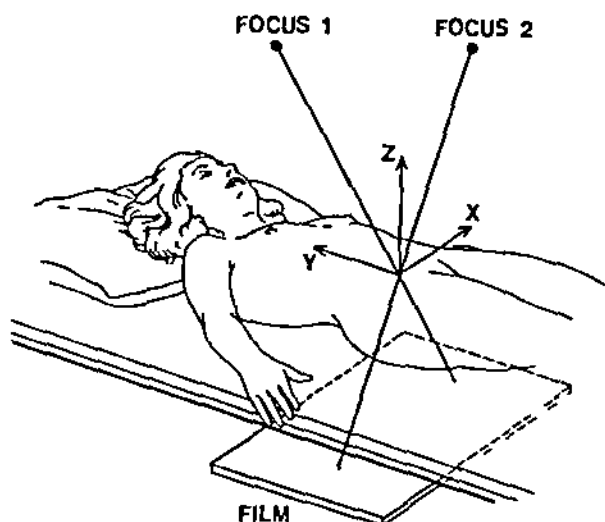


Figure 2 The stereo investigation of a patient The distance between the foci is about 650 mm, the film-focus distance is about 1200 mm, and the film size is 600 × 400 mm The directions of the co-ordinate axes are also shown

insertion of the balls, instead, the ends of the wire in the socket were used as measurement points Another 3–4 tantalum balls (Figure 1), diameter 0 8 mm, were inserted into the pelvis according to the technique of Aronson et al (1974) They were widely separated in the pelvic bone to increase the precision of the method Thus they were placed in the anterior and posterior superior iliac spines, the pubic tubercle, and the ischial tuberosity The tantalum balls serve as measurement points on the radiographs (Figure 1) All the tantalum balls were inserted during total hip replacement

The radiographic examination (Selvik 1974, Hansson et al 1978) was performed 5–15 days postoperatively and was repeated during the following months (Table 1) Simultaneous exposures of the pelvis with two roentgen tubes on one film were made with the patient supine (Figure 2) On each film, a calibration cage supplied with tantalum indicators, whose mutual positions were known, was also double-exposed The co-ordinates of the images of both patient and calibration indicators were than measured by means of an instrument for cartography The information thus obtained was treated by computer so that the three-dimensional positions of the indicators were determined in a laboratory co-ordinate system This system is defined by the calibration cage markers situated in two planes. The patient is investigated in such a position that the main axes of the body (transverse, longitudinal, and sagittal axes) are parallel to those of the cage co-ordinate system (Olsson et al 1976) In the subsequent analysis, the rigid body motion between the [illegible] and the pelvis was computed. [illegible] rotational movements of the [illegible] acetabulum were calculated.

The precision of the [illegible] photogrammetric method was [illegible] estimated to be approximately [illegible] for rotations about and 0 1 mm for the [illegible] along the three co-ordinate axes (O[illegible]

RESULTS

The tantalum balls in the specific [illegible] i e in the pelvic bone or in the [illegible] socket, were found to be stable [illegible] segment, and the acetabular socket [illegible] pelvis behaved as rigid bodies.

In one patient (BJ), the [illegible] acetabular socket in relation to the [illegible] bone was investigated twice on the [illegible] in the supine position, but there [illegible] significant difference between the measurements. By re-evaluating [illegible] roentgenograms (one from patient BJ [illegible] from patient SH) and recalculating positions of the markers, the [illegible] found to differ less than 0.2° [illegible] translations less than 0 05 mm, [illegible] with the precision tests mentioned [illegible]

In all cases, a migration of the [illegible] socket was found but the direction [illegible] amount varied (Table 1). In general [illegible] was a gradual migration in the [illegible] tion In cases GA, BJ and SH [illegible] were made at various intervals over [illegible] of 13–24 months. In one case (BJ) the [illegible] migration was greater during the [illegible] months and amounted to about 1 mm [illegible] the following 21 months, the [illegible] about 0 8 mm The movement [illegible] along the transverse and sagittal axes [illegible] but varied considerably in direction [illegible] different cases and during the [illegible] observation periods in the same case [illegible] cases, these movements amounted [illegible] than 0 6 mm during the entire [illegible] period

The rotatory movements [illegible] siderably in the different cases and [illegible] observation period to another The [illegible]

...s and the direction varied irregularly in ...e case during the different observa- ...riods. In case BJ the rotation about ...ittal axis amounted to 2 9° during the ... months, the upper part going to the ...ide of the patient This period was ...d by lower rotational values during the ...ng months, the total rotation about the axis amounting to 5 5° in 24 months.

... GL, there was a rotatory movement ... socket, judging from the values of the ...ory movements, but this rotation ...not be quantitated because there were ...wo measuring points in the socket

...ng the follow-up, the present cases ...d no clinical or radiographical signs of ...on or mechanical loosening The con-...al radiographs showed no signs of ...ion of the femoral or acetabular parts ... prosthesis (Figure 1) Clinically, the ...ed hip joints did not cause any ...ms, but the other joints did because of ...atoid arthritis. Two of the patients ...nd GA) died of causes unrelated to the ...hip replacement 1 and 2 years after ...ion, respectively Unfortunately, the hip ...were not examined at the autopsies

...USSION

... of the investigated patients with ...atoid arthritis had symptoms of pros-... loosening during the observation ... of at most 24 months No migration ... sockets could be detected on conven-... radiographs taken at the same time ...he roentgen stereophotogrammetric ...nations.

... this investigation, a continuous ...tion of the acetabular socket measuring ... 1 8 mm in 2 years was found along the ...udinal axis in the cranial direction A ...ar migration was also found along the ... axes, but the directions varied even in ...individual cases during the different ...vations periods. The same was also ... concerning rotatory movements. In ...al, the translatory and rotatory movements were greater during the first few months after the operation than later on

The investigated cases showed no indication of a completely stable prosthesis, instead, there was a continuous migration upwards with a translation and rotation along and about the different axes varying both in amount and direction A similar migrat on of a knee prosthesis (Marmor) in a woman with rheumatoid arthritis has been found for the polyethylene tibial plateau resulting in tilting of the tibial prosthesis

The roentgen stereophotogrammetric method is applicable to all non-radiopaque plastic prostheses. With modifications, it can be used for metal prostheses Indicators should *be inserted into the prostheses* during manufacture but can be inserted during the operation In some cases, for instance, with the Charnley hip socket, the method can be of use without special indicators in the prosthesis, the ends of the wire being used as indicators.

In conclusion the roentgen stereophotogrammetric method can be a valuable aid in the early detection of prosthetic loosening, thereby increasing the possibility of obtaining a correct diagnosis and instituting appropriate therapy

REFERENCES

... (1974) A...

Charnley J & Cupic, Z (1973) The nine and ten year results of the low friction arthroplasty of the hip *Clin Orthop* 95, 9–25

Hansson, L I Olsson, T H, Selvik, G & Sundén, G (1978) A roentgen stereophotogrammetric investigation of innominate osteotomy (Salter) *Acta orthop scand* 49, 68–72.

Lindberg L., Carlsson, Å. & Josefsson, G (1977) Use of antibiotic-containing cement in total hip arthroplasty done in the presence of or after deep wound infection. *Proceedings of the Fifth Open Scientific Meeting of the Hip Society, 1977*, pp 170–175 Mosby, Saint Louis.

Olsson, T H (1975) A roentgen stereophotogrammetric study of the kinematics of the spine Thesis, Lund.

Olsson, T H, Selvik, G & Willner, S (1976) Kinematic analysis of spinal fusions. *Invest Radiol* 11, 202–209

Selvik, G (1974) A roentgen stereophotogrammetric method for the study of the kinematics of the skeletal system Thesis, Lund

Sjöstrand, L. O (1974) [illegible] in total hip arthroplasty Thesis, [illegible]

Willert, H-G., Ludwig J & [illegible] Reaction of bone to [illegible] arthroplasty *J Bone Jt Surg* [illegible] 1368–1382.

Correspondence to Lars Ingvar Hansson, Ortopediska kliniken, Lasarettet, S-221 85 [illegible]

...op scand. 51, 541–545, 1980

...CTION AFTER REMOVAL OF A SEPTIC TOTAL ...PROSTHESIS

...ey of 27 Girdlestone Hips

...ARNE AHLGREN, GUDMUNDUR GUDMUNDSSON
... BARTHOLDSSON

...edic and Psychiatric Departments of Karnsjukhuset, Skövde, Sweden

An evaluation of the results of removal of a septic total hip prosthesis in 27 patients was made at least 1 year after the operation The function of many of the patients improved throughout the first year after removal It is concluded that the Girdlestone hip in many cases offers a satisfactory solution for the patient

Key words function, psychiatric and social evaluation, septic total hip plasty, removal

Accepted 11 vi 79

... of a total arthroplasty of the hip is an ...ely distressing experience for a patient ...-stage procedure including removal of ...nfected prosthesis and immediate ...on of a new one may succeed in certain ...ts (Lindberg et al 1977) In some cases, ...er, such a procedure is not possible and ...ly way is to remove the prosthesis. In ... to evaluate function following simple ...al we decided to review 27 patients at ... year after extraction of the prosthesis. ... survey is based on a clinical and ...raphic examination and also includes a ... and psychological assessment

...ENTS AND METHODS

...y-seven patients, 15 males and 12 females, ...vailable for review 1 year or more after ...al of their septic total hip prosthesis. Twenty-...ostheses were of the Charnley type and one ... the McKee-Farrar type
... mean age at arthroplasty was 63 6 years ... 1) and at review 67 5 years. The average interval between extraction and the review was 40 6 months (range 12 68 months)

Twenty-two of the patients had been operated upon for primary coxarthrosis, three for complications following fracture of the femoral neck, one for rheumatoid arthritis and one for secondary changes after congenital dislocation of the hip

Sixteen of the patients with arthrosis had a bilateral affection Of these six had been also treated with arthroplasty of the other hip Except for the fractures none of the hips in question had been operated upon previously

In the interval between arthroplasty and extraction of the prosthesis the wires holding the greater trochanter had been removed in three cases and extraction-reimplantation had been attempted in two

The psychological and social evaluation was performed jointly by a psychiatrist, a social worker and an occupational therapist, all of whom had no previous knowledge of the patients and worked independently of the Orthopaedic Department

Pain on weight-bearing, raised erythrocyte sedimentation rate and radiographic signs of loosening were constant findings in all 27 cases.

Pain was the prominent symptom in all but three cases. In these, removal was indicated by a profuse and persistent secretion from a sinus.

...470/80/030541–05$02.50/0

Table 1 Age at arthroplasty

Years	
40–49	2
50–59	8
60–69	9
70–79	8
Total	27

Table 2 Walking [illegible]

–2 km	[illegible]
–0 5 km	[illegible]
–200 m	[illegible]
Indoors only	[illegible]
Mainly confined to a wheelchair	[illegible]
Total	[illegible]

Local inflammatory signs occurred at one time or another in all cases, in 15 with fistulation In 14 of these cases bacterial cultures were positive

Before extraction of the prosthesis the patients had received a fairly long course of antibiotic therapy This treatment had resulted in abatement of symptoms of varying duration Routine culture of specimens obtained at extraction was positive in 15 cases

Postoperatively skeletal traction was applied for 4 to 6 weeks, followed by training in a walker with full weight-bearing A shoe raise, usually of the order of 5 cm, was always necessary

At operation we tried to remove all the cement Such removal, particularly from the femur, was often a very arduous task even though access was facilitated by fenestration or guttering of the shaft and/or chiselling off of the greater trochanter In 12 cases some fragments of cement were left behind, but this did not seem to interfere with wound healing except possibly in one of the patients who had a recurrent sinus secretion for up to 1 year after the removal

In 19 cases healing was by first intention In the remaining eight cases healing was delayed three had a secreting sinus for up to 3 months and five had persistent or recurrent drainage for longer periods and one for as long as 16 months. Antibiotic therapy was generally discontinued 3 months after all signs of infection had disappeared In no case was a second operation performed to remove remaining cement

RESULTS

Subjective evaluation

All of the patients were satisfied with the overall result of the operation and some felt that the outcome greatly exceeded their expectations. Freedom from pain and soiling drainage was particularly appreciated

All of the patients reported that the hip was much better and much less p[illegible] it was before both insertion and re[illegible]

Eighteen patients had no pain [illegible] nine only had mild or occasional [illegible] association with changes in the w[illegible] after much walking or standing

Pain on weight-bearing was [illegible] seven patients, this was slight or o[illegible] in five and more severe in the r[illegible] Three of these seven were not [illegible] the pain-relief obtained and the [illegible] function and later underwent [illegible] arthroplasty

The ability to walk varied [illegible] with the general health and [illegible] patient (Table 2). Thus 22 [illegible] outdoors alone, whereas five needed [illegible] another person Of these five, [illegible] mostly confined to a wheelchair [illegible] pointed out that the hip was [illegible] responsible for the incapacity of the [illegible] patients who suffered from [illegible] stability or stiffness of other [illegible] vertigo and senility

Walking aids were used to [illegible] all patients able to walk, mostly [illegible] outdoors and one indoors. All [illegible] felt that their gait and the distance [illegible] walk gradually improved during the [illegible] Many of them had been troubled by [illegible] feeling of instability and weakness [illegible] tendency to stumble Several of the [illegible] could not move safely around [illegible] after the operation.

All but one patient found that the [illegible] motion of the hip was sufficient [illegible] fortable sitting One patient had [illegible] restricted motion of both hips [illegible] most of his time in a wheelchair

e motion was invariably very limited tively, but gradually improved with muscle tone during the first few

ical and social evaluation

rpose of this aspect of the follow-up evaluate the patient's subjective by assessment of his degree of ncy and anxiety, disturbance of ed for tranquillizers, and also an of his ability, working capacity l activity Finally, the patients were ed personally concerning their o the hospital care and the aids they ed to relieve their handicap

of the patients regretted the extrac- e prosthesis, but one did regret the ation Broadly speaking, the patients sfied with the results of the operation main reasons the relief from severe the disappearance of the embarassing t fistula

y four of the patients had no in eating, dressing or managing sonal hygiene Twelve of the patients ng alone and two were living in a home ged All of those living alone received the heavier chores and the washing, of the women nevertheless found the e household strenuous The men living own required help with the cooking and

Those who earlier had been able to ar could still do so However, most of d had their cars exchanged for those omatic gears. All of the patients except ed that they could continue with their tivities and hobbies to the same extent r

three of the patients reported psy- symptoms but all of them had earlier from depression anxiety and dis- e of sleep and all needed tran- s. Another three patients required es. Two patients had part-time jobs was working full time as before The were pensioners.

All of the patients except one were satisfied with the care and treatment they had received, including the special aids supplied to help relieve their handicap The patient who was not satisfied thought that the infection was due to a mistake made at the earlier operation

Clinical evaluation

All of the patients could stand and even the two most severely incapacitated could take a few steps with the aid of a walker All had a positive Trendelenburg sign Gait was rated as good in 19 cases, fair in four and poor in four

Shortening varied from 3 to 6 cm, most frequently from 4 to 5 cm Radiograms on weight-bearing demonstrated that the shortening increased by 5 cm in one case, by 2 cm in 19 cases and by 1 cm in seven cases.

In the supine position all except one of the patients had an active flexion range of 50 degrees or more Passively flexion could be increased by 20–30 degrees (Table 3) Active rotation and range of abduction and adduction was reduced in most cases but could be increased passively, especially outward rotation and adduction Four patients had flexion contractures of 15 to 30 degrees and six had contractures in outward rotation of the order of 10 to 30 degrees. No adduction contractures were encountered and no relationship was found between the presence of contractures and walking capacity

DISCUSSION

Santesson (1849) reports that Charles White of Manchester suggested in 1770 the

Table 3 Range of flexion

	Active	Passive
0 –30°	1	0
31°–60°	8	4
61°–90°	18	10
91°–120°	0	13
Total	27	27

resection of the femoral head as a measure against tuberculosis However, Anthony White was the first one to make the operation in an infected case According to Santesson (1849) the operation was performed in 1818 at Westminster Hospital in London Girdlestone (1943, 1945) used this procedure not only in the treatment of tuberculosis and pyogenic arthritis of the hip but also in osteoarthritis The operation now bears his name and is most certainly very seldom used as a primary treatment but is regarded as a salvage procedure, for example, in primary infections, avascular necrosis and in cases where the general condition of the patient precludes more extensive surgical interventions (Murray et al 1964, Collis & Johnston 1971, Parr et al 1971)

The operation has also long been used in the case of failed hip arthroplasty and in recent years it has received renewed attention as an ultimate measure after unsuccessful total hip arthroplasty (Plaue & Stadtler 1975, Haw & Gray 1976, Slooff et al 1976, Vidal et al 1977, Clegg 1977, Gudmundsson et al 1977) In general these authors have found the result good or acceptable but have not excluded the possibility of another arthroplasty

Josefsson et al (1978) have compared the functional results of the Girdlestone procedure to those of exchange arthroplasty Admittedly the latter gives a better result but the difference was less than expected

The result of earlier investigations and the present one has led us to conclude that a septic total hip arthroplasty should first be treated by the Girdlestone procedure, which should not be delayed too long once infection is diagnosed Assessment of the result should be delayed for several months and if the outcome then is unsatisfactory for the patient, arthroplasty should be performed provided it is technically possible This strategy is in accordance with that of Slooff et al (1976) and Vidal et al (1977) but contrasts with that of Lindberg et al (1977)

We have not found complete removal of the cement an absolute necessity for healing which is in contrast to Clegg's fi[illegible] 1977)

The optimal period of p[illegible] traction does not yet seem to be [illegible]tablished Haw & Gray (1976) [illegible] of skeletal traction for 6 weeks [illegible] (1971) used traction for periods [illegible] less than a week to 2 months The [illegible] correlation between the length of [illegible] patient was held in traction and t[illegible] shortening or function The t[illegible] present investigation 4 6 weeks [illegible] reasonable to us and during th[illegible] patient was allowed intermittent [illegible] of the hip and knee

The opinions the patients exp[illegible] orthopaedic surgeons at follo[illegible] responded well with those gained b[illegible] chiatrist and his co-workers It was [illegible] surprising how well the patien[illegible] stress connected with an unsu[illegible] arthroplasty and also that only [illegible] had a grudge against the medical [illegible]

REFERENCES

Clegg J (1977) The results of the ps[illegible] after removal of an infected total hip [illegible] *J Bone Jt Surg* 59 B 298-301

Collis D K & Johnston, R. C (19[illegible]) [illegible] femoral-head and neck resection [illegible] up study *J Bone Jt Surg* 53-A, [illegible]

Girdlestone G R (1943) Acute pyogenic [illegible] the hip An operation giving free [illegible] effective drainage *Lancet* i, 419-4[illegible]

Girdlestone G R (1945) Pseudarthrosis [illegible] Discussion on treatment of [illegible] arthritis of the hip joint. *Proc roy Soc* [illegible] 363

Gudmundsson, G., Ahlgren, S. A., B[illegible] & Hermansson I (1977) F[illegible] removal of total hip prostheses [illegible] the Swedish Orthopaedic [illegible] *orthop scand.* 48, 239.

Haw, C. S & Gray H (1976) Excision [illegible] of the hip. *J Bone Jt Surg* 58-B, [illegible]

Josefsson G & Lindequist, S (19[illegible]) [illegible] operation or removal of the prosthesis [illegible] operation offers the best function [illegible] Paper read at the Swedish Orthopaedic [illegible] tion meeting in Stockholm.

Lindberg, L. Carlsson, A. & Josefsson, G [illegible] Use of antibiotic-containing cement [illegible]

plasty done in the presence of or after deep d infection *The Hip* Proceedings of the Open Scientific Meeting of The Hip ty Mosby, Saint Louis.
W R, Lucas, D B & Inman, V T (1964) ral head and neck resection *J Bone Jt* 46-A, 1184–1197
L, Croft, C & Enneking, W F (1971) tion of the head and neck of the femur with without angulation osteotomy *J Bone Jt* 53 A, 935–944
R & Stadtler, J (1975) Infizierte *endoprothesen–ein aktuelles Problem Z op* 113, 965–973
Santesson, C (1849) *Om hoftleden och ledbrosken uti anatomiskt, pathologiskt och chirurgiskt hanseende, jemte en kritisk ofversigt ofver några bland inflammationslarans vigtigaste punkter* (Diss) P A Norstedt & Soner Stockholm
Slooff T J J H, Schaapsmeerders F Van de Sandt, H M & Van Rens Th J G (1976) Treatment of forty loosened total hip replacements. *Acta orthop belg* 42, 492–500
l'époque des prothèses de hanche? *Rev Rhum* 44, 395–401

ondence to Gudmundur Gudmundsson, M D, Department of Orthopaedic Surgery KSS S-kovde, Sweden

op scand 51 547–555, 1980

ITEAL CYSTS (BAKER'S CYSTS) IN ADULTS

suloplasty With and Without a Pedicle Graft

ANG RAUSCHNING

ent of Orthopaedic Surgery, University Hospital Uppsala Sweden

In 15 adult patients undergoing surgery for symptomatic popliteal cysts of fairly long duration the communication into the joint was closed by two different procedures In the early series *Series A* (8 patients) the opening was tightly sutured and in *Series B* (7 patients) a new type of capsuloplasty was performed using a proximally based flap from the gas-

whereas radical excision of the cyst does not seem essential for the therapeutic result

Key words popliteal cysts Baker's cysts capsuloplasty

Accepted 7 viii 79

al cysts are still considered today by uthors to be due to a synovial hernia-rough the capsule of the knee joint on & Berman 1972, Pinder 1973, er & Kirkpatrick 1975) The prevailing n however, is that they are fluid-fed communicating gastrocnemio-embranosus bursae (Gristina & Wilson Goldstein & Dickerson 1974, Smillie Lindgren 1978, Rauschning 1979)

se cysts are often caused by an un-g intra-articular disorder (Burleson et 6, Gristina & Wilson 1964, Bowerman hletaler 1973) and a correction of the lisease constitutes rational treatment in cases (Jayson et al 1972 Pinder 1973) associated knee disorder is not curable f the cyst gives rise to troublesome symptoms, it is the general opinion that surgical excision is the treatment of choice (Justis 1971, Smillie 1974) Most authors also advocate closure of the communication (Haggart 1943, Childress 1970, Solomon & Berman 1972)

Recurrences following conventional surgical treatment are frequent (Harvey & Corcos 1960, Vahvanen 1973, Meire et al 1974) In a recent clinical and radiographic follow-up examination of 41 routinely excised popliteal cysts, 15 postoperative complications and 40 recurrences were found (Rauschning & Lindgren 1979)

This paper describes a modified surgical approach and operative technique an earlier series *(Series A)*, the was tightly sutured, and in *Series B* a

developed reinforcement capsuloplasty was applied, with the use of a pedicle graft from the gastrocnemius tendon

PATIENTS AND METHODS

Patients, preoperative symptoms and findings (Tables 1 and 2)

During the period June 1975 through May 1977, 15 adults, aged 19–69 years (mean age 42 7 years) were operated upon consecutively by the author for popliteal cysts at the Department of Orthopaedic Surgery, University Hospital, Uppsala Six cysts presented in the left knee and nine in the right Nine of the male patients recalled a specific knee injury, in most cases sustained during sports. The [illegible] symptoms averaged 5 6 years ([illegible] 17 years). They were assessed [illegible] following clinical criteria *Grade 0* [illegible] pain *Grade 1*, swelling and [illegible] strenuous work or sports. *Grade 2* [illegible] tenderness after normal [illegible] constant tense swelling and pain.

Associated disorders of the knee [illegible] among these patients (Tables 1 and 2) [illegible] a few cases was surgical treatment of the [illegible] ing condition considered indicated.

At preoperative arthrography all [illegible] identified as communicating [illegible] semimembranosus bursae on the [illegible] of communication and the [illegible] the tendons behind the knee (Fig 1 [illegible] admission to hospital all patients had a [illegible] cyst, in most cases tense or tender

Table 1 Clinical data of a consecutive series of 8 patients operated upon for popliteal [illegible] through March 1976 (Series A) Communication closed by one row of sutures No [illegible] immobilization For grading and follow-up see Methods

Patient no, age at op (years) sex	Associated disorder of the knee, remarks on the operative technique and findings at operation	Grading of subj symptoms		[illegible] months postop	[illegible]	[illegible]
		preop	postop		[illegible]	[illegible]
1 36 ♂	Osteoarthritis with varus deformity	2	0	18	[illegible]	[illegible]
2 46 ♂	——	2	0	13	[illegible]	[illegible]
3 39 ♂	Two negative arthrographies. Clinical signs of chondromalacia of the patella	2	0	12	[illegible]	[illegible]
4 24 ♂	——	2	0	[illegible]	[illegible]	[illegible]
5 38 ♂	——	2	0	35	[illegible]	[illegible]
6 40 ♀	Operation in supine position Closure of the communication after excision of ruptured medial meniscus. The cyst was left *in situ*	1	0	14	[illegible]	[illegible]
7 28 ♀	Severe rheumatoid arthritis. Anterior synovectomy 8 weeks before operation on the cyst	2	0	31	[illegible]	[illegible]
8 45 ♂	Severe rheumatoid arthritis. Anterior synovectomy 3 years before operation on the popliteal cyst	2	0	15	[illegible]	[illegible]

X) Follow-up arthrography was not performed in this patient as he suffered [illegible] wound infection following excision of rheumatic nodules in the elbow

…chnique

Figure 2, Tables 1 and 2) With the
g prone and with a pneumatic tourni-
l to the upper thigh, an 8–10 cm long,
slightly curved skin incision was made,
he easily palpable medial border of the
sus tendon The fascia was divided
ly exposing the semimembranosus
the medial wall of the cyst. If fibrotic and
e posterior wall of the cyst was dissected
cted
of the capsular opening was facilitated
he knee and thus relaxing the muscles
on the individual anatomy, it was
proceed either anteriorly or posteriorly
membranosus tendon On retraction of
nemius dorso-laterally the communica-
into view (Figure 3 A) It was
concealed by thin synovial mem-
folds, which were excised (Through this incision the postero-medial capsule may be opened for additional intra-articular procedures) The neurovascular structures in the popliteal fossa were protected by the broad muscle belly of the gastrocnemius Very little bleeding occurred in these planes of cleavage

Methods for closure of the communication In the early *Series A* (Table 1) the transverse opening in the capsule was closed by suturing the tendon of the medial head of the gastrocnemius muscle into the gap by a few non-absorbable mattress sutures. A suction drain was inserted and a light compression bandage was applied to the whole leg Postoperatively joint exercises were instituted and all patients progressed to early full weight bearing ambulation

In *Series B* (Table 2) a 1–2 mm thick and 1–2 cm long proximally based tendinous flap was raised from the anterior surface of the gastrocnemius tendon to cover the opening with some

…inical data of a consecutive series of 7 patients operated upon for popliteal cysts, September …gh May 1977 (Series B) Communication closed by gastrocnemius tendon capsuloplasty …erative immobilization in a plaster cast For grading and follow-up, see Methods

Associated disorder of the knee, remarks on the operative technique and findings at operation	Grading of subj symptoms		Follow-up		
	preop	postop	months postop	Recurrent cyst clin exam	Recurrent cyst arthrography
Osteoarthritis. The communication was closed by three rows of sutures	2	0	22	no	no
Patello-femoral osteoarthritis. Six osteocartilaginous loose bodies were found in the cyst (cf Figure 1), there were none in the joint	1	0	24	no	no
Operation in the supine position Closure of the communication followed advancement of the tibial tuberosity for chondromalacia of the patella The cyst was left *in situ*	1	0	24	no	no
Medial osteoarthritis, varus deformity	2	0	22	no	no
Medial meniscus excised 1957 Old rupture of the anterior cruciate ligament Large loose body in the cyst	1	0	18	no	no
Operation on the cyst in the supine position was preceded by arthroscopy, which showed patello-femoral erosion	2	0	19	no	no
Osteoarthritis with varus deformity	2	0	15	no	no



Figure 1 Preoperative arthrograms (patient 10) The cyst has filled with contrast medium high through the communication high up behind the medial femoral condyle Six loose bodies are in the cyst

nerve &
vessels
common approach
semitendinosus
semi
gracilis
capsule
medial
femoral condyle

Figure 2 Surgical anatomy and approach Schematic horizontal section through the ... quadrant of the knee joint at the level of the communication (dotted line) between the ... cyst The semimembranosus muscle may be retracted either posteriorly or ... opening



The pedicle graft capsuloplasty as used in Series B *Retraction of the gastrocnemius exposes the ed capsular opening, through which in this case the osteoarthritic medial femoral condyle is seen roximally based flap is cut from the gastrocnemius tendon (here held in place by a forceps) and the is then sutured (B) Finally the tendon graft is lowered and sutured to the capsule for reinforcement st suture line (C)*

femur
gastro-
cnemius
tibia
cyst

1 The pedicle graft capsuloplasty as used in Series B *(schematic sagittal section) Left A proximally raft has been raised from the articular surface of the gastrocnemius tendon Right The graft has been to the capsule (see text)*

overlapping (Figures 3 and 4) The capsular rim was scarified and then affixed to the base of the flap by a continuous atraumatic suture using non-absorbable suture material (Figure 3 B). (The flap should be cut prior to closure of the opening so as not to risk cutting the suture.) The flap then was let down on to the capsule trimmed to cover the thin area of the capsule and sutured to the firm capsular portion with interrupted non absorbable sutures (Figure 3 C) After release of the tourniquet and coagulation of active bleeding points a suction drain was inserted the deep fascia resutured and the wound closed and dressed After turning the patient to a supine position, a plaster cylinder was applied with the knee in slight flexion Postoperatively the leg was elevated early quadriceps setting exercises were instituted and the patients were allowed to walk about with full weight bearing usually without crutches.

RESULTS

Postoperative course (Series A and B)

The only complication was encountered in patient 6 who complained of sensory loss on the medial aspect of her lower leg and for 1 week her wound was red and swollen A culture of the clear fluid discharging from the wound showed no bacterial growth. In the remaining patients healing of the wound was uneventful

The total intra- and postoperative bleeding averaged 60 ml Including the patients in whom additional surgical procedures were performed the mean length of stay in hospital was 4 days (range 1–11 days) Postoperatively in *Series A* slight to moderate effusion was noted for some weeks. In *Series B* the plaster and the skin sutures were removed 3 weeks postoperatively (6 weeks in patient 12) All wounds showed primary healing and a full range of knee movement was regained within a few weeks. No physiotherapy was required in any of the patients of either series.

Follow-up (Tables 1 and 2)

Clinical re-examination (Series A and B) The average observation times in *Series A* *and B* were 24 months and [illegible] respectively The [illegible] popliteal space were assessed [illegible] same criteria as described above.

There were no [illegible] popliteal space and neither [illegible] aggravation of the [illegible] signs. In patients 6 and 11 [illegible] had improved According to the [illegible] postoperative effusion had [illegible] or 2 months. Patient 6 [illegible] hypaesthesia above the [illegible] also a soft painless popliteal [illegible]

Follow-up arthrography Th[illegible] *Series A* were examined by arthrography as described (Rauschning & Lindgren 1979) [illegible] three recurrences (Table 1).

In *Series B* arthrography [illegible] active provocation test, which [illegible] increase the fluid pressure [illegible] posterior capsule 10–15 ml of [illegible] contrast medium (Urografin [illegible] Schering) was injected into the [illegible] on his side with the knee flexed [illegible] the patient was asked to try to [illegible] knee against the examiner's [illegible] fluoroscopy and on the films [illegible] the suprapatellar pouch was [illegible] posterior joint recesses [illegible] posterior capsule (Figure 5) [illegible] contrast medium from the [illegible] in any case

DISCUSSION

As popliteal cysts in adults [illegible] secondary to an underlying [illegible] such disorder was therefore [illegible] possible. In patients 7 and 8 [illegible] toid arthritis the cysts had [illegible] anterior synovectomy [illegible] accordance with that of Jayson [illegible] and Pinder (1973). They [illegible] symptoms, however which [illegible] due to the hard fibrinous [illegible] cysts. One torn meniscus was [illegible]





5 *Follow-up arthrograms (patient 10 of Figure 1) 2 years after a pedicle graft capsuloplasty Left ... sive flexion the contrast medium is evenly distributed between the anterior and posterior com... nts of the joint Right On provocation (see text) the contrast fluid is forced from the suprapatellar ... arrow above) into the posterior recesses of the knee There is no recurrence of the cyst*

...atient patello-femoral disability neces... l an advancement tuberculoplasty The ...ood es contained in two of the cysts might ... aused symptoms by mechanical irritation ... essure impingement

...popliteal cysts in children were referred ...rgery as several comprehensive studies ...ent years have shown that as a rule ... cysts constitute a harmless condition ... troubles the parents much more than ...atient and that most infantile cysts ...ear spontaneously (Fairbank 1969 ... Iahon 1973 Dinham 1975)

...nodified approach to the deep portion of ... cyst was worked out in earl er ...nological studies (Rauschning 1979) ... was appl ed in all operations and ...red optimal access for suturing of the ...lar opening Incisions centred over the ...ing as described by most authors (Haggart 1943 Justis 1971 Goldstein & Dickerson 1974 among others) yield poorer access to the gap (see Figure 2)

In *Series A* (Table 1) the communication was closed suturing the tendinous belly of the gastrocnemius into the capsular gap with heavy non absorbable mattress sutures, a procedure similar to those previously described by a few other authors (Moser 1950 Solomon & Berman 1972) The only postoperative complication occurred in patient 6 She was operated on in the supine position which impeded optimal access to the communication The postoperative swelling of her wound and the low-grade fever might be attributable to extravasation of synovial fluid from the joint, since the opening was not successfully closed (Rauschning & Lindgren 1979)

In *Series B* (Table 2, Figures 3 and 4) a

reinforcement capsuloplasty was introduced Studies of the surgical anatomy had verified that the postero-medial capsule is thin immediately distal to the slit-shaped opening and that the site of communication is subject to capsular tearing forces on active flexion and rotation of the knee As the base of the pedicle graft from the gastrocnemius tendon is left intact, it presumably maintains its vascular supply and also eliminates the pull of the tendons on the sutures. Free tendon or fascia lata grafts have been advocated by Haggart (1943) and Childress (1970) for closure of the gaps, but apart from being avascular they are difficult to suture into the opening due to its anatomy An additional suture of the semimembranosus to the gastrocnemius was advocated by Childress (1970) but this measure is felt to be of dubious value as it hinders active knee flexion and seems doomed to mechanical failure The capsuloplasty used in *Series B* was easy to perform and the average operation time was 1 hour in both series. In *Series B* postoperative plaster immobilization was used in addition to the surgical reinforcement. This immobilization is perhaps not absolutely necessary for the prevention of recurrences, but is considered an advantage, as it will minimize postoperative haemorrhage resulting from tissue movements, probably eliminate tearing of the capsuloplasty during healing and also prevent undue distension of the posterior capsule by hydrostatic pressure which might occur on knee flexion It also facilitates early ambulation Three weeks of immobilization were considered adequate, as postoperative knee effusion usually subsides within this time

No postoperative complications occurred in *Series B* and no recurrences were found although additional provocation manoeuvres were performed at follow-up arthrography The average observation time of 20 6 months is admittedly short However numerous publications bear witness to the fact that recurrent popliteal cysts occur early, usually within a few months (Burleson et al. 1956 Hoffman 1963, Rauschning & [illegible] among others). Moreover a [illegible] graft capsuloplasties have been [illegible] all these patients have made [illegible] recovery and show no [illegible] recurrent cyst.

No adverse effects from the [illegible] communication were [illegible] series – in particular no [illegible] the joint No "compensat[illegible]" [illegible] the posterior synovial recesses [illegible] follow-up arthrography [illegible] regained a full range of [illegible] within a short time, which [illegible] due to the fact that the [illegible] denuded of their bursal [illegible] whole cyst is generally [illegible] This study would seem to [illegible] that a durable tight closure of the communication rather than [illegible] the cyst, is the decisive [illegible] venting complications and [illegible]

CONCLUSIONS

1 This study confirms the [illegible] arise when excessive synovial [illegible] joint is pumped over [illegible] gastrocnemio-semimembranosus [illegible]

2 In adults, a popliteal cyst [illegible] secondary to an *associated* [illegible] *joint* which produces the [illegible]

3 Popliteal cysts demand [illegible] *careful examination of the* [illegible] arthroscopy, if indicated, [illegible] any such associated disorder.

4 At operation on the cyst [illegible] *postero-medial approach* described [illegible] paper greatly facilitates [illegible]

5 The essential operative [illegible] *closure of the communication* [illegible] excision of the cyst

6 The *pedicle graft* [illegible] performed in *Series B* with [illegible] *mobilization* relieved the [illegible] in all cases and led to [illegible] recurrences or adverse effects

..OWLEGEMENTS

indgren, M D is gratefully acknowledged
lertaking the radiographic examinations.
il support for this study was received from
wedish National Association against
itism

{ENCES

r, E & Kirkpatrick, J A (1975)
:opaedic diseases Physiology-pathology-
ology 4th ed, pp 677–678 W B
ders Co, Philadelphia, London, Toronto
ian, J W & Muhletaler, C (1973)
rography of rheumatoid synovial cysts of
nee and wrist *J Canad Ass Radiol* 24,
32

n, R J, Bickel, W H & Dahlin, D C
6) Popliteal cyst A clinico-pathological
:y *J Bone Jt Surg* 38-A, 1265–1274

is, H M (1970) Popliteal cysts associated
undiagnosed posterior lesions of the
al meniscus. *J Bone Jt Surg* 52-A
–1492.

, J M (1975) Popliteal cysts in children
case against surgery *J Bone Jt Surg*
, 69–71

k, T J (1969) Examination of the knee
Brit med J, 3, 220–222

in, L A & Dickerson, R C (1974) *Atlas*

s in adults and children A review of 90
s. *Arch Surg* 88, 357–363

t, G E (1943) Synovial cysts of the
iteal space Clinical significance and treat-
t *Ann Surg* 118, 438–444

, J P & Corcos, J (1960) Large cysts in
in
and

n, B K (1963) Cystic lesions of the
iteal space *Surg Gynec Obstet* 116,
551–558

Jayson, M I V, Dixon A St J, Kates, A, Pinder, I M & Coomes, E N (1972) Popliteal and calf cysts in rheumatoid arthritis. Treatment by anterior synovectomy *Ann rheum Dis* 31, 9–15

Justis, J (1971) Affections of fascia and bursae In *Campbell's operative orthopaedics* Vol. 2, 5th ed pp 1504–1516 Ed by A. H Crenshaw The C V Mosby Comp, St Louis.

Lindgren, P G (1978) Gastrocnemio-semimembranosus bursa and its relation to the knee joint IV Clinical considerations *Acta radiol (Stockh)* 19, 609–622.

MacMahon, E (1973) Baker's cysts in children—is surgery necessary? *J Bone Jt Surg* 55-A, 1311

Meire, H B, Lindsay, D J, Swinson, D R & Hamilton, E B D (1974) Comparison of ultrasound and positive contrast arthrography in the diagnosis of popliteal and calf swellings. *Ann rheum Dis* 33, 221–224

Moser, H (1950) Traumatische kommunizierende Arthrozele in der Kniekehle *Zbl Chir* 75, 942–950

Pinder, I M (1973) Treatment of the popliteal cyst in the rheumatoid knee *J Bone Jt Surg* 55-B, 119–125

Rauschning, W & Lindgren, P G (1979) Popliteal cysts (Baker's cysts) in adults. I Clinical and roentgenological results of operative excision *Acta orthop scand* 50, 583–591

Rauschning, W (1979) Popliteal cysts and the gastrocnemio-semimembranosus bursa Studies on the surgical and functional anatomy *Acta orthop scand*, Suppl. 179, 1–43

Smillie, I S (1974) Affections of the synovial membrane Local In *Diseases of the knee joint* pp 140–162. Churchill Livingstone, Edinburgh and London

Solomon, L & Berman, L (1972) Synovial rupture of the knee joint *J Bone Jt Surg* 54 B, 460–467

Vahvanen, V (1973) Popliteal cyst. A follow-up study on 42 operatively treated patients. *Acta orthop scand* 44, 303–310

ondence to Wolfgang Rauschning Department of Orthopaedic Surgery, University Hospital,
Sweden

hop scand. 51, 557–560, 1980

H TIBIAL OSTEOTOMY WITH OVERCORRECTION VARUS MALALIGNMENT IN MEDIAL GONARTHROSIS

MYRNERTS

ment of Orthopaedic Surgery, Linkoping University, The Medical School, Linkoping, Sweden

Seventy-eight knee joints with varus malalignment were examined preoperatively using three-point measurement Operation was performed with or without 5° overcorrection of the varus deformity using random selection. The overcorrection group showed significantly better results than the normal-correction group

Key words gonarthrosis, high tibial osteotomy, overcorrection, varus

Accepted 10 viii 79

he past 20 years osteotomy of the femur ia has been a generally accepted mode eatment for gonarthrosis with malalign- (Jackson & Waugh 1961) The aim is to ge the mechanical axis of the leg in order istribute the load more evenly on the ilar surfaces of the knee joint The otomy is preceded by an X-ray examina- to enable the surgeon to decide how 1 angular change will be needed

he purpose of this investigation was to y the value of overcorrection of the varus lignment in medial gonarthrosis

Three-point measurement" is an radiographic X-ray technique for assessment e medio-lateral instability of the knee The me varus and valgus positions of the knee are oked in a standardized way In these ions films are taken over the hip, knee and . Lines are drawn between the centre of the ral head and the centre of the knee (hip-knee and between the centres of the knee and the : (knee-ankle line) The *medio-lateral in ility* is measured as the angle through which knee-ankle line has moved in relation to the knee line between the two measurements. The *s/valgus deviation* of the knee is defined as angle between the hip-knee line and the mid-tion of the knee-ankle line i e the bisector of medio-lateral angle of instability

METHODS

The degree of angular change required was determined by three-point measurement[1] (Edholm et al 1976, 1977) Patients were allocated at random to one of two groups

Normal correction group – operation with an angular change equal to the varus/valgus deviation at three-point measurement,

Overcorrection group – operation with an angular change equal to the varus/valgus deviation at three-point measurement + 5° overcorrection

If it could be predicted that after operation with overcorrection the articular surface of the tibia would be inclined more than 10° with respect to a line perpendicular to the long axis of the tibia, an angular change equal to the varus/valgus deviation was always made Such patients were not included in the investigation

At operation a wedge was resected between the tuberositas tibiae and the knee joint. No tightening of the joint capsule or ligaments was carried out When necessary, resection of part of the fibular head was done to obtain close apposition between the surfaces of the osteotomy Osteotomy of the fibular diaphysis was not done Fixation was obtained with 1–3 staples. After operation the joint was stabilized with an anterior plaster slab From the first postoperative day partial weight-bearing was allowed and quadriceps drill was carried out From the second day gentle movement of the joint was encouraged. After 12 to 14 days the patient was fitted with a circular

-6470/80/030557-04$02.50/0

knee plaster and allowed to go home Six weeks after operation the patient was readmitted for removal of the plaster, X-ray, and physiotherapy *All patients were examined preoperatively and 3, 6, 12 and in most cases 24 months after operation* by a surgeon and a physiotherapist using standardized tests of subjective and objective clinical variables and also by three-point measurement X-ray

Wound infection was defined as secretion with or without positive bacterial culture Pseudoarthrosis was said to be present when the *osteotomy had not healed after 6 months* The chi 2 test, Student's *t*-test, and Fischer's exact test were used in the statistical evaluation of the results

PATIENTS

[illegible]

and overcorrection groups (Table 1) There was no difference between the patients in the two groups with regard to degree of gonarthrosis and varus/valgus deviation at three-point measurement X-ray before operation

RESULTS

Pain on weight-bearing was [illegible] cent of the patients in the [illegible] group and *in 89* per cent of the overcorrection group 55 per cent [illegible] cent, respectively, were free from [illegible] walking *100 m* (Table 2). [illegible] not significant With regard to [illegible] *pain after walking 1 000 m* and [illegible] pain at rest there was no [illegible] difference between the two groups [illegible] there was no significant difference [illegible] *the patients in the two groups* [illegible] ability to walk 300 m on [illegible] against time

Twenty-four months after [illegible] overcorrection group had [illegible] ($P < 0.007$) less starting pain than the [illegible] *correction group.* The patients [illegible] overcorrection group reported [illegible] better walking ability 12 months [illegible] *and 24 months* ($P < 0.005$) after [illegible] than the patients in the [illegible] group The patients in the [illegible]

Table 1 Sex and age at the time of operation One woman in the normal-correction group [illegible] operated upon twice Owing to random selection three women belong to both [illegible]

Group	Men	Women	Total	Age at [illegible]
Normal correction	13	27	40	45-76 [illegible]
Overcorrection	19	18	37	40-75 [illegible]
Total	32	45	77	

Table 2 Pain on weight bearing Before operation all patients had pain after walking [illegible]

Group	Pain before operation	1 year after operation			2 years after [illegible]		
		No pain	Less pain	More pain	No pain	Less pain	[illegible]
Normal correction	100%	55%	75%	5%	61%	87%	[illegible]
Overcorrection	100%	69%	89%	3%	70%	[illegible]	[illegible]

3 Patient's opinion about the result of ion at the final follow-up examination 1 or 2 years after operation

	ormal-correction Group	Overcorrection Group
han before ation	12%	5%
before	12%	8%
e better fore	29%	16%
tter than fore	32%	43%
at all	15%	27%

were more satisfied with the result of ion (Table 3), the difference being ant ($P < 0.05$)

ents from *both* groups in whom rrection of 3° to 7° resulted showed antly ($P < 0.02$) better subjective than patients from both groups in undercorrection was the final result

means of the varus/valgus deviations by three-point measurement were 2.0° in the overcorrection group and 0.5° in the normal-correction group 1 year operation As the intention was to a varus/valgus deviation of 5° valgus overcorrection group and 0° in the l-correction group, it is evident that ean result in both groups was an orrection The resulting varus/valgus on as found by three-point measure-differs significantly ($P < 0.005$) between vercorrection and normal-correction , however

mobilization under anaesthesia has ecessary The patients quickly achieved ctory movement in the treated joint e 12-month follow-up examination ion had increased in 20 per cent, was nged in 77 per cent and had decreased er cent of the patients. The degree of of the knee was increased by more ° in one-third of patients, unchanged in rd, and reduced by more than 5° in rd The mean power of flexion of the as unchanged

(6.4 per cent) wound infections and seudoarthrosis occurred All wound infections healed after antibiotic therapy In one of the patients with wound infection a total hip replacement had previously been performed deep infection developed in the hip in connection with the superficial knee infection In the patient with pseudoarthrosis, healing took place after extraction of the staples.

Manifest deep thrombosis of the leg veins occurred in two patients, the condition resolving in both after heparin treatment

Fourteen (17.9 per cent) patients were subjected to reoperation Two patients required a total knee prosthesis because of severe pain on weight-bearing in spite of good correction of the angular malalignment In 12 cases the staples were extracted – in seven because they failed to stabilize the osteotomy, in three owing to local inflammation, and in two because the staples were judged to prevent healing

DISCUSSION

Coventry (1973) used X-rays with the patient standing and weight-bearing on both legs for determining the size of the wedge to be resected The angle between the long axes of the femur and tibia in the frontal plane was measured Coventry's aim with operation for varus malalignment was to get an angle of 5° valgus between the long axes of the bones after healing

All knee joints are unstable in the frontal plane, and the patient can move the knee into any position within the range of instability using muscular power Coventry's method of evaluation of the intended wedge size will therefore not be reliable, as it is not known whether the patient is holding his knee in an extreme varus or valgus position or somewhere in between

It is possible, however, that the knee will be in extreme varus when the patient is examined standing If, therefore, a varus malalignment is corrected with the aim of obtaining an angle of 5° of valgus between the long axes of the bones, this angle plus the

total instability in that particular patient will probably be the resulting correction

This difficulty can be avoided by restricting high tibial osteotomy to patients with a mild degree of gonarthrosis (Insall 1975) or by reducing the instability by tightening the lateral ligaments (Coventry 1973) Another possibility is to use the three-point measuring technique (Edholm et al 1976, 1977) which can be used to determine the instability of the knee

When the intended size of the wedge has been determined the next problem is to excise *the exact amount of bone at operation This* can be done with great precision with the aid of the SAAB jig (Myrnerts 1978) Sometimes, however, correction is partially lost after operation

According to Coventry (1979) the question of whether to overcorrect a varus malalignment, and if so by how much, is still unsettled In this investigation several different subjective and objective variables have been used in order to get an impression of the result of operation Of the variables presented above, *most significance is placed upon the patient's* opinion of the result of operation at the final examination The findings [illegible] tibial osteotomy for varus mal[illegible] aim at overcorrection, but the ex[illegible] be aimed at in the individual case [illegible] tain

REFERENCES

Coventry, M (1973) Osteotomy abo[illegible] degenerative and rheumatoid arthr[illegible] *Jt Surg* 55 A, 23–48

Coventry, M (1979) Upper tibial os[illegible] gonarthrosis *Orthop Clin* N[illegible] 191–210

Edholm P, Lindahl O, Lindholm B[illegible] R, Olsson K E. & Wennberg E [illegible] instability *Acta orthop scand* 47 [illegible]

Edholm P, Lindahl, O., Lindholm B[illegible] R., Olsson K E. & Wennberg E [illegible] instability and tibial osteotomy [illegible] *scand* 48, 95–98

Insall J N (1975) High tibial osteo[illegible] treatment of osteoarthritis of the [illegible] *Ann* 7, 347–359

Jackson J P & Waugh, W ([illegible] osteotomy for osteoarthritis of th[illegible] *Bone Jt Surg* 43-B 746–751

Myrnerts, R (1978) The SAAB jig [illegible] high tibial osteotomy *Acta orthop* [illegible] 85–88

Correspondence to Rune Myrnerts, M D, Department of Orthopaedic Surgery Regionsh[illegible] 85 Linkoping Sweden

..op scand 51, 561–564, 1980

..E INSTABILITY BEFORE AND AFTER HIGH ..AL OSTEOTOMY

.. MYRNERTS

..nent of Orthopaedic Surgery, Linköping University, The Medical School, Linkoping Sweden

Knee joints were examined by three-point measurement (Edholm et al 1976, 1977) The instability in arthrotic joints did not differ significantly from that .. normal knees b.. the .. .. measured by th.. .. in normal knees. .. instability increa.. ..iated with significantly poorer subjective results of operation The findings indicate that shortening of the lateral stabilizing structures of the knee joint should be carried out in connection with high tibial osteotomy for varus malalignment. No upper limit of preoperative instability consistent with a good result of operation was established

Key words gonarthrosis, high tibial osteotomy, knee instability, varus

Accepted 9 viii 79

.. a knee joint with varus malalignment is ..d by high tibial osteotomy, weakness of ..teral structures may increase after the ..ion Coventry (1973) recommends ..on of the fibular head and reattachment .. fibular collateral ligament after the ..omy is done He also approximates the ..lata with horizontal mattress sutures. ..mi (Beltrami et al 1976) on the other considers that the ligaments only require ..te surgery in exceptional cases basing ..atement on the fact that his results do ..how a high incidence of ligament in..ity although he does not combine ..ning of the ligaments with the os..ny Hagstedt (1974) did not attempt to ..n the collateral ligament in his series. ..und no difference in mobility, stability, ..reedom from pain in knees with and ..ut laxity Laxity is defined by Hagstedt ..e possibility of manually provoking an ..mal deviation in the frontal plane in a ..aximally extended knee' Shoji & Insall ..) regard marked preoperative instability ..ontraindication to high tibial osteotomy, but cannot define the degree of instability that can be accepted

This investigation was done to determine,

(i) the degree of instability in the normal knee joint,

(ii) the degree of pre- and postoperative instability consistent with a good result of operation, and

(iii) whether instability is aggravated by high tibial osteotomy

METHODS

A new X-ray technique, three-point measurement, was used In this the knee is brought into maximum varus and valgus positions in a standardized manner (Edholm et al. 1976, 1977) The angle in the frontal plane between the line from the centre of the head of the femur to the centre of the head of the tibia (hip-knee line) and a line from the centre of the head of the tibia to the centre of the tibial surface of the talus (knee-ankle line) is recorded The difference between the angles obtained in the maximum varus and valgus positions is defined as the medio-lateral instability of the knee joint, and the mid-position between the maximum varus and the valgus positions is

..6470.80.030561–04$02.50 0

called the varus/valgus deviation of the knee joint (Figure 1)

The three-point measurement technique was used to examine normal joints The technique was also employed to examine knees with gonarthrosis before and 12 months after high tibial osteotomy for varus malalignment The lateral structures were not shortened at operation in this series At the final follow-up examination 12 to 24 months after operation the patients were asked how satisfied they were with the result

MATERIAL

The series comprises 48 knee joints in young person[illegible]
ray or [illegible]
with g[illegible]
high tibial osteotomy (Table 1) All the affected joints showed focal medial gonarthrosis

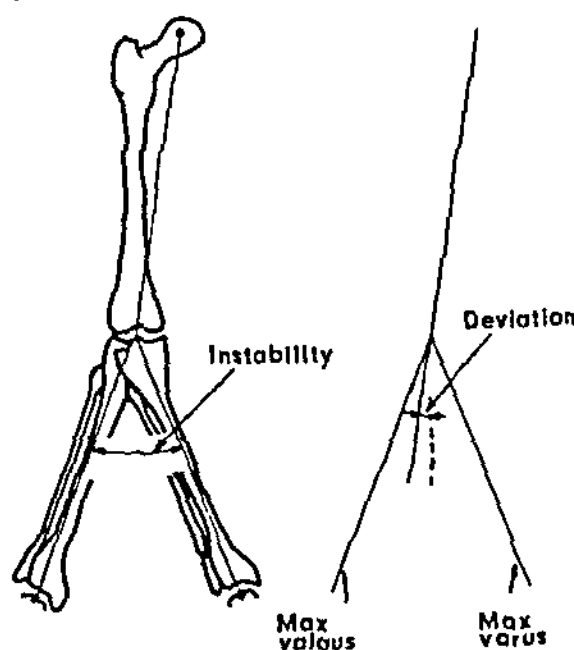


Figure 1 The three point technique for measuring instability and deviation of the knee Varus *deviation (+) is present when the bisector of the* [illegible]

Table 1 Age and sex distribution in the two groups

	Normal knees	Affected knees
Men	24	43
Women	24	56
Total	48	99
Age	22–54 mean 32	40–76 mean 62

RESULTS

The mean of the varus/valgus [illegible] three-point measurement was [illegible] the normal joints. Medio-lateral [illegible] varied from 0–9 5° (mean [illegible])

The affected joints were [illegible] than the normal ones (mean [illegible] 1°–12 5°), but the difference was [illegible] nificant The mean of the [illegible] deviations on three-point [illegible] differed *significantly* (*P* < 0 001) the [illegible] joints being in a varus position ([illegible] varus, range 1–20 5° varus).

Knee instability before operation [illegible] confirmed that modera[illegible] instability [illegible] this material constitutes a [illegible] high tibial osteotomy as there was [illegible] relation between preoperative [illegible] good or poor results (Figure 2) The [illegible] degree of preoperative instability [illegible] 12 5°, and this patient regarded the [illegible] the operation as relatively good [illegible] sometimes occurred with [illegible] only 3–4° (within the normal [illegible] some excellent results were [illegible] preoperative instability outside the [illegible] range (7 patients, instability [illegible]

Before operation the knee [illegible] maximum *valgus* position [illegible] angulation of 6 0° *varus* (range 2 5 [illegible] 17° varus) In maximum var[illegible] mean angulation was 11 6° var[illegible] – 24° varus).

Knee instability after operation Th[illegible] instability increased by 2 6° [illegible] (Figure 3). This increase [illegible] (*P* < 0 001). The increase [illegible] carried with it a grea[illegible] jective results (Figure 4) [illegible] increase of more than 2° [illegible] showed significantly (*P* < 0[illegible]) [illegible] jective results than those [illegible] increased less than 2° [illegible] patient showing an increase [illegible] instability of more than 5° ha[illegible] pain free knee

The patient's opinion of the result of operation related to the mean preoperative instability are graded.
than before operation
as before
'e better than before
better than before
in at all now

The instability 1 year after operation as a function of the preoperative instability (94 knees)

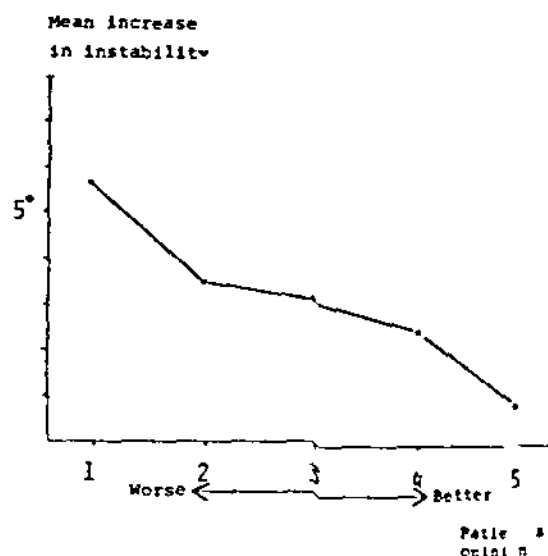


Figure 4 Mean increase in instability in relation to the patient's opinion [illegible]
Opinions are graded as in Figure 2

DISCUSSION

The findings in this investigation do not indicate that moderate preoperative instability constitutes a contraindication to high tibial osteotomy for varus malalignment No upper limit of instability consistent with a good result was established

A significant increase in instability occurs in connection with the operation Coventry's (1973) recommendation of shortening the lateral structures of the knee joint at operation is supported by these findings.

In medial gonarthrosis the varus/valgus deviation found by three-point measurement results from an increase in maximum varus angulation combined with a decrease in maximum valgus angulation Only rarely will the maximum valgus position remain on the lateral side of the prolongation of the hip-knee line, probably because shortening of the medial collateral ligament makes passive abduction impossible.

REFERENCES

Beltrami, P., Calandrello, B [illegible]
Axial deviations of the [illegible]
arthrosis. Correction by [illegible]
tibia and fibula. *Ital J Orthop* [illegible]
163–179

Coventry M (1973) [illegible]
degenerative and rheumatoid [illegible]
Jt Surg 55 4, 23–48.

Edholm, P., Lindahl, O., [illegible]
R., Olsson K E. & [illegible]
instability *Acta orthop scand* [illegible]

Edholm, P., Lindahl, O., [illegible]
R., Olsson K E. & [illegible]
instability and tibial osteotomy [illegible]
scand. 48, 95–98.

Hagstedt, B (1974) High tibial [illegible]
gonarthrosis. ISBN 91 [illegible]

Shoji, H & Insall, J (1976) High tibial [illegible]
for osteoarthritis of the knee [illegible]
concept. *Int Surg* 61, 11 [illegible]

Correspondence to Rune Myrnerts, M D Department of Orthopaedic Surgery [illegible]
Linkoping, Sweden

hop scand. 51, 565–567, 1980

NICAL RESULTS WITH THE SAAB JIG IN H TIBIAL OSTEOTOMY FOR MEDIAL GONARTHROSIS

MYRNERTS

.ment of Orthopaedic Surgery, Linkoping University, The Medical School Linkoping, Sweden

In 56 patients with medial gonarthrosis high tibial osteotomy was *performed using the SAAB jig, and another 43 patients with the same*

tion of the articular surface of the tibia on lateral X-rays when the SAAB jig was used Operation using the device is not technically difficult, but is more time-consuming The SAAB jig is a useful tool for achieving the predetermined correction in high tibial osteotomy

Key words gonarthrosis high tibial osteotomy, operating aid

Accepted 9 viii 79

SAAB jig*, a device to facilitate high osteotomy, is described elsewhere ierts 1978) The purpose of this study is mpare operation with and without this

HOD

knees a bone wedge of predetermined size :sected from the upper tibia
ising the SAAB jig,
without the SAAB jig, by resecting a wedge tch one of a series of wedge models or by g use of the fact that a wedge base of 1 mm : lateral corticalis of the upper tibia will give lge of approximately 1° (Bauer et al 1969).
: aim in all cases was to resect a wedge the f which had been determined preoperatively ree-point measurement (Edholm et al 1976, X-ray examinations were carried out imtely after operation and 1 week, 6 weeks, 3 is, 6 months, and 12 months later The resultant wedge size was determined by measuring the angle between the long axis of the tibia and a line parallel to the articular surfaces of the tibial condyles on frontal X-rays of the knee before and after operation Lateral views were used to detect any difference in the inclination of the tibial surface in the sagittal plane compared with that before operation

At operation with the SAAB jig a new type of staple was used Staple gliding was measured on frontal X-rays, and was said to be present when the staple had slipped outwards by more than 3 mm

Wound infection was defined as secretion with or without positive bacterial culture.

At the final follow-up examination 1 or 2 years after operation the patients were asked how satisfied they were with the result.

PATIENTS

Fifty-six patients were operated on using the SAAB jig and 43 without this aid (Table 1). All showed focal medial gonarthrosis with varus malalignment There was no significant difference in the groups with regard to sex, age, and wedge size

* uiries about the SAAB jig should be made to alle-Werner, Box 430 51, S-110 72 Stockholm, en

6470/80/030565–03$02.50 0

Table 1 Wedge size and age and sex of the patients in the two groups

	SAAB-jig	No SAAB-jig
Men	29	16
Women	27	27
Total	56	43
Age (mean)	61	63
Wedge size (mean)	9 8°	11.0°

Table 2 The difference between intended and obtained wedge size measured immediately after operation

Group/Difference	/ 0°2° /	/ 2°4° /	/ 4°6° /	> / 6° /
SAAB jig	60 3%	28 3%	5 7%	5 7%
No SAAB jig	42 9%	25 2%	11 9%	19%

Table 3 Increase in anterior inclination of the articular surface of the tibia measured on a lateral X-ray film immediately after operation

Group / Increase	0°5°	6°10°	>10°
SAAB jig	62 0%	26 0%	12 0%
No SAAB jig	28 9%	44 8%	26 3%

RESULTS

Operation time Operation with the SAAB jig was more time-consuming The mean operation time was 76 min compared with 59 min for operation without the jig The difference is significant ($P < 0\ 001$)

Exactness of wedge size The difference between intended and obtained wedge sizes measured immediately after operation was significantly ($P < 0\ 001$) less when the SAAB jig was used (Table 2)

Anterior inclination of the articular surface of the tibia On lateral films all but three patients showed an increase in anterior inclination of the articular surface of the tibia after operation, and this [illegible] significantly ($P < 0\ 00$[illegible]) [illegible] SAAB jig was not used (Table [illegible])

Increase in the anterior [illegible]

Table 4 Complications and [illegible]

Group	[illegible]
Wound infection	[illegible]
Peroneal palsy	[illegible]
Extraction of staples	[illegible]
Reosteotomy	0
Total knee replacement	[illegible]

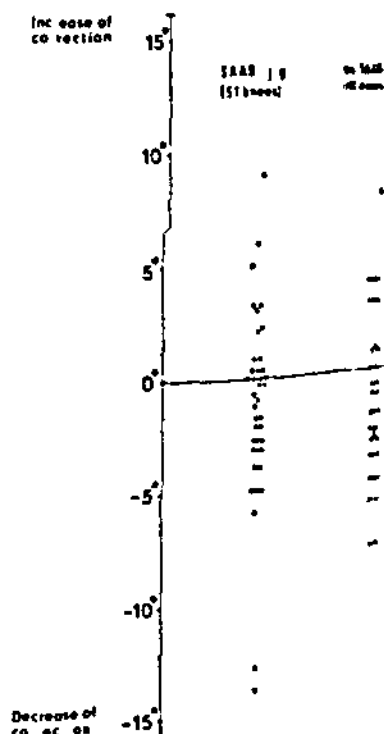


Figure 1 Changes in correction in the [illegible] during the first year after operation

Table 5 Subjective results of operation [illegible] without the SAAB jig

[illegible]	SAAB [illegible]	[illegible]
[illegible]	[illegible]	[illegible]
Worse than before [illegible]	[illegible]	[illegible]
[illegible] same as before	[illegible]	[illegible]
[illegible] better than before	[illegible]	[illegible]
Much [illegible] than before	[illegible]	[illegible]
[illegible]	[illegible]	[illegible]

-relation with good or poor subjective

g of staples Coventry staples (Coventry slipped more than 3 mm in 37 per cent of ses whereas the SAAB staple slipped han 3 mm in 23 per cent The difference significant

-ications and reoperations The com- ons and reoperations encountered with ithout the SAAB jig showed no signifi differences (Table 4) The usual reason traction of staples was gliding

of correction There was a tendency to orrection after operation both with and ut the SAAB jig Both groups include its showing increase in correction and its with loss of correction There was no icant difference in loss of correction or without the SAAB jig (Figure 1)

nt's opinion There was no significant ence in the subjective result between tions with and without the SAAB jig e 5)

om the X ray films an attempt was made udge postoperative contact in the tomy and the healing time There were pparent differences between operations and without the SAAB jig

CUSSION

ie present study the SAAB jig was used in normal correction and overcorrection etermined by the three-point measure- technique. With regard to most ibles investigated there was no significant rence between operation with and without the SAAB jig It is technically relatively easy to operate with this device, although the operation time is prolonged by 15 minutes Operation with the SAAB jig did not in itself give a better subjective end result, but significantly greater accuracy was achieved Use of the device resulted in significantly less anterior tilting of the articular surfaces of the knee

It has been shown (Myrnerts 1980) that overcorrection of the varus malalignment at high tibial osteotomy for medial gonarthrosis gives significantly better subjective end results It is therefore rewarding to aim at exactness and for this the SAAB jig should prove useful

ACKNOWLEDGEMENTS

The author wishes to express his thanks to Professor Olov Lindahl for help and guidance throughout this work, and to Mr Henry Norrbom for invaluable technological assistance in designing the SAAB jig

REFERENCES

Bauer G Insall J & Koshino T (1969) Tibial osteotomy in gonarthrosis. *J Bone Jt Surg* 51 A 1545–1563

Coventry M (1969) Stepped staple for upper tibial osteotomy *J Bone Jt Surg* 51 A, 1011

Edholm P Lindahl O Lindholm, B., Myrnerts, R Olsson K E & Wennberg E (1976) Knee instability *Acta orthop scand* 47, 658–663

scand 48, 95–98.

Myrnerts, R (1978) The SAAB jig – an aid in high tibial osteotomy *Acta orthop scand* 49, 85–88

Myrnerts R (1980) High tibial osteotomy with overcorrection of varus malalignment in medial gonarthrosis. *Acta orthop scand* 51, 557–560

-spondence to Rune Myrnerts, M D Department of Orthopaedic Surgery Regionsjukhuset, S-581 85 -ping Sweden.

op scand 51, 569–573 1980

URE OF THE CORRECTION OF VARUS DEFORMITY
IINED BY HIGH TIBIAL OSTEOTOMY

MYRNERTS

ient of Orthopaedic Surgery, Medical School, University of Linkoping Regionssjukhuset, Linkop-
·den

Failure of the correction of varus deformity after high tibal osteotomy has been analysed in 99 knee joints As this relapse occurred mainly after removal of the cast at 6 weeks, it is recommended that the patient should not load the affected leg without a cast until 10 weeks after the operation

No patient linked factor was identified that might be considered to account for the failure of correction during union

There was a tendency for the valgus/varus deviation of the knee, as determined by the three-point technique, to drift in the varus direction Between 3 and 24 months after the operation this drift was on average 1 1°

Key words failure of angular correction gonarthrosis, high tibial osteotomy, varus

Accepted 30 x 79

s on corrective tibial osteotomy rarely e the intended degree of angular in the frontal plane and how sful the operation was in this regard during the operation itself a difference n the desired and the actual change in can arise This is due in some measure difficulty of removing a bone wedge of the predetermined size Another is that the wedge removed may be d slightly forwards or backwards in n to the frontal plane through the tibia, he result that the angular change in the l plane that the removal of the wedge is led to produce is partly lost.

lure of the angular correction often postoperatively The time at which relapse occurs has received little atten- likewise the responsible factors have not dealt with. Ziller & Seyfarth (1974) that in 17 out of 25 tibial osteotomies med to correct varus deformity there was an average change of 4° in the varus direction during the period of union This figure is difficult to interpret because two radiographic variants were used, films taken with the patient lying supine immediately after the operation being compared with films taken with patient standing after union

Possible causes of failure of correction are

(1) Displacement of the osteotomy surfaces during union,

(2) continued wear of cartilage and bone, and

(3) changes in the stabilizing structures of the knee joint

One purpose of the present study was to identify the factors that might be responsible for failure of the angular correction achieved at the operation Another aim was to determine the time or times at which the relapse is likely to occur and to analyse the implications of the results for the postoperative treatmen*

5470 80 030569–05502 50 0

METHODS

Angular displacement of the osteotomy surfaces in [illegible]

of the tibia, both drawn on frontal films. The angle was measured before and immediately after the operation and then after intervals of 1 and 6 weeks and 3, 6, 12 and 24 months The standard deviation of the error of the method determined by replicate measurement on 10 films was 1°

The *medio-lateral instability* of the joint and its *varus/valgus deviation* were determined by an orthoradiographic technique the 'three-point measurement" (Edholm et al 1976, 1977)[1] This determination was performed before the operation and 3 6, 12 and 24 months afterwards By the three-point method it is possible to measure the total angular change resulting from the surgical procedure involving both bone and soft tissue By subtracting the above angular displacement from the total angular change that part of the change in the varus/valgus deviation that was due to the stabilizing soft tissues was isolated

The patient's fat free weight (FFW) was determined from the expression FFW = 1 2 + 162 L²R where L is the body length and R the sum of the widths of the right and left wrists (von Dobeln 1960) both expressed in metres. The normal weight (N) was taken as 1 2 × FFW for men and 1 35 × FFW for women (von Dobeln 1960)

The *body weight* determined by weighing was classified according to a 4-degree scale,

1 less than 1 1 N – normal weight
2 ⩾ 1 1 N and < 1 2 N – moderate obesity
3 ⩾ 1 2 N and < 1 3 N – marked obesity
4 ⩾ 1 3 N – very marked obesity

The patients' *age* at the operation was recorded

Knee joint mobility was measured with a goniometer

The *degree of arthrosis* of the knee joint was estimated on frontal views of the joint taken with the patient standing on both legs with the knees slightly flexed (Marklund & Myrnerts 1974). The degree of arthrosis was classified according to the following 5 grade scale (Ahlback 1968)

Degree I At most a slight reduction of the cartilage height

Degree II Obliteration of the joint space

Degree III Bone loss of ⩽ 7 mm measured along the medial or lateral margins of the joint from a line perpendicular to the [illegible] and tangential to the una[illegible]

Degree IV Bone loss > 7 [illegible] above

Degree V Bone loss > 7 [illegible] luxation position, defined [illegible] placement of the tibia [illegible] relation to the femur

The *bone density* was determined [illegible] absorption as described by [illegible]

MATERIAL

The series for the study compr[illegible] women and 40 men). Their ages [illegible] 76 years, mean 62 years (Table 1). [illegible] patients the operation was perf[illegible] giving 99 joints as the total ma[illegible] All the patients had a medial [illegible] number of joints used in the [illegible] study (see below) differ because of the [illegible] performing the various examinations [illegible] patients.

Table 1 Distribution of the p[illegible] to sex, and age at the time of [illegible]

Age	40–49	50–59	60–69	[illegible]
Women	2	11	[illegible]	[illegible]
Men	6	9	20	[illegible]
Total	8	20	4[illegible]	[illegible]

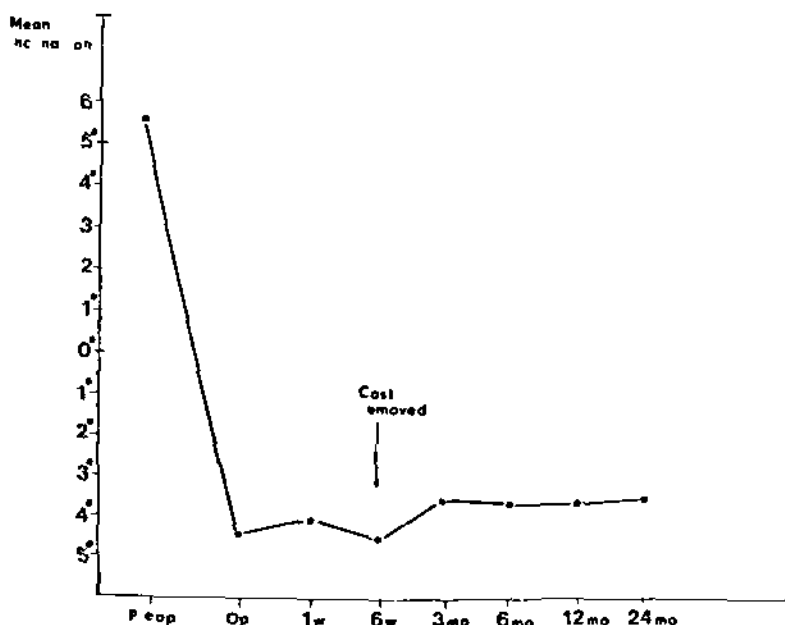
RESULTS

Failure of the initial [illegible] angular displacement

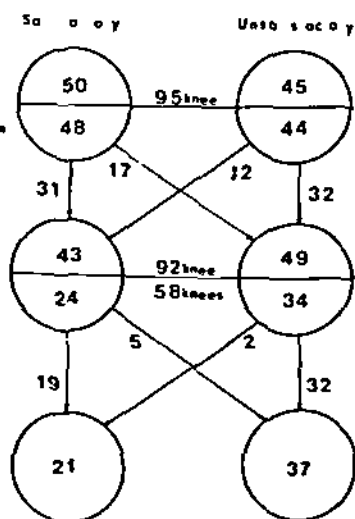
The change in the [illegible] articular surface of the tibia [illegible] direction achieved at the operation [illegible] on average unchanged during [illegible] weeks but then there was a [illegible] until the third month ($P<0$[illegible] Subsequently the tilt remained [illegible] constant until the end of the [illegible] of 24 months (Figure 1).

During the first 3 [illegible] operation the tibial [illegible] mean of 0 8° medially ([illegible] 15° medially). From [illegible]

[1] The varus/valgus deviation of the knee is defined as the angle between the hip-knee line and the mid position of the knee-ankle line i.e the bisector of the medio-lateral angle of instability



1 Mean inclination of the upper tibial articular surfaces in relation to a line perpendicular to the he tibia before and at defined times after the operation
medial inclination
lateral inclination



2 Changes in the initial correction red on frontal films of the tibia the 99 knees 92 were examined both im tely and 6 months after the operation Fifty- of the 99 knees were examined at both 6 ts and 24 months after the operation

joints followed up for the full period showed on average a further 0 3° of medial tilt (range 5° laterally to 5° medially)

During the first 6 months after the operation there was a failure of correction in 17 of the 48 knee joints where the original correction was classed as *satisfactory* – that is to say the difference between the angular correction actually achieved and the intended apical angle of the wedge was not greater than + 2° (Figure 2) Of the 44 knee joints where the correction at operation was *un satisfactory* 26 were undercorrected and 18 overcorrected In 12 of the knee joints with unsatisfactory correction due to angular displacement of the osteotomy surfaces in the frontal plane the correction improved and was then classed as satisfactory (Figure 2). As expected there was only a slight further deterioration after 6 months. Of the 37 joints where the correction was still unsatisfactory at 24 months, 20 were undercorrected and 17 overcorrected

There was no statistically significant correlation between the postoperative failure of angular correction and any of the variables obesity, bone density, degree of arthrosis, age and instability of the joint Nor was it evident that restricted mobility of the joint, manifested as a flexion contracture of more than 15° and restriction of full flexion to less than 90°, was associated with a medial change in the tilt of the tibial plateau

Failure of initial angular correction as determined by the three-point technique

A *satisfactory correction* was recorded in 45 out of 91 joints 3 months after the operation This was defined as a difference of not more than ± 2° between the intended and the actual varus/valgus deviation of the knee as determined by the three-point technique All the patients were followed up for 1 year and 60 per cent for 2 years. At 2 years the proportion of satisfactory corrections fell from 49 to 44 per cent Of the 46 joints with an *unsatisfactory correction* at 3 months 42 (91 per cent) were undercorrected and 4 (9 per cent) overcorrected Between 3 and 24 months the percentage with undercorrection varied between 88 and 95 per cent

Changes in the varus/valgus deviation of the joint, as determined by the three-point technique, usually occurred as a displacement of both the valgus and the varus extreme positions. Between the 3- and 24-month follow-ups, a varus displacement of the varus/valgus deviation of the knee was recorded in 37 out of 55 joints, usually as a simultaneous increase in varus and decrease in valgus (18 out of 37) The mean displacement in the varus direction was 1 1°

DISCUSSION

The analyses disclosed no single patient-linked factor that could account for the observed postoperative failure of the initial angular correction of the varus deformity It is possible that combinations of the various factors such as marked obes[illegible] severe arthrosis and pro[illegible] the knee joint might prove to be [illegible] in a larger series. Sta[illegible] yielded no correlation betwe[illegible] combinations of various factors [illegible] study

A constant drift in the va[illegible] high tibial osteotomy obser[illegible] Insall (1976) is confirmed by the [illegible] the present study Here [illegible] between the 3- and 24-month [illegible] varus/valgus deviation of the [illegible] determined by the three-poi[illegible] changed by an average of 1 1° [illegible] direction It might be possible to [illegible] in the future by placing [illegible] exercise of the muscles that [illegible] on the lateral side

The cast was removed af[illegible] exercising of the joint was [illegible] patient being advised to [illegible] point where pain was felt [illegible] showed that displacement of the [illegible] surfaces occurred between [illegible] months after the operation, [illegible] prolonged the period of [illegible] by 4 weeks so as to reduce the [illegible] original correction during the [illegible] union.

REFERENCES

Ahlback S (1968) Osteoarthrosis of [illegible] radiographic investigation. [illegible] (Stockh) Suppl. 2[illegible]
von Dobeln W (19[illegible]) [illegible] nomenklatur Svenska Lä[illegible] 2472 2475
Edholm, P., Lindahl O Lind[illegible] R., Olsson, K E & W[illegible] instability [illegible]
Edholm, P., Lindahl O Lind[illegible] R., Olsson, K E & W[illegible] instability and [illegible] scand 48, 95–9[illegible]

nd T & Myrnerts, R (1974) Radiographic -rmination of cartilage height in the knee - *Acta orthop scand* 45, 752–755

, B (1966) Post traumatic osteopenia *Acta op scand*, Suppl 91

Shoji, H & Insall, J (1976) High tibial osteotomy for osteoarthrosis of the knee *Int Surg* 6, *11–14*

Ziller, R & Seyfarth H (1974) Loss of correction following high tibial osteotomy *Beitr Orthop Traum* 21, 358–363

ondence to Rune Myrnerts M D, Department of Orthopaedic Surgery Medical School University oping Regionssjukhuset, S 581 85 Linkoping Sweden

›p scand. 51, 575–578 1980

ŠTIC ARTHROPLASTY OF THE FIRST łTARSO-PHALANGEAL JOINT

NDUR GUDMUNDSSON & KRISTJÁN RÓBERTSSON

ıent of Orthopaedic Surgery and the Department of Radiology Kärnsjukhuset, Skövde Sweden

Twenty-nine patients were operated on for painful conditions of the first metatarso-phalangeal joint using Swanson's implant arthroplasty In three cases the implant had to be removed. An analysis was made of the remaining 26 cases 4 to 6 years postoperatively based on a clinical and radiographic review The results were deemed favourable and comparable to those attained by successful resections or osteotomies. The relatively high incidence of reactive bone changes, plus implant breakage in five cases, makes long-term results more uncertain.

Key words silastic implant arthroplasty great toe pain relief, reactive bone changes, implant breakage

Accepted 10 viii 79

·der to avoid certain disadvantages ated with the commonly used ıons for painful rigidity and valgus nity of the first metatarso-phalangeal Swanson in 1972 introduced an implant ›plasty for the great toe (Swanson 1972) mplant is made of pliable silicone rubber tic) in one piece and has an in- dullary stem to fit the first phalanx after ll basal resection (Figure 1A) The pros- is supplied sterile and is available in sizes. It was used in 29 cases as an ıative to the Keller and Reverdin- enström procedures. The survey is l on a clinical and radiographic review

IENTS AND METHODS

›tal of 29 patients were treated with ›son's Silastic arthroplasty of the first arso-phalangeal joint 4 to 6 years prior to study Eight patients had bilateral ıtions, making a total of 37 arthroplasties. ›an age at operation was 53 6 years (range 1 years) and at review 59 2 years.

Interval between operation and review averaged 5 3 years (range 48–72 months).

The indication for operation was painful valgus deformity or rigidity in 30 joints and rheumatoid arthritis in 4 joints.

In the interval between operation and review the prosthesis was removed in three cases leaving 26 patients (34 joints), 19 females and 7 males, for assessment

Management Basically a simple Keller procedure was performed A fascial flap as recommended by Swanson was omitted A canal was shaped in the [illegible] The [illegible] used [illegible] fitted snugly against the cut surface of the phalanx.

After operation a pressure dressing and a splint were applied and worn for 2 weeks. Thereafter active motion was encouraged and full weight-bearing was allowed. A night splint was worn for a month

The duration of stay in hospital was on the average 7 days for unilateral cases (range 3–14) and 8 days for bilateral cases (range 6–14).

Five patients were pensioners and four were either apprentices or were unemployed. In 20 working patients the duration of disability averaged 6 weeks (range 4–9 weeks).

-6470/80/030575–04$02.50 0

Table 3 Passive range of dorsiflexion in 34 metatarso-phalangeal joints

sis	Range of dorsiflexion 0°–20°	21°–40°	>40°	Total
valgus		4	9	13
rigidus	3	10	4	17
atoid arthritis		2	2	4
	3	16	15	34

Table 4 Radiographic incidence of new bone formation around the base of the implant

of ...chment	Time after operation 1 year	2–4 years	4–6 years
	7	4	4
	10	6	6
ate	10	11	19
	4	5	5
adiographed	3	8	0
	34	34	34

...e radiograms were supplemented by ...graphy in the lateral projection (Hagert ...

... of the 34 joints radiographed at follow- ...lowed signs of bone reaction around the ...lant i e new bone formation and/or ...osis and widening of the phalanx The ...e of new bone formation was graded* ...three stages by measuring the encroach- ... upon the base of the implant (Table 4) ...ter the first postoperative year or so, ...rently a period of stress adaption, ...oachment was seen to increase in about ... third of the joints but otherwise no ...er changes were observed. Encroachment ... absent in four joints, two with ...matoid arthritis and in two joints with ...lant fracture (vide infra)

...t review five cases of implant fracture ...e found A common feature of four of ...e cases was that the postoperative radiograms showed a space between the base of the implant and the resected surface of the phalanx (Figure 1A) This space persisted in two joints in which no encroachment of new bone was seen and in the two other joints the setting process was prolonged Such incongruity apparently concentrated the forces acting upon the implant to the area of the junction between the stem and the base of the implant where cracks were found in all four cases (Figure 1B, C) In the fifth case a fragment from the dorsal edge of the implant



Figure 1 A Two months after operation for painful hallux rigidus B, C Frontal and lateral views of the same toe 4 5 years after operation showing breakage of implant

...Minor encroachment Less than half of the ...ness of the implant base
...erate encroachment More than half of the ...ness of the implant base
...re encroachment The whole thickness of the ...ant base

base had been pinched off at some time between 2 5 and 5 years after operation

CONCLUSIONS

In our opinion this method, at any rate 4–6 years after operation, compares well with more established methods The number of dissatisfied patients was comparatively less than that reported by Goldie et al (1974) who reviewed 110 patients 2 years after Reverdin osteotomy or resection Sixteen were not satisfied with the result (14 5 per cent) compared with 2 (7 per cent) in this material

No attempt was made to compare the results of this survey with those of other methods, i e osteotomies and resections, performed by the same surgeons but the general impression was that this method afforded a higher rate of complete pain relief and good cosmetic appearance Range of motion of the joint and the frequency of shoe problems, on the other hand, appeared not to differ appreciably

As there were two patients who develo[illegible] persistent unaccountable pain resulting [illegible] removal of the implant and five impl[illegible] showing breakage on radiograms, it is [illegible] opinion that the method in its present f[illegible] should be used with caution particular[illegible] younger patients To avoid fractures of [illegible] implant a close fit between the impla[illegible] the resected phalanx is apparently of [illegible] importance

REFERENCES

Goldie I Nielsen J M. & Lundh, [illegible] Hallux valgus – en oversikt och resulta[illegible] operativ behandling *Lakartidn.* 71 63-[illegible]

Hagert C G (1975) Metacarpophalangeal implants An experimental and rontgenographic study *Scand. J* [illegible] *reconst Surg* Dissertation.

Swanson A B (1972) Implant arthroplasty [illegible] the great toe *Clin Orthop* 85 75 81.

Wenger R J J & Whalley R C (1978) [illegible] replacement of the first metatarsopha[illegible] joint *J Bone Jt Surg* 60 B 88 92.

Correspondence to Gudmund Gudmundsson M D Dept of Orthopaedic Surgery Kärnsjukhuset [illegible] S-541 01 Skovde Sweden

[illegible] op. scand. 51, 579–580 1980

[illegible]OGRAPHY IN THE DIAGNOSIS OF POSTERIOR [illegible]OCATION OF THE STERNO-CLAVICULAR JOINT

A LOURIE

[illegible]nt Service, John Radcliffe Hospital Oxford, England

A case of posterior dislocation of the sterno-clavicular joint is described in which tomography was helpful in confirming the diagnosis. It is suggested that this investigation may be useful where doubt exists in dislocations of this joint

Key words dislocation, sterno-clavicular joint tomography

Accepted 4 xi 79

[illegible] sterno-clavicular joint is a diarthrodial [illegible] which provides the only true articulation [illegible]en the trunk and upper limb girdle It is [illegible]unded by strong ligamentous structures, [illegible]t is generally agreed that dislocation of [illegible] oint is uncommon, occurring in approx-[illegible]ly 3 per cent of shoulder-girdle injuries [illegible]e 1958) Of the two varieties of disloca-[illegible] anterior and posterior, the latter is much [illegible]arer While the clinical diagnosis may be obvious, with easily palpable defor-[illegible] together with engorgement of neck [illegible] mild respiratory distress, and difficulty swallowing, radiographs in special [illegible]tations (Baker 1959, Hobbs 1968) are [illegible] required to confirm the diagnosis. The [illegible]wing case illustrates the value of [illegible]graphy in this respect

[illegible]E REPORT

[illegible]l aged 15 fell onto her right shoulder while [illegible]-jumping She immediately experienced pain [illegible]e region of the right clavicle but was able to [illegible]inue riding and was admitted to the Accident [illegible]ice 4 hours later At that time she complained [illegible]ain at both ends of the clavicle slight [illegible]ulty in swallowing and upper chest pain on inspiration There was marked tenderness at the medial end of the clavicle with some abnormal mobility, and an easily palpable "step" at the sterno-clavicular joint, the clavicle disappearing beneath the outer border of the manubrium In this region a small, mobile soft-tissue swelling could be felt presumably the intra articular disc of the sterno-clavicular joint A clinical diagnosis of posterior dislocation of the sterno-clavicular joint was made but routine antero-posterior and 40° oblique radiographs did not provide confirmation of this Postero-anterior tomography of both sterno-clavicular joints was carried out, and clearly showed the medial end of the left (normal) clavicle coming into focus at a "slice" 1 cm anterior to that at which the medial end of the right clavicle came into focus (Figures 1 and 2) This was taken as confirmation of the clinical diagnosis, and under general anaesthesia reduction was achieved by abduction, traction and extension of the upper limb The reduction was complete and remained stable A figure-of-eight bandage was applied and the patient made an un eventful recovery

DISCUSSION

While anterior dislocation of the sterno-clavicular joint usually presents no difficulty in diagnosis, with obvious prominence of the medial end of the clavicle, posterior dis-locations may sometimes be less evident clinically, especially in obese patients. It is

[illegible]-6470 80 030579 02$02 50 0



Figure 1 Tomographic "slice' at 8 cm showing medial end of left clavicle in focus



Figure 2 Tomographic slice at 9 cm [illegible] medial end of right (dislocated) clavicle [illegible]

stated that the pain associated with posterior dislocation is more severe than with anterior dislocation, but in the patient reported here pain was not an especially marked feature This patient did complain (though not spontaneously) of slight dysphagia and dyspnoea, but there were no signs of venous congestion and no pneumothorax

In view of the vital structures in direct posterior relation to this joint, it is important to obtain the best diagnostic information and clinical examination may be insufficient There are anatomical difficulties in taking true lateral radiographs of an individual sterno-clavicular joint in either the sagittal or the coronal plane The standard AP or PA projections or the various inclined views which have been described, may be difficult to interpret It is suggested that where any doubt exists regarding the diagnosis of posterior dislocation of the sterno-clavicular joint, or where detailed radiographic infor[illegible] tion is required (e g suspicion of associated fracture) accurate tomogra[illegible] most helpful tool

ACKNOWLEDGEMENT

I am grateful to Mr J Spivey F R C S Co[illegible] tant Orthopaedic Surgeon for perm[illegible] report this case under his care

REFERENCES

Baker E C (1959) Tomography of the [illegible] clavicular joint. *Ohio St med J* 55 60[illegible]

Hobbs D W (1968) Sterno-clavicular [illegible] new axial radiographic view *Radiolog*[illegible] 801

Rowe C R (1958) *Fractures and other* [illegible] (Ed Cave E F) Year Book [illegible] Publishers, Chicago

Correspondence to Mr J A Lourie Ph.D F R C S Nuffield Orthopaedic Centre Headington [illegible] OX3 7LD England

·an Rheumatoid Arthritis Surgical
y

naugural conference of the European natoid Arthritis Surgical Society will be in Vienna, Austria, from April 23–25,

a further information about the society ne conference, contact the President, Jan Pahle, M D, Oslo Sanitetsforening natism Hospital, Akersbakken 27, Oslo 1, ay

Volvo Awards for Low Back Pain arch

der to encourage research into low back the Volvo Company of Goteborg, den, has again this year sponsored three s of US$ 3,000 each Awards will be made petitively on the basis of scientific merit in ollowing three areas

I Clinical studies
I Bioengineering studies
I Studies in other basic science areas

Papers submitted for the contest must contain original material, not previously published Multiple authorship is acceptable The manuscripts should be full-length in a form suitable for submission to a scientific journal Five copies of each paper submitted in full should be sent to the address given below, post marked *not later than January 2, 1981*

One of the authors should be prepared to come to Paris, France, at the time of the meeting of the International Society for the Study of the Lumbar Spine, May 17–20, 1981, to present the paper and to receive the prize

A board of referees will be chaired by the undersigned and will contain members from the fields of clinical medicine, bioengineering and biochemistry

Please direct all correspondence to
Professor Alf Nachemson
Past President, ISSLS
Department of Orthopaedic Surgery I
Sahlgren Hospital
S-413 45 Goteborg
Sweden

ˡp scand. 51 583–588 1980

ᐟMATE FAILURE OF DIAPHYSEAL BONE

ᐟᐟ erimental Study on Dogs

Z, K ERIKSSON & L STRÖMBERG

ents of Orthopaedic, General and Experimental Surgery Karolinska Hospital and Department th of Materials and Solid Mechanics The Royal Institute of Technology Stockholm Sweden

The fracture process of torsion tested entire canine diaphyseal bones was studied with a high speed camera The speed of the final fracture propagation proved to be incompatible with plastic deformation of macroscop cal parts of the bone

Key words bone bone strength biomechanics fracture stress mechanical

Accepted 8 xi 79

ᐟorque-twist curve of entire diaphyseal from dogs consists of a linear part g from zero load and a non-linear part ᐟing the ultimate failure of the bones e 1). The linear part of the curve ᐟterizes the elastic deformation of the ᐟ(Chamay 1970, Currey 1970) It has assumed by many authors that the non-ty basically corresponds to plastic mation of the bone (Currey 1970 ᐟski 1970, Burstein et al 1972 Pope & ater 1972)

e development of small cracks in the c, however, has been pointed out pre-ly by Frost (1960) Pope & Outwater) and Carter & Hayes (1977a) among s. Microcracks formed during the non-ᐟ phase of the deformation proved to ᐟe the bone stiffness to such an extent the non linear behaviour of the bone can ᐟplained by this effect (Carter & Hayes b, Netz et al 1979 1980)

e therefore postulated that the bone ᐟrial is elastic even in the non-linear e, and that the non linearity is caused by ᐟocracks (Netz et al 1980)

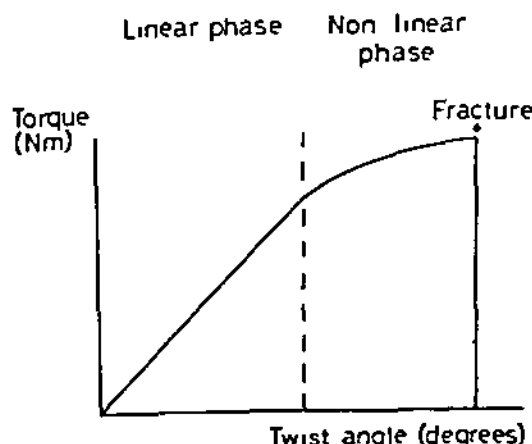


Figure 1 The torque-twist relationship of entire diaphyseal bones The relationship is linear starting from zero torque and non linear preceding the final fracture The magnitude of the torque is in newtonmetres (Nm) and that of twist in degrees

Robertson et al. (1978) studied the fracture toughness of bovine bone material and found that the size of the plastic zone around the crack tip is less than 0 02 mm. On this basis, they concluded that crack propagation

64ᐟ0 80/040583 06 $02.50/0

involves localized disruption around individual or small groups of lamellae This finding supports our suggestion that an elastic bone material is not incompatible with a non-linear load-deformation relationship

The aim of the present work was to study whether plastic deformation of macroscopic parts of the diaphyseal bone occurs during the final fracture process

MATERIAL AND METHODS

The test material consisted of related pairs of femora and of tibiae with closed epiphyseal lines from two healthy dogs The animals were chosen at random from a group of 30 long-legged dogs of various breeds and of both sexes The weight of the experimental dogs was approximately 15 kg One bone from each related pair was selected at random as the test bone and the other as its control

Immediately after sacrifice, all soft tissue was removed from the bones, which were kept moist at room temperature (+ 20°C) in gauze saturated with physiological saline solution

Torsion testing was carried out using the method and torsion machine described by Stromberg & Dalén (1976) The entire diaphyseal bones were fixed in the machine grips by casting the bone ends in two metal cuffs The castings consisted of a metal alloy with a solidification temperature of 47 5°C This technique prevented undue stress concentrations in the bone ends and made it possible to test the bone within 15–30 minutes after sacrificing the animal

The torsion machine permits twisting of the test bone at a constant twist rate, irrespective of the load within the test range The twist rate was fixed in the present study at 6 degrees per second The torque as a function of time was registered on a multichannel light beam recorder (Ultralette 5651, ABEM, Bromma, Sweden)

For each related pair of bones, the control bone was first twisted to ultimate failure and the maximum torque capacity determined Subsequently the test bone was twisted to ultimate failure The last 2 5 seconds of this test, including the final fracture process, were registered with a high speed camera (HYCAM, K20S4AW, I Weinberger, Zurich, Switzerland) The film speed was 5,000 exposures per second

All bones were twisted outwards. The onset of the filming period was determined by the recorded torque-twist curve of the control bone (Stromberg

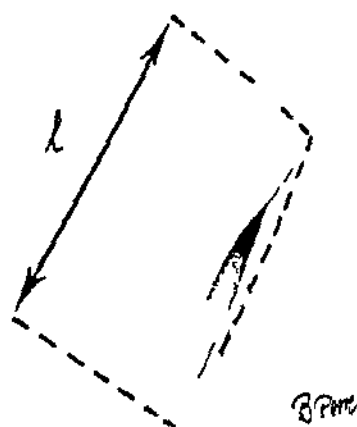


Figure 2 Measurement of fracture pa[illegible] Assuming that the fracture propagates [illegible] point in two directions only one half of the fracture path was measured

& Dalén 1976 Netz et al. 1978) H[illegible] filming requires intense lighting of the [illegible] prevent the effects of heat due to the li[illegible] bones were continuously sprayed [illegible] physiological saline solution during film[illegible]

The length of the final fracture pa[illegible] measured on the test bones as indicated i[illegible] 2

RESULTS

Exposures immediately before the fi[illegible] of a bone are shown in Figures 3a and [illegible] immediately after in Figures 3c and [illegible] exposures are consecutive in the orde[illegible] d, the time lapse between them bein[illegible] seconds Figure 3a as well as Figu[illegible] a still unfractured bone 0 0002 second[illegible] Figure 3c, the final fracture is evide[illegible] pleted The bones failed throug[illegible] fractures

The length of the fractures of the [illegible] bones and of the control bones (Fig[illegible] shown in Table 1, together [illegible]

3 *Four consecutive high speed film exposures The time interval between two pictures was 0 0002 The torque in relative numbers is shown on the potentiometer*

ited fracture propagation speed of the one fractures. The intense lighting on st bones did not seem to affect the num torque capacity or the final fracture as shown in Table 1

USSION

liaphyseal bone is a complex construc- f heterogeneous materials. The distribution of cortical and spongy bone varies in different parts of the bone as does the distribution of inhomogeneities, such as blood vessel channels, medullary and resorbed bone cavities, etc (Currey 1962, Piekarski 1970, Robertson et al 1978) Microcracks connected with inhomogeneities have been observed by many authors (Frost 1960, Currey 1962, Piekarski 1970, Carter & Hayes 1977a) The reduction of the effective



Bone	Maximum Torque capacity (Nm)		Fracture path length (mm)		Fracture propagation speed (m/s)
	Control bone	Test bone	Control bone	Test bone	Test bone
Tibia	26 2	26 8	73	77	> 385
Femur	28 2	27 8	76	78	> 340

stiffness of the entire bone in the non-linear range (Netz et al 1979a) indicates that the number of microcracks prior to final failure is Considerable At present it is not clear whether or not their distribution is uniform in the entire bone As the microcracks are more effective local stress raisers than inhomogeneities (Currey 1962, Piekarski 1970) it is reasonable to assume that they are decisive for initiation and propagation of the final fracture The final failure process of the entire diaphyseal bone is accomplished within 0 0002 seconds. In spite of the film speed the time to fracture is too short to permit details of the fracture process to be discerned

Assuming that the final fracture is initiated at one point and propagates in two directions, a lower limit of an effective propagation speed can be estimated at 340 m/s It is, however, possible that the final fracture is formed through joining of local fractures initiated at different points. The true propagation speed of a local fracture may thus be lower than the estimated value

The energy supplied to the bone during the final fracture process is insignificant This means that the final failure is unstable and the fracture energy is supplied entirely by released elastic energy of the bone The propagation speed of a main or of local fracture(s) depends solely upon the mechanical properties of the material and is independent of the test machine twist rate In comparison with the time to failure, plastic deformation of macroscopical parts of the bone is a time-consuming process. Therefore only a very thin layer in the immediate neighbourhood of the fracture surface can be deformed plastically during the fracture process. This is also in accordance with the results of Chamay (1970) and Robertson et al (1978) The fracture process is typical for an elastic-cracking material Plastic deformation of macroscopic parts of the bone during the fracture process must therefore be ruled out

The results of the present study support a previous postulation, i e, that an entire diaphyseal bone from an adult individual is elastic for all torques, even in the [illegible] range of the torque-twist curve and [illegible] the final fracture process (Netz et al 1980). Plastic effects do not [illegible] behaviour of

1978) They can not be ruled out, [illegible] although they only occur in [illegible] microscopic size (Chamay 1970).

ACKNOWLEDGEMENTS

Financial support was obtained from the [illegible] Medical Research Council (project no [illegible] 04788-03) and the Trygg Hansa Research [illegible] for Bodily Injury in Personal Accident [illegible]

REFERENCES

Burstein A H Currey J D, Frankel [illegible] Reilly, D T (1972) The ultimate [illegible] bone tissue and effects of yielding J [illegible] 5, 35–44

Carter, D R. & Hayes, W C. (19[illegible]) [illegible] bone fatigue damage. *Clin. Orth* [illegible] 265–272.

Carter, D R. & Hayes, W C. (19[illegible]) [illegible] bone fatigue damage – I Residual [illegible] stiffness. *J Biomech.* 10, 325–337

Chamay A (1970) Mechanical and morph[illegible] aspects of experimental overload and [illegible] bone *J Biomech* 3, 263 270.

Currey J D (1962) Stress concentrations [illegible] *Quart J micr Sci.* 103, 111–11[illegible]

Currey J D (1970) The mechanical [illegible] bone *Clin Orthop* 73, 210–231

Frost H L (1960) Presence of micros[illegible] in vivo in bone. *Henry Ford [illegible]* 25–35

Netz P, Eriksson, K. & Strömberg L [illegible] Torsional strength and geometry of [illegible] bone *Acta orthop scand.* 49 [illegible]

Netz P, Eriksson, K. & Strömberg L [illegible] Non linear properties of diaphyseal bone [illegible] *orthop scand.* 50, 139 143.

Netz P Eriksson, K. & Strömberg L [illegible] Material reaction of diaphyseal bone [illegible] torsion *Acta orthop scand.* 51, [illegible]

Piekarski K. (1970) Fracture of bone *J [illegible] Phys* 41, 215–223

Pope M. H & Outwater J O. ([illegible]) fracture characteristics of bone [illegible] *Biomech* 5, 457–465

n, D M, Robertson D & Barrett, C R
d Fracture toughness, critical crack length
lastic zone size in bone *J Biomech* **11**,
364

Stromberg L & Dalen, N (1976) Experimental measurements of maximum torque capacity of long bones *Acta orthop scand* **47**, 257–263

ndence to Pelle Netz, M. D, Department of Orthopaedic Surgery Karolinska Sjukhuset, S tockholm 60 Sweden

›p scand. 51, 589–594, 1980

VANT INTERFERON TREATMENT AND THE LATE ELOPMENT OF CEREBRAL METASTASES IN A ENT WITH OSTEOSARCOMA

AKE BROSTRÖM[1], SNORRI INGIMARSON[2], HANS STRANDER[2], NAR SÖDERBERG[3]

ment of Orthopaedic Surgery, Section of Orthopaedic Oncology, Karolinska Hospital
nhemmet, Karolinska Hospital, and [3]Department of Tumour Pathology Karolinska Hospital
olm Sweden.

A consecutive series of patients with osteosarcoma have been receiving adjuvant interferon therapy at the Karolinska Hospital in Stockholm We report here a case of tibial chondroblastic Grade III osteosarcoma, a boy aged 17 years, who received interferon therapy for 15 months and survived more than 5 years. The first sign of tumour spread was multiple cerebral metastases – an observation suggesting an antitumour effect of human leucocyte interferon on osteosarcoma

Key words adjuvant therapy, interferon, metastasis, osteosarcoma

Accepted 6 xi 79

ithstanding the advances that have ly been made in the treatment of os-coma, the prognosis remains poor, with ar survival rate of well below 50 per cent cer Treatment Reports, 1978) By the the condition has been diagnosed atogenous tumour spread to distant sites inly the lungs – has usually occurred cer Treatment Reports, 1978) There may be metastatic spread to bones including skull and vertebrae Most metastases lop within 1 year of the onset of the ase (Sweetman et al 1971) Brain istases are rare and they are usually a idary rather than a primary manifestation mour spread

his article reports the unusual course of osteosarcoma in a patient receiving vant interferon therapy for 15 months.

E REPORT

May, 1971, a boy of 17 years with no known ous history of systemic disease noted swelling left proximal tibial condyle This was treated as a benign lesion and resection was performed in July of that year Two months later there was a local recurrence A block resection of bone 12 by 4 cm was performed and a bone graft was transplanted from the iliac crest. The free margins of the bone were small and it was doubtful whether the operation had been radical Subsequently, a histologic diagnosis of osteosarcoma was made A conglomerate of lymph nodes removed from the left inguinal fossa 1 month later contained no demonstrable tumour cells.

Eighteen months later there was a second local recurrence, and this time, on the basis of an open biopsy examination, the tumour was classified as a chondroblastic osteosarcoma Grade III The patient was then included in the clinical trial concerning the effect of interferon on osteosarcoma that is being conducted at this hospital (Strander et al. 1977). He was given daily intramuscular injections of 3×10^6 units of interferon for 1 month (Cantell et al. 1974). Subsequently a mid femur amputation was performed The interferon treatment was then continued with the same dose but now reduced to three times a week, it was

-6470.80 040589-06 $02.50 0

withdrawn in February, 1974 Early on there were some minor side effects such as pain at the injection site and fever, and later minor loss of hair

Throughout the treatment the patient felt well, he put on 15 kg and was able to return to work Monthly follow-ups, including lung radiography, showed normal conditions until April, 1975 when a right sided pneumothorax developed. Scintigraphy or lung tomography were not performed Spontaneous remission followed, however, and after 1 month chest radiographs were normal.

In July there was a recurrence of pneumothorax in the same lung The course was much the same as before and no special treatment was given Four months later paresis of the left facial nerve and paralysis of the left arm were noted

Cerebral scintigraphy, computed tomography and carotid angiography showed three separate tumours in the right cerebral hemisphere Microscopic examination of stereotaxic biopsy specimens revealed osteosarcoma tumour cells. Further examinations, including lung films, whole-body bone scintigraphy and liver scintigraphy revealed no remarkable features.

The brain tumours were not accessible for surgery The treatment consisted of irradiation with 39Gy, and high-dose cortisone directed at reducing the oedema (Dexamethazone, 8 g daily).

In July, 1976 more than 5 years after the tumour was diagnosed a single pulmonary metastasis was detected in the right lung, and death followed 3 months later Autopsy disclosed one small metastasis in the third lumbar [illegible] confirmed the metastasis in the right lung [illegible] across – and the cerebral metastases [illegible] tumours were found in any organ, [illegible] liver For a graphical summary [illegible] case history see *Figure 4*

Histological findings

This case illustrates the difficulty [illegible] judging slides of osteosarcoma. The [illegible] twice diagnosed as a benign lesion. [illegible] the patient's age are typical of osteosarcoma [illegible]

In 1976 all cases of osteosarcoma [illegible] diagnosed between 1971 and 19[illegible] by a group of bone experts from [illegible] Dahlin, Chief Surgical Pathology [illegible] Hospitals, Mayo Clinic Rochester [illegible] Thomas, Chief, Laboratory of Pathology [illegible] Institute NIH Bethesda) (Broström et al. [illegible]) using the histologic classification of [illegible] Broders (*Dahlin 1975 Broders et al. 19*[illegible]) original diagnosis of benign tumour [illegible] 1971, was then changed to osteosarcoma [illegible] time there was a predominant [illegible] picture, but parts of the tumour [illegible] teoblastic and fibroblastic features and [illegible] grading could be made (Figure 1). In the [illegible] recurrence cell growth was more aggressive [illegible] tumour was assigned to chondroblastic [illegible] osteosarcoma (Figure 2).





Figure 1 The first open biopsy in July, 1971 Tumour classified as osteosarcoma



re 2 *Open biopsy in the second recurrence Tumour classified as chondroblastic Grade III*



3 *After 1 month of interferon treatment Regressive alterations in the cell picture can be seen.*

ecimens from the operation in January 1973 ere regressive alterations in the cell picture, necrosis and intracellular cavities. These were noticed after 1 month of interferon nt (Figure 3) The autopsy slides revealed tic spread of osteosarcoma

DISCUSSION

That this patient survived more than 5 years, when the osteosarcoma was treated initially as a benign lesion and recurred twice, is

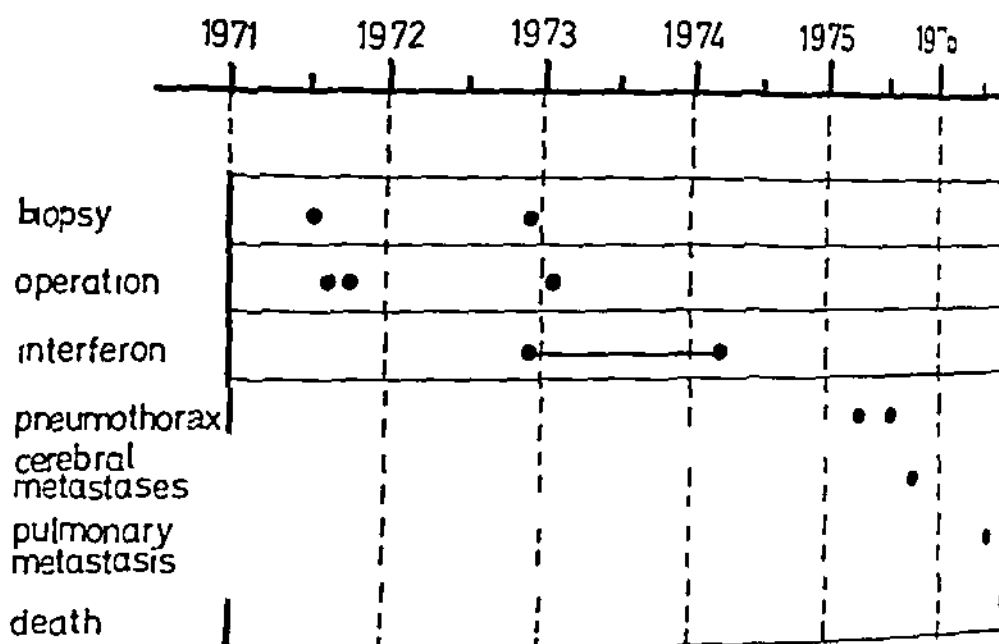


Figure 4 Summary presentation of the case history

remarkable Previous reports suggest a more favourable course of the disease for patients with a long period of symptoms, which indicates a slower growth of the tumour (McKenna et al 1966) In the present case however an aggressive behaviour of the tumour cells was evident already in the original specimens. The regressive changes, with central necrosis found in the later specimens might be due either to fast growing cells or to some effect of the treatment While the development of pneumothorax can in principle be a manifestation of metastases in the lung and pleura this can hardly have been the cause in our patient in view of the spontaneous remission on two occasions and the normal chest films and also in view of the very small metastasis in the right lung This tumour was first confirmed 1 year after the first pneumothorax during a period of intensive cortisone treatment for the brain metastases. The first signs of tumour spread should have been the cerebral manifestations.

During the interferon treatment the patient felt well except for minor side effects, which are consistent with previous findings (Ingimarson unpublished results) It would seem that there is a fairly effective [illegible] penetration of interferon into the CS[illegible] brain (Habif et al 197[illegible] Jordan et al 1[illegible] et al 1974) A further reason why th[illegible] of metastatic disease were [illegible] is that adjuvant chemotherapy [illegible] effective in the treatment of metastases [illegible] lung than at other sites ([illegible] Benjamin et al 1978). The unusual [illegible] course in this patient suggest th[illegible] adjuvant interferon therapy did [illegible] beneficial effect

ACKNOWLEDGEMENT

We would like to thank Professor Kari C[illegible] providing the interferon.
Financial support for this work was [illegible] Anders Otto Swärd s Foundation.

REFERENCES

Benjamin R Baker L, O'Bryan, R, [illegible] Gottlieb J (1978) Chemotherapy for [illegible] osteosarcoma Studies by the [illegible] Hospital and the Southwest Onco[illegible] *Cancer Treatment Rep* 62, 23 -[illegible]

: A. C, Hargrave, R, & Meyerding, H W) Pathological features of soft tissue fibro ma *Surg Gynec Obstet* 69, 267–280

n L. Å, Aparisi, T, Ingimarson, S, rgren, C., Nilsonne, U, Strander, H & G (1980) Can historical controls be in current clinical trials in osteosarcoma ysis of prognostic factors in a historical and ntemporary group *Intern J Rad Oncol Phys* (In press)

Treatment Reports (1978) Proceedings of osteosarcoma study group, Febr 1978 onal Cancer Institute NIH, USA *Cancer itment Rep* 62, 187–313

K, Hiruonen, S, Mogensen, K. E & ila, L (1974) Human leucocyte interferon luction, purification, stability and animal riments *In Vitro* (Ed Waymouth, C) The sue Culture Association, Rockville

D C (1975) Pathology of osteosarcoma *i Orthop* 111, 23–32

D V, Lipton, R & Cantell, K. (1975) rferon crosses blood-cerebrospinal fluid ner in monkeys (38790) *Proc Soc exp Biol d* 149, 286–289

, Nash, C, Morgan, C W, Armstrong, J A, roll, R G & Postic, B (1974) Interferon inistered in the cerebrospinal space and its ct on rabies in rabbits *Infect Immun* 9, –293

Ingimarson, S, Cantell, K & Strander H Symptomatic side effects of long term treatment with human leucocyte interferon (Manuscript)

Jordan, G W, Fried, R P & Merigan T C (1974) Administration of human leucocyte interferon in Herpes Zoster I Safety circulating antiviral activity, and host responses to infection *J infect Dis* 130, 56–62

McKenna, R J Schwinn C P, Song, K. Y & Higinbotham, N L (1966) Sarcomata of the osteogenic series (osteosarcoma, fibrosarcoma chondrosarcoma, paraosteal osteogenic sarcoma and sarcoma arising in abnormal bone) – an analysis of 522 cases *J Bone Jt Surg* 48-A, 1–26

Strander H, Cantell K, Ingimarson, S, Jacobsson P Å, Nilsonne, U & Soderberg, G (1977) Interferon treatment of osteogenic sarcoma – a clinical trial Conference on modulation of host immune resistance in the prevention or treatment of induced neoplasias, 9–11 Dec 1974 Fogarthy Int Center Proc US Government Printing Office, Washington D C 28, 377–381

Sutow, W W (1976) *Late metastases in osteosarcoma Lancet* i, 856

Sweetnam, E, Knowelden, J & Seddon, H (1971) Bone sarcoma treatment by irradiation, amputation or a combination of the two *Brit med J* 2, 363–367

pondence to Lars Åke Brostrom, M D, Dept of Orthopaedic Surgery, Karolinska Hospital, 01 Stockholm, Sweden

ɔp scand 51, 595–600 1980

)METHACIN AND ASPIRIN: EFFECT OF 'STEROIDAL ANTI-INFLAMMATORY AGENTS ON RATE OF FRACTURE REPAIR IN THE RAT

L ALLEN, ARTHUR WASE & W T BEAR

Institute for Therapeutic Research, Merck Sharp and Dohme Research Laboratories Merck and ny Inc, West Point, PA, USA

A total of 210 male Charles River CD rats, 45 days old were subjected to a fracturing of the right radius and ulna by digital pressure while under ether anesthesia These animals were then assigned randomly to dose groups (1, 2 or 4 mg/kg/day of indomethacin and 100 200 or 300 mg/kg/day of aspirin) and were dosed for 21 days. Dose levels were chosen to provide approximately equipotent levels of the test compounds with the highest dose approaching toxicity Radiographs were taken of control rat fractures [illegible]

of the radius and ulna were examined in random sequence without knowledge of the treatment regimen. A histologic grade based on the morphologic stage of fracture healing was given There was a drug- and dose-related retardation of fracture healing which was statistically significant at all dose levels of indomethacin and the highest level of aspirin as compared to controls. Decreased mean grades in the groups given 100 and 200 mg/kg/day of aspirin, though not statistically significant, suggest a retarding effect on fracture healing at these levels also No statistically significant changes in numbers of pseudoarthroses were found

Key words anti inflammatory agents bone fractures fracture repair, indomethacin rats

Accepted 6 xii 79

ɔrts have appeared in the literature esting that indomethacin may be useful habilitation of patients who have suffered ures or who have undergone orthopedic ical procedures (Bernstein et al 1977, mar & el-Salamouny 1968 Kudo et al 3, Kuner & Weller 1969, LeClerc & issier 1969) However recently some stions have been raised concerning the possibility of delay of fracture healing by indomethacin (Huusko et al. 1975, Rø et al 1976, Sudmann 1976, Sudmann & Hagen 1976) The present study was designed to determine whether the nonsteroidal anti-inflammatory agents, indomethacin and aspirin would retard healing of standard, unimmobilized, simple transverse fractures of the radius and ulna in the young rat

-64"0 80 040595-06 $ 0

MATERIALS AND METHODS

A total of 210 male Charles River CD rats 45 days old, were used The rats were anesthetized with ether and were subjected to fractures of their right forelimbs All forelimbs were broken using digital pressure applied over a fulcrum Immediately after fracture, while still under anesthesia, the rats were radiographed using a Picker X-ray machine at 50 kVp, 48 mAs, on nonscreen, high-resolution (Kodak MA-2) sheet film The films were developed in a Kodak rapid processing X-omat and were examined to ensure that each rat had received a uniform, simple transverse fracture of the radius and ulna Twenty-four hours after fracture, the rats were observed to ascertain that their limbs were not deformed, and were assigned randomly to dose groups. Dosing was begun on the day following the fracturing procedure

Thirty rats were assigned to each of seven groups 100 mg/kg/day aspirin 200 mg/kg/day aspirin, 300 mg/kg/day aspirin, 1 mg/kg/day indomethacin, 2 mg/kg/day indomethacin, 4 mg/kg/day indomethacin, and control (which received only the vehicle, 0 5 per cent methylcellulose) The doses of indomethacin and aspirin were chosen to provide reasonably equipotent anti inflammatory activity with the highest levels approaching toxicity Indomethacin is considered approximately 100 times as potent an anti-inflammatory agent as aspirin in the rat (Winter 1964)

Dosing suspensions were prepared fresh daily Indomethacin and aspirin suspensions were maintained on automatic stirrers throughout the dosing period each day and were administered by

in a room equipped with laminar airflow and constant temperature control Purina Lab Chow and water were available *ad libitum* throughout the study, food was not withdrawn prior to autopsies The rats were identified by consecutive numbers using indelible black ink on their tails

On days 8, 14 and 21 rats in the control group were anesthetized with ether, and fracture sites were radiographed using the same procedure as described previously The serial radiographs were used to determine the proper time for termination of the study when fractures in the control rats showed radiographic evidence of mineralized bridging of fracture sites all surviving animals were killed and autopsied (day 22)

Rats dying prior to termination of the study were examined to determine the cause of death, no tissues from these rats were saved for histologic examination One rat was found dead on day 22 and was included with the other rats killed at the termination of the study Those rats [illegible] day 22 were anesthetized with ether [illegible] sanguinated for autopsy Autopsy was [illegible] removal of the fractured forelimbs by [illegible] the carpus and cubitus. The tissue was [illegible] per cent neutral buffered formalin. The bones were decalcified using 15 per cent formic acid the radius and ulna were [illegible] and embedded in paraffin to allow [illegible] sections through the center of each callus.

All the histologic sections, stained [illegible] hematoxylin and eosin were examined in sequence without knowledge of the regimen The degree of fracture repair [illegible] determined using a 5 point scale. A grade [illegible] applied if there was complete bony union [illegible] bony union was less than complete due [illegible] presence of a small amount of cartilage [illegible] callus, the repair was graded 3 (Figure [illegible] complete cartilaginous union (grade 2 [illegible]




Figure 1 Incomplete bony union. [illegible] partial plate of hyaline cartilage [illegible] (Grade 3) (Hematoxylin and eosin [illegible]



e 2 Complete cartilaginous union A plate aline cartilage traverses the callus (Grade 2) atoxylin and eosin 33×)




Figure 3 Incomplete cartilaginous union Fibrous remnants remain within the callus (Grade 1) (Hematoxylin and eosin 33×)

ed present if there was a well formed plate of ne cartilage uniting the fragments (Figure ncomplete cartilaginous union (grade 1) was nt when there was retention of fibrous nts in the cartilaginous plate (Figure 3) The ation of a pseudoarthros s (false joint) was a grade of 0 in that it indicated the most e form of arrest in fracture repair a nion (Figure 4) Pseudoarthrosis was con ed present if there was an incontrovert ble y within the cartilaginous plate between ure fragments, containing blood or other fluid or lined by low cubo dal mesothelia The was based on the least healed bone (radius na) however when a dec sion was equivocal to irregularities of sectioning) it was based synthes s of grades for both bones.

ne fracture repair scores were examined st cally by first re-expressing them in a rankit and then applying the appropriate analys s of variance for overall comparison of rankit mean scores The pairwise comparison between control and drug treated groups was accomplished using least significant difference test ($P - 0\ 05$). The all or none data for pseudoarthrosis formation in treated rats were analyzed for poss ble treatment related differences using Fisher s (1 sided) Exact Test at the same level of s gnificance (Harter 1961 McNemar 1969).

RESULTS

Two rats died prior to day 22 both of these animals were in the 4 mg/kg/day in domethacin group and both succumbed to midjejunal perforations with secondary peritonitis. A third rat in this group died of




Figure 4 Pseudoarthrosis formation A cavity partially lined by low mesothelia filled with proteinaceous material and blood is present within the cartilaginous plate (Grade 0) Hematoxylin and eosin, 33 ×)

intestinal perforation on day 22 The rat is a sensitive model for the effects and side-effects of the prostaglandin synthetase inhibitors particularly indomethacin

A distinct drug- and dose-related impairment of fracture healing was observed in both indomethacin- and aspirin-treated rats (Tables 1 and 2) A statistically significant decrease in mean fracture healing scores was observed at 300 mg/kg/day aspirin and at all dose levels of indomethacin The decreases noted at 100 and 200 mg/kg/day of aspirin were not statistically significant but do suggest a considerable biologic effect In addition, there was an increase in pseudoarthrosis formation at 4 m. kg indomethacin as compared to controls other drug treated groups as well th not found to be statistically significant

DISCUSSION

The cause of the fracture retardation b anti-inflammatory agents is not fully derstood However the inhibitory these compounds on prostaglandin may be an essential factor Prostag have been reported to enhance bo tion, and therefore possibly decrease production *in vitro* and in some systems (Dietrich & Raisz 1975). Inhib of prostaglandins would therefore have a salutary effect on bone However, the vasodilatory effects of staglandins in the inflammatory (and the reparative) process would be inhibited by the anti inflammatory Since bone formation requires adequate oxygen supply (cartilage and cell oxygen supply (cartilage and collagen tissues are formed in oxygen-poor Bassett 1962) the delay in ossification fracture sites caused by prostaglandin synthetase inhibitors may be attributed their depressive action on prostaglandin hence control of regional blood (Staszewska-Barczak & Vane 19 addition, indomethacin has been reported inhibit the activity of primitive oste (Sudmann 1975) although the effects of domethacin on differentiated osteoclasts not yet been fully studied. The retard healing occurs in the face of weight bearing on the limb which is to accelerate fracture repair (Sarmiento 1977) A study of collagen metabolism callus tissue from closed non femoral fractures in rats treated with indomethacin sufficient to delay repair indicated that the delay was brought about by an inhibition of synthesis (Rø et al 1978). It should be pointed out that this is only a

Table 1 Indomethacin/Aspirin Effect of nonsteroidal anti inflammatory agents on rate of fracture repair in rats Mean fracture repair scores in the various dose groups

Treatment group	Mean score*
Control	2.53
Aspirin	
100 mg/kg/day	2 27
200 mg/kg/day	2.10
300 mg/kg/day	1 47**
Indomethacin	
1 mg/kg/day	1 73**
2 mg/kg/day	1 23**
4 mg/kg/day	1 11**

Slides read in random sequence without knowledge of treatment regimen * Based

** ($P < 0 05$) by least significant difference test

2 Indomethacin/Aspirin Effect of nonsteroidal anti inflammatory agents on rate of fracture repair in rats Summary of fracture repair scores in the various dose groups

	No of rats with*				
	Pseudo-arthrosis formation	Incomplete cartilaginous union	Complete cartilaginous union	Incomplete bony union	Complete bony union
atment roup / Numerical grade	0	1	2	3	4
ol	1	2	11	12	4
n					
mg/kg/day	1	6	9	12	2
mg/kg/day	1	5	16	6	2
mg/kg/day	3	14	10	2	1
ethacin					
mg/kg/day	3	7	15	5	–
mg/kg/day	2	19	9	–	–
mg/kg/day	5	15	8	–	–

group contained 30 male rats 2 rats at 4 mg/kg/day indomethacin died prior to scheduled ation All slides read in random sequence without knowledge of treatment regimen

bone repair since rats with fractures treated with indomethacin do proceed to full union in most cases (Wase, unpublished data)

ACKNOWLEDGMENTS

The authors wish to express their gratitude to Drs R E Zwickey, C L Tate, and D L Bokelman for comments and guidance in the course of the study, to Mrs M E Hunsberger for manuscript preparation, and to Dr N Bohidar for statistical analyses

REFERENCES

Bassett, A L (1962) Current concepts of bone formation *J Bone Jt Surg* 44-A, 1217–1244

Bernstein, B, Forrester, D, Singsen, B, King K K, Kornreich, H & Hanson V (1977) Hip joint restoration in juvenile rheumatoid arthritis *Arthr and Rheum* 20, 1099–1104

Dietrich, J W & Raisz, L G (1975) Prostaglandins in calcium and bone metabolism *Clin Orthop* 111, 229–237

Dittmar, F K & el-Salamouny, A R (1968) Erfahrungen mit einem Indolessigsaurederivat (Indomethacin) in der Therapie posttraumatischer u postoperativer Schwellungs zustande *Chirurg* 39, 83–85

Harter, H L (1961) Expected value of normal order statistics *Biometrika* 38, 151–165

Huusko P J, Nieminen, L H E & Nieminen, L S (1975) The effect of indomethacin on tooth extraction wound healing in rats *Experientia (Basel)* 31, 1056–1058

Kudo I, Kanazawa, M, Orima, M, Sato, K, Ogiwara, T, Mune, K, Ishida, H, Kawasaki, K, Yamomoto, H, et al (1968) [Clinical evaluation of indomethacin, a nonsteroidal anti-inflammatory agent, in oral surgery] *Shikai-Tenbo* 31, 177–180 (in Japanese).

Kuner, E. & Weller S. [illegible] Nachbehandlung der Osteosynthese [illegible] *med Wschr* 94, 202 203

LeClerc, F P & Autissier D (19[illegible]) [illegible] de l'indomethacine dans le traitement [illegible] traumatismes des membres et des sequelles *Gaz Hop (Paris)* 1, 31 [illegible]

McNemar, Q (1969) *Psychological* [illegible] ed, pp 272–275 John Wiley & Sons, [illegible] York

Rø J, Sudmann E & Marton, P F (19[illegible]) [illegible] of indomethacin on fracture healing [illegible] *Acta orthop scand* 47, 588 599

Rø J Langeland N & Sander J (19[illegible]) [illegible] indomethacin on metabolism of rat callus *in vitro* *Acta orthop scand* [illegible] 323–328

Sarmiento, A, Schaeffer J F, Beck[illegible] Latta L L & Enis J E (19[illegible]) [illegible] healing in rat femora as affected by [illegible] weight bearing *J Bone Jt Surg* [illegible] 369–375

Staszewska-Barczak, J & Vane J R (1[illegible]) [illegible] role of prostaglandins in the local [illegible] circulation *Clin Exp Pharmacol Ph*[illegible] Suppl 2 71–78

Sudmann E (1975) Effect of indomethacin [illegible] bone remodeling in rabbit ear chambers [illegible] *orthop scand* Suppl. 160 91–115.

Sudmann E (1976) Indomethacin [illegible] fracturtilheling Risiko for seinkt [illegible] pseudoartroseutvikling [Indomethacin [illegible] fracture healing The risk of delayed [illegible] and development of pseudoarthrosis] [illegible] *Laegeforen* 96, 52 (Letter to the Editor)

Sudmann, E & Hagen T (1976) Indomethacin induced delayed fracture healing [illegible] *Unfall Chir* 85, 151–154

Winter C A (1964) Anti-inflammatory [illegible] methods Comparative evaluation of indomethacin and other agents [illegible] symposium on non steroidal anti-inflammatory drugs (Ed. Garattini S & Dukes, M N G) pp 190–202 Excerpta Medica Found Amsterdam.

Correspondence to Henry L Allen, V M D, 44–2 M S D R L., West Point PA 19486 USA

op. scand. 51 601–608 1980

ELECTRIC POTENTIALS AFTER FRACTURE 'HE TIBIA IN RATS

PEZ-DURAN STERN & J YAGEYA

nent of Orthopaedic Surgery and Department of Human Physiology Universidad Complutense, , Spain.

The aim of the present study was to analyse the changes in the bioelectric voltage with time after fracture until healing occurred The right tibia of adult rats was fractured and every day during the first week, and then 10, 14, 21, 30 and 90 days after the fracture the bioelectric potentials were registered with callomelan electrodes placed on the anteromedial surface of the tibia The data collected were statistically analysed The biopotentials [illegible]

early phase of callus formation

Key words biopotentials bone fracture healing time

Accepted 28 1 80

the first reports of Fukada & Yasuda) and Becker (1961) on electrical omena in bones, two lines of research been followed On the one hand the es of bone piezoelectricity and its onship to Wolff's law, and on the other the analysis of bioelectric potentials and ubsequent development of callus stimula- by electric or magnetic fields (Weigert , Richez & Chamay 1972, Basset et al)

a previous paper (López-Durán & ya 1978), the bioelectric pattern of the in rats was found to be similar to that ribed by Becker (1961) Friedenberg & hton (1966) and Weigert (1973) The amal metaphysis shows a negative value h becomes positive in the middle of the hysis and remains so for the rest of the After periosteal stripping we found an ease in the registered voltage, but the ial pattern remained the same Limb ervation only produced a decrease in the collected potentials When the bone was fractured a significant increase in voltage occurred along with a change in the electric spatial arrangement The aim of the present study was to analyse the changes in the bioelectric voltage with time after fracture until healing of the tibia in rats

MATERIAL AND METHODS

Under ether anaesthesia the right tibia of adult Wistar albino rats of both sexes was fractured by finger pressure The fractures were located in the distal third of the tibia at the point of insertion of the fibula Thereafter the rats were allowed to move freely in their cages under standard con- [illegible] the first week and then [illegible] exposed avoiding damaging the periosteum, and the bioelectric potentials were recorded using callomelan electrodes as previously described (López-Durán & Yageya 1978). Before and after

1 64"0 80 040601 08 $02 50

bone repair since rats with fractures treated with indomethacin do proceed to full union in most cases (Wase, unpublished data)

ACKNOWLEDGMENTS

The authors wish to express their gratitude to Drs. R E Zwickey, C L Tate, and D L Bokelman for comments and guidance in the course of the study, to Mrs. M E Hunsberger for manuscript preparation, and to Dr N Bohidar for statistical analyses.

REFERENCES

Bassett, A L (1962) Current concepts of bone formation *J Bone Jt Surg* 44-A, 1217–1244

Bernstein, B, Forrester, D, Singsen, B, King, K K, Kornreich, H & Hanson, V (1977) Hip joint restoration in juvenile rheumatoid arthritis. *Arthr and Rheum* 20, 1099–1104

Dietrich, J W & Raisz L G (1975) Prostaglandins in calcium and bone metabolism *Clin Orthop* 111, 229–237

Dittmar, F K. & el-Salamouny, A. R (1968) Erfahrungen mit einem Indolessigsäurederivat (Indomethacin) in der Therapie posttraumatscher u postoperativer Schwellungszustande. *Chirurg* 39, 83–85

Harter, H L (1961) Expected value of normal order statistics *Biometrika* 38, 151–165

Huusko, P J, Nieminen, L H E & Nieminen, L S (1975) The effect of indomethacin on tooth extraction wound healing in rats. *Experientia (Basel)* 31, 1056–1058

Kudo, I, Kanazawa, M, Orima M, Sato, K, Ogiwara, T, Mune K, Ishida, H, Kawasaki K., Yamomoto, H, et al (1968) [Clinical evaluation of indomethacin, a nonsteroidal anti inflammatory agent, in oral surgery] *Shikai Tenbo* 31, 177–180 (in Japanese)

Kuner, E. & Weller S. (19[illegible]) [illegible] Nachbehandlung der Osteo[illegible] *[illegible] med Wschr* 94, 202–205

LeClerc, F P & Autissier D (19[illegible]) [illegible] de l'indomethacine dans le [illegible] traumatismes des membres [illegible] sequelles. *Gaz Hop (Paris)* 1, 31 [illegible]

McNemar Q (1969) *Psychological [illegible]* ed pp 272–275 John Wiley & Sons [illegible] York

Rø, J Sudmann, E & Marton P F (19[illegible]) [illegible] of indomethacin on fracture healing [illegible] *Acta orthop scand* 47, 588 599

Rø, J, Langeland N & Sander J (197[illegible]) [illegible] indomethacin on metabolism of rat [illegible] callus *in vitro* *Acta orthop scand* [illegible] 323–328

Sarmiento, A, Schaeffer J F, Beck[illegible] Latta, L L. & Enis, J E (19[illegible]) [illegible] healing in rat femora as affected by [illegible] weight bearing *J Bone Jt Surg* [illegible] 369–375

Staszewska Barczak J & Vane, J R (1[illegible]) [illegible] role of prostaglandins in the local [illegible] circulation. *Clin Exp Pharmacol Pr[illegible]* Suppl 2 71–78

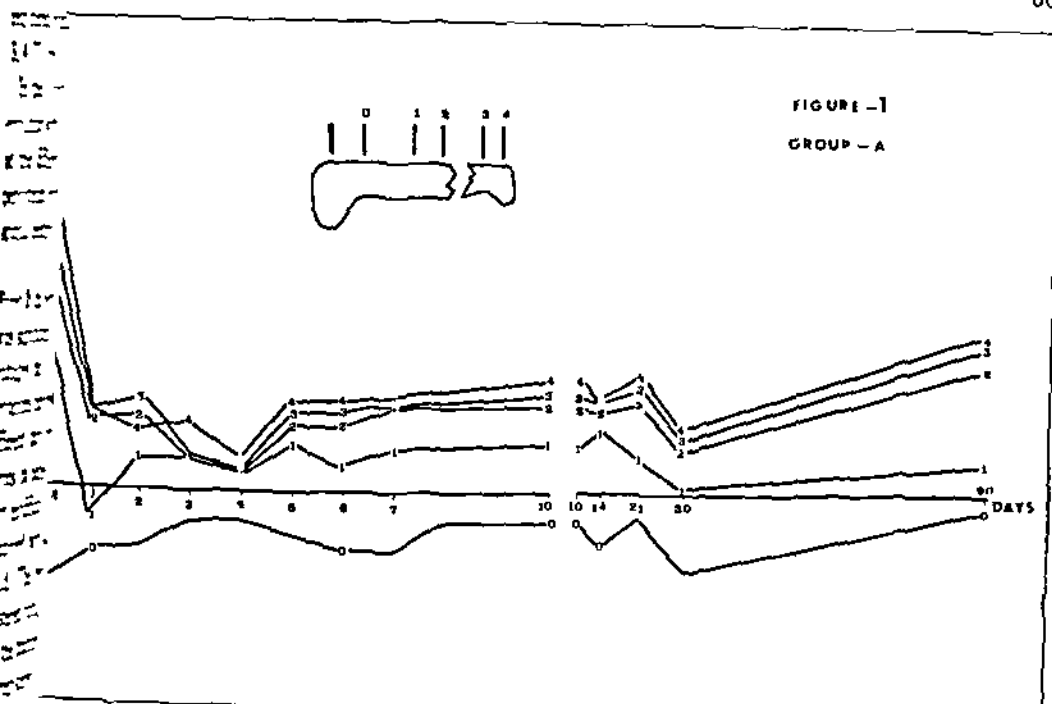
Sudmann E (1975) Effect of indometha[illegible] bone remodeling in rabbit ear chambers [illegible] *orthop scand*, Suppl. 160, 91 115.

Sudmann, E (1976) Indometha[illegible] fracturtilheiling Risiko for senk[illegible] pseudoartroseutvikling [Indometha[illegible] fracture healing The risk of delayed [illegible] and development of pseudoarthrosis] [illegible] *Laegeforen* 96, 52 (Letter to the Editor)

Sudmann, E & Hagen T (1976) Indometh[illegible] induced delayed fracture healing *Arch* [illegible] *Unfall Chir* 85, 151–154

Winter, C A (1964) Anti inflammatory [illegible] methods Comparative evaluation of [illegible] domethacin and other agents *Inter[illegible] symposium on non-steroidal anti-inflammatory drugs* (Ed Garattini S & Dukes M [illegible]) pp 190–202. Excerpta Medica Fo[illegible] Amsterdam

Correspondence to Henry L. Allen V M D, 44–2 M S D R.L. West Point, PA 19486 USA



1 Series A Evolution in time after the fracture of the average voltage values registered from 0 to 4 (IM = immediately)

1 Average voltages at various distances from the proximal epiphysis with increasing time after the fracture Series A

after ...re ...of rats)	Voltage in mV				
	Point				
	0	1	2	3	4
...ediately (7)	−3 033	6 033	7 829	9 329	10 571
...ay (7)	−2 143	−0 486	2 129	2 471	2.571
...ays (8)	−1 925	0 950	2.350	2 825	2.000
...ays (6)	−1 000	1 167	1 000	1 133	2.267
...ays (7)	−0 917	0 600	0 929	0 843	0 929
...ays (7)	0 043	1 529	2 157	2 586	2 786
...ays (8)	−1 950	0 800	2 137	2 637	2.887
...ays (8)	−1 950	1 350	2.750	2.787	2.925
...ays (14)	−0 957	1 693	2 800	3 107	3 671
...ays (8)	−1 650	1 987	2 675	2 975	2.925
...ays (6)	−0 800	1 183	2 817	3 250	3 630
...ays (7)	−2 571	−0 100	1 457	1 729	1 957
...ays (5)	−0 540	0 900	4 020	4 800	4 940
...trol (18)	−3 642	1 176	5 367	5 539	5 472

every measurement the interelectrode voltage was registered and if greater than 2 mV it was balanced to zero

The voltage was registered over the same points previously reported, as indicated in the figures The reference electrode was placed over the proximal epiphysis, and the negative one moved sequentially from proximal to distal over both metaphyses, the proximal diaphysis and on each side of the fracture Once the registration was finished, the periosteum was stripped off and a new series of measurements was made

Thereafter the rats were killed with an overdose of Pentothal and the tibias were dissected free for histological studies The tibias were fixed in 10 per cent buffered formalin phosphate After decalcification and embedding in paraffin, the samples were cut in serial sections at 6 μ and subsequently stained with H E and Van Gieson

The recorded voltage values in mV were subjected to computation to obtain the average values and the standard deviation for each group, and as the groups comprised less than 30 units, Student's test was used to compare data If not otherwise reported in the text, only values of the order of $P < 0.001$ were accepted as significant

RESULTS

The average voltage values of the registrations before removal of periosteum (Series A), the days on which they were recorded, and the number of rats included in each group are shown in Table 1 and are graphically represented in Figure 1 Table 2 and Figure 2 present the average voltage values at the same points and times in the same animals after the periosteum was stripped off (Series B)

We found some characteristics common to both series

(1) During the entire period of the study, from the 1st to the 90th day after fracture, there was a decrease in the registered voltages which was most patent for points 1 to 4 (Figure 1)

(2) Both series, A and B, presented some oscillation of the recorded voltages Series B showed more waves than Series A (Figures 1 and 2)

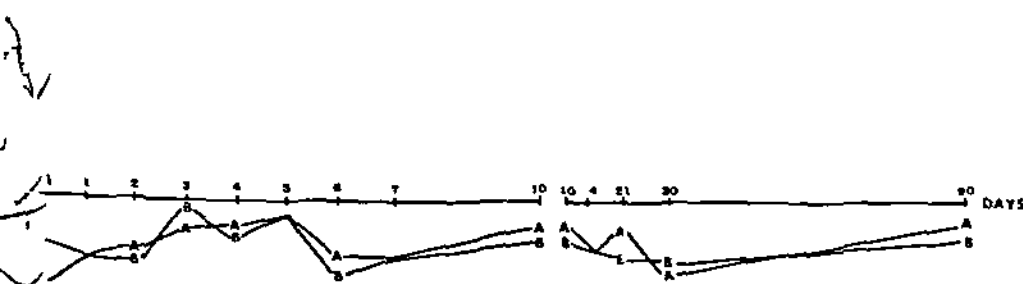
(3) The periosteum had during the earlier phases of repair a clear influence over the registered potentials, especially for [illegible] 3, 4 (Figure 4)

In the following an analysis is made [illegible] evolution with time of the registered [illegible] at the different points, the influence [illegible] periosteum upon them and the [illegible] spatial electric pattern with time


Point 0 In Series A the control [illegible] was significantly different from the [illegible] voltages on days 3, 4, 5, 10 and 21 [illegible] variations between the values recorded [illegible] different days were not significant [illegible] series. In Series B without periosteum [illegible] cant modifications of the registered *compared with the normal values* [illegible] found The periost did not influence [illegible] registered voltage at any stage and [illegible] that the fracture had only a weak effect [illegible] the registered potentials over the metaphysis

Point 1 In Series A, only the [illegible] registered on the first day after [illegible] showed a significant difference [illegible] normal value For Series B, there [illegible] difference between the control [illegible] those registered on days 1, 6 10, 14 [illegible] 30 There was also a clear difference [illegible] the voltage registered on day 6 and [illegible] registered on days 2 and 5 [illegible] decrease in the registered [illegible] statistically significant on day 6 after [illegible] The difference *between* Series A and B [illegible] the periosteum is only significant for [illegible] 5 days and is negligible thereafter

Points 2, 3 and 4 The behaviour [illegible] series was almost the same. The [illegible] significant differences which appeared [illegible] the whole period are shown in Table [illegible] 3 points we found a significant [illegible] between the normal voltage and its [illegible] tion immediately after the fracture [illegible] following days In both series [illegible] metaphysis was the point where the [illegible] influence of the fracture upon the [illegible] registered



3 *Evolution in time of the average values registered at point 0 Difference between Series A periosteum) and Series B (without periosteum)*



ure 4 Point 4 (representative of points 2, 3 and 4) Evolution in time after the fracture of average age values and the influence of the periosteum upon the registered potentials

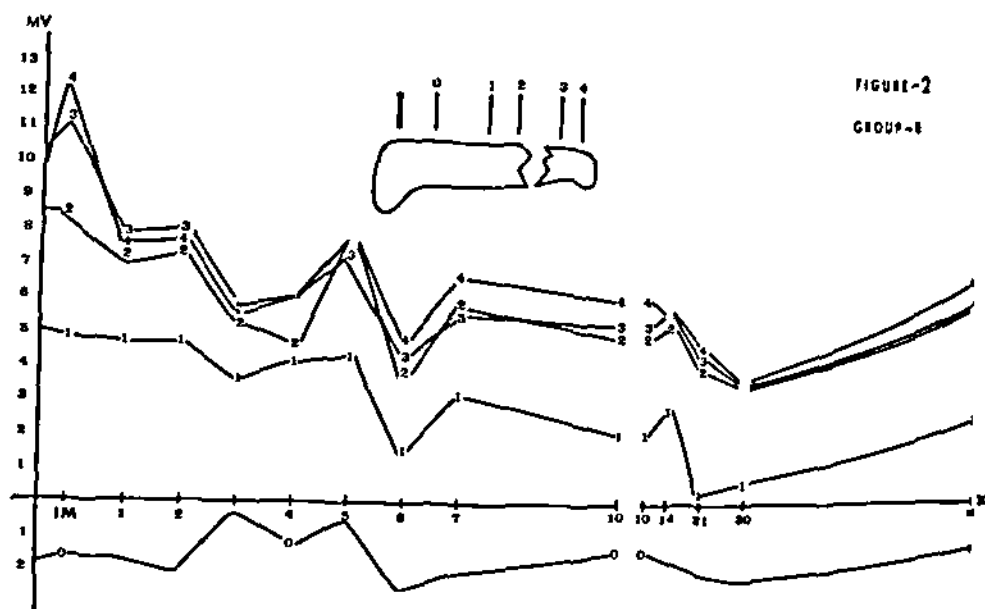


Figure 2 Series B Evolution in time after the fracture of the average voltage values ... points 0 to 4

Table 2 Average voltages at various distances from the proximal epiphysis with ... the fracture, and after periosteal stripping Series B

Time after fracture (no of rats)	Voltage in mV				
	Point				
	0	1	2	3	4
Immediately (21)	−1 675	4 895	8 576	11 362	[illegible]
1 day (11)	−1 725	2 764	6 491	6 036	[illegible]
2 days (12)	−2 162	4 775	7 414	8 075	[illegible]
3 days (8)	−0 225	3 687	5 212	5 775	[illegible]
4 days (7)	−1 760	4 214	4 743	6.043	[illegible]
5 days (10)	−0 533	4 330	7 640	7 410	[illegible]
6 days (12)	−2 733	1 517	3 858	4 392	[illegible]
7 days (10)	−2.144	3 200	5 960	5 690	[illegible]
10 days (14)	−1 421	2.143	5 100	5 267	[illegible]
14 days (8)	−0 075	2 887	5 225	5 762	[illegible]
21 days (6)	−2.180	0 197	4 133	4 366	[illegible]
30 days (7)	−2 414	0 671	3 414	3 500	[illegible]
90 days (5)	−1 500	2.540	6 080	6.080	[illegible]
Control (28)	−1 814	5 086	9 543	10 335	[illegible]

and remained so until the end of the ...owing some oscillations in the early ...f repair

...nberg & Brighton (1966) stated that ... fracture there is an inversion in the ... of the registered potentials with a ...m in the vicinity of the fracture zone ...nd only a decrease in the recorded ... which always remained positive and ...ed a maximum near the fracture ...nlike Friedenberg, a normalization of ...orded potentials was not found even 2 ... after bone healing This discrepancy ... perhaps be explained by the fact ...ur measurements were made over ...um or bone whilst theirs were made ...e skin

...influence of the fracture tended to be ...trated around the fracture area, except ... our study) the proximal metaphysis ... always showed a significant difference ... registered voltages compared with ...collected over the fracture and it was ...ossible to distinguish electrically one ...end from the other The oscillations ...red, especially those of Series A, are ...scent of the voltage distributions ...ed by Becker (1961) and Becker & ...y (1970) in amphibian limb regenera... It is difficult to correlate the decreased ...e and the registered oscillations with ...natomic and functional data in common ...The callus starts immediately after the ...re as a violent cell proliferation over the ... bone and is first restricted to the ...re area 4 days later This could possibly ...in the voltage depression registered on ...day in Series A (Figure 1), especially in ... of the fact that there is a progressive ...from cell proliferation to cell differentia... and vascular penetration during those ... The persistence of a decreased voltage ...e healed fractures could be related to the ...delling process always active after ...ng The oscillations could also be related ...e callus stability, but this is a dynamic ... and the biopotentials described here ... registered on a static unstressed bone ...ne blood flow to the fracture area increases immediately after the f... (Paradies & Kelly 197..) achieving a maximum 10 days later and th... falling to a plateau which is maintained until the 21st day after fracture Friedenberg & Brigh on (1966) suggested that negative voltages correspond to the most vascularized areas of the bone, and accordingly the callus should develop a negative voltage but we found only a decreased positive voltage over the entire tibia with the highest values around the fracture area Digby (1966) considers that positive voltages correspond to centrifugal flow directions and negative voltages to centripetal flow In the early stages of callus formation in displaced fractures of long bones, periosteal flow is greater than that of the medulla, and from the 14th–21st day onwards there is a reversion to predominantly medullary flow This could possibly explain the recorded voltage oscillations. The predominance of the medullary flow over the whole callus from the 14th day postfracture can perhaps explain the reduction of the differentiation effect of the periosteum on the registered voltages Since we have not directly analysed the relation between blood flow and the registered biopotentials, this statement on the relationship between the decrease in intensity and the callus stimulation by electric or magnetic fields remains to be proven

ACKNOWLEDGEMENTS

We wish to express our thanks to Prof A Gallego M D who directed and encouraged us in this work, and to Dr I Reimann for her very valuable advice and critical reading of the manuscript.

REFERENCES

Bassett, C A L., Pawluk, R J & Pilla A A (1974) Acceleration of fracture repair by electromagnetic fields. A surgically noninvasive method *Ann N Y Acad Sci* **238**, 242–263

Becker, R O (1961) The bioelectric factors in amphibian limb regeneration *J Bone Jt Surg* 43-A, 643–656

Becker, R O & Murray, D G (1970) The electrical control system regulating fracture healing in amphibians. *Clin Orthop* **73**, 169–199

Digby, P S B (1966) Mechanics of calcification in mammalian bone *Nature (Lond)* **212**, 1250–1252

Friedenberg, Z B & Brighton, C T (1966) Bioelectric potentials in bone *J Bone Jt Surg* 48-A, 915–923

Fukada, E & Yasuda, I (1957) On the piezoelectric effect of bone *J Phys Soc Jap* **12**, 1158

López Durán Stern, L. & Yageya, J. [illegible] Potenciales oseos, su modificacion en [illegible] fractura *Rev Ortop Traum* [illegible] 235–251

Manabe S, Shima, I & Yamauchi, S [illegible] Cytokinetic analysis of osteogenic cells [illegible] healing process after fracture. *A[illegible] scand* **46**, 161–177

Paradies, G R & Kelly P J (19[illegible]) [illegible] and mineral deposition in [illegible] fractures. *J Bone Jt Surg* 57 [illegible]

Richez, J & Chamay A (1972) Bone [illegible] to pulses of direct microcurrent *[illegible] Arch Path Anat* **357**, 11–18.

Weigert M (1973) Anregung der Knochen[illegible] durch elektrischen Strom. *[illegible] heilkunde* **115**, 1–101

Correspondence to Dr L Lopez-Duran, Catedra 1ª Patologia Quirurgica Prof H. Duran Fr[illegible] Clínico de San Carlos Madrid 3, Spain

...RVATION OF THE WRIST JOINT – AN ...RNATIVE IN CONDITIONS OF CHRONIC PAIN

...ÖSTLUND FINN SOMNIER & RUNE AXELSSON

...artment of Orthopaedic Surgery Central Hospital, Mölndal, Sweden

Nine patients with chronic pain in the wrist secondary to lunatomalacia and non-union of the scaphoid bone were treated by denervation of the wrist joint. This operation was first presented by Wilhelm in 1966. We have been using a modified technique. The purpose of the operation is to achieve relief of pain by selective neurotomy without impairment of hand function and with preservation of wrist mobility. Eight patients were considerably improved, one was not helped at all. No appreciable progression of the pathological changes have occurred radiographically during the period of follow-up. We find our results encouraging and the method worth trying.

Key words: denervation; lunatomalacia; Wilhelm's denervation; wrist joint

Accepted 3.xii.79

...ic pain in the wrist may be very ...ing and frequently presents a difficult ...peutic problem. The pain may be due to ...ry osteoarthritis, non-union of the ...oid or posttraumatic changes following ...res of the distal end of the radius. Other ... may be due to lunatomalacia (Axelsson ...). In most of these cases there is no ...l therapy. The surgical procedures ...h may be employed are merely of a con...ve or symptomatic nature. Arthrodesis of ...wrist is a well-established procedure with ...obvious disadvantage that it results in ... of joint mobility.

...1958 Wilhelm presented a detailed ...omical study of the innervation of the ...t. Eight years later the same author ...ved that effective relief of pain could be ...ered by selective neurotomy of sensorial ...e branches to the joint capsule without ... impairment of hand function and with preservation of wrist mobility (Wilhelm 19 8, 1966).

At the Department of Orthopaedic Surgery Mölndal Central Hospital, this method has been used in a number of cases, and this paper reports our experience so far.

PATIENTS AND METHODS

Case material

During 197–197 nine patients were operated upon according to the method described below. Age, sex, occupation and diagnosis are presented in Table 1. There were seven cases of lunatomalacia and two cases of non-union of the scaphoid. Symptoms had lasted for an average of 4 years (1.5–10 years). All had pain during manual work and five also pain at rest. Only two showed normal wrist mobility. Two had previously been operated upon but with poor results. In one of these styloidectomy had been performed and in

the other shortening of the radius and tenolysis Eight had been using different kinds of wrist support during heavy work Three of the patients had been taking analgesics continuously It is shown in Table 2 that the patient's absence from work varied greatly One had to change to a lighter job three times The others showed a varying capacity for work One patient attended a psychiatric hospital for a couple of months owing to a mental collapse caused by the constant wrist pain All patients in this study were right-handed

Surgical technique

The operation may be performed in different ways, varying the incisions and extent of denervation Wilhelm recommends preoperative anaesthetic block of the nerve branches that are to be resected We have not done this All patients in this series have been operated upon according to the following modified technique

The operation is performed in a bloodless field and with intravenous regional anaesthesia (IVRA)

1 We begin with a dorso-radial longitudinal curved incision, dissecting down to the dorsal aspect of the radius proximal to the [illegible] radio-ulnar joint. The posterior [illegible] nerve is then located adjacent to the [illegible] about 3 centimetres are resected.
2 A transverse incision is made over the [illegible] styloid process. The volar and dorsal [illegible] of the superficial radial nerve are [illegible] the articular branches are resected.
3 An S-shaped longitudinal incision is [illegible] the volar aspect of the carpus. The [illegible] transverse carpal ligaments are [illegible] retracting the flexor digitorum tendons [illegible] median nerve towards the ulnar side [illegible] border of the pronator quadratus [illegible] located Here the anterior interosseous [illegible] identified and resected for 3 cm.
4 A curved incision is made on the [illegible] of the wrist distal to the head of the [illegible] cutaneous dorsal branch of the ulnar [illegible] identified and the articular [illegible] excised

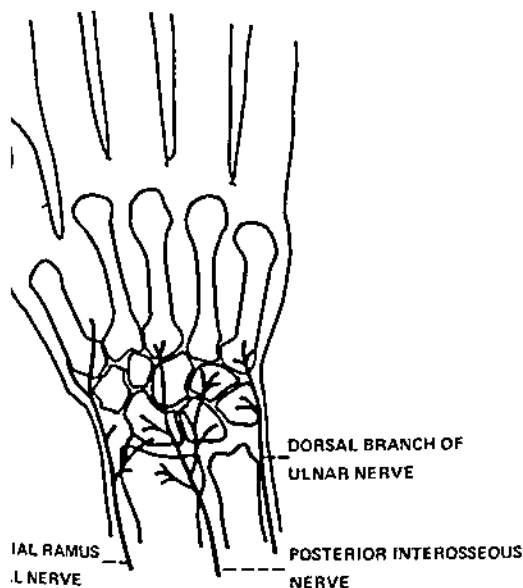
All the cutaneous incisions are closed [illegible] sutures and a dorsal plaster splint is [illegible] resected nerve branches are sent for [illegible] verification

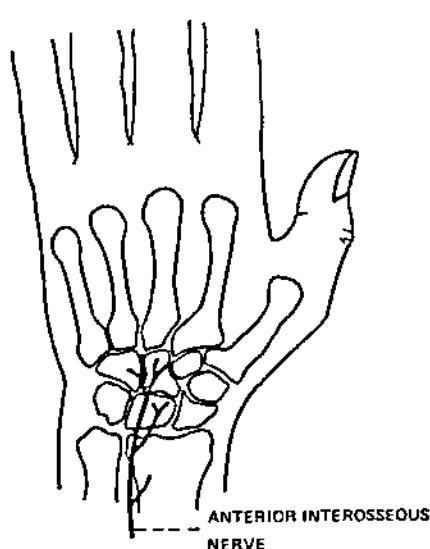
Table 1 Age, sex, occupation and diagnosis

No	Sex	Age (years)	Occupation	Side	Diagnosis
1	F	53	Children's nurse	R	Lunatomalacia
2	M	49	Police inspector	R	Non union of the scapho[illegible]
3	M	55	Cement worker	L	Lunatomalacia
4	M	25	Carpenter	R	Lunatomalacia
5	F	48	Factory worker	L	Lunatomalacia
6	M	42	Fitter	R	Lunatomalacia
7	M	44	B Sc (Econ)	R	Non-union of the scapho[illegible]
8	M	29	Sawmill worker	L	Lunatomalacia
9	M	40	Welder	R	Lunatomalacia

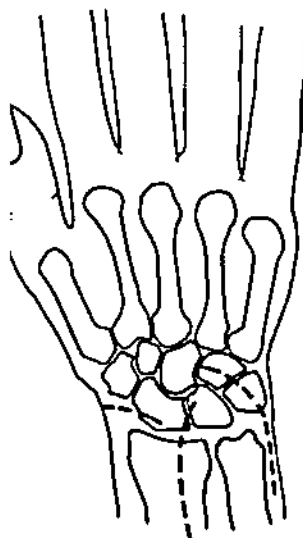
Table 2 Preoperative conditions

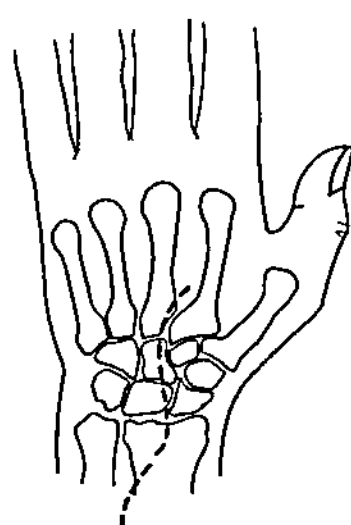
No	Mobility	Pain during work	Pain at rest	Duration of pain (years)	Sick l[illegible]
1	Impaired	Yes	Yes	4–5	0
2	Impaired	Yes	No	10	5 [illegible]
3	Impaired	Yes	Yes	2–3	2 [illegible]
4	Impaired	Yes	Yes	2–3	5 [illegible]
5	Normal	Yes	Yes	2.5	6 [illegible]
6	Normal	Yes	No	1.5	5 [illegible]
7	Impaired	Yes	No	2	0
8	Impaired	Yes	Yes	10	1 [illegible]
9	Impaired	Yes	No	1.5	0





Innervation relevant to the operative procedure





2 Recommended lines of incision

define a denervation of this extent as a total f only the posterior interosseous nerve is d we call it a partial denervation

ires 1 and 2 demonstrate the details of the ation and the incisions.

Postoperative course

Apart from slight superficial infection of the wound in one patient no postoperative complications were seen A plaster splint was worn for

an average period of 3 weeks (Table 3) In one case the splint was worn for a much longer time because previous operations had given poor results and we therefore decided to prolong the immobilization in this patient

Follow up study

The follow-up study was performed at Molndal Central Hospital All patients were examined by two of the authors on the same occasion A detailed analysis of the conditions before and after the operation and a careful clinical examination were carried out The latter consisted of a full neurological and anatomical examination of the upper extremity compared with the healthy side X-ray films were taken of both wrists by the same radiologist and the films were studied jointly by him and the authors

RESULTS

Results are listed in Table 4 One patient with light work went back to work immediately after the operation while another six patients could not return to work until 6–8 weeks after the operation The patient who was splinted for 15 weeks because of previous postoperative difficulties did not return to work until 6 months after the operation Most of the patients considered they had good strength, either normal or improved, in the operated wrist Three reported reduced strength, which they had suffered from even before the operation. Measured objectively a slight or moderate reduction in strength was found in all patients except one who [illegible] strength

All patients were found to [illegible] sensibility and sudomotor [illegible] swelling of the wrist joint was [illegible] patients considered the mobility [illegible] one experienced an improvement [illegible] reduction Objectively an [illegible] noted in four cases, no change in [illegible] reduction in four None of the [illegible] normal range of wrist mobility [illegible] the unaffected joint although, as [illegible] above, some patients subjectively [illegible] had In five patients we found [illegible] during wrist movements.

Eight no longer suffered from [illegible] one complained of slight pain during [illegible] in the weather and in one pain [illegible] changed Eight patients were free [illegible] during normal manual work. [illegible] plained of slight pain during work [illegible] when changes in the weather [illegible] two experienced slight pain [illegible] manual work. In one case the [illegible] changed

Six patients were able to return [illegible] former occupations. Two were [illegible] duties One patient changed to [illegible] occupation, but he had already [illegible] this before the operation

From an overall viewpoint there [illegible] vincing improvement in all cases [illegible] Four patients were very satisfied [illegible] operation four were satisfied and [illegible] satisfied

Table 3 Postoperative course

No	Type of denervation	Time in plaster splint (weeks)	Sick leave
1	Total	3	8 weeks
2	Partial	4	8 weeks
3	Total	2	6 weeks
4	Total	15	6 months
5	Total	3	8 weeks
6	Partial	3	8 weeks
7	Total	3	2 days
8	Total	3–4	Cannot be est[illegible]
9	Total	3	7 weeks

Table 4 Results of the follow-up

No	Interval between operation and follow-up in months	Subjective strength	Objective strength	Pain at rest	Pain during work	Subjective wrist joint mobility	Objective wrist joint mobility	Sensibility
1	14	Slight reduction	Slight reduction	No	Only when change in weather	Normal	Better	Normal
2	19	Good	Slight reduction	No	No	Increased	Better	Normal
3	33	Good	Slight reduction	No	Only when change in weather	Normal	Better	Normal
4	23	Good	Slight reduction	Only when change in weather	Only when change in weather	Normal	Better	Normal
5	37	Good	Normal	No	No	Normal	Reduced	Normal
6	10	Good	Moderate reduction	No	Only during heavy manual work	Normal	Reduced	Normal
7	28	Good	Slight reduction	No	Only during very heavy manual work	Reduced	Reduced	Normal
8	25	Moderate reduction	Slight reduction	Yes	Yes	Normal	Reduced	Normal
9	24	Slight reduction	Slight reduction	No	No	Reduced	Unchanged	Normal

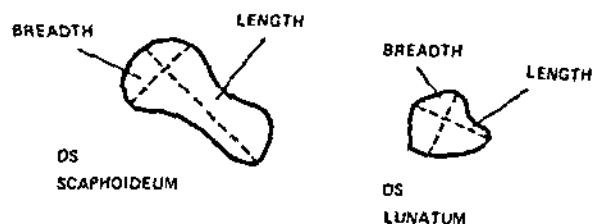


Figure 3 Measurement and calculation of quotient The greatest diameter (length) is multiplied by the greatest perpendicular diameter (breadth)

Radiographs were taken of both wrists The antero-posterior projection was chosen for evaluation because it is more difficult to define the different bones in lateral projections The maximal length and breadth of the affected bone were measured on radiographs taken at the follow-up examination and on preoperative radiographs when available (Figure 3) The following quotient was calculated Length × breadth measured at follow-up divided by length × breadth preoperatively The same quotient was calculated for the healthy wrist joint A quotient of 1 0 thus means that no change in the volume has occurred A quotient <1 indicates a volume reduction Four out of eighteen quotients could not be calculated for technical reasons

The X-ray evaluation showed unaltered conditions apart from insignificant reductions in four cases Thus the denervation did not lead to Charcot-like changes in the joints

DISCUSSION

In 1966 Wilhelm presented his method of denervation which he had performed on 21 patients They had all been tested before operation and according to these tests different nerve branches were resected The average time of follow-up was 16 months He reported good or excellent results in 17 cases Eleven years later Buck-Gramcko (1977) presented a much larger follow-up study consisting of 195 patients operated upon by seven German and Swiss hand surgeons The average follow-up time here was 4[illegible] Preoperative tests were performed [illegible] cases He found 69 per cent of the p[illegible] be practically free of pain Twen[illegible] cent were only slightly improved [illegible] cent were not helped at all [illegible] patients showed evidence of a Char[illegible] The indications for the denervation [illegible] reports were for most of the pa[illegible] same as we used, i e lunatomalacia [illegible] union of the scaphoid bone

As can be seen Wilhelm reported [illegible] percentage of successful cases The [illegible] this may be that Buck-Gramcko de[illegible] with long-term results and some pa[illegible] initially experienced pain rel[illegible] developed a recurrence of pain

In the nine cases presented b[illegible] denervation procedure was simpl[illegible] found it sufficient to resect four nerve b[illegible] out of the 10 capsular branches [illegible] described by Wilhelm With this mod[illegible] the preoperative test is unnecessar[illegible] average follow-up interval was 2[illegible] which is longer than Wilhelm prese[illegible] less than in the report of Buck-Gramcko

Eight patients improved consider[illegible] now have a painless wrist [illegible] preserved mobility under normal co[illegible] Only one was not helped at all This [illegible] compared with Wilhelm who repor[illegible] provement in 17 cases out of 21 a[illegible] Gramcko who found good results [illegible] thirds of his patients

Our material is small but we [illegible] results encouraging and consider the [illegible] well worth trying With our modific[illegible] surgical procedure is simplified [illegible] operation trauma reduced

REFERENCES

Axelsson, R (1971) Treatment of [illegible]
Thesis, Gothenburg
Buck-Gramcko, D (1967) Zur Dener[illegible] Handgelenkes und der [illegible] Finger *Handchirurgie* I, 179-1[illegible]

amcko D (1977) Denervation of the joint. *J Hand Surgery*, **2**, 54–61

A (1958) Innervation der Gelenke der n Extremitat *Z Anat Entwickl -Gesch* 331–371

Wilhelm, A (1966) Die Gelenkdenervation und Ihre anatomischen Grundlagen. Ein neues Behandlungsprinzip in der Handchirurgie *Hefte Unfallheilkd* **86**, 1–109

ndence to Tord Rostlund, M D , Department of Orthopaedic Surgery Molndal Hospital P O S-431 22 Molndal, Sweden

thop scand. 51, 617–620 1980

IE SCANNING IN LUMBAR DISC HERNIATION

PETER JOHANSEN JOHANNES FOSSGREEN
NS HVID HANSEN*

tment of Physical Medicine and Rheumatology, Amtssygehus (University Hospital), and
artment of Nuclear Medicine, Kommunehospital (University Hospital) Aarhus, Denmark

99m technetium methylene diphosphate was used for whole body scanning and linear multiplane tomoscanning in 10 patients with typical clinical symptoms of prolapsed disc, in order to investigate whether there would be an increased focal accumulation corresponding to the bone structures adjacent to the affected disc.

The diagnosis of a prolapsed disc was confirmed by amipaque myelography, carried out in 9 patients, and finally verified at operation.

In none of the 10 cases could accumulation of radioactivity in the bony structures of the affected lumbar segment be demonstrated Consequently this method has not been adopted for the diagnosis of prolapsed lumbar discs.

However it was demonstrated that 99m technetium methylene diphosphate scintillography is useful in the differential diagnosis of anchylosing spondylitis and discitis.

Key words disc herniation, lumbar spine, multiplane tomoscanning technetium 99 whole body scanning

Accepted 4.xii 79

well known that inflammatory conditions one and joints result in an increased mulation of 99m technetium methylene osphonic acid (MDP) (Handmaker & nards 1976, Merrick 1975) and it has also established that an accumulation of rity may be found together with signs of neration in the spine (Berghs et al 1978, dberg & Loken 1974, Johannsen et al. 3)

y using multiplane tomography it should possible to produce a series of tomograms arying depths from the surface in order to ain more accurate diagnostic information Rae & Anger 1974)

Vorking on the assumption that enerative and possibly inflammatory nges in the involved disc and adjacent ebral bodies are part of the pathogenesis of the prolapsed vertebral disc, we investigated whether with the aid of this method we could show increased focal accumulation corresponding to the bony structures adjacent to the affected disc.

PATIENTS AND METHODS

The investigation involved 10 patients with typical clinical symptoms of a prolapsed lumbar disc.

Amipaque myelography, 99m Tc MDP linear scintillography and whole body scans were carried out.

In addition to these 10 patients, 15 patients were examined There were three with symptoms of prolapsed lumbar disc who had not undergone surgery, two with disc degeneration, defined as radiologically proven narrowing of the disc space,

1 6470.80.040617-04 $

Figure 1 A 33 year old man with pro L4/L5 a Myelography b Whole bo gram c Linear tomoscannogram



three with clinical and radiological discitis, three with clinically and rad proven anchylosing spondylitis, one with pain without signs of root compression, signs of prolapsed disc but the scintigr insufficient and two patients with osteo

99^m Tc MDP (kit from the Radi Centre Ltd, Amersham) on averag (17 9–21 0) was given intravenously The later tomoscannograms were carried o depth of 3 cm, 6 cm and 9 cm, mea measured over the lumbar spine from L1 scintimate 2F linear scanner was used whole body scannograms were obtained Pho/gamma scintillation camera.

Both linear scintillograms and whole scannograms were interpreted by one authors without prior knowledge of the history or the diagnosis.

RESULTS

The patients involved are two wo eight men between 29 and 53 years with surgically proven prolapsed lumb

f the 10 patients had, prior to surgery, graphically proven prolapsed lumbar n the remaining patient myelography ot indicated because the level of the was obvious clinically

the patients had had an X-ray of the r spine and 50 per cent showed ving of the involved disc space in- ng disc degeneration

results of a typical case showing graphy, whole body scanning and linear ing are illustrated in Figure 1a, b, c In on three patients with clinical toms of herniated lumbar disc were ined, none of them showed llographic accumulation

comparison the three patients with al and radiological signs of discitis were ined Very prominent pathological nulation corresponding to the affected and the adjacent bony structures was l in all three (Figure 2)

ne patients with active anchylosing dylitis showed pathological accumulation sponding to several intervertebral spaces vertebral bodies, in addition to the typical ological accumulation found in the area of acro-iliac joints (Figure 3)

CUSSION AND CONCLUSION

nany instances localization of the level of olapsed lumbar disc is problematical and rent methods have developed in an mpt to improve the diagnostic accuracy ly examination, including tomography, been shown to be inadequate (Magora & wartz 1976, Schalimtzek 1958) mography, epidural venography and dis- raphy signify progress but are not ciently accurate and/or give rise to nificant side-effects (Drasin et al 1976 gora & Schwartz 1976 Masare 1976, kin et al 1976)

Myelography is associated with a number subjective discomforts and side-effects so t a less taxing and an equally precise method of examination is required (Ratjen 1977, Shapiro 1962, Spangfort 1972)

The question we posed was whether bone scintillography could be used in place of myelography for localizing the level of a prolapsed lumbar disc. Our investigation proved to the contrary



Figure 2 Linear tomoscannogram of a 49-year-old woman with discitis L4/L5



Figure 3 Linear tomoscannogram of a 25 year-old man with anchylosing spondylitis

Scintillography can, however, contribute to the differential diagnosis when patients present with pain in the lumbar spine In inflammatory conditions such as discitis and anchylosing spondylitis there is pathological accumulation of 99^m Tc MDP. The same has been demonstrated in numerous examinations of neoplastic conditions of the spine However, with a prolapsed lumbar disc a positive scintillogram cannot be expected

ACKNOWLEDGMENT

We would like to thank the Neurosurgical Department and E Ratjen, M D, Department of Neuroradiology, Kommunehospital (University Hospital), Aarhus.

REFERENCES

Berghs, H, Remans, J, Drieskens, L, Kiebooms L & Polderman, J (1978) Diagnostic value of sacroiliac joint scintigraphy with 99^m technetium pyrophosphate in sacroiliitis *Ann rheum Dis* 37, 190–194

Drasin, G F, Daffner, R H, Sexton, R F & Cheatham, W (1976) Epidural venography diagnosis of herniated lumbar intervertebral disc and other disease of the [illegible] *Amer J Roentgenol* 128, [illegible]

Goldberg, H E & Loken, M K [illegible] varied usefulness of bone [illegible] 109, 65–72

Handmaker, H & Leonards, R [illegible] scan in inflammatory osseous [illegible] *Nucl Med* 6, 95–105

Johannsen, A., Jepsen, O L & [illegible] Radiological and scintigraphical [illegible] the sacroiliac joints in the [illegible] sacroiliitis. *Danish med. Bull* 21, [illegible]

Magora, A & Schwartz A [illegible] between the low back pain [illegible] ray findings. *Scand. J* [illegible] 115–125

Massare, C. (1976) Die lumbale [illegible] *Röntgen Bl.* 29, 184–192

McRae, J & Anger, H O [illegible] with the multiplane tomograph (Abstr) *Nucl. Med.* 15, 516

Merrick, M V (1975) Bone scanning *Radiol* 48, 327–351

Raskin, M M., Martinez Lopez, M & [illegible] J (1976) Lumbar thermography in [illegible] disease *Radiology* 119, 149–152

Ratjen, E. (1977) Kontrastundersøgelse spinalkanalen. Personal Communication

Schalimtzek, M (1959) *Den* [illegible] *funktionsundersøgelse af* [illegible] Universitetsforlaget, Aarhus

Shapiro, R. (1962) *Myelography* [illegible] Medical Publishers, Chicago

Spangfort, E V (1972) The lumbar disc [illegible] *Acta orthop scand* Suppl 142

Correspondence to Dr Johannes Fossgreen, Department of Physical Medicine and Rheumatology, Aarhus Amtssygehus (University Hospital) 8000 Aarhus C, Denmark

thop scand 51, 621–624, 1980

ATERAL FEMORAL NECK FRACTURES AS A MPLICATION OF MYELOGRAPHY

M TAMINIAU & T. J J H SLOOFF

tment of Orthopaedics, University Hospital, Nijmegen, The Netherlands

This paper discusses two cases of bilateral subcapital fracture of the proximal femur as a complication of myelography with Conray 60 The literature is reviewed

Key words arthroplasty, fractures, myelography

Accepted 11 xi 79

myelography with water-soluble radio- ie substances such as sodium monoiodo- honates (Abrodil, methiodal sodium, trast U), the toxic properties of these tances can cause side-effects of varying nsity (Praestholm 1979, Penning 1970, isette 1971, Hugander 1974) Less toxic stances such as meglumine iodothalamate nray 60) and meglumine iocarmate (Dimer also have side-effects, but less frequently nsette 1971, Skalpe 1971, Morrey 1977)

These side-effects can be subdivided into e groups meningeal reactions, radicular nptoms and hyperexcitation phenomena onsette 1971) The latter group includes smodic contractions, convulsions and leptic seizures, which according to the rature occur in 8 to 19 per cent of cases r lumbar myelography with the above- ntioned substances (Hurteau 1954, Ahlgren 69, Penning 1970, Skalpe 1971, Morrey 77)

That these muscle spasms can cause severe mplications is illustrated by the following o case reports

SE REPORTS

tient A

37-year-old woman who 1 year previously had n operated on for lumbar disc herniation was admitted for lumbar myelography Persistent low back pain had long confined the patient to bed

Finally she was admitted for further evaluation on the suspicion of a radicular syndrome

Without premedication myelography was performed, using 6 ml Conray 60 diluted with 4 ml CSF The radiopaque substance was allowed to flow no higher than level T12–L1 A possible disc hernia was seen at level L4–5 After myelography the patient was returned to her room and placed prone in bed. One hour later she suddenly developed severe muscle spasms in both legs, and heard a snapping noise, after which pain developed in both inguinal regions, radiating down into both legs. During these severe tonic spasms, causing flexion of the spine and hips, she received no medication In view of the persistent pain, a radiological examination was made which revealed bilateral medial femoral neck fracture

The neck fractures were treated by osteosynthesis using Smith Petersen nails. Several years later bilateral femoral head necrosis developed, for which she was treated by total hip arthroplasty (Figure 1)

Patient B

A 40-year-old athletic man, complaining of low back pain for the past 9 years, was treated on suspicion of lumbar disc herniation by complete bed-rest for a period of 6 weeks.

Because of persistent pain he was hospitalized for myelography Before the examination, 20 ml Valium (diazepam) was given i m as premedication. The myelography was performed using 4 ml Conray 60 and 8 ml CSF and revealed an impression at level L4–L5, typical of a disc herniation

1–6470 80 040621 04 $02 50 0




Figure 1 Both hips of patient A, shown successively after the accident, after osteosynthesis and after removal of the Smith-Petersen nails



Figure 2 Both hips of patient B [illegible] successively after the accident [illegible] synthesis and after arthroplasties.

The level of contrast medium extended to L1 The patient was then returned to his room and kept in a sitting position for 12 hours, whereupon he received a second dose of 20 mg Valium i v

About 4 to 5 hours after myelography he suddenly developed myoclonic spasms in both legs, followed by extreme flexion in both hips Administration of 10 mg Valium i v reduced the myoclonic spasms The next day he complained of bilateral inguinal pain, which seemed maximal during movements of the hip A striking sign was lateral of both legs X-ray examination of the pelvis revealed bilateral femoral neck fractures

Reposition of the fractures was followed by fixation with Smith-Petersen nails In the course of time the patient developed necrosis of the left and pseudarthrosis of the right hip, necessitating total hip arthroplasties (Figure 2)

DISCUSSION

Both case reports demonstrate that myoclonic spasms after myelography can lead to severe complications In both cases bilateral femoral neck fracture of the medial type (Garden [illegible]) was observed, leading to avascular [illegible] and pseudarthrosis. In the literature [illegible] six cases of fracture after myelography [illegible] three patients the examination had [illegible] performed with Conray 60, and D[illegible] been used in the other three cases. [illegible] fracture of the femoral neck was [illegible] three cases, a unilateral fracture in [illegible] fracture of the pelvis in one case

Penning (1970) suggested that [illegible] tion of these myoclonic tonic spasms [illegible] be sought in contact between the [illegible] medium and the conus medullaris [illegible] irritation of the efferent [illegible] regulates muscle tone To avoid this [illegible] it is advisable to have the patient [illegible] straight for 5 to 8 hours after the [illegible] tion During this period there should [illegible] complete absorption of the [illegible] substance from the subarachnoid [illegible] also advisable to inject [illegible]

pam) i v before administering the aque substance

Data from the literature show that of above-mentioned six patients one was d horizontally two in a sitting position n three in an unspecified position after graphy Only three of these patients ed premedication before myelography patients received Valium and one was phenobarbital The literature offers the ing advice for myelography

emedication with Valium i v

e quantity of radiopaque substance must t exceed 5 ml,

possible the radiopaque substance ould not reach level L2–3

r a period of 5–8 hours after the examination the patient should sit up raight

the case of excitation symptoms –40 mg Valium should be injected i v

e patient should be under observation r 24 hours

MENTS

ust be emphasized that the level attained he radiopaque substance seems to be of t importance for the development of clonic spasms When during myelohy the radiopaque substance extends too contact between the conus and the tance presumably occurs

is advisable to administer Valium proactically in a dose of 10 to 40 mg i v even though Valium has not appeared to be 100 per cent effective Lumbar puncture may also be considered in order to reduce the quantity of radiopaque substance used

It should be noted that Conray 60 and Dimer X are no longer used for myelography in our hospital We are currently using metrizamide (Amipac) which reportedly has a lower incidence of neurotoxicity Time will tell

REFERENCES

Ahlgren P (1969) Lumbale Myelographie mit Conray Meglumin 282. *Fortschr Rontgenstr* **111**, 270–276

Gonsette R (1971) An experimental and clinical assessment of water soluble contrast medium in neuroradiology a new medium – Dimer – *Clin. Radiol* **22**, 44–56

Hugander A (1974) Fractures caused by muscle traction following lumbar myelography with *meglumine iothalamate (Conray 60) and* meglumine iocarmate (Dimer X) *Z Rechtsmedizin* **75**, 219 224

Hurteau E E (1954) Arachnoiditis following the use of iodized oil. *J Bone Jt Surg* **36 A** 213–219

Morrey B F (1977) Femoral neck fractures following water soluble myelography induced spinal seizures *J Bone Jt Surg* **59-A**, 393–400

Praestholm, J (1970) Water-soluble contrast lumbar myelography with meglumine iothalamate (Conray) *Brit J Radiol* **43**, 303 308

Penning L. (1970) Caudagrafie met methyl glucamine-jothalamaat *Ned T Geneesk* **114**, 861–862.

Skalpe I (1971) Lumbar myelography with Conray Meglumin 282. *Acta neurol. scand* **47**, 569 578

espondence to Prof Dr T J J H Slooff Orthopaedic Department Radboud Hospital, Th. nenlaan 7 Nijmegen The Netherlands.

rthop scand 51 625–632, 1980

CHANICAL STRENGTH OF SLIDING
{EW-PLATE HIP IMPLANTS

omechanical Study of Unstable hanteric Fractures VI

'EEN JENSEN

echanics Laboratory, Department of Orthopaedic Surgery T-2
ofte Hospital, Hellerup, Denmark

Static load testing of sliding screw-plate hip implants manufactured from
... was
... escop-
...
... n and
Jewett hip implants superior yield loads were determined for both implant angles
Calculations were made of the improvement of implant strength due to
...

Key words biomechanics femoral neck fractures fracture fixation, stress, mechanical

Accepted 3 xi 79

ing recent years numerous papers have mmended the sliding screw-plate for rnal fixation of unstable trochanteric tures, as the number of technical failures been reduced considerably with the use of method in spite of a policy of early ɔilization with full weight bearing (Ecker et 975, Jacobs et al 1976, Jensen et al 1978, lholland et al 1972, Parker & Reitman 6)

n recently published studies the author analysed the modes of failure of Jewett McLaughlin hip implants manufactured n Cobalt-Chromium-Molybdenum alloy or n 316 LVM stainless steel (Jensen 1980 ı and focused on the failure loads, which 'e found to be less than the hip joint load ing one-legged stance or normal level king

The purpose of the present study was to perform a comparable analysis of sliding screw-plate hip implants manufactured from the same metals and compare the results with those obtained in the former series (Jensen 1980 a b)

MATERIALS AND METHODS

The experiments were performed on sliding screw-plates manufactured from Cobalt-Chromium-Molybdenum alloy (Catalogue numbers 6447 6449–5–XXX, Howmedica Inc) or from 316 LVM stainless steel (Catalogue numbers 1131–01,02–XX, Zimmer-USA International) as shown in Figure 1

In order to achieve results which can be compared with those of former series (Jensen 1980 a b) the moment arm about the intersection

1 6470 80 040625 09 $02.50 0




Figure 1 Sliding screw-plate implants manufactured from Cobalt-Chromium-Molybdenum alloy (left) or 316 LVM stainless steel (right)

between the back of the plate and the centre line of the screw was kept at 41 4 mm corresponding to a screw length of 74 0 mm in implants with a 135° angle and to 127 0 mm in the 150° implants. Five experiments were performed for each series of 135° implants with 2 5" screws and 150° implants with 4 5" screws mounted in 3-hole plates

The telescoping effect of the implants was eliminated by gluing the screw to the barrel with a slightly expanding 2-component polyurethane glue (Foss Than 2K 2350, Sadofoss, Denmark), which did not apply any additional bending strength During the assembling process care was taken to ensure that the screw length was exact

The difference between the two types of implants, apart from the metal is that the screw manufactured from Cobalt-Chromium-Molybdenum alloy is hexagonal with a diameter of about 9 mm and the rotational stability of the implant is ensured by a stud on the lower medial part of the barrel The screw in the 316 LVM stainless steel modification has a circular cross section measuring 9 mm and a distally placed, longitudinal slot fitting with a tap in the barrel for rotational stability

Strain gauges (QFLA 3 TML, [illegible] attached to the implants at three [illegible] screw 3 mm from the medial edge of the [illegible] the barrel 20 mm from the lateral border [illegible] the plate just distal to the counter-bore [illegible] for operation tools.

Static mechanical load testing was [illegible] on the implants mounted at an inclination [illegible] to the vertical with simultaneous [illegible] applied load the deflection of the [illegible] elongation of the moment arm and the [illegible] strain as measured by the above-mentioned gauges

A detailed description of the [illegible] arrangement has been presented in a [illegible] paper (Jensen 1980 a). Also included [illegible] previous publication are equations for the [illegible] tion (a) of the bending moments about [illegible] gauge centre on the screw and the barrel [illegible] of the varus angulation of the implants

The yield points, where the metal [illegible] permanent plastic deformation, were [illegible] as the points on the graphs where the [illegible] is transformed into a curved line

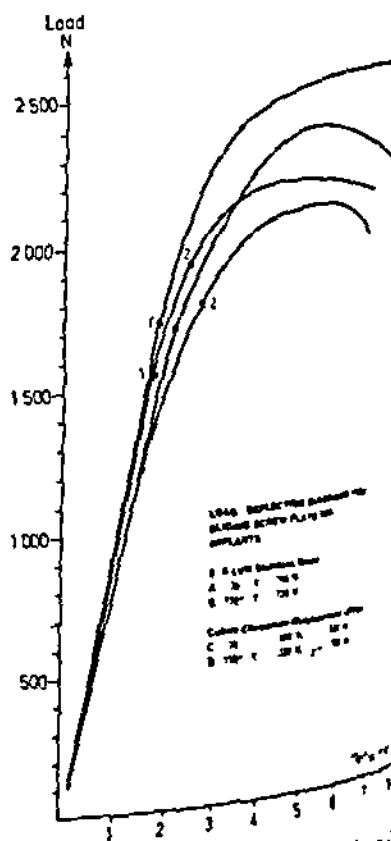


Figure 2 Load deflection [illegible] screw-plate hip implants

JLTS

load deflection diagrams for the sliding plate hip implants are demonstrated in e 2 It is seen that two yield points determined in implants manufactured Cobalt-Chromium Molybdenum alloy as the 316 LVM stainless steel implants nted only one yield point

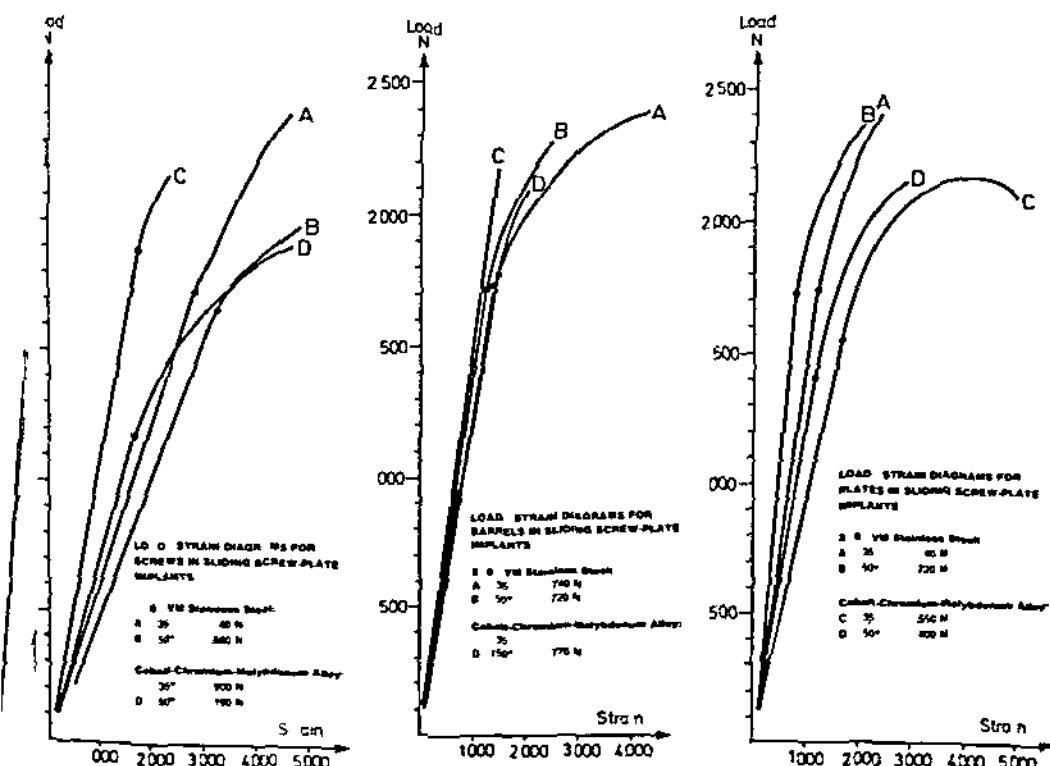
Figures 3 4 and 5 the load strain ams for the screws the barrels and the s are demonstrated

was found that the single yield point mined for the 316 LVM stainless steel ants corresponded to a permanent plastic mation arising simultaneously for all components of the implant The yield t was found to be 1 740 N for the 135° w plate and 1 720 N for the 150° screw

For the Cobalt Chromium Molybdenum alloy implants bending of the screw was observed at 1 930 N in the 135° implant corresponding to the highest yield point while the plate bent at a load of 1 550 N and the barrel did not show any sign of bending Correspondingly the screw and the plate of the 150° implants bent simultaneously at a load of 1 220 N while the barrel bent at a load of 1 790 N Bending of the screw was with both implant angles encountered at surface strains of about 1 750 μr while bending of the plate was encountered at the level of the supporting steel bar 25 mm distal to the intersection between the centre line of the screw and the back of the plate

For both types of metals the implants with a 135° angle were the strongest

The varus angulation of the implants at the yield points encountered are listed in Table 1



ures 3 4 and 5 Load strain diagrams for screws barrels and plates of sliding screw-plate hip plants

Table 1 Calculations of the varus angulation in hip implants during mechanical [illegible]

Screw-plate angle degrees	β degrees	Deflection e_1 mm	β_1 degrees	Varus angulation $\beta-\beta_1$	Deflection e_2 mm	β_2 degrees	[illegible]
135° – Co-Cr-Mo	56°	1 65	53 8°	2 2°	2.40	52.8°	[illegible]
135° – 316 LVM	56°	1 85	53 5°	2 5°			
150° – Co-Cr-Mo	71°	1 50	69 0°	2 0°	2.75	67.5°	[illegible]
150° – 316 LVM	71°	2 15	68 2°	2 8°			

β = Nail plate angle – 79°
$\sin\beta_x = \sin\beta - \frac{e}{L_N}$

It is seen that varus angulations of about 2–3° corresponded to permanent deformations of the implants, as it has also been experienced with the Jewett and McLaughlin implants (Jensen 1980 a,b)

The bending moments about the strain gauge centre on the screws are listed in Table 2 It is demonstrated that the bending moments applied for bending of the screw were higher for 135° implants made from Cobalt-Chromium-Molybdenum alloy, whereas the highest bending moment applied to 150° implants was in the stainless steel modification For the 135° implants the bending moments were thus 44–49 Nm, which is about double the 22–29 Nm for McLaughlin nail plates and about one third more than the strongest Cobalt-Chromium-Molybdenum alloy Jewett implants (Jensen 1980 a,b)

In the present series the telescoping [illegible] of the sliding screw-plate implants [illegible] locked, and the holding capacity of the [illegible] was not exceeded in any case In the [illegible] situation, however, telescoping of [illegible] implants is experienced Assuming the [illegible] calculated bending moments [illegible] pond to bending of the implants [illegible] similar varus angulation in the [illegible] modifications, further calculations [illegible] made on the effect of a telescoping of [illegible] and 20 mm, respectively, as listed in Ta[illegible] It is thus seen that a telescoping of [illegible] improves the actual strength of the [illegible] by about 28 per cent in the 135° [illegible] and by about 11 per cent in the [illegible] implants compared with the exp[illegible] results A telescoping of 20 mm [illegible] load bearing capacity of the 135° [illegible]

Table 2 Calculated bending moments about the strain gauge centre on the screws in [illegible] hip implants

Screw-plate angle degrees	Elongation of moment arm ΔM A mm	Reduction of moment arm X mm	Yield load J N	[illegible]
135° – Co-Cr-Mo	2 93	19 04	1 930	[illegible]
135° – 316 LVM	0 39	16 50	1,740	[illegible]
150° – Co-Cr-Mo	2 25	10 56	1,220	[illegible]
150° – 316 LVM	0 50	9 65	1,720	[illegible]

$M_B = J \times (M A + \Delta M A - X)$
X is calculated from the position of the intersection of the centre line of the screw and the [illegible] plate in relation to the length of the barrel and $\alpha = 169°$ – screw-plate angle

– 3 *Calculations of yield loads of screw corresponding to reduced moment arms after telescoping of implants*

plate 's	Bending moment about strain gauge	Telescoping = 10 mm Moment arm $(L_N-10)\sin\alpha$	Calculated load $\frac{M_B}{MA_1+\Delta MA-X}$	Telescoping – 20 mm Moment arm $(L_N-20)\sin\alpha$	Calculated load $\frac{M_B}{MA_1+\Delta MA-X}$
	Nm	mm	N	mm	N
- Co-Cr Mo	48 7	35 8	2,479	30 2	3,464
- 316 LVM	43 9	35 8	2 235	30 2	3 124
- Co-Cr Mo	40 3	38 1	1,354	34 8	1,519
- 316 LVM	55 4	38 1	1,914	34 8	2,156

80 per cent and the 150° implants by 25 per cent The yield loads thus ated for the 135° implants correspond ?–4 1 times the body weight of a 60 kg n after a telescoping of 10 mm and to 8 times the body weight after a oping of 20 mm

:USSION

rent types of sliding implants have been luced for the treatment of hip fractures sie 1962, 1964, Pugh 1955, Schumpelich ntzen 1955), but the most widely used oping implant in Western Europe is the g screw-plate, originally described by son (1964) and subsequently proven to nically efficient Hence it was decided to rm biomechanical studies on this type mplant, made of Cobalt-Chromium-bdenum alloy or 316 LVM stainless as the results could be compared with Jewett and McLaughlin implants tested rly (Jensen 1980 a b)

cording to Jergesen (1964) internal on of fractures always implies very small ments at the fracture site, which might ause any macroscopic displacement but lead to fatigue fracture of the implant inaro et al 1977) In the case of unstable anteric fractures the mechanical weight mission over the fracture site is unble, because an exact reduction of the fracture can not be obtained (Clawson 1957, Johnston 1973, Kennedy et al 1957, Kumar 1973) This leads to repeated, high stresses on the implant and may give rise to fatigue fracture of the implants, it also involves a risk of implant breakage following sudden stress of high magnitude (Bechtol & Murphy 1952)

Biomechanical studies of sliding screw-plates have been performed on a model of unstable, 4-fragmentary trochanteric fractures with different modifications of reduction and fixation by hip implants (Kaufer et al 1974, Sonstegard et al 1974) In these experiments, however, the possible movement of the implant within the femoral head as well as the holding power of the screws in the femoral shaft could not be considered and consequently only the ultimate compressive strength of the implants was reported It is, however, more important to define the yield point where permanent plastic deformation begins, as considerable bending can take place before the ultimate strength of the implant is exceeded (Brettle et al 1971, Dumbleton & Black 1977) and thereby result in dislocation of an internally fixed fracture

Compared with the studies mentioned (Kaufer et al 1974, Sonstegard et al 1974) however, the results obtained in the present series were quite similar for stainless steel implants with a 135° angle

In the 316 LVM stainless steel implants all three parts of the implant, i e the screw, barrel and plate bent simultaneously at loads

of about 2 9 times the body weight of a 60 kg person This means that the implants can accurately resist the lowest hip joint load during level walking, as reported by Paul (1976) and Rydell (1966), and are thus found to be suitable for the internal fixation of unstable trochanteric fractures where no reliable bony support is obtained The internal fixation of these fractures does, however, not only concern the mechanical strength of the implant but also the degree of osteoporosis of the femoral neck and head A high strength implant may lead to an increased number of cuttings or penetrations through the mechanically weak bone The main advantage of the sliding implants is the ability of the screw to telescope when the fractured bone ends tend to impact as a result of muscular tension and weight-bearing Thus a stable load transmission system is created through bony contact The telescoping of the screw not only prevents perforation of the bone, but also improves the weight bearing capacity of the implant by a reduction of the moment arm For the 135° implants manufactured from either of the metals a telescoping of 10 mm thus increased the weight-bearing capacity to 3 7–4 1 times the body weight of a 60 kg person and a telescoping of 20 mm to 5 2–5 8 times the body weight, which is above the hip joint load calculated for normal level walking

In the tests on the implants manufactured from Cobalt Chromium-Molybdenum alloy two yield points were encountered For the 135° implant the lowest yield point in the experiments was caused by bending of the plate at the level of the supporting steel bar In a clinical situation, however, the plate is supported by cortical bone up to the junction with the screw and this yield point is therefore considered of less importance The 135° implant is thus strong enough for the internal fixation of unstable trochanteric fractures. The lowest yield point in the 150° implants is, however, caused by bending of not only the plate, but also the screw at loads of about 1,220 N, which is comparable with the results obtained at mechanical testing of 125° and 135° Jewett hip nail-plates [illegible] 1980 a) The yield loads presented [illegible] equal about twice the body weight of a [illegible] person and consequently can [illegible] recommended for the internal fixation [illegible] unstable trochanteric fractures [illegible] early weight bearing mobilization. [illegible]ing of 10 or 20 mm respectively [illegible] improve the weight bearing capacity [illegible] sliding screw plate implant by 11 and [illegible] cent, but it is still less than 25 [illegible] body weight As seen from the results [illegible] even the 150° sliding [illegible] manufactured from 316 LVM stainless [illegible] is of doubtful reliability as [illegible] improves the weight bearing capacity [illegible] only 3 2–3 6 times the body weight

However compared with the [illegible] obtained at the mechanical testing of [illegible] and McLaughlin implants (Jensen [illegible] sliding screw plate implants are [illegible] superior and should be recommended for fixation of unstable trochanteric fractures although the best solution from a mechanical point of view is a 135 [illegible] made from either of the metals [illegible] purpose

ACKNOWLEDGEMENTS

Gratitude is expressed to Conrad [illegible] Eng, Copenhagen Engineering College [illegible] valuable help The study was kindly [illegible] the Danish Medical Research Council [illegible] 512–6595 and the Medical Research Fund for Copenhagen Grant N 75 [illegible] were supplied by Howmedica International [illegible] Limerick Ireland Zimmer-USA [illegible] Warsaw Indiana N C Nielsen Ltd [illegible] and Simonsen & Weel Ltd, Denmark [illegible] was supplied by Sadoloss Ltd, Denmark

REFERENCES

Bechtol C. O & Murphy E F ([illegible] clinical applications of engineering [illegible] the problems of fractures and [illegible] *Amer Acad Orthop Surg* [illegible] *Course Lectures* 9, 272–2[illegible]

le, J, Hughes, A N & Jordan, BA (1971) allurgical aspects of surgical implant erials. *Injury* 2, 225–234

n, D K (1957) Intertrochanteric fractures ie hip *Amer J Surg* 93, 580–587

n, D K. (1964) Trochanteric fractures ted by the sliding screw plant fixation hod *J Trauma* 4, 737–752

ston, J H & Black, J (1977) *An introduc to orthopaedic materials* C. C Thomas, ngfield, Illinois

M L., Joyce III, J J & Kohl, E J (1975) treatment of trochanteric hip fractures g a compression screw *J Bone Jt Surg* A, 23–27

ro, P, Crova, M & Calderale, P M (1977) mechanical failure in osteosynthesis *Ital J hop Traum* 3, 321–332

R R, Armstrong, J., Whitaker, J H & ell, J (1976) Treatment of inter- hanteric hip fractures with a compression screw and a nail plate *J Trauma* 16, –603

J Steen, Tøndevold, E & Mossing, N 78) Unstable trochanteric fractures treated h the sliding screw-plate system *Acta hop scand* 49, 392–397

J Steen (1980a) Mechanical strength of ett and McLaughlin hip nail plates nufactured from Cobalt-Chromium lybdenum alloy *Acta orthop scand* 51, –156

J Steen (1980 b) Mechanical strength of Laughlin hip nail plates manufactured from LVM stainless steel *Acta orthop scand* , 439–444

en F (1964) Metallic surgical implants. *J ne Jt Surg* 46-A, 401–408

ton, R C (1973) Mechanical considerations the hip joint *Arch Surg* 107, 411–417

Kaufer, H, Matthews, L S & Sonstegard, D (1974) Stable fixation of intertrochanteric fractures. *J Bone Jt Surg* 56-A, 899–907

Kennedy, J C, McFarlane, R M & McLachlin, A D (1957) The Moe plate in inter- trochanteric fractures of the femur *J Bone Jt Surg* 39-B, 451–457

Kumar, V (1973) The syndrome of the lesser trochanter in adults. *Injury* 4, 327–334

Massie, W K (1962) Extracapsular fractures of the hip treated by impaction using a sliding nail-plate fixation *Clin Orthop* 22, 180–201

Massie, W K. (1964) Fractures of the hip *J Bone Jt Surg* 46-A, 658–690

Mulholland, R. C & Gunn, D R (1972) Sliding screw plate fixation of intertrochanteric femoral fractures. *J Trauma* 12, 581–591

Parker, H G & Reitman, H K (1976) Changing patterns in fracture management emphasizing early motion and function. *Surg Clin N Amer* 56, 667–672

Paul, J P (1976) Force actions transmitted by joints in the human body *Proc roy Soc B* 192, 163–172.

Pugh, W L (1955) A self-adjusting nail-plate for fractures about the hip joint *J Bone Jt Surg* 37-A, 1085–1093

Rydell, N W (1966) Forces acting on the femoral head prosthesis. *Acta orthop scand*, Suppl. 88

Schumpelich, W & Jantzen, P M (1955) A new principle in the operative treatment of trochanteric fractures of the femur *J Bone Jt Surg* 37-A, 693–698

Sonstegard, D A., Kaufer, H & Matthews, L S (1974) A biomechanical evaluation of implants, reduction and prosthesis in the treatment of intertrochanteric hip fractures. *Orthop Clin. N Amer* 5, 551–570

spondence to J Steen Jensen, M D, Department of Orthopaedic Surgery T-2, Gentofte Hospital, 900 Hellerup, Denmark

rthop scand 51, 633–638 1980

⁻OPIC BONE FORMATION FOLLOWING ⁴RNLEY HIP ARTHROPLASTY

ROMANN-ANDERSEN, T. SCHERFF SØRENSEN, K HOUGAARD, DRAVKOVIC & E FRIGAARD

rtment of Orthopaedic Surgery O, Odense University ıtal, Odense, Denmark

In a consecutive series of 309 patients the degree of ectopic bone formation was assessed 3 months 2 years, and 5 years after total hip arthroplasty At the three follow-up examinations ectopic bone formation was found in 49 per cent, 61 per cent, and 71 per cent In men ectopic bone formation was more common and more pronounced than in women It was demonstrated that walking ability and range of hip movement may be reduced in the presence of ectopic bone formation A past history of hip surgery, preoperative exostoses, and postoperative elevation of the erythrocyte sedimentation rate did not appear to influence the formation of ectopic bone There was no correlation between the degree of ectopic bone [illegible]

postoperatively

Key words ectopic bone formation, total hip arthroplasty

Accepted 11 xii 79

›pic bone formation (EBF) is a common ırrence after arthroplastic operations on hip Its cause is unknown It is known to an intramembranous ossification (Nollen 3, Rosendahl et al 1977) Nollen, in 1973, ıonstrated that the concentration of ıline phosphatases rose to significantly ıer values in patients who developed F postoperatively than in those who did In the literature it is agreed that it is not sible to point out preoperatively factors ıch may lead to postoperative EBF On the er hand, opinions differ as to the clinical ıificance of EBF

This paper reports a clinical study A ıber of clinical characteristics of EBF in a ısecutive series of 309 patients will be described, and in the discussion the results will be compared with those of others

PATIENTS AND METHOD

The patient material comprises the first 309 patients who underwent hip replacement by the method of Charnley in the Department of Orthopaedic Surgery O, Odense University Hospital Their median age was 61 years, range 26–78 years, 138 of the patients were males and 171 females. Bilateral operation was performed in 56 cases. All the patients were operated on according to the method of Charnley, with the lateral approach to the hip joint, trochanteric osteotomy, and total excision of the hip joint capsule After insertion of the prosthesis the trochanter was reattached using cerclage wires of stainless steel.

)1–6470 80 040633 06 $02 50

The patients were seen at follow-up 3 months, 2 years, and 5 years after the operation From these examinations 356 320, and 138 X-ray films were available for use in the present study The EBF was measured on routine anteroposterior views.

EBF was graded according to the classification used by DeLee et al. (1973), which ranges from no EBF to bridging EBF (Table 1) For the clinical assessment of hip function we used Charnley's (1972) grading for hip pain, walking ability, and range of hip motion with a score from 1 to 6 With this grading, 6 signifies a normal hip and 1 a hip with constant pain and disablement For groups of patients these scores are given with 1 decimal place

Table 1 Grading of ectopic bone formation

Grade 0	No ectopic bone
Grade 1	Ectopic bone less than 50 per cent of the distance between the femur and pelvis.
Grade 2	Ectopic bone 50–99 9 per cent of the distance between the femur and pelvis.
Grade 3	Ectopic bone bridging the distance between the femur and pelvis

RESULTS

Table 2 gives the incidence and sex ratio for EBF At 3 months, 2 years, and 5 years, EBF was present in 49 per cent, 61 per cent, and 71 per cent, respectively These [illegible] males were 53 per cent, 69 per cent [illegible] per cent and for females 45 per cent [illegible] cent, and 65 per cent. At 3 months [illegible] of the patients had bridging EBF [illegible] creasing frequency, over a 5-year period [illegible] increasing EBF was found. It was [illegible] apparent from the study that men had [illegible] grades of EBF more often than women [illegible] years the difference between men and w[illegible] with and without EBF was [illegible] significant ($P < 0.05$). At 5 years men [illegible] bridging EBF twice as often as women [illegible] influence of EBF upon the clinical res[illegible] terms of pain, walking ability and ra[illegible] hip motion – is shown in Table 3 [illegible] to the above-mentioned function sc[illegible] regards the analysis of pain, there [illegible] convincing differences between the [illegible] EBF On the other hand walking ab[illegible] range of hip motion showed, at 2 years [illegible] 5 years, a reduction of function wh[illegible] directly proportional to the severity [illegible] EBF If the patients had EBF (grad[illegible] and 3) there was a statistically s[illegible] ($P < 0.05$) reduction of walking ab[illegible] range of hip motion at 2 years.

Among the 45 bilaterally operated [illegible] there was at 2 years the following c[illegible] between the grade of EBF in the [illegible]

Table 2 Frequency of ectopic bone formation and sex ratio of patients with this compl[illegible]

	Ectopic bone formation (grade)						
	0		1		2		[illegible]
	No	Per cent	No	Per cent	No.	Per cent	[illegible]
At 3 months							
Total number	183	51	113	32	41	12	[illegible]
Males	80	47	60	36	19	11	[illegible]
Females	103	55	53	28	22	12	[illegible]
At 2 years							
Total number	123	39	110	34	61	19	[illegible]
Males	47	31	60	40	29	20	[illegible]
Females	76	45	50	30	32	19	[illegible]
At 5 years							
Total number	40	29	51	37	34	25	[illegible]
Males	18	24	29	39	19	25	[illegible]
Females	22	35	22	35	15	24	[illegible]

: 4) The same grade in 19 cases (42 per a difference of more than 1 grade in 9 ts (20 per cent), and in 16 patients (36 nt) there was no EBF in one hip, but 1 or 2 in the other

er hip surgery had been performed on tients prior to the arthroplasty At 2 the EBF findings were grade 0, 1, 2, in 23, 17, 6, and 4 patients, or 46 per 34 per cent, 12 per cent, and 8 per cent ation to the total material, this group of its showed no increase in EBF

the preoperative X-ray films the oses were measured at the upper lateral of the acetabulum, and the findings were d into four groups according to the of the exostoses in millimetres. Table 5 its the relationship between exostotic and the grade of EBF at 2 years after peration For exostoses ≤20 mm the s in the groups correspond to those in total series Only 16 patients had oses exceeding 20 mm in length It may be mentioned that none of these patients with large exostoses developed bridging EBF postoperatively

Finally, it was investigated whether an elevated erythrocyte sedimentation rate was demonstrable at 3 months in patients who developed EBF Table 6 shows there was no such correlation On the contrary, among 41 patients with an erythrocyte sedimentation rate >30 mm/1 h, 20 patients had no EBF, 10 patients grade 1, one patient grade 2, and one patient grade 3 EBF

DISCUSSION

EBF develops rapidly, often within 1 month (Nollen 1973, Spranger 1973) Of our patients 49 per cent had developed EBF 3 months after the operation DeLee et al (1973) and Spranger (1973) have reported that the condition *remains stationary after 1 year* Unlike them we found an increasing

Table 3 Clinical evaluation in cases with ectopic bone formation

	Ectopic bone formation (grade)			
	0	1	2	3
At 2 years				
Pain	5.5	5 7	5 8	5 4
Walking ability	5 3	5 0	5 1	4 5
Range of motion	4 8	4 6	4 3	3 8
At 5 years				
Pain	5 4	5 5	5 3	5 7
Walking ability	5 4	5 0	4 9	4 9
Range of motion	4 8	4 7	4 2	4 0

Table 4 Ectopic bone formation in bilaterally operated patients (at 2 years after the operation)

		Ectopic bone formation (grade) left hip			
		0	1	2	3
Ectopic bone formation (grade) right hip	0	8	3	3	
	1	5	7	2	1
	2	5	6	1	
	3			1	3

Table 5 Preoperative presence of exostoses and postoperative ectopic bone formation (at 3 y[illegible] the operation)

	Ectopic bone formation (grade)							
	0		1		2		3	
Exostosis (mm)	No	Per cent	No	Per cent	No	Per cent	No	P[illegible]
0	42	43	29	30	16	11	10	
1–10	55	37	52	35	30	20	11	
11–20	24	41	19	32	11	19	5	
>20	2	13	10	62	4	25	0	

Table 6 Ectopic bone formation and the erythrocyte sedimentation rate (at 3 months after the operation) 345 patients

	Ectopic bone formation (grade)			
ESR (mm/1 h)	0	1	2	3
0–20	127	87	33	14
21–30	24	10	6	3
31–40	10	6	1	
41–50	12	2		1
>50	7	2		

frequency and severity up to 5 years after the operation, in particular for grade 2 The total frequency of EBF in our material was relatively high Charnley (1972) reported 5 per cent, Lazansky (1973) 8 1 per cent, Bergstrom et al (1973) 19 per cent, and Spranger (1973) 25 per cent Rosendahl et al (1977) found a much higher frequency (90 per cent) Reports in the literature that men are more apt than women to develop EBF (DeLee et al 1973, Lazansky 1973) were confirmed by our findings as early as at 3 months after the operation, and at 5 years bridging EBF was present in twice as many men as women

There is no agreement concerning the clinical significance of EBF Charnley (1972) and Bergstrom et al (1973) reported that on the whole it had no influence upon the result Johnston (1973) reported that EBF rarely caused poor results On the other hand, Ilstrup et al (1973) found that pronounced EBF significantly reduced hip function, and this view was supported by Rose[illegible] (1977) According to DeLee et al [illegible] was impossible to predict the [illegible] patients with only slight EBF [illegible] reduced hip function, while in pa[illegible] severe EBF hip function might be [illegible] This latter observation is no doubt [illegible] some cases Our total results su[illegible] view that EBF does not give rise to [illegible] pain, but that it may reduce the [illegible] ability and the range of hip motion, [illegible] this reduction is directly proportion[illegible] degree of EBF

Among bilaterally operated pa[illegible] found no convincing correlation betw[illegible] in the two hips Unlike DeLee et a[illegible] therefore, we believe that there is no [illegible] of uniform development in the two [illegible] indeed our findings indicate that EB[illegible] constitutionally governed phenome[illegible] values show that patients with a pa[illegible] of other hip surgery do not make [illegible] risk group as regards the develo[illegible] EBF This was also pointed out by [illegible] al (1973)

Lazansky (1973) stated that the [illegible] preoperative exostoses the higher the [illegible] EBF, while DeLee et al (1973) [illegible] the formation of EBF was unaf[illegible] the formation of EBF was unaffected [illegible] size of the osteophytes as well as [illegible] possible removal at operation In [illegible] there was nothing to indicate that th[illegible] the exostoses could be used to [illegible] grade of EBF

An elevated erythrocyte sedim[illegible]

the arthroplastic operation is, according llen (1973), not typical of patients who ing to develop EBF, and this they took pport the view that EBF is not an inatory process We agree with this In the present material 76 per cent of itients had an erythrocyte sedimentation ≤20 mm/1 h (normal value), and apart 2 patients all those who had an ocyte sedimentation rate >30 mm/1 h BF of grade 0 or 1

the present study it was not possible to istrate groups of patients with an ised risk of developing EBF after plastic operation on the hip

ERENCES

trom B, Lindberg, L, Persson B M & nerfält R (1973) Complications after total arthroplasty *according to Charnley in a* edish series of cases *Clin Orthop* **95**, -95

Charnley, J (1972) The long term results of low-friction arthroplasty of the hip performed as primary intervention *J Bone Jt Surg* 54-B, 61–76

DeLee, J, Ferrari, A & Charnley, J (1973) Ectopic bone formation following low friction arthroplasty of the hip *Clin. Orthop* **121**, 53–59

Ilstrup, M D, Nola D R, Beckenbaugh, R D & Coventry, M B (1973) *Factors influencing the* results in 2012 total hip arthroplasties. *Clin. Orthop* **95**, 250–262

[illegible]

Orthop **95**, 96–103

Nollen, A J G (1973) The effect of E H D P on the para-articular ossifications after total hip replacement *Arthroplasty of the hip* (Ed Chapchal G) pp 138–142 Thieme, Stuttgart.

Rosendahl S, Christoffersen, J K & Nørgaard, M (1977) *Para-articular ossifications following* hip replacement *Acta orthop scand* **48**, 400–404

Spranger M (1973) Periarticular ossifications, an early complication of arthroplasty of the hip. *Arthroplasty of the hip* (Ed Chapchal, G) pp 135–138 Thieme Stuttgart.

spondence to C Kromann-Andersen Department of Orthopaedic Surgery O Odense University tal 5000 Odense C, Denmark

rthop scand 51 639 648 1980

REPLACEMENT WITH THE McKEE-FARRAR STHESIS IN RHEUMATOID ARTHRITIS

DOR BALDURSSON

ment of Orthopaedic Surgery University Hospital Lund Sweden

A follow up investigation was made of 78 patients suffering from rheumatoid arthritis (RA) who underwent total hip replacement (THR) according to McKee-Farrar during the years 1969–1975 There were 27 bilateral cases. The mean observation time was 47 months (range 9–85 months)

performed on the 78 patients. No correlation was shown between the results and RA serology age at THR, preoperative classification of hip radiographs, or observation time A high frequency of migration of the prosthetic components was found

Key words arthritis, rheumatoid arthroplasty hip

Accepted 21 2.80

y reports on total hip replacement R) include patients treated for matoid arthritis (RA) Comparison of the lts is usually difficult and often impos- as the criteria for assessment of results not standardized Andersson (1972) nined and assessed the results of Moore roplasty in a group of patients according une different assessment methods at the e time and found great discrepancy veen the results. According to the method ted the percentage of good results ed from 30 to 97 and the poor results ed from zero to 48 per cent

nother cause of difficulties is that the lts in published series seldom are arated according to the different nostic categories of the patients. The olems of the RA patient needing THR differ in many ways from the problems of a patient with osteoarthrosis or ankylosing spondylitis (Baldursson et al 1977)

Table 1 lists some reports of THR in RA in which the parameters of pain walking ability and hip mobility are reported in a manner that allows comparison of results. Good pain relief and increased hip mobility are constant findings in the reports, but walking ability is not as consistently improved

Rheumatoid arthritis is a chronic disease with periods of exacerbations and remissions. Fluctuations in disease activity make evaluation of results difficult Often there are symptoms arising from many joints and multiple operations may be needed The patients are often relatively young The patients are perhaps unable to use walking aids because of hand or arm impairment The

6470 80 040639 10 $02.50 0

Table 1 Some earlier reports on total hip replacement in rheumatoid arthritis

Year	Author	Reviewed Pat	Reviewed Hips	Mean age (years)	Observation time (months)	Results: Pain relief	Results: Walking	Results: [illegible]
1970	Welch & Charnley	186	274	54	> 12	Grade 5 or 6 in 99 per cent*	Small improvement	[illegible]
1972	Arden et al	27	40		Min 12	No pain or occasional discomfort in 90 per cent	Improved	[illegible]
1972	Harris et al		46		Min 3	No pain or occasional discomfort in 79 per cent	Not evaluated	[illegible]
1973	Bucholtz & Noack	296	403		Min 24 for 169 patients	Mean grade 5 6 after THR*	Mean grade increased from 2.0 to 4 4*	[illegible]
1974	Deutman	22	27		Min 12	Grade 5 or 6 in 96 per cent*	Mean grade increased from 1 3 to 3 0*	[illegible]
1975	Halley & Charnley	21	38	All ≤ 30	Mean 37 6 (6–99)	97 per cent pain-free*	Mean grade increased from 2.0 to 3 6*	[illegible]
1976	Poss et al	205	275	55	Min 18	Relief in 96 per cent	Improved in 82 per cent	[illegible]
1978	Colville & Raunio	278	378	39	Mean 30 Min 12	Grade 5 or 6 in 95 per cent*	Not evaluated	[illegible]

* Grading according to the method of d'Aubigné & Postel (1954)

osteoporotic bone in RA causes special technical problems during operation

Total hip replacement has been performed in our department since 1969 Initially, the McKee-Farrar prosthesis was chosen as the standard type for RA patients The use of all-metal prostheses has later been discontinued, the last McKee-Farrar hip was inserted in 1975 A change to metal-plastic prostheses was made because of reports of high friction and wear in all-metal hip prostheses (Swanson et al 1973) The high friction combined with low elasticity in the metal socket puts greater strain upon the cement-bone interface in an all-metal hip than in a metal-plastic hip prosthesis This probably increases the risk of loosening, particularly with the abnormally soft bone often found in RA

Animal experiments suggest [illegible] al 1973) that wear particles [illegible] chromium-molybdenum prostheses [illegible] capable of inducing malignant [illegible] Furthermore, metal sensitivity [illegible] wear particles, has been suggested [illegible] possible cause of prosthetic loosening [illegible] Evans et al (1974) and by Jones et al [illegible]

The purpose of this study was [illegible] the complications and results of [illegible] series of RA patients operated [illegible] McKee-Farrar hip prostheses

PATIENTS AND METHODS

A follow-up investigation was made of [illegible] with definite or classical RA [illegible] McKee-Farrar prostheses in the [illegible]

opaedic Surgery of the University Hospital of d during the years 1969 to 1975 Before the ning of this study, in 1974, seven patients died of causes unrelated to the THR All who were alive at that time were examined e author at least once (Table 2)

e mean age at THR was 56 years (20–75 s), the mean duration of RA at THR was 18 s (2–47 years) and the mean duration of hip toms was 6 years (6 months–27 years) y patients had a seropositive RA.

e conditions immediately before THR were pared with the conditions at the last follow-up ination In eight hips in which the prosthesis been removed, exchanged or reinserted, the itions immediately before the reoperation taken as the last follow-up examination

in, walking ability and hip mobility were ed according to the method of d'Aubigné & el (1954) in the form used by Halley & nley (1975) except that alphabetic prefixes not used. This method assessed hip mobility e sum of flexion, extension, abduction, adduc- internal rotation and external rotation

he main indication for THR was pain in 99 and stiffness in six Pain of grades 1–3 rding to the grading system of d'Aubigne & el (1954) was present before THR in 102 hips mobility of grades 1 or 2 according to the e system was found in 25

bservation time was defined as the time from THR to the last follow-up examination or oval, exchange or reinsertion of the original Kee-Farrar prosthesis. One exception was e This hip was unstable after THR and it decided to reoperate after the operation nd had healed The prosthesis was exchanged 2 ks after the primary THR In this one case, second prosthesis was regarded as primary first one was excluded from the assessment of lts) The mean observation time was 47 nths (9–85 months) For 101 THRs, the ervation time was 24 months or longer Three

Table 2 Patients

		Patients	THRs
rated 1969–1975		85	112
d before the beginning of this study		7	7
ilable for study		78 patients	105 THRs
mined	Men	21	29
	Women	57	76
	Total	78 patients	105 THRs

prostheses had been removed within 24 months after THR and one patient in this series died 22 months after THR

Fifteen of the 105 operated hips in this material had been operated on prior to THR Cup arthroplasty had been done in seven hips, synovectomy in five, and nailing of a pertrochanteric fracture in one In one hip an osteotomy of the proximal femur had been done and in another, an arthrodesis followed by an osteotomy of the proximal femur

As a part of the rehabilitation of the patients, in addition to the McKee-Farrar hip prostheses, 332 other orthopaedic operations were performed, 217 of these were done before THR (Baldursson & Brattstrom 1979b)

All radiographs were examined by a radiologist (Tord H Olsson) and special attention was paid to migration of prosthetic components.

The preoperative radiographs were graded (by the author) according to the method of Larsen et al (1977) Fourteen hips had medium destructive changes with erosion and joint space narrowing (Grade III) Twenty-one hips had severe destructive changes with bone deformation in addition to erosion and joint space narrowing (Grade IV) Sixty-two hips had mutilating changes with disappearance of the original articular surfaces and gross bone deformation (Grade V) In eight hips the grading method was not applicable because of previous operations.

General anaesthesia was used in all cases. Antibiotic prophylaxis with penicillin or cloxacillin was started before operation in 44 THRs, and in 43 antibiotics were only given postoperatively This prophylaxis was usually given for 2 weeks. In 18 THRs, no antibiotics were given All THRs were carried out in a conventional operating room This room was only used for clean orthopaedic surgery, and the THRs were done as the first operation in the morning No bilateral THRs were done in one session.

The standard approach to the hip was through an anterolateral incision. The technique of McKee & Farrar (1966) was used, except that it was rarely considered necessary to place the patient on an extension table Because of the risk of fracturing the femur, the femoral neck was usually divided *in situ* instead of dislocating the hip One or two suction drains were put in the wound through separate incisions.

Radio-opaque bone cement was used in 87 THRs. The cement was pressed into the femur with plastic rods or with the fingers. Antibiotic-containing cement was not used. The femoral part of the prosthesis was usually reduced into the socket before the cement in the femur had hardened

The mean operating time was 150 minutes (75-230 minutes)

There was no mortality in connection with the primary THRs

[illegible]

first on the day after THR Recovery has been only partial

One supracondylar *fracture* of the femur occurred during THR It was treated by skeletal traction and healed uneventfully In five THRs the *reamer perforated* the femur, but this was seen during the operation and a new reaming was done No harmful effects of these perforations have been seen

In another five THRs perforation also occurred but was not detected until postoperative radiographs had been taken and the tip of the prosthesis was seen to protrude from the femur Two of these prostheses (in the same patient) have loosened and been removed in one case after a failed exchange of a prosthesis The other three THRs have functioned well without visible ill effects of the protruding stems (observation time 66–84 months)

In one hip a *lump of cement* on the ventral side of the hip joint was thought to hinder hip flexion and was removed surgically 3 months after THR

One hip mentioned above *dislocated* on the day after THR and could not be kept from dislocating again except by abducting and internally rotating the hip Two weeks after the primary THR the prosthesis was exchanged and the hip functioned well after that.

Superficial infection was noted after nine THRs, none of which had proven or suspected deep infection In four of these, antibiotics had been given before and after THR In two hips antibiotics were given only after THR In one hip antibiotic prophylaxis was started before THR but by mistake the patient then had no antibiotics for the next 24 hours. In two THRs no antibiotic prophylaxis was given

Deep infection was considered proven in two THRs with positive bacteriological culture In one of these no antibiotic prophylaxis had been given In the other THR cloxacillin had been given only postoperatively One of the infected THRs has been exchanged but in the other the patient's general condition contraindicated exchange of the prosthesis.

In one hip deep infection was suspected on clinical and radiological grounds. Samples were taken for aerobic and anaerobic bacteriological cultures from the medullary canal of the femur The cultures were negative but the patient died suddenly 2 days after the exploratory operation

At the autopsy both parts of the [illegible] loose from the bone

Fracture of the [illegible] trauma was found in four hips [illegible] after THR Three of these [illegible] acetabular protrusion of 3 mm or [illegible] Two prostheses were removed [illegible] pain and new prostheses were [illegible] other patients with acetabula[illegible] been re-operated and are able to [illegible] distances with calipers to take the [illegible] the hip

Prosthetic exchange was performed [illegible] hips because of pain and *loosening* of [illegible] thesis. Infection has not been prove[illegible] hips

One socket loosened suddenly [illegible] THR and the patient was re-operated [illegible] hospital with reinsertion of the [illegible] Infection was not found

RESULTS

Table 3 demonstrates that three [illegible] pain free before THR Two of [illegible] ankylotic and the third had [illegible] mobility Following THR, 99 hips [illegible] pain, five were unchanged and [illegible] painful than before THR.

The mean pain grade before THR [illegible] and at follow up 5 5 Eleven hips had [illegible] grade of three or lower at the last [illegible] tion In ten cases, the pain was [illegible] be due to loss of stability caused by [illegible] mechanical loosening of the [illegible]

Table 3 Pain assessed according to the [illegible] *d'Aubigné and Postel*

Before THR

Grade	1	2	3	4	5	6	
6	45	16	18			3	[illegible]
5	3	1	2				6
4	3	1	1				5
3	7	1	1				9
2							–
1	1	1					2
	60	20	22			3	

— 1 Walking ability assessed according to the method of d'Aubigné and Postel

	Before THR(Before first THR in bilateral cases)						
	1	2	3	4	5	6	
	1	3					4
	1	2	1	1			5 At follow-up
	7	13	4				24
	11	14	1	1			27
	14	3	1				18
	34	35	7	2			Total

bular fracture In one hip, the cause of
ain could not be explained

ble 4 shows that following THR the
ng ability increased in 39 patients,
ined unchanged in 33 and diminished in
The mean grade for walking ability was
before THR and 2 4 at follow-up

ible 5 shows that following THR,
lity improved in 86 hips, remained
anged in 15 and diminished in four The
grade for mobility before THR was 3 2
at follow up 4 6 At the last follow-up ex-
ation, the total range of motion was less
100 degrees in five hips Two of these
were evaluated immediately before re-
ation, another belongs to a patient who is
elchair-bound because of a cerebral

e 5 Hip mobility assessed according to the method of d Aubigné and Postel

	Before THR						
	1	2	3	4	5	6	
6		3	4	5	3		15
5	8	2	9	23	3		45
4	2	7	18	11	2		40 At follow-up
3	1		1				2
2	1						1
1		1	1				2
	12	13	33	39	8		Total

haemorrhage and the last two were ankylotic before THR

Table 6 shows that before THR there was severe pain or stiffness in all 105 hips Considerable pain as well as stiffness was found at follow-up in two hips, nine had pain, but mobility was fair There was one painless stiff hip

The functional capacity was assessed according to the criteria of the American Rheumatism Association (Steinbrocker et al 1949) Eighteen patients were considered improved, 48 unchanged and 12 worse at follow-up than before THR (Baldursson & Brattstrom 1979a)

Sixty-one patients with 87 THRs in whom the original McKee-Farrar prosthesis was in place were examined at least twice with at least a 12-month interval between the examinations and with at least 12 months between THR and the first examination This was carried out to see if there was any change in the results between the examinations The mean time from THR to the first examination was 30 months and the mean time between the two examinations was 21 months Of the 18 hips not included in this group, eight were failures (see below) The pain grade was unchanged between the first and the last examination in 77 hips, four were improved and six were worse Mobility was unchanged in 62 hips, improved in eight and worse in 17 Most of the variations amount to only one grade according to the system of d'Aubigné & Postel

Pain relief and increase in mobility after THR were further analysed in relation to 1)

Table 6 Pain and stiffness before and after THR

	P	P+S	S
Before THR	80	22	3
At follow-up	9	2	1

P – pain, i.e. grade 1–3 according to the grading method of d Aubigné & Postel.
S stiffness, i.e mobility grade 1 or 2.

rthop scand. 51, 649–654, 1980

'ATERAL PERTHES' DISEASE

NEVELOS

mes's University Hospital, Leeds, U.K.

Bilateral Perthes' disease is defined as the form of the condition where radiological changes affect both hips simultaneously The radiological

Key words Perthes' disease, bilateral disease, simultaneous radiological changes, two unilateral attacks

Accepted 2 xii 79

occasional bilateral occurrence of hes' disease has been known since Calvé's 0) and Perthes' (1910, 1913) classic papers. ough the existence of bilateral disease has been doubted, no detailed study of this of Perthes' disease has been published relative incidence of bilateral disease has ed widely in the larger series reported (1965) found that only 7 per cent of his ents with Perthes' disease had bilateral lvement, although Lauritzen (1975) rded a 22 per cent relative incidence This difference might have arisen because the ria for bilateral disease have not been rly formulated

adiological abnormalities in the ffected' hip in unilateral disease have observed and recorded many times over years (Sandoz 1928) and these changes been held to be an abortive form of hes' disease by most authors.

his paper reports the study of the ographs of 147 patients with Perthes' ase An attempt is made to define eral Perthes' disease to differentiate it unilateral disease and from what can be rded as unilateral disease affecting the hips at grossly different ages.

RADIOLOGICAL STUDY

About a third of all the patients who had been treated for Perthes' disease in Leeds, Bradford and Nottingham between 1944 and 1978 had surviving 'full sets' of radiographs, taken at regular intervals from diagnosis to healing Not all of them had lateral views taken The affected side(s) and the severity of the disorder – whether or not fragmentation of the femoral capital epiphysis occurred – could, however, be assessed A total of 147 sets of radiographs were available to the author comprising a random selection of the

I *Fragmenting type of Perthes' disease affecting both sides simultaneously and progressing concurrently*

This type of the disease was rare only two patients were found in this series. In both patients the symptoms referred to only one of the hips during the whole course of the disease Figures 1 to 4 show radiographs of one of the patients with this type of Perthes' disease This boy was treated on a Jones's abduction frame for a year, then he was mobilized in patten ended calipers.

The radiological features of the disease in both these children were thought to be reminiscent of

–6470 80 040649–06 $02.50 0




Figure 1 Radiograph of a boy who was 4 years old at the onset of right sided symptoms of Perthes' disease
Figure 2 Both femoral capital epiphyses begin to fragment 6 months later
Figure 3 Fragmentation continues 5 months later
Figure 4 Re constitution of the capital epiphyses 1 year later




Figure 5 Radiograph of a boy [illegible] at the onset of right sided sym[illegible] disease He never had symptoms in the [illegible] Figure 6 Twelve months [illegible] epiphysis shows fragmenta[illegible] Figure 7 Eighteen months [illegible] The shape of the right femoral head [illegible]tory than that of the left


multiple epiphyseal dysplasia' Radiological surveys however failed to reveal abnormalities in other epiphyses.

II *Perthes disease affecting both sides simultaneously but only one capital epiphysis showing fragmentation*

Six patients showed this type of radiological appearance in this study All had symptoms referable to only one of the hips during the whole course of the disease the symptoms were not always related to the hip which later developed fragmentation Figures 5 to 7 show radiographs of one of the patients with this type of [illegible] disease This boy only had [illegible] his right hip where fragmentation [illegible] develop As expected the hip [illegible] fragmentation healed with a better [illegible] hip where the capital epiphysis [illegible] fragmentation

III *Apparently unilateral Perthes [illegible] with radiological abnormalities [illegible] uninvolved' hip also*

Analysis of the radiographs of [illegible] this series revealed abnormalities [illegible] 'uninvolved' side of those patients [illegible] to have unilateral disease These [illegible] included (i) Irregularities in the [illegible] outline of the femoral [illegible] Flattening of the infero-medial [illegible] epiphysis (iii) Posture [illegible] convexity of the upper border of [illegible] metaphysis and (iv) Irregularities [illegible] of the metaphysis.



...re 8 Radiograph of a boy who was 3 years old ...e onset of symptoms of Perthes' disease on the ...side only The right capital epiphysis is ...ular in density and outline, Gage's sign (see ...) is positive

...re 9 Two years later healing Perthes' disease ...e left, little evidence of abnormality on the ...

... every one of these 62 patients one or more of ... irregularities were observed in the ...volved' hip The patients' symptoms referred ... to the hip which showed typical Perthes' ...se Some 19 of the 62 patients did not ...lop fragmentation of the capital femoral ... The ... 12 ... an ...ently normal hip Figures 8 and 9, and 10 ... 11 show the radiological appearances found in ... type of Perthes' disease

... Unilateral Perthes' disease affecting first one ... hip and then after a clear time interval the ... other

...ine patients in the study had this presen...on They represented the majority of those ...nts who had been designated as having ...teral' Perthes' disease They all presented with ...t seemed to be unilateral disease, symptoms ...

... ptoms in the other so-far unaffected hip and ...ographs taken at this time showed early ...hes' disease in this hip as well, while the other ... continued to undergo the typical changes of ... disorder, or remained healed and unaffected. ...ures 12 to 15 show a typical case of this type




Figure 10 Radiograph of a boy who was 3 years old at the onset of left-sided symptoms of Perthes' disease Typical changes on the left The right capital epiphysis is irregular in density and outline, its infero-medial border is flattened, Gage's sign is positive

Figure 11 Four years later, healed Perthes' disease on the left, apparently normal right hip

of Perthes' disease in a girl who was 4 years old at the onset of left-sided disease A year and a half ...

V Unilateral Perthes' disease

The radiographs of 68 patients showed unilateral Perthes' disease only, with no radiological irregularities observable on the unaffected side Their symptoms related only to the hip with Perthes' disease The study of the radiographs of these patients were included in a series reported earlier (Nevelos et al 1977)

DISCUSSION

Since the original description of Perthes' disease in 1910, little attention has been paid to the bilateral form of the disorder other than noting its existence No clear definition of




Figure 12 Radiograph of a girl who was 4 years old when left sided Perthes' disease was diagnosed Right hip clinically and radiologically normal
Figure 13 One year later typical left Perthes' disease still no abnormality on the right



Figure 14 Eight months [illegible] symptoms on the righ[illegible] healing Perthes disease on the [illegible] fragmenting Perthes disease on the [illegible]
Figure 15 Three and a [illegible] Perthes' disease The result [illegible] right as expected

bilateral disease has been established and this might explain why such dissimilar figures have been quoted for its relative frequency Values for the relative frequency of bilateral Perthes' disease in the literature have ranged from 7 per cent (Wilk 1965) and 12 per cent (Edgren 1965) to 22 per cent (Lauritzen 1975) Ferguson (1975), however, was reluctant even to accept the concept of bilateral disease in any form

Most authors who noted the occasional presence of radiological abnormalities on the symptomless side of unilateral Perthes' disease considered them to be due to 'abortive or fleeting' Perthes' disease (Sandoz 1928 Sundt 1949 Goff 1954 Katz 1965 Chivabongs 1972 Mattner & Tomaschewski 1975 and Kranitz et al 1976) Emr & Komprda (1968) felt that these abnormalities represented a 'developmental variation' rather than the disease process itself

Until the aetiology and pathogenesis of Perthes' disease is known the assessment of the condition will remain [illegible] Recent evidence (Nevelos et a[illegible] et al 1978, Burch & Nevelos [illegible] that Perthes' disease might be [illegible] in the proximal femur of a [illegible] disease process with a possib[illegible] The finding of radiological [illegible] hips at the same time [illegible] tion Thus it is logical to [illegible] three types of the disorder [illegible] paper to be manifesta[illegible] radiological severity of [illegible] disease The series of radiograph[illegible] here was not an 'inclusive [illegible] radiographs of the pa[illegible] treated in the three [illegible] indicated period were [illegible] however, that if one [illegible] Perthes' disease [illegible] affect both hips at the same [illegible] relative incidence of [illegible] higher than the figures [illegible] literature In the [illegible]

ıld be almost 50 per cent but because of ɜ, no firm conclusions can be drawn ardıng the relatıve frequency of the erent types of the dısorder.

It ıs ımportant to note ın the three erent types of bılateral Perthes' dısease, ıptoms – however mınor – were referable only one hıp durıng the whole course of ı disease

The first type of bılateral dısease, when h hıps show fragmentatıon concurrently ıs ınıscent of a mıld form of multıple physeal dysplasıa (Grıffiths & Wıtherow 77), although a radıologıcal survey dıd not ow other epıphyseal abnormalıtıes

n fewer than half of the patıents ın thıs dy the dısease affected only one femoral ıtal epıphysıs Symptoms were referable to y thıs affected hıp and no abnormalıtıes ıld be detected ın the unaffected hıp, and ı these patıents had undısputable unılateral rthes' dısease, and the study of theır lıographs has been ıncluded ın an earlıer ort (Nevelos et al 1977)

In a small proportıon of patıents a clear ıe ınterval between the onset of lıologıcal changes ın the two hıps was served It ranged from 6 months to 4 years ıe ımportant features of thıs type of Perthes' ease are that symptoms were referable to th hıps alternately at the onset of each ndıtıon and that durıng the first attack the mptomless sıde was clınıcally and dıologıcally normal Although these patıents re desıgnated as havıng had 'bılateral' rthes' dısease, ıt mıght be more approprıate consıder them as havıng suffered two parate and unılateral attacks. Thıs type of the sease has, perhaps, more ın common wıth the ry rare 'recurrent' form of Perthes' dısease, ın hıch the second attack affects the same rather an the contralateral hıp Three such cases ıve been reported (Kemp et al 1971, erkreım & Foss Hauge 1976) The three other ses of 'recurrent' Perthes' dısease had all had lateral dısease at the first attack and, after ealıng, suffered a second, unılateral attack Kemp et al 1971, Katz 1973, Axer & Hendel 977).

It ıs suggested, therefore, that bılateral Perthes' dısease ıs the form of the condıtıon when, despıte unılateral symptoms, radıologıcal abnormalıtıes of equal or dıfferent severıty affect both capıtal femoral epıphyses sımultaneously

ACKNOWLEDGEMENTS

The author thanks the orthopaedıc surgeons of Leeds, Bradford and Nottıngham for allowıng hım to study the records and radıographs of theır patıents.

REFERENCES

Axer, A & Hendel, D (1977) Recurrent Legg-Calve-Perthes' dısease *Clın Orthop* **126**, 170–171

Bjerkreım, I & Foss Hauge, M (1976) So-called recurrent Perthes' dısease *Acta orthop scand* **47**, 181–185

Burch, P R J & Nevelos, A B (1979) Perthes' dısease a new genetıc hypothesıs. *Med Hypotheses* **5**, 513–528

Burwell, R G, Dangerfield, P H, Hall, D J, Vernon, C L & Harrıson, M H M (1978) Perthes' dısease An anthropometrıc study revealıng ımpaıred and dısproportıonate growth. *J Bone Jt Surg* **60-B**, 461–477

Calve, J (1910) Sur une forme partıculıère de pseudocoxalgıe greffée sur des déformatıons caractérıstıques de l'extrémıté supérıeure du femur *Rev Chır (Parıs)* **42**, 54–84

Chıvabongs, A (1972) Verlauft dıe Perthessche Erkrankung vorwıegend eınseıtıg? *Z Orthop* **110**, 418–425

Edgren, W (1965) Coxa plana *Acta orthop scand*, Suppl. **84**.

Emr, J & Komprda J (1968) Developmental varıatıon ın epıphyseogenesıs of the femoral head ın the unaffected hıp ın unılateral Legg-Calvé-Perthes' dısease *Sborn věd Prací lék. Fak. Hradcı Králové* **11**, 237–244

Ferguson A B Jr (1975) The pathology of Legg-Perthes' dısease and ıts comparıson wıth aseptıc necrosıs. *Clın Orthop* **106**, 295–297

Gage, H C (1933) A possıble early sıgn of Perthes' dısease *Brıt J Radıol* **6**, 295–297

Goff C W (1954) *Legg-Calvé Perthes' dısease and related osteochondroses of youth* Charles C Thomas, Sprıngfield Illınoıs.

Grıffiths, H E D & Wıtherow, P J (1977) Perthes'

disease and multiple epiphyseal dysplasia *Postgrad med J* **53**, 464–472

Katz, J F (1965) 'Abortive' Legg Calvé Perthes' disease or developmental variation in the epiphyseogenesis of the upper fumer *J Mt Sinai Hosp* **32**, 651–659

Katz, J F (1973) Recurrent Legg-Calvé-Perthes' disease *J Bone Jt Surg* **55**-A, 833–836

Kemp H B S Cholmeley J A & Bayens, J K (1971) Recurrent Perthes' disease *Brit J Radiol* **44**, 675–681

Kranitz, J, Barta O. & Bellyei, A (1976) The so-called healthy side of Perthes' disease *Magy Traum Orthop* **19**, 90–94

Lauritzen, J (1975) Legg Calvé-Perthes' disease *Acta orthop scand*, Suppl 159

Mattner, H R & Tomaschewski, H (1975) Doppelseitiger Befall der Huftgelenke bei der Perthesschen Erkrankung *Padiat Grenzgeb* **14**, 81–89

Nevelos, A B, Burch, P R J & Gelsthorpe K (1976) Perthes disease *J B*[illegible] 375

Nevelos A B, Colton C. L, [illegible] Woodward, P M (1977) Perthes [illegible] study of radiological features [illegible] *scand* **48**, 411–421

Perthes, G (1910) Über [illegible] juvenilis. *Deut Z Chir* **107**, 111 [illegible]

Perthes, G (1913) Über Osteochondritis [illegible] juvenilis. *Arch klin Chir* **101**, [illegible]

Sandoz, A (1928) Beitrage zur [illegible] Osteochondritis deformans [illegible] Legg Perthes Krankheit. *Beitr klin Ch*[illegible] 189–236

Sundt, H (1949) Further observations [illegible] malum coxae Calvé-Legg Perthes [illegible] regard to prognosis and treatment [illegible] *scand*, Suppl 148.

Wilk, L H (1965) Juvenile osteochondritis [illegible] hip critical evaluation of pathogenesis [illegible] ment *J Amer med Ass* **192**, [illegible]

Correspondence to A B Nevelos, F R C S, 85, Cookridge Lane Leeds, LS16 7NE, U.K.

a orthop scand 51, 655–660 1980

;INTIGRAPHIC EVALUATION OF THE SEVERITY -F PERTHES' DISEASE IN THE INITIAL STAGE

E J FASTING, INGJALD BJERKREIM, NORVALD LANGELAND,
IF HERTZENBERG & KARL NAKKEN

ohies Minde Orthopaedic Hospital University of Oslo and Ullevål Hospital
tion of Nuclear Medicine University of Oslo Norway

A method of grading Perthes' disease according to the involvement of the femoral capital epiphysis is presented 99mTc pyrophosphate bone scintigraphy was performed on patients in the initial stage of Perthes' disease An estimate of the femoral head involvement was made based on the size of the area with decreased activity visible on the scintigraphic image The estimate allowed classification into one of four grades of severity of involvement A comparison was made between the involvement seen on the scintigraphic image and the involvement later seen on radiographs. The importance of early diagnosis and treatment could be demonstrated

Key words bone, epiphysis, hip, Legg Perthes' disease osteochondritis, necrosis radiosotopes

Accepted 7 xi 79

rthes' disease is in most cases characterized a typical radiological appearance, but the gree of femoral head involvement differs tterall (1971) grouped the disease cording to the amount of femoral iphyseal involvement seen on the diographs in the fragmentation stage A rrelation between the severity and the end sult was thereby demonstrated This diological grouping is however only possible latively late in the course of the disease, and e influence of the early treatment given nnot be evaluated Using 18-F scintigraphy ohr (1973) demonstrated areas both with creased and increased activity in the moral epiphysis in Perthes' disease More cently 99mTc-labelled complexes have been e agents of choice in bone scintigraphy sing 99mTc-pyrophosphate it has been ossible to demonstrate a pathological image iowing only decreased activity in the very rly stage, even before radiological changes are visible (Danigelis et al 1975, Fasting et al 1978)

The purpose of the present paper is to demonstrate the possibility of a scintigraphic grading of the severity of Perthes' disease according to the size of the area with decreased activity seen on the gamma camera picture This in turn gives an opportunity to evaluate the effect of early treatment

PATIENTS AND METHODS

This investigation was performed to evaluate scintigraphy in the initial stage of Perthes' disease Only patients examined within the first 4 months after onset of symptoms and having typical radiological signs of Perthes' disease were included The material thereby consisted of 18 patients with Perthes' disease in 20 hips, 3 females and 15 males. Their ages ranged from 2 5 to 11 years, with a mean of 5 4 years. Thirteen right and seven left hips were involved The mean duration after the onset of symptoms at the first

)01 6470 80 040655 06 $02.50/0

examination was 2 6 months, at which time treatment was commenced All patients were treated with skin traction for about 4 weeks Thereafter non-weight-bearing was practised using bed rest, a hip plaster spica, crutches or a three lateral socket until the radiological remodelling stage was evident

Bone scintigraphy was performed at the time the patient first presented using a gamma camera (Pho/G
6 mCi
et al
with a
detailed study and quantification of the area with decreased activity in the capital femoral epiphysis

Since the size of the area showing decreased activity differed greatly between hips, the hips were divided into one of four scintigraphic grades The grading was designed to correspond as closely as possible with the radiological grouping of Catterall (1971)

Grade 1 Decreased activity involving a minor part (roughly 1/4) of the capital femoral epiphysis.
Grade 2 Decreased activity involving a moderate part (roughly ½) of the epiphysis (Figure 1)
Grade 3 Decreased activity involving most (roughly 3/4) of the epiphysis (Figure 2)
Grade 4 Decreased activity involving the whole epiphysis (Figure 3) The subjective estimation of the scintigraphic grade in each case was performed blindly by the collaboration of two investigators



Figure 2 The radiograph and scintigraphic image in a 6 year-old ... Perthes' disease in the right hip f... Scintigraphic grade 3 in the right h... evenly distributed activity in the left ep...



Figure 3 The radiograph and scintigraphic image in a 4 year-old ... Perthes' disease in the left hip f... Scintigraphic grade 4 in the left hi... evenly distributed activity in the right ...



Figure 1 The radiograph and the bone scintigraphic image of a 4 year-old boy with Perthes' disease in the right hip for 3 months Scintigraphic grade 2 in the right hip Normal evenly distributed activity in the left epiphysis

The patients had their hips ... examined in both AP and the L... positions, and the examination was ... to 5 month intervals. Normal ra... first examination were found in ... hips had typical changes during the ... disease

Later in the course of the disease in the fragmentation stage, a radiological grouping from 1 to 4 was performed according to the degree of epiphyseal involvement (Catterall 1971)

Wilcoxon's test was applied to test for statistically significant differences (Wilcoxon 1947). The differences were considered significant when $2\alpha < 0.05$

RESULTS

The nuclear medical examination revealed decreased activity in the entire capital femoral epiphysis in nine hips corresponding to scintigraphic grade 4 (Table 1) Four hips showed decreased activity of scintigraphic 3 and seven hips of scintigraphic grade 2 No hips had decreased activity corresponding to grade 1 The age of the patients and the duration of symptoms did not differ among these grades

Grouping according to Catterall (1971) was performed in the fragmentation stage (Table 2) The age of the patients was almost the same in each of these groups but the duration of symptoms before the start of treatment was less in radiological group 1

When comparing the severity of the disease seen on the scintigraphic image in the initial stage with the subsequent radiological evaluation three different courses could be demonstrated (Figure 4) The first consisted of seven hips which were unchanged in severity from the scintigraphic grading to the radiological grouping The second comprised eight hips which were found to have less femoral head involvement in the radiographs than seen at scintigraphy, i e the scintigraphic grade was more severe than the radiological, they had "improved" The third consisted of five hips that had changed from a scintigraphically less severe grade to a radiologically more severe group, they had "worsened" In Table 3 a comparison is made between these three disease courses. A difference in duration of symptoms before the treatment started was apparent The treatment had been started significantly ($2\alpha < 0.05$) earlier in those cases whose scintigraphic grade was more severe than

Table 1 Results of scintigraphic grading in 20 hips with Perthes' disease in the initial stage within 4 months after onset of symptoms Mean age in years and mean duration of symptoms in months when treatment was started

Scintigraphic grade	Number of hips	Age	Duration
1	0		
2	7	4.8	2.7
3	4	5.5	2.5
4	9	5.7	2.1

Table 2 Results of radiologic grouping in fragmentation stage in 20 hips with Perthes disease (Catterall 1971) Mean age in years and mean duration of symptoms in months when treatment was started

Radiologic group	Number of hips	Age	Duration
1	2	4.5	0.5
2	4	6.2	2.8
3	10	5.8	2.6
4	4	4.8	3

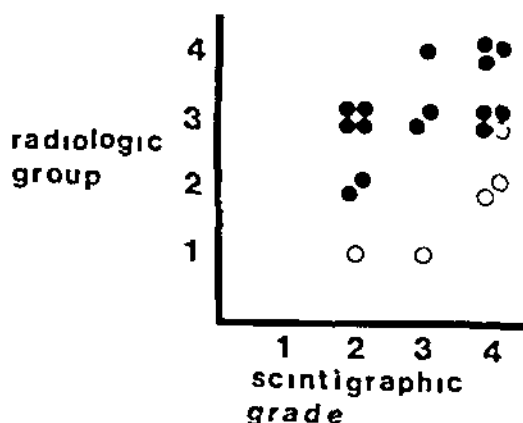


Figure 4 The comparison between the radiologic grouping (Catterall 1971) and the scintigraphic grading ● Cases treated within 4 months after onset of symptoms ○ Cases treated within 1 month after onset of symptoms

Table 3 Comparison of the scintigraphic grading of Perthes' disease in the initial [illegible] radiological grouping in the fragmentation stage (Catterall 1971) in 20 hips Mean age [illegible] duration of symptoms in months when treatment was started

	Number of hips	Sex: Male	Sex: Female	Side: Right	Side: Left	Age	Duration
Radiologic group less severe than scintigraphic grade	8	5	3	5	3	6	[illegible]
Radiologic group more severe than scintigraphic grade	5	5	0	4	1	5½	[illegible]
Radiologic group similar to the scintigraphic grade	7	7	0	3	4	4½	[illegible]

their radiological group The mean duration of symptoms being half (1 5 months) that of the other two disease courses (3 0 and 3 2 months) All five hips in which treatment was started within 1 month after the onset of symptoms had a less severe radiological group than scintigraphic grade, i e they had "improved"

DISCUSSION

Catterall (1971) classified Perthes' disease into four radiological groups and demonstrated the prognostic value of this Katz (1973) made a classification into three different groups and also he found an unmistakable association of better results with a milder form of epiphyseal involvement and poorer results in cases with total epiphyseal involvement A major determinant for tracer uptake is bone vascularity (Siegel et al 1976) The areas seen with decreased uptake of the tracer should therefore be the ischaemic areas of the caput epiphysis. Revascularization usually does not take place before 4 months after the start of the disease (Jonsater 1953, Larsen & Reimann 1973) As the bone scintigraphic examination in the present study was performed within 4 months after the onset of symptoms, the areas in the epiphysis with decreased uptake should therefore correspond to areas with decreased blood flow and therefore may be [illegible] by bone necrosis at the [illegible] disease It seems essential [illegible] quantitative estimation of the [illegible] as soon as possible in the course [illegible] disease and before revascularization [illegible] occurred This provides a new [illegible] differentiating patients with [illegible] of epiphyseal involvement in the [illegible] of Perthes' disease and a [illegible] which to judge the effectiveness of [illegible] treatments A quantification of the [illegible] uptake at a later stage as performed [illegible] (Morley et al 1978) does not [illegible] severity of disease and may be [illegible] why no correlation with the [illegible] findings nor the results was found

The treatment of Perthes' disease [illegible] matter of dispute not only [illegible] type of treatment, but also [illegible] treatment has any influence on the [illegible] all (Sundt 1949). Little [illegible] paid to the problem of early [illegible] although Lauritzen (1975) and [illegible] (1978) found better results [illegible] was started shortly after the first [illegible] In the present investigation the [illegible] grading was designed to [illegible] widely accepted radiological [illegible] difference between the [illegible] in the initial stage and the [illegible] grouping in the fragmentation [illegible] reflect the influence of the [illegible]

nd/or the natural course of the disease in us early period In the present study, treatment seemed in most cases to have little influence on the course of the disease, the rea with bone necrosis seen on the radiographs being as large as, or larger, than the area with decreased activity on the scintigraphic image However, early treatment seems to have an influence on the course of the disease In the present study hips treated within 1 month after the onset of symptoms all improved (radiological grouping less severe than scintigraphic grading) There was also a statistically significantly shorter duration of symptoms before the start of treatment in hips that had improved compared with the others This supports the view that early treatment is of importance in Perthes' disease It may be possible to change the course into a milder abortive form by very early treatment or to prevent bone necrosis in some cases (Emr et al 1973, Fasting et al 1978)

For clinical purposes bone scintigraphic examination with ^{99m}Tc-pyrophosphate is a useful supplement to the radiological examination The examination can be repeated and the revascularization and new bone formation can be followed in the different stages of Perthes' disease

REFERENCES

Bjerkholt H, Langeland N & Alvik, E (1978) Different ways of treating Perthes' disease *Acta orthop scand* 49, 634

Bohr, H (1973) Densitometry and 18-F scintigraphy in the study of the revascularization of the femoral head in coxa plana (C-P) *Acta orthop scand* 44, 417–425

Catterall, A (1971) The natural history of Perthes' disease *J Bone Jt Surg* 53-B, 37–53

Danigelis, J A, Fisher, R L, Ozonoff, M B & Sziklas, J J (1975) ^{99m}Tc-polyphosphate bone imaging in Legg-Perthes' disease *Radiology* 115, 407–413

Emr, J, Svobodova, L, Svoboda, L, Feltl, M & Skalska, H (1973) Results of the attempt to prevent the Perthes' disease in the East-Bohemian Region *Acta Chir orthop Traum čech* 40, 316–323

Fasting, O J, Langeland, N, Bjerkreim, I, Hertzenberg, L & Nakken, K (1978) Bone scintigraphy in early diagnosis of Perthes' disease *Acta orthop scand* 49, 169–174

Jonsater, S (1953) Coxa plana *Acta orthop scand*, Suppl 12, 1–98

Katz, J F (1965) "Abortive" Legg-Calvé-Perthes' disease or developmental variation in epiphyseogenesis of the upper femur *J Mt Sinai Hosp* 32, 651–659

Larsen, E H & Reimann, I (1973) Calvé-Perthes' disease *Acta orthop scand* 44, 426–438

Lauritzen, J (1975) Legg-Calvé-Perthes' disease *Acta orthop scand*, Suppl 159

Morley, T R, Short, M D & Dowsett, D J (1978) Femoral head activity in Perthes' disease Clinical evaluation of a quantitative technique for estimating tracer uptake *J nucl Med* 19, 884–890

Siegel, B A, Donovan, R L, Alderson, P O & Mack, G R (1976) Skeletal uptake of ^{99m}Tc-diphosphate in relation to local bone blood

dividual comparisons by ranking methods. *Biometrics* 3, 119–122

Correspondence to Dr Ove J Fasting Aker Hospital, Surgical Department, Trondhjemsv 235, Oslo 5, Norway

-ta orthop scand. 51, 661–666 1980

)ISTAL TRANSFER OF THE GREATER 'ROCHANTER IN COXA VARA

' TAUBER, A GANEL, H HOROSZOWSKI & I FARINE

epartment of Orthopaedic Surgery A, The Chaim Sheba Medical Center (Affiliated › the Tel-Aviv University), Sackler School of Medicine, Tel-Hashomer, Israel

Seven patients (nine hips) who suffered from coxa vara were treated by distal transfer of the greater trochanter The operation eliminated or markedly diminished the preoperative Trendelenburg sign, thus improving gait In three patients (four hips) operated upon at the ages of 9 and 12 years, the initial coxa vara was converted into an almost normal valgus femoral neck There was one poor result due to technical failure

Key words coxa vara, trochanter major transfer

Accepted 26 xii 79

.nfantile Coxa Vara is an uncommon ondition with various etiologies (Sharrard 979) Its features have been widely described nd its association with avascular necrosis omplicating treatment of congenital disloca-ion of the hip are well documented (Salter et il 1969, Gage & Winter 1972, Laurent 1953, Gore 1974, Weiner et al 1977) It may result n shortening and widening of the femoral ıeck, relative hypertrophy of the greater .rochanter and cause a typical limp or waddling gait, very like that in congenital dis-location of the hip, due to inefficient gluteal muscles. These patients have limited abduction of their hips and a positive Trendelenburg's sign

Correction of gluteal insufficiency due to the short femoral neck, which usually has a marked varus angulation, is achieved by distal transfer of the greater trochanter (Cohen 1971, Westin personal communica-tion 1976) The purpose of the present paper is to demonstrate the value of this operation in a series of seven patients with nine affected hips

PATIENTS

During the years 1973–1978, seven patients suffering from coxa vara were treated by distal transfer of the greater trochanter All our patients were females whose age ranged between 4 and 25 years (average 13.5 years) In two patients both hips were involved All of them had a marked [illegible]

METHOD

The greater trochanter was osteotomized with a Gigli saw and transferred distally 3–4 centimeters. Fixation was achieved by two compression screws or by two Steinmann pins.

The hip was immobilized in abduction for 6 weeks. In three patients a hip spica was used whereas in the others immobilization was achieved by two straight knee casts (tutors) held apart by a broom stick Six weeks following operation, hip exercises and weight bearing were started

Follow-up examinations at 3-month intervals included assessment of pain, limp, Trendelen-

0001 6470 80 040661 06 $02.50 0

ansfer of the greater trochanter

ength of follow-up (years) (months)		Pain	Limp	Trendelenburg sign after operation	Limb length discrepancy after operation	Remarks
6		Occasional	Only when tired	Minimal	1 cm	
5		None	–	Minimal	2.5 cm	
3	10	None	–	Minimal	1 5 cm	
3	10	Occasional on the left side	None	L-negative R minimal		Originally L-CDH
3		Occasional bilateral	None	Negative	None	
1	1	None	+	Minimal	2 5 cm	
	3		+	Minimal	2 5 cm	Pseudarthrosis. The screw broke



Figure 2 Case 2 5 years after operation Note the corrected femoral neck shaft angle 128° and the contour of the almost normal femoral neck

performed and maintained in abduction casts for 4 months Avascular necrosis of both femoral heads manifested itself on the radiographs with flattening and fragmentation of the ossifying nuclei Recovery took 4 years and the result was a bilateral coxa vara and coxa magna

At the age of 12 years the patient had a typical Trendelenburg gait and limited abduction in both hips. The femoral neck shaft angle was 105° in both hips (Figure 3)

Distal transfer of the greater trochanter was performed on both sides simultaneously at the one operation The hips were immobilized for 6 weeks in abduction casts On re-examination 3 years and 9 months after operation there was no limp A residual minimal Trendelenburg sign was elicited on the right side The femoral neck shaft angle was 130° on both sides (Figure 4).



Figure 3 Case 4 involvement of both hips. Note the impingement of the trochanter on the acetabular rim limiting abduction

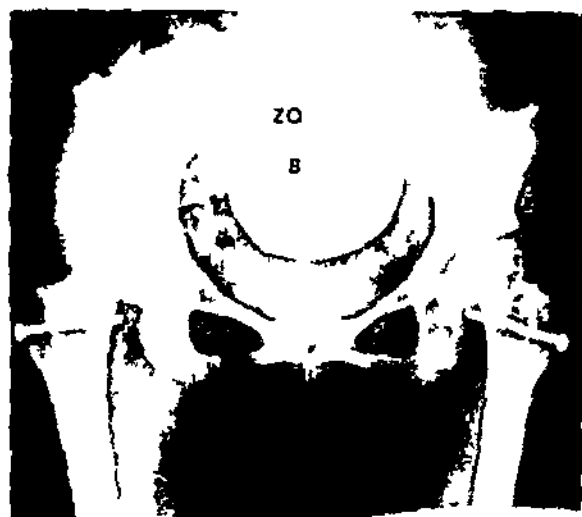


Figure 4 Case 4, 3 years and 10 months after operation Note the correction of the varus and elimination of mechanical hindrance of abduction



Figure 5 Case 7 standing radiograph [illegible] broken screw and the [illegible] trochanter

RESULTS

The clinical results are summarized in Table 1 In all the patients the gait was improved by diminishing or eliminating the Trendelenburg sign

Limb length discrepancy was not affected except in one case in whom it was diminished In one patient (No 7) (Figure 5) a too early mobilization resulted in screw breakage and non-union

The radiographic results summarized in Table 2 demonstrate a change of the coxa vara into an almost normal femoral neck shaft angle in three patients (four hips)

DISCUSSION

Avascular necrosis of the femoral head complicates the closed treatment of congenital dislocation of the hip (Gage & Winter 1972, Weiner et al 1977) However, it can affect the normal hip (Gore 1974) as well Its incidence is reduced by adequate premanipulative traction and adductor tenotomies (Salter et al 1969, Gage & Winter 1972, Gore 1974, Weiner et al 1977)

In the patients reported here [illegible] traction was performed and in all of [illegible] diagnosis of congenital dislocation [illegible] delayed and treatment started [illegible] children were older than 7 months [illegible] adding another risk factor which could [illegible] tribute to the development of avascular necrosis (Gage & Winter 1972, Weiner et al 1977) This vascular impairment [illegible] one of the etiological factors [illegible] characterized all the patients [illegible] study

Distal transfer of the greater trochanter [illegible] cases of coxa vara associated with [illegible] muscular insufficiency, was [illegible] department by the late Professor [illegible] 30 years ago, and is used for the same [illegible] dications by others (Cohen 1971, [illegible] al 1976) This operation [illegible] improvement in all our patients by [illegible] diminishing the marked Trendelenburg [illegible] in six hips and eliminating it [illegible] hips.

Residual limp was noted in two [illegible] in both, the affected limb was [illegible] shorter than the normal one [illegible] (Case 7), one of the [illegible] (Figure 5) and non-union [illegible] trochanter and the femoral shaft [illegible] This was due to technical [illegible]

Table 2 Radiographic results

Case no	Neck shaft angle before operation	Neck shaft angle after operation	Femoral head
1	–	L 115° R 145°	Round
2	115°	128°	Round
3	–	120°	Bifid
4	R 105°	130°	Coxa magna
	L 105°	130°	Coxa magna
5	R 115°	115°	Non spherical
	L 115°	115°	
6	115°	125°	Coxa magna
7	120°	120°	Coxa magna

nobilization One patient (Case 1) com-
ılained of limp only following physical
xercises or a long walk This could be
ıttributed to some muscle weakness in the hip
vhich had been operated on twice Three
ıatients reported occasional pain, which did
ıot interfere with their daily activities.

Comparison of the radiographs before
ıperation and at follow-up examination
evealed that in three patients (four hips), the
ıngle between the femoral neck and shaft
ncreased between 10 and 15°, thus con-
verting the initial varus into an almost
ıormal valgus neck. With angular correction
emodeling of the femoral neck also occurred
Of these three patients two were operated
ıpon at the age of 12 years and one at 9½
years.

In two patients who were older than 16
years when operated upon angular correction
did not occur

In the younger age group distal transfer of
the greater trochanter is a good alternative to
a conventional valgus osteotomy Its main
disadvantage is that usually the limb is not
lengthened as in a valgus osteotomy But its
advantages are that the femoral head remains
in the acetabulum, and that it is a much
simpler procedure However, attention has to
be paid to careful operative technique, such
as osteotomizing the trochanter from its base
in the digital fossa, and excising the bony
protuberance which might remain between
the femoral head and the osteotomy site, thus
contouring the femoral neck

In conclusion, considering the cases
reported above, distal transfer of the greater
trochanter yields good results by diminishing
markedly the Trendelenburg sign and thus
improving gait When the operation is
performed before the age of 12 years, correc-
tion of the coxa vara and femoral neck
remodeling will occur, yielding a very good
result

REFERENCES

Cohen, J (1971) Congenital dislocation of the hip Case report of an unusual complication and unusual treatment *J Bone Jt Surg* 53-A, 1007–1011

Gage, J R & Winter, R B (1972) Avascular necrosis of the capital femoral epiphysis as a complication of closed reduction of congenital dislocation of the hip *J Bone Jt Surg* 54 A, 373–388

Gore, D R. (1974) Iatrogenic avascular necrosis of the hip in young children *J Bone Jt Surg* 56-A, 493–502.

Laurent, J E (1953) Congenital dislocation of the hip *Acta chir scand*, Suppl. 179

Salter, R. B, Kostuik, J & Dallas, S (1969) Avascular necrosis of the femoral head as a complication of treatment for congenital dislocation of the hip in young children A clinical and experimental investigation. *Canad J Surg* 12, 44–60

Sharrard, W J W (1979) *Paediatric orthopaedics and fractures* Vol. 1, 2nd ed. pp 382–389 Blackwell Scientific Publications, Oxford

Weiner, D S, Hoyt, W A & O'Dell H W (1977) Congenital dislocation of the hip The relationship of premanipulation traction and age to avascular necrosis of the femoral head *J Bone Jt Surg* 59 A, 307–311

Westin G W, Ilfeld F W & [illegible] Total avascular necrosis of the [illegible] epiphysis in congenital [illegible] *Orthop* 119, 93–98

Correspondence to Dr A Ganel, Department Orthopaedic Surgery A Chaim Sheba [illegible] Hashomer, Israel

Acta orthop scand 51, 667–672 1980

EXTENSION DEFICIT AND LATERAL INSTABILITY IN DEGENERATIVE DISEASE OF THE KNEE

KURT KOLSTAD BO SAHLSTEDT & ANDERS WIGREN

Departments of Orthopaedic Surgery and Diagnostic Radiology,
University Hospital, Uppsala, Sweden

During the period October 1975–June 1977, 70 Marmor knee arthroplasties were performed The operative procedure provided a good opportunity to study the anatomical conditions *in vivo* The causes of extension deficit and lateral instability of the knees were analysed in a prospective investigation *Thirty-seven out of 69 knees had an extension deficit exceeding 10°* preoperatively At operation a bony impediment to extension was found in 32 of these 37 knees, and by removal of this obstruction the extension deficit was relieved in 31 of the knees. At radiography a bony impediment was demonstrated preoperatively as a cause of an extension deficit in 29 of the 32 knees No false positive diagnosis was made radiographically Varus or valgus instability exceeding 5° was observed preoperatively in 42 of the 70 knees Lateral stability was achieved in all knees at operation by compensating for the intra-articular loss of cartilage and bone with the Marmor module system Macroscopically intact collateral ligaments were found in all knee joints even in those severely affected by rheumatoid arthritis All knees except three showed lateral stability 1 year postoperatively

Key words flexion contracture, knee instability, Marmor knee, polycentric knee arthroplasty, osteoarthritis of the knee, rheumatoid arthritis of the knee

Accepted 28 xii 79

Rheumatoid arthritis and osteoarthritis can give rise to severe deformities, limitations of movement and instability of affected joints In the literature sporadic reports and assumptions can be found concerning the cause of the extension deficit and lateral instability in degenerative disease of the knee Helfet (1974) considers limited extension and reduced mobility of the knee to be due primarily to soft tissue contracture Several authors (Marmor 1973, Smillie 1974, Brattstrom 1977, Gschwend 1977, Cavendish & Wright 1978) have mentioned bony obstruction as one of the causes of an extension deficit in the knee, but this idea seems to have received little attention

Coomes (1962) concluded that there is some lengthening of the collateral ligaments in knees affected by rheumatoid arthritis. He did not state, however, whether the radiographs in his investigation were taken during weight-bearing, and his conclusion is therefore not entirely convincing The laxity of the ligaments in severely affected knees might be due largely to loss of bone and cartilage between the ligament attachments as a result of the degenerative joint disease Coomes' experimental studies show that as

0001-6470/80/040667-06 $02.50/0

soon as the laxity of the ligaments has been tightened, they behave almost normally as regards elasticity The absence of a meniscus alone does not cause clinically measurable varus-valgus instability (Markholf et al 1976) Some authors (Marmor 1967, Gunston 1971, Aglietti & Rinonapoli 1977, Cavendish & Wright 1978, Freeman et al 1978, Goodfellow & O'Connor 1978) assume that the instability is partly due to destruction of cartilage and bone in the joint

Arthroplasty of the knee is reserved for joints that are severely damaged by a degenerative disease, which often threatens the independence of the patient (Brattstrom et al 1977) The extensive surgical exposure of the knee joint permits the study of the anatomical conditions *in vivo* In a previous paper (Wigren et al 1978) we have reported the occurrence of meniscal regeneration observed at reoperations following polycentric knee arthroplasty In connection with knee arthroplasty a prospective study was performed on the occurrence of a bony block as the cause of extension deficit The reason for lateral instability was also studied, and the results are described in this paper

PATIENTS AND METHODS

During the period October 1975–June 1977, a Marmor arthroplasty was performed on 70 knees, 46 in women and 24 in men In 10 women and 5 men the operation was bilateral In 75 per cent of the knees the diagnosis was rheumatoid arthritis (RA) and in 25 per cent osteoarthritis (OA). One of the knees with OA exhibited sequelae from a fracture of the tibial condyle The ages of the RA patients varied between 29 and 79 years and those of the OA patients between 60 and 77 years. The age and sex distributions in the two groups are presented in Figure 1

At preoperative clinical and radiographic examination of 69 of the 70 knees (one knee is excluded because of inadequate records), the number of knees with a clinical extension deficit exceeding 10°, measured with a goniometer was recorded The extension deficit of the knee joint is defined as the angle between the neutral position of the joint (0°) and the maximal passive extension achievable Furthermore a record was made of the occurrence of a [illegible] impediment to extension on the [illegible] lateral view taken with the knee [illegible] extension Registration was [illegible] extension deficit exceeding 10° [illegible] administration of epidural [illegible] tourniquet was then applied and the knee [illegible] was opened through a medial [illegible] As the first measure before the Marmor [illegible] was inserted any bone [illegible] extension was removed whereupon the [illegible] was examined again.

Preoperatively with the patient [illegible] varus or valgus instability [illegible] noted Measurement was made with a [illegible] with the knee in maximal extension [illegible] was then compared with the degree of [illegible] achieved after insertion of the [illegible] the Marmor prosthesis and at [illegible] postoperatively

As the surgical technique in the [illegible] does not allow total free dissection of the [illegible] ligaments, this was carried out [illegible] human joints with severe knee [illegible] instability due to rheumatoid arthritis

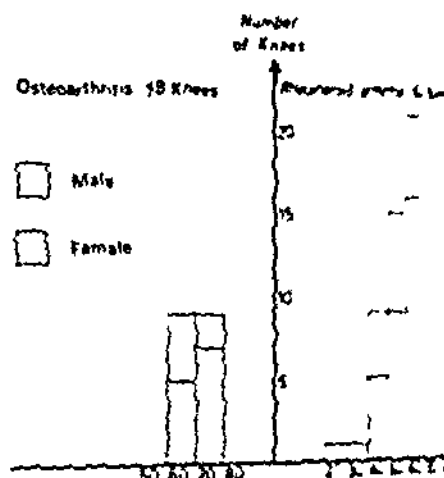


Figure 1 Distribution of [illegible] age, sex and diagnosis (number of knees)

RESULTS

Preoperatively 37 of the 69 knees [illegible] extension deficit exceeding 10° [illegible] examination. Of these 37 knees [illegible] affected by rheumatoid arthritis and [illegible] teoarthritis. The extension deficit [illegible] knees varied from 15 to 45° [illegible]

and from 15 to 40° in the OA group, with a mean value of 27° in the former group (Table 1) After administration of epidural anaesthesia there were 32 knees with an extension deficit exceeding 10° Thus in 5 knees the anaesthesia caused the extension deficit to disappear Preoperatively a bony block impeding extension was observed radiographically in 29 of these 32 knees (Table 2) There were no radiographic signs of bony impediment in any of the other knees (Figure 2) After removal of the bony prominence which was found in 32 knees an extension deficit exceeding 10° was found in only one of them In this patient the preoperative extension deficit was 55° After

Table 1 Preoperative distribution of 37 knees with an extension deficit exceeding 10° between the diagnoses rheumatoid arthritis (RA) and osteoarthritis (OA)

	R A	O A
Number	3 2	5
Ext.deficit	15 55	15 40
Mean	2 7	

Table 2 The number of knees with an extension deficit exceeding 10° after administration of epidural anaesthesia was 32 In 29 of these a bony impediment to extension was observed at preoperative radiography

	RA	OA
Number	28	4
X ray with bony block	25	4

Table 3 Varus or valgus instability of more than 5° was found preoperatively in 42 out of 70 knees with the distribution shown between the diagnostic groups One year postoperatively all knees except three were laterally stable

	RA	O A
Pre op instability	30	12
Post op instability	2	1



Figure 2 Radiograph showing a typical bony prominence on the anterior part of the tibial plateau preventing full extension. It has made an impression on the femoral condyle proving that the bony block is the cause of the extension deficit

removal of the bony prominence on the anterior lip of the tibia 20° remained

At preoperative examination varus or valgus instability exceeding 5° was found in 42 out of 70 knee joints, of which 30 were in patients with RA and 12 in patients with OA (Table 3) In 40 joints the instability was 5–10° and in two RA joints it amounted to 15° with the knee in maximal extension At operation the collateral ligaments appeared intact in all knee joints In the RA knees the anterior cruciate ligament was often missing while the posterior cruciate ligament was intact In the OA knees the cruciate ligaments were unaffected The lateral instability was caused mainly by bone destruction and loss of





Figures 3 and 4 Dissection of collateral ligaments from cadaver human knees with severe degeneration due to rheumatoid arthritis It is clear that the loss of bone and cartilage in the joint is mainly responsible for the lateral instability The collateral ligaments (arrow) are intact, and the medial is stretched by valgus force (Figure 3) and folded by varus force (Figure 4)

cartilage and bone on the tibial and femoral condyles, and by the use of the module system of the Marmor prosthesis lateral stability was achieved on the operating table in all knees. One year postoperatively all knee joints except three remained stable These three knees showed lateral instability of ≤5° with the knee extended One knee had been operated on several times previously for a fracture of the lateral tibial condyle The patient had also had a pertrochanteric femoral fracture treated with Ender nails and had considerable atrophy of the vastus medialis muscle Two of the knees displayed instability of less than 5° at the 1-year follow-up At later follow-ups [illegible] were considered to be laterally [illegible] anterior drawer [illegible] observed clinically in any of the [illegible] postoperatively

In autopsy cases with [illegible] with severely affected [illegible] ligaments were easily [illegible] intact, and the instability was [illegible] bone and cartilage [illegible] articular surface [illegible] could be seen (Figures 3 and 4)

DISCUSSION

In 37 out of 69 knees there was [illegible] deficit of more than 10° [illegible] 10° was considered [illegible] clinically measurable [illegible] administration of [illegible] number of knees with [illegible]

reduced to 32 In 31 of them full extension was achieved after removal of the impeding bone, which was thus the cause of the extension deficit in these cases In the one knee in which the extension deficit did not disappear, there was in addition to the mechanical bony impediment also a soft tissue contracture We found that the radiographic findings gave high diagnostic reliability There were no false positive radiographic findings In addition to the bony prominence of the anterior lip of the tibia (Johnson 1959), an impression on the femoral condyle should also be visible as proof of the functional impairment (Figure 2) This study shows that the most common cause of an extension deficit in these severely damaged knees is a prominence of bone on the tibial plateau forming a mechanical obstruction and not a soft tissue impediment as the word flexion contracture implies *The term flexion contracture should be reserved for a flexion deformity in which a mechanical bony impediment to extension can not be demonstrated radiographically* Only in knees in which the deficit disappears under anaesthesia is it possible to apply conservative treatment This opinion is in agreement with that of Smillie (1974) It seems to us that in knee joints with restricted extension, radiography in the lateral projection with the knee extended to the maximum should be performed *If a bony impediment is demonstrated radiographically, conservative treatment of the extension deficit has no chance of success* Information regarding the radiographic findings should be given to the physiotherapist when the patient is referred for muscle exercises and prophylactic treatment against increasing contracture Otherwise extensive exercises may give rise to tibial or femoral fracture of the soft rheumatic bone (Brattström 1977)

Lateral instability of more than 5° was found preoperatively in 60 per cent of the knees in this study Five degrees was considered to be the lower limit for clinically reliable measurements (Markholf et al 1976). At operation lateral stability was achieved in all knees by replacing the lost bone and cartilage with the modules of the Marmor prosthesis All knees except three were still stable at follow-up 1 year postoperatively This would not have been possible if the collateral ligaments of the knee joints had not been intact Further proof that these ligaments were not destroyed even in knee joints with severe rheumatoid degeneration was the macroscopic observation of undamaged ligaments in the autopsy material This finding corresponds to the ligament stability demonstrated experimentally by Coomes (1962) It is thus concluded that *the collateral ligaments are intact and latently retain their function despite severe bone destruction in the arthritic knee The loss of bone and cartilage is the principal cause of the lateral instability* It is therefore essential when performing polycentric knee arthroplasty to choose a surgical technique which will not affect the attachments of the collateral ligaments. Marmor's recommendation (1973) of drilling out the bed for the tibial part of the prosthesis with retention of the posterior and lateral tibial margin instead of an L-resection of the tibial plateau would seem a safe method

REFERENCES

Aglietti, P & Rinonapoli, E (1977) Methods of combining the correction of deformities of the knee with the use of the total condylar prosthesis. (Studies of postoperative stability) *Ital J Orthop Traum* **3**, 139–153

Brattstrom H (1977) Frakturer hos reumatiker – ett diagnostiskt och terapeutiskt försummat kapitel Svenska Lakaresällskapets [illegible] Psykotekniska institutionen, Stockholms universitet nr 92.

Cavendish, M E & Wright, J T M (1978) The Liverpool mark II knee prosthesis. *J Bone Jt Surg* **60 B** 315–319

Coomes, E N (1962) Lateral instability of the knee following polyarthritis. *Ann rheum Dis* **21**, 378–387





Figures 3 and 4 Dissection of collateral ligaments from cadaver human knees with severe degeneration due to rheumatoid arthritis It is clear that the loss of bone and cartilage in the joint is mainly responsible for the lateral instability The collateral ligaments (arrow) are intact, and the medial is stretched by valgus force (Figure 3) and folded by varus force (Figure 4)

cartilage and bone on the tibial and femoral condyles, and by the use of the module system of the Marmor prosthesis lateral stability was achieved on the operating table in all knees One year postoperatively all knee joints except three remained stable These three knees showed lateral instability of ≤5° with the knee extended One knee had been operated on several times previously for a fracture of the lateral tibial condyle The patient had also had a pertrochanteric femoral fracture treated with Ender nails and had considerable atrophy of the vastus medialis muscle Two of the knees displayed instability of less than 5° at the 1-year follow-up At later follow-ups these joints were considered to be laterally stable The anterior drawer phenomenon was not observed clinically in any of the knees postoperatively

In autopsy cases with rheumatoid [illegible] with severely affected joints the [illegible] ligaments were easily identifiable and [illegible] intact, and the instability was due to loss of bone and cartilage especially at the [illegible] articular surface, where a [illegible] could be seen (Figures 3 and 4)

DISCUSSION

In 37 out of 69 knees there was an [illegible] deficit of more than 10° A deficit of [illegible] 10° was considered the smallest [illegible] clinically measurable with [illegible] administration of epidural [illegible] number of knees with an extension [illegible]

Acta orthop scand. 51 673–678 1980

RECURRENT DISLOCATION OF THE PATELLA

Treatment by a Modification of the Method of McCarroll & Schwartzmann

NIELS HEJGAARD, LEIF SKIVE & CLAUS PERRILD

Department of Orthopaedic Surgery T–3, and Department of Radiology, Gentofte Hospital, Copenhagen Denmark

In a retrospective examination of 40 knees operated on according to a

cent Twelve per cent had recurrence of the dislocation There was very little correlation between the preoperative X ray and the final results. Open epithyseal plates were found to be a contraindication for the operation The duration of the condition and the number of dislocations had no bearing on the end results. The operative method is recommended for both traumatic and non traumatic dislocations of the patella

Key words dislocation, injuries, knee joint, patella, radiography, tendon transfers

Accepted 16 xi 79

The treatment of intermittent dislocation of the patella remains a controversial problem, giving rise to a wealth of different operative methods, according to Cotta (1959) the number is about 140 In the light of theoretical and clinical experience, a procedure combining active and passive correction as described by McCarroll & Schwartzmann (1945) appears to be superior to other methods (Thestrup Andersen 1955, 1959 Heywood 1961, Crosby & Insall 1976) McCarroll & Schwartzmann have applied the method on patients suffering from severe cases of patellar dysplasia, most often with chronic dislocation as seen for instance after poliomyelitis In the Department of Orthopaedic Surgery T–3 at Gentofte, the dominant group of patients with intermittent dislocation of the patella have for a number of years been young athletes with trauma as the basic aetiological factor The purpose of the present study is to assess in a retrospective examination the clinical and roentgenographic results of a modification of the procedure of McCarroll & Schwartzmann, carried out on the above-mentioned clientele

PATIENTS AND METHODS

During the period from 1971 until 1975 a consecutive series of 39 patients underwent operation and 37 were followed up Three of these had both knees operated on, so that a total of 40 knees were subjected to examination Mean age was 19 1 years (range 11–40) and the follow up time was 3 8–7 6 years (mean 5 6 years) Males and females were equally represented. In all cases the indication for operation was recurrent dislocation of the patella, defined as complete dislocation more than once

The operative procedure consists of a transposi-

0001 6470 80 040673 06 $02.50 0

tion of the tibial tubercle medially and distally until normal articulation of the patella is considered to be obtained The [illegible] lodged [illegible] a self-loc[illegible] rectional [illegible]
Schwartzmann consists of a semitendinosus tendon transfer into a subperiosteal longitudinal tunnel in the ventral part of the patella The passive correctional procedure as mentioned above is retained, while the active part of the operation is modified by loosening the distal edge of the pes anserinus and the semitendinosus tendon is then swung proximally so that it can be sutured to the distal-medial edge of the patella and to the proximal part of the patellar ligament The patient is immediately mobilized with full support in a knee plaster capsule which is removed after 6 weeks After this active training is prescribed

The clinical results of the operation were classified according to Table 1

Roentgenographic examinations The level of the patella is assessed as prescribed by Insall & Salvati (1971) though as modified by Jacobsen & [illegible]

referred to by Thestrup Andersen 1955) were used In tangential X ray exposures of the femoropatellar joint by Furmaier's technique morphology and subluxation were assessed as prescribed by Wiberg (1941) Brattstrom (1964) Merchant et al (1974), and Laurin et al (1978) (Figure 1)

Statistical calculations are based on Fisher's exact test with 5 per cent as the level of significance

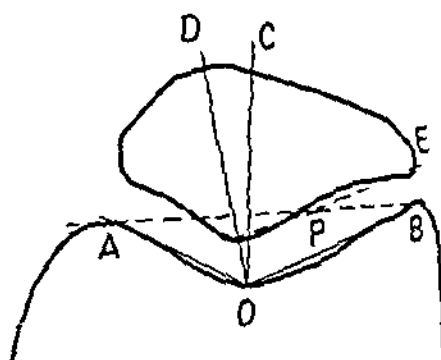


Figure 1 Axial view of the right patello[illegible] joint ("Merchant view") The sulcus angle of Brattstrom is AOB Mean 142 degrees s.d. [illegible] degrees The congruence of Merchant is DOC (CO bisects the sulcus angle) Mean −6 degrees s.d. 11 degrees The lateral patellofemoral angle of Laurin is EPB Normally it is never open medially

RESULTS

The mean duration of hospital treatment was 3 8 days (range 2–10 days) and the rehabilita[illegible] tion period was 24–670 days (mean 1[illegible] days) Table 2 shows the final operative results

There were only two complications, though serious ones Out of nine patients with open epiphyseal discs one developed [illegible]

Table 1 The criteria used for assessing the results of operation

EXCELLENT	No pain or stiffness no crepitus full range of movement no loss of function
GOOD	Minimal pain or stiffness minimal crepitus full range of movement, restriction of strenuous sports only
FAIR	Moderate occasional pain or stiffness moderate crepitus limitation of flexion less than 10 degrees moderate restriction of sports
POOR	Severe pain and stiffness with crepitus limitation of flexion over 10 degrees inability to maintain the body weight on the semiflexed knee complete restriction of sports
RECURRENCE	

Table 2 Assessement of results

RESULT	NUMBER OF KNEES	PERCENTAGE	
EXCELLENT	17	43	68
GOOD	10	25	
FAIR	4	10	20
POOR	4	10	
RECURRENCE	5	12	
TOTAL	40		

recurvatum with a 15 degree dorsal tilting of the tibial condyles, resulting in a marked feeling of instability Another patient developed a recurrent patella dislocation accompanied by chondromalacia so severe that patellectomy had to be performed 3 years after the operation

The poor results were due particularly to chondromalacia and reduction of quadriceps power In five cases the patella remained unstable, relapsing into dislocation which was in most cases complicated by synovitis and chondromalacia

Symptom yielding chondromalacia was found preoperatively in 11 patients Of these eight patients became free of symptoms after the operation On the other hand the presence of preoperative chondromalacia had no bearing on the final result (Table 3) Five out of 21 knees without preoperative femoropatellar pain developed postoperative chondromalacia

The dislocations were considered traumatic in 75 per cent (30/40), of these 67 per cent (20/30) had a successful result compared with 78 per cent (7/9) of the habitual dislocations. This difference is not significant ($P > 0\ 20$) The duration of the condition and the number of dislocations were found to have no bearing on the final result

Preoperative X-ray examinations revealed seven cases of patella alta six of which had traumatic dislocations. After operation one of these cases relapsed, while the remaining six were classified as excellent and good Only in two did the level of the patella normalize, one with an excellent result, whereas the other relapsed

Merchant's congruence angle (Figure 1) was preoperatively normal in all patients Postoperatively no lateral subluxation was found, while medial subluxation due to overcorrection was in evidence in 10 cases (mean −36 6 degrees, s d 7 degrees) of which only five were classified as good Brattstrom's sulcus angle was found to be normal in all cases. Laurin's angle was also found to be normal in all but one patient, where the angle was 0 degrees (Figure 1) This patient relapsed We found no signifi-

Table 3 The bearing upon the operative result of preoperative chondromalacia

RESULT	+ CHRONDROMALACIA		− CHRONDROMALACIA	
	NUMBER OF KNEES	PERCENTAGE	NUMBER OF KNEES	PERCENTAGE
EXCELLENT / GOOD	8	72	15	72
FAIR / POOR	1	9	4	19
RECURRENCE	2	19	2	9
TOTAL	11		21	
NO INFORMATION 8 KNEES				

cant correlation between the end-result and Wiberg's patellar types

DISCUSSION

With a median hospitalization time of 3 days we are approaching that of meniscectomy, which in our department is 2 6 days This short hospital stay can be partly attributed to mobilization as early as within the first 24 hours postoperatively

Transposition of the tibial tubercle close to open epiphyseal discs involves the risk of the development of genu recurvatum owing to *anterior epiphysiodesis.* The recorded incidence varies from about 18 per cent (Crosby 1976) to 33 per cent (Heywood 1961) The authors arrived at 11 per cent (confidence limits 0 28–48 25, $P < 0\,05$) in the present material, which should call for some caution

Correction of patellar instability *may remove the inconvenience of chondromalacia* (Dandy & Poirier 1975) The present study has been able to confirm this observation, as 72 per cent (8/11) became free of symptoms after normal patellar stability had been obtained In cases of continued instability chondromalacia disappeared in only 20 per cent (1/5) Only in five cases did postoperative chondromalacia develop, but in these it is worth noting that three patellae were medially overcorrected If this finding is related to the high frequency of poor results in patients suffering from postoperative medial subluxation (10 cases), it should be stressed that during operation as much attention must be given to medial overcorrection as is given to a too distal transposition of the tibial tubercle

The occurrence of patella alta was found mainly in cases of traumatic dislocation, which is at variance with the findings of Jacobsen & Metz (1976) of quite normal knee morphology in 10 patients with traumatic dislocations of the patella That high-riding patella involves a predisposition to dislocation was established by Thestrup Andersen (1955, 1958) and by Insall et al. (1972), but [illegible] bearing on traumatic dislocations [illegible] grounds for variance The discrepancy [illegible] most likely to stem from the fact that [illegible] the patients of our material with high-riding patella, the majority were found to [illegible] Wiberg's patellar type III

The preoperative assessment of [illegible] patellar X-ray parameters was deemed to be of little value with regard to predicting the operative effect Thus indication for operation can be based on clinical findings exclusively

It may be concluded that with a [illegible] degree of certainty and few complications the modified McCarroll & Schwartzmann operation is capable of stabilizing the [illegible] patellar joint in patients with [illegible] patellar dislocations of traumatic as well as of non-traumatic origin.

REFERENCES

Andersen P Thestrup (1955) *Luxatio [illegible]* Thesis Det Hoffenbergske Etablissement Copenhagen

Andersen, P Thestrup (1958) [illegible] deformities of the knee joint in [illegible] of the patella and achondroplasia. *Acta orthop scand* 28, 27–50

Andersen, P Thestrup (1959) Treatment of recurrent dislocation of the patella by the method of McCarroll and Schwartzmann [illegible] *chir scand* 117, 252–257

Brattström, H (1964) Shape of the [illegible] groove normally and in recurrent dislocation of patella. A clinical and X ray [illegible] vestigation *Acta orthop scand.* Suppl [illegible]

Cotta, H (1959) Zur therapie der [illegible] patellarluxation *Arch orthop Unfall-Chir* [illegible] 265–271

Crosby, E B & Insall, J (1976) Recurrent dislocation of the patella Relation of treatment to osteoarthritis. *J Bone Jt Surg* [illegible]

Dandy D J & Poirier H (1975) Chondromalacia and the unstable patella. *Acta orthop scand* 46, 695–699

Heywood, A W B (1961) Recurrent dislocation of the patella A study of its pathology and treatment in 106 knees. *J Bone Jt Surg* [illegible] 508–517

Insall, J & Salvati E. (1971) Patella position in the normal knee joint. *Radiology* [illegible] 101–104

Insall, J Goldberg V & Salvati E (1972) Recurrent dislocation and the high riding patella *Clin Orthop* **88**, 67–69

Jacobsen K & Bertheussen K (1974) The vertical location of the patella Fundamental views on the concept patella alta using a normal sample *Acta orthop scand* **45**, 436–445

Jacobsen K & Metz P (1976) Occult traumatic dislocation of the patella *J Trauma* **16**, 829–835

Laurin C A Lévesque H P Dussault R Labelle H & Peides J P (1978) The abnormal lateral patellofemoral angle A diagnostic roentgenographic sign of recurrent patellar subluxation. *J Bone Jt Surg* **60-A** 55–60

McCarroll H R & Schwartzmann J R (1945) Lateral dislocation of the patella Correction by simultaneous transplantation of the tibial tubercle and semitendinosus tendon *J Bone Jt Surg* **27**, 446–542

Merchant A C Mercer R L Jacobsen R H & Cool C R (1974) Roentgenographic analysis of patellofemoral congruence *J Bone Jt Surg* **56 A** 1391–1396

Wiberg G (1941) Roentgenographic and anatomic studies on the femoropatellar joint *Acta orthop scand* **12**, 319–410

Correspondence to Dr Niels Hejgaard Henriettevej 27 DK 2920 Charlottenlund Denmark





Figure 3 Xerography of knee joints operated on by two different methods of anterior displace[ment] Figure 2)

paralysis 3, fracture of the tibial tuberosity 3, suture granuloma 2, deep vein thrombosis 2, quadriceps rupture 1, anterior compartment syndrome 1, pulmonary embolus 1, fracture of the shaft of the tibia 1

The grade of change in the patellar cartilage according to Outerbridge (1961) was

Grade I 15 joints
Grade II 12 joints
Grade III 26 joints
Grade IV including patello-femoral arthrosis 15 joints

In this respect, there were no differences between men and women

At the follow-up, the patient's evaluation of the result of the operation indicated improvement in about 90 per cent (Table 2) The results in women were slightly but not significantly worse The working capacity before the onset of disabling symptoms and the preliminary postoperative capacity are presented in Table 3 The patients who did not work may have been students or [illegible] for reasons other than their knee cond[ition] Before the onset of knee disability [illegible]

Table 2 Patients evaluation of the results (pe[illegible]

	Men	Wom[en]
Free from symptoms	27	14
Improved	9	13
Unchanged	1	0
Worse	1	3

Table 3 Working capacity before ons[et of] symptoms and after surgery (patients)

	Before	Aft[er]
Heavy work	16	6
Moderate	24	[illegible]
Slight	14	13
Very slight	6	[illegible]
Not working	2	1

4 Pain on walking up and down stairs (joints)

en	Pain	No pain
fore	37	1
fter	9	29
omen		
efore	30	0
fter	16	14

ain on sitting with bent knees (joints)

len	Pain	No pain
efore	38	0
fter	4	34
omen		
efore	30	0
fter	9	21

han 61 per cent of these patients had articipated in sporting activities, the men nore often than the women After the operaion, 56 per cent did so, the change being ingnificant, although the results with regards o sporting capacity were slightly worse in omen After surgery, pain on walking up nd down stairs improved significantly $P<0\,001$) (Table 4), with a tendency for a less satisfactory improvement in women The ability to sit with bent knees without pain also improved significantly after surgery ($P<0\,001$) (Table 4) The pain index, which indicated considerable pain before surgery, shifted favourably in both sexes ($P<0\,001$) (Table 5)

Table 5 Pain index before and after anterior displacement of the tibial tuberosity (joints)

Men	1	2	3	4	5	6
Before				10	12	16
After	21	11	2	3		1
Women						
Before				13	7	10
After	16	9		4	1	

In Table 6, the various residual signs and symptoms which may be generated in the patello-femoral joint are listed for both sexes separately Note that, after surgery, a considerable amount of semi-objective signs and symptoms remained, most pronounced in women Crepitations seem to have little to do with the symptoms of the patient since many, in fact most of those with crepitations, were otherwise free from symptoms after surgery Also, tenderness of the tibial tuberosity, which is related to the operation rather than

Table 6 Residual patello-femoral signs in both sexes (joints)

		Men	Women	Significance
Stepping on chair	Able	36	22	$0\,05>P>0\,02$
	Unable	2	8	
Displacement pain	+	6	13	$0\,05>P>0\,02$
	−	32	17	
Tenderness medially	+	10	12	n s.
	−	28	18	
Tapping pain	+	7	11	n s.
	−	31	19	
Crepitations	+	22	21	n.s.
	−	16	9	
Tenderness of the tibial tuberosity	+	4	10	$0\,05>P>0\,01$
	−	34	20	

to the disease, was more frequent in women than in men

The arthrotomy disclosed a number of previously undiagnosed intra-articular conditions In 15 joints, there *was evidence of medial* and in two of lateral femoro-tibial degenerative changes These changes were slight and could *not have been* detected without arthrotomy *or* arthroscopy *In 12* cases, there were signs of synovitis and *in 11* an ulceration *of the femoral* cartilage *corresponding* to the changes on the patella – "mirror defect" *Anatomical changes of the* Hoffa fat pad were *seen in four cases*, and *inveterate anterior cruciate ligament ruptures in* two Over-growth *of the synovial* fringe on the joint cartilage was seen in two cases *There was one case* of ruptured *semi-lunar* cartilage and *finally in one joint a loose* body

Second follow-up

In the second follow-up study 17 months *later only 47* joints were included The *patient's opinion was now compared* between the first and the second examinations In men *there was further* improvement in four cases *whereas one patient, free from* symptoms in *the first follow-up*, now claimed that he was *worse than before the operation In women*, the second *follow-up revealed slightly worse results None* of the women had improved *further* during the 17 months whereas six had changed for the worse, thereby *reducing the* initial result of *about 90 per cent* improvement to about 70 per cent improvement *With regard* to working capacity, six men had changed *to lighter work* whereas four had changed *to* heavier work in the 17-month *interval*, in women, no less than eight had changed their *working* conditions but only *one to a lighter job* With regard to sport, there were no changes of importance in either sex between the *first* and the second examinations The pain index improved *in no less than eight men and of these seven* were rendered completely free from pain during this *time period*, whereas one was slightly worse, changing *one* step in the pain [illegible] In women, *however*, only two knees [illegible] *during this* time interval whereas in [illegible] *pain increased* according to the index

Otherwise, the findings of the se[illegible] *follow-up did* not significantly devia[illegible] those of the first examination

Thigh circumference and range of motion

At the time of the first re-exam[illegible] there was a decreased circumference of [illegible] thigh amounting to, on average 1 cm (T[illegible] *7) There were no such differences in the* [illegible] *At the* second examination this differe[illegible] had decreased significantly, on average 1 [illegible] had been added to the thigh circumferen[illegible] 17 months At one of the *measuring* s[illegible] the thigh, the data even went so far as [illegible] indicate that the *side to side difference* [illegible] now been *over-compensated* for Th[illegible] however, is not so since the circumference [illegible] the thigh *of the untreated leg* also incre[illegible] somewhat *with time* In fact, at the sec[illegible] *follow-up* there was no longer any differe[illegible] between the thigh circumference of t[illegible] treated and the untreated legs. The [illegible] motion was *restricted* in one sense only [illegible] there was a slight limitation – less than [illegible] – of the flexion motion which did [illegible] improve significantly between the *first* [illegible] *the* second *examinations* (Table 8) F[illegible] *extension* was recorded in all cases

Analysis of poor results

In order to analyse probable causes of [illegible] failure, the cases were arranged [illegible] groups. Group 1 consisted of all knees [illegible] *had improved* in all the variables [illegible] – 48 knees These knees were [illegible] *with those* 20 – Group 2 – that had [illegible] improvement with regard to at least [illegible] the *parameters* of pain or dysfunction [illegible] 1 consisted of 33 men and 15 women [illegible] *in group* 2 there were five men and 1[illegible] with a significant preponderance of [illegible] *($P \leq 0.001$)*

Table 7 Circumference measurement (cm) (Bilateral surgery excluded)

Untreated minus treated			
1st examination	Average ± 1 s d	N	Significance
Thigh 15 cm	−0 98 ± 1 52	56	$P < 0\ 001$
Thigh 25 cm	−1 01 + 1 51	56	$P < 0\ 001$
Calf	−0 05 + 0 73	56	n s.
Treated			
1st examination minus 2nd examination			
Thigh 15 cm	−1 24 ± 2 54	39	$0\ 01 > P > 0\ 001$
Thigh 25 cm	−0 90 ± 2 42	39	$0\ 05 > P > 0\ 02$
Untreated			
1st examination minus 2nd examination			
Thigh 15 cm	−0 68 ± 1 93	39	$0\ 05 > P > 0\ 02$

Table 8 Range of flexion motion (bilateral surgery excluded)

1st examination	Average ± 1 s d	N	Significance
Untreated minus treated	−7 9° ± 13 7°	56	$P < 0\ 001$
1st examination minus 2nd examination	−1 3° + 11 6°	56	n s.

Also, the women in Group 1 were significantly younger than the women in Group 2, 27 ± 13 and 37 ± 10, respectively ($0\ 05 > P > 0\ 02$) In Group 1 there were 10/48 complications and in Group 2, 9/20 complications with a significant preponderance in Group 2 ($0\ 05 > P > 0\ 02$) In Group 2, all the complications were in women Seven of the 15 joints with chondromalacia grade IV – arthrosis, belonged to Group 2, which indicates less satisfactory results in this type of patient, the difference, however, being non-significant

Variation between methods

The modified method of anterior displacement (Figure 2) was equally distributed among Groups 1 and 2. Although the complications were somewhat – but not significantly – fewer with the modified method, there were otherwise no differences in the results not even with regard to tuberosity tenderness. The degree of anterior displacement, measured on postoperative radiograms, varied somewhat (9 8 ± 2 5 mm) but this variation was not related to the results.

The data were also analysed with regard to whether shaving of the cartilage had been performed or not There was a slight but not quite significant preponderance of women in the shaving group ($0\ 1 > P > 0\ 05$) The follow-up time was significantly ($0\ 02 > P > 0\ 01$) longer in the shaving group, which merely indicates that this procedure was more often undertaken during the first part of the trial period There was a significant ($0\ 02 > P > 0\ 01$) shift towards more severe patello-femoral changes in those patients who had been shaved Otherwise,

there were no initial differences between patients selected for the two types of treatment, nor did the results differ significantly in any of the measured variables The two sets were also evenly distributed between Groups 1 and 2

DISCUSSION

From the data in this study the conclusion must be drawn that anterior displacement of the tibial tuberosity is beneficial to patients with patello-femoral pain There is in the data no indication as to how the cases should be selected The finding of somewhat poorer results in women, and particularly in older women, in this study is confused by the fact that poor results in women were associated with complications of the surgery and the interaction of sex, complications and results cannot be clarified on the basis of our data Shaving did not seem to add to or deduct from the results even if it must be taken into account that shaving was reserved for those patients with the most obvious gross anatomical changes This is a prospective study without controls. In order to evaluate the placebo effect the material was investigated twice, which should permit an evaluation of the durability of the result Only in women did the results deteriorate over the 17-month interval, whereas in men the results improved further in most of the variables evaluated However, also in women a rate of improvement of about 70 per cent in repeated examinations over 30 months can not be explained as a placebo effect, taking into consideration the long-standing preoperative symptoms in these patients

APPENDIX

Surgical treatment of chondromalacia patellae – an annotated bibliography

This bibliography attempts to survey the therapeutic approaches to chondromalacia patellae and to bring the reader up-to-date in this field

Chondrectomy or patellar cartilage s[illegible] Budinger (1906 1908) Aleman (1928), K[illegible] (1939) Wiles et al (1960), Wilppula & Va[illegible] (1971) Chakraverty (1972). *Chondr*[illegible] *combined with drill holes* Pridie (1959), De[illegible] et al (1966) Insall (1967, 1974).

Medial ridgectomy Outerbridge (1961[illegible] Crooks (1967)

Subtotal patellectomy Diamond (1964), [illegible] (1969) Groeneveld (1973).

Patellectomy Friberg (1941), West ([illegible] Geckeler & Quaranta (1962), Bentley (19[illegible]

Patellar prosthesis McKeever (1955), DeP[illegible] al (1960) Hanslik (1973) Levitt (1973).

Patelloplasty Cave et al. (1945), DePalma ([illegible] Campbell (1963).

Patellar surface allograft replace[illegible] Outerbridge & Dunlop (1975).

Medial shift of the tibial tubercle [illegible] Goldthwait (1963) Trillat et al. (1964), De[illegible] Golski (1973)

Downward advancement of the vastus me[illegible] *muscle* Outerbridge & Dunlop (1975).

Release of the lateral capsule Slocum [illegible] (1973) Merchant & Mercer (1974), Ficat [illegible] (1975)

Anterior displacement of the tibial tube[illegible] Maquet (1963) Bandi (1972), Nasser[illegible] Sussenbach (1973), Lund & Nilsson (1980).

The most wide-spread procedure is [illegible] doubt the removal of degenerative cartil[illegible] the joint surface of the patella. Good resu[illegible] this method have been reported by B[illegible] (1906 1908) Aleman (1928), Silverskjöld ([illegible] Karlson (1939), Cave et al. (1945), B[illegible] (1947) Wiles et al (1956 1960), W[illegible] Vahvanen (1971) Eriksson & Forssberg ([illegible] Chrisman & Snook (1974), Hencke ([illegible] [illegible] n et al ([illegible] [illegible] 1977, Deburge 1974 Janssen 19[illegible]

In recent years two additional method[illegible] been introduced i e the lateral release of [illegible] patella (Slocum et al. 1973 Ficat et al 19[illegible] the anterior displacement of the tibial tuber[illegible] The latter method was introduced by [illegible] (1963) and promising results, although [illegible] series only, have been presented by Bandi ([illegible] and Nassert & Sussenbach (1973). The [illegible] and [illegible] series so far are by Maquet (1976) and L[illegible] Nilsson (1980).

REFERENCES

Aleman, O (1928) Chondromalacia post[illegible] patellae *Acta chir scand.* 63, 149 19[illegible]

Bandi, W (1972) Chondromalacia Patellae und Femoro-Patellare Arthrose Atiologie, Klinik und Therapie *Helv chir Acta*, Suppl 11
Bentley, G (1970) Chondromalacia patellae *J Bone Jt Surg* 52-A, 221–232
Bentley, G (1977) Surgical treatment of chondromalacia patellae. *J Bone Jt Surg* 59-B, 107–108
Bronitsky, J (1947) Chondromalacia patellae. *J Bone Jt Surg* 29, 931–945
Budinger, K. (1906) Uber Ablosung von Gelenkteilen und verwandte Prozesse *Dtsch Z Chir* 84, 311
Budinger, K. (1908) Uber traumatische Knorpelrisse im Kniegelenk *Dtsch Z Chir* 92, 510
Cave, E F, Rowe, C R & Yee, L B K (1945) Chondromalacia of the patella *Surg Gynec Obstet* 81, 446–450
Campbell (1963) Fascial arthroplasty of the knee *Campbell's operative orthopaedics* 4th ed p 1082 C V Mosby Co, St Louis
Chakraverty, A C (1972) Excision of the patella for chondromalacia *J Bone Jt Surg* 54-B, 760–761
Chrisman, O D & Snook, G A (1974) The role of patelloplasty and patellectomy in the arthritic knee *Clin Orthop* 101, 40–45
Crooks, L M (1967) Chondromalacia patellae *J Bone Jt Surg* 49-B, 495–501
Deburge, A (1974) Chondrectomies. Table Ronde SO FCOT XLVIII *Rev Chir orthop*, Suppl 11, 357
DePalma, A F (1954) *Diseases of the knee* J B Lippincott Co, Philadelphia
DePalma, A F, Sawyer, B & Hoffman, J D (1960) Reconsideration of lesions affecting the patello-femoral joint *Clin Orthop* 18, 63–85
DePalma, A F, McKeever, C D & Subin, D K (1966) Process of repair of articular cartilage demonstrated by histology and autoradiography with tritiated thymidine *Clin Orthop* 48, 229–242
Devas, M & Golski, A (1973) Treatment of chondromalacia patellae by transposition of tibial tubercle *Brit med J* 1, 589–591
Diamond, B (1964) Subtotal patellectomy *J Bone Jt Surg* 46-A 1364
Eriksson, B & Forssberg G (1972) Chondromalacia patellae "Idiopathica" *Opusc med (Stockh)* 17, 32–33
Ficat P, Ficat C & Bailleux, A. (1975) Syndrome d'hyperpression externe de la rotule Son intérêt pour la connaissance de l'arthrose *Rev Orthop* 61, 39–59
Friberg S (1941) Über total Exterpationen der Patella *Acta chir scand.* 85, 361–388
Geckeler E O & Quaranta, A V (1962) Patellectomy for degenerative arthritis of the knee *J Bone Jt Surg* 44-A, 1109–1114
Goodfellow, J, Hungerford, D S & Woods, C (1976) Patello-femoral joint mechanics and pathology 2. Chondromalacia patellae *J Bone Jt Surg* 58-B, 291–299
Groeneveld, H B (1973) Neuere Moglichkeiten der Behandlung der femuropatellaren Arthrose *Z Orthop* 111, 527–529
Hanslik, L (1973) First experience on knee-joint replacement using the Young hinged prosthesis combined with a modification of the McKeever patellar prosthesis *Clin Orthop* 94, 115–121
Henche, H R (1974) Die Behandlung der Chondropathia als Präarthrose des Femoropatellargelenks *Z Orthop* 112, 630–631
Insall, J N (1967) Intra-articular surgery for degenerative arthritis of the knee A report of the work of the late K. H Pridie *J Bone Jt Surg* 49-B, 211–228
Insall, J (1974) The Pridie debridement operation for osteoarthritis of the knee *Clin Orthop*, 101, 61–67
Insall, J, Falvo, K. A & Wise, D W (1976) Chondromalacia patellae *J Bone Jt Surg* 58-A, 1–8
Janssen, G (1974) Die Chondropathia patellae als Prägonarthrose - Zur Atiologie und Therapie anhand von Ergebnissen nach Abrasio patellae *Z Orthop* 112, 1036–1044
Karlson, S (1939) Chondromalacia patellae *Acta chir scand* 83, 347–381
Levitt, R L (1973) A long-term evaluation of patellar prostheses. *Clin Orthop* 97, 153–157
Lund, F & Nilsson, B E (1980) Anterior displacement of the tibial tuberosity in chondromalacia patellae *Acta orthop scand* (Present communication)
Maquet, P (1963) Un traitement biomécanique de l'arthrose fémoro-patellaire L'avancement du tendon rotulien *Rev Rhum* 30, 779–783
Maquet, P (1976) Advancement of the tibial tuberosity *Clin Orthop* 115, 225–230
McKeever, D C (1955) Patellar prosthesis. *J Bone Jt Surg* 37-A, 1074
Merchant, A. C & Mercer, R. L (1974) Lateral release of the patellae *Clin. Orthop* 103, 40–45
Nassen, D & Süssenbach, F (1973) Therapie der Patellofemoralarthrose durch Ventralisierung der Tuberositas tibiae *Z Orthop* 111, 84–87
Outerbridge, R. E (1961) The etiology of chondromalacia patellae *J Bone Jt Surg* 43-B, 752–757
Outerbridge, R E (1964) Further studies on the etiology of chondromalacia patellae *J Bone Jt Surg* 46-B, 179–190
Outerbridge, R E. & Dunlop, J A Y (1975) The

problem of chondromalacia patellae *Clin. Orthop* **110**, 177–196

Pridie, K H (1959) A method of resurfacing osteoarthritic knee-joints. *J Bone Jt Surg* **41-B**, 618–619

Roux-Goldthwait (1963) Operation for recurrent dislocation of the patella. *Campbell's operative orthopaedics*, 4th ed p 355 C. V Mosby Co, St Louis.

Sacks, S (1969) Symposium on chondromalacia patellae XI SICOT Meeting, Mexico City

Silverskjold, N (1938) Chondromalacia of the patella. *Acta orthop scand* **9**, 214

Slocum, D B, James, S L & Larson, R L (1973) Surgical treatment of the dislocating patellae in athletes. *J Bone Jt Surg* **55-A** 1770

Trillat, A., Dejour, H. & Couette, A. [illegible] Diagnostic et traitement des [illegible] recidivantes de la rotule. *Rev Chir* [illegible] **50**, 819

West, F E. (1962) End results of [illegible] *Bone Jt Surg* **44-A**, 1089–1108.

Wiles, P, Andrews, P S. & Devas, M. B. [illegible] Chondromalacia of the patella *J Bone Jt Surg* **38-B** 95

Wiles, P, Andrews, P S & Bremner R. A. [illegible] Chondromalacia of the patella A study of later results of excision of the [illegible] cartilage. *J Bone Jt Surg* **42 B** 65–7[illegible]

Wilppula, E. & Vahvanen, V [illegible] Chondromalacia of the patella A [illegible] study of 25 cases treated with [illegible] *Acta orthop scand* **42**, 521–52[illegible]

Correspondence to Bo Nilsson, M D, Department of Orthopaedic Surgery Malmo General H[illegible] S–214 01 Malmö, Sweden

cta orthop scand 51 689–694 1980

)PTIMAL CORRECTION IN HIGH TIBIAL OSTEOTOMY ?OR VARUS DEFORMITY

'UNE MYRNERTS

)epartment of Orthopaedic Surgery, Linkoping University, the Medical School, Linköping, Sweden

As a basis for determining the required correction in high tibial osteotomy [illegible]

[illegible]

way the desired correction can be calculated For this patient series it was found that correction to between 3 and 7° valgus of the varus/valgus deviation (three-point technique) led to the best subjective rating of the end result by the patients. To compensate for the expected relapse after the operation another 1 or 2° may be added to the angular change at the operation To avoid an increase in the instability of the knee a lateral capsule reconstruction should be performed

Key words gonarthrosis, optimal correction, tibial osteotomy, varus deformity

Accepted 30 x 79

When, in 1961, Jackson introduced high tibial osteotomy as a form of treatment for arthrosis of the knee with varus or valgus deformity he stated that the aim of the operation was "to make the leg look straight" Jackson & Waugh 1961) Bauer and co-workers (1969) took radiographs of the knee joint with the patient standing They obtained the best results when the lateral angle between the axes of the long bones (the FT angle) was between 164 and 177° and recommended that this should be the surgeon's objective

Coventry (1973) used radiographs taken with the patient standing on both legs. The aim was to obtain an FT angle of between 167 and 170° after the operation This figure was subsequently changed to 170–175° (Coventry 1979)

In an earlier article (Myrnerts 1980a) the author reported a randomized series in which the operation in one group of the patients aimed at a correction to 5° valgus, measured from the varus/valgus deviation as determined by the three-point technique (Edholm et al 1976, 1977) [1] In the other group a varus/valgus deviation of 0° was aimed at

Though postoperative displacement of the osteotomy surfaces introduced variations in the end result (including those associated with the soft tissues), the study showed that when the correction to 5° valgus was successful within 2° the patient was more satisfied with the result of the operation (statistically significant $P<0.02$).

The study reported in this article was un-

[1] The varus/valgus deviation of the knee is defined as the angle between the hip-knee line and the mid position of the knee-ankle line, i.e., the bisector of the med o-lateral angle of instability

0001 6470 80 040959–06 $02.50 0

Acta orthop scand. 51, 695–702, 1980

ANKLE FRACTURES

Supination-Eversion Fractures Stage II
Primary and Late Results of Operative and Non-Operative Treatment

JOHANNES YDE & KRISTIAN D KRISTENSEN

Department of Orthopaedic Surgery, Hjørring Hospital, and Department of Surgery, Frederikshavn Hospital, Denmark

Sixty-nine patients with stage II supination-eversion fractures of the ankle, 34 treated by operation and 35 treated conservatively, were seen at follow-up after 3–10 years. There was no statistically significant difference

lateral malleolus in the anatomical position obtained by operation.

Key words ankle fractures, arthrosis, non-operative treatment, operative treatment, supination-eversion fractures stage II

Accepted 13.xii 79

In most clinics the treatment of the various types of malleolar fractures is mainly non-operative, although for many years it has been considered expedient to perform osteosynthesis in some of the displaced posterior tibial fractures, unstable ruptures of the syndesmosis, and loose medial malleolar fractures (Müller 1945) During the past 15 years, however, ever increasing importance has been attached to the state of the lateral malleolus (Danis 1949, Willenegger 1961, Weber 1966, Cedell 1967) to which about 20 per cent of the body weight is transferred during the first phase of walking (Weber 1966) It has been demonstrated experimentally by Riede et al (1969) that a 2 mm displacement of the lateral malleolus may entail a talar displacement of 1–2 mm and 1–2 degrees of external rotation, reducing the articular surface contact between the tibia and talus by about 50 per cent On this basis Riede et al concluded that any malleolar fracture uniting with displacement of the lateral malleolus has a tendency to develop arthrosis due to incongruence after a varying length of time

The ankle injury designated by N Lauge Hansen (1942) as a supination-eversion fracture stage II (SE II) is a pathologically well-defined (Figure 1) and common subgroup of ankle fractures (Cedell 1967)

In the present study the course of treatment and the late results (subjective, objective, and radiological) of operative and non-operative treatment of SEII injuries were compared

PATIENTS AND METHODS

During the 8-year period 1968–1976 a total of 488 malleolar fractures were treated, primarily and after discharge, in the Department of Orthopaedic Surgery, Hjørring Hospital, Denmark, and 247 in the Department of Surgery, Frederikshavn Hospital, Denmark. The two series do not include patients under 15 years of age, epiphysiolyses,

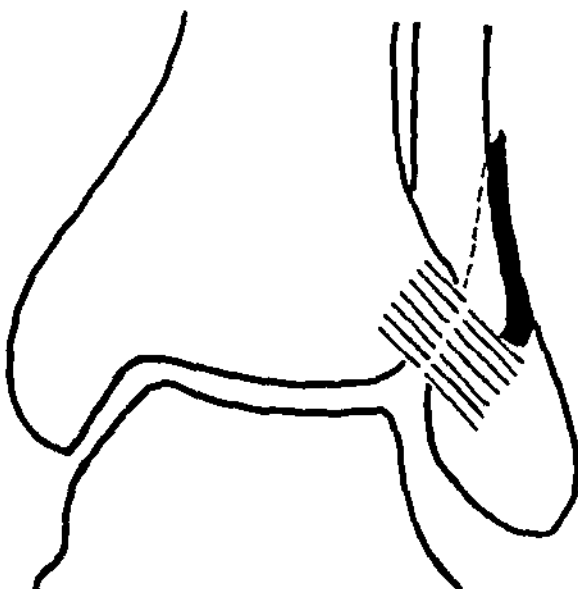


Figure 1 Supination-eversion fracture stage II Rupture of the anterior tibiofibular ligament (stage I) Distal oblique fibular fracture (stage II)

"pure" ligament injuries, or fractures caused by direct violence The Lauge Hansen classification (1942) was used for typing and staging the fractures (Table 1) During the period all the SE II injuries in Frederikshavn were treated non-operatively

During the winter of 1978–79, 34 operatively treated patients (Hjørring) and 35 non-operatively treated patients (Frederikshavn) were seen at follow-up The reasons for the reduction in the number of patients making up the two materials can be seen in Table 2 The sex ratio

Table 1 Distribution of fracture types according to the classification of Lauge Hansen (1942) Percentage

Fracture types	Hjørring n=488	Frederikshavn n=247
supination-adduction	20 1	18 6
supination-eversion		
stage II	33 2	35 2
III	2 3	3 3
IV	21 5	17 4
V–VI	0 4	0 4
	57 4	56 3
pronation-abduction/ pronation-eversion	20 9	21 1
other	1 6	4 0
	100 0	100 0

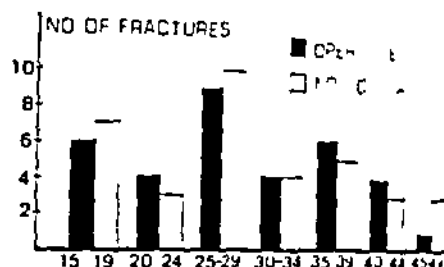


Figure 2 Age distribution

(males/females) for the operatively trea ed patients is 1 5 [illegible]
Figure [illegible]
main [illegible]
7/8, " [illegible]
"other [illegible]
joint [illegible]
The primary displacement according to the classification of Cedell (1967) is listed in Table [illegible]

Operative treatment (Hjørring)

Radiologically visible displacement of an SE II fracture was considered an indication for osteosynthesis Relative contra indications were age over 49, unfavourable soft tissue conditions and fractures occurring more than 24 hours before admission Other reasons for conservative treatment were the patient's wish not to undergo operation and the lack of operative capacity

Six different surgeons did the operations which were performed in a bloodless field. The fracture was exposed by a slightly arcuate longitudinal incision over the lateral malleolus, accurately reduced, and fixed Until 1974 the fixation was by steel wire cerclage (20 fractures, Figure 3), and after that time by small AO screws (12 fractures [illegible] methods was [illegible] ligament was sutured [illegible] fragments fixed with a Palmer pin or a [illegible] suture In addition the ligament was stabilized by the staple described by Cedell & Wiberg ([illegible]) [illegible] this elastic steel staple was hammered in parallel with the ligament A suction drain was inserted and after a below the knee plaster cast had been applied the leg was kept elevated for about [illegible] In 26 patients the plaster cast was worn for about 6 weeks, in 18 patients in the form of a walking cast during the last 2 or 3 weeks. Since [illegible] the plaster cast has been removed (7 patients) at the time of removal of the sutures on the [illegible] postoperative day, and the patients have [illegible] exercises, but weight-bearing has not been [illegible]

Table 2 Criteria and reasons for exclusion of patients from the study of supination eversion injuries stage II

	Hjørring	Frederikshavn
Total SE II material	160	87
Exclusion		
Age over 49	74	31
Not operated on because of		
local disease	2	0
late admission	4	0
lack of time and other reasons	31	0
Treatment completed elsewhere	4	5
Follow-up not practicable		
dead	4	1
systemic disease	1	0
new injury	0	3
remote domicile (>50 km)	5	4
refused other reasons	1	8
Total excluded	126	52
Total seen at follow up	34	35

until about 6 weeks after the operation At that time the cerclage and Wiberg staple were removed under general anaesthesia, whereas the small screws were left, unless they caused annoying prominence Most recently, after the use of cerclage had been abandoned the removal of the Wiberg staple has been on an outpatient basis with local anaesthesia

The mean stay in hospital was 11 1 days (range 5–21 days)

Non operative treatment (Frederikshavn)

All SE II fractures were treated non-operatively without reduction of the fracture Primarily, the patients were admitted until the swelling subsided Within the first 2 weeks a lower leg walking cast was applied and worn until 6–8 weeks after the trauma

The mean stay in hospital was 5 7 days (range 1–10 days).

The materials were examined clinically and radiologically by the authors after a mean follow-up period, for both series, of 6 0 years with a range of 3–10 years.

RESULTS

1 Primary results

The radiological results of the reduction were recorded about 2 weeks after the treatment was started (Table 5) Within the operated group 82 4 per cent (28/34) obtained

Table 3 Occupational strain on ankle joint

Group	Occupation	Operative treatment	Non-operative treatment
1	*unprotected, heavy* fisherman, farmer, woodcutter, shipyard worker	8	7
2	*unprotected* factory worker shopkeeper, cleaner (full time)	15	10
3	*possibility of protection* cleaner (part time), country housewife	6	2
4	*little strain on legs* housewife, teacher, student	5	16
		34	35



Figure 3 Fixation of the distal oblique fibular fracture by cerclage The anterior tibiofibular ligament is sutured and strengthened by a staple

"anatomical" reduction, while 71 3 per cent (25/35) in the non-operatively treated group had a "poor" position according to the Cedell classification (1967) Whether the reduction

Table 4 Radiological degree of displacement before treatment (classification according to Cedell 1967)

Degree of displacement	Operative treatment	Non-operative treatment
Anatomical no displacement	1	0
Good slight rotation	7	8
Poor lateral and/or dorso-proximal displacement marked rotation, valgus position	26	27
	34	35

Table 5 Radiological result of reduction [illegible] operative and conservative treatment [illegible] fication according to Cedell 1967)

	Operative treatment	Non-operative treatment
Anatomical	28	1
Good	5	9
Poor	1	25
Total	34	35

was effected by cerclage or by small [illegible] does not seem to have affected the res[illegible] (Table 6)

One operatively treated patient develope[illegible] skin necrosis after removal of the cer[illegible] wire and Wiberg staple Healing took pl[illegible] within 6 weeks One non-operatively trea[illegible] patient developed a plaster pressure [illegible] which left a chronic eczematized scar

The period off work was recorded [illegible] exclusion of the patients in the group [illegible] work which causes least strain on the leg[illegible] Table 3, group 4) This period averaged [illegible] weeks in the operatively treated and [illegible] weeks in the non-operatively treated group

2 Late results

The minimum follow-up period is 3 [illegible] The subjective symptoms were class[illegible] according to Baek Kristensen (1953) [illegible] Cedell (1967), the objective findings acco[illegible] to Baek Kristensen (1953), Cedell (1967) [illegible] Weber (1966)

Radiological changes of the joint [illegible] recorded according to the cr[illegible] Magnusson (1944) and Weber (1966) [illegible] comparing the subjective and objective [illegible] the classifications of Cedell were used, as [illegible] make the strictest demands.

Table 6 Radiological result of reduction [illegible] fibular fixation with cerclage or small [illegible] (classification according to Cedell 1967

	Cerclage	[illegible]
Anatomical	17	12
Good	2	2
Poor	1	0
Total	20	12



Figure 4 Fixation of the distal oblique fibular fracture by a small AO screw

Subjective results (Table 7)

(1) good — The patient is completely symptom-free or rarely has quite negligible symptoms of pain, swelling, stiffness, or tiredness, but only after extra exertion

(2) medium — Moderate symptoms of pain, swelling, stiffness, or tiredness after exertion, but no reduced capacity for work and in most cases normal capacity for exercise and sports

(3) poor — Severe symptoms of pain, swelling, stiffness, or tiredness, especially on exertion, and as a rule reduced capacity for work

Within the operated group three of the four patients with moderate symptoms after exertion had an "anatomical" and one a "good" result of the reduction In two the complaints were apparently due to the scar and in the remaining two to the non-removed osteosynthesis material

After non-operative treatment one patient complained of chronic eczema after a pressure sore, and two had mild symptoms of arthrosis ("poor" position of the fracture) In the remaining three patients there was no objective or radiological explanation for the symptoms

Table 7 Late subjective results (classification according to Cedell 1967)

	Operative treatment	Non-operative treatment
Good	30	29
Medium	4	6
Poor	0	0
Total	34	35

Table 8 Classification of late objective results (+) increase, (−) decrease (modification of Cedell classification)

Components	Good	Medium	Poor
gait	normal	normal	limp
size of the lower leg (+)	≤1 cm	>1–2 cm	>2 cm
calf size (−)	≤1 cm	>1–2 cm	>2 cm
ligament tenderness	none	slight	marked
dorsoplantar flexion (−)	<15°	16–30°	>30°
pronation-supination (−)	<1/3	<2/3	>2/3
pes transverso-planus	none	slight	marked

Objective results (Table 9) Cedell's classification was used, with minor modifications (Table 8) One of the operated patients had a moderately increased circumference of the lower leg Among the four non-operatively treated patients with a "medium" result three had ligamentous tenderness and one a reduced calf circumference Of these four patients three had moderate symptoms after exertion

Radiological results (Table 10) The injured ankle joint – and the contralateral joint for comparison – were investigated radiologically The examination included the oblique projection advocated by Bolin (1961) which best reproduces the fibular malleolar rotation and visualizes the joint between the fibula-malleolus and talus

Neither group showed any changes in position as compared with the primary radiological result after the initial treatment. There was no instance of pseudarthrosis Radiological signs of arthrosis were found in one of the operated patients who had a "good result of reduction and no symptoms or signs and in four of the non-operatively treated patients all of whom had a "poor" position of the fracture and two of them complaints on extra exertion.

The results of operative and non-ope[illegible] treatment were subjected to a two[illegible] statistical test by the Fisher exact [illegible] The following test probabilities were [illegible] subjective symptoms $P = 0.71$, [illegible] findings $P = 0.36$, radiological [illegible] $P = 0.36$ As none of these P values is [illegible] 0.05, there is no statistically sig[illegible] difference between the results of the [illegible] methods.

DISCUSSION

In a follow up study made to compar[illegible] results of operative and non-ope[illegible] treatment it is important that the [illegible] materials should be as well-defined [illegible] possible particularly with regard to the [illegible] and severity of the injuries Several [illegible] (Burwell & Charnley 1965 Cedell [illegible] Maatz & Nonnemann 1973 Yde [illegible] consider that the Lauge Hansen classi[illegible] of types and stages affords so far the [illegible] accurate description of ankle fracture [illegible] well suited for recording and assess[illegible]

Table 9 Late objective results (classification according to Cedell 1967)

	Operative treatment	Non-operative treatment
Good	33	31
Medium	1	4
Poor	0	0
Total	34	35

Table 10 Radiological arthrosis (cla[illegible] according to Magnusson 194[illegible]

	Operative treatment	Non-operative treatment
0	33	3
(+)	1	4
+	0	8
++	0	5
+++	0	6
Total	34	35

-atment of such injuries (Willenegger, 1961, erbruggen & Willenegger 1973)

There is a satisfactory similarity between e sex ratio, the primary fracture displace-ent, and the follow-up period in the two aterials. On the other hand, the -cupational exertion on the ankle joint is -eater in the operatively than in the non-peratively treated group (cf Table 3) A inor inaccuracy in staging the SE fractures the evaluation of whether the deltoid gament is injured In the non-operatively -eated group the staging is based exclusively n clinical and radiological data, whereas in ie operated group the operative finding is icluded as well This is the reason why the on-operative group may erroneously include few fractures of the type SE IV having njury of the deltoid ligament (Cedell 1967)

Comparison of the late results with Baek Kristensen's analysis from 1953, after closed eduction by the principles of Lauge Hansen 1942), shows no difference Muschter & Götz 1974) also showed that non-operatively reated SE II injuries have a "good prog-iosis" Cedell (1967), analysing 38 operatively treated SE II injuries after a ninimum follow-up period of 5 years, found 16 to be subjectively "good", one "medium", and one "poor", objectively 31 "good", seven "medium", and none "poor" Only one patient had developed radiologically visible arthrosis.

Supination-eversion fracture in stage II is generally – and apparently rightly – con-sidered a relatively benign injury which leaves few major permanent complaints This con-tributes to the difficulty in demonstrating any differences in the results of the therapeutic methods Larger series than the present ones and perhaps a longer observation time are presumably needed to decide whether the dis-placement of the lateral malleolus persisting after non-operative treatment affords the same possibility of free function of the ankle joint as open reduction obtaining union of the lateral malleolus in a radiologically accurate anatomical reduction

REFERENCES

Bolin H (1961) The fibula and its relationship to the tibia and talus in injuries of the ankle due to forced external rotation *Acta radiol (Stockh)* 56, 439

Burwell, N H & Charnley, A D (1965) The treatment of displaced fractures at the ankle by rigid internal fixation and early joint movement. *J Bone Jt Surg* 47 B, 634–660

Cedell, C.-A & Wiberg, G (1962) Treatment of eversion-supination fracture of ankle (2nd degree). *Acta chir scand* 124, 41–44

Cedell, C A. (1967) Supination-outward rotation injuries of the ankle. *Acta orthop scand.*, Suppl 110

Danis, R (1949) Les fractures malléolaires. *Theorie et pratique de l'osteosynthese* Masson, Paris.

Kristensen T B (1953) *Ankelbrud* Nyt nordisk forlag, København.

Lauge Hansen N (1942) *Ankelbrud I Genetisk diagnose og reposition* Munksgaard, København

Maatz, R & Nonnemann H C. (1973) Bericht uber 938 bimalleolare Luxationsfrakturen. *Chirurg* 44, 456–560

Magnusson R. (1944) On the late results in non-operated cases of malleolar fractures. I Fractures by external rotation. *Acta chir scand*, Suppl 84

Muschter, K & Gotz K. (1974) Ergebnisse konservativ behandelter Sprunggelenkstraumen mit Beteiligung der Syndesmose *Zbl Chir* 99, 267–274

Muller, G M (1945) Fractures of the internal malleolus. *Brit med J* 2, 320

Riede, U., Willenegger, H & Schenk, R (1969) Experimenteller Beitrag zur Erklarung der sekundaren Arthrose bei Frakturen des oberen [illegible] 348

Te[illegible] Die [illegible] bei [illegible] 93, 80–86.

Weber, B G (1966) Die Verletzungen des oberen Sprunggelenkes. *Aktuelle Probleme in der Chirurgie*, Vol 3 Verlag Hans Huber, Bern und Stuttgart.

Willenegger, H (1961) Die Behandlung der Luxations-frakturen des oberen Sprunggelenkes nach biomechanischen Gesichtspunkten. *Helv chir Acta* 28, 225–239

Yde, J (1980) The Lauge Hansen classification of malleolar fractures. *Acta orthop scand* 51, 181–192.

Correspondence to Kristian D Kristensen, M D, Arsenalvej 68 DK-9800 Hjørring Denmark

PROCEEDINGS OF THE FINNISH ORTHOPAEDIC ASSOCIATION

Helsinki, Finland, November 10, 1979

EDITOR A. ALHO

ULTRASONIC WELDING OF EXPERIMENTAL OSTEOTOMIES

H Aro, H Kallioniemi & A J Aho

Departments of Medical Chemistry, Oral Surgery and Surgery, University of Turku, Turku

Thirty-two scapular osteotomies were performed in rabbits Ultrasonic osteosynthesis was carried out by applying a mixture of ethyl-cyanacrylate liquid monomer and bone chips at two different sites in the osteotomy line and polymerizing it with ultrasound (URSK – 8N, Medexport, Moscow) Control osteotomies were fixed with steel wires The stability of the osteotomies was tested manually and the stage of healing was estimated by radiographical and histological examination up to 8 weeks after surgery

The results revealed that 41 per cent of the welded osteotomies (7/17) and 93 per cent of the controls (14/15) were stable Histologically ultrasonic welding inhibited new bone formation and even after 8 weeks the osteotomies showed fibrous union Inflammatory cell infiltration was moderate at the welding sites. By contrast, the controls had osseous union as early as 2 weeks after surgery

In conclusion, the present study revealed that ultrasound as a method of osteosynthesis has marked disadvantages as regards bone healing

TORSIONAL STRENGTH OF CORTICAL AND CANCELLOUS BONE GRAFTS AFTER RIGID PLATE FIXATION

P Waris

Surgical Hospital, University Central Hospital, Helsinki

Biomechanical properties of cortical and cancellous interposition grafts in rabbit tibiofibular bones fixed with 6-hole DCP/ASIF plates were investigated with torsional loading 3 to 52 weeks postoperatively

In cortical grafts, torque, energy absorption and [illegible]

weeks, of the torque and energy absorption capacity of the cancellous grafts.

From 12 to 52 weeks the values of the biomechanical properties of both graft types decreased At 36 weeks the mean values of torque, *energy absorption, torsional rigidity and angle* deformation for cortical grafts were 39, 34, 57 and 82 per cent of the control bones, and those for the cancellous grafts were 26, 17, 42 and 58 per cent, respectively

REVASCULARIZATION OF PERIOSTEAL GRAFTS

M Poussa

Orthopaedic Hospital of the Invalid Foundation, Helsinki

Acta orthop scand 51, 197–204

EXPERIMENTAL GROWTH DISTURBANCE OF THE ACETABULUM AND DISLOCATION OF THE HIP

J Soini & V Ritsila

Orthopaedic Hospital of the Invalid Foundation, Helsinki

The aim of this study was to clarify the role of dysplastic acetabular growth disturbance in the development of experimental subluxation or dislocation of the hip

Acetabular growth disturbance was provoked operatively in 3-week-old growing rabbits by performing a wedge resection extra-articularly in the acetabular roof The growth of the hip was observed at regular intervals. During the follow-up, a disturbance of acetabular growth was noted

0001 6470 80 040703 $02.50 0

which later led to a dislocation or subluxation with typical secondary changes

From these preliminary studies, it appears that acetabular growth disturbances could be induced repeatedly with the method applied

SKELETAL BLOOD FLOW IN THE RABBIT MEASURED WITH RADIOACTIVE MICROSPHERES

K Aalto
Surgical Hospital, University Central Hospital, Helsinki

The distribution of cardiac output was measured in 14 adult white New Zealand rabbits. Radioactive microspheres were introduced into the arterial circulation by a left ventricular injection The skeleton was removed from the carcass after boiling in a pressure cooker and the activities were measured The proportion of the cardiac output distributed in the skeleton averaged 5 64 per cent, SD 0 96 per cent

In 10 rabbits a diaphyseal tibia osteotomy was performed and stabilized by external fixation The proportion of the cardiac output found in the intact tibia was 0 12 per cent, SD 0 07 per cent The circulation in the osteotomized tibia as compared with the intact bone from the 6th to 30th postoperative day was significantly higher, 0 21 per cent, SD 0 09 per cent ($P<0\ 01$) Autoradiography and histology revealed that most of the injected particles present at the osteotomy site were in the endosteal callus, indicating centrifugal blood flow in the tibia after osteotomy

PERIOSTEAL AND PERICHONDRAL GRAFTS IN RECONSTRUCTION OF THE PATELLAR JOINT SURFACE

V Ritsilä, M Poussa, J Rubak, O Snellman & K Österman
Orthopaedic Hospital of the Invalid Foundation, Helsinki

In our original studies (*IRCS Medical Science* 3 49–50, 1975) we utilized perichondral as well as periosteal grafts to restore experimental cartilage defects of the knee joint We have now applied our method to the reconstruction of the patellar cartilage in three patients. The graft was taken from the periosteum of the tibia or the perichondrium of the costal cartilage Two of the patients were females 16 and 35 years old, and one patient was a 28-year-old male All had sustained severe chondral injuries. Postoperatively the patients were followed up for more than a year All improved subjectively Arthroscopy visualized a smooth patellar surface and biopsy of the grafted area revealed hyaline cartilage. We conclude that free periosteal and perichondral grafts maintain their vitality and form cartilage and bone The grafts retain part of their extracellular message but they can also adapt to environmental factors as undifferentiated tissues

FACTORS INFLUENCING THE RESULTS OF OPERATIVE FUSION OF THE LUMBOSACRAL SPINE

T. Tunturi
University of Tampere and Central Hospital, Tampere

One hundred and two patients out of a total of 119 were accepted for the study after a radiologically successful posterior fusion of the lumbar spine The follow-up period was on average 4 8 years. Data obtained from the patients' records and from questionnaires relating to social factors were subjected to a multiple-step regression analysis (*Acta orthop scand* 50, 415–425, 1979)

The factors that had a statistically significant and independent effect on the operative results may be summarized as follows The operative results improved with decreasing duration of preoperative disability, with increasing number of fused segments, with decreasing strenuousness of preoperative work, with rising social position, with rising educational level and with decreasing number of previous back operations. Age had no significant effect on the operative result. In conclusion vocational and other social factors affect the result of lumbosacral fusion and should be considered before subjecting the patient to operation

TREATMENT OF LUMBAR SPONDYLOLISTHESIS IN YOUNG PATIENTS USING FREE OSTEOPERIOSTEAL GRAFTS

K Österman, V Ritsilä & O Snellman
Orthopaedic Hospital of the Invalid Foundation, Helsinki

Our experimental and clinical studies have shown that free periosteal grafts under the proper circumstances possess great bone forming capacity Solid fusion of the lumbar spine of the rabbit can be achieved using this method. Fusion of the scoliotic spine with osteoperiosteal grafts in connection with the Harrington method has also proved successful.

Thirty-six young patients with spondylolisthesis were treated using osteoperiosteal grafts. In

of the patients the slipping was more than one third of the vertebral body Posterior fusion was carried out in 20, posterolateral in 8, and fusion and laminectomy in 8 patients. Fusion of the affected segment was obtained in 31 patients. Twenty-five patients were symptom-free postoperatively, five patients had some low back pain after exercise and six patients had radiating pain Follow-up time varied from 1 to 4 years.

PRELIMINARY RESULTS OF 100 LUBINUS PROSTHESES IN TOTAL HIP REPLACEMENT

T Tervo, H von Bonsdorff & S Hakkinen
Department of Orthopaedics, Central Hospital of Central Finland, Jyväskylä

Sixty-six women and 34 men were operated on The indication for the total hip replacement was primary osteoarthrosis – 57, secondary osteoarthrosis – 18, and rheumatoid arthritis – 25 Fourteen hips had been operated on earlier Follow-up time varied from 1½ to 2¾ years.

The evaluation of the radiographic severity was made according to Rønningen & Langeland (*Acta orthop scand* 50 169–174, 1979) The index sum was on average 11 7 in the II° group (30 hips) and 14 9 in the III° group (70 hips)

The patient's own opinion of the result was good in 71, satisfactory in 27 and poor in 2 hips, the opinion of the authors gave figures of 83, 15 and 2, respectively There were no infections, one early dislocation, one femoral stem loosening, one avulsion of the lesser trochanter, early signs of resorption of the stump of the femoral neck (less than 3 mm) in 6 hips and ectopic bone formation in 19 hips (with no clinical symptoms).

SECONDARY HYPERALDOSTERONISM AFTER SEVERE TRAUMA

P Slatis, A Kaustc & S Santavirta
Division of Orthopaedic Surgery and Traumatology, Surgical Hospital, University Central Hospital, Helsinki

Ten patients being treated in the intensive care unit were studied for changes in plasma aldosterone concentrations during an 8-day period after a major injury Eight of the patients had sustained a blunt injury and two had a burn trauma The average amount of fluid replacement during the first 24 hours amounted to 6273 ± 3523 ml. Three patients died

An increase in plasma aldosterone was consistently found after trauma. Peak values, 253 3 ± 196 0 ng/l were registered immediately after admission to the hospital. The aldosterone concentrations then fell to 180 0 ± 193 0 ng/l on the first day and 97 2 ± 73 8 ng/l on the second day after the trauma. The reaction subsided within 3 days and subsequently the aldosterone concentrations remained within normal limits.

High initial aldosterone values were recorded especially in the burn cases. There was no sign of persistent secondary hyperaldosteronism. Sodium depletion, however, caused a transitory increase in the aldosterone level in one case

THE RICHARDS COMPRESSION SLIDING NAIL IN FRACTURES OF THE PROXIMAL END OF FEMUR

P Vanttinen, O Kiviluoto & P Salenius
Department of Orthopaedics and Traumatology, University Central Hospital, Helsinki

From April 1978 to June 1979, 46 patients (mean age 67 years) were treated with the Richards compression sliding nail. The fractures were subcapital –4, transcervical–8, intertrochanteric–10, and pertrochanteric–24

During the 7-month follow-up period, change of position was observed in three neck fractures, and three pseudarthroses ensued However, there was not a single change of position or non-union among the pertrochanteric fractures, although nine of these patients subjected their extremity to full weight-bearing within 10 days.

Bony union ensued within 1 month in 12 cases, in 2–4 months in 24, and in 4–6 months in 6

One patient developed a deep infection, which responded to antibiotics. The causes of three postoperative deaths were myocardial infarction, cerebral thrombosis and pneumonia The frequency of complications was higher ($P < 0.001$) in the subseries of patients treated surgically more than 3 days after trauma, compared with those whose operation took place within 3 days.

THE RYDELL OSTEOSYNTHESIS IN THE TREATMENT OF FEMORAL NECK FRACTURES

M Talja, M Rusanen & L Lauttamus
Lahti Town Hospital, Lahti

Since 1972, the Rydell osteosynthesis, described in 1961, has been performed in 31 cases (14 men, average age 55.3 years, 17 women, average age

71 3 years) The result was good in 15 out of 17 cases with Garden stage I and II fractures Poor results were found in 8 out of 14 cases with stage III and IV fractures

Osteonecrosis of the femoral head was found in four cases Two post-operative femoral neck dislocations occurred due to operative errors One patient complained of marked postoperative stiffness of the hip In one case a subcapital refracture was observed 9 months postoperatively One patient developed pseudarthrosis and one died three weeks postoperatively because of pulmonary embolism

During the last 3 years the Rydell nail has been used only in undislocated and minimally dislocated femoral neck fractures The internal fixation pin seems to exclude sliding, without disturbance to the impaction of the fracture during loading

PROGNOSIS OF PATIENTS WITH FEMORAL NECK FRACTURE

P Luthje
Central Hospital of Central Finland, Jyväskyla, Department of Clinical Sciences, University of Tampere, and Tampere Central Hospital, Tampere

The ability to cope socially was studied with the aid of interviews, 3 to 5 years after the trauma, in 54 patients operated on for femoral neck or trochanteric fracture, in 50 patients not yet operated at the time of the interview and having fractures in the same locations, and in 48 control subjects of the same age The groups did not differ in terms of marital status, education state of health, and leisure activities.

Prior to the injury, the social adaptation of the non-operated patients was either slightly ($P < 0\ 025$) or markedly ($P < 0\ 0025$) reduced when compared with the controls, and they had to be helped in all activities more often than the operated patients ($P < 0\ 025$) or the controls ($P < 0\ 05$) The patients not yet operated on were less able to cope in their daily activities than were the controls ($P < 0\ 005$) At follow-up 24 per cent of the operated patients and 10 per cent of the control persons lived in nursing homes and hospitals Twenty-four per cent of the non-operated patients lived in similar institutions at the time of the injury The mortality during the follow-up time was 50 per cent In conclusion, it can be stated that the ability of patients with femoral neck and trochanteric fractures to cope socially is reduced

CORRELATION BETWEEN [illegible]

M Harkonen
University of Tampere and Central Hospital [illegible]
Tampere, Tampere

A total of 313 out of 460 patients with [illegible] injuries were followed up for an average of 5 [illegible] and 3 months. The distribution of the [illegible] as follows C1–C7, 119, Th1–Th11, [illegible] Th12–L1, 149, and L2–L5, 94 Flexion, [illegible] angulatory deformity, compression, [illegible] narrowing of the vertebral canal, [illegible] terpediculate distance, increase in [illegible] distance and lowering of the disc space [illegible] examined radiologically

During the follow-up the forward sliding [illegible] narrowing of the vertebral canal in the [illegible] spine were reduced to a marked extent. The [illegible] radiological deformities showed a tendency [illegible] deteriorate Narrowing of the vertebral canal [illegible] forward sliding were most often associated [illegible] neurological symptoms. The clinical result [illegible] patients with injuries of the [illegible] thoracolumbar and lumbar segments [illegible] great extent to depend on the findings on the [illegible] radiographs. In cervical spinal injuries [illegible] clinical results were noted in connection [illegible] persisting radiological deformities.

In the patients with cervical spinal [illegible] the goal of the treatment should be to achieve [illegible] anatomical result The present [illegible] not permit any confident conclusion [illegible] to the usefulness of correcting deformities [illegible] spinal segments.

ARTHROGRAPHY IN THE DIAGNOS[illegible] LIGAMENT INJURIES OF THE ANKLE

T Raatikainen & J Puranen
Oulu University Central Hospital, Oulu

During 1970–1978, 120 lateral ligament [illegible] of the ankle were diagnosed by arthrography [illegible] operatively treated in the Oulu University Cen[illegible] Hospital. In 50 ankles there was an isolated [illegible] rupture of the anterior fibulotalar (FTA) [illegible] and in 60 ankles a combined injury of the F[illegible] and the fibulocalcanear (FC) ligament. An [illegible] rupture of the FC ligament was found in [illegible] ankles. The arthrographic diagnosis was [illegible] 109 of the 110 cases of FTA rupture [illegible] cent) The typical X-ray finding was the [illegible] the contrast medium out of the joint space [illegible] and on the lateral side of the lateral [illegible]

arthrography on the basis of spread into the peroneal tendon sheaths. Furthermore the rupture was suspected in five cases in which there was noticeable spread at the calcanear insertion of the TC ligament. Thus the X-ray diagnosis was correct in 87 per cent of these injuries. There were no cases of pathological findings in arthrography without a ligament rupture.

CORRECTIVE OSTEOTOMY OF TRAUMATIC HUMERUS VARUS

M Vastamäki & K. Solonen
Orthopaedic Hospital of the Invalid Foundation, Helsinki

Postfractural varus deformity of the humeral neck was treated with high corrective osteotomy of the humerus in seven adult patients (four males and three females). The average age was 41 years. All had been subject to high energy trauma. Indications for operative treatment were severely limited abduction (under 60°) and forward flexion of the arm. Wedge osteotomy was performed through a deltopectoral incision and fixation was with a T-formed AO-plate, on average 11 months after the injury. The follow-up time varied from 6 months to 11 years.

Six patients regained complete or almost complete painless motion. In the remaining case the result was only "satisfactory" because of frozen shoulder severe muscle atrophy and poor motivation for recovery. This correction of varus and rotational deformity appears to be a useful method in cases where the glenohumeral joint is not damaged and the soft tissue contractures are not severe.

FRACTURES OF THE CARPAL SCAPHOID IN CHILDREN

V Vahvanen & M Westerlund
Aurora Hospital, Helsinki

One hundred and eight children with carpal scaphoid fractures were followed until radiological fusion occurred. All fractures united during conservative treatment. The locations of the fractures were: distal third – 87 per cent (avulsions – 38 per cent), waist – 12 per cent, and proximal pole – 1 per cent. *The large number of avulsion* fractures and the location of the fractures in the distal third of the scaphoid were typical for children. In three neglected cases of waist fracture large bone resorption occurred on the fracture surfaces, but conservative treatment started in two cases at 3 weeks, and in one case at 3 months, resulted in fusion. Generally an immobilization time of 4–8 weeks in the classical plaster cast was enough, but in neglected cases and in cases with major bone resorption a longer period of immobilization, up to 16 weeks, was needed.

DIAGNOSIS AND TREATMENT OF ACUTE DISLOCATION OF THE PATELLA

E Karaharju, P Slätis, D Hallikainen & J Joukainen
Division of Orthopaedic Surgery and Traumatology, Surgical Hospital, University Central Hospital, Helsinki

To be published.

INJURIES OF COMPETITION SKIERS IN FINLAND. A THREE-YEAR SURVEY

J Sandelin, O Kiviluoto & S Santavirta
Department of Orthopaedics and Traumatology, University Central Hospital, Helsinki, and Porvoo District Hospital, Porvoo

This epidemiological study was performed in 1976–1978 in cooperation with the Pohjola Insurance Company and the Finnish Skiing Association.

The total number of licenced competition skiers in Finland in 1978 amounted to 7,814, 7 052 participating in cross-country skiing, 275 in ski jump and 487 in downhill events. During the 3-year period a total of 180 serious accidents were registered. Ski jumpers had 39 injuries and the risk of injury was highly significantly ($P<0.001$) greater than in downhill events (27 injuries) or cross-country (57 injuries). Fractures and luxations predominated in both ski jump and downhill events, muscle and tendon injuries were the largest group in cross-country. With ski jumpers the injury was predominantly located in the head or neck, while lower extremity trauma was more common in cross-country and downhill skiers. The risk of malleolar injuries was highest in ski jumping while downhill skiers had more knee injuries. Twenty-five per cent of the injuries were fractures and 18 per cent of the patients had operative treatment. Ski jumpers required four *times more sick leave days* than those in downhill events and ten times more than cross-country skiers.

TIBIAL OSTEOTOMY, A FIVE TO TEN YEAR FOLLOW-UP STUDY

S Vainionpää, E Läike, P Kirves & P Tiusanen
Kotka Central Hospital, Kotka

Between January 1969 and June 1974 145 knees in 135 patients were operated on because of osteoarthritis of the knee A wedge osteotomy was used in all cases Ninety-six of the 116 patients still alive (105 knees) were seen at the follow-up examination in 1979 The average postoperative follow-up time was 7 years with a minimum of 5 years All osteotomies united without reoperation In 89 knees (84 7 per cent) the initial result was good or fair Best results in cases of varus deformity were achieved with a 7° overcorrection and in valgus deformity when the femorotibial angle was corrected to 171°–178° Deterioration was noted in 26 cases after an initially good result, this seems to be a higher rate than earlier described In 16 knees total arthroplasty was indicated because of a poor result. In 15 of the 19 knees with preoperative instability the result was good or fair All five knees with initial subluxation less than 12 mm became good or fair after osteotomy Thus, instability and minor subluxation are not, according to this study, obvious contraindications for osteotomy

XANTHOMAS OF THE ACHILLES TENDON

P Paavolainen, E Karaharju & T Holmström
Surgical Hospital, University Central Hospital, Deacons Hospital, Helsinki, Department of Pathology, University of Helsinki, Helsinki

Two patients had bilateral xanthomas in the Achilles tendons associated with type II hyperbetalipoproteinaemia inherited as an autosomal dominant Both patients had elevated serum cholesterol normal or slightly elevated serum triglycerides and an electrophoretic pattern of elevated beta lipoproteins. Subtotal resection of the tumours was found to be satisfactory in both patients. The alternative is total excision and reconstruction of the defect with fascial grafts. The surgical interventions for the tendon [illegible] medical [illegible] lipid metabolism

The early recognition and evaluation of patients with hyperbetalipoproteinaemia is important because of an increased incidence of atheromatous coronary heart disease, manifesting at an early age

PRIMARY MALIGNANT FIBROUS [illegible]TIOCYTOMA OF BONE

P Jussila, T Sorvari & T Romppanen
Division of Orthopaedic Surgery and Traumatology, Surgical Hospital, [illegible] Central Hospital, Helsinki, and Department of Pathology, University Central Hospital, [illegible]

A review of 869 malignant primary bone tumours yielded nine lesions with features allowing classification as malignant fibrous histiocytoma Correlation with clinical data and roentgenograms indicated that these tumours occurred as osteolytic lesions associated with pathological fractures in metaphyses of long bones. Five patients received ablative radical surgery, two patients were not given any [illegible] treatment, one was given radiation treatment and one chemotherapy for their tumours. [illegible] patients had pulmonary metastases and one [illegible] metastasis in the lymph nodes. The average survival period was 1 7 years and the [illegible] survival was 22 per cent. Six patients underwent surgery, chemotherapy or radiation therapy for their metastases Primary malignant fibrous histiocytoma of bone is a very malignant tumour and treatment should be the same as for osteosarcoma Radiation and chemotherapy are also recommended. The differential diagnosis of [illegible] teolytic osteosarcoma and fibrosarcoma is [illegible]

EXPOSED KNEE JOINT IN AVULSION INJURIES OF THE LOWER EXTREMITY

S Asko-Seljavaara & J Haajanen
Division of Plastic Surgery and Department of Orthopaedic Surgery and Traumatology, Surgical Hospital University Central Hospital, Helsinki

Two cases are reported in which the exposed knee joint was covered with well-vascularized [illegible] tissues. In the first case a medial [illegible] myocutaneous flap was used to cover the [illegible] knee joint The cutaneous part of the [illegible] extended over the avulsed patella and [illegible] ligament The donor area of the flap and the degloving injury of the thigh were covered with meshed split skin grafts. In the second case, a lateral gastrocnemius muscle flap was used [illegible] the transposed muscle was covered with [illegible] split skin grafts. The primarily covered [illegible] healed without complications. The [illegible] myocutaneous flap forms well-vascularized [illegible] tissue over the joint, and later it is easy to [illegible] the joint for further reconstructions.

THE USE OF RADIOISOTOPE BONE SCANNING IN DISEASES OF THE FACIAL BONES

A Tasanen
Helsinki Finland

The observations in 50 patients were as follows – In primary gingival cancer the bone image appears larger than in normal radiography – In lung and breast cancer patients unexpected metastases in the mandible may be found. – All inflammatory processes markedly increase the radioisotope uptake in the mandible as in all bones. This is especially valuable in primary chronic osteomyelitis. – Fibrous dysplasia results in highly increased isotope uptake instead of monostotic dysplasia, tetrostotic dysplasia may be seen in the bone scan – Growth disturbances in the condylar head may be detected in hemimandibular hypertrophy of unilateral hyperplasia of the condylar head – Increased uptake is also seen in eosinophilic granuloma dentigerous cyst and active arthrosis of the temporomandibular joint

ta orthop scand, 51, 711–718 1980

SYMMETRIC BIPHASIC VOLTAGE STIMULATION F THE OSTEOTOMIZED RABBIT BONE

ARO[1] A J AHO[2], K VAAHTORANTA[1] & T EKFORS[3]

-partments of Physiology[1], Surgery[2] and Pathological
ıatomy[3], University of Turku, Turku Finland

An experimental study was performed to determine the effect of electric current on the healing of osteotomies in the antebrachium of the rabbit. Starting with the assumption that the waveform of biphasic asymmetric voltage simulates the asymmetric pattern of stress induced physiological electrical potentials in normal bone, biphasic asymmetric voltage was applied to the osteotomized radius or ulna The effects of the electrical stimulation were evaluated by means of X rays and histological studies. The voltage supplied induced periosteal proliferation whether implanted, insulated electrodes were employed or uninsulated external transfixation pins were used as electrodes. The stimulation had not only osteogenic but also chondrogenic effect The external callus formation at the osteotomy sites and around the transfixation pins proved to be greater in the stimulated animals th in in the controls.

Key words chondrogenesis electrical stimulation, fracture healing, osteogenesis

Accepted 3 iii 80

'he occurrence of mechanically induced lectrical potentials in bone (Fukada & asuda 1957, Cochran et al 1968) may play n important part in the regulation of fracture ealing and bone remodelling, and in the pre- ention of osteoporosis. Furthermore, osteo- :ogenic effects can be produced in bone by pplication of different types of electric urrents constant direct current (Friedenberg t al 1970), pulsed direct current (Levy & Rubin 1972) and alternating current (Klapper & Stellard 1974) Electricity has been applied o bone using an invasive technique, in which lectrodes are implanted into bone Friedenberg et al 1970) or using a non- nvasive technique, in which case stimulating urrent is induced in bone electromagneti- ally (Bassett et al 1974)

Despite intensive work during the last two decades the most efficient form of electricity for this purpose remains undiscovered (Brighton 1977) Hassler et al (1977) have shown a correlation between healing quality and power dissipation when direct current and alternating currents were applied The significance of asymmetry in voltage wave- form emphasized by Bassett et al (1977) was not studied however

Since mechanical stress during walking generates asymmetric, intermittent and bidirectional potentials in bone (Cochran 1974), it seems reasonable that asymmetric alternating current or voltage should be active in stimulating osteogenesis. Only Bassett (1971) has reported some preliminary results of the use of asymmetric alternating current, i e an alternating current containing a direct current component He noticed, for example, that an asymmetric alternating current increased osteogenesis at the cathode, while

0001-6470 80 050711-08$02.50 0

symmetric alternating current did not result in increased new bone formation at either electrode. Jörgensen (1972, 1977) has reported promising clinical experience with the use of a slow pulsating, asymmetric direct current stimulation in human crural fractures, yet the shortage of experimental studies has hampered the evaluation of the results.

On the basis of the information given above we started to investigate the effects of stimulation with asymmetric biphasic voltage (i.e. a direct current containing bipolar alternating current pulses) using osteotomized rabbit bones. We also tried to develop a *standardized experimental fracture* with external transfixation for the evaluation of the effectiveness of electrical stimulation on bone repair.

MATERIALS AND METHODS

Animals and surgical techniques

Sixteen mature rabbits, weighing from 2.5 to 3.6 kg, were operated on under intravenous pentobarbitone sodium (Nembutal®, Abbot) anaesthesia. Surgical sterility was maintained.

Radius series

In the radius series of five rabbits the distal shaft of the bone was exposed and a 2 mm transverse osteotomy was made using an oscillating saw. Two holes 1.0 mm in diameter were drilled in the cortex using a dentist's drill. The holes, which penetrated into the medullary cavity, were placed one proximal and one distal to the osteotomy at a distance of 5 mm. Ten per cent iridized platinum electrodes (0.5 mm) insulated with teflon (Alu Oy, Finland) were used. The bone electrode was fixed with the aid of chromic catgut into the distal hole of the radius so that the bent uninsulated 2 mm long tip of the electrode extended from the periosteum to the medullary cavity (invasive technique). The second electrode was fixed with chromic catgut to the soft tissue close to the osteotomy gap. The electrodes ran subcutaneously to the shoulder region to emerge from the skin. The emerging parts of the electrodes were covered with a silicone rubber tube to prevent skin irritation. The electrodes were connected to the insulated copper leads from the stimulator by the detachable connector which was fixed to the leather harness of the rabbit. The stimulator was placed on top of the wire mesh cage (Figure 1).




Figure 1 Diagram of the implanted [illegible] electrode leads in relation to the osteotomy of the rabbit radius

Ulna series

An external transcutaneous fixation method was used in the ulna series of five rabbits. The method made it possible to combine the direct stimulation and the immobilization [illegible] (non-invasive technique). The ulna was used for practical reasons. The osteotomy was easier to perform due to the greater diameter of the bone and use of the ulna made an external transfixation possible. A transverse osteotomy was made at the proximal shaft of the ulna. The osteotomy was



Figure 2 Illustration of the radiographic appearance of the osteotomized rabbit ulna stabilized with two Kirschner pins, which are used as electrodes

ansfixed by two parallel Kurschner pins 1 2 mm in ameter The pins were inserted transcutaneoulsy bove and below the site of the osteotomy and stened together by metal plates insulated with ibber The pins, left uninsulated in bone and soft ssues, were used as electrodes. Lead connections to ie stimulator were similar to those of the radius ries

ontrol series

Identical surgical procedures and fixations were erformed in the control series of six rabbits but ie electrodes were not connected to the imulator

lectrical stimulator

The voltage supplied was selected on the basis f previous knowledge

1 The voltage waveform recorded on the urface of a dog's radius in a walking simulator as potentials of unequal amplitude and opposite olarity (Cochran 1974)

2 The optimal frequency is about 0 7 Hz which orresponds to normal walking frequency (Levy 971)

3 The voltage supplied should be limited to 1 V o avoid undesirable electrochemical reactions in issues near the electrodes.

The desired biphasic asymmetric voltage vaveform was achieved by a battery operated ransistorized oscillator delivering both direct current and alternating current (Kone Oy, Instrunent Division, Finland)

The voltage diagrams are shown in Figure 3 Bipolar rectangular alternating current pulses amplitude 100 mV, pulse duration 8 ms, frequency 0 8 Hz) were combined with the constant direct current level, which was 300 mV in the radius series and 100 mV in the ulna series. The currents measured during stimulation had both positive peaks (+22 µA in the radius series and +100 µA in the ulna series) and negative peaks (−18 µA in the radius series and −100 µA in the ulna series). The polarity was kept constant throughout the stimulation in the radius series. In the ulna series the polarity was reversed every 2 days

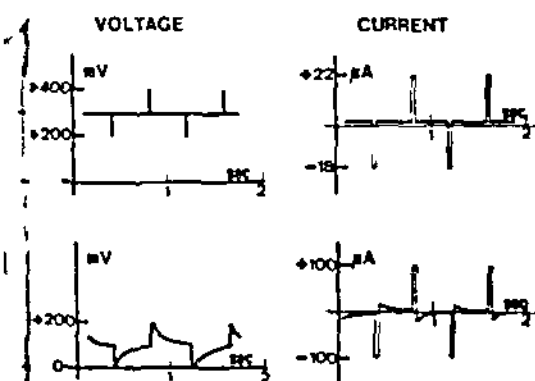


Figure 3 The voltage and current diagrams between electrodes in the radius (top) and ulna (bottom) series

Evaluation methods

After 14 days for the radius series and after 21 days for the ulna series the rabbits were killed by an overdose of pentobarbitone sodium. X ray examinations were performed after killing Bone samples were dissected taking the ulna and the radius together to avoid damaging the fracture area The samples were fixed in 10 per cent buffered formalin, decalcified in New Decalc* (Histo-Lab Sweden) and embedded in paraffin Longitudinal sections were stained with haematoxylin and eosin, van Gieson, Alcian blue and periodic acid Schiff

RESULTS

General observations The rabbits tolerated the experiment satisfactorily The stimulated as well as the control animals lost an equal amount of weight, 200–600 g, during the experiment Three rabbits were excluded from the material owing to wound/pin infection or splintage of bone fragments. The subcutaneously implanted anode leads in the radius series caused soft tissue irritation Histologically the inflammatory cell infiltration was moderate or abundant around the anode leads

Radius series

Macroscopically the periosteal callus in the stimulated animals was observed to extend from the osteotomy site to the midshaft of the radius, in the controls, however, the callus formation was limited to the osteotomy area only

X-ray studies (Figures 4 and 5) revealed a



Figure 4 Anterior X-ray picture of an electrically stimulated osteotomy in the radius 2 weeks after operation Marked fibrous callus extends from the osteotomy site to the midshaft (small arrows) of the bone Calcified callus occurring midshaft and at the osteotomy gap indicated with large arrows Solid white line=position of bone electrode Interrupted black line=position of electrode in soft tissue (× 1 7)




Figure 5 Anterior X ray picture of the osteotomy in the control radius 2 weeks after operation Slight callus visible at the end of the bone fragment (arrow) E=bone electrode Interrupted black line=position of electrode in soft tissue (× 1 7)


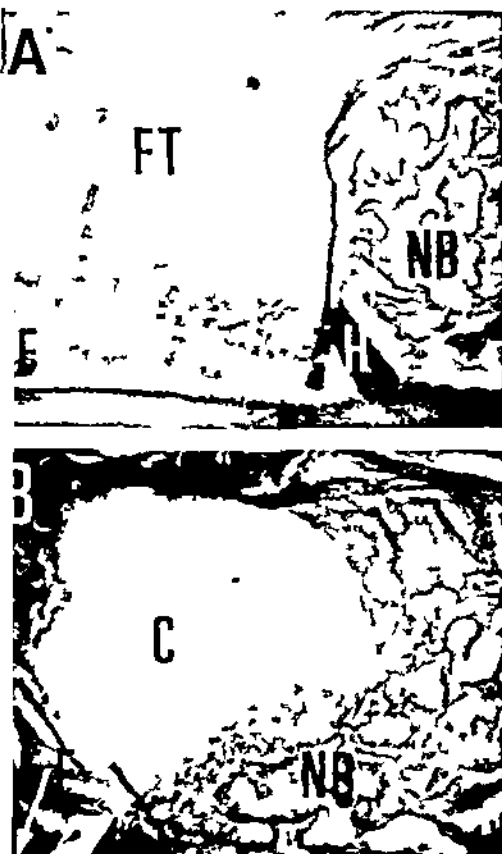


Figure 6 Periosteal reaction in the [illegible] radius in a control animal (A) and in an [illegible] electrically stimulated by [illegible] 14 days (B) New bone formation [illegible] cartilage formation (C) are [illegible] stimulated animal (× 40).

periosteal reaction along the shaft of the stimulated radius, but osteotomies showed no signs of bony consolidation in any of the animals


Histologically the periosteum of the stimulated radius showed marked osteogenic reaction which extended from the osteotomy to the proximal part of the radius. The periosteal reaction consisted of new bone formation but also included cartilaginous areas (Figure 6B) The controls had minimal periosteal new bone formation in the midshaft of the radius (Figure 6A) [illegible] endosteum showed only slight bone [illegible] along the shaft of the [illegible] the controls the endosteal [illegible] formation was found only at the [illegible] site being however greater [illegible] stimulated animals. The [illegible] stimulated animals had [illegible] external callus consisting of new bone [illegible]



gure 7 The osteotomy areas of the radius in a ntrol animal (A) and in a animal electrically

[illegible] ne (NB) is seen only in the periosteum some stance from the fracture gap (F) where fibrous ssue (FT) and a clot (H) are seen (× 15)





igure 8 New bone formation around the ectrode pins (E) in a control ulna (A) and in a imulated ulna (B) 21 days after electrical imulation. Only weak new bone formation (NB) seen in the control ulna whereas in the imulated ulna the electrode pin (E) is surrounded y marked periosteal new bone (NB) The direction f the fixation pins (E) is illustrated by a solid line × 15)

cartilage (Figure 7B) In the controls the external callus consisted of fibrous tissue at the osteotomy sites and new bone was present some distance away from the osteotomy site (Figure 7A)

Ulna series

Macroscopically the electrode pins were found to be surrounded by periosteal callus in all animals and the reaction extended to the osteotomy site In the stimulated animals the observed callus was more distinct

X-ray studies showed that none of the osteotomies had bony uniting callus. A slight periosteal reaction around the pins seemed typical as well

Histologically the most distinct change was to be seen in the periosteum The electrode pins were surrounded by periosteal new bone and the reaction proved to be more pronounced in the stimulated than in the control ulnas (Figure 8A and 8B) The periosteal response consisted of new bone but also contained cartilaginous areas in some of the stimulated animals. The electrode pins were also surrounded by endosteal new bone in the stimulated animals. The controls had only thin trabeculae of new bone around the pins in the medullary cavity All the osteotomies had fibrous union However, the periosteal new bone formation between the osteotomy site and the electrode pins was more pronounced in the stimulated ulnas

DISCUSSION

The results of this study of bone regeneration in the antebrachium using asymmetric biphasic voltage stimulation were found to be beneficial and encouraging It was observed that the periosteal bone and cartilage formation was greater in the stimulated than in the control animals The small number of animals does not, however, allow any statistical analysis. It is probable that the optimal method of inducing [illegible] means of artificially produced [illegible] simulate naturally occurring electrical [illegible] in bone Mechanical stress induces a [illegible] voltage waveform in bone (Bassett [illegible]) which is asymmetric under physiological [illegible]ditions (weight-bearing) (Cochran [illegible]) Bone stimulation by means of a [illegible] asymmetric voltage might simulate [illegible] voltage waveform artificially and [illegible] more closely to the physiological [illegible] events in bone than stimulation by means of a direct current, a pulsed current or [illegible] alternating current.

It is generally accepted that [illegible] promoted only around the cathode ([illegible] 1977) In our study the polarity was [illegible] every 2 days (the ulna series) and [illegible] new bone formation was noted locally [illegible] both the electrodes. When the polarity [illegible] not changed during stimulation (the [illegible] series), electrical stimulation promoted [illegible] periosteal reaction similar to that [illegible] by Connolly et al. (1977). This [illegible] necessary periosteal reaction can be [illegible] due to the irritating effect of the [illegible] mechanism by which positive polarity [illegible] tissue irritation (Jorgensen 1972, [illegible] al 1975) is unknown, but the [illegible] can be avoided if the polarity is [illegible] every 24–48 hours of stimulation ([illegible] 1977) The results of our ulna series [illegible] this observation

The voltage supplied seemed to [illegible] particularly the cambium layer cells [illegible] so much those lining the endosteal [illegible] the cortical bone The stimulated [illegible] developed an external callus that [illegible] osteotomy gap, yet it was the [illegible] tomies that showed a tendency to [illegible] dominantly by medullary callus [illegible] series. It should be noted that [illegible] did not significantly effect the [illegible] osteotomies, because the other [illegible] mized bone of the antebrachium [illegible] splint The reason for the [illegible] of electrical stimulation is [illegible] Rubin (1972) have previously [illegible] same phenomenon when pulsed [illegible]

with a peak current of 500 μA or more s applied The prevailing opinion is that : common factor in cartilage formation is a v oxygen tension (Bassett & Herrmann 61) It can be assumed that the periosteal outgrows its blood supply in the mulated animals and cartilage formation is :refore more prominent in the stimulated nes than in the controls owing to decreased ygen tension Further studies by the thors (Aro et al 1979), on the other hand, ve revealed that electrical stimulation :reases oxygen tension in the fracture area

fact there can be several possible echanisms by which electric current fluences cell behaviour (Bassett et al 1977) As it is desirable in clinical work to avoid ening the fracture area because of the risk contamination, we set out to study the ssibilities of a less invasive method than e one with separate implanted electrodes in e fracture area The study showed that abilization pins for long bone fractures can :ll be used as electrodes instead of local :ctrode leads. This observation confirms the nical reports on the combination of :ctrical stimulation and external transfixa- m (Jorgensen 1972, 1977, Inoue et al 1977, Satzger & Herbst 1976) We have since rther improved the external transfixation ethod by increasing the number of pins. his improved immobilization technique with :eater stability has been found applicable to ie immobilization of a tibial osteotomy in ie rabbit (Aho et al 1978) This ex- :rimental fracture model combined with ectrical stimulation is in principle analogous) the clinical application of electrical imulation when bone rods of the Hoffmann pparatus are used as electrodes in human -ural fractures (Jorgensen 1972, 1977).

'CKNOWLEDGEMENTS

ve are grateful to Mrs. Anja Vuoristo for the istological preparations. This study was upported by a personal grant to H Aro from the innish Orthopaedic Association and by a grant om the Paulo Foundation

REFERENCES

Aho A J, Aro, H, Vaahtoranta K & Ekfors, T (1978) A combined method for electrical stimulation and external transfixation of the tibial fracture of the rabbit A preliminary report European Society for Surgical Research, 13th Congress, Helsinki Abstract p 65

Aro H, Eerola, E & Aho, A J (1979) Oxygen tensions in normal and electrically stimulated fractures. *Acta chir scand*, Suppl 493, 62

Bassett, C A L & Herrmann, L. (1961) Influence of oxygen concentration and mechanical factors on differentiation of connective tissue *in vitro* *Nature (Lond)* 190, 460

Bassett, C A. L. (1971) Biophysical principles affecting bone structure *Biochemistry and Physiology of bone* (Ed. Bourne, G H), Academic Press New York

Bassett, C A L., Pawluk, R. J & Pilla, A A (1974) Acceleration of fracture repair by electromagnetic fields. A surgically non-invasive method *Ann N Y Acad Sci* 238, 242–261

Bassett C. A L, Pilla A A & Pawluk, R J (1977) A non-operative salvage of surgically-resistant pseudoarthroses and non-unions by pulsating electromagnetic fields. *Clin. Orthop* 124, 128–143

Brighton, C T, Friedenberg, Z B, Zemsky, L M & Pollis, P R (1975) Direct current stimulation of non union and congenital pseudoarthrosis. *J Bone Jt Surg* 57-A, 368–377

Brighton C T (1977) Bioelectrical effects on bone and cartilage Editorial comment. *Clin Orthop* 124, 2–4

Cochran, G V B, Pawluk R J & Bassett, C A L (1968) Electromechanical characteristics of bone under physiological moisture conditions. *Clin Orthop* 58, 249–270

Cochran G V B (1974) Acceleration of bone healing by electrical stimulation *Bull Prosth Res* 9, 291–294

Connolly, J, Hahn H & Jardon, O M (1977) The electrical enhancement of periosteal proliferation in normal and delayed fracture healing *Clin Orthop* 124, 97–105

Fukada E. & Yasuda, L. (1957) On the piezoelectric effect of bone *J Physiol Soc Japan* 12, 1158–1162.

Friedenberg Z B, Andrews E T, Smolenski, B I, Pearl, B W & Brighton, C T (1970) Bone reaction to varying amounts of direct current *Surg Gynec Obstet* 131, 894–899

Hassler, C. R., Rybicki E F., Diegle R. B & Clark, L. C. (1977) Studies of enhanced bone

healing via electrical stimuli Comparative effectiveness of various parameters *Clin Orthop* **124**, 9–19

Inoue, S, Ohashi, T, Imai, R, Ichida, M & Yasuda, I (1977) The electrical induction of callus formation and external skeletal fixation using methyl methacrylate for delayed union of open tibial fracture with segmental loss. *Clin Orthop* **124**, 92–96

Jorgensen T E (1972) The effect of electric current on the healing time of crural fractures *Acta orthop scand* **43**, 421–437

Jorgensen, T E (1977) Electrical stimulation of human fracture healing by means of a slow pulsating, asymmetrical direct current *Clin Orthop* **124**, 124–127

Levy, D D (1971) Induced osteoge[illegible] electrical stimulation. *J electrochem. S*[illegible] 1438–1742.

Levy, D D & Rubin B (1972) Induc[illegible] growth *in vitro* by pulse stimula[illegible] *Orthop* **88**, 218–222.

Klapper, L & Stellard R E (1974) Mech[illegible] electrical stimulation of bone format[illegible] *N Y Acad Sci.* **238**, 530–539

von Satzger G & Herbst, E. (1976) E[illegible] stimulation of osteogenesis in two cases [illegible] genital pseudoarthrosis of the [illegible] European Symposium on Electrical St[illegible] of Bone Growth and Repair Brussels [illegible] Abstract 14

Correspondence to Dr Hannu Aro, Department of Medical Chemistry Turku University S[illegible] Turku 52, Finland

Acta orthop scand. 51, 719–726, 1980

THE FORMATION OF STRESS BY ACRYLIC BONE CEMENTS DURING FIXATION OF THE ACETABULAR PROSTHESIS

NIELS J HOLM

The Department of Orthopaedic Surgery T-2, Gentofte Hospital, Hellerup Denmark

The forces developed by acrylic cement during the final phase of polymerization under conditions that simulate the cementing of the acetabular prosthesis are evaluated. Calculations show that forces of 500–1100 N may be reached in a three-point fixational system The importance of the dimensions of the plastic and the bone and the relevance of the E-moduli are discussed

Key words bone cement, hip joint prosthesis

Accepted 17 xi 79

The use of acrylic compounds as a means of fixation of total hip prostheses is a commonly accepted procedure During polymerization the acrylic compound undergoes certain changes in physical properties as it passes from semi-liquid to solid These changes include a change in volume, a change in temperature, and a change in viscosity The commercially available cements differ somewhat in handling characteristics and as shown by various investigators (Ohnsorge & Grotz 1974, Debrunner et al 1976, Holm 1977) they also vary as to certain physical properties. It was therefore found to be of interest to investigate further the behaviour of the most commonly used acrylic cements in order to increase the understanding of the nature of these substances. It is a well known fact that methylmethacrylate reduces in volume when polymerizing, the cement contracts. If this takes place in a situation where the contraction is hindered stress will arise In the present experiment the behaviour of the acrylic cement during insertion of an acetabular component is investigated under conditions that imitate the actual situation

MATERIAL AND METHODS

Design of the apparatus

In order to evaluate the build up of stress in the cement during polymerization under conditions that imitate conditions in the acetabulum an apparatus was designed and constructed The most commonly used surgical procedure when preparing the acetabulum includes the drilling or gouging of three or more holes in the acetabular wall in order to give the acrylic cement good points of purchase in the bone The apparatus (Figure 1) consists of a U-shaped heavy steel bar with a measuring device attached The measuring device consists of a pin that passes through a hole in one branch of the "U" to the other The pin moves a lever which can be coupled to a transducer or a dial gauge Thus any change in the distance between the branches of the U-bar can be measured. The U-bar was dimensioned such that the contraction arising from the polymerization of the cement caused changes in the distance between the branches of the order of magnitude of 100 µ Calibration showed the [illegible] manufacturer As soon as it could be handled the dough was pressed manually into a mould on top

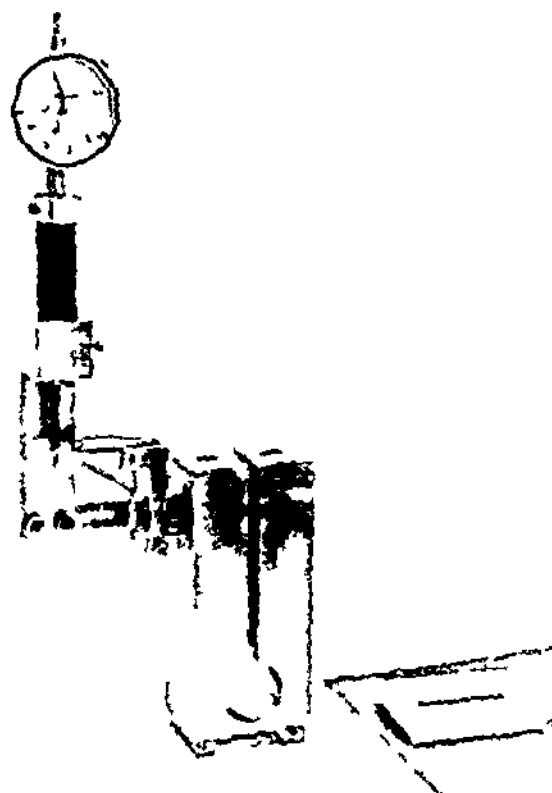


Figure 1 Apparatus for measuring cement shrinkage, mounted with dial gauge Note dovetail grooves with adjustable width on the top of the branches The mould is shown on the side

of the U-bar where it would gain purchase in two dovetail grooves. The mould ensured the correct thickness of the sample and it was removed while the cement was still in the doughy state The experiment thus consisted of a square block of cement on top of the U-bar, fixed in dovetail grooves and contracting freely (Figure 1) The whole assembly was placed in a waterbath at 38° C and all measurements were made at body temperature Samples with the dimensions 20 x 8 mm and 20 x 4 mm in cross-section of each of the types of cement were tested. The dimension of the cement plug in the dovetail grooves was 6 x 6 mm and the distance between the grooves was 26.5 mm. Further samples of 70 mm [illegible] were tested by moulding them over the [illegible] the top of the U-bar A thermocouple was [illegible] in the cement at a depth of 2 mm. The [illegible] was calibrated with a transducer [illegible] simultaneous readings for strain and temper[illegible] were recorded continuously on the graph.

The change in volume of the cement [illegible] polymer[illegible] [illegible] to a [illegible] with a tight stopper and the change in [illegible] was measured in a burette mounted in the [illegible] by recording the rise and fall of the [illegible] water every 20 seconds. The measurements [illegible] started as soon as it was possible to [illegible] cement, i e 2 to 3 minutes after mixing the [illegible]ponents The volumes of the portions of [illegible] used were measured by calculating [illegible] in water by weighing

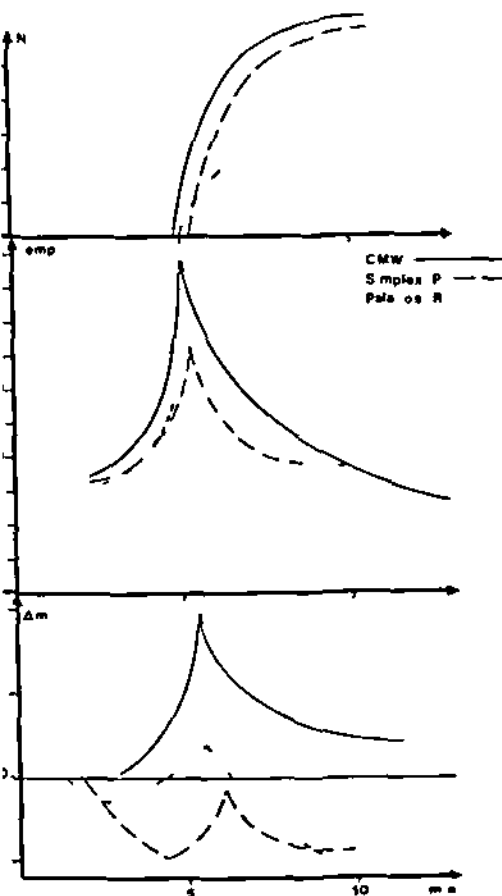
Three brands of acrylic cements [illegible] CMW Bone Cement*, Surgical Simplex P* [illegible] Palacos R* Eight portions of the same [illegible] batch of each brand of cement were [illegible] stress formation

RESULTS

Temperature All cements showed a [illegible] in temperature at a certain and [illegible] brand a fairly constant time [illegible] beginning of mixing the powder and [illegible] liquid The average maximum temperatures reached were between 76° and 94°C. It [illegible] be noted that all cements just 2 mm [illegible] surface reached temperatures that [illegible] above the coagulation temperature for [illegible] This occurred in both 8 mm and [illegible] specimens. CMW showed the [illegible] temperature and the highest average [illegible] the cements where the temperature [illegible] later also showed slightly lower [illegible] temperatures. Mean maximum [illegible] are given in Table 1

Table 1 Average values for force, shrinkage, maximum polymerization temperature and [illegible] shrinkage

Cement	Force N/mm	Shrinkage per cent	Average max temp °C	[illegible]
CMW	2.8 ± 0 03	1 0	94 0	[illegible]
Simplex	2.7 ± 0 06	2.0	76.0	[illegible]
Palacos	1 7 ± 0.05	2 0	84 0	[illegible]



igure 2 The time relationship between the evelopment of force temperature changes and olume changes in acrylic cements

Volume The cements changed volume luring polymerization the changes following consistent pattern in all experiments. The hape of the graphs for Simplex and Palacos vere very similar and showed an initial con raction followed by an expansion again ollowed by a contraction The graph for CMW was somewhat different as it did not how the dip" but demonstrated a con- inuous expansion followed by contraction. Repeated experiments showed that the dip" n the first part of the graph depends on the ambient temperature the "dip" being less pronounced at higher temperatures. The exact magnitude of the change in volume in he first soft phase of polymerization is difficult to assess as a true starting volume cannot be obtained with the method used. For reasons given below these first changes of volume were found to be of no practical con sequence and the matter was pursued no further The graph in Figure 2 demonstrates the force of contraction and the changes in volume and temperature When the volume curves are compared with the temperature and force recordings it will be noted that the time of maximum volume coincides within 15 to 30 seconds with the beginning of the formation of forces The time elapsing from the beginning of mixing till the beginning of the final contraction of volume was between 6 and 10 minutes at 20°C and between 5 and 6 minutes at 38°C for all three cements In Table 1 the percentage volume changes of the three cements are given The final shrinkage involved in the build up of forces is between 2 and 3 per cent of the maximum volume recorded for each cement

Stress The build-up of stress in the cement paralleled the decrease in temperature and reached maximum when the temperature curve had fallen and was levelling off The average forces measured are shown in Table 1 The measurements showed that within the tested limits the build up of force is a linear function of the distance between anchoring points The cross-sectional area had no influence on the values as these were the same for the 80 and the 160 mm² samples but they were proportionally larger for the samples 70 mm in length. Thus the build up of forces can be expressed per mm distance The values for linear shrinkage are given in Table 1 The values for CMW and Simplex are of the same magnitude about 2 8 N/mm whereas Palacos demonstrated a lower value of 1 7 N/mm Statistical analysis showed this difference to be significant ($P < 0\ 01$)

Calculation of forces and stress

The results of the present experiments may be used as a basis for a calculation of the forces that the polymerizing cement imposes on the acetabulum The experiments

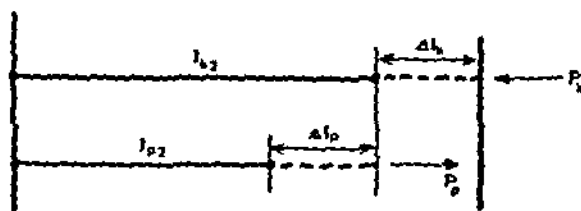


Figure 3 The relationship between two interacting elastic materials

demonstrate that the force per mm for the two distances of fixation of the cement, i e 26 5 and 33 mm, is the same, about 2.8 N/mm for CMW. This shows that the contraction of the cement that takes place is independent of the forces arising within the limits of the dimensions to be considered. However, when polymerization has taken place the two materials involved, the acetabular bone and the cement, may be considered as two elastic materials – springs – interacting with equal force on each other when forces and deformations of the two materials have reached an equilibrium The forces may then be calculated from a knowledge of the data for the apparatus, the values found, and the known or estimated mechanical characteristics of the materials In the following a simplified situation of uniaxial stress will be considered with the two materials acting as two springs in equilibrium (see Figure 3)

P_k = force acting on bone
P_p = force acting on cement
Δl = linear shrinkage of cement during unrestrained polymerization
l_{k_1} = distance between unloaded anchoring points
l_{p_1} = length of cement before polymerization
K_k and K_p = coefficients of stiffness of bone and cement

During the polymerization process the cement and the bone must assume the same length

$l_{k_2} = l_{p_2}$ = distance between anchoring points after polymerization.
Δl_k and Δl_p are considered elastic deformations

$P_k = P_p$ = the force acting on cement a
bone due to polymerization

We will then have

(1) $\Delta l = \Delta l_k + \Delta l_p \quad \Delta l_p = \Delta l - \Delta l_k$

(2) $P_k = \Delta l_k \times K_k$

$P_p = \Delta l_p \times K_p$

(3) $P_k = P_p$

(2) and (3) $\Delta l_k \times K_k = \Delta l_p \times K_p$ which giv

(4) $\Delta l_k = \dfrac{\Delta l_p \times K_p}{K_k}$

This used in (1) will give

$$\Delta l_k = \frac{(\Delta l - \Delta l_k)K_p}{K_k}$$

$$\Delta l_k = \Delta l \times \frac{K_p}{K_p + K_k}$$

this applied to (2) gives

(5) $P_k = \Delta l \times \dfrac{K_p \times K_k}{K_p + K_k}$

If Δl and the coefficients of stiffness for bo and cement are known this equation will g the resulting force. In the present stud the modulus of elasticity is used for th calculation of K The coefficient of stiffn will be

$$K = \frac{P}{\Delta l} = \frac{\sigma \times A}{\Delta l} = \frac{E \times \varepsilon \times A}{\varepsilon \times l} = \frac{E \times A}{l}$$

K = coefficient of stiffness
P = force
E = modulus of elasticity
σ = stress
A = cross-sectional area

$\varepsilon = \text{strain} = \dfrac{\Delta l}{l} \qquad \Delta l = \varepsilon \times l$

Example

CMW is used as an example using anch holes of 6 mm diameter and dimension the cement of 4 x 20 mm.

The stiffness of the U bar apparatus K_f determined from the calibration

f 554 N/mm

$$f = \Delta l \times \frac{K_p \times K_f}{K_p + K_f} \quad \text{which gives}$$

$$\Delta l = P_f \times \frac{K_p + K_f}{K_p \times K_f}$$

$$K_p \quad \frac{E \times A}{l}$$

$= 260\ kp/mm^2 = 2550\ N/mm^2$ (Holm 1977)

$- 20 \times 4\ mm = 80\ mm^2$

26 5 mm.

$K_p - 7700$ N/mm

P_f is determined from K_f and the contraction measured (Table1)

$P_f \quad \Delta l \times K_f \qquad P_f = 0\ 13 \times 554 \quad 72$ N

Δl (the unstressed length of the cement) can now be determined

$$\Delta l = \frac{7\ 2\,(554 + 7700)}{554 \times 7700} = 0\ 14\ mm$$

This figure is used in the further calculations where P_k is the figure wanted (Equation (5)) E for bone is a difficult figure to determine The literature gives very varying values. Currey (1970) in his comprehensive article gives the findings of 13 investigators working on femoral cortical bone and quotes values from 49 000 to 214 000 kp/cm², most values being of the order of magnitude of 150 000 kp/cm² Dietschi (1976) found values of 80 000 kp/cm² – 785 kN in pelvic cortical bone and this value will be used here The thickness of the cortical bone of the acetabular joint surface is from 2 to 4 mm. Thus

$$K_k \quad \frac{E \times A}{l} \quad \frac{785 \times 10^3 \times (6 \times 4)}{26\ 5} = 7112\ N/mm$$

By inserting in (5) P_k will be

$$P_k = \frac{0\ 14 \times 7700 \times 7112}{7700 + 7112} \approx 518\ N$$

This will be the resultant force on the bone in our uniaxial example The stress on the bone will be

$$\sigma = \frac{518}{24} = 22\ N/mm^2$$

DISCUSSION

Temperature The temperatures found in this investigation are measured 2 mm below the surface of the cement polymerizing under water at body temperature The values found here do not differ from those found by other investigators (Ohnsorge & Krosen 1969, Ohnsorge & Gobel 1969, Charnley 1970, Debrunner et al 1976) The exothermic nature of the polymerization process is a well established fact and will not be further dealt with here The temperature changes are only taken as an indicator of the progress of the process. The fact that the temperatures rise to about 90° C even though the cement is surrounded on one side by metal and on the remaining surfaces by water demonstrates that the heat problem cannot be overcome by cooling

Volume Debrunner et al (1976) found that the changes in volume were dependent on mixing techniques, ambient temperature, and speed of polymerization He also demonstrated that the porosity is dependent on external pressure Thus volume changes in the early phases of polymerization could be quite variable. The present experiment demonstrated slight differences between the cements in the relation between the contraction caused by the chemical process and the expansion caused by the heat generated by the same process. However these changes in volume that take place in the early phases of polymerization when the cement is still

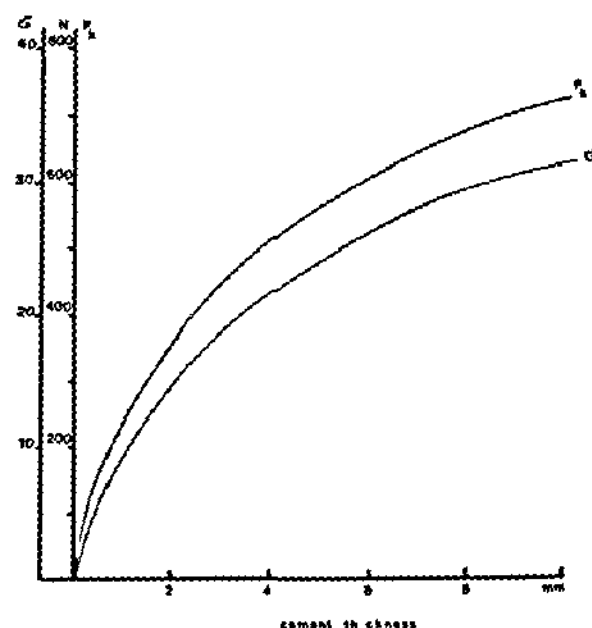


Figure 4 The variation in force, P_k, and stress, σ, with varying cement thickness

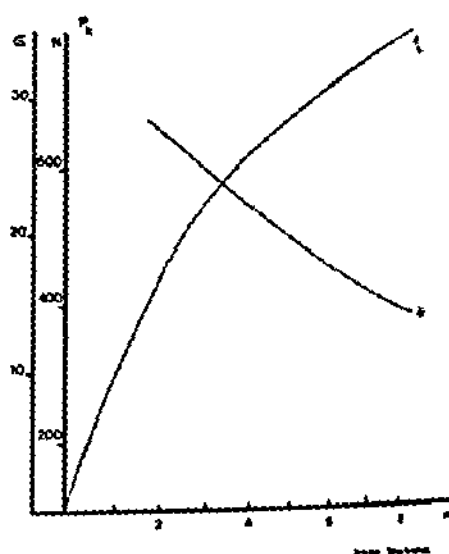


Figure 5 The variation in force P_k and stress, σ, with varying bone thickness

doughy are of no consequence as regards surgical use, as even a slight stress will merely cause the cement to flow During this phase Charnley (1970) found no stress from expansion and in the present work the absence of forces from contraction is demonstrated. In this context the injection pressure of the cement will be the determining factor in the cement's "grip" on the bone Thus only the final contraction when the cement has reached sufficient stiffness to support stress is of practical importance The cause of the final contraction of the cement is a combination of thermal contraction from cooling and the final stage of polymerization By calculating the expected change of volume from the coefficient of thermal expansion for acrylics it will be seen that the cooling is responsible for 40–50 per cent of the final contraction (Coefficient of thermal expansion $= 227 \times 10^{-4}$, Debrunner et al 1976) The present findings correspond well with the findings of Debrunner et al (1976) For the above-mentioned reasons it would not seem advisable to attempt to include large amounts of air in the cement by stirring in order to make the cement expand in the soft phase More air increases the porosity of the cement and therefore decreases its mechanical strength.

Stress The present experiment was designed as an investigation of the stress conditions in the acetabulum when a cemented prosthesis is inserted It seems obvious that the shrinkage of polymerizing and cooling methylmethacrylate – when inserted in some way as in the usage in hip replacement – will generate stress. Charnley (1970) found no such stress, but the experimental design that he used was aimed at finding pressure from expansion, not the stress arising from the final contraction. The values of linear shrinkage found in the present experiment correspond well with the figures given by Willert & Semlitsch (1976) and are about 0 3–0 4 per cent The development of force and stress in the acetabulum after insertion of the prosthesis will depend on the pressure of the acetabulum, but also on the thickness of cement and bone, the distance between anchoring points, the size of the holes drilled and the E-moduli of the bone and the cement The cement will have a very poor grip on a smooth sclerotic surface of the bone, but on the other hand irregularities, e g bone cysts will help distribute the force as they [illegible] points of purchase for the cement The

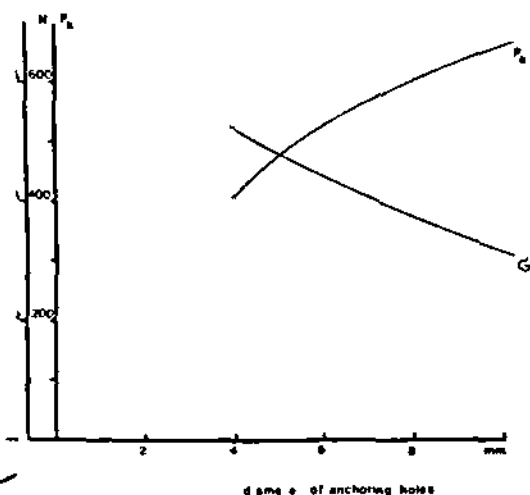


Figure 6 The variation of force, P_k, and stress, σ, with varying diameter of anchoring holes

influence of changes in the various parameters will be considered briefly, as an illustration, in each case keeping the other parameters constant The force and the stress on the bone both increase as the thickness of cement increases The relationship is shown in Figure 4 Differences in thickness of bone will alter the value of K_k This influence is demonstrated in Figure 5 The force will increase as the bone gets stiffer, but as this is accomplished by increasing the thickness and thus cross-sectional area, the stress which is force per mm^2 will decrease The same effect will be seen if the diameter of the anchoring holes is increased (with constant thickness of bone) This is shown in Figure 6 Changes in the distance between anchoring holes will only have a minor influence on the forces as will be seen from the calculations. If the distance is increased from 26 5 mm to 40 mm the force will only increase by about 4 per cent The factor Δl increases from 0 14 to 0 15

In surgery a three point fixation of the acetabular prosthesis is intended through the placement of three (or more) holes in the [illegible]

[illegible] magnitude may be attempted A calculation

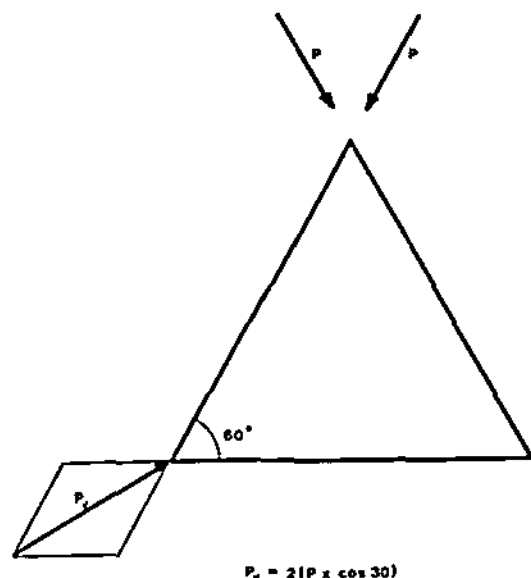


Figure 7 The calculation of force in a three-point fixation

of vectors will indicate an increase in the forces If we make the simplified assumption of having the three points of fixation placed in the corners of an equilateral triangle we will have forces expressed by

$$P_v = 2(P \times \cos 30) = 1\ 73\ P$$

(Figure 7) For the values found here this would mean that local forces of the order of magnitude of 500 to 1100 N would be acting at each of the points of fixation

The calculations presented here are of course based on certain simplifications. The acetabulum is not a frictionless plane and both cement and bone form a continuous surface and not strips of 20 mm width However the approximations were felt acceptable under the circumstances. The uncertainties and variations of the E-modulus for bone, which varies greatly – as between the thin, soft bone of a girl with rheumatoid arthritis and the sclerotic bone of a man with osteoarthrosis – and the variation in the thickness of cement as well as the other factors involved will influence the forces greatly Especially the E-modulus is important as it is such an important factor in the value of the bone constant K_k

ACKNOWLEDGEMENTS

The Department of Mechanical Technology, The Danish College of Engineering, is thanked for help and advice Acrylic cements were supplied by CMW Laboratories, Ltd (CMW Bone Cement), North Hill Plastics, Ltd (Surgical Simplex), and Kulzer & Co (Palacos R) The work was supported by P Carl Petersens Fond to whom my gratitude is expressed

REFERENCES

Charnley, J (1970) *Acrylic cement in orthopaedic surgery* E & S Livingstone, Edinburgh & London

Currey, J D (1970) The mechanical properties of bone *Clin Orthop* **73**, 210–231

Debrunner, H U, Wettstein, A & Hofer, P (1976) The polymerization of self-curing acrylic cements and problems due to the cement anchorage of joint prosthesis *Artificial hip and knee joint technology* (Ed Schaldach, M & Hohmann, D) pp 294–324, Springer, Berlin & Heidelberg

Dietschi C. (1976) *Sur Prob*[illegible] *künstlichen Huftgelenkes* A. W [illegible] Verlag Stuttgart

Holm, N J (1977) The modulus of elas[illegible] flexural strength of some acrylic bone ce[illegible] *Acta orthop scand* **48**, 436–442

Ohnsorge, J & Grotz, J (1974) Ku[illegible] Langzeitige Dimensionsänderu[illegible] aushartenden Knochenzementes. *Z. Or*[illegible] **112**, 975–977

Ohnsorge, J & Gobel G., (1969) Oberfläche[illegible] peraturen des abhartenden Knoche[illegible] Palacos beim Verankern von Metall[illegible] sen im Oberschenkelmarkraum. *Ark* [illegible] *Unfall Chir* **67**, 89–100

Ohnsorge, J & Krosen, [illegible] Thermoelektrische Temperaturmessung[illegible] abhärtenden Knochenzementes "Pa[illegible]" *Z Orthop* **106**, 476–482.

Willert H-G & Semlitsch, M. (1976) P[illegible] associated with the cement anchorage [illegible] artificial joints. *Artificial hip and knee j*[illegible] *technology* (Ed. Schaldach, M. & Hohmann, D) pp 325–346 Springer Berlin Heidelberg

Correspondence to Niels J Holm, Kulsviertoften 34 DK-2800 Lyngby, Denmark

cta orthop scand 51, 727–731 1980

THE RELAXATION OF SOME ACRYLIC BONE CEMENTS

NIELS J HOLM

The Department of Orthopaedic Surgery T–2, Gentofte Hospital, Hellerup Denmark

The creep and relaxation of acrylic cements during conditions simulating the conditions in the acetabulum have been examined CMW and Simplex were found to reach stresses of about 10 N/cm² after 1 year whereas Palacos had lost most of its stress after 6 weeks.

Key words bone cement, hip joint prosthesis

Accepted 17 iii 80

The problems of loosening of acetabular components in total hip replacement are gaining importance The details of how the acrylic cements transfer forces from the acetabular component of a total hip replacement to the bone are not well understood, but in a previous article (Holm 1980) the author has shown that acrylic cements may generate total stresses between the anchoring holes drilled into the acetabular bone of up to about 000 N, mainly because of contraction when cooling It is well known that plastics will creep and undergo relaxation under load, i e plastic deformation occurs with time The present investigation is an attempt to evaluate the speed of creep and relaxation of some acrylic cements.

MATERIAL AND METHODS

Three brands of cement were tested, CMW Bone Cement* Surgical Simplex*, and Palacos R* The apparatus and experimental setup has been described in detail in a previous paper (Holm 1980). It consisted of a measuring device in which the linear contraction of methylmethacrylate was evaluated by measuring the deformation of a U-shaped spring The acrylic specimen was moulded across the open end of the "U" and allowed to contract The relaxation was then measured under a slowly decreasing load as the U-spring regained its original shape The test pieces for the present experiment were all 20 × 8 mm and the distance between anchoring points was 26.5 mm. The cement was mixed at room temperature (22°C) by hand according to the manufacturers' instructions and placed in the mould to obtain the correct dimensions. The initial deformation, i.e. linear shrinkage, was measured with a dial gauge from which further daily readings were taken Two samples of CMW were tested as well as two of Simplex and one of Palacos R One long term experiment was conducted with CMW The individual experiments were continued for about 3 weeks whereas the long term experiment lasted 3 months. All experiments were carried out in distilled water at 38°C.

The standard method of testing creep involves loading the test piece in tension with a constant stress and expressing the elongation as a function of time A relaxation test is made by straining a given test piece to a given length in tension or compression and measuring the stress as it falls towards zero In the present experiment the relaxation of the cement is evaluated by a test with very small values of strain and a slowly decreasing value of stress. It is thus a compromise between a creep and a relaxation test. This method was chosen in order to get an estimate of the time factor involved when the cement is anchored to the bone where the stress will decrease as the cement creeps.

The creep of a plastic material can be expressed by the formula

$$\varepsilon = \varepsilon_0 + mt^n \text{ (Schreyer 1972)} \qquad (1)$$

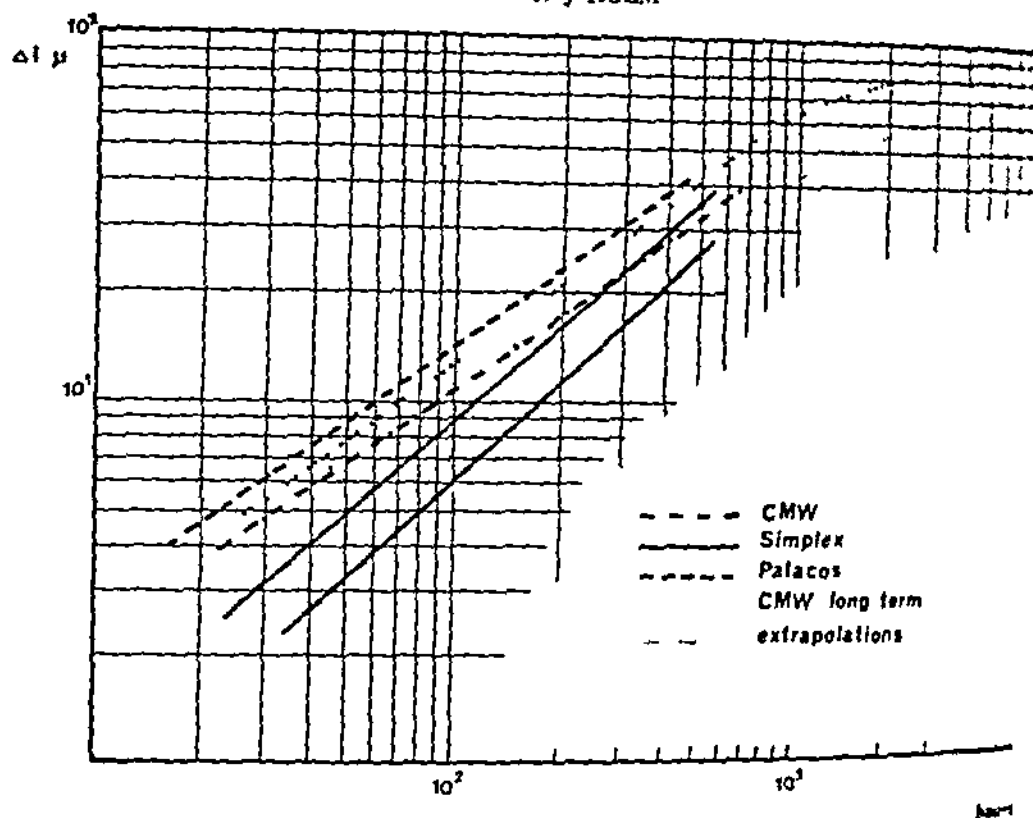


Figure 1 Creep of some acrylic cements Double logarithmic presentation with extrapolation

ε = strain at a given time ε_0 = strain at the time = 0 ε_0 thus is the strain which occurs immediately upon loading, i e basically the elastic strain m and n are material constants. m is a temperature dependent constant and on the graph it will be the projection to the time = 1 n is the inclination of the line and is independent of the stress. The equation $\varepsilon = \varepsilon_0 + mt^n$ can be transformed to $\varepsilon - \varepsilon_0 = mt^n$, and in logarithmic form we have

$$\ln(\varepsilon - \varepsilon_0) = \ln m + n \times \ln t \quad (2)$$

which is a useful expression for a double-logarithmic presentation

In the present experiment the elongation, Δl was measured directly and was used instead of the strain

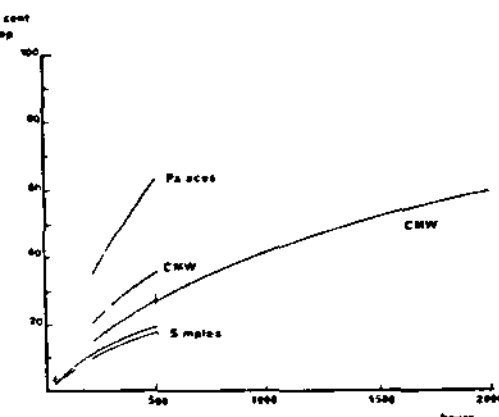
ε_0 was difficult to determine with accuracy as the test piece had been under stress for some time before the first reading could be taken. In other words, an exact starting time could not be determined because of the continuous nature of the polymerization process. Furthermore ε_0 is based on the condition of constant stress whereas the stress in the present experiment, as in the acetabulum, was decreasing with time. In the calculation, therefore, Δl is substituted for $\varepsilon - \varepsilon_0$, as $\varepsilon - \varepsilon_0 \times 26\,5$ mm $= \Delta l$.

This means that the values obtained for m are only valid for a distance between anchoring points of 26.5 mm and are therefore of minor interest whereas the n-value which is independent of this is the important figure

RESULTS

The results are shown graphically in Figure 1 Figure 2 shows the percentage relaxation in the five experiments. The values of m and n were calculated by linear regression and are given in Table 1 together with the coefficient of correlation, the maximum linear elongation, the percentage relaxation, and the elongation at 500 hours, Δl $\Delta l_{max} - \Delta l_{500}$. Special consideration will be given to the extrapolated values in the long term experiment.

The first observation to be made is that the mathematical expression is valid as shown by the coefficients of correlation even though the formula is designed to describe a regular



gure 2 Percentage creep of some acrylic ments

st This holds true up to about 500 hours. he primary linear shrinkages were not fferent from those previously reported Holm 1980), i e approximately the same ilues were obtained for CMW and Simplex id a considerably lower value for Palacos. lso Palacos showed an m-value which was bout twice the value for the two other rands. These two factors, a high m-value id a low linear shrinkage, account for the pid relaxation of Palacos of 68 per cent in 00 hours as compared with 20 per cent for implex and 30 per cent for CMW The n-ilues which represent the inclination of the nes in Figure 1 do not vary greatly and are etween 0 7 and 0 8 The lines are therefore most parallel. The long-term experiment ith CMW shows that the cement no longer illows the mathematical expression after bout 500–550 hours. As will be seen from e graph the curve levels off indicating that the relaxation proceeds much more slowly as the stress decreases. A new n-value has been calculated which demonstrates the extension in time This n-value will only be valid up to about 2000 hours. After this time the n-value decreases further, but at that time the experiment was discontinued At 2000 hours about two-thirds of the shrinkage had relaxed and the stress in the test sample at this time could be calculated to be

$$\frac{0\,058 \text{ mm} \times 554 \text{ n}}{1\,6 \text{ cm}^2} \approx 20 \text{ N/cm}^2$$

The m-value for this section of the test is a theoretical extrapolation and is of no interest

DISCUSSION

As shown in a previous paper (Holm 1980) methylmethacrylate, when used in fixation of acetabular components with anchoring holes, creates considerable forces which contribute to the fixation of the cup As plastics are known to creep it is important to know the length of time the forces are present. The relaxation and creep of acrylics have been fairly well investigated (Schreyer 1972) A number of factors make the evaluation of acrylic cements complicated Commercial acrylics such as Plexiglas[a] show a creep of about 1 per cent per year under standard conditions.

Several factors will, however, increase this factor The temperature has a definite influence, creep increases when the temperature increases. Another factor which

able 1 Calculated values for n and m, coefficient of correlation, maximum linear shrinkage, shrinkage at 500 h and the percentage creep/relaxation at 500 h

	n	m	Coefficient of correlation	Δl_{max} mm	$\Delta l_{max} - \Delta l_{500}$ mm	Per cent relaxation at 500 h
MW 1	0 7	0 4	† 98	0 094	0 062	34
MW 2, 500 h	0.8	0.3	0 99	0 145	0 104	28
MW long-term † 500 h	0 5	(2 1)	0 99	0	0.058 (2000 h)	60 (2000 h)
implex 1	0 8	0 1	0 98	0 132	0 106	19
implex 2	0 8	0 3	0 98	0 134	0 108	19
alacos R	0 7	0 7	0 99	0 068	0.025	62

greatly increases the speed of creep is humidity

Creep and relaxation are simply two ways of describing the same phenomenon The mechanism which is at work consists of a stretching and realignment of molecules which is greatly facilitated by the presence of water which acts as an internal "lubricant" As shown by Ohnsorge & Grötz (1974) acrylic cement will absorb 1 3 per cent by volume of water, which accounts for a part of the creep To these variables are added the degree of polymerization of the cement, i e the length and branching of the molecules, and the amount of air incorporated in the cement during mixing

The present results comply well with the general knowledge of relaxation and creep (Schreyer 1972) At the termination of the experiments there was still considerable stress in the CMW and Simplex samples whereas Palacos had lost most of its stress. The results may be extrapolated forwards in time but the estimates will contain considerable uncertainty It seems reasonable to assume that all acrylic cements behave in a similar manner and it will be seen from Figure 1 that the curves are asymptotic. An estimate of the time when the stress has reached 10 N/cm² (≈0 03 mm shrinkage) can be made from the graph. This will show that the time for CMW will be of the order of magnitude of $1–2 \times 10^4$ hours ≈ 1–2 years. The time for Simplex is difficult to evaluate, but it will not be shorter rather the opposite as it shows only 20 per cent relaxation at 500 hours. For Palacos, the time will be considerably shorter, the graph would indicate less than 1000 hours.

The physical behaviour of acrylic bone cement has clinical significance in terms of mechanical fixation and loosening Immediately following polymerization the cement has a grip on the bone of 500–1000 N (CMW, Simplex). This force counteracts the forces of friction. As it decreases with time friction prevails and mechanical loosening may start.

The behaviour of bone in terms of relaxation and creep is difficult to evaluate In fact, when loaded in compression creep is [illegible] be expected when the composition of [illegible] composite biological material is [illegible] The compression forces will be [illegible] the apatite crystals in the bone and [illegible] substance cannot be expected to [illegible] creep If a plastic deformation were to [illegible] it would come from remodelling as long as [illegible] loads are within the tolerances of the bone Hert et al (1969) have shown that a [illegible] on bone causes no discernible remodelling Perren et al. (1969) measured the [illegible] the compression plates used in the [illegible] osteotomies and found decreasing [illegible] time, but their results are not [illegible] applicable in the present context as [illegible] measuring the strain with an [illegible] between the measuring points [illegible] situation does not exist in the acetabulum where the anchoring holes are placed [illegible] otherwise basically intact cortical bone.

It is evident that any remodelling [illegible] resorption of bone at the edges of [illegible] anchoring holes in the acetabulum [illegible] rapidly decrease the cement forces [illegible] cases where the cement for some [illegible] to be set in cancellous bone no [illegible] therefore no relaxation can be expected

CONCLUSION

The acetabular component of a [illegible] replacement when fixed by [illegible] anchoring holes for the cement [illegible] acetabular corticalis is held in place by [illegible] contraction forces of the cement for a [illegible] period of time. The speed with which [illegible] acrylic compound undergoes relaxation [illegible] dependent on the type of cement – Palacos creeping much faster than CMW and Simplex – and on the response of the bone

ACKNOWLEDGEMENTS

The Department of Mechanical Technology [illegible] Danish College of Engineering is thanked for [illegible] and advice.

Acrylic cements were supplied by [illegible]

aboratories, Ltd (CMW Bone Cement), North ill Plastics, Ltd (Surgical Simplex) and Kulzer Co (Palacos R)

The work was supported by P Carl Petersens ond to whom my gratitude is expressed

EFERENCES

ert, J., Liskova, M & Landrgot, B (1969) Influence of the longterm, continuous bending on the bone. *Folia morph. (Warszawa)* 17, 389–399

Holm, N J (1980) The formation of stress by acrylic cements during the fixation of the acetabular prosthesis. *Acta orthop scand*, 51, in press.

Ohnsorge, J & Grötz, J (1974) Kurzzeitige und langzeitige Dimensionsänderungen des aushärtenden Knochenzementes. *Z Orthop* 112, 975–977

Perren, S M, Huggler, A., Russenberger, M, Straumann, F, Muller, M E. & Allgöwer, M (1969) The dynamic compression plate *Acta orthop scand.*, Suppl. 125

Schreyer, G (1972) *Konstruieren mit Kunststoffen*, Teil 1 p 502–569 Carl Hanser Verlag, München.

orrespondence to Niels J Holm, Kulsviertoften 34, DK 2800 Lyngby, Denmark

cta orthop scand. 51, 733–741 1980

TENSILE FRACTURE OF CANCELLOUS BONE*+

DENNIS R CARTER‡, GREG H SCHWAB† & DAN M SPENGLER††

Orthopaedic Research Laboratories, Massachusetts General Hospital and Harvard Medical School, Boston, Massachusetts, †Department of Orthopaedics, Baylor College of Medicine, Texas Medical Center, Houston, Texas and ††Department of Orthopaedics, University of Washington, Seattle, Washington, USA

Excised specimens of cancellous bone from human femora were subjected to compressive or tensile testing, and the resulting force-displacement curves were recorded The relationships between bone strength and apparent density were similar for specimens tested in these two loading modes. The modulus of elasticity was also comparable for the tensile and compressive specimens. Specimens loaded in compression absorbed considerable energy after the initial fracture because of progressive impaction of the trabeculae In the specimens loaded in tension, the fractured bone fragments separated and therefore absorbed little additional energy after the initial failure The energy absorption capacity was thus significantly lower for the tensile specimens.

The results of this study show that the primary difference in mechanical properties of cancellous bone tested in tension and compression is the energy absorption capacity This finding suggests that tensile and avulsion fractures of cancellous bone observed clinically are associated with minimal energy absorption and therefore may be precipitated by relatively minor trauma.

Key words apparent density, cancellous bone, elastic modulus, energy absorption, strength

Accepted 26 ii.80

Cancellous bone plays an important role in the transmission and distribution of stresses in the human skeletal system, particularly in the vertebral column, in synovial joints, and near ligamentous and tendinous attachments. Previous mechanical testing of cancellous bone specimens *in vitro* has been conducted primarily in compression (Carter & Hayes 1977, Galante et al. 1970, Lindahl 1976, McElhaney et al 1970, Townsend et al. 1975b) Data from some of these studies indicate that cancellous bone acts very much like porous engineering materials which have many applications because of their excellent energy absorption capabilities (Hayes & Carter 1976, Patel 1969, Pramuk 1976). The stress-strain curve for a rigid cellular plastic tested in compression is very similar to that for cancellous bone (Figure 1) Compression curves for both materials consist of an initial linear region followed by yield and a long "plateau" region where the stress remains approximately constant as the strain is increased In the plateau region the cellular plastic or cancellous bone is being gradually compressed and the small struts of material (trabeculae in cancellous bone) are fracturing At very high strain values, debris begins to fill the pores of the material, and the specimen stiffness increases markedly The

*This research was supported in part by NIH Grant AM 27117 and by the Medical Research Service of the Veterans Administration.

Read in part at the Annual Meeting of the Orthopaedic Research Society San Francisco, California, February 1979

0001–6470 80 050733–09 $02 50 0

cuum. The specimens were then suspended om an analytical balance to determine the bmerged weight They were centrifuged on otting paper for 15 minutes to remove residual ater from the pores and weighed in air to obtain drated tissue weight. The volume of bone tissue cubic centimetres (excluding pores) was lculated as the difference between the hydrated sue weight and the submerged weight expressed grams (Mueller et al 1966) Tissue density of e specimen was calculated by dividing hydrated sue weight by bone tissue volume Apparent nsity of the specimen was calculated by dividing drated tissue weight by bulk volume of the ecimen as determined by micrometer easurements Bone porosity defined as the rcentage of bone volume occupied by nonmeralized tissue, was calculated as

$$P - 100\left(1 - \frac{\rho}{\rho_t}\right)$$

here P porosity (per cent)

ρ – apparent density

ρ_t – tissue density

fter measurements were made, the specimens ere allowed to dry overnight in room air

The configuration used for testing was a odification of ASTM standard D 1623 for tensile sting of rigid cellular plastics (ASTM, 1978). he ends of the dried specimens were embedded a depth of approximately 1 65 millimetres with a polyester embedding resin After the resin had ured the ends of the specimen were bonded with polyamine blend of diglycidyl ester bisphenol Devcon) to small metal platens which could be eld conveniently in the grips used for mechanical esting (Figure 2)

Before testing, the specimens were rehydrated ith saline solution and maintained in a wet ondition during the testing procedure Tensile nd compressive loading to failure was done at 21 egrees centigrade with an MTS loading system t a constant strain rate of 0 01 per second A orce-displacement curve was recorded for each pecimen tested. This curve was later used for ata analysis. Twenty-eight specimens with narrow extracted were tested in tension and ourteen were tested in compression To evaluate he influence of the specimen preparation procedures on the mechanical properties, we tested an dditional 10 specimens (5 in tension and 5 in ompression) from which the marrow had been xtracted with a jet of warm water

Initial attempts to bond the wet specimens to he small metal platens resulted in an unsatisfactory bond It was therefore necessary to dry the specimens before bonding them and rewet these specimens prior t est ng This procedure was a

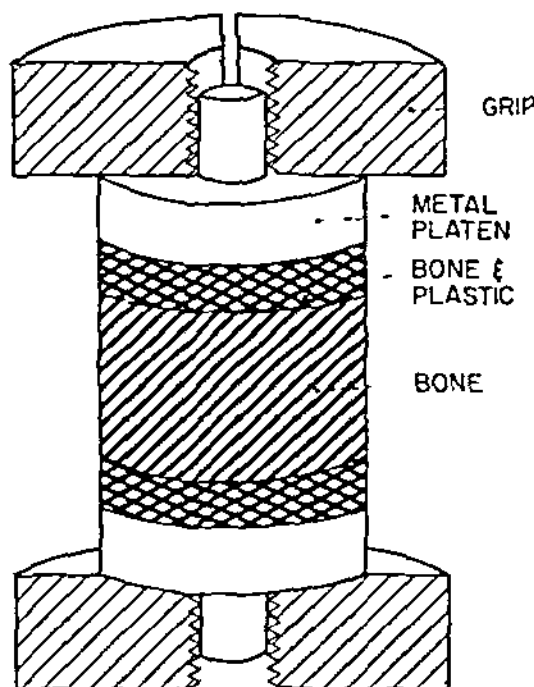


Figure 2 Specimen testing configuration

source of concern, as other researchers have shown that drying of bone tissue can cause

had been removed with a jet of warm water, had not been bonded to the metal platens and had not been allowed to dry at any time

RESULTS

The tissue density of the bone specimens examined was between 1 6 and 1 95 grams per cubic centimetre These values are comparable to those commonly found in human cortical bone (Gong et al 1964) The values for apparent density of the specimens ranged from 0 2 to 0 8 grams per cubic centimetre The specimen porosity ranged from approximately 50 to 90 per cent

The force-displacement curves recorded for the specimens tested in compression were similar to those reported in earlier compression studies of cancellous bone (Figure 1B)

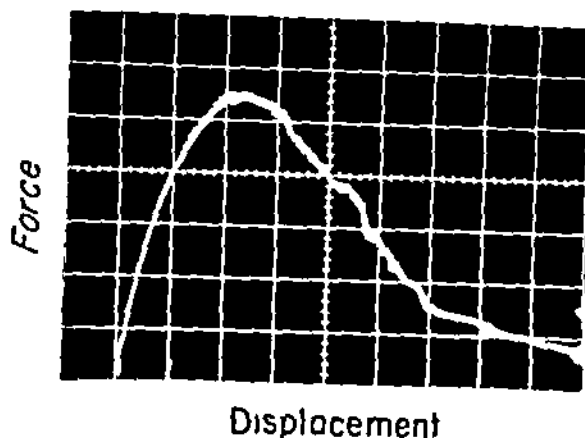


Figure 3 The force versus displacement curve of a specimen tested in tensile loading

The force-displacement curves recorded for the specimens tested in tension, however, differed markedly from those for the compression specimens These tensile curves were characterized by an initial linear region followed by a region which was nonlinear until the maximum force was achieved Beyond this point progressive trabecular fracture occurred, resulting in a gradual loss of force with increasing displacement until total separation of the fracture surfaces was observed (Figure 3) The gradual decrease in force after the maximum force was achieved was accompanied by a tearing phenomenon wherein the trabeculae of the cancellous bone progressively tore free from the adjacent bone

The area under the force-displacement curve for the specimens represents the energy absorbed Under small strain conditions the energy absorption capacity of the specimens was virtually identical in tension and compression Under large strain conditions (fracture), however, the tensile specimens absorbed very little energy, since after fracture occurred the bone ends separated and no further forces were transmitted through the specimens Compressive fracture of the specimens led to progressive impaction of the trabeculae and prolonged energy absorption.

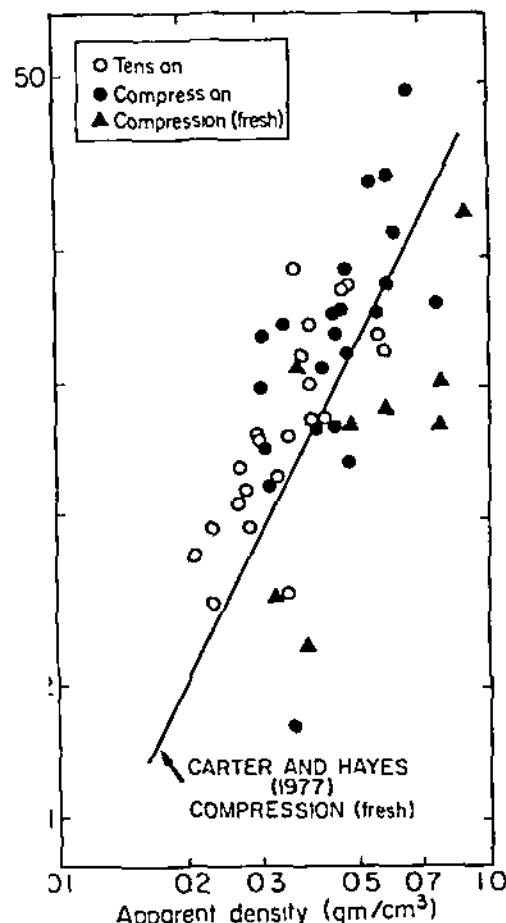
The strength of the specimen was defined as the maximum stress achieved before progressive trabecular tearing (in the case of tension) or collapse (in the case [of com]pression) The elastic modulus [of each] specimen was calculated us[ing a] mathematical model which accounte[d for] altered compliance at the embedded [ends of] the specimens (see Appendix)

There had been some concern t[hat] specimens might fracture at the i[nterface] between the bone and the embedding [plastic]. However, the compression specimens [tended] to experience diffuse fracture [of] trabeculae throughout the specimen [length] and the tension specimens fractured t[hrough] the cancellous bone rather than at the plastic interface This fracture beh[avior] suggests that the interface did not ser[ve as a] site of stress concentration

All specimens which were dried [and] rewetted for testing showed comp[arable] material properties whether the marrow [was] extracted by chemical means or by wat[er]. However, the compression specimens [which] were kept wet throughout the prepar[ation] procedure were generally more comp[liant] than specimens which were dried [and] rewetted Data for these fresh [specimens are] presented separately

The apparent density had a [strong] influence on the ultimate strength of [the] compression and tension specimens (Fi[gure] 4) Since a power relationship betw[een] ultimate strength and apparent density [was] anticipated (Carter & Hayes 1977), the re[sults] are presented on a log log graph Analysis [of] covariance revealed no statistically signific[ant] difference in the ultimate strength of the [dried] and rewetted specimens tested in the [two] loading modes, although significant d[ata] scatter was present The compress[ion] specimens which were tested fresh howe[ver] showed a slightly lower ultimate stre[ngth] than specimens which had been dried [and] rewetted The relationships between stre[ngth] and apparent density for all specimens [were] consistent with those from earlier compr[es]sion tests of fresh cancellous bone (Carter & Hayes 1977)

The apparent density also had a str[ong] influence on the elastic modulus of the



'e 4 *The influence of apparent density on the 'e and compressive strength of cancellous*

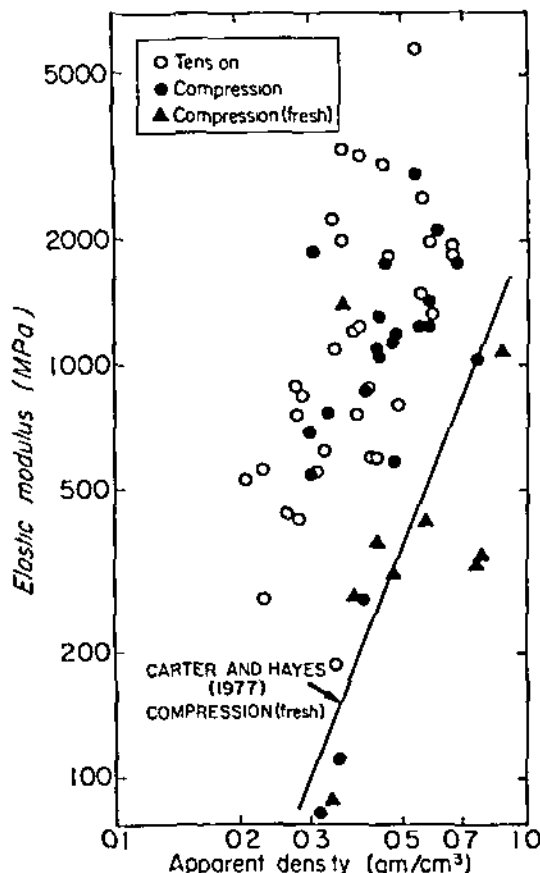


Figure 5 The influence of apparent density on the tensile and compressive elastic modulus of cancellous bone

ımens (Figure 5) Again, no statistically ficant difference was found in the elastic uli of dried and rewetted specimens :d in the two loading modes However, :lastic moduli for these specimens were ficantly greater than those for the com- sion specimens tested fresh The elastic uli of these fresh specimens were in :r agreement with those from the earlier pression tests of fresh cancellous bone ter & Hayes 1977) These findings :est that although the elastic moduli for rewetted specimens were the same in ion and compression, the numerical es may be significantly greater than those ıro

DISCUSSION

In this study the strength of cancellous bone was found to be comparable in tensile and compressive loading In both loading modes, the strength of the bone was approximately proportional to the square of the apparent density This finding is consistent with that of a previous study on the influence of apparent density on the compressive behaviour of fresh cancellous bone specimens (Carter & Hayes 1977) The elastic moduli of the dried and rewetted specimens of this study were the same in tensile and compressive loading The modulus values of the rewetted specimens, however, were

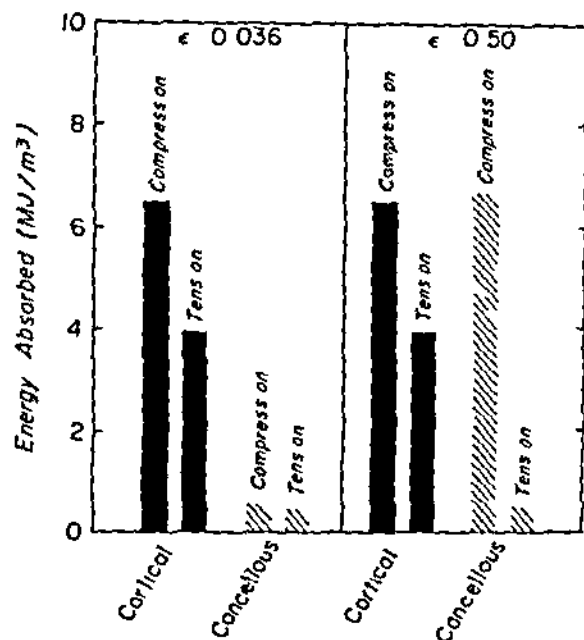


Figure 6 The energy absorption capacity of cortical and cancellous bone at low strains (strain = 0 036) and at high strains (strain = 0 50) The assumed apparent density of the cancellous bone is 0 4 grams per cubic centimetre Energy absorption for cortical bone is derived from the study of Reilly & Burstein (1975)

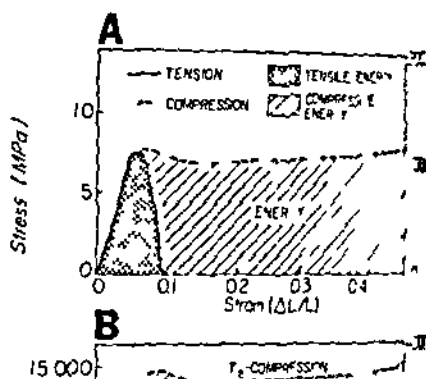



Figure 7 A The tensile and compressive stress strain behaviour of cancellous bone with an apparent density of 0 4 grams per cubic centimetre B The force-deformation curves for compressive fracture of the twelfth thoracic vertebra and a tensile fracture of the patella

significantly greater than those of fresh specimens tested in compression in this and a previous study (Carter & Hayes 1977) At small strains, the energy absorption capacity of the cancellous bone specimens was approximately the same in tension and compression However, at large strains the specimens showed a much greater capacity to absorb energy in compression than in tension

In *in vivo* situations, tensile fracture of cancellous bone causes displacement of the fractured bone ends, after which no further energy can be absorbed by the bone In compressive fracture of cancellous bone, however, initial fracture is followed by progressive impaction of the trabeculae, which results in high energy absorption Displacement of the fractured bone ends occurs in all fractures of cortical bone, preventing further energy absorption after initial fracture At a strain of approximately 50 per cent (as may be encountered with severe trauma), the energy absorbed in fracture of cancellous bone in compression can exceed that absorbed in fracture of cortical bone under any loading condition (Figure 6).

The cancellous bone specimens in this study were taken from an 84-year-old subject. With increasing age there may be a great decrease in cancellous bone apparent density (Lindahl & Lindgren 1962). This decrease is caused primarily by an increase in bone porosity since the ash weight of bone remains constant or increases very slightly after the age of 20 years (Currey & Butler 1975, ... et al 1974, and Carter & Spengler 1978). The mechanical properties in this study were evaluated as a function of bone apparent density These relationships should therefore provide a sound basis for estimating the mechanical behaviour of cancellous bone from any age specimen, provided that the local apparent density of the bone can be assessed.

Specimens of this study were tested at a strain rate of 0 01 per second. Carter & Hayes (1977) demonstrated that the strength and modulus of cancellous bone is approximately proportional to the strain rate raised to the 0 06 power This finding suggests th



gure 8 A Tensile fracture through cancellous bone of the patella with an energy absorption of proximately 3 joules B Compression fracture of a vertebral body with an energy absorption of proximately 100 joules C Torsional fracture of the tibia with an energy absorption of approximately joules

during impact loading with a strain rate of 10 per second, the values for strength and modulus recorded in this study would be increased by approximately 32 per cent Differences in trabecular orientation between specimens could easily affect the mechanical properties by an equivalent or greater amount (Galante et al 1970)

The mechanical behaviour of cancellous bone described in this study and previous studies (Carter & Hayes 1977) can be related to the characteristics of fractures through specific cancellous bone structures. As an example, we estimated the fracture behaviour of the twelfth thoracic vertebra in compression and the patella in tension Stress-strain curves were estimated for cancellous bone tissue under compressive and tensile loading based on an apparent density consistent with the findings of this study and other studies (Carter & Hayes 1977, Kazarian & Graves 1977) From these stress-strain curves, force-deformation curves were generated for tensile fracture of the patella and compressive fracture of the twelfth thoracic vertebra (Figure 7) Estimation of these force-displacement curves took into account the difference in geometry of the two structures. The curve estimated for the vertebra is consistent with experimental findings of Kazarian & Graves (1977)

The estimated force required to fracture the patella is less than that required to fracture the vertebral body simply because the patella is smaller The estimated energy absorbed by the patella is markedly less than that absorbed by the vertebra not only because of its smaller size, but also because less energy is absorbed by cancellous bone in tension than in compression

The amount of energy absorbed during a tensile fracture of the patella can be calculated from the force-deformation curve as approximately 3 joules (Figure 8A) In

contrast, the energy absorbed during a severe compression fracture (1 centimetre of deformation) of a vertebral body is approximately 100 joules (Kazarian & Graves 1977), and the energy absorbed by a torsional fracture of the tibia is approximately 10 joules (Burstein & Frankel 1968) (Figures 8B and C) This observation emphasizes that relatively minor trauma can produce avulsion fractures and tensile fractures through cancellous bone

APPENDIX

Estimation of elastic modulus of cancellous bone from force-displacement data

The tested specimen consisted of cancellous bone with a cross-sectional area (A) and a length (L) The ends of the specimens were embedded in plastic resin to a depth of 0 5 L_{BP} so that the length of cancellous bone was L_B (Figure 9) Under a force (F), the total deformation recorded (ΔL) was caused by the deformation of the exposed cancellous bone (ΔL_B) and the deformation of the bone-plastic specimen ends (ΔL_{BP})

$$\Delta L = \Delta L_B + \Delta L_{BP} \quad [1]$$

or

$$\Delta L = L_B \varepsilon_B + L_{BP} \varepsilon_{BP} \quad [2]$$

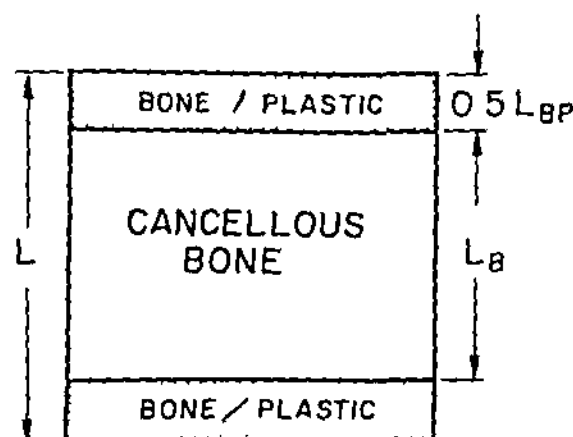


Figure 9 Schematic drawing of a tested specimen

where ε_B and ε_{BP} are the strains in cancellous bone and bone-plastic composite respectively Equation 2 can be rewritten

$$\varepsilon_B = \frac{1}{L_B}(\Delta L - L_{BP}\varepsilon_{BP})$$

The elastic modulus of cancellous bone (E_B) is equal to the stress (F/A) divided by the bone strain (ε_B) Expressing this in terms of Equation 3 yields

$$E_B = \frac{L_B(F/A)}{\Delta L - L_{BP}\varepsilon_{BP}}$$

The strain experienced by the bone-plastic composite at the specimen ends (ε_{BP}) is

$$\varepsilon_{BP} = \frac{F/A}{E_{BP}}$$

where E_{BP} is the elastic modulus of the plastic composite E_{BP} can be approximated by mixture theory as

$$E_{BP} = fE_p + (1-f)E_{CB}$$

or

$$E_{BP} = E_{CB} - f(E_{CB} - E_p)$$

where

f = void fraction of cancellous bone
E_p = elastic modulus of solid plastic
E_{CB} = elastic modulus of compact bone comprising the trabeculae

Substituting equation [7] into equation yields

$$\varepsilon_{BP} = \frac{F/A}{E_{CB} - f(E_{CB} - E_p)}$$

Substituting equation [8] into equation yields

$$E_B = \frac{L_B(F/A)}{\Delta L - L_{BP}\left[\frac{F/A}{E_{CB} - f(E_{CB} - E_p)}\right]}$$

or

$$E_B = \frac{L_B}{\left[\frac{A}{(F/\Delta L)} - \frac{L_B}{E_{CB} - f(E_{CB} - f(E_{CB} -}\right.}$$

...re L_B = 0 0067 metres (estimated from ten specimens)

L_{BP} = 0 0033 metres (estimated from ten specimens)

A = 0 0000785 square metres

E_p = 3 5 gegapascals (from manufacturer)

E_{CB} = 20 gegapascals (estimated from literature)

f = void fraction, calculated for each specimen

$F/\Delta L$ = slope of the force-displacement curve, measured for each specimen

REFERENCES

...erican Society for Testing and Materials (1978) *Annual book of ASTM standards* ASTM Philadelphia, PA

...ck, J, Mattson, R & Korostoff, E (1974) *Haversian osteons size, distribution, internal* structure, and orientation *J biomed Mat Res* 8, 299–319

...rstein A H & Frankel, V H (1968) The viscoelastic properties of some biological materials. *Ann. N Y Acad Sci* 146, 158–165

...rter D R & Hayes, W C (1976) Bone compressive strength The influence of density and strain rate *Science* 194, 1174–1176

...rter D R & Hayes W C (1977) The compressive behavior of bone as a two-phase porous structure *J Bone Jt Surg* 59-A, 954–962

...rter D R & Spengler, D M (1978) Mechanical properties and composition of cortical bone *Clin Orthop* 135, 192–217

...rrey J D & Butler, G (1975) The mechanical properties of bone tissue in children *J Bone Jt Surg* 57-A 810–814

Evans, F G (1973) *Mechanical properties of bone* Charles C Thomas, Springfield, Illinois.

Galante, J, Rostoker, W & Ray, R D (1970) Physical properties of trabecular bone *Calcif Tiss Res* 5, 236

Gong, J K, Arnold, J S & Cohn, S H (1964) Composition of trabecular and cortical bone *Anat Rec* 149, 325–332.

Hayes, W C & Carter, D R (1976) Postyield behavior of subchondral trabecular bone *J biomed Mater Res* 10, 537–544

Kazarian, L & Graves, G (1977) Compressive *strength characteristics of the human vertebral* centrum *Spine* 2, 1–14

Lindahl, O (1976) Mechanical properties of dried defatted spongy bone *Acta orthop scand* 47, 11–19

Lindahl, O & Lindgren, A (1962) Grading of osteoporosis in autopsy specimens. *Acta orthop scand* 32, 85–100

McElhaney, J H, Fogle, J L, Melvin, S W, Haynes R. R, Roberts V L & Alem, N M (1970) Mechanical properties of cranial bone *J Biomech* 3, 495–511

Mueller, K. H, Trias, A & Ray, R. D (1966) Bone *density and composition. Age-related and* pathological changes in water and mineral content *J Bone Jt Surg* 48 A, 140–148

Patel, M R (1969) The deformation and fracture of rigid cellular plastics under multiaxial stress. Ph D dissertation, University of California, Berkeley

Pramuk P F (1976) Treatment of structural foam testing results. *Polym Eng Sci* 16, 559–563

Reilly, D T & Burstein, A H (1975) The elastic and ultimate properties of compact bone tissue. *J Biomech* 8, 393–405

Townsend, P R, Rose, R. M & Radin, E L. (1975a) Buckling studies of single human trabeculae *J Biomech* 8, 199–201

Townsend, P R, Raux, P., Rose, R M, Miegel, R E. & Radin, E. L (1975b) The distribution and anisotropy of stiffness of cancellous bone in the human patella *J Biomech* 8, 363–367

...rrespondence to Dennis R Carter, Ph D, Orthopaedic Research Laboratories, Massachusetts ...neral Hospital Boston Massachusetts 02114 USA.

a orthop scand 51, 743–753 1980

FFECT OF DIAPHYSEAL INJURY ON THE PROXIMAL ROWTH ZONE OF THE TIBIA IN RABBITS

KÉRY G LENART & I SZÁSZ

nmelweis University of Medical Science, Department of Orthopaedics, and
tional Institute of Haematology and Blood Transfusion, Budapest, Hungary

found that the disturbed circulation and the venous stasis may have a marked effect on osteogenesis and bone growth but other factors are probably also involved In the early stage after the injury an increase in the ground substance widening of the zone of germinative and proliferative cells in the growth plate and a reticular arrangement of the bony trabeculae in the metaphysis were observed. In the late stage, along with a return to normal circulation, normalization of the osteogenesis and bone growth was also found.

Key words circulatory disturbance, diaphyseal injury, growth cartilage, metaphysis, radioactive isotopes

Accepted 31 i 80

is well known that diaphyseal fracture or ıer trauma in childhood may enhance ıgitudinal bone growth (Bisgard 1936, ount 1955, Emneus & Hedström 1964, aheli 1967, Edvardsen 1976) The exact echanism of this enhancement is not yet own

The aim of the present investigation was study the epiphyseal and metaphyseal action following diaphyseal injury istological methods, radioactive isotopes d radiography were used in the experi-ents.

ATERIAL AND METHODS

total of 130 four week-old chinchilla rabbits th an average weight of 665 g were used for the periments. The following diaphyseal injuries re inflicted under Nembutal anaesthesia, to the ht tibiae of the rabbits

Group 1 In 40 animals the anterior surface of the tibia was exposed, the periosteum longitudinally incised and then circularly detached in the middle third of the bone Care was taken not to damage the nutritive artery and the perichondrium of the bone ends

Group 2 In 40 animals after exposure of the middle third of the tibia and stripping of the periosteum, a hole was drilled into the medullary cavity on the anterior surface at the border of the middle and distal thirds of the bone using a dental drill Care was taken not to damage the nutritive artery and the perichondrium of the bone ends.

Group 3 In 40 animals the tibia was fractured manually, without exposure, in the antero-posterior direction on the border of the middle and distal thirds of the bone, about 2 cm proximal to the distal end. The site of fracture was measured before actually breaking the bone and it was always distal to the foramen nutricium of the tibia. After reduction of the fracture a cast was applied and worn for 2 weeks.

01-6470 80 050743-11 $02.50 0

Group 4 Ten animals received a cast similar to that used in group 3 and wore it for 2 weeks, however the cast was applied without prior injury

From groups 1 2, and 3 ten animals from each group were killed by intravenous air embolism 2, 6 12 and 18 weeks after the bone injury All the animals from group 4 were killed after 2 weeks. Both lower limbs were removed the tibiae were cleaned and the left tibia was used as control

The following examinations were performed

(i) Bilateral X-ray pictures were taken of every pair of tibiae and qualitatively evaluated.


(ii) Seventy two hours before killing 2 ml blood was taken from two animals from each group, 3 3 per cent sodium citrate and 30 μCi Na $_{51}CrO_4$* (specific activity 369 Ci/g) was added to this blood and the mixture was incubated for 60 minutes at 37°C Unbound ^{51}Cr was eliminated by three washings in 0 16 M NaCl The ^{51}Cr labelled erythrocyte suspension was then diluted to its original volume with physiological NaCl solution and injected intravenously to the donor animal 48 hours before killing

Five animals from each group received a 50 μCi/kg body weight $^{85}SrCl_2$** solution (specific activity 3 3 Ci/g) intravenously 48 hours before killing After the animals were killed the proximal ends of the tibiae were halved in the frontal plane and under a magnifying glass an 8–10 mm high circular segment including the growth plate and the metaphysis, was removed in the horizontal plane The radioactivity of the removed samples was measured in an FH–49, Friesecke-Hoepfner well type scintillation counter Radioactivity was expressed in cpm/g (counts per minute/gram sample weight) related to the unit weight of the [illegible] control sam[illegible] radioact[illegible] The va[illegible] analysed statistica[illegible]

(iii) The proximal ends of the tibiae, after fixation in 4 per cent neutral Formalin decalcification in EDTA and embedding in paraffin were cut in the frontal plane into 7 μ thick sections and stained with haematoxylin-eosin

The height of the columns of growth cartilage cells was measured as follows an ocular micrometer with a scale divided into 100 equal parts of 10 mm each was inserted and a 4 1 projective and a 10/0 25 objective light microscope was used One unit of the micrometer corresponded to 10μ On each slide measurements were made at three sites, in the middle and on the two marginal areas of the growth cartilage and in 5 views The height was defined in micra as

* $Na_2{}^{51}CrO_4$ and ** $^{85}SrCl_2$ was supplied by the Central Institute of Physical Research Budapest






Figure 1a and b Comparative anteroposterior and lateral (b) roentgenograms of the [illegible] and control tibiae 2 weeks after the [illegible] fracture Increased transparency in the [illegible] of the fractured bone

arithmetic mean of the values measured The • were analysed statistically, according to the iod of Snedecor (1962) The standard deviation the standard error were calculated. The wing levels were used in the test of significance ly significant $P<0\ 01$, significant $P<0\ 05$

SULTS

Early stage (2–6 weeks) after all three s of diaphyseal injury

Roentgenograms revealed normal growth ilage bilaterally Under the growth plate a row sclerotic zone could be observed in majority of the cases, generally on both s. In the injured bones an increased nsparency was found in the metaphysis is phenomenon was most noticeable after physeal fracture (Figure 1a and b) The centration of ^{51}Cr labelled erythrocytes markedly greater in the injured bone, ecially after diaphyseal fracture (Table 1) e measured radioactivity of ^{85}Sr was also nificantly greater in the injured bone. The erence was most marked after diaphyseal cture (Table 2a and b)

At the site of the injury, proliferation of the senchymal cells and thick fibrous tissue is found Fibrous callus could be observed the vicinity of the drill hole and the cture In the metaphysis of the injured bone enlarged sinusoids filled with erythrocytes and an eosinophilic homogenous substance were found The bone marrow showed signs of stasis (Figure 2a and b) In the growth cartilage the ground substance was increased, the zone of the germinative and proliferative cells widened and the cell columns were irregular (Figure 3a and b) The trabeculae of the metaphysis in the primary spongiosa were thick, consisted of immature bony tissue and had a reticular appearance (Figure 4a and b) The growth cartilage of the injured bone was significantly higher than that of the intact bone (Figure 3a and b)

Roentgenograms and qualitative histological examination did not show any difference between the uninjured immobilized and control extremities after 2 weeks The concentration of ^{51}Cr labelled erythrocytes was increased though not significantly on the immobilized side (Table 1) The increase in ^{85}Sr activity on this side was not significant and the growth plate was also not significantly higher (Table 2a and b, Table 3a and b)

B *Late stage (12–18 weeks) after all the three types of diaphyseal injuries*

Roentgenograms revealed no difference between the bone structure of the injured and uninjured proximal ends of the tibiae Due to

Table 1 The increase in radioactivity of the proximal end of the tibiae, on the injured and immobilized side, after the injection of ^{51}Cr labelled erythrocytes, expressed as a percentage of control

	2 weeks	6 weeks	12 weeks	18 weeks
Periosteal stripping	55 0 52.0	15 4 12.4	8 7 7 1	7 0 4 8
Cortical drilling	89 7 89 2	26 0 25 9	9 1 6 8	6 4 5 3
Fracture	94 8 91 8	40 9 39 7	14 7 13 7	5 1 3 9
Cast only	7 1 6 9			

Number of animals in each group 2

Table 2a ^{85}*Sr activity measured in the proximal end of the right and left tibiae, expressed as counts per minute/gram*

	2 weeks		6 weeks		12 weeks		18 weeks	
	right side M ± SE	left side M ± SE	right side M ± SE	left side M ± SE	right side M ± SE	left side M ± SE	right side M ± SE	left side M ± SE
Periosteal stripping	13794 ± 961	9505 ± 665	11495 ± 924	9287 ± 766	8611 ± 694	8009 ± 583	11063 ± 516	10867 ± 402
Cortical drilling	20165 ± 843	12039 ± 754	32250 ± 729	28006 ± 598	24765 ± 1133	23778 ± 812	4072 ± 113	3991 ± 108
Fracture	27064 ± 704	15388 ± 434	16494 ± 816	11211 ± 571	14720 ± 1596	13064 ± 1436	25190 ± 711	24790 ± 561
Cast only	24815 ± 1140	23840 ± 815						

Number of animals in each group 5
M = mean
SE = standard error

Table 2b The rise in ^{85}*Sr activity in the proximal end of the tibiae, on the injured and immobilized side, expressed as a percentage of the control*

	2 weeks M ± SE	6 weeks M ± SE	12 weeks M ± SE	18 weeks M ± SE
Periosteal stripping	45 1 ± 0 5	24 0 ± 1 1	8 7 ± 1 8	1 8 ± 0 9
Cortical drilling	64 3 + 1 3	29 4 ± 1 3	5 0 ± 1 3	2 3 ± 1 0
Fracture	76 0 + 2.0	47 2 + 1 1	11 3 ± 0 7	1 8 ± 1 1
Cast only	- -			




Figure 2a The dilated sinusoids of the metaphyseal bone marrow are full of erythrocytes Signs of stasis are seen Haematoxylin eosin × 40 *b* Metaphyseal bone marrow of the intact tibia Haematoxylin eosin × 40

Figure 3a. The growth cartilage of the injured bone is widened. Haematoxylin-eosin × 40. b. The growth cartilage of the intact tibia. Haematoxylin-eosin × 40

	2 weeks		6 weeks		12 weeks		18 weeks	
	right side M ± SE	left side M ± SE	right side M ± SE	left side M ± SE	right side M ± SE	left side M ± SE	right side M ± SE	left side M ± SE
Periosteal stripping	658 ± 10	566 ± 8	545 ± 11	486 ± 9	443 ± 6	439 ± 9	289 ± 7	284 ± 9
Cortical drilling	684 ± 11	568 ± 9	541 ± 8	487 ± 9	463 ± 6	439 ± 8	288 ± 12	286 ± 13
Fracture	718 ± 12	570 ± 8	567 ± 10	484 ± 12	480 ± 10	435 ± 8	287 ± 10	286 ± 13
Cast only	567 ± 9	563 ± 6						

Number of animals in each group 10
M = mean
SE = standard error

Table 3b The increase in the height of the proximal growth cartilage of the tibiae on the injured and immobilised side, expressed in micra

	2 weeks M ± SE	6 weeks M ± SE	12 weeks M ± SE	18 weeks M ± SE
Periosteal stripping	92 ± 3	59 ± 3	4 ± 3	5 ± 2
Cortical drilling	116 ± 2	54 ± 1	24 ± 2	2 ± 1
Fracture	148 ± 3	83 ± 3	45 ± 2	1 ± 3
Cast only	4 ± 3			

Number of animals in each group 10
M = mean
SE = standard error








Figure 4a Reticular arrangement of the bony trabeculae in the metaphysis of the injured bone Haematoxylin eosin ×40 b Metaphysis of the intact tibia Longitudinal arrangement of the trabeculae Haematoxylin-eosin ×40

Figure 5a and b Comparative anteroposterior (a) and lateral (b) roentgenograms of the fractured and control tibiae 18 weeks after the diaphyseal fracture No structural difference in the proximal bone ends

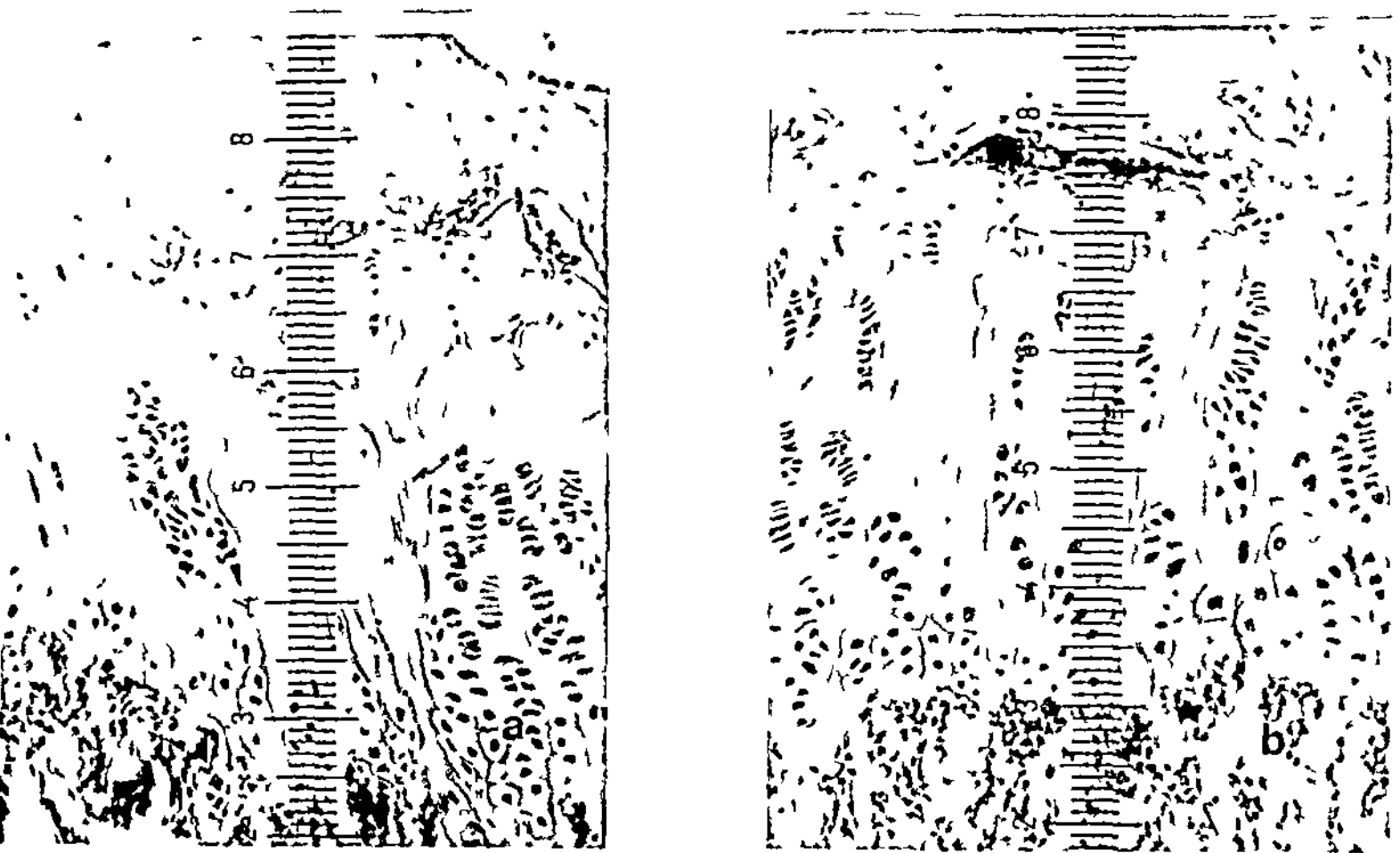


Figure 6a and b Degenerative changes in the growth cartilage of the injured (a) and intact bone (b)
Haematoxylin eosin × 40

the age of the animals the growth plate is hardly discernible on either side The metaphyseal transparency found before in the injured bones had disappeared (Figure 5a and b) The concentration of the ^{51}Cr labelled erythrocytes was not decidedly different on the two sides (Table 1) The activity of the ^{85}Sr showed a significant increase in the 12th week, by the 18th week the difference was no longer significant (Table 2a and b)

No signs of stasis could be observed in the bone marrow In the growth plate fibrous degeneration of the increased amount of ground substance and the complete disorganization of the columns of chondrocytes could be found bilaterally The trabeculae of the metaphysis were thin and no active osteogenesis could be seen (Figure 6a and b) The height of the growth cartilage was not significantly different on the two sides in the 18th week (Table 3a and b) These changes could be interpreted as signs of ageing and closure of the growth zones

DISCUSSION

The results of the investigations described can be interpreted in the following way

We have found that as a result of the diaphyseal injuries a thick connective tissue layer with fibrous and bony callus developed possibly impairing the circulation through the cortex

It was proved by Morgan (1959) and Brookes (1971) that the venous sinusoids of the metaphyseal bone marrow are drained especially via the large central vein of the bone marrow and through the emissary vein across the cortex If the venous circulation is damaged as a result of the diaphyseal injury, stasis will develop in the metaphyseal bone marrow As also described by Brookes we consistently observed after every kind of bone injury stasis in the metaphyseal bone marrow The presence of stasis is supported by the elevated concentration of ^{51}Cr labelled erythrocytes found in the metaphyseal bone marrow

Richards & Brookes (1968) describ[ed] in the pH of the tissue as a result of stasis, which enhances the forma[tion] immature bony tissue in osteo[...] Although pH was not measured w[e] found in the early stage an increase ground substance, a widening of the germinative and proliferative cells, a[...] cant increase in the height of the cartilage together with more [...] osseous tissue in the metaphysis increased metaphyseal transparency X ray pictures may be interpreted presence of immature bony trabec[...] proof of the consequent increa[...] mineralization, the activity of ^{85}Sr b[...] the bone minerals increased significa[...]

In the later stage as a sign [...] improving circulation the stasis disap[...] The normalization of growth and oss[...] may be interpreted as being a consequ[...] the return of normal circulation.

In the final stage the height of the cartilage on both sides and the percen[...] radioactivity did not show sig[...] differences Radiographic and hi[...] examinations showed signs of [...] closure of the growth zones

On the basis of the agreement betw[...] experiments and the data cited fr[...] literature it can be assumed that th[...] sensitive epiphyseal and metaphyseal [...] to diaphyseal injury to growing tibia[...] the resultant disturbed circulation and stasis. The investigations showed that [...] marked changes occurred after fra[...] lesser ones occurring after periosteal [...]

ACKNOWLEDGEMENTS

The authors are indebted to Mrs. K. Boga[...] help in the statistical analysis.

REFERENCES

Bisgard, J D (1936) Longitudinal overg[...] long bones with special reference to [...] *Surg Gynec Obstet.* 62, 823-835

…ount, W P (1955) *Fractures in childhood* Williams and Wilkins, Baltimore
…ookes, M. (1971) *The blood supply of bone* Butterworths, London
…ardsen P (1976) Overgrowth of the femur after fracture of the shaft in childhood *J Bone Jt Surg* 58-B, 339–342
…néus H & Hedström, Ö (1964) Overgrowth … fracture of the humerus in children … *orthop scand* 35, 51–58
…organ, J D (1959) Blood supply of growing rabbit's tibia *J Bone Jt Surg* 41-B, 185–204
Richards, D J & Brookes, M (1968) Osteogenesis and the pH of the osseous circulation. *Calcif Tissue Res* 2, Suppl 93
Snedecor, O W (1962) *Statistical methods* Applied to experiments in agriculture and biology 5th ed, 4th reprint. Iowa State University Press
Staheli, L T (1967) Femoral and tibial growth following femoral shaft fracture in childhood *Clin Orthop* 55, 159–163

…orrespondence to Lajos Kéry, M D, Orthopaediai Klinika, Budapest, Karolina ut 27, H–1113, …ungary

ta orthop scand. *51*, 755–759, 1979

ONGITUDINAL GROWTH AND DENTAL ˜EVELOPMENT IN OSTEOSARCOMA PATIENTS

–Å BROSTRÖM, U ADAMSON, R FILIPSSON & K HALL

⁻partment of Orthopaedic Surgery and Department of Endocrinology and Metabolism, Karolinska ɔspital and Department of Clinical Genetics, Karolinska Institute, Stockholm, Sweden.

The body height at 8 0 years and at the time of diagnosis, as well as the dental maturity, were analysed in a sample of patients with classical and primary osteosarcoma, registered in Sweden between 1972 and 1974, in order to investigate whether these patients have an accelerated body height growth In contrast to previous reports the height development was found to be normal The dental maturity was also normal

Key words bone tumour, endocrinology, growth, osteosarcoma

Accepted 12.xii 79

steosarcoma is a highly malignant tumour hich preferentially occurs in males (sex tio about 1 5) (Dahlin & Coventry 1967) ıd which generally appears during the first ɹree decades of life with a peak incidence ɔinciding with the pubertal growth spurt Veinfeld & Dudley 1962, Price 1958, Dahlin Coventry 1967, Lockshin & Higgins 1968, ɔranton et al 1975, Salzer et al 1976, arsson & Lorentzon 1974) Price (1958) und a correlation between the time of ⁻velopment of primary bone tumours and ⁻celerated skeletal growth Such a lationship is also supported by the observa- on that the predominant tumour location is ıe metaphyseal region of the long bones, i e ose to the growth zones (Dahlin & Coventry 967) Furthermore, it has been reported that steosarcoma occurs more frequently in tall ıdividuals (Fraumeni 1967) It should also be ıentioned that bone sarcoma in dogs, which ⁻sembles human osteosarcoma, is one undredfold more common in large sized dogs ıan in smaller ones (Tjalma 1966)

We were not able to confirm the previous observation of an accelerated body height growth in osteosarcoma patients in a preliminary analysis Therefore, the present work was carried out in order to study if growth and dental development differ between osteosarcoma patients and healthy individuals

PATIENTS AND METHODS

All osteosarcoma patients who had been reported to the Cancer Registry at the National Board of Health and Welfare in Sweden during the years *1972–1974* were included in the study Patients with paraosteal tumours or with clinical evidence of metastases upon admission to the hospital were excluded. There were altogether 44 osteosarcoma [illegible] osteosarcoma tumours located in the long bones were also included in the study

Information on body height from birth to the onset of the disease was obtained from the



Figure 1 Age distribution at the time of diagnosis, males (☐) and females (▨) (n = 19)

children's health centres and from the health services of the schools where body height is registered at regular intervals. Only cases in which two or more measurements were available around the age of 8 years and two or more measurements at the onset of the disease were included in the final analysis Accordingly 28 of the 47 subjects had to be excluded In the remaining 19 subjects (9 boys and 10 girls) the height at 8 0 years and the height at the age when the diagnosis was made were calculated by linear interpolation as described by Filipsson & Hall (1975) The height at 8 0 years was compared with the corresponding figure for normal Swedish children given by Taranger (1976) Since the total sample was small and the patients were of different chronological ages at the onset of the disease a standardized normal variable ($x_1 - x$/S D) (x_1 = the height of the subject, x = the normal mean height, S D = the normal standard deviation) was used

The number of erupted teeth is generally registered annually by the school dentists in Sweden Information on the number of erupted permanent teeth at different ages from about 7 years of age was obtained for 24 of the subjects (16 boys and 8 girls). Height registrations [illegible] available in 13 of these 24 subjects [illegible] maturity was analysed according to the [illegible] described by Filipsson (1975). This method [illegible] used for retrospective studies and is based [illegible] finding that the eruption curve of the [illegible] permanent molars and incisors has a simila[illegible] all children The individual tooth eruption [illegible] are, however, displaced in relation to each [illegible] along the age axis. The chronological [illegible] reference point on the curve can be used to [illegible] the dental maturity of each child

RESULTS

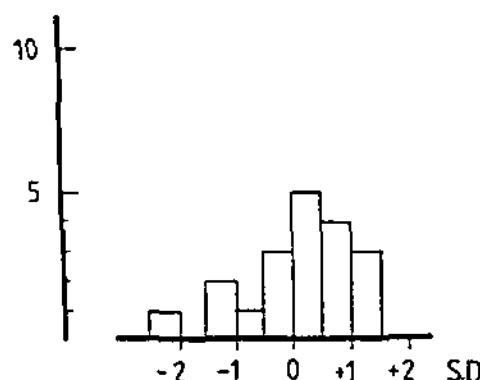
The mean age at the time of diagnosis [illegible] 17 4 years (S D = 7 1) in the whole [illegible] (47 patients), 19 1 years for the males [illegible] 14 2 for the females. The correspond[illegible] figures for the 9 males and 10 females [illegible] whom height registrations were [illegible] were 13 2 (S D = 2 9) and 13 4 years (S D [illegible] 4 4) respectively The distribution of the [illegible] at diagnosis in the latter group is ill[illegible] in Figure 1

The mean height of the osteosar[illegible] patients at the age of 8 0 years was 128 4 [illegible] for boys and 128 1 cm for the girls. As [illegible] from Table 1 these values are very [illegible] those found in normal Swedish boys and [illegible] (Taranger 1976) The difference in [illegible] between the patients and the healthy [illegible] was small and statistically not [illegible] The same was true for the height at the [illegible] of the disease The distribution of [illegible] standardized height variables at 8 0 years [illegible] at the time of diagnosis are shown in [illegible] 2 and 3 There was a significant [illegible] between the standardized height at 8 0 [illegible]

Table 1 Body height at the age of 8 0 years in osteosarcoma patients and healthy Swedish ch[illegible]

Group		Number of subjects	Body height, cm Mean	SD
Boys	patients	9	128 4	5 1
	controls	114*	128 6*	5 3*
Girls	patients	10	129 1	5 9
	controls	81*	127 4*	5 5*

* from Taranger (1976)



re 2 *Distribution of the standardized body ht ($x_i-\bar{x}$/S D) at the age of 8 0 years in cts with osteosarcoma (n = 19)*

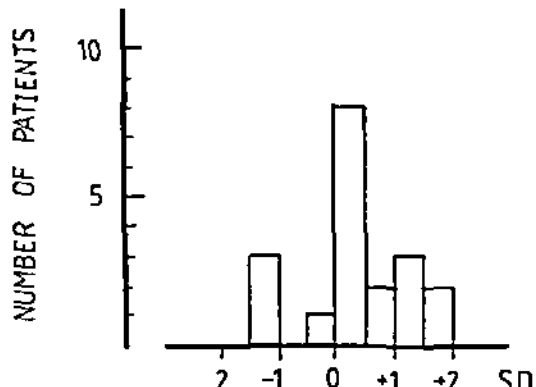


Figure 3 Distribution of the standardized body height ($x_i-\bar{x}$/S.D) at the age of diagnosis in subjects with osteosarcoma (n = 19)

the standardized height at the age of nosis ($r = 0\ 88$, $P < 0\ 001$) As seen from re 4 only two subjects deviated more one S D in their position in relation to normal mean height curve from 8 0 years he age of diagnosis

'he mean age at the reference point of the h eruption curve was 8 7 years for the s and 8 4 years for the girls These figures espond very well to the normal values for dish boys and girls (Table 2)

SCUSSION

contrast to previous reports (Price 1958, umeni 1967, Larsson & Lorentzon 1974) present study has shown that patients h primary and classical osteosarcoma do not have an accelerated body height growth This finding is also supported by the observation that the dental development was normal

The exclusion of subjects having too few height registrations might have had an influence on the results. However, there was no obvious difference between the total material and the analysed group with respect to the age at the onset of the disease This age, which was 13–14 years, is also in accordance with that found in other studies. The information on body height was more often lacking in males than in females and this could be of significance in a disease with a higher incidence of males. Since the evaluation of the growth data was made separately for the sexes the altered sex ratio in the analysed group can probably be disregarded.

The reports in the literature of a pre-

ble 2 Age at the reference point of the tooth eruption curve in patients with osteosarcoma and healthy Swedish children

Group		Number of subjects	Age at the reference point, years Mean	S.D
Boys	patients	16	8 67	0 70
	controls	133*	8 75*	0.73*
Girls	patients	8	8 36	0 63
	controls	137*	8.44*	0 68*

* from Filipsson (1975)

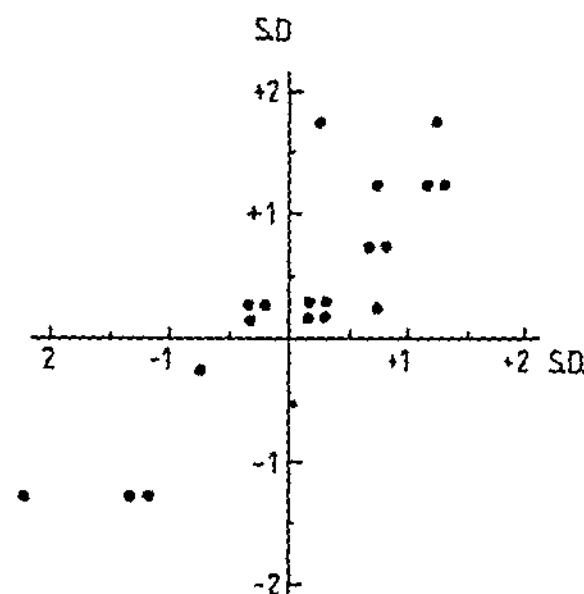


Figure 4 Correlation between the standardized height measurements at 8 0 years (abscissa) and at the age of diagnosis (ordinate) (n = 19)

dominance of tall stature and high growth rate in subjects with osteosarcoma were based on cross-sectional growth data and not on individual growth curves However, the evaluation of growth data in cross-sectional studies on pubescent children is difficult without information regarding the somatic maturation since there is a wide variation in the timing and duration of the adolescent growth spurt The change in growth rate around the age of diagnosis observed in some of the patients could therefore very well be attributed to pubertal maturation None of the three prepubertal patients in the present study showed an accelerated growth at the onset of the disease

Our findings do not definitely exclude the possibility that the tumours may have a growth promoting effect as suggested on the basis of hormonal studies in osteosarcoma patients (McMaster et al 1975) However, the time period with symptoms prior to diagnosis was only about 3 months which is in good agreement with that observed in previous reports (Brostrom et al 1980, Sweetnam et al 1971) This period appears to be too short to prove that there is an accelerated growth rate during the pubertal growth spurt

ACKNOWLEDGEMENTS

This work was supported by grants from Swedish Medical Research Council 4224, the Swedish Society of Medical Sciences and the Anders Otto Swärds fond

REFERENCES

Brostrom, L Å, Aparisi T, Ingimarsson [illegible] Lagergren, C., Nilsonne, U Strander F [illegible]

[illegible]

and a contemporary group *Int. J Rad [illegible] Biol Phys* (In press)

Dahlin, D & Coventry, M (1967) Osteo[illegible] sarcoma A study of six hundred cases *J B[illegible] Jt Surg* 49 A, 101–110

Filipsson, R & Hall, K (1975) Prediction of [illegible] height of girls from height and dental ma[illegible] at ages 6–10 years. *Ann. hum. Biol.* [illegible] 355–363

Filipsson, R (1975) A new method for assess[illegible] of dental maturity using the individual [illegible] number of erupted permanent teeth *Ann hu[illegible] Biol* 2, 13–24

Fraumeni, J (1967) Stature and malignant [illegible] of bone in childhood and adolescence *Can[illegible]* 20, 967–973

Larsson, S E & Lorentzon, R (197[illegible]) T[illegible] incidence of malignant primary bone [illegible] in relation to age, sex and site – a stud[illegible] osteogenic sarcoma chondrosarcoma [illegible] Ewing's sarcoma diagnosed in Sweden [illegible] 1958 to 1968 *J Bone Jt Surg* 56-B [illegible]

Lockshin, M D & Higgins, I T T ([illegible]) Prognosis in osteogenic sarcoma *Clin Orth[illegible]* 58, 85–101

McMaster, J, Scranton P & Drash, A ([illegible]) Growth and hormone control mechanisms [illegible] osteosarcoma Evidence for a new thera[illegible] approach *Clin Orthop* 106, 366–3[illegible]

Price, C H G (1958) Primary bone-f[illegible] tumours and their relationship to [illegible] growth *J Bone Jt Surg* 40-B 574–5[illegible]

Salzer, M, Salzer-Kuntschnik, M, Z[illegible] Price, C. H G, Willert, H G, [illegible] M, Matejovsky, Z., Groh, P & K[illegible] (1976) Therapie und Prognose des [illegible] Osteosarcoms. *Arch orthop [illegible]* 279–287

anton Jr, P E, De Cicco, F A, Totten, R. S & Yunis, E J (1975) Prognostic factors in osteosarcoma *Cancer* 36, 2179–2191

eetnam E, Knowelden, J & Seddon, H (1971) Bone sarcoma treatment by irradiation, amputation or a combination of the two *Brit med J* 2, 363–367

ranger, J (1976) The somatic development of children in a Swedish urban community – a prospective longitudinal study Thesis. Gothenburg University Medical School, Sweden

Tjalma, R A (1966) Canine bone sarcoma, estimation of relative risk as a function of body size *J nat Cancer Inst* 36, 1137–1150

Weinfeld, M. D & Dudley, H R. (1962) Osteogenic sarcoma. A follow-up study of the 94 cases observed at the Massachusetts General Hospital from 1920–1960. *J Bone Jt Surg* 44-A, 269–276

rrespondence to Lars-Åke Broström M.D, Department of Orthopaedic Surgery Karolinska Hospital 04 01 Stockholm, Sweden

a orthop scand. 51, 761–765 1980

ƆSTOPERATIVE INFECTIONS RESULTING ROM BACTEREMIA

ɿ Experimental Study ın Rabbıts

BLOMGREN & U LINDGREN

·partment of Orthopaedic Surgery, Huddinge University Hospital,
ıddinge, Sweden

The possibility that postoperative infections can result from bacteremia in the early postoperative period was investigated in an animal model. Defects were made bilaterally in the proximal femora of rabbits. On one side the defects were filled with acrylic bone cement The rabbits were infected with a suspension of *Staphylococcus aureus* either in the wound hematoma or by an intravenous route The cement implant did not attract infection, as the infections became equally distributed both on the cemented and the uncemented side in the locally as well as in the intravenously inoculated group The experiment also shows that if bacteria occur in the bloodstream in the early postoperative period there is a high risk of the wound becoming infected

Key words bacteremia, bone cement, postoperative complications wound infection

Accepted 26 ıı 80

ɔr a long time it has been known that ıumatized areas can become the seat of a ɔod-borne infection (Starr 1922, Winters & ıhen 1960, Gerszten et al 1970) Acute ·matogenous osteomyelitis has been ported to follow closed fractures (Canale et 1975, Watson & Whitesides 1976) The ɹrgical trauma has, however, not been conɹered in earlier discussion The present ıdy investigates the susceptibility of an ·erative wound to hematogenous infection

ATERIALS AND METHODS

ı standard operation was performed on the right d left femora of 14 male New Zealand rabbits able 1) Anesthesia with barbiturate (Nembutal ɔbot Laboratories) and ketamin chloride etalar Parke-Davis & Co) was used Skin ɜrilization and draping as in an ordinary operating theater was applied. A longitudinal incision exposed the lateral aspect of the proximal f [illegible]

Laboratories Ltd), on the left side no further procedures were performed The wound was closed with absorbable polyglycolic acid sutures (Dexon, Davis and Geck Ltd).

On the first postoperative day 1 ml of a bacterial suspension containing a *Staphylococcus aureus* strain (Wood 46) was injected into an auricular vein in seven rabbits. Simultaneously seven rabbits had 0 5 ml of the same bacterial suspension injected into the postoperative hematoma. Daily injections were continued for 3 days. The experimental period was 1 week in the group receiving direct inoculation and 2 weeks in the intravenously inoculated group.

The *Staphylococcus aureus* strain (Wood 46) is known to be able to cause septic arthritis (Lindberg 1969) and is sensitive to most commonly used antibiotics. After one animal passage the strain was tested for desoxy-

)1–6470/80 050761–05$02.50 0

Table 1 Details of the experiment

	Animals receiving	
	Direct inoculation	Intravenous inoculation
n	7	7
Initial body weight (g)	2730 ± 260	2710 ± 220
Final body weight (g)	2500 ± 120	2110 ± 430
Experimental period	1 week	2 weeks
Average number of bacteria per dose	3.2×10^{9}	7.2×10^{6}

ribonuclease and coagulase and phage typing was done according to standardized methods The strain was then used in the experiment

Autopsy was performed after 1 or 2 weeks, respectively, according to a detailed scheme and a new set of sterile instruments was used for each anatomical layer A bacteriologic specimen was obtained from each location using a sterile cotton stick Samples were taken from the surgical areas blood, lungs kidneys liver, spleen and heart The specimens were cultured on blood agar and hematin plates and incubated for 12 hours at 37° C, if necessary the plates were incubated for another 24 hours Colonies suspected of being *Staphylococci* were tested first for desoxyribonuclease and then for coagulase and all positive colonies were phage typed

RESULTS

The general condition of the rabbits [illegible] bacteria intravenously was severely [illegible] and they had a greater loss of body [illegible] compared with those receiving direct [illegible] oculations into the wound hematoma [illegible] 1) During the first 24–48 hours of the [illegible] periment, the intravenously infected [illegible] did not consume measurable quantities [illegible] food or water Two rabbits did not [illegible] and died on the 6th and 7th post[illegible] day, respectively (Table 2). One rabbit [illegible] seems to have died of septicemia [illegible]

Table 2 Macrosopic infections at autopsy (= abscesses)

	Rabbit no	Kidney	Lung	Liver	Right femur (cement)	Left femur
Animals receiving direct inoculation	1	—	—	—	—	—
	2	—	—	—	—	Abscess
	3	—	—	—	—	—
	4	—	—	—	—	—
	5	—	—	—	—	—
	6	—	—	—	Abscess	—
	7	—	—	—	Abscess	—
Animals receiving intravenous inoculation	1	—	—	—	—	—
	2	—	—	—	Abscess	Abscess
	3†	—	—	—	—	—
	4	—	—	—	—	—
	5†	—	—	—	—	—
	6	—	—	—	Abscess	—
	7	—	—	—	—	Abscess

† Died

Table 3 Results of the bacteriologic analysis

	Rabbit no	Heart blood	Kidney	Lung	Liver	Right femur (cement)	Left femur
nimals	1	—	—	—	—	—	—
eiving	2	—	—	—	—	—	S.A
ect	3	—	S A	—	—	—	—
oculation	4	—	—	—	—	S.A	—
	5	—	—	—	—	—	S A.
	6	—	—	—	—	S.A.	S.A
	7	—	—	—	—	S.A	—
nimals	1	—	S A	G-rod	—	—	S.A
eiving	2	—	S A	—	—	S.A	S A.
ravenous	3	E coli	E coli	E coli	E coli	E coli	E coli
oculation			S.A				
	4	—	S A	—	S.A	S.A	S.A
	5	S A	S.A	S.A.	S A	S.A.	S.A.
	6	—	S A.	—	—	S A	—
	7	—	—	E coli	—	S.A	S A

A – Staphylococcus aureus of the experimental strain (Wood 46) proved by phage typing

aph aureus strain whereas in the other 3) dissemination with *E coli* had curred None in the directly inoculated oup died

Autopsy performed after the experimental riod on the remaining rabbits revealed acroscopic signs of infection in the area of eration in half the cases, but only in seven murs had indisputable abscesses formed e macroscopic infections were evenly dis-buted between the two experimental oups. Apart from the area of surgery, no vious macroscopic infection was found able 2) The bacterial evaluation (Table 3) owed that at the end of the experiment cteremia had disappeared in all the in-avenously infected rabbits The ex-rimental strain of *Staph aureus* was, wever frequently isolated from the dneys.

In four intravenously infected rabbits, *aph aureus* was found around the mented defect of the femur and in four ound the uncemented femur defect Thus, ly two of the operated femurs were found be sterile in the intravenously infected oup

In the group of seven rabbits that had been directly inoculated with *Staph aureus* at the femur defect, three defects with and three without cement were infected at the end of the observation period Obviously, the cement was in neither group associated with a change in the incidence of infection.

DISCUSSION

Staphylococcus aureus (Wood 46) was used in this experiment because of its known potentiality to cause bone and joint infection (Rigdon 1942, Lindberg 1969, Norden & Kennedy 1970) and the possibility of identifying the experimental strain according to the phage type The dispersion of *Staphylococcus aureus* in the blood resulted in a considerable death rate in these series. The experimental period of 2 weeks was chosen in order to allow the bacteremia to disappear before sacrifice After that period no positive blood culture was found but a remarkably high number of cultures from the kidneys were

positive Continuation of bacteremia as a kidney infection has been reported earlier by Thompson & Dubos (1938), Norden & Kennedy (1970) and Elson et al. (1977).

This experiment shows that if bacteria occur in the bloodstream during the early postoperative period there is a definite risk of wound infection Surgery often necessitates prolonged intravenous support and in some cases urinary catheterizations are performed This involves a risk of bacteremia (Maki et al 1973 Donovan et al 1976, Svanbom 1979) and will be of particular significance in artificial joint replacements because of the known difficulties in overcoming the infection in such cases (Creuss et al 1975 D'Ambrosia et al 1976, Downes 1977, Ahlberg et al 1978)

Howe (1968) proved that a silk suture implanted in a surgical wound in guinea pigs did not lead to a higher infection rate after a period of bacteremia than in control wounds The rate of infection found in this experiment is in agreement with that found in an experiment by Elson et al (1977) in which an infection rate of 70 per cent was noted in rats after intravenous injection of *Staph aureus* However, no conclusion as to whether the bone cement or the operative trauma alone caused wound infection can be drawn from their series In both the series mentioned (Howe 1968, Elson et al 1977) bacteremia occurred during a period when wound bleeding must have been present to some extent This is not likely to be the case in the present experiment, thus indicating that it was the *traumatized tissue* which tended to attract hematogenous infection In our experiment the cement implant obviously did not lead to higher infection rates in the locally or the intravenously inoculated group The size of the infection dose is of decisive importance to the development of a clinical infection This factor is difficult to determine in bacteremia since the bacteria may multiply in the blood during a short period of time and then disappear But if bacteremia occurs during the early postoperative period a postoperative infection is likely to occur

REFERENCES

Ahlberg Å., Carlsson, Å S & Lindberg L [illegible] Hematogenous infections in total joint replacement. *Clin. Orthop* 137, 69 75

Canale S T., Puhl, J Watson, F M & [illegible] R (1975) Acute osteomyelitis following [illegible] fractures. *J Bone Jt Surg* 57 A, 415-[illegible]

Cruess, R. L Bickel, W S & von Kessler K. C. (1975) *Infections in total hips secondary to a primary source elsewhere* *Clin. Orthop* [illegible] 99–101

D Ambrosia R D., Shoji H. & Heater R. [illegible] Secondarily infected total joint replacements [illegible] hematogenous spread. *J Bone Jt Surg* [illegible] 450–453

Donovan T L. Gordon R. & Nagel D A [illegible] Urinary infections in total hip arthroplasty [illegible] *Bone Jt Surg* 58 A 1134–1137

Downes, M E (1977) *Late infections after total hip replacement* *J Bone Jt Surg* [illegible] 42–44

Elson R. A Jephcott A. E., McGechie, D [illegible] Verettas, D (1977) *Bacterial infection* [illegible] acrylic cement in the rat. *J Bone Jt Surg* [illegible] 453–457

Gerszten E Allison, M J & *Dalton, H. P* [illegible] An epidemiologic study of 100 [illegible] cases of osteomyelitis, *Sth. med. J (Birmingham, Ala)* 63, 365–367

Howe C W (1968) *Experimental wound* [illegible] *from transient bacteremia. Surg Gynec Obstet* 126, 1066 1070

Lindberg L. (1969) Experimental staphylococcal arthritis in golden hamsters (Mesocricetus Auratus) *Acta path. microbiol. scand.* [illegible] 117–125

Maki B G., Goldman, D A. & Rhame F [illegible] (1973) Infection control in intravenous therapy *Ann intern. Med.* 79 867–887

Norden C W & Kennedy E. [illegible] perimental osteomyelitis. I A description of the model. *J infect. Dis* 122 410–418

Rigdon R H (1942) Pathogenesis of [illegible] following the intravenous [illegible] staphylococci in the adult rabbit. *Arch Surg* 55, 553–561

Starr C L. (1922) *Acute hematogenous* [illegible] teomyelitis. *Arch Surg* 4, 567 [illegible]

Svanbom M (1979) Septicemia and [illegible] endocarditis in a *Swedish hospital* [illegible] fectious diseases. Thesis, Roslagstull [illegible] Stockholm Sweden.

Thompson R. H S & *Dubos*, R. J [illegible] Production of experimental osteomyelitis [illegible] rabbits by intravenous [illegible] Staphylococcus aureus. *J exp. Med.* [illegible] 191–209

ıtson, F M & Whitesides, T. E. (1976) Acute hematogenous osteomyelitis complicating ıclosed fractures. *Clin. Orthop* **117**, 296–302.

Winters, J L. & Cahen, I. (1960) Acute hematogenous osteomyelitis. *J Bone Jt Surg* **42-A**, 691–704

rrespondence to Urban Lindgren, M D, Department of Orthopaedic Surgery, 141 86 Huddinge ospital, Sweden

a orthop scand. 51, 767–771, 1980

ƆFT TISSUE INTERPOSITION ARTHROPLASTY ƆR OSTEOARTHRITIS OF THE ARPOMETACARPAL JOINT OF THE THUMB

F LUCHT, POVL SIGURD VANG & JØRGEN MUNCK

thopedic Hospital, Aarhus, Denmark

A soft tissue interposition arthroplasty for carpometacarpal osteoarthritis of the thumb is described Thirty-seven joints in 32 patients were operated on The results with regard to pain, strength and mobility are recorded In 34 cases the patients reported considerable improvement after the operation and the majority of the patients could resume their usual work Only minor complications occurred

Key words carpometacarpal osteoarthritis interposition arthroplasty, thumb

Accepted 3 iii.80

teoarthritis of the carpometacarpal joint of thumb occurs most frequently in women er the menopause (Aune 1955) It may be a quel to Bennett's fracture, but in most cases aetiology has not been established owever, reduced stability of the joint due to permobility seems to be a predisposing tor (Aune 1955, Eaton & Littler 1973) hen the arthritic changes progress they ay result in a painful thumb with decreased obility and strength

In the early stage of the arthritis, rest and nservative treatment with splinting and rticosteroid injections can be helpful In ses with advanced degenerative changes eration is the only means of improving the ndition The following types of operations ve been used Excisional arthroplasty of the apezium (Gervis 1949, Murley 1960, einmann & Lipscomb 1967), fusion of the apeziometacarpal joint (Leach & Bolton '68 Mattsson 1969, Eaton & Littler 1969, ken & Carstam 1970, Stark et al 1977) icone implant arthroplasty (Swanson 1972, essler 1973, Dickson 1976 Ferlic et al. 1977, Haffajee 1977, Lister et al 1977) and total prosthesis (Caffinière 1973, Kremchek et al 1978)

The aim of the present paper is to present an additional and easy method which is applicable in most cases of carpometacarpal osteoarthritis of the thumb

METHOD

The operation is performed under regional anaesthesia A slightly curved dorsal incision is made from the styloid process of the radius to the middle of the first metacarpal bone. The superficial branch of the radial sensory nerve is identified and preserved and the trapeziometacarpal joint localized. A soft tissue flap consisting of subcutaneous adipose tissue and connective tissue, is dissected from the anatomical snuff-box. The flap has a breadth of 1½–2 cm and a length of 3–3½ cm with the base located outside the proximal end of the first metacarpal bone (Figure 1). During the dissection the radial artery is identified and care is taken not to damage this structure. Then the capsule of the trapeziometacarpal joint is opened the full breadth

01–6470 80 050767–05$02 50 ©

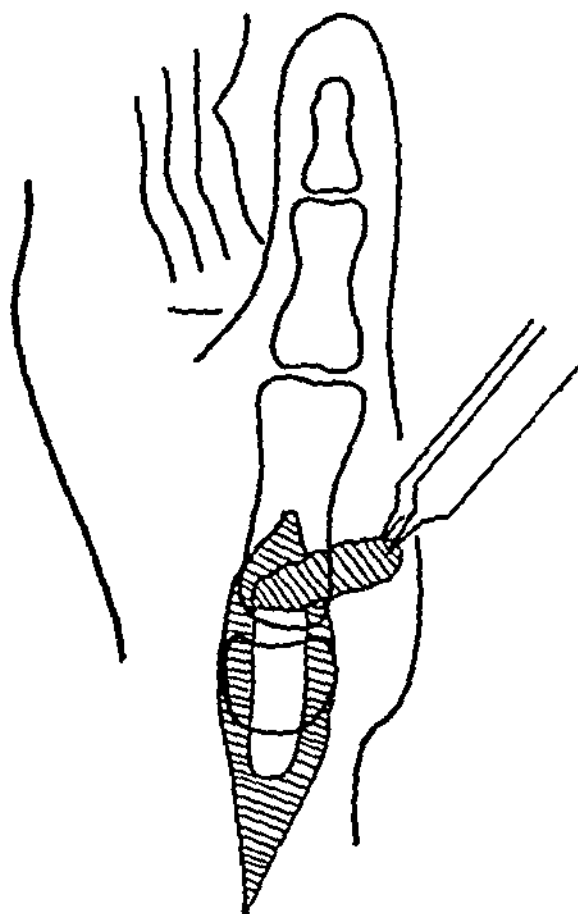


Figure 1 The soft tissue flap before the interposition

of the joint The capsule is dissected from the bones leaving a collar of 3–4 mm on each side By pulling the thumb the trapeziometacarpal joint can be opened Osteophytes and cartilage are removed until an opening of approximately 3–4 mm is obtained while pull ng the finger slightly The soft tissue flap is now interposed between the trapezium and the metacarpal bone by means of a resorbable suture The suture is pulled through the tip of the flap and both ends of the suture are passed down through the opening and through the skin on the volar side of the hand where they are knotted over a small gauze tampon The interposition can be supplemented with a part of the abductor pollicis longus tendon preserving its distal insertion In the present series this was done in 23 cases (62 per cent) Finally the joint capsule is closed using non resorbable sutures The thumb is immobilized in abduction with an elastic bandage for 3 weeks after which the patients begin active exercises (Figure 2a b)

MATERIAL

During the period 1966–1977 34 pa[illegible] operated on The main indication [illegible] operation was pain which had not [illegible] conservative treatment. The average [illegible] symptoms prior to the operation was 3 [illegible] 8 months.

At the follow-up examination one [illegible] died and one had moved abroad. The [illegible] includes the remaining 32 patients. In five [illegible] both thumbs have been operated on, [illegible] total of 37 operations. The average [illegible] period was 5 years and 7 months [illegible] minimum follow up period 15 months.

The age of the patients at the time of [illegible] varied between 23 and 70 years with an [illegible] 55 years. There were 3 men (9 4 per cent) [illegible] women (90 6 per cent). All the women [illegible] man had idiopathic osteoarthritis. The [illegible]



Figure 2 Osteoarthritis of the [illegible] joint of the thumb (a). The same [illegible] operation (b)

ble 1 The metacarpal angle after soft tissue interposition arthroplasty for osteoarthritis

Metacarpal angle	Total no of thumbs	No of thumbs with hyperextension in the metacarpophalangeal joint
> 40°	5	0
30°–40°	8	3
20°–30°	12	8
< 20°	12	11
	37	22

n developed osteoarthritis after Bennett's cture

The average time of hospitalization was 3 days. e patient developed a wound infection stoperatively but she recovered without further gery Another patient sustained a post-umatic sympathetic dystrophy She was treated h stellate blocks and was immobilized for 4 eks after which the symptoms disappeared.

SULTS

e criteria described by Kessler (1973) for assessment of results were the ones used the present material, in a modified form.

in Twenty-nine joints (78 per cent) were mpletely free of pain In five joints (14 per nt) mild and periodic pain occurred These tients especially complained of pain after rd work. In the remaining three joints (8 r cent) there were still significant and her constant pains. The pain in these three tients could be explained by arthritis in the ier articulations of the trapezium A pan-pezium arthritis was not present in the ier patients in the material

nch test The strength of the thumb was sted by asking the patients to pinch a sheet paper firmly between the thumb and the dex finger A normal pinch when the sheet uld not be withdrawn was shown in all but e case

Ability to touch the base of the fifth finger In the present series 32 thumbs (87 per cent) could reach the centre of the base of the little finger Two fingers could be opposed to a distance of 1 cm, two fingers to a distance of 2 cm and one to a distance of 4 cm The last patient had arthrodesis in the metacarpophalangeal joint of the thumb

The metacarpal angle The angle between the first and the second metacarpals in adduction and in radial abduction was measured in radiographs taken with the hand in pronation on a flat surface The angle was more than 40° in 5 cases, between 30° and 40° in 8 cases, between 20° and 30° in 12 cases and below 20° in 12 cases. As shown in Table 1 a reduced angle is combined with hyperextension in the metacarpophalangeal joint of the thumb

Personal evaluation All but the three patients with pantrapezium arthritis reported considerable improvement after the operation

One woman stopped working outside the house after the operation, three patients changed to an easier job, while the remaining 28 patients resumed their usual work. In eight cases the patients had some difficulty handling a small object like a sewing-needle

DISCUSSION

None of the operations designed for treatment of osteoarthritis of the thumb has resulted in a stable, painless thumb with satisfactory strength and reasonable movement in all cases. The excisional arthroplasty of the trapezium is simple and provides a pain-free and mobile thumb, but the strength is decreased and the joint rather unstable (Murley 1960, Weilby 1971) Froimson (1970) and Buck-Gramcko (1972), however, combined the excision of the trapezium with insertion of tendon graft interposition material and reported good results. Fusion of the trapeziometacarpal joint

creates good stability but the mobility is reduced In addition, fusion takes a long time and pseudarthrosis often occurs (Mattsson 1969, Weilby 1971) Stark et al (1977) did not find that fusion predisposed to painful arthritis of the trapezioscaphoid joint The interposition arthroplasty introducing silicone into the joint has in some materials given good results (Kessler 1973, Dickson 1976, Aschworth et al 1977), but Crawford (1977) at a follow-up found chronic synovitis and torn and dislocated prostheses The most frequently used method is excision of the trapezium and replacement with a silicone prosthesis In ideal cases this method provides good stability and motion as well as freedom from pain However, the common problem with the trapezium arthroplasty has been subluxation and dislocation of the trapezium implant, which has been described in up to 32 per cent of the operated joints (Weilby & Søndorf 1978) The number of dislocations can be reduced by improved operation technique including tendinous reinforcement of the capsular repair (Swanson 1972, Ferlic et al 1977, Haffajee 1977, Lister et al 1977), or stabilization of the implant by incorporation of a local tendon strip (Eaton 1979) The total prosthesis is a promising method for operation of carpometacarpal arthritis of the thumb, but only small series have been published (Caffinière 1973 Kremchek et al 1978)

The present method for operation of disabling osteoarthritis of the thumb is technically simple and in most cases the patients were effectively relieved of pain The abduction of the thumb was somewhat reduced and a compensatory hyperextension of the metacarpophalangeal joint had developed However, the function of the thumb was sufficient for the patients to perform their usual work except for the heaviest procedures, and in no cases was the thumb unstable The method was not very suitable when the carpometacarpal arthritis was part of a pantrapezium arthritis, which in the present series occurred in 3 out of 37 cases. It is suggested that pain in these patients derived from the trapezi[illegible] joint Kessler (1973), among 60 pa[illegible] with osteoarthritis of the carpometa[illegible] joint of the thumb, had only fo[illegible] with associated osteoarthritis of [illegible] trapezioscaphoid joint, while Swanso[illegible] found additional arthritic changes [illegible] second trapeziometacarpal joint in [illegible] cent, in the trapeziotrapezoid joint in [illegible] cent and in the trapezioscaphoid joi[illegible] per cent

The operation method to some exte[illegible] to be chosen with due regard to the pa[illegible] work Thus fusion may be the [illegible] procedure of choice in those pati[illegible] whom stability and strength are very [illegible] tant For the patient not doing heav[illegible] the present method is a simple alterna[illegible] the other available methods. In contra[illegible] previously described soft tissue in[illegible] methods (Froimson 1970 Buck-Gr[illegible] 1972) it is not necessary to remov[illegible] trapezium, which is the keystone [illegible] thumb arch (Lister et al. 197[illegible]) [illegible] advantages are that foreign materi[illegible] thumb is avoided and the possibili[illegible] future revision operation is not jeopar[illegible]

REFERENCES

Aschworth C. R., Blatt G., Chuinard, R. G[illegible] Stark H H (1977) Silicone-rubber [illegible] tion arthroplasty of the carpometacarpal [illegible] of the thumb *J Hand Surg* 2, 345–[illegible]

Aune S (1955) Osteoarthritis of the [illegible] carpometacarpal joint. *Acta chir scand* [illegible] 449–456

Buck-Gramcko D (1972) *Operative Behandlung* [illegible] des Sattelgelenksarthrose des Daumens [illegible] *Handchirurgie* 4, 105–109

Caffinière J Y (1973) Prothèse totale [illegible] métacarpienne *Rev Chir orthop* [illegible] 299–308

Crawford G P (1977) Interposition arthroplasty of the carpometacarpal joint of the thumb [illegible] *Hand* 9, 130–134

Dickson R A (1976) Arthritis of the car[illegible] tacarpal joint of the thumb. Treatment [illegible] silicone sponge interposition arthroplasty [illegible] *Hand* 8, 197–203

on R G (1979) Replacement of the trapezium for arthritis of the basal articulations *J Bone Jt Surg* 61-A, 76–82

on, R. G & Littler, J W (1969) A study of the basal joint of the thumb Treatment of its disabilities by fusion *J Bone Jt surg* 51-A, 661–668

on R G & Littler, J W (1973) Ligament ... ion for the painful thumb joint *J Bone Jt Surg* 55-A, 55–1666

en, O & Carstam, N (1970) Functional assessment of basal joint fusion of the thumb *Scand J plast reconstr Surg* 4, 122–125

lie, D C, Busbee, G A. & Clayton, M L (1977) Degenerative arthritis of the carpometacarpal joint of the thumb A clinical follow-up of eleven Niebauer prostheses *J Hand Surg* 2, 212–215

mson, A 1 (1970) Tendon arthroplasty of the trapeziometacarpal joint *Clin Orthop* 70, 191–199

rvis, W H (1949) Excision of the trapezium for osteoarthritis of the trapezio-metacarpal joint *J Bone Jt Surg* 31 B, 537–539

ffajee D (1977) Endoprosthetic replacement of the trapezium for arthrosis in the carpometacarpal joint of the thumb *J Hand Surg* 2, 141–148

ssler, I (1973) Silicone arthroplasty of the trapeziometacarpal joint *J Bone Jt Surg* 55 B, 285–291

emchek, E J, Duffy, F P., Zenni, E J & Sheridan, R. T (1978) Arthritis of the basal joint of the thumb and surgical treatment *Orthop Transact* 2, 35

Leach, R E & Bolton, P E (1968) Arthritis of the carpometacarpal joint of the thumb Results of arthrodesis. *J Bone Jt Surg* 50-A, 1171–1177

Lister, G D, Kleinert, H E, Kutz, J & Atasoy, E (1977) Arthritis of the trapezial articulations treated by prosthetic replacement. *The Hand* 9, 117–129

Mattsson H S (1979) Arthrodesis of the first carpometacarpal joint for osteoarthrosis. *Acta orthop scand* 40, 602–607

Murley, A H G (1960) Excision of the trapezium in osteoarthritis of the first carpometacarpal joint *J Bone Jt Surg* 42 B, 502–507

Stark, H H, Moore J F, Ashworth, C R & Boyes, J H (1977) Fusion of the first metacarpotrapezial joint for degenerative arthritis *J Bone Jt Surg* 59 A, 22–26

Swanson, A. B (1972) Disabling arthritis of the base of the thumb Treatment by resection of the trapezium and flexible (Silicone) implant arthroplasty *J Bone Jt Surg* 54-A 456–471

Weilby, A (1971) Surgical treatment of osteoarthritis of the carpometacarpal joint of the thumb *Scand J plast reconstr Surg* 5, 136–141

Weilby, A & Søndorf, J (1978) Results following removal of silicone trapezium metacarpal implants *J Hand Surg* 3, 154–156

Weinman, D T & Lipscomb, P R (1967) Degenerative arthritis of the trapeziometacarpal joint Arthrodesis or excision? *Mayo Clin Proc* 42, 276–287

orrespondence to Ulf Lucht Mirabellevej 7, 8240 Risskov, Denmark

ɔLLAGEN-INDUCED PLATELET AGGREGATION ꟿD BLEEDING TIME IN ADOLESCENT ꞁIOPATHIC SCOLIOSIS

F UDEN, INGA MARIE NILSSON & STIG WILLNER

ɔartment of Orthopaedic Surgery and Coagulation Laboratory Malmo, General Hospital, (University ‿und), Malmo, Sweden

Collagen is the main supportive protein of connective tissue Another of its functions is the initiation of haemostasis by activation of the platelets. It has been suggested that collagen is abnormal in idiopathic scoliosis. The present study lends further support to this view collagen of fascia specimens from patients with adolescent idiopathic scoliosis was found to aggregate platelets less readily than collagen from non scoliotic controls and suspensions of fascia from patients with adolescent idiopathic scoliosis contained more collagen than those from the controls. The collagen abnormality is probably also reflected in a prolonged bleeding time. The changes in the collagen in patients with scoliosis persist at least for some years after the cessation of growth.

Key words bleeding time, collagen, scoliosis

Accepted 18 iii.80

the possible underlying causes of ɔpathic scoliosis, only hereditary factors now widely accepted, but nothing definite known of their mode of action (Cowell et 1972, Harrington 1977, Wynne-Davies 58) In the last decade a disturbance of ınective tissue has been discussed as a ssible causal factor, it having been served that scoliosis is unusually common patients with defective collagen, e g in lers-Danlos syndrome and in Marfan's ıdrome (McKusick 1972)

Collagen is the most important ɔportive factor of connective tissue other important function of collagen is the tiation of haemostasis by activation of the telets (Hugues 1960) The connection ween collagen defects and impaired ‾mostasis has been described in different types of Ehlers-Danlos syndrome (Karaca et al 1972, McKusick 1972, Pinnell et al 1972) and in scurvy (Caen & Legrand 1972) This paper concerns possible defects of the collagen in adolescent idiopathic scoliosis and the influence of collagen on bleeding time

MATERIAL

The material consisted of 14 females and one male with adolescent idiopathic scoliosis with a range of curves between 50–100° according to Cobb The patients were operated on in a one-step procedure with correction and internal fixation according to Harrington and posterior fusion. Biopsy specimens were obtained from the fascia of the longitudinal dorsal muscles on the convex as well as on the concave side of the curve. Ten age-matched patients (three females and seven males)

ıs investigation was supported by grants from the Swedish Medical Research Council (B79-19X-)97 15B and B78-17X-04780-

ı1-6470 80 050773-05$02.50

Table 1 Results of the analysis of collagen from patients with idiopathic scoliosis and [illegible] first figure in brackets denotes the mean values for control samples obtained from back [illegible] second figure, mean values for the other control samples CC = minimal concentration of [illegible] platelet rich plasma (PRP) that induces platelet aggregation

No	Age years av ± s d	Collagen in suspension mg/1 av ± s.d	CC mg collagen/1 PRP a v ± s.d	CC mg collagen/1 PRP Geometric mean and range	[illegible]
Scoliosis 15	18 ± 4	130 ± 70	3 2 ± 2 4	2 5 (1 3–8.4)	[illegible]
Controls 10	19 ± 6	50 ± 20	0 8 ± 0 4	0 7 (0 2–1 4)	[illegible]
(5 + 5)	(16 21)	(50 50)	(1 0 0 6)		[illegible]
t-test for difference between means		$P<0\ 01$	$P<0\ 01$	$P<0\ 001$	[illegible]

operated upon for disc herniation, spondylolisthesis or fractures of the extremities served as controls (Table 1) In five cases the specimens were obtained from the fascia of the same muscles, as in the scoliotic group, in the remaining five, from the muscle fasciae of the extremities

The bleeding time was determined in 68 patients, aged 11 to 32 years (mean 18 ± 6 years), operated for scoliosis, and in 24 healthy non-scoliotic controls, aged 11 to 16 years (mean 13 ± 2 years)

METHODS

Collagen suspensions were prepared as described in detail elsewhere (Udén & Nilsson 1978) In short, the pieces of fascia were scraped clean freeze-dried in a vacuum and homogenized in ice-cold 8 35 mM acetic acid for 60–90 seconds. The suspension was stored at −60°C Before being used it was rehomogenized and centrifuged at 1200*g* for 30 minutes at + 4°C The supernatant which was clear was immediately used to determine the platelet aggregating power of the collagen The amount of collagen in the supernatant was calculated from the content of hydroxyproline measured by a modified Woessner method (Udén & Nilsson 1978)

The platelet aggregation was assessed photometrically A Payton Dual Channel Aggregation Module was used It includes constant magnetic stirring and constant recording of the transmission The lowest concentration of collagen in platelet-rich plasma (PRP) that induced platelet aggregation was called the critical concentration (CC) – high CC is associated with low aggregating power (Udén & Nilsson 1978) PRP was obtained from healthy volunteers [illegible] responsiveness of PRP even from healthy [illegible] varies the CC of the collagen suspension [illegible] scoliotic patients and from controls [illegible] expressed [illegible] (C [illegible] fa[illegible] Ivy [illegible]

The statistical methods used were [illegible] *t* test for differences between means and [illegible] linear correlation test

RESULTS

The collagen content of the suspension [illegible] patients with scoliosis was [illegible] higher than that from controls, [illegible] collagen from patients with scoliosis [illegible] aggregated platelets only one-[illegible] efficiently as collagen from the [illegible] (Table 1) The first figure in brackets [illegible] 1) denotes the mean value found for [illegible] control samples obtained from the same [illegible] muscle fascia as in the patients with [illegible] the second figure, the corresponding [illegible] the other controls.

Platelet aggregation and the [illegible] of collagen in the suspension did not [illegible] with the patients' age ($r=-0.2$ [illegible] respectively) However, in the scoliotic [illegible] a significant correlation ($P<0.01$) was [illegible] between CC and collagen concentration [illegible] suspension ($r=0\ 68$), which means that [illegible]

e easily the collagen was dissolved the it aggregated platelets. There was no ificant difference in collagen content in suspensions or the platelet aggregation erties with sex

he Ivy bleeding time in 68 patients with iosis was 9 6 ± 2 6 (av ± s d) minutes 7 9 ± 1 7 (av ± s d) minutes in the trols. The difference was significant ($P <$) There was no correlation between age bleeding time (r = 0 009)

SCUSSION

lagen is the only constituent of connective ue that has any appreciable tensile ngth (Grant & Prockop 1972a), and defects collagen can cause scoliosis. For instance, iosis can be provoked in animals by β-ino-propionitrile (Ponséti & Baird 1952), ch inhibits the first reaction necessary for r-molecular cross linking of collagen ant & Prockop 1972b) Also in a highly red line of chickens with a readily soluble agen there was an incidence of scoliosis of per cent (Riggins et al 1977)

lso in idiopathic scoliosis collagen ormalities are on record. Francis et al 77) tested the resistance of extracted ymeric skin collagen against depolymeriza- by NaOH This resistance was decreased most patients with adolescent idiopathic liosis as compared with non-scoliotic itrols. The authors felt that a decrease in ymeric collagen resistance reflects a cor- ponding decrease *in vivo* of the number or er types of collagen cross-links. The iormality was greatest in the youngest ients.

t has been reported from Australia that nges in the collagen content of scoliotic es are related to the degree of scoliosis and mobility (Taylor et al 1976) To dis- guish between primary and secondary cts the authors tested the extractability of llagen by pepsin across thirteen zones of mal and scoliotic discs and found a signifi- nt difference between patients with scoliosis and the controls. The values did not vary with the side of the curve from which a given specimen had been obtained and could thus not be related to mechanical loading (Bushell et al 1978)

Other authors have found no alterations in collagen from patients with idiopathic scoliosis, for instance, Nordwall compared tendons and ligaments from 40 patients with idiopathic scoliosis with corresponding specimens from 20 patients with paralytic or congenital scoliosis. He tested the biomechanical properties, the shrinkage on heat denaturation and the collagen content He found no significant difference between the groups (Nordwall 1973)

Bradford et al (1977) studied skin fibroblasts in culture They compared patients with idiopathic scoliosis with seven age-matched controls and found no significant difference in any parameter tested (cell layer, extractability with salt or acetic acid and hydroxyproline to proline ratio) except that the fibroblasts from the scoliotic patients had a lower hydroxyproline to proline ratio in the non-dialyzable media (Bradford et al 1977) The authors concluded that idiopathic scoliosis is not a generalized connective tissue disorder

A perusal of the literature failed to reveal any studies of the platelet aggregating properties of collagen from patients with idiopathic scoliosis. Our finding that the collagen in adolescent idiopathic scoliosis has a decreased platelet aggregating power might be an artefact caused by the preparation of the collagen suspensions, for instance, interaction of the state of aggregation of the collagen itself due to storing However, the suspensions were all used within 2 hours and a correction for changes with time is included in the method (Udén & Nilsson 1978).

We used a crude suspension of collagen in the test of the platelet aggregating power Otherwise the collagen loses most of its aggregating power (Udén & Nilsson 1978) Using a suspension one can also obtain information about the insoluble part of the collagen, though it is then not possible to

assess the percentage of the total collagen that is solubilized, but it was clear that the suspension of fascia from patients with adolescent idiopathic scoliosis contained more collagen than corresponding suspensions from non-scoliotic controls and that the collagen had a decreased platelet aggregating power *in vitro*. A possible explanation for these findings is an altered cross-linking of the collagen as in Ehlers-Danlos syndrome type VI, which is characterized by scoliosis and a bleeding tendency and in which the basic defect is a decreased cross-linking due to lack of lysin-hydroxylase (Pinnell et al. 1972). Another possibility is a decreased content of collagen type III, which has an increased platelet aggregating power (Balleisen et al. 1975), or an otherwise altered structure of the collagen. However, the main point is that there are significant differences in the scoliotic fascia, which speak in favour of collagen being involved in the development of idiopathic scoliosis.

The prolonged bleeding time also supports the concept of an *in vivo* defect of the platelet aggregating power of the collagen. The bleeding time was not so prolonged as to cause any undue bleeding during the operation.

Inter-individual comparison of collagen-induced platelet aggregation is best based on identical anatomical structures (Udén & Nilsson 1978). In five of our controls this was not the case. However, they did not differ a great deal from the other controls, and the differences between the patients with scoliosis and the two subgroups were still significant ($P < 0.05$). About one-third of the patients with scoliosis were adults and since they did not demonstrably differ from the younger patients it would appear that the collagen defect persists even into adulthood.

The methods used in this paper and in the above cited papers give indirect information about mature collagen and may reflect different qualities of this complex molecule. It is therefore not surprising that abnormalities are found in some investigations but not in others. For instance, a defect of the collagen due to some hormonal influence [illegible] increased rate of synthesis is not [illegible] observable in a fibroblast culture.

Our knowledge of the role [illegible] collagen in scoliosis is still very [illegible] the basic defect or defects are not [illegible] but, judging from our present know[illegible] seems likely that collagen is at least [illegible] in the development in some cases of [illegible] cent idiopathic scoliosis.

REFERENCES

Balleisen, L., Gay, S., Marx, R. & K[illegible] (1975) Comparative investigation [illegible] influence of human and bovine collagen [illegible] II and III on the aggregation of [illegible] platelets. *Klin. Wschr.* 53, 903–905

Bradford, D. S., Oegema, T. R. & Brown [illegible] (1977) Studies on skin fibroblasts of [illegible] with idiopathic scoliosis. *Clin. Orth.* [illegible] 111–117

Bushell, G. R., Ghosh, P. & Taylor [illegible] (1978) Collagen defect in idiopathic [illegible] *Lancet* ii 94–95

Caen, J. P. & Legrand, Y. (1972) [illegible] the platelet-collagen reaction. *Ann. N.* [illegible] *Sci.* 201, 194–204

Cobb, J. R. (1948) Outline for the [illegible] scoliosis. Amer. Acad. Orthop. [illegible] Instructional Course Lectures 5, 2[illegible]

Cowell, H. R., Hall, J. N. & MacEwen [illegible] (1972) Genetic aspects of idiopathic [illegible] *Clin. Orthop.* 86, 121–131

Francis, M. J. O., Smith, R. & Sanders [illegible] (1977) Collagen abnormalities in [illegible] adolescent scoliosis. *Calcif. Tiss. Res.* 22, 381–384

Grant, M. E. & Prockop, D. J. ([illegible] biosynthesis of collagen. *New Eng. J.* [illegible] 286, 194–199 (First of three parts)

Grant, M. E. & Prockop, D. J. ([illegible] biosynthesis of collagen. *New Eng. J.* [illegible] 286, 291–300 (Third of three parts)

Harrington, P. R. (1977) The etiology of [illegible] scoliosis. *Clin. Orthop.* 126, 17–2[illegible]

Hugues, J. (1960) Accolement des pla[illegible] collagen. *C. R. Soc. Biol. (Paris)* 154, 1[illegible]

Karaca, M., Cronberg, L. & Nilsson, I. M. [illegible] Abnormal platelet-collagen reaction [illegible] Danlos syndrome. *Scand. J. Haem.* [illegible] 465–469

McKusick, V. A. (1972) *Heritable dis[illegible] connective tissue.* The C. V. Mosby Co. [illegible] Louis.

-son I M, Magnusson, S & Borzhgrevink C -I (1963) The Duke and Ivy methods for etermination of the bleeding time *Thrombos hathes haemorrh (Stuttg)* 10, 223–234

-wall A (1973) Studies in idiopathic scoliosis elevant to etiology, conservative and operative reatment *Acta orthop scand*, Suppl. 150

-ell, S R, Krane, S M, Kenzora, J E & Glimcher, M J (1972) A heritable disorder of onnective tissue *New Engl. J Med* 286, 013–1020

-séti I V & Baird W A (1952) Scoliosis and issecting aneurysm of the aorta in rats fed with Lathyrus odoratus seeds. *Amer J Path* 8, 1059–1062

Riggins, R S, Abbott, U K., Ashmore, C R, Rucker, R B & McCarrey, J R (1977) Scoliosis in chickens. *J Bone Jt Surg* 59-A, 1020–1026

Taylor, T K F Ghosh, P, Bushell G R & Sutherland, J M (1976) Disc metabolism in scoliosis. *Scoliosis Proceedings of 5th symposium at Brompton Hospital*, London, p 231 246, (Ed P A. Zorab) Academic Press, London.

Uden, A & Nilsson, I M (1978) A method for measuring collagen-induced platelet aggregation *Thrombos Res* 12, 1087–1097

Wynne-Davies, R (1968) Familial (idiopathic) scoliosis. *J Bone Jt Surg* 50-B, 24–30

-espondence to Alf Udén M D, Department of Orthopaedic Surgery, Malmo General Hospital, S-01 Malmo Sweden

orthop scand. 51, 779–789 1980

ROWTH RELATED HORMONES IN IOPATHIC SCOLIOSIS

Endocrine Basis for Accelerated Growth

ʀs B Skogland & James A A Miller

hies Minde Orthopaedic Hospital, University of Oslo, Norway

In a total of 95 children with idiopathic scoliosis and 60 controls between the ages of 7 and 17 years, a prospective study of hormones related to growth and maturation was carried out.

The pituitary release mechanism for growth hormone was evaluated [illegible]

The girls with idiopathic scoliosis had a significantly higher response to the growth hormone stimulation test than had the controls between the ages of 7 and 12 years whereas no significant difference could be found for the older girls. In girls with a skeletal age between 9 and 12 years a significantly higher mean serum level of testosterone was found ($P<0.05$). No significant differences could be demonstrated for the remaining hormones.

Growth hormone and testosterone are the most important growth factors in prepubertal and pubertal children Thus, the present findings suggest a hormonal basis for the increased stature in children with idiopathic scoliosis which has previously been reported.

Key words adolescence, growth, growth hormone, idiopathic scoliosis, sex hormones

Accepted 5 iii.80

is an accepted clinical observation that liosis deteriorates during periods of rapid wth and this has been documented by ious authors (Calvo 1957, Duthie 1959, ies 1976, Duval-Beaupère et al 1970) olescent idiopathic scoliosis is most often gnosed in girls 11–13 years of age (Willner 2), i e during one of the most intensive wth periods of life These observations icate a close relationship between gitudinal growth and the development of opathic scoliosis (IS) Willner (1972) found t girls with IS were significantly taller n healthy controls even without making correction for the deformity He could not identify the prepubertal growth spurt among children with IS and he suggested that a period of increased height velocity had occurred prior to the diagnosis, indicating a different growth pattern in these children.

In 1967 Neugebauer (1974) introduced the so-called "combined brace and hormone therapy" and achieved at least a temporary reduction of the scoliosis on terminating growth by oestrogen therapy

Several investigators have carried out biochemical analyses in an attempt to find evidence for more intensive growth in

1 6470.80/050779–11$02.50 0

Table 1 Number of patients included in the study

	Female	Male	Total
Scoliotics (IS)	84	11	95
Controls (C)	46	14	60
	130	25	155

patients with IS than in healthy children However, the results of these investigations, in particular those from growth hormone studies, are not in agreement with one another Misol et al (1971) were not able to find any difference in growth hormone (GH) levels between IS patients and controls, whereas Willner et al (1976) found higher mean fasting levels of GH in scoliotics and also higher levels of somatomedin A in the same group This latter finding was not confirmed by Spencer & Zorab (1977)

Testosterone is an important growth factor during adolescence (Tanner 1973, Wilkins 1965), therefore it is interesting that the investigation of Edelmann & Gupta (1974) indicated remarkably high levels of male sex hormones in the IS patients In addition, the increased urinary excretion of total hydroxyproline in the IS patients (Zorab et al 1971) could be linked with more intensive growth

Several hormones influence growth and maturation in pre-pubertal and pubertal children The objective of this study was to analyse some of the most relevant hormones and try to identify potential differences between children with and without IS The importance of GH and testosterone is evident, but the selection of other "relevant" hormones is a matter for discussion Therefore, a representative selection of such hormones has been included which, according to the literature, may influence physical development

PATIENTS AND METHODS

During the period April 1977–May 1979, a prospective study of 155 consecutive patients was carried out. A total of 95 patients with progressive idiopathic scoliosis and 60 [illegible] examined between the ages of 7 and [illegible] (Table 1) Idiopathic scoliosis was de[illegible] structural scoliosis without a known [illegible] without association with other [illegible] cases the deformity had been diagnosed [illegible] age of 5 years (in the majority of cases [illegible] years of age) and progression of the [illegible] always be documented No distinction [illegible] between juvenile and adolescent [illegible] idiopathic scoliosis. The patients [illegible] treatment for scoliosis curves ranging from [illegible] 72 degrees (Cobb 1948) at the time [illegible] examination, the mean scoliosis angle [illegible] 34 5 with a standard deviation of 12.2 (34.5 ± 12.2) The control group consi[illegible] patients attending the hospital for vario[illegible] paedic disorders other than IS (Table 2)

Height and sitting height were measured [illegible] patients. None of the patients in the [illegible] group or in the control group suffered fr[illegible] disease where hormonal disorders co[illegible] suspected All patients were hospitalized [illegible] blood samples were collected, either [illegible] some kind of conservative treatment or [illegible] observation. None expected surgical opera[illegible] blood samples were collected by the same [illegible] gator who also talked to every child be[illegible] test

The purpose and nature of the [illegible] carefully explained to the patients and [illegible] parents. Sixty patients consented to par[illegible] the control group The blood samples [illegible] patients were taken as part of the [illegible] investigation

The first part of the study was [illegible] evaluate the response to a GH stimulation [illegible] which the effect of propranolol and L-dopa [illegible] release was compared in the two groups [illegible]

Table 2 Control group Overview of [illegible] and number of patients

	[illegible]	[illegible]
	12	[illegible]
Cong dislocation of the hip	[illegible]	[illegible]
Cong scoliosis/kyphosis	[illegible]	[illegible]
Scheuermann's disease		[illegible]
Neuromuscular scoliosis	2	[illegible]
Anisomelia	[illegible]	
Other spine deformities	[illegible]	
Cong club foot	2	
Spondylolisthesis	2	
Anteversion of fem neck	[illegible]	[illegible]
Perthes' disease	[illegible]	[illegible]
Others	[illegible]	[illegible]

-le 3 Hormones investigated Number of girls in each group The differences in sample are random and purely due to technical rcumstances (for FSH and LH, see text)

ormone	No of patients IS	C
rth hormone		
H)	84(11)	46(14)
osterone	61(7)	44(13)
iormone binding		
bulin (SHBG)	78(10)	40(14)
radiol	59(7)	44(12)
oxin	50(8)	23(8)
ctin	66(10)	28(13)
isol	60(6)	24(11)
	26(4)	
	25(4)	

1974) All 155 patients are included in this y After an overnight fast of at least 8 hours a ula was inserted into an antecubital vein and open during the test with heparin solution parin 100 I U./ml NYCO) The first blood ple was collected shortly after the insertion of cannula and then a single dose of propanolol eral[*] I C I) 1 mg/kg body weight was inistered orally Sixty minutes later a second d sample was collected and 10 mg/kg body ght of L-dopa (Eldopar,[*] WEIFA) was given ing the following 120 minutes blood samples obtained every 30 minutes. The patients recumbent throughout the procedure With exception of nausea in some of the patients no plications occurred during or after the test er in the IS or the control group

he serum GH was determined by radio-munoassay (Norman & Turter 1968 Sand & jesen 1973) The response to the GH stimula- test was evaluated in the different age groups measuring the mean peak response by ulating the number of individuals with a ponse over a given "threshold' and by ulating the mean area under the time-ponse curve which was called the integrated centration of GH (ICGH)

n the first series of 29 IS patients and 2 trols the test period lasted only 150 minutes l for technical reasons the GH value at time o is missing for 4 other IS patients. Thus, in ler to avoid the exclusion of these 35 patients, ICGH was calculated for the time 60–150 nutes in all patients as well as for the whole t period (0–180 min) where poss ble Good cor-ation was found between the two areas in all the patients with full-time testing (regression coefficient—0 8)

Blood samples to determine the serum levels of the other hormones were obtained together with the first sample for GH analysis (time 0 of the stimulation test) The number of hormone tests in each group of IS patients and controls (C) is given in Table 3 Testosterone was determined by radioimmunoassay after paper chromatographic isolation according to Naess et al (1976) Sex hormone binding globulin (SHBG) determinations were performed by equilibrium dialysis as described by Aakvaag et al. (1978), thyroxine and cortisol by radioimmunoassay according to the description by the same authors. The other hormone assays were carried out according to previous publications for FSH and LH (Sand & Torjesen 1973, Torjesen et al. 1974) prolactin (Rutlin et al. 1977) and oestradiol (Fosså et al 1977) The values of FSH and LH in the first 30 IS patients were all normal so no further samples for this purpose were collected.

The skeletal age was determined in all patients by the Greulich & Pyle method (1970) and all results were evaluated according to skeletal as well as chronological age

For the evaluation of the GH data the girls were divided into age groups using the age of 12 years as the 'start of puberty' For the evaluation of thyroxin, prolactin and cortisol 13 years of age was chosen as the "turning point" in order to avoid comparison of very different sample sizes.

The data analysis was run on a Digital Equipment Corporation "DEC-10' computer, using standard statistical routines. Significance testing was carried out using the Mann-Whitney U-test. However, the Welch test (Armitage 1974) was used in cases with more than 25 per cent difference in standard deviations and where sample sizes were larger than 20 and 40, respectively The two-tailed test was used in all cases.

RESULTS

Growth hormone The female patients with IS in all age groups had a more marked response to the stimulation test than had the controls, but the number of positive responses (rise > 5 μg/l) was not significantly different in the two groups (84 and 82 per cent in the IS group and the control group, respectively). Among the IS patients the majority of those with no response (13/15) had high fasting values (> 7 μg/l), whereas in the control

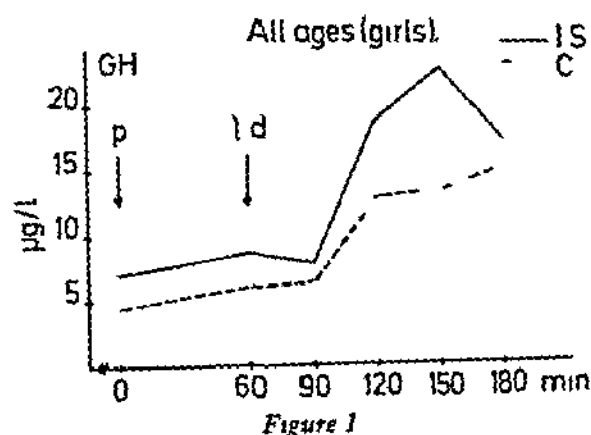


Figure 1

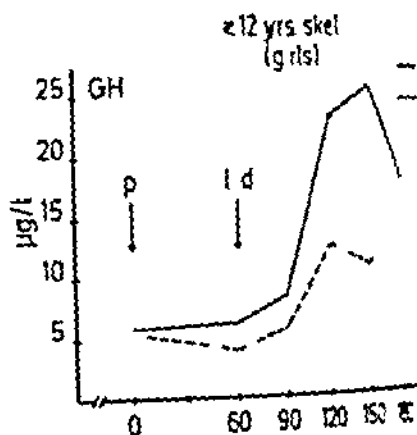


Figure 2

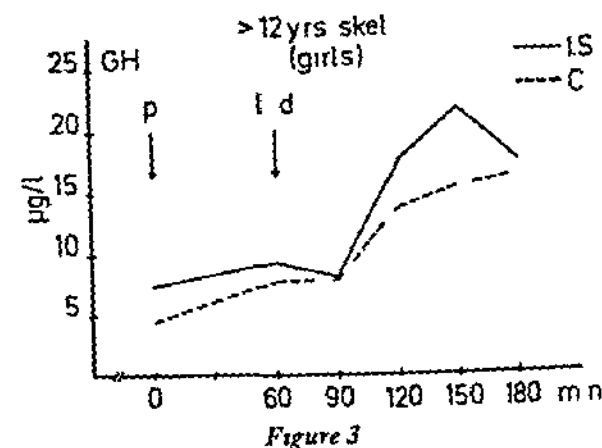


Figure 3

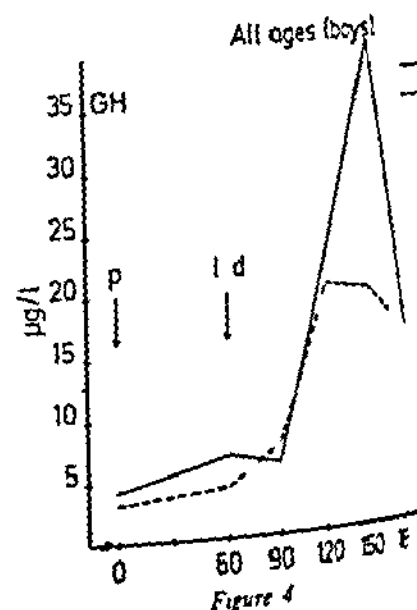


Figure 4

Figures 1–4 Mean GH response curves for scoliotics and controls after stimulation with propanolol (p) and L dopa (l–d) (for standard deviation values see tables)

group only 3 out of 8 "non-responders" had fasting values >7 μg/l There was no significant difference in mean fasting values between the IS and the control group

The individual peak responses were much higher in the IS group and there was a significantly greater number of IS patients who reached a peak value of more than 30 μg/l ($P<0\,001$, binomial test) The mean peak values were $23\,2 \pm 17\,78$ μg/l and $13\,18 \pm 13\,03$ μg/l for the scoliotics and the controls, respectively, this difference is statistically significant ($P<0\,01$)

For the total sample of girls with IS the mean peak response time was 150 minutes after propanolol administration and 90 minutes after L-dopa (Figure 1) [illegible] control group a marked peak in GH [illegible] centration occurred 60 minutes after [illegible] administration of L-dopa but the rise [illegible] less pronounced. In addition, there [illegible] second rise after the first peak, probably [illegible] to the emotional stress caused by the [illegible] situation No fall could be seen in the [illegible] group within the test period of 3 hours [illegible]

The ICGH values for the IS group [illegible] significantly higher than for the controls during the time period 60–1[illegible] [illegible] ($P<0\,01$) as well as during the total [illegible] time ($P=0\,01$) When the different [illegible] groups are considered, a significantly [illegible] ICGH was found in the scoliotics for the [illegible]

cal ages 7–12 years ($P = 0 05$) Based on etal age, there was also a significantly ·er ICGH in the scoliosis patients in the igest age group, $P < 0 005$ and $P < 0 02$ the shortest and longest time period ectively (Figure 2) For girls over 12 s, no significant difference could be onstrated in ICGH levels compared er on the basis of chronological or skeletal (Figure 3 and Table 4)

he mean peak response was significantly er in IS girls 7–12 years old when pared on the basis of skeletal age 0 02), but this was not so when they compared on the basis of chronological age ($0 05 < P < 0 1$) In girls older than 12 years (chr and skel.) no significant difference occurred in this respect (Tables 5, 6) In the boys, no significant difference between the IS and control groups could be demonstrated in ICGH values or in the values of mean peak response (Figure 4) There was however a significantly higher number of boys in the IS group, in whom the response exceeded the arbitrarily chosen threshold of 30 µg/l ($P < 0 001$)

Testosterone and sex hormone binding globulin (SHBG) In girls, the serum level of testosterone was found to increase steadily from the age of 9 years (chr) to the age of 15

Table 4 Integrated concentration of GH (mean ± s d) in the different age groups for scoliotics (IS) and controls (C)

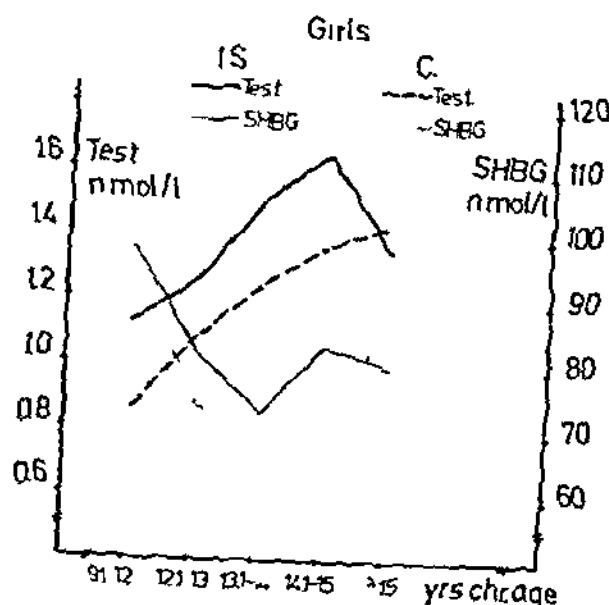
Age group	ICGH (60–150 min) (µg min/l) IS	n	C	n	Signif test
s < 12 years. chr	1240 0 ± 612.6	12	780 6 ± 630 1	16	$P = 0 05$
s > 12 yrs. chr	1287 0 ± 823 9	72	967 1 ± 779 4	30	N S
s < 12 yrs skel	1437 0 ± 722.3	22	766 0 ± 603 6	17	$P < 0 005$
s > 12 yrs. skel	1225 0 + 816 5	62	982 0 ± 792.9	29	N S
ls All ages	1280 0 ± 794 2	84	902.2 ± 729 3	46	$P < 0 01$
's All ages	1596 0 + 929 4	11	1186 0 ± 798 1	14	N S

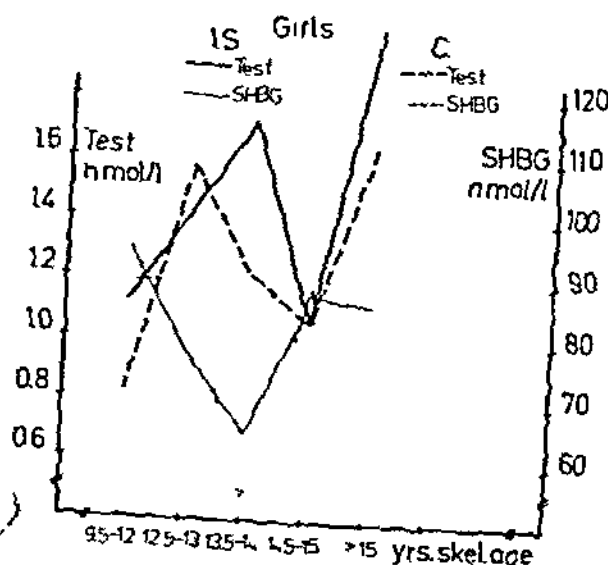
ble 5 Mean serum levels of GH at different stages of the stimulation test in girls of both age groups

ne nutes)	Mean (± s.d.) serum level GH (µg/l) 7–12 0 yrs skel. IS	C	12.5–17 yrs. skel IS	C
(propanolol)	5 8 ± 6.3	5 5 ± 6.5	7 3 ± 9 1	4 3 ± 5 5
(L-dopa)	6 2 ± 7 4	3 9 ± 4 3	9 4 ± 8 5	7 5 ± 7 4
	8 5 ± 6 1	5 7 ± 6 2	7 9 ± 8 5	7 7 ± 8 7
	23 3 ± 14 6	12.4 ± 13 1	17 1 ± 15 4	13 6 ± 13 1
	25 9 ± 20 1	10 7 ± 8 1	21 8 ± 17 0	15.3 ± 13 9
	17 8 ± 13 8	15.2 ± 10 3	17 4 ± 13 3	16 2 ± 14 0

ble 6 Mean serum levels of GH at different stages of the stimulation test in the total sample of girls and boys

me mutes)	Girls all ages IS	C	Boys all ages IS	C
0 (propanolol)	6 9 ± 8 4	4 7 ± 5 9	4 1 ± 3 8	3 1 ± 2.5
0 (L-dopa)	8 5 ± 8 3	6 2 ± 6 6	6 7 ± 9 4	4 2 ± 2.8
0	7 9 + 7 7	6 9 ± 7 8	5 9 ± 5 9	7 4 ± 8 5
0	18 7 + 15 4	13 1 ± 13 0	23 9 ± 22.7	20 1 ± 19 0
0	23 2 + 17 7	13 6 ± 12.2	39 8 ± 36.5	19 6 ± 14 7
0	1[illegible] + 13 3	15 8 ± 12.6	15 5 ± 10 5	15 5 ± 10 5





Figures 5–6 Mean levels of testosterone (test) and sex hormone binding globulin (SHBG) in scoliotics and controls (for s d values see Table 7)

years and then a decrease [illegible] oldest age group This was the [illegible] scoliotics and controls but the [illegible] were markedly higher in the IS [illegible] ages below 15 years, although the [illegible] were not statistically significant (F[illegible] The corresponding SHBG levels [illegible] from the youngest group towards [illegible] 15, and then a significant rise [illegible] oldest age group The rise in SH[illegible] centration for the age group 14.1 1[illegible] (chr) among the scoliotics is not [illegible]

If the data are evaluated accord[illegible] skeletal age, an increase in testoster[illegible] centration could be observed from [illegible] years of age in the group of scolio[illegible] the age of 14, thereafter a decrease [illegible] concentrations occurred in the [illegible] 14.5–15.0 years before a significant rise [illegible] end of puberty ($P < 0.05$) (Figure 6 and [illegible] 7) The mean serum level of testoste[illegible] the youngest age group (9.5–12.0 [illegible] (skel)) was significantly higher for the [illegible] patients ($P < 0.05$) whereas the di[illegible] SHBG values was small. With the exc[illegible] of the age group 12.5–13.0 years (sk[illegible] SHBG concentrations decreased with [illegible] ing testosterone values and [illegible] low concentration of SHBG in the older [illegible] group (skel) is surprising but the [illegible] curve at this stage is not signific[illegible]

Oestradiol No significant differences [illegible] be demonstrated in oestradiol concentr[illegible] except for the age group over 15 years [illegible] ($P < 0.05$), for the remaining age [illegible] differences were negligible (Fig[illegible] Table 8).

Table 7 Blood levels of testosterone and sex hormone binding globulin (mean ± s d.) in [illegible] ages in the scoliotic and control groups

Skel. age (years)	Testosterone (nmol/l) IS	n	C	n	SHBG (nmol/l) IS	n	C
9.5–12.0	1.12 ± 0.43	15	0.82 ± 0.30	11	94.9 ± 33.3	17	[illegible]
12.5–13.0	1.43 ± 0.62	11	1.58 ± 0.74	6	77.4 ± 26.9	17	[illegible]
13.5–14.0	1.73 ± 0.91	15	1.23 ± 0.44	8	64.6 ± 23.3	20	[illegible]
14.5–15.0	1.07 ± 0.22	11	1.07 ± 0.24	7	87.4 ± 30.1	15	[illegible]
> 15.0	2.03 ± 0.86	7	1.67 ± 0.63	7	86.2 ± 29.1	7	[illegible]

'e 8 *Blood levels of oestradiol (mean ± s d) in of different ages in the scoliotic and control groups*

age ·s)	Oestradiol (nmol/l) IS	n	C	n
-12 0	0 11 ± 0 07	15	0 12 ± 0 07	11
-13 0	0 33 ± 0 33	10	0 35 ± 0 32	5
-14 0	0 23 ± 0 10	15	0 25 ± 0 13	8
-15 0	0 37 ± 0 21	10	0 31 ± 0 24	7
>15 0	0 39 ± 0 20	7	0 17 ± 0 13	7

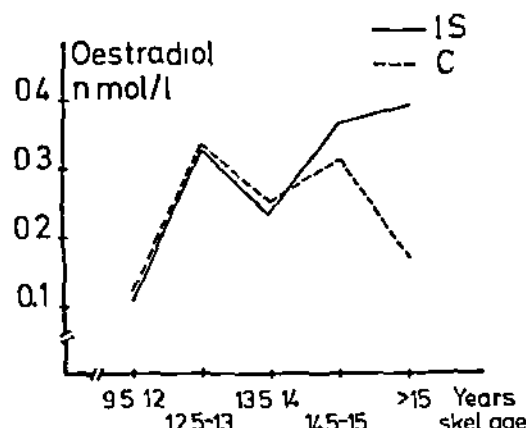


Figure 7 Mean levels of oestradiol in girls of different ages in scoliotics and controls (for s d values see Table 8)

er hormones investigated No significant :rences could be demonstrated between iotics and controls as far as the other nones are concerned (Table 9) There , however, a marked lower blood centration of prolactin in IS girls over 13 :s ($0 05 < P < 0 1$), whereas no difference ld be observed for the younger girls

'here was no correlation between the osterone values and the severity of the ›rmity or between the GH values and iosis angle, nor could any correlation be ionstrated between the GH and testo- one values on the one hand and height or ing height on the other

SCUSSION

a longitudinal study of Swedish girls, llner (1974) found that the girls with IS had increased stature long before the onset of scoliosis After the deformity had been diagnosed the difference in height between *scoliotics and controls remained unchanged,* but the rate of growth seemed to be equal in the two groups

The present study seems to present sound evidence for differences in the hormonal status between scoliotics and controls which suggest that they have different growth patterns.

Frasier (1974) maintained that "there is general agreement that the measurement of GH in a single fasting blood sample is not an appropriate method of screening for growth

3le 9 *Concentrations (mean ± s d) of some growth related hormones in girls of different ages in the liotic and control groups The units are in µg/l except for thyroxin and cortisol which are in nmol/l*

rmone	Age group (years chr)	Blood concentration IS	C	Signif test
yroxin	< 13	103 0 ± 16 8	111 3 ± 20 8	N S
yroxin	> 13	103 5 ± 23 8	105 2 ± 18 7	N S
yroxin	All ages	103 3 ± 21 6	107 6 ± 19 4	N S
›lactin	< 13	14 22 ± 7 51	14 48 ± 7 97	N S
›lactin	> 13	14 79 ± 6 71	19 72 ± 10 92	$0 1 > P > 0 05$
›lactin	All ages	14 57 ± 6 97	17 48 ± 9 95	N S
rtisol	< 13	523 1 ± 181 5	557 5 ± 213 5	N S
rtisol	> 13	455 4 ± 152 9	414 2 ± 128 8	N S
rtisol	All ages	480 2 ± 165 7	479 9 ± 183 8	N S
H	All ages	0 907 ± 0 41		
I	All ages	1 192 + 0 52		

hormone deficiency" It is of course *not* supposed to be more appropriate when *looking for differences* in "normal" pituitary function

The L-dopa stimulation test is a well established procedure for the evaluation of pituitary function (Eddy et al 1971, Chakmakjian et al 1973, Eddy et al 1974) However, as the response to L-dopa alone is inconstant and as propanolol, a beta-receptor blocking agent, has been shown to potentiate this response (Camanni et al 1974) it was decided to use the combined stimulation (Trygstad 1977) Fass et al (1979) found a markedly lower number of false positive results in the combined test compared to the L-dopa test and the sleep screen test It has been shown that there is a significant correlation between standard pharmacological stimulation tests and the physiological 24-hour integrated serum concentration of growth hormone (Plotnik et al 1979)

The results of the stimulation test in this study indicate a significant, higher sensitivity of the GH release mechanism in prepubertal (7–12 years) girls with IS The lack of a significant difference in age groups over 12 years corresponds well with the anthropometric data of Willner (1974) and Burwell & Dangerfield (1977) The present study also confirms the finding of Plotnik et al (1974), that the ICGH is the same in prepubertal and pubertal normal girls Girls with IS, however, have higher ICGH before puberty

Testosterone is an important growth factor during adolescence in girls as well as in boys (Wilkins 1965), and is probably, in addition to the adrenal androgens, responsible for the prepubertal growth *spurt even in girls* (Sizonenko 1978)

Hence, the present finding, demonstrating a significantly higher concentration of testosterone in serum of the IS girls aged 9–12 years (skel) may be of pathogenetic importance

Since only free testosterone is supposed to be biologically active (Vermeulen et al 1969), the *inverse* relationship between SHBG and testosterone indicates a potentiation of its *growth promoting action* The [illegible] the pubertal peak in testosterone [illegible] *tion in the IS* group suggests a [illegible] growth spurt in these children (Figure [illegible]

The difference in oestradiol values [illegible] age of 15 *years is* not *easy to* [illegible] however, it is *reasonable to* think [illegible] drop in oestradiol in the controls is a [illegible] fluctuation

An attempt has been made in this [illegible] reduce the sources of errors by [illegible] two populations which are to be compar[illegible] homogeneous as possible The test [illegible] have been exactly the same for both [illegible] Emotional stress as well as physical [illegible] known to influence GH secretion [illegible] all children involved were [illegible] hospital but none of them were [illegible] surgical intervention In spite of the [illegible] the patients were calmed down before [illegible] started, some of them *became* [illegible] and this may be the reason why a [illegible] rise in GH concentration occurred [illegible] control group *A secondary* [illegible] GH concentration *did not* occur [illegible] group, probably because the [illegible] rise is followed by a refractory phase [illegible] is good documentation for the [illegible] maximum response normally occurs [illegible] *60–90* minutes after L-dopa [illegible] (Eddy et al 1974, Camanni et al [illegible]

The great variance of the individual [illegible] in a study of this kind makes [illegible] analysis difficult, *nonetheless*, [illegible] difference could be *clearly* [illegible] there seems to be little doubt [illegible] higher testosterone levels in [illegible] scoliosis girls or the *increased* [illegible] *growth hormone in the same* [illegible] *difference in* growth rate is [illegible] *during these* years and it is in [illegible] that most of the IS cases are diagnosed

In boys, *no significant differences* [illegible] found in testosterone [illegible] However, even if the *group* [illegible] small to permit division into [illegible] trend similar to that found in the [illegible] be shown in the GH release

Nordwall & Willner (1975) [illegible]

IS had an earlier skeletal development
:ontrols in the age group 11–12 years
In the present study it was therefore
sing to find that hormonal differences
ie even more marked when comparing
opulations on the basis of skeletal age
: choice of 12 years of age as the start
berty might be a matter for discussion
iormal development of secondary sexual
cteristics starts earlier and the growth
certainly starts earlier However, the
al age is more difficult to determine
ely before the age of 12 years and it
also convenient to choose this age in
to avoid statistical problems with
le sizes
e lack of correlation between hormones
he one hand and anthropometric sizes
everity of scoliosis on the other was not
pected A more detailed report on the
opometric measurements done in con-
on with this study will be published
The present findings are consistent with
: of Willner (1974) and Burwell &
gerfield (1977) who found differences in
ling height between scoliotics and
ols. Though Burwell et al could not
onstrate significant differences, they did
correct for loss in height caused by the
rmity Willner (1972) also found that the
ig-height was greater in girls with IS and
e "young girls" (11–13 years) even without
ecting for the deformity
he question as to whether the primary
e of scoliosis is due to a different growth
ern has not been addressed in this study
etheless, hormones may influence the
e in a way which could be relevant to
iosis. Dymling & Willner (1978) reported
se in which a marked progression of the
iosis occurred during treatment with GH
testosterone
[illegible]
wn to decrease the mechanical stability of
epiphyseal plate (Oka et al 1978) On the
er hand when it is given in larger doses
the growth plate becomes narrowed and after
some time will fuse Thus, if hormones can
affect both spinal geometry and material pro-
perties, the possible role of growth-regulating
hormones as primary factors in the develop-
ment of idiopathic scoliosis should not be
totally excluded

CONCLUSION

The blood levels of growth promoting hormones in children with idiopathic scoliosis were significantly higher than in a control group The higher sensitivity of the pituitary release mechanism of growth hormone and the elevated concentrations of testosterone could be the reason for the accelerated prepubertal growth reported in these children

ACKNOWLEDGEMENTS

We wish to express our gratitude to Olav Trygstad M D for his valuable advice and criticism

We are also indebted to the Hormone Laboratory, Aker Hospital, Oslo for doing all the hormone analyses and for helpful discussions.

J A.A M was supported by a Fellowship from the Norwegian Research Council for Science and the Humanities.

REFERENCES

Aakvaag, A., Bentdal, Ø, Quigstad, K, Walstad, P., Rønningen, H & Fonnum, F (1978) Testosterone and TeBG in young men during prolonged stress. *Int. J Andrology* 1, 22–31

Armitage, P (1974) *Statistical methods in medical research.* p 123 Blackwell Scientific Publ., Oxford

Burwell, R. G & Dangerfield, P H (1977) *Scoliosis Proceedings of a Fifth Symposium* (Ed. Zorab, P A.) pp 123–163, Academic Press, London

Calvo I J (1957) Observations on the growth of the female adolescent spine and its relation to scoliosis. *Clin. Orthop* 10, 40–46.

Camanni, F., Massara, F & Molinatti, F M. (1974) Propanolol enhancement of L-dopa induced growth hormone stimulation. *Biomedicine* 21, 241–243

Chakamakjian, Z H, Marks, J F & Fink, C W

(1973) Effect of Levodopa (L-dopa) on serum growth hormone in children with short stature *Pediat Res* **7**, 71–74

Cobb, J R. (1948) Outline for the study of scoliosis American Academy of Orthopaedic Surgeons. Instructional Course Lectures. St Louis, pp 261–275

Dymling, J F & Willner, S (1978) Progression of a structural scoliosis during treatment with growth hormone *Acta orthop scand* **49**, 264–268

Duthie, R. B (1959) The significance of growth in orthopaedic surgery *Clin Orthop* **14**, 7–19

Duval-Beaupère, G, Dubousset, J, Queneau, P & Grossiord, A (1970) Pour une théorie unique de l'evolution des scolioses. *Presse méd* **78**, 1141–1146

Eddy, R. L, Jones, A L, Chakmakjian, Z H & Silverthorne, M C (1971) Effect of Levodopa (L-dopa) on human hypophyseal trophic hormone release *J clin Endocr* **33**, 709–712

Eddy, R L, Gilliland, P F, Ibarra, J D, McMurry, J F & Thompson, J Q (1974) Human growth hormone release Comparison of provocative test procedures. *Amer J Med* **56**, 179–185

Edelmann, P & Gupta, D (1974) Hormonuntersuchungen bei idiopathischen Scoliosen *Z Orthop* **112**, 836–838

Fass, B, Lippe, B M. & Kaplan, S A (1979) Relative usefulness of three growth hormone stimulation screening tests *Amer J Dis Child* **133**, 931–933

Fidler, M W & Brook, C G D (1974) Slipped upper femoral epiphysis following treatment with human growth hormone *J Bone Jt Surg* **56-A**, 1719–1722.

Fosså, S D, Fosså, J & Aakvaag A (1977) Hormone changes in patients with prostatic carcinoma during treatment with estramustin phosphate *J Urol (Baltimore)* **118**, 1013–1018

Frasier, S D (1974) A review of growth hormone stimulation tests in children *Paediatrics* **53**, 929–937

Greulich, W W & Pyle, S I (1970) *Radiographic atlas of skeletal development of the hand and wrist* 2nd ed, Stanford University Press, Stanford, Calif

Harris, W R (1950) The endocrine basis for slipping of the upper femoral epiphysis. *J Bone Jt Surg* **32** B, 5–11

[illegible]

J T (1971) Growth hormone blood levels in patients with idiopathic scoliosis. *Clin Orthop* **81**, 122–125

Naess, O, Haug, E., Attramadal, A., [illegible] Hansson, V & French, F (19[illegible]) [illegible] receptors in the anterior pituitary [illegible] nervous system of the androgen [illegible] (Tfm) rat Correlation between [illegible] binding and effects of [illegible] gonadotropin secretion. *Endocrinology* [illegible] 1295–1303

Neugebauer, H (1974) Die "[illegible] Therapie" bei idiopatischen Skoliosen. [illegible] *klin Wschr* **86**, Suppl. 22.

Nordwall, A. & Willner, S (19[illegible]) [illegible] skeletal age and height in girls with [illegible] scoliosis. *Clin Orthop* 110, 6-1[illegible]

Norman, N & Turter, Aa. R. (19[illegible]) [illegible] immunoassay studies with human [illegible] hormone and a pituitary [illegible] factor *Acta endocr (Kbh.)* **58**, [illegible]

Oka M, Yamamuro T., Hama, H. & Tak[illegible] (1978) Die mechanische Festigkeit [illegible] Wachstumsknorpels unter dem Einfluss [illegible] Geschlechtshormonen *Z Orthop* **116**, [illegible]

Plotnik, L P, Thompson, R. G., Beitins [illegible] Blizzard, R M (1974) Integrated [illegible] centrations of growth hormone correlated [illegible] stage of puberty and oestrogen levels [illegible] *J clin Endocr* **38**, 436–439

Plotnik, L P., Lee, P A., Migeon, C [illegible] Kowarski, A A. (1979) Comparison [illegible] physiological and pharmacological [illegible] growth hormone function in children [illegible] short stature *J clin. Endocr* **48**, [illegible]

Ray R D, Evans, H M & Becks, H (19[illegible]) [illegible] of the pituitary growth hormone [illegible] epiphyseal disk of the tibia of the rat [illegible] *Path* **17**, 509–528

Rutlin E, Haug, E. & Torjesen, P [illegible] Serum thyrotrophin prolactin and [illegible] hormone, response to TRH during [illegible] treatment. *Acta endocr (Kbh.)* **84**, [illegible]

Sand, T & Torjesen, P A (19[illegible]) [illegible] charcoal used in the radioimmunoassay [illegible] human pituitary luteinizing hormone [illegible] *endocr (Kbh)* **73**, 444–454

Sizonenko, P C. (1978) Endocrinological [illegible] of growth. *Postgrad. med. J* **54**, [illegible]

Spencer, G S G & Zorab, P A. (19[illegible]) [illegible] somatomedin activity in normal and [illegible] children. *Pediat Res* **11**, 883–8[illegible]

Tanner, J M (1973) *Growth at adolescence* [illegible] ed Blackwell Scientific Publ., Oxford [illegible]

Torjesen, P A., Sand, T., Norman, N., [illegible] O & Foss, J (1974) Isolation of LH, F[illegible] TSH from human pituitaries after the [illegible] of HGH *Acta endocr (Kbh.)* **77**, [illegible]

Trygstad, O (1977) Personal communication [illegible]

Vermeulen, A., Verdonck L., Van de [illegible] M. & Orie N (1969) Capacity of the [illegible]

adolescence 3rd ed Charles C Thomas, Springfield, Ill.
llner, S, Nilsson, K O, Kastrup, K & Bergstrand, C G (1976) Growth hormone and somatomedin A in girls with adolescent idiopathic scoliosis. *Acta pediat scand* **65**, 547–552
Willner, S (1972) *Factors contributing to structural scoliosis* Studentlitteratur, Lund
Willner, S (1974) A study of growth in girls with adolescent idiopathic structural scoliosis. *Clin. Orthop* **101**, 129–135
Zorab P A, Clark, S, Cotrel, Y & Harrison, A (1971) Bone collagen turnover in idiopathic scoliosis estimated from total hydroxyproline excretion. *Arch Dis Childh* **46**, 828–832.

rrespondence to Lars B Skogland Sophies Minde Ortopedisk Hospital, Trondheimsveien 132, Oslo Norway

ıorthop scand. 51, 791–798 1980

JTO-TRACTION FOR TREATMENT OF JMBAGO-SCIATICA

Multicentre Controlled Investigation

F LARSSON, ULLA CHÖLER, ANDERS LIDSTRÖM,
RTRUD LIND, ALF NACHEMSON,
NILSSON & JAN ROSLUND

partments of Orthopaedic Surgery at Malmö Skovde, Danderyd and Nacka Hospitals and at Sahlgren spital in Goteborg and Karolinska Hospital in Stockholm, Sweden

In this controlled prospective study of the Auto-traction method for the treatment of lumbago-sciatica, 82 patients were randomly allocated to either treatment with Auto-traction for up to three 1-hour sessions in 1 week, or they were given a corset and advised to rest. The orthopaedic surgeons participating in the study worked at six different hospitals and all had limited experience of the Auto-traction method obtained during a 1-week course All patients were clinically evaluated by an independent observer who also performed the follow-up examinations 1 and 3 weeks after the treatment sessions. In addition a 3-month follow-up was performed by letter

The Auto-traction method gave prompt relief of pain and a normalizing of the SLR test more often than treatment with only a corset and rest. The difference between the two treatment groups was statistically significant. The immediate difference noted between the treatment groups had decreased slightly at 3 weeks but was still statistically significant at this time

Key words back pain sciatica, therapy, traction

Accepted 3 iii 80

nsurgical treatment of lumbago and sciatica fers a wide range of alternatives, including ventional physiotherapy, manipulation and ier manual methods, and traction The undance of methods and the uncertainty as which of them are the most satisfactory is derstandable in view of the fact that the derlying cause of the pain is in most cases known (Nachemson 1971) Although the ferent methods of treatment have been ex-nsively used for many years, few systematic idies of their efficacy have been carried out most cases, back disorders are episodic d regress spontaneously (Hult 1955, Horal 1969) Controlled studies are therefore generally necessary to determine whether the treatment is more effective than no treatment at all, or whether a particular method of treatment is better than other methods.

Dynamic physiotherapy has been found in several studies to give poor results compared with other methods of treatment (White 1966, Kendall & Jenkins 1968, Lidström & Zachrisson 1970) There are thus indications that this type of treatment is ineffective and may even aggravate the symptoms.

Various manual treatments have been studied in a number of controlled trials in

01–6470 80 050791–08802.50 0

patients with lumbar symptoms (Glover et al. 1974, Doran & Newell 1975, Rasmussen 1977, Brodin 1977, Bergquist-Ullman & Larsson 1977). The results of these studies are contradictory. They do suggest, however, that treatment of lumbago patients with manipulation or other manual methods may accelerate recovery in some patients. In the long-term, however, the treatment does not seem to offer any advantages. One of the studies shows that equally good results can be obtained by giving patients information and ergonomic advice, "the Back School" (Bergquist-Ullman & Larsson 1977). In two controlled studies in patients with lumbago-sciatica and disc herniation, conventional traction (Tru Trac) was not found to be superior to placebo treatment (Lidström & Zachrisson 1970, Weber 1973).

These studies have either shown poor results of treatment or positive effects that were of limited or marginal significance in most cases. The results reported by Lind (1974) with her own method, Auto-traction, developed from previous methods of traction, stand out in sharp contrast to these disappointing results with other methods. Lind (1974) presented her results with the method in three different studies. In a controlled trial in patients with lumbago-sciatica all 15 traction patients were rid of their pain within 1 week, whereas only a few of the patients in two equally large control groups were free from pain. In an uncontrolled study 20 patients with disc herniation confirmed by myelography were treated with Auto-traction before planned operation. Fifteen of the patients recovered so permanently that they did not need surgery. In a retrospective study of the results in a large number of patients with lumbago or lumbago-sciatica, more than 90 per cent of the patients are reported to have become free from pain after the treatment (Lind 1974). In addition to pain relief, regression of the neurological deficit symptoms was achieved in many of the patients. Rapid recovery from back symptoms in such a high proportion of patients has seldom been reported previously in the medical literature. An excep[illegible] very good results initially reported [illegible] denervation, but in later studies th[illegible] were less impressive (Rees 1971, Sh[illegible] Lora & Long 1976, King 1977). Th[illegible] reported by Lind (1974) are superior [illegible] that can be expected after opera[illegible] verified disc herniation (Hirsch & N[illegible] 1963, Hakelius 1970, Spangfort 197[illegible]

The aim of the present study [illegible] determine whether the results repor[illegible] Auto-traction could be reproduced[illegible] primary objective was to find o[illegible] results could be obtained when the [illegible] was used by relatively untrained [illegible] and not by the inventor. A [illegible] was considered most suitable fo[illegible] purpose.

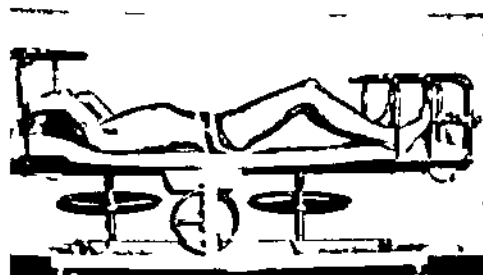
PATIENTS AND METHOD

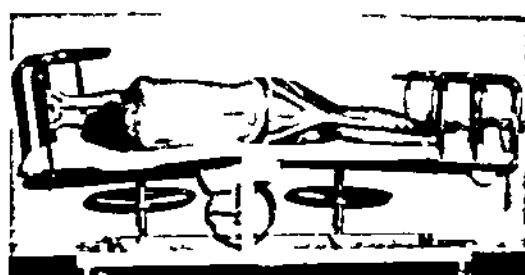
Auto-traction

The treatment is performed on a special [illegible] bench. The bench is made up of two [illegible] can be individually angulated and [illegible] 1). The patient is positioned on the be[illegible] prone, supine or lateral position (Fig[illegible] patient's pelvis is fixed to the foot end [illegible] bench with a belt and a chain. The pa[illegible] the bars at the head end and supports [illegible] his feet on the bars at the foot end. Tr[illegible] performed by the patient himself by pull[illegible] arms, and he is constantly in control of th[illegible] tion. The direction of the traction can be [illegible] by changing the angulation of the [illegible] bench, the patient's position, and the [illegible] traction-belt. Treatment is most ofte[illegible] traction in a horizontal plane and the [illegible] position and direction of traction are [illegible] as the treatment proceeds. The right p[illegible] found when the symptoms disappear and th[illegible] normalizes during traction. It is often p[illegible] predict this position by analysing the p[illegible] clinical condition and symptoms. A[illegible] treatment session, that can last for [illegible] more the patient is supplied with a [illegible] high fabric corset and a special p[illegible] waist to achieve lumbar lordosis [illegible] position. Repeated treatment sessions [illegible] required. The patient is confined to bed [illegible] few days after the treatment and the [illegible] gradually in the corset. The [illegible]



ure 1 The multiplane Auto-traction table





ure 2 The Auto-traction table with a patient in the supine and lateral positions

onomic advice and equalization of leg length erences. A more detailed description of the exact hod of treatment and aftercare is to be found in d s work (1974).

study

The study was designed as a randomized con-led trial in a defined group of patients. The ients were treated at six departments of opaedic surgery (the Department of hopaedic Surgery at Malmo Skovde, nderyd and Nacka Hospitals and at Sahlgren spital in Goteborg and at Karolinska Hospital Stockholm) by five orthopaedic surgeons who had attended a 1-week course of instruction by G Lind 1 year earlier and had subsequently gained some personal experience of the method A few patients were also treated by G Lind herself The patients were examined by an independent investigator who visited the different units regularly

[illegible]

neurological deficit.

b Duration of the current episode ≥2 weeks and ≤ 3 1/2 months

c. Age 20–55 years.

d. Positive Straight Leg Raising test (SLR).

[illegible]

groups

Patients allocated to the *Auto-traction group* were given up to three treatments all within 1 week. The treatment sessions were not to last for more than 1 hour. *Patients treated as outpatients* were usually taken home by ambulance. The *control group* were fitted with a corset of the same type as the traction group and given the same instructions with respect to rest. Standard analgesics (paracetamol) were prescribed when required for both groups. The patients were treated as outpatients except at one hospital where all patients (10 traction patients and 10 control patients) were hospitalized for 5 days.

Data were registered on a standardized protocol immediately before and 1 and 3 weeks after the start of treatment.

At the *first investigation,* before the start of treatment, previous back symptoms and the duration of the present episode of pain were recorded. The nature, extent and intensity of the pain were determined. The intensity of the pain in the leg and back was graded on a 0–100 scale using a graphic self-rating method ([illegible] 1974). The patient's clinical [illegible], SLR, lumbar mobility and the [illegible] condition in the lower extre[illegible] [illegible]. The range of lumbar mobility was [illegible] using a method by which certa[illegible] [illegible] the lumbar spine are measured ([illegible] 1971).

At the *investigations after 1 and 3* [illegible] patient was asked whether he still had [illegible] leg or back. If so the pain was [illegible] same way as at the first investig[illegible] likewise the clinical signs were [illegible] additional treatment was given betwe[illegible] vestigations at 1 and 3 weeks. In order [illegible] elucidate the long term course the [illegible] sent a self administered question[illegible] after about 3 months.

For the statistical analysis χ^2 test and [illegible] exact test were used.

RESULTS

Two patients allocated to Auto-tra[illegible] excluded at an early stage. One [illegible]

Table 1. Clinical details of the two groups of patients before the onset of treatment. Percen[illegible] parentheses. N = number of patients. SLR = Straight Leg Raising test

Clinical data	All patients: Auto-traction N = 41	All patients: Corset N = 41	Patients given Auto-tr[illegible]: Positive effect of treatment N = 17	Patients given Auto-tr[illegible]: No pos[illegible] effect of treatment N = 2[illegible]
ANAMNESTIC DATA				
Mean age (years)	36.5	38	35	3[illegible]
No. of female patients	12	19	4 (24)	8 ([illegible])
No. of patients with earlier episodes	33	27	13 (76)	20 ([illegible])
Mean duration of recent episode (weeks)	6.5	6.8	6.4	6.6
No. of patients on sick leave	37	38	15 (88)	22 ([illegible])
THE CLINICAL PICTURE				
No. of patients with radiation of pain below the knee	36	37	14 (82)	22 ([illegible])
No. of patients with decreased reflexes or paresis	20	25	7 (41)	13 ([illegible])
No. of patients with disturbance of sensibility	14	23	3 (18)	11 ([illegible])
Mean value of SLR test	42°	38°	43°	42°
No. of patients with bilateral positive SLR test	18	20	5 (29)	13 ([illegible])
No. of patients with crossed SLR test	3	3	0	3

receive treatment and the other was unable perform the traction The study thus uded 82 patients, with 41 in each atment group, and comprises all patients lling the criteria who could be collected ing the 3-month period of the trial All ients were observed for 3 weeks and 81 ld be contacted for follow-up after about 3 nths. On average, the patients in the Auto- tion group received 2 5 treatments.

nical details

The clinical details of the patients before start of treatment are given in Table 1 out half the patients in each group showed ence of the Achilles reflex of reduced ngth on dorsal extension of the foot or s The corset group contained more men and more patients with reduced sibility The other clinical features listed Table 1 were evenly distributed between two groups.

mber of recoveries within 3 weeks

ression of pain in the leg and back Table shows the number of patients who were from pain at the follow-up examinations after 1 and 3 weeks. Patients who became free from pain in both back and leg and those in whom only the back pain or only the sciatica was relieved are shown separately Fifteen per cent of the traction patients recovered fully within 1 week, compared with none of the corset patients. Freedom from pain in their back or leg at 1 week stated during the same period in a further 27 per cent of the traction patients and in 4 per cent of the corset patients As shown in Table 3, the differences between the treatment groups were statistically significant for both complete and partial recovery after 1 week. Twelve of the 17 traction patients who were free from pain in their back or leg at 1 week stated that they had recovered immediately after the treatment, while the remaining 5 patients were unable to state any direct temporal relationship Between 1 and 3 weeks the differences between the treatment groups decreased *somewhat Four of the traction* patients who had experienced complete or partial recovery at 1 week had suffered recurrence of pain in the back or leg at 3 weeks and a few more patients in each group had recovered. At the 3-week follow-up there was no longer a significant difference between the number of fully recovered patients in the

ble 2 Number of completely and partly recovered patients after 1 week and 3 weeks Group 1 Free m pain both in the back and in the leg Group 2a Free from pain in the leg but not in the back. oup 2b Free from pain in the back, but not in the leg Group 3 Pain in the back and in the leg Percentages are given in parentheses

	1 week		3 weeks	
	Auto-traction	Corset	Auto-traction	Corset
mpletely recovered				
Group 1	6 (15)	0 (0)	7 (17)	3 (7)
rtly recovered				
Group 2a	8 (20)	1 (2)	9 (22)	4 (10)
Group 2b	3 (7)	1 (2)	4 (10)	1 (2)
t recovered				
Group 3	24 (58)	39 (96)	21 (51)	33 (81)
tal	41 (100)	41 (100)	41 (100)	41 (100)

Table 3 Statistical analysis of differences in results between the two treatmen...

	1 week	3 weeks
Completely recovered	$P < 0.05$	Not significant
Completely recovered or free from pain in the leg	$P < 0.001$	$P < 0.05$
Completely recovered or free from pain in the leg or the back	$P < 0.001$	$P < 0.01$

two treatment groups However, if the patients who had achieved relief from pain in either the leg or back also are included, the difference between the two groups was still statistically significant ($P < 0.01$) At the 3- patients who had become free from pain after the treatment were spread among all the therapists

Regression of the SLR test Before treatment all patients had a positive SLR test At the first follow-up 11 of the traction patients had a negative SLR test, compared with none of the corset patients This difference is statistically significant ($P < 0.01$) At the 3-week follow-up 15 of the traction patients and 5 of the corset patients had a negative SLR test This difference is also statistically significant ($P < 0.01$) In all patients except two the sciatica had disappeared when the SLR test was negative

Regression of the neurological abnormalities In the Auto-traction group, the Achilles reflex returned in one patient and two patients reported regression of reduced sensibility within 3 weeks of the start of treatment These three patients belonged to the gro... did not experience regression of pain d... treatment In the remaining Auto... patients the neurological defect re... persisted after 3 weeks.

Relief of pain in patients who h... recovered

About half of the patients with pe... symptoms after 1 week in both tr... groups experienced alleviation of the... Several methods were used to comp... degree of improvement in patients... persistent symptoms. However no diff... could be detected between the two gr... to the degree of alleviation of pain in p... with some persistent pain in the back... the leg

Results after 3 months

Table 4 shows the number of patien... persistent symptoms more than 3 m... after entry into the study There wa... difference between the two groups... symptoms had either been consist... a...

Table 4 The number of patients with symptoms persisting for more than 3 months after entry in... study

	Auto-traction[1] No	Auto-traction[1] %	Corset No	Corset %
Persisting symptoms	21	53	24	[illegible]
Free from symptoms	19	47	17	41
Total	40	100	41	[illegible]

[1] Data lacking for one patient

urred after disappearing for from 1 to 4 eks. The number of patients who had covered completely and subsequently experienced a recurrence of the symptoms ing the period of observation was atively small (5 patients in the traction oup) Most of the patients in Table 4 with rsistent symptoms had thus had symptoms oughout the period of observation We ve no information regarding the intensity extent of symptoms at 3 months ernative methods of treatment were often ed after the first 3 weeks Four traction ients and six corset patients had dergone operations for disc herniation at time of the follow-up

SCUSSION

ere were clear differences between the two oups with respect to the results of the atment Complete freedom from pain or edom from pain in either the back or legs as achieved rapidly in 42 per cent of the to-traction patients, compared with only 4 cent of the corset patients. Only 15 per nt of the Auto-traction patients became mpletely free from pain, however The ults are thus clearly less favourable than viously reported (Lind 1974), in spite of fact that the series seem comparable The rapists in this study, however, had limited perience of the method and at the most three atment sessions were given in 1 week, each ting for only 1 hour No conclusions can be wn from this study as to what results ght be achieved if these conditions were ered In the more successful series of Lind 74) multiple, prolonged treatment sessions re often used

It appears that the patients who did not ome free from pain in the leg or back, also l not achieve any lasting alleviation of the in.

In contrast to the findings of Lind (1974) neurological symptoms were not luenced by the treatment The neurological deficit symptoms of disc herniation usually persist, however, for a long time after both surgical and conservative treatment (Weber 1978)

It is always difficult to judge whether a certain effect of treatment is the result of a direct influence on the cause of the pain or merely a placebo effect The Auto-traction method is probably associated with a greater placebo effect than treatment with only a corset and rest On the other hand, there are certain factors which may be regarded as circumstantial evidence that the difference between the two groups was not merely due to a placebo effect The effect of treatment generally appeared in immediate association with the traction and was often accompanied by a negative SLR test There was a tendency for poorer results in patients with bilateral positive or crossed SLR test or reduced sensibility This may be taken as demonstrating that mechanisms other than pure psychological factors determined whether or not the patient would respond to the treatment

A corset and rest were included in both treatment groups, in an endeavour to restrict the difference in management of the two groups to the Auto-traction It is possible that the patients in the Auto-traction group complied better with the directions regarding bed-rest during the week of treatment The difference in results between the two groups can hardly be explained by this factor, however At one of the hospitals all patients in both groups were hospitalized and confined to bed for 5 days. In spite of the fact that complete rest was thus guaranteed, this hospital reported the greatest difference in results between the two treatment groups. The surgeon at this hospital also had the most experience with Auto-traction

ACKNOWLEDGEMENT

This study was supported by a grant from the Swedish Work Environment Fund.

REFERENCES

Bergquist-Ullman, M & Larsson, U (1977) Acute low back pain in industry A controlled prospective study with special reference to therapy and confounding factors *Acta orthop scand*, Suppl 170

Brodin, H (1977) Results from lumber spine mobilization (Gaymans-Lewit technique) 5th International Congress of the International Federation of Manual Medicine, Copenhagen Abstracts p 14

Doran, D M L. & Newell, D J (1975) Manipulation in treatment of low back pain: A multicentre study *Brit med J* 2, 161–164

Glover, J R, Morris, J G & Khosla, T (1974) Back pain A randomized clinical trial of rotational manipulation of the trunk *Brit J industr. Med* 31, 59–64

Hakelius, A (1970) Prognosis in sciatica A clinical follow-up of surgical and non-surgical treatment *Acta orthop scand*, Suppl 129

Hirsch, C & Nachemson, A (1963) The reliability of lumbar disc surgery *Clin Orthop* 29, 189–194

Horal, J (1969) The clinical appearance of low back disorders in the city of Gothenburg, Sweden Comparisons of incapacitated probands with matched controls *Acta orthop scand*, Suppl 118

Hult, L (1955) Cervical, dorsal and lumbar spinal syndromes *Acta orthop scand*, Suppl 17

Huskisson, E C. (1974) Measurements of pain *Lancet* ii, 1127–1131

Kendall, P H & Jenkins, J M. (1968) Exercise for backache A double blind controlled study *Physiotherapy* 53, 154–157

King J S (1977) Randomized trial of the Rees and Shealy method for the treatment of low back pain *Approaches to the validation of manipulation therapy* (Ed. B[illegible]) Charles C Thomas, Springfield, Ill

Lidström, A & Zachrisson, M (19[illegible]) [illegible] therapy on low back pain and [illegible] attempt at evaluation *Scand. J Rehab.* [illegible] 2, 37–42.

Lind, G A M (1974) Auto-Traction T[illegible] of low back pain and sciatica. Thesis [illegible]sity of Linkoping

Lora, J & Long, D (1976) So-called facet [illegible]tion in the management of intractable [illegible] pain *Spine* 1, 121–126.

Moll, J M H & Wright, V (1971) [illegible] of spinal mobility *Ann Rheum Dis* [illegible] 381–386

Nachemson, A (1971) Low back pain [illegible] and treatment *Clin Med.* 78, [illegible]

Rasmussen, G G (1977) Manipulation [illegible] treatment of low back pain – a [illegible] clinical trial 5th International Congress [illegible] International Federation of Manual [illegible] Copenhagen, Abstracts p 27

Rees, W. E S. (1971) Multiple [illegible] cutaneous rhizolysis of segmental nerves [illegible] treatment of the intervertebral disc [illegible] *Ann Genet Prac* 26, 126–12[illegible]

Shealy, C N (1976) Facet denervation [illegible] management of back and sciatic pain [illegible] *Orthop* 115, 157–164

Spangfort, E V (1972) The lumbar disc [illegible]tion. A computer-aided analysis of [illegible] operations. *Acta orthop scand*, Suppl 1[illegible]

Weber, H (1973) Traction therapy in [illegible] to disc prolapse *J Oslo City Hosp* [illegible] 167–176

Weber, H (1978) Lumbar disc herniation [illegible] spective study of prognostic factors [illegible] controlled trial *J Oslo City Hosp* 28, [illegible]

White, A W M (1966) Low back pain [illegible] receiving workmen's compensation *Can med Ass J* 95, 50–56.

Correspondence to Ulf Larsson, Department of Orthopaedic Surgery, Lasarettet, [illegible] Sweden

a orthop. scand. 51 799–802, 1980

TAL HIP REPLACEMENT IN CONGENITAL ;LOCATION OF THE HIP

S O FREDIN & LARS E UNANDER-SCHARIN

rtment of Orthopedic Surgery, Malmo General Hospital (University of Lund) Malmö Sweden

Twenty cases of congenital dislocation of the hip were treated with total hip replacement The hips were completely dislocated with the femoral head supported by a nearthrosis proximal to the original acetabulum The concept was to reconstruct the hip with an acetabular cup at the site of the original acetabulum even if a portion of the proximal end of the femur had to be sacrificed in the process. The Harris prosthesis appears, in most in stances, to be the most suitable type of prosthesis but it was concluded that the surgeon needs a selection of prostheses for this procedure Nine-tenths of the patients were improved by the procedure and the complications could mostly be successfully dealt with This type of surgery is justified in cases with special indications.

Key words congenital dislocation hip endoprosthesis

Accepted 11 xii.79

: first report of the surgical management congenital dislocation of the hip (CDH) presented by Schantz (1922) The hod used – the osteotomy – was later lified by Hass (1943) and by Blount i2) Also in 1952, Merle d'Aubigné sented a series of 16 hips with CDH .ted by the procedure of Smith-Pedersen unley & Feagin (1973) after the introduc- of total hip replacement (THR) at first ised against the use of this method in H because of the technical difficulties. wever, Harris (1974) and Harris et al 77) have demonstrated, using a modified sthesis designed by Harris himself, that :R operations can be successful also in npletely dislocated hips. Data supporting view have been presented by Dunn & llace (1976), Hess & Umber (1978) and owe et al (1979)

PATIENTS AND METHODS

Twenty hips in 16 patients, all women were included in the study The criterion for selection was a complete dislocation with the femoral head articulating in a nearthrosis proximal to the original acetabulum. The criterion for operation was primarily pain rather than limping and limita tion of motion. Pain at rest was not a major problem in these patients and has not been evaluated. The average age of the patients was 50 years (range 19–69) and the time of follow-up 18 months (range 6–36) The duration of pain prior to the operation was 5–20 years. In seven cases previous operations had been carried out in the same hip (intertrochanteric osteotomy in four the procedure of Smith Petersen in three and a sub-trochanteric rotational osteotomy together with the Chiari procedure in one case) Although, only four cases were operated on bilaterally all but four patients had bilateral CDH with varying degrees of deformity and symptoms from the contralateral hip In several cases there were also deformities of

1–6470.80.050799 $ 2.50 0

the spine the knee or the other hip In one patient the CDH was associated with arthrogryposis

Surgical procedure

The concept of Harris (1974) that the acetabular cup should be implanted at the site of the original acetabulum was applied in all cases

Osteotomy of the trochanter and the femoral head were performed and the capsule completely excised The position of the sciatic nerve was determined The iliopsoas tendon often had to be released from the lesser trochanter and sometimes also the rectus muscle from the lower anterior iliac spine After the dissection it was possible to pull the femur distally Hooks were applied at the pecten ossis pubis, the obturator and the ischiadic foramina as guides for the localization and reaming of the original acetabulum. In 11 hips the acetabular roof was reinforced by transplantation of the femoral head fixed with screws. The femoral shaft was then shortened to a convenient length in order to permit the insertion of the femoral stem The following prostheses were used The Harris type in nine hips the Legrange le Tournel in five hips, the Christiansen in five hips and the Lubinus in one hip After the insertion of the two components of the prosthesis the trochanter was in 10 hips, attached to the femur by wires.

Antibiotic prophylaxis with Cloxacillin for 7 days was used in all patients. In two cases Gentamicin was added to the methylmethacrylate cement The peroperative bleeding was 2100 ml (range 1000–4800) and the duration of the operation was 131 minutes (range 52–185).

Complications

Peroperative Seventeen of the operations were uncomplicated In two cases the femoral shaft was fractured in one case there was perforation of the shaft by the femoral stem and in one a fracture of the trochanter

Postoperative Four hips dislocated post operatively

Primary dislocation occurred in two hips both were treated with open reduction and there was no re-dislocation

Secondary dislocation occurred in two hips. One patient had three dislocations within 2 months and was treated with closed reduction under general anesthesia without further re-dislocation Another patient had multiple dislocations treated with open and closed reductions. The prosthesis was in this case exchanged twice After the most recent exchange to a Charnley prosthesis with a



Figure 1 Preoperative X-ray of a [illegible]

long neck this patient has had two [illegible] of dislocation separated by long [illegible] No neurovascular injuries were [illegible] any clinical signs of thrombo[illegible] plications or infection.

RESULTS


Out of the twenty hips evaluated [illegible] free from symptoms, ten [illegible] unchanged and one worse (the [illegible] multiple dislocations). All [illegible] operative walking pain which [illegible] 14 out of 20 hips evaluated. [illegible] and function are briefly presented [illegible] Inability to balance the pelvis [illegible] Trendelenburg sign – was not [illegible] evaluated preoperatively and the [illegible] therefore inconclusive (Table 2)

DISCUSSION

The THR procedure in CDH is a [illegible] difficult operation with the [illegible]

Table 1 Walking distance and function (16 patients)

		Preoperatively	Postoperatively
alking distance without pain	0–1000 m	16/16	9/16
" "	1000–3000 m	0	2/16
" "	> 3000 m	0	5/16
alking without support		5/16	10/16
able to climb stairs		4/16	0/16
oticeable leg length difference		16/16	9/16



ure 2 Postoperative X-ray A Harris prosis has been inserted and the acetabular roof tored with a transplant of the femoral head

se for new problems to arise The anatomy confusing, in particular the identification of original acetabulum Even if the Harris osthesis is superior in cases with a short nur and a completely excised trochanter it is cessary to have a choice of other types. However, when the femur is hypoplastic with a narrow cavity the Harris mini or micromini type is the only possibility Firm fixation of the trochanter is important in order to avoid postoperative dislocation and limping, particularly when the gluteal muscles are atrophic as in our patient with multiple dislocations. This patient had been operated on three times before the THR

Table 2 The Trendelenburg sign before and after THR in CDH (12 and 20 patients respectively)

	Preoperatively	Postoperatively
Positive	10/12	13/20
Negative	0/12	3/20
Uncertain	2/12	4/20

With early detection and treatment of CDH there will be less need for this type of surgery Since the cases are few it is impossible for the average orthopedic surgeon to gain the experience necessary for successful surgery of completely dislocated CDH In this study there was improvement in 9/10 of the patients, a success rate similar to those presented in the previous studies The complications, mostly dislocations of the prosthesis, can be successfully dealt with The procedure is therefore justified in the hands of a few and in patients severely disabled by their condition

REFERENCES

Blount, W P (1952) Proximal osteotomies of the femur American Academy of Orthopaedic Surgeons, International Course Lectures, Vol 9, Ann Arbor J W Edwards.

Charnley, J & Feagin, J A (1973) Low-friction arthroplasty in congenital subluxation of the hip. *Clin. Orthop* 91, 98–113

Crowe, J F, Mani, J V & Chitranjan R S (1979) Total hip replacement in congenital dislocation and dysplasia of the hip *J Bone Jt Surg* 61-A, 15–23

Dunn H K & Wallace, H E (1976) Total hip reconstruction in chronically dislocated hips. *J Bone Jt Surg* 58 A, 838–845

Harris, W H (1974) Total hip replacement for congenital dysplasia of hip Technique *The hip Proceedings of the Second Scientific Meeting of the Hip Society*, p 251–264, C V Mosby, St Louis.

Harris, W H, Crothers, O & Oh, I [illegible] hip replacement and femoral head [illegible] grafting for severe acetabular [illegible] adults. *J Bone Jt Surg* 59-A, 7[illegible]

Hass, J (1943) A subtrochanteric [illegible] pelvic support. *J Bone Jt Surg* 25, [illegible]

Hess, W E. & Umber, J S. (19[illegible]) Total arthroplasty in chronically dislocated [illegible] *Bone Jt Surg* 60-A, 948–954

Merle D'Aubigné, R. (1952) [illegible] arthroplasty for congenital dislocation of the hip in adults. *J Bone Jt Surg* 34-B [illegible]

Schanz, A (1922) Zur Behandlung der [illegible] angeborenen Huftverrenkung [illegible] *Wschr* 69, 930

Correspondence to H O Fredin M D, Department of Orthopaedic Surgery Malmo General [illegible] S-214 01 Malmo Sweden

ɔrthop. scand *51*, 803–810 1980

ASSIFICATION OF TROCHANTERIC FRACTURES

TEEN JENSEN

artment of Orthopaedic Surgery T-2, Gentofte Hospital,
erup, Denmark

A comparative analysis of the information contained in five different classification systems was performed

The system classifying the fractures into five types in relation to the comminution of the calcar femorale or greater trochanter was found to be superior to the others as it contained the most reliable information about the possibility of obtaining stable fracture reduction and gave the most accurate prediction of the risk of secondary fracture dislocation

Key words femoral neck fractures, fractures, classification

Accepted 21 i 80

a comparison of the results obtained with ferent methods of internal fixation in chanteric fractures it is essential to take ɔ consideration how the fractures have n assessed, as misleading conclusions ght otherwise be drawn

Numerous follow-up studies have not ssified the fractures at all (Cleveland et al 47, 1959, Kennedy et al 1957, Petersen et 1974, Sahlstrand 1974, Sarmiento 1963, ylor et al 1944, 1955), whereas some series ve divided the fractures into displaced and displaced (Hafner 1951, Rasmussen 1953, ade et al 1959) Another system was based the fracture mechanism (Ender 1970, der & Simon-Weidner 1970) As many as ee systems have been developed in which fractures are assessed as stable or stable in an attempt to describe the echanical fixation problems involved in connection with internal fixation procedures.

The first demand on a classification system that *it should contain valid information* ncerning the possibility of obtaining a imary stable and anatomical fracture reduc-n The second demand is a prediction of risk of secondary fracture dislocation lowing internal fixation

From these premises an evaluation and comparison of the existing classification systems was undertaken with the purpose of selecting the system which most accurately predicted the prognosis of the fracture treatment

PATIENTS AND METHODS

During the period January 1st 1978 to June 30th 1979, 234 patients with trochanteric fractures were treated with the sliding screw-plate internal fixation system (Clawson 1964, Jensen et al 1978) With this type of internal fixation technical failure as well as secondary impaction of the fractures following telescoping of the screw are encountered Both situations lead to bony support between the fracture surfaces.

The fractures were assessed from the preoperative X-rays using the five classification systems described in Table 1 The Evans classification system (1949) as slightly modified by Jensen & Michaelsen (1975) is illustrated in Figure 1

The fracture reduction was evaluated from the immediate postoperative X-rays Anatomical reduction was defined as a maximum diastasis over the fracture line of 4 mm. Fracture diastasis exceeding the 4 mm was looked for medially and laterally in the AP projection and anteriorly or posteriorly in the lateral projection.

)1–6470. 80. 050803–08$02.50 0

Table 1 Classification systems for trochanteric fractures

Primary Dislocation
Type 1 undisplaced
Type 2 displaced

Presence of Medial Comminution
Type 1 stable, i e no medial comminution
Type 2 unstable, i e dislocated lesser trochanter or larger femoral arch fragment

Ender's System (1970)
Type 1 eversion fracture, i e posteromedial rotational wedge
Type 2 impaction fracture, i e inversion and adduction of neck fragment with varus [illegible] fracture
Type 3 diatrochanteric fracture, i e fracture line extending subtrochanterically or [illegible]

Tronzo's System (1973)
Type 1 incomplete fracture only involving greater trochanter
Type 2 uncomminuted fracture, with or without slight displacement Intact posterior [illegible] relatively small lesser trochanter fragment
Type 3 comminuted posterior wall with telescoping of neck spike into shaft fragment [illegible] trochanter fragment large
Type 4 like Type 3, but greater trochanter totally broken off
Type 5 comminuted posterior wall without telescoping of the two major fragments [illegible] displaced outside shaft Most posterior wall lost medially
Type 6 reversed oblique fracture with medial displacement of shaft Greater trochanter [illegible] to neck fragment

Evans' System (1949)
Type 1 undisplaced 2-fragmentary fracture
Type 2 displaced 2-fragmentary fracture
Type 3 3 fragmentary fracture without posterolateral support due to dislocated greater [illegible] fragment
Type 4 3-fragmentary fracture without medial support due to dislocated lesser trochanter or [illegible] arch fragment
Type 5 4-fragmentary fracture without medial and posterolateral support. Combination of 3 and 4

The fractures were X-rayed regularly until fracture union or technical failure of fixation was experienced The occurrence of technical failure as well as telescoping of the implant with secondary impaction were registered Technical failure was defined as bending or loosening of the implant and cutting or penetration of the screw through the bone Secondary dislocation was defined as impaction or varus displacement due to technical failures or impaction due to telescoping of the implant

Statistical analysis of the data was applied. An information analysis was performed by multidimensional contingency tables adding variables in steps and comparing in relation to Kullback's information measure (1959) For each step of the analysis the significance of the information contained was calculated In addition a multiple contingency table analysis was performed with successive testing as described by Madsen (1976).

RESULTS

A review of the different [illegible] systems is presented in Table 2 [illegible] based on the preoperative X-rays and [illegible] to the quality of fracture reduction [illegible] the immediate postoperative X-rays

Applying a step-wise information [illegible] the Evans classification system was [illegible] contain the most reliable [illegible] ($P < 0\ 00005$) about the [illegible] achieving anatomical reduction [illegible] different fracture types. Having [illegible] Evans system the next step of the [illegible] revealed that the second best [illegible] considering only the primary [illegible] the fracture ($P < 0\ 00005$). The [illegible]

STABLE





UNSTABLE









ire 1 Classification of trochanteric fractures ording to Evans (1949) as modified by Jensen Iichaelsen (1975)

ems did not give any significant information in the subsequent steps of the analysis 0 3539)

appears from Table 2 that the stable 2-mentary fractures (Types 1 and 2 ording to Evans) can be anatomically iced in both planes in 94 per cent (32/34) cases. The remaining three fracture types the Evans system are all considered table Of the fractures with detachment of reater trochanter fragment (Type 3) only per cent (31/95) could be anatomically reduced in both planes The instability of this fracture type is caused mainly by the difficulty of obtaining reduction in the lateral plane, which was the case in 64 per cent (61/95) In 28 per cent (27/95) this was combined with a medial diastasis. Among fractures with detachment from the calcar femorale (Type 4) only 21 per cent (6/28) could be anatomically reduced in both planes. The main problem is the postoperative medial diastasis encountered in 64 per cent (18/28) of cases. Type 5 fractures with detachment of both trochanters could be anatomically reduced in only 8 per cent (6/77) of cases, whereas fracture diastasis was encountered in 69 per cent (53/77) in both planes.

Table 3 compares the preoperative classification according to the different systems with the secondary fracture dislocation, as evaluated from the final X-rays. The step-wise information analysis was repeated and confirmed that the Evans classification system was significantly the most informative also in this respect ($P<0\,018$) In the second step of the analysis the second best system was again that based on the primary fracture dislocation ($P<0\,00005$) No additional information was contained in the remaining systems ($P<0\,1335$) according to the subsequent steps of the analysis.

Stable 2-fragmentary fractures (Types 1 and 2 in the Evans system) were followed by secondary dislocation in 9 per cent (3/34) of cases, whilst Type 3 fractures dislocated in 58 per cent (55/95), mainly due to fracture diastasis in the lateral plane or bi-plane diastasis. Lack of medial support (Type 4) led to secondary dislocation in 61 per cent (17/28) of cases. This was caused by medial or bi-plane diastasis in 83 per cent (15/17). Secondary dislocation occurred eventually in 78 per cent (60/77) of the highly comminuted 4-fragmentary fractures (Type 5). In 80 per cent (48/60) of cases these dislocations were caused by fracture diastasis in both planes.

The Evans classification system thus revealed a grading which included a decreasing possibility of anatomical reduction and an

Table 2 Classification of trochanteric fractures in relation to the qual[illegible]

Type	Number	Anatomical reduction in both planes	Fracture diastasis in lateral plane	Fracture diastasis in AP plane	[illegible]
Primary Dislocation					
1	41 (18 %)	30 (73 %)	7	4	0
2	193 (82 %)	45 (23 %)	43	18	[illegible]
Medial Comminution					
1	139 (59 %)	63 (45 %)	39	6	[illegible]
2	95 (41 %)	12 (13 %)	11	16	[illegible]
Ender system					
1	114 (49 %)	49 (43 %)	18	13	[illegible]
2	106 (45 %)	23 (22 %)	31	6	[illegible]
3	14 (6 %)	3 (21 %)	1	3	[illegible]
Tronzo system					
1	2	1	1	0	0
2	106 (45 %)	59 (56 %)	23	10	[illegible]
3	33 (14 %)	4 (12 %)	4	4	[illegible]
4	52 (22 %)	6 (12 %)	18	5	[illegible]
5	40 (17 %)	5 (13 %)	4	3	[illegible]
6	1	0	0	0	1
Evans' system					
1	25 (11 %)	24 (96 %)	1	0	0
2	9 (4 %)	8 (89 %)	1	0	0
3	95 (41 %)	31 (33 %)	34	3	[illegible]
4	28 (12 %)	6 (21 %)	4	11	[illegible]
5	77 (33 %)	6 (8 %)	10	8	[illegible]

increasing risk of secondary dislocation ($P < 0.01$, Spearman-test)

A multiple contingency table analysis was applied and revealed that the fracture types according to Evans determined the quality of reduction ($P < 0.00005$) The comminuted fractures were thus more difficult to reduce In the continuation of the analysis it appeared that secondary dislocation was determined by the quality of the reduction ($P < 0.00005$) This meant that secondary dislocation depended solely on the quality of reduction and not on the fracture type as such.

DISCUSSION

The simplest possible method of classifying trochanteric fractures is to divide them into displaced and undisplaced (Hafner 1951, Rasmussen 1953, Wade et al. 19[illegible] leads to fairly reliable informa[illegible] the fracture reduction and the risk of [illegible] dislocation More than 50 per [illegible] fractures will be in the risk gr[illegible] and consequently the system [illegible] sufficient grading

Ender (1970) described a system [illegible] the fracture mechanism in [illegible] his own method of internal fixa[illegible] condylocephalic nails (Ender 19[illegible] Simon-Weidner 1970 K[illegible] Poigenfürst & Schnabl 19[illegible] the present analysis this system [illegible] any reliable prediction of the [illegible] reduction or secondary fracture [illegible] it does not differentiate sufficiently

The mechanical importance of the [illegible] femorale has been pointed out [illegible] reports, leading to a classification [illegible]

Table 3 Classification of trochanteric fractures in relation to secondary fracture dislocation

Secondary Dislocation in Relation to Reduction

Anatomical reduction both planes	Diastasis lateral plane	Diastasis AP plane	Diastasis both planes	Telescoping	Technical failure	Secondary dislocation total
islocation						
1 (3%)	5 (71%)	4 (100%)	0	9	1	10 (24%)
5 (11%)	27 (63%)	12 (67%)	81 (93%)	118	13	125 (65%)
omminution						
3 (5%)	28 (72%)	5 (83%)	29 (94%)	61	7	65 (47%)
3 (25%)	4 (36%)	11 (69%)	52 (93%)	66	7	70 (74%)
tem						
4 (8%)	10 (56%)	10 (77%)	31 (91%)	50	8	55 (48%)
0	21 (68%)	4 (67%)	44 (96%)	66	6	69 (65%)
2 (67%)	1	2 (67%)	6 (86%)	11	0	11 (79%)
stem						
–	1	–	–	1	–	1 (50%)
5 (8%)	16 (70%)	9 (90%)	13 (93%)	41	4	43 (41%)
1 (25%)	1 (25%)	3 (75%)	19 (90%)	23	2	24 (73%)
–	11 (61%)	3 (60%)	22 (96%)	32	5	36 (69%)
–	3 (75%)	1 (33%)	26 (93%)	29	3	30 (75%)
–	–	–	1	1	–	1 (100%)
stem						
1 (4%)	1 (100%)	–	–	1	1	2 (8%)
–	1 (100%)	–	–	1	–	1 (11%)
2 (6%)	24 (71%)	3 (100%)	26 (96%)	51	7	55 (56%)
1 (17%)	1 (25%)	8 (73%)	7 (100%)	16	1	17 (61%)
2 (33%)	5 (63%)	5 (63%)	48 (91%)	58	5	60 (78%)

dial comminution (Harrington 1975, et al 1976, Johnson et al 1968, 1973 Laros & Moore 1974 Massie 964 Murray & Frew 1949, Niemann ikin 1968, Rennie & Mitchell 1976, nto 1967, Sarmiento & Williams 1970, 951) This classification does not take ccount the postero-lateral instability by the difficulty obtaining sufficient on of the fractures in the lateral plane quently this system was not found to iciently reliable

classification system originally ed by Boyd & Griffin (1949) and later d by Tronzo (1973) has only been n a few publications (Bosacco et al Boyd & Andersson 1961 Ecker et al. Tronzo considered both the medial and stero-lateral instability The gradings an increasing degree of instability but the system is rather complicated and in the present analysis the Tronzo system did not prove to be reliable enough in the prediction of the risk of unstable fracture reduction and secondary fracture dislocation

The classification of Evans (1949) is rather simple and based on the presence of mechanical instability as related to detachments from the lesser or greater trochanter This system has been used in numerous publications (Bremner & Graham 1958, Clawson 1957, 1964, Cram 1955, Cuthbert & Howat 1976 Dimon 1973, Dimon & Hughston 1967, Evans 1949, 1951, Foster 1958 Friedenberg et al. 1972, Harrington & Johnston 1973, Horn & Wang 1964, Jensen & Michaelsen 1975, Jensen et al. 1978 Jensen & Sonne-Holm 1980, Kuderna et al 1976 Kyle et al. 1979, Lowell 1966, Morrison et al 1978 Parker 1955, Robey

1956) The Evans classification system has been slightly modified by Jensen & Michaelsen (1975) who based the assessment on the primary X-rays after the accident and reduced the number of types from 6 to 5 by including the extremely rare fracture with a reversed oblique fracture line and large greater trochanter fragment into Type 3

The essential result of the present comparison of the classification systems is that the modification of the Evans system offers the best prediction of the possibility of obtaining reliable anatomical reduction and the risk of secondary fracture dislocation *From the present series a new classification* system could be invented based on three classes The first class would include the stable 2-fragmentary fractures (Types 1 and 2 according to Evans), which can be anatomically reduced in both planes The second class would contain fractures (Types 3 and 4 according to Evans) in which it is difficult to obtain reduction in one plane and *the third class those with difficulty of* reduction in both planes (Type 4 according to Evans) Such a classification system would be consistent with the present analysis which revealed a clear correlation between the fracture type and the possibility of fracture reduction and that mechanically unreliable fracture reduction was significantly related to secondary fracture dislocation With five *existing classification systems, however, there* is no need for a new system It is considered of greater importance to apply one of the existing systems so that the results of the fracture treatment can be compared In this respect the classification system described by Evans with slight modifications (Figure 1) is the system of choice

Only the sliding screw plate system (Clawson 1964, Jensen et al 1978) which allows secondary impaction was considered in the present series. With this fixation method secondary fracture dislocation is possible in all cases with fracture diastasis, leading to the establishment *of bony support In other* methods of internal fixation a secondary fracture dislocation always involves either failure of the osteoporotic bone of the [illegible] head or neck or technical failure of [illegible] implant. A fairly true picture of the [illegible] of the fracture is assumed to be [illegible] in the present series, although a [illegible] *diastasis of up to 4 mm was* [illegible] definition of anatomical reduction [illegible] might explain why 8 per cent (5[illegible] anatomically reduced fractures [illegible] secondarily

In conclusion, the Evans [illegible] system (1949) in the present modification [illegible] found to give the most reliable predic[illegible] the instability of reduction and the [illegible] *secondary fracture dislocation of* [illegible] fractures and should thus be [illegible] any analysis of the internal fixation of [illegible] fractures.

ACKNOWLEDGEMENTS

This study was kindly supported by [illegible] Gjenforsikrings Jubilæumsfond. Grat[illegible] expressed to Sv Kreiner-Møller [illegible] Department for Data Processing, [illegible] for the statistical aid.

REFERENCES

Bosacco, D N., Berman, A. T., [illegible] Fabiani J A. & Conner J H ([illegible] weight bearing for intertrochanteric fr[illegible] Amer Academy Orthop. Surg [illegible] Washington D C.

Boyd H B & Anderson, L D ([illegible] ment of unstable trochanteric fractures [illegible] *Gynec Obstet* 112, 633–638.

Boyd, H B & Griffin, L L ([illegible] and treatment of trochanteric fractures [illegible] *Surg* 58, 853–866.

Bremner R A & Graham, W D [illegible] Treatment of pertrochanteric [illegible] fractures of the femur by [illegible] with a two-piece nail and plate J [illegible] *Surg* 40-B 694–700.

Clawson, D K (1957) Intertrochanteric [illegible] of the hip. *Amer J Surg* 93, [illegible]

Clawson, D. K. (1964) Trochanteric [illegible] treated by the sliding screw [illegible] method. *J Trauma* 4, 737–[illegible]

reland, M, Bosworth, D M & Thompson, F R (1947) Intertrochanteric fractures of the femur *J Bone Jt Surg* **29**, 1049–1068

reland, M, Bosworth, D M, Thompson, F R, Wilson, H J & Ishizuka, T (1959) A ten-year analysis of intertrochanteric fractures of the femur *J Bone Jt Surg* **41-A**, 1399–1408

m, R H (1955) The unstable intertrochanteric fracture *Surg Gynec. Obstet.* **101**, 15–19

hbert, H & Howat, T W (1976) The use of the Küntscher Y-Nail in the treatment of intertrochanteric and subtrochanteric fractures of the femur *Injury* **8**, 135–142

hon, J H (1973) The unstable intertrochanteric fracture *Clin Orthop* **92**, 100–107

hon, J H & Hughston J C (1967) Unstable intertrochanteric fractures of the hip *J Bone Jt Surg* **49-A**, 440–450

er, M L, Joyce III, J J & Kohl, E J (1975) The treatment of trochanteric hip fractures using a compression screw *J Bone Jt Surg* **57 A**, 23–27

ler, J (1970) Probleme beim frischen per- und subtrochanteren Oberschenkelbruch *Hefte Unfallheilk* **106**, 2–11

ler, J & Simon-Weidner, R (1970) Die Fixierung der trochanteren Bruche mit runden elastischen Condylennageln *Acta chir austr* **2**, 40–42.

ins, E M (1949) The treatment of trochanteric fractures of the femur *J Bone Jt Surg* **31-B**, 190–203

ins, E M (1951) Trochanteric fractures. A review of 110 cases treated by nail plate fixation *J Bone Jt Surg* **33 B**, 192–204

ter, J C (1958) Trochanteric fractures of the femur treated by the vitallium McLaughlin nail and plate *J Bone Jt Surg* **40-B**, 684–693

denberg Z B Gentchos E & Rutt, C (1972) Fixation in intertrochanteric fractures of the hip *Surg Gynec Obstet* **135**, 225–228

fner, R H V (1951) Trochanteric fractures of the femur *J Bone Jt Surg* **33-B**, 513–516

rrington, K D (1975) The use of methylmethacrylate as an adjunct in the internal fixation of unstable comminuted intertrochanteric fractures in osteoporotic patients. *J Bone Jt Surg* **57-A** 744–750

rrington, K D & Johnston J O (1973) The management of comminuted unstable intertrochanteric fractures. *J Bone Jt Surg* **55 A**, 1367–1376

rm, J S & Wang, Y C. (1964) The mechanism, traumatic anatomy and non-operative treatment of intertrochanteric fractures of the femur *Brit J Surg* **51**, 574–580

obs, R. R., Armstrong J., Whitaker, J H & Pazall, J (1976) Treatment of intertrochanteric hip fractures with a compression hip screw and a nail plate *J Trauma* **16**, 599–603

Jensen J Steen & Michaelsen, M (1975) Trochanteric femoral fractures treated with McLaughlin osteosynthesis *Acta orthop scand* **46**, 795–803

Jensen, J Steen, Tøndevold, E & Mossing, N (1978) Unstable trochanteric fractures treated with the sliding screw-plate system *Acta orthop scand* **49**, 392–397

Jensen, J Steen & Sonne-Holm, S (1980) Critical analysis of Ender nailing in the treatment of trochanteric fractures. *Acta orthop scand.* **51**, 817–825

Johnson, L. L, Lottes, J O & Arnot, J P (1968) The utilization of the Holt nail for proximal femoral fractures. *J Bone Jt Surg* **50-A**, 67–78

Kapral, W (1976) Osteosynthese pertrochanterer Frakturen mit Federnägeln nach Ender *Aktuel Chir* **11**, 371–388

Kennedy, J C, McFarlane, R. M & McLachlin, A D (1957) The Moe plate in intertrochanteric fractures of the femur *J Bone Jt Surg* **39 B**, 451–457

Kuderna, H., Bohler, N & Collon, D J (1976) Treatment of intertrochanteric and subtrochanteric fractures of the hip by the Ender method *J Bone Jt Surg* **58-A**, 604–611

Kumar, V (1973) The syndrome of the fracture of the lesser trochanter in adults A neglected aspect of the trochanteric fracture *Injury* **4**, 327–334

Kullback, S (1959) *Information theory and statistics* John Wiley & Sons, New York.

Kyle, R F, Gustilo, R B & Premer, R F (1979) Analysis of six hundred and twenty-two intertrochanteric hip fractures. *J Bone Jt Surg* **61-A**, 216–220

Laros, G S & Moore, J F (1974) Complications of fixation in intertrochanteric fractures. *Clin Orthop* **101**, 110–119

Lowell, J D (1966) Fractures of the hip *New Engl J Med* **274**, 1418–1425

Madsen M (1976) Statistical analysis of multiple contingency tables. *Scand J Statist* **3**, 97–106

Massie, W K. (1962) Extracapsular fractures of the hip treated by impaction using a sliding nail-plate fixation. *Clin. Orthop* **22**, 180–201

Massie, W K. (1964) Fractures of the hip *J Bone Jt Surg* **46-A**, 658–690

Morrison D., Mrstik, L. L & Weingarden, T L. (1978) Management of unstable intertrochanteric fractures of the hip *J Amer Osteopath. Ass* **77**, 793–802.

Mulholland, R. C. & Gunn, D R (1972) Sliding

1956). The Evans classification system has been slightly modified by Jensen & Michaelsen (1975) who based the assessment on the primary X-rays after the accident and reduced the number of types from 6 to 5 by including the extremely rare fracture with a reversed oblique fracture line and large greater trochanter fragment into Type 3

The essential result of the present comparison of the classification systems is that the modification of the Evans system offers the best prediction of the possibility of obtaining reliable anatomical reduction and the risk of secondary fracture dislocation. From the present series a new classification system could be invented based on three classes. The first class would include the stable 2-fragmentary fractures (Types 1 and 2 according to Evans), which can be anatomically reduced in both planes. The second class would contain fractures (Types 3 and 4 according to Evans) in which it is difficult to obtain reduction in one plane and the third class those with difficulty of reduction in both planes (Type 4 according to Evans). Such a classification system would be consistent with the present analysis which revealed a clear correlation between the fracture type and the possibility of fracture reduction and that mechanically unreliable fracture reduction was significantly related to secondary fracture dislocation. With five existing classification systems, however, there is no need for a new system. It is considered *of greater importance to apply one of the* existing systems so that the results of the fracture treatment can be compared. In this respect the classification system described by Evans with slight modifications (Figure 1) is the system of choice.

Only the sliding screw plate system (Clawson 1964, Jensen et al. 1978) which allows secondary impaction was considered in the present series. With this fixation method secondary fracture dislocation is possible in all cases with fracture diastasis, leading to the establishment of bony support. In other methods of internal fixation a secondary fracture dislocation always involves either failure of the osteoporotic [illegible] head or neck or technical failure [illegible] implant. A fairly true picture of the [illegible] of the fracture is assumed to be [illegible] in the present series, although [illegible] diastasis of up to 4 mm was [illegible] definition of anatomical reduction [illegible] might explain why 8 per cent ([illegible]) [illegible] anatomically reduced fractures [illegible] secondarily

In conclusion, the Evans [illegible] system (1949) in the [illegible] found to give the most reliable [illegible] the instability of reduction and the [illegible] secondary fracture dislocation of [illegible] fractures and should thus be [illegible] any analysis of the internal [illegible] fractures.

ACKNOWLEDGEMENTS

This study was kindly supported by [illegible] Gjenforsikrings Jubilaeumsfond. Gratitude [illegible] expressed to Sv Kremer-Møller (and [illegible]) Department for Data Processing [illegible] for the statistical aid.

REFERENCES

Bosacco, D N., Berman, A. T., [illegible] Fabiani, J A. & Comer J. H. ([illegible]) [illegible] weight bearing for intertrochanteric [illegible] Amer Academy Orthop. Surg [illegible] Washington D.C.

Boyd, H. B & Anderson, L. D. ([illegible]) [illegible] ment of unstable trochanteric fractures *Gynec. Obstet.* 112, 633–638

Boyd, H B & Griffin, L. L. (1947) [illegible] and treatment of trochanteric fractures [illegible] *Surg* 58, 853–866.

Bremner R. A. & Graham W D. [illegible] Treatment of pertrochanteric [illegible] fractures of the femur by [illegible] with a two-piece nail and plate. *J. [illegible] Surg* 40-B 694–700.

Clawson, D K. (1957) Intertrochanteric [illegible] of the hip. *Amer J Surg* 93, [illegible]

Clawson, D K. (1964) Trochanteric [illegible] treated by the sliding screw plate [illegible] method. *J Trauma* 4, 73–[illegible]

ıorthop scand. 51, 811–816, 1980

;ABLE TROCHANTERIC FRACTURES. 'COMPARATIVE ANALYSIS OF FOUR ETHODS OF INTERNAL FIXATION

STEEN JENSEN, E TØNDEVOLD & S SONNE-HOLM

ɔartments of Orthopaedic Surgery T-2 and T-3, Gentofte Hospital, Department of Orthopaedic ˈgery A, Frederiksberg Hospital and Department of Orthopaedic Surgery U, Rigshospitalet, University ;openhagen, Denmark

A series of 375 patients with stable trochanteric fractures were treated with the McLaughlin or Jewett nail-plate, the sliding screw-plate or Ender nailing

Technical failure of fixation was encountered in 5 per cent of the cases regardless of the method of fixation used Re-operations were performed in less than 3 per cent of cases treated with hip implants but in 20 per cent of cases with Ender nailing, mainly because of distal slipping of the nails resulting in knee problems.

With an improved technique, however, Ender nailing can be used as successfully as any of the hip implants for the internal fixation of stable trochanteric fractures.

Key words femoral neck fractures, internal fixation, fractures, internal fixation

Accepted 21 ı.80

.rious methods have been described for the .ernal fixation of trochanteric fractures. In estern Europe the most commonly used ·thods have been the Jewett and :Laughlin nail-plates. In the beginning of : 1960s various types of telescoping devices ·re introduced (Böttger & Dahlke 1963, awson 1964, Ehlers & May 1964, Massie 62, Schumpelick & Jantzen 1955) and the ding screw-plate has been widely used ·nsen et al 1978) In 1970 condylocephalic iling was introduced (Ender 1970, Ender & mon-Weidner 1970, Simon-Weidner 1970) d has become very popular especially in iddle Europe and Scandinavia

The purpose of the present study was to mpare the results of the internal fixation of trochanteric fractures treated by the Jewett or McLaughlin nail-plates, the sliding screw-plate or Ender nailing In the present paper only the treatment of stable trochanteric fractures (Evans 1949, Jensen 1980c) will be considered, the results obtained in unstable fractures (Evans 1949, Jensen 1980c) are discussed in a separate report (Jensen et al. 1980).

PATIENTS AND METHODS

During the period April 1st 1971 to June 30th 1979, a total of 1,646 patients with trochanteric fractures were admitted to the four departments of orthopaedic surgery participating in the study There were 421 cases classified as stable according to the classification system described by Evans

J1–6470. 80. 050811–06$02.50. 0

(1949) and recommended by Jensen (1980 c) Of these 273 were undisplaced 2 fragmentary fractures and 148 displaced 2 fragmentary fractures

Five patients were treated by other methods, 33 patients died before fracture union and 8 patients were lost to follow up This study thus includes 375 patients treated by one of the four methods and followed radiologically until fracture union or technical failure was encountered

The fracture reduction was evaluated from the postoperative X ray Anatomical reduction was defined as a diastasis over the fracture line of 4 mm or less Fracture diastasis of 5 mm or more was looked for medially or laterally in the AP projection and anteriorly or posteriorly in the lateral projection The fractures were X rayed regularly until fracture union with registration of the occurrence of technical failure, telescoping of the sliding screw plate with secondary fracture dislocation and distal slipping of the Ender nails with or without displacement of the fracture Technical failure was defined as any complicating fracture bending or breakage of the implant or [illegible] of the implant in relation to the bone All [illegible] were evaluated by the three authors

In addition the rates of deep [illegible] osteitis non union and re-operation [illegible] recorded Prophylactic antibiotics [illegible] applied

The median age of the patients at the [illegible]

RESULTS

The distribution of the four [illegible] treatment in relation to the two [illegible] fractures is shown in Table 1 No [illegible] concerning age, sex and fracture type [illegible] found

Deep infection or osteitis was [illegible]

Table 1 Treatment of stable fractures

Fracture type	McLaughlin nail plate	Jewett nail plate	Sliding screw plate	Ender nailing	Total
Undisplaced 2 fragmentary	78	109	32	24	[illegible]
Displaced 2 fragmentary	37	55	18	22	[illegible]
Total	115	164	50	46	[illegible]

Table 2 Quality of reduction in stable trochanteric fractures

Reduction	McLaughlin nail plate	Jewett nail plate	Sliding screw-plate	Ender nailing	Total
Anatomical in both planes	107 (93%)	147 (90%)	45 (90%)	39 (90%)	[illegible]
Diastasis in lateral plane	6	7	3	3	19
Diastasis in AP plane	1	10	1	3	15
Diastasis in both planes	1	–	1	1	3

? per cent (1/115) following McLaughlin plate fixation, in 1 8 per cent (3/164) Jewett and in 2 per cent (1/50) after ıg screw-plate fixation The total rate of tions following surgery of the hip region thus 1 5 per cent (5/329), whereas no in- ons were encountered after Ender con- ephalic nailing (P = 0 8, Chi-square

he quality of fracture reduction is listed Table 2 Anatomical reduction was ined in 93 per cent (107/115) of cases McLaughlin fixation, in 90 per cent /164) following Jewett, in 90 per cent 50) following sliding screw-plate and in per cent (39/46) following Ender nailing lane diastasis was encountered in less ı 1 per cent (3/375) of cases (P = 0 99, -square test)

'he results of treatment of stable hanteric fractures are listed in Table 3 ion in the postoperative position was ained in 93 per cent (349/375) of cases In cases telescoping of the sliding screw- te was experienced prior to union as is ended with this device Secondary dis- cement with distal slipping of the nails s encountered in 11 per cent (5/46) of der nailings. Distal slipping without cture displacement was encountered in 19 per cent (9/46) of cases. Distal displacement of the Ender nails often caused knee pain, necessitating re-operation

Technical failures were encountered in 5 per cent (19/375) of the entire series with no significant difference between the methods (P = 0 95, Chi-square test) The type of failures are listed in Table 4 Varus dislocation of the fracture of less than 10° was encountered in about 2 per cent (7/375) of cases, whereas one fracture dislocated 30° after a McLaughlin nail-plate fixation Secondary fracture dislocation and technical failures were observed within the first 4 weeks following the operation in 62 per cent (16/26) of cases The remainder were encountered before the 12th week

Re-operations were performed in 4 per cent (9/252) of cases with hip nail-plates or screw-plates with no significant difference between the methods (P = 0 9, Chi-square test) Re-operation was, however, necessary in 20 per cent (9/46) of patients treated by Ender nailing, either due to technical failure or distal slipping of the nails resulting in knee complaints. Bi-plane anatomical reduction was followed by technical failures or secondary displacements in 2 per cent (7/338) of cases All three fractures reduced with diastasis in both planes dislocated secondarily compared

Table 3 Results of treatment of stable trochanteric fractures

ult	McLaughlin nail plate	Jewett nail-plate	Sliding screw-plate	Ender nailing	Total
ion in post rative ition	110 (96%)	155 (95%)	45 (90%)	39 (85%)	349
ondary dis- cement with ion			2	5	7
n-union	–	–	–	–	–
chnical lure	5 (4%)	9 (5%)	3 (6%)	2 (4%)	19 (5%)
tal	115	164	50	46	375

Table 4 Technical failures following internal fixation of stable trochanteric fractures

	McLaughlin nail plate	Jewett nail-plate	Sliding screw plate	Ender nailing	
Cutting/migration < 10 mm	1	2	1		
Penetration of fem head	1	4		2	
Penetration of acetabulum		3	1		
Failure of nail-plate junction	3				
Plate loose			1		
Number of patients	5 (4 %)	9 (5 %)	3 (6 %)	2 (4 %)	19 (5
Varus dislocation < 10°	3	2	1	1	
Varus dislocation > 20°	1				
Re-operations	1 (1 %)	7 (4 %)	1 (2 %)	9 (20 %)	15 (4

with 38 per cent (13/34) of those reduced with diastasis in one plane only A multivariate logistic analysis revealed a highly significant relationship between technical failures and fractures reduced with diastasis ($P < 0\ 00005$)

DISCUSSION

In the treatment of stable trochanteric fractures the problems involved in obtaining fracture union are minor (Ender 1970, Jensen & Sonne-Holm 1980), a fact which should encourage the use of simple methods of treatment Internal fixation is not a great mechanical problem because an exact fracture reduction, which can usually be obtained, leads to a stable weight-transmission system in which load on the hip joint is transmitted to the femoral head through bony contact over the fracture line

In surgery of the hip region one of the serious complications is deep infection or osteitis This was experienced in 1 5 per cent of cases in this series regardless of the method used Although prophylactic antibiotics were not applied the infe is much lower than usually reported & Kjellander 1978)

In a comparison of the results obt different methods of internal fi fracture classification system predi difficulty of obtaining sufficient reduction and the risk of failure of fixation should be applied. The clas system introduced by Evans (1949), based on the comminution of t medially and posteriorly, allows suc diction (Jensen 1980c)

Every X-ray in the present se described by the three authors acco the classification system mentione allows comparison of the results Ma the comparison caused by the retr uncontrolled design are of minor im as this was a radiological study

In the present series 93 per ce fractures could be reduced without d in connection with McLaughlin t fixation and 96 per cent united postoperative position Technical following stable fractures have been r

–occur in 6–13 per cent (Foster 1958, ...n & Michaelsen 1975, Laros & Moore ...) In the present series a technical failure of only 4 per cent was experienced, and one patient developed a varus dislocation 30° due to failure of the nail-plate tion In a biomechanical study of ...aughlin implants (Jensen 1980 a, b) very failure loads for the nail-plate connection ... reported and most of the failures in the ...ent series are also due to failure of the ...lant at this point

...wett nail-plate fixation has been followed ...echnical failures in 4–20 per cent of cases ...yd & Griffin 1949, Dimon & Hughston ...7, Jacobs et al 1976), although Laros & ...ore (1974) claimed 43 per cent in a series ...nly seven cases In the present series bi...e anatomical reduction was achieved in ... per cent and technical failure occurred in ... 5 per cent of cases. All failures were due ... displacement of the nail tip inside the ...oral head or protrusion outside the con...ments of the head or neck

...echnical failures after sliding screw-plate ...tion of stable trochanteric fractures were ...he present series observed in 6 per cent of ...s, which is consistent with other reports ...awson 1964, Jacobs et al 1976) ...atomical reduction was encountered in 90 ... cent.

...he results obtained with any of the ...e types of hip implants were completely ...sfactory with very low failure rates and a ...operation rate of about 3 per cent Any ...e of hip implant can thus be used ...cessfully for the internal fixation of stable ...chanteric fractures

...Condylocephalic nailing according to Ender ...70) has in mixed series of stable and ...stable fractures been followed by technical ...ures in 7–28 per cent of cases (Hult & ...sson 1978 Kapral 1976 Kuderna et al ...76, Poigenfürst & Schnabl 1977, Wynn ...es et al 1977) and re-operations have been ...formed in 8–13 per cent (Poigenfürst & ...hnabl 1977, Wynn Jones et al 1977) In ... present series technical failures were ...served in 4 per cent of cases, which is comparable with the failure rates experienced with hip nail plates. In addition 30 per cent of the nails slipped distally and caused knee problems leading to a total of 20 per cent re-operations (Jensen & Sonne-Holm 1980, Kuderna 1976) In the present series only 85 per cent of the fractures were reduced anatomically It should be possible to obtain better fracture reduction and to improve the operative technique by filling out the entire medullary cavity with nails and not letting the nail ends protrude into the knee region. If this is the case then Ender nailing can also be recommended for the internal fixation of stable trochanteric fractures

ACKNOWLEDGEMENTS

This study was kindly supported by Nordisk Gjenforsikrings Jubilaeumsfond Gratitude is expressed to Sv Kreiner-Møller (cand stat) Department for Data Processing, Herlev Hospital for statistical aid.

REFERENCES

Boyd, H B & Griffin, L L (1949) Classification and treatment of trochanteric fractures. *Arch Surg* 58, 853–866

Bottger, G & Dahlke, H (1963) Zur operativen Behandlung der per und subtrochanteren Oberschenkelfrakturen mit der nichtsperrenden Laschenschraube nach Pohl *Chirurg* 34, 514–519

Clawson D K (1964) Trochanteric fractures treated by the sliding screw plate fixation method. *J Trauma* 4, 737–752

Di[illegible]

Eh[illegible] Behandlung pertrochanterer Oberschenkelbruche am hoheren Lebensalter mit der Laschenschraube nach Pohl *Mschr Unfallheilk.* 67, 163–170

Ender, J (1970) Probleme beim frischen per- und subtrochanteren Oberschenkelbruch. *Hefte Unfallheilk* 106, 2–11

Ender J & Simon-Weidner R (1970) Die Fixierung der trochanteren Bruche mit runden elastischen Condylennageln. *Acta chir austr* 2, 40–42

Evans, E M (1949) The treatment of trochanteric

fractures of the femur *J Bone Jt Surg* **31**-B, 190–203
Foster, J C (1958) Trochanteric fractures of the fem [illegible] and [illegible]
Hult, I [illegible] av [illegible] 4603–4608
Jacobs, R R, Armstrong, J, Whitaker, J H & Pazell, J (1976) Treatment of intertrochanteric hip fractures with a compression hip screw and a nail plate *J Trauma* **16**, 599–603
Jensen, J Steen (1980 a) Mechanical strength of Jewett and McLaughlin hip nail plates manufactured from Cobalt-Chromium-Molybdenum alloy *Acta orthop scand* **51**, 145–156
Jensen, J Steen (1980 b) Mechanical strength of McLaughlin hip nail plates manufactured from 316 LVM stainless steel *Acta orthop scand* **51**, 439–444
Jensen, J Steen (1980 c) Classification of trochanteric fractures *Acta orthop scand* **51**, 803–810
Jensen, J Steen & Michaelsen, M (1975) Trochanteric femoral fractures treated with McLaughlin osteosynthesis *Acta orthop scand* **46**, 795–803
Jensen, J Steen & Sonne-Holm, S (1980) Critical analysis of the Ender nailing in the treatment of trochanteric fractures *Acta orthop scand* **51**, 817–825
Jensen, J Steen, Sonne-Holm, S & Tøndevold, E (1980) Unstable trochanteric fractures. A comparative analysis of four methods of internal fixation *Acta orthop scand* (In press)
Jensen, J Steen, Tøndevold, E & Mossing, N (1978) Unstable trochanteric fractures treated with the sliding screw-plate system *Acta orthop scand* **49**, 392–397
Kapral, W (1976) Osteosynthese Frakturen mit Federnägeln nach Ender *Chir* **11**, 371–388
Kuderna, H (1976) Ursache und [illegible] Kniebeschwerden und Aussenrota[illegible] lungen nach Stabilisierung Frakturen mit Endernageln. *Akt. Tra* **6**, 163–165
Kuderna, H, Bohler, N & Collon, D J Treatment of intertrochanteric and trochanteric fractures of the hip by the method *J Bone Jt Surg* **58** A 604–611
Laros, G S & Moore, J F (1974) Compl[illegible] of fixation in intertrochanteric fractures *Orthop.* **101**, 110–119
Massie, W K (1962) Extracapsular frac[illegible]
Po[illegible] tramedullary nailing of pertroch[illegible] fractures with elastic nails — Op[illegible] procedure and results. *Injury* **9**, 102–111
Schumpelick, W & Jantzen P M (1955) [illegible] principle in the operative treatm[illegible] trochanteric fractures of the femur *J B[illegible] Surg* **37** A, 693–698
Simon-Weidner, R (1970) Die Fi[illegible] trochanterer Brüche mit multiplen [illegible] Rundnageln nach Simon Weidner [illegible] *Unfallheilk* **106**, 60–62
[illegible] (1978) [illegible] parison of the treatment of fractures of the femur by internal fixa[illegible] a nail-plate and the Ender technique. *I[illegible]* 35–42

Correspondence to J Steen Jensen, M D, Department of Orthopaedic Surgery T-2, Gentofte H[illegible] DK-2900 Hellerup, Denmark

a orthop scand. 51, 817–825 1980

RITICAL ANALYSIS OF ENDER NAILING IN THE REATMENT OF TROCHANTERIC FRACTURES

STEEN JENSEN & S SONNE-HOLM

partment of Orthopaedic Surgery U, Rigshospitalet,
uversity of Copenhagen, Denmark

A consecutive series of 152 trochanteric fractures treated by Ender nailing has been analysed. The mortality was 5 per cent after 3 weeks and the infection rate 2.6 per cent.

The follow-up was attended by 139 patients, 41 having had stable and 98 unstable trochanteric fractures. In the group with stable fractures, secondary displacement of the fracture or the nails occurred in 12 per cent and knee pain in 32 per cent, necessitating re-operation in 22 per cent of these patients. The corresponding figures for the unstable fractures were 64 per cent secondary displacement, 59 per cent knee pain and 46 per cent re-operations.

The results are discussed and it is concluded that, with an improvement in fracture reduction and operative technique, it may be possible to successfully treat stable trochanteric fractures with Ender nailing However, this method cannot be recommended for unstable trochanteric fractures.

Key words femoral neck fractures, fracture fixation

Accepted 25.ii.80

1966, Kuntscher introduced condylo-phalic nailing of trochanteric fractures Kuntscher 1966, 1970) using a slightly rved, ordinary medullary nail. The method is, however, not widely used (Bø 1979, Collado et al. 1973)

Ender and Simon-Weidner further veloped the method of condylocephalic iling, applying three to five elastic, pre-bent ils with a diameter of 4 5 mm (Ender 1970, der & Simon-Weidner 1970, Simon-eidner 1970). During the last 5 years the thod has gained wide popularity and a mber of reports, especially from Middle rope have recommended this internal ation system claiming the advantages of ly weight-bearing reduced mortality and orter hospitalization time (Bohler et al 1975 der 1973 Ender & Simon Weidner 1974, Hult & Nilsson 1978, Philadelphy et al. 1975, Poigenfürst 1973). There have not been very many clinical reports (Kapral 1976, Kuderna et al. 1976, Poigenfürst & Schnabl 1977, Wynn Jones et al. 1977), but some papers have focused on the avoidance of technical failures without giving any background for their recommendations (Kuderna 1976, Persch & Birkner 1977).

The purpose of the present study was to perform a critical analysis of the radiological results and the clinical consequences of internal fixation of trochanteric fractures by the Ender method.

PATIENTS AND METHODS

During the period December 8th 1975 to December 31st 1978 condylo-cephalic elastic

01-6470 80 050317-09802.50 0

nailing according to Ender was used in the treatment of 152 consecutive, trochanteric fractures.

The operative technique was that described by Ender & Simon-Weidner (1974) and Kuderna et al (1976) The patient is placed supine on a fracture table and the fracture is reduced under X-ray image intensification The medial supracondylar region of the femur is exposed and the cortex perforated proximal to the adductor tubercle

Three to five elastic nails 4 5 mm in diameter are introduced into the medullary cavity, diverging through the femoral neck and protruding into the subchondral area of the femoral head In fractures with a large fragment from the greater trochanter this is fixed by introducing an additional nail in the area of the lateral femoral condyle After completion of the operation the nails are left protruding a few millimetres outside the bone cortex in the supracondylar region

Postoperatively early weight-bearing mobilization was emphasized although tibial traction was applied for 3 weeks in severely comminuted fractures. None of the cases included in the study was operated on by either of the authors.

The median age of the patients was 76 years (range 35–97) and 75 per cent (114/152) were women A follow-up of 139 patients was performed, as seven patients died before fracture union and six were lost to follow-up The mortality was thus 5 per cent (7/152) within 3 weeks.

The fractures were classified from the primary X-rays into stable and unstable fractures depending on the existence of bony support across the calcar femorale and postero-laterally (Evans 1949, Jensen 1980) The postoperative X-rays were evaluated with reference to the quality of the fracture reduction, i e the appearance of fracture diastasis medially, laterally, anteriorly or posteriorly over the fracture line The reduction was considered ideal if there was a fracture diastasis of less than 0 5 cm, in all other situations the reduction was considered mechanically unstable The positioning of the nails was also recorded. The fractures were followed up until bony union took place or technical [illegible] occurred. Technical failure was defined as [illegible] plicating supracondylar or femoral shaft fr[illegible] or a secondary dislocation of the fracture [illegible] The number of infections, re-operations and [illegible] complaints were recorded

RESULTS

The classification of the fractures [illegible] Table 1; 29 per cent (44/152) [illegible] as stable and 71 per cent as unstable.

Deep infection at the operation s[illegible] encountered in two cases and suprac[illegible] osteitis in another two cases. The [illegible] rate was thus 2 6 per cent (4/152).

Full weight-bearing was obtained af[illegible] weeks No significant relationship was [illegible] between the time taken to achieve [illegible] weight-bearing, the fracture type and [illegible] quality of reduction In six patients [illegible] unstable fractures traction was [illegible] postoperatively

Stable trochanteric fractures were fol[illegible] up in 41 out of 44 cases. Ideal [illegible] achieved in 37 cases. Fracture gaps [illegible] observed in 16 per cent (7/44) [illegible] medially in four and anteriorly or [illegible] in three cases

Technical failures are listed in Ta[illegible] Distal slipping of the nails without [illegible] displacement of the fracture, as record[illegible] nine cases, was of no clinical significan[illegible] one case the fracture dislocated [illegible] whereas bony support was achieved [illegible] secondary impaction in four cases (Fig[illegible] Secondary displacement followed [illegible] fracture reduction in 8 per cent (1[illegible]) [illegible]

Table 1 Classification of trochanteric fractures

Stable 44	2-fragmentary, undisplaced	24
	2-fragmentary, displaced	20
Unstable 108	3-fragmentary without medial support	12
	3-fragmentary without postero-lateral support	42
	4-fragmentary	54

Table 2 Technical failures following Ender nailing of 139 trochanteric fractures

	Stable $n-41$	Unstable $n-98$
racondylar or femoral shaft fracture		3
;ration/cutting of nails within fem head		4
etration through cartilaginous border	2	11
[illegible]		1
[illegible]	3	45
	9	13
al	14	76
nificant failures with re-operations	9/41 22 %	36/98 37 %

per cent (2/7) of insufficiently reduced es

Knee complaints were recorded in 32 per it (13/41) and were caused by distal pping of the nails in eight cases

Re-operations (Table 3) were performed in 22 per cent (9/41) of the cases, a total of 10 operations. These were caused by distal slipping of the nails, except in one case where knee complaints were the only indication



gure 1 *Secondary impaction and distal slipping of the nails A The fracture is reduced with a diastasis er the fracture line The nails are protruding too far into the knee region.*



B Secondary impaction of fracture has been obtained but one nail has slipped back
resulting in knee pain

Unstable trochanteric fractures were followed up in 98 out of 108 cases Ideal reduction was achieved in 20 per cent (21/105) and mechanically unreliable reduction in 80 per cent (84/105) A medial diastasis was encountered in 56 cases and anterior, posterior or lateral diastasis in 28 cases A multivariate logistic analysis revealed no significant correlation between the stability of the reduction and the positioning of the nails ($P > 0\ 05$) but there was a highly si relationship between the fracture type mechanical stability of the fracture ($P < 0\ 00005$). The comminution of fracture determines the stability of reduction

Technical failures are listed in Ta One spiral fracture of the femoral sh treated by tibial traction. There were supracondylar fractures which resulted

Figure 2 (next page) A Three-fragmentary fracture without postero-lateral support reduced with diastasis B Secondary impaction leading to bony support over the fracture line

A

B

Table 3 Re-operations following Ender nailing of trochanteric fractures

	Stable n 41	[illegible]
Nail plate fixation		1
Re-tapping of nails	1	[illegible]
Resection of nail ends		[illegible]
Removal of nails due to distal slipping	8	[illegible]
Removal of nails due to knee complaints	1	6
Number of operations	10	[illegible]
Number of patients	9 41	[illegible]
	22%	[illegible]

hip fractures being treated by nail-plate fixation, and in addition a AO-angular plate was applied to one of the supracondylar fractures

Secondary fracture displacement was caused by distal slipping of the nails in 45 cases and penetration through the cartilaginous border of the femoral head in 11 cases The latter complication necessitated a nail-plate osteosynthesis in one case Ideal reduction was followed by secondary displacement of the fracture in 15 per cent (3/20) of the cases, whereas a mechanically unreliable reduction led to technical failures in 69 per cent (59/85) (Figure 2) A multivariate logistic analysis revealed a highly significant relationship between mechanically unreliable reduction and the appearance of technical failures ($P < 0\ 00005$) No significant correlation between the fracture type and technical failures was found.

Varus angulation was encountered in eight cases, three being less than 10° and five between 20° and 30° (Figure 3) Secondary fracture displacement was thus observed in a total of 62 per cent (60/97) of cases Significant technical failures occurred in 64 per cent (63/98)

Knee complaints were recorded in 59 per cent (57/97) of cases, and were due to distal slipping of the nails in 40 cases. In 27 cases re-operations were necessary

Re-operations were performed, as listed in Table 3, in 46 per cent (45/98) of patients with a total of 54 operations, because ten patients were operated upon twice and [illegible] patients three times. Nearly all operations were caused by distal slipping of the nails [illegible] knee complaints. Ideal fracture reduction [illegible] encountered in nine of the re-operated patients

DISCUSSION

It has been claimed that Ender nailing [illegible] the following advantages a low [illegible] rate, a small demand for blood transfusion [illegible] early mobilization with full weight-bearing [illegible] reduced hospitalization time and [illegible] mortality (Bohler et al 1975, Ender [illegible] Ender 1973, Ender & Simon-Weidner [illegible] Philadelphy et al 1975 Poigenfürst [illegible])

In the present series deep infections [illegible] knee region were encountered in 2 6 per [illegible] of the cases. This is in the same range [illegible] 3 5 per cent reported after McLaughlin [illegible] plate fixation, where the infections [illegible] located in the hip region (Jensen [illegible] Michaelsen 1975)

The 5 per cent postoperative mortality [illegible] after 3 weeks is not significantly [illegible] ($P > 0\ 05$, Chi-square test) than the 9 per [illegible] reported in a large overall survey of [illegible] fractures by Jensen & Tøndevold ([illegible])

A classification system based on [illegible] mechanical stability of the fracture [illegible] 1949) was applied as recommended [illegible] Jensen (1980) Only about 30 per cent of [illegible] fractures in this series were considered [illegible]



3A Three fragmentary fracture without postero-lateral support reduced with anterior diastasis iot introduced into the subchondral area




Figure 3B Distal slipping of nails resulted in secondary varus dislocation

, while Kuderna et al (1976) reported r cent and Wynn Jones et al. (1977) 85 ent. The main problem in the internal on of stable trochanteric fractures is to obtain an exact reduction This was achieved in 84 per cent and secondary displacement of the fracture and the nails occurred in 12 per cent of these cases.

Knee complaints are rather common following condylo-cephalic nailing (Bø 1979, Kapral 1976, Kuderna 1976, Wynn Jones et al 1977) In the present series 32 per cent of the patients with stable fractures suffered from knee pain, often necessitating re-operation This prevents early mobilization and prolongs hospitalization time, although most of the re-operations were nail removals. The problems involved in obtaining fracture union in stable trochanteric fractures are minor (Ender 1970) and Ender nailing is theoretically a fairly simple fixation method However, it should be emphasized that a mechanically reliable reduction together with a perfect operative technique are the prerequisites for the attainment of good results. Thus, with an improved surgical technique satisfactory results might be obtained with Ender nailing in stable trochanteric fractures

In unstable trochanteric fractures internal fixation is a much greater problem, and secondary displacement or implant failures with subsequent re-operations occur rather frequently (Jacobs et al 1976, Jensen & Michaelsen 1975, Laros & Moore 1974) In former reports on Ender nailings the number of technical failures have ranged between 12 and 28 per cent (Hult & Nilsson 1978 Kapral 1976, Kuderna et al 1976, Poigenfürst & Schnabl 1977, Wynn Jones et al 1977) and re-operations have been performed in 8–13 per cent of cases (Poigenfurst & Schnabl 1977, Wynn Jones et al 1977) Kuderna (1976) reported as many as 16 per cent nail removals due to knee complaints. In the series of Kuderna et al (1976) and Wynn Jones et al (1977) however, most of the fractures were stable

In the present series the rate of technical failures was 64 per cent The multivariate logistic analysis revealed that the probability of technical failure in both stable and unstable fractures is determined by the mechanical reliability of the fracture reduction The fracture type as such significantly influences the quality of the reduction It has been pointed out that secondary impaction of the fracture is to be expected following [illegible] nailing (Kapral 1976, Martinek et al [illegible] Persch & Birkner 1977 Poigenfürst [illegible] Schnabl 1977, Wynn Jones et al [illegible] Fracture impaction was observed in [illegible] cent of cases in the present series, [illegible] secondary varus dislocation was found in [illegible] cent This could be acceptable if the fracture impaction did not lead to distal slipping [illegible] nails and subsequent knee pain necessitating removal of the nails As a consequence [illegible] re-operations, hospitalization time is prolonged and in addition, the benefit of early weight-bearing mobilization is lost.

From the results in this series [illegible] nailing can not be recommended for internal fixation of unstable trochanteric fractures An altered technique with [illegible] dimensional bending of the nails, as [illegible] by Kuderna (1976) is not liable to [illegible] problems Persch & Birkner (1977) [illegible] sized the importance of exact reduction [illegible] the unstable 3- and 4-fragmentary fractures however, it is extremely difficult to [illegible] mechanically reliable reduction, especially [illegible] orthopaedic surgeons with limited skill [illegible] are the ones most often operating [illegible] patients in a hard working [illegible] emergency department in the Scandinavian countries.

ACKNOWLEDGEMENTS

This study was kindly supported by [illegible] Gjenforsikrings Jubilaeumsfond. [illegible] expressed to Sv Kreiner-Møller [illegible] Department for Data Processing [illegible] for statistical aid

REFERENCES

Bø O (1979) Operative [illegible] pertrochanteric fractures of the femur [illegible] of a three-year series. J Trauma 19 [illegible]

Bohler, J, Ender H G & [illegible] Erfahrungen mit der [illegible] tramedullaren Fixation [illegible] Frakturen mit elastischen [illegible] Ender Mschr Unfallheilk 78 351 [illegible]

F, Vıla, J & Beltran, J E (1973) ylo-cephalıc nail fixatıon for trochanterıc ıres of the femur *J Bone Jt Surg* 55-B, 779

(1970) Probleme beım frıschen per- und ochanteren Oberschenkelbruch *Hefte llheılk* 106, 2–11

H G (1973) Fıxatıon trochanterer Brüche Federnageln nach Ender und Sımonlner *Langenbecks Arch klın Chır* 334,

J & Sımon-Weıdner, R (1970) Dıe rung der trochanteren Brüche mıt runden, ıschen Condylennageln *Acta chır austr*)–42

J & Sımon-Weıdner, R (1974) Dıe rung der Brüche des Trochantermassıvs elastıschen Rundnageln *Akt Chır* 9, 76

E M (1949) The treatment of trochanterıc ures of the femur *J Bone Jt Surg* 31-B, -203

. & Nılsson, M H (1978) Ender-spıknıng rochantara femurfrakturer *Lakartıdn* 75, –4608

R R, Armstrong, J, Whıtaker, J H & ll, J (1976) Treatment of ıntertrochanterıc fractures wıth a compressıon hıp screw and ıl plate *J Trauma* 16, 599–603

J Steen & Mıchaelsen, M (1975) chanterıc femoral fractures treated wıth Laughlın osteosynthesıs *Acta orthop* d 46, 795–803

J Steen (1980) Classıfıcatıon of hanterıc fractures *Acta orthop scand* 51, ress

J Steen & Tøndevold E (1979) Mortalıty r hıp fractures *Acta orthop scand* 50, -167

, W (1976) Osteosynthese pertrochanterer kturen mıt Federnageln nach Ender *Akt r* 11, 371–388

ıa H (1976) Ursache und Vermeıdung Knıebeschwerden und Aussenrotatıonsstellungen nach Stabılısıerung pertroıterer Frakturen mıt Endernageln *Akt Traumatol* 6, 163–165

Kuderna, H, Bohler, N & Collon, D J (1976) Treatment of ıntertrochanterıc and subtrochanterıc fractures of the hıp by the Ender method *J Bone Jt Surg* 58-A, 604–611

Küntscher, G (1966) Zur operatıven Behandlung der pertrochanterer Frakturen *Zbl Chır* 91, 281–295

Küntscher, G (1970) A new method of treatment of pertrochanterıc fractures *Proc roy Soc Med* 63, 1120–1121

Laros, G S & Moore, J F (1974) Complıcatıons of fixatıon ın ıntertrochanterıc fractures *Clın Orthop* 101, 110–119

Martınek, H, Wıelke, B, Egkher, E, Fasol P, Passl, R & Sprängler, H (1976) Der Verhalten mıt Federnageln versorgter pertrochanterer Oberschenkelbruche unter Belastung *Arch orthop Unfall Chır* 86, 235–241

Persch, F & Bırkner, H (1977) Fehlerquellen beı Versorgung pertrochanterer Frakturen nach Ender und Sımon-Weıdner *Mschr Unfallheılk* 80, 317–321

Phıladelphy, G, Lugger, L J & Oberhammer, J (1975) Dıe Behandlung der pertrochanteren Oberschenkelbruche mıt der Kondylenrundnagelung *Z allg Med* 50, 373–375

Poıgenfürst, J (1973) Anderung der Behandlungsergebnısse beı pertrochanteren Bruchen durch Stabılısıerung mıt elastıschen Rundnägeln *Wıen med Wschr* 123, 155–160

Poıgenfürst, J & Schnabl, P (1977) Multıple ıntramedullary naılıng of pertrochanterıc fractures wıth elastıc naıls Operatıve procedure and results *Injury* 9, 102–113

Sımon-Weıdner, R (1970) Dıe Fıxıerung trochanterer Bruche mıt multıplen elastıschen Rundnageln nach Sımon-Weıdner *Hefte Unfallheılk* 106, 60–62

Wynn Jones, C, Morrıs, J, Hırschowıtz, D, Hart, G M, Shea, J & Arden, G P (1977) A comparıson of the treatment of trochanterıc fractures of the femur by ınternal fixatıon wıth a naıl plate and the Ender technıque *Injury* 9, 35–42

pondence to J Steen Jensen M D, Dept Orthop Surg T-2, Gentofte Hospıtal, DK-2900 ıp Denmark

orthop scand. 51, 827–831, 1980

TERNAL FIXATION VERSUS ENDOPROSTHESIS THE TREATMENT OF FEMORAL NECK ACTURES IN THE ELDERLY

'rospective Analysis of the Comparative Costs and Consumption of Hospital Resources

ɔ SØREIDE, ANTTI ALHO & DAVID RIETTI

artment of Surgery, University of Bergen, keland Hospital, Bergen, Norway

The consumption of hospital resources and the costs involved in treating femoral neck fractures in the elderly were studied and a comparison was made between internal fixation (von Bahr screws) and primary prosthetic replacement (Christiansen's endoprosthesis) The 1 year results of screw fixation were excellent or good in 55 per cent of the patients, fair in 17 per cent and poor in 28 per cent, compared with 79 per cent excellent or good [illegible]

and reoperations in the internal fixation group Considering the total costs, prosthetic replacement was found to be 1 6 times more expensive than internal fixation.

Key words cost analysis, femoral neck fractures, internal fixation, prosthetic replacement

Accepted 3 iii 80

two most widely accepted types of rative treatment for femoral neck fractures he elderly are internal fixation and pros- ic replacement.

ue to the increasing cost of medical care the limited resources available it is in- sting to compare the consumption of pital resources and the cost involved in two methods of treatment to ascertain the mal method of treatment from both the lical and economic viewpoints.

TIENTS AND METHODS

hundred and four patients, older than 67 's of age admitted during the period 1974–1976 for treatment of femoral neck fractures were randomly allotted to one of two treatment groups. Internal fixation was performed in 51 patients (mean age 78 years) using von Bahr screws (von Bahr et al. 1974, Sooeide et al 1979b), and replacement arthroplasty was performed in 53 patients (mean age 78 years) using a Christiansen trunnion bearing hip prosthesis (Christiansen 1969, Søreide et al. 1975).

The medical records of the patients were evaluated in March 1978 The construction of a [illegible]

consumption and costs.

For the calculation of costs, we have identified the basic costs per patient day of maintaining a standard bed in our 1050 bed hospital. In 1976 this expenditure amounted to N kr 482. The other

–6470.80/050827–05$02.50.0

Table 1 Costs of primary admission of patients with femoral neck fractures

	Costs per patient[1]			
		Internal fixation ($n=51$)		Endoprosthesis ($n=53$)
Stay in hospital		8 6		19 2
Operation		0 7		4 6
duration	0 2		0 7	
implants	0 5		3 4	
blood transfusions	0 0		0 5	
X ray examinations		0 9		1 1
Laboratory tests		0 5		1 0
Antibiotics		0 05		0 4
Other costs[2]		0 3		0 3
Total		11 05		26 6

[1]All costs are expressed using the basic costs of a hospitalization day in a regular ward as a unit (1 day = 482 Norwegian kroner in 1976).
[2]Including intensive care

categories of expenditure are given in units of this cost

Student's t test (two-tailed) has been used for the statistical analysis unless otherwise stated

RESULTS

The admission procedures and the initial treatment (tibial traction), daily nursing and the work of medical staff (except for the operative procedures), physiotherapy and secretarial work were found to be identical for the two groups These parameters were therefore excluded from further analysis

Clinical results In this series of patients (Søreide et al 1979a) internal fixation was found to be a less time-consuming operation and was followed by a shorter hospitalization time The failure rate after 1 year of follow-up was 25 per cent (13/51) (technical failures, non-union and femoral head necrosis) Primary prosthetic replacement was a more time-consuming operation and was associated with a requirement for blood transfusions, but involved fewer reoperations. The failure rate was 9 per cent (5/53) (postoperative dislocations) The mortality rates recorded 1 6 and 12 months after the operations were similar for the two groups with 9 deaths [illegible] per cent) in the internal fixation group [illegible] deaths (21 per cent) in the prosthetic [illegible] year after the operations.

Consumption of resources during the first [illegible] in hospital Prosthetic replacement [illegible] a significantly longer hospitalization [illegible] ($P<0\ 005$), as well as higher operation [illegible] including blood transfusions ($P<0$ [illegible]) [illegible] number of laboratory tests ($P<0.005$) [illegible] use of antibiotics ($P<0\ 005$) (Table 1) [illegible] total cost per patient treated was 2·4 [illegible] higher in the prosthetic group compared [illegible] the internal fixation group.

Follow up The time from operation [illegible] most recent follow-up was noted. [illegible] patients in the internal fixation group [illegible] mean follow-up period was 17 [illegible] compared with 13 months for 40 [illegible] the prosthetic group This difference [illegible] statistically significant ($P<0.005$) The [illegible] ber of outpatient visits (4 versus 2) and [illegible] number of X ray examinations (4 [illegible] were significantly higher in the [illegible] fixation group ($P<0\ 005$). Calculated [illegible] patient (Table 2) the outpatient [illegible] amounted to the cost of 1 4 hospital[illegible]

Table 2 Costs of postoperative follow-up

	Costs per patient[1]	
	Internal fixation ($n=43$)	Endoprosthesis ($n=40$)
Visits to outpatient department	0 7	0 4
X-ray examinations	0 9	0 5
Total	1 6	0 9
Average costs related to the original number of patients in the group	1 4	0 7

[1]See Table 1

in the internal fixation group and 0 7 n the prosthetic group

nissions and reoperations Fifteen its in the internal fixation group and six its in the prosthetic group required subnt admissions to the hospital because acture-related complications ($P=0\ 03$, r's test) (Table 3) Eleven patients in nternal fixation group needed further tions (nine prosthetic replacements) ared with three patients in the pros: group ($P=0\ 02$, Fisher's test) The costs of readmission were somewhat higher than the costs of the first admission, but the costs per readmitted patient were similar in the two groups. Based on the original number of patients in each treatment group, the average costs per patient remained lower in the endoprosthetic group due to the smaller number of readmissions in this group

Total costs of treatment Total costs per patient in the two groups are given in Table 4 Prosthetic replacement was found to be 1 6 times more expensive than internal fixation

Table 3 Costs of readmissions expressed as average costs per readmitted patient

	Costs per readmitted patient[1]			
	Internal fixation ($n=15$)		Endoprosthesis ($n=6$)	
Stay in hospital		15 3		16 5
Reoperation		3 6		1 8
duration	0 6		0 3	
implants, etc	2.5		0 8	
blood transfusions	0 5		0 7	
X ray examinations		0 9		0 6
Laboratory tests		0 7		1 1
Antibiotics		0 2		0 3
Other costs[2]		0 04		1 4
Total		20 74		21 7
Average costs related to the original number of patients in the group		6 1		2.5

[1]See Table 1
[2]Including intensive care

Table 4 Total costs of treatment of acute femoral neck fracture in elderly patients Costs are given per patient related to the original number of patients in each treatment group and are expressed using the basic costs of a hospitalization day in a regular ward as a unit

	Costs per patient[1]	
	Internal fixation ($n = 51$)	Endoprosthesis ($n = 53$)
Primary admission	11 05	26 6
Follow up	1 4	0 7
Readmission	6 1	2 5
Total	18 55	29 8

[1]See Table 1

DISCUSSION

Most reports on operative treatment of femoral neck fractures and on comparisons of different methods are based on analysis of medical factors only In spite of fairly high failure rates, internal fixation has been widely advocated and it has been accepted that a certain number of patients require further surgical treatment (mostly with secondary prosthetic replacement) due to complications or failures following the osteosynthesis

As an alternative method, primary prosthetic replacement has been recommended for treatment of femoral neck fractures in the elderly as the results may be more reliable (Johnson & Crothers 1975, Søreide et al 1979a) Despite the more extensive tissue trauma and the more time-consuming operation compared with internal fixation, comparable mortality rates are encountered in randomized series (Søreide et al 1979a) The results of hemiarthroplasty, however, deteriorate significantly with increasing follow-up time (Søreide et al. 1980)

In the present series, primary failures non-unions and avascular necrosis resulted in reoperations in 21 6 per cent of the patients, a figure which seems comparable with those in other reports (Johansson 1964, von Bahr et al 1974) In addition, the number of cases of avascular necrosis may be expected to increase with time (Johansson 1964, Massie 1973) In the prosthetic group [illegible] were necessary in 5 6 per cent of the [illegible] A longer follow up reveals a [illegible] quality of the results, and [illegible] which may lead to further [illegible] (Søreide et al 1980)

Generally, it may be concluded [illegible] osteosynthesis and prosthetic [illegible] acceptable methods and both seem to [illegible] satisfactory solutions to this difficult [illegible] If it is not possible on purely [illegible] premises to decide which method is [illegible] then it is obvious that economic [illegible] become more interesting Given the [illegible] resources available, they are not only [illegible] tant, but probably decisive in the [illegible] between the two treatment alternatives

We contend not only that the [illegible] of primary prosthetic replacement [illegible] with internal fixation of femoral [illegible] fractures in the elderly are only [illegible] (Søreide et al 1979a), but that this [illegible] accompanied by a substantial [illegible] costs. This is a good example of the [illegible] often met with in modern surgical [illegible] where the advantages associated [illegible] treatment may be so slight that the [illegible] expenditure may not be justified.

The present study suggests that the [illegible] most significant cost entity is the [illegible] of the initial hospitalization period [illegible] longer duration of stay in the [illegible] group reflects an increased [illegible]

operatively in this group (Søreide et al 9a) On the other hand the mortality res for the groups are equal This finding cates that we can now apply surgical pro- ıres which are more elaborate and .nsive without increasing the mortality This can however only be achieved by siderably increasing the consumption of ›urces and the costs

rimary prosthetic replacement was in this rt term study found to be a more ınitive type of treatment than internal .tion as fewer patients were readmitted to hospital However this finding and the ›ciated reduced costs for the prosthetic ıp do not compensate for the great erence in costs involved in the first stay in pital On the other hand it may be said a readmission irrespective of the direct is an additional burden on the hospital system One may contend that once itted the disutility of 19 days in hospital the prosthetic group is not more than ginally different from the disutility of 9 s for the internal fixation group Similarly follow up is less expensive for the pro- tic group This may be of potential efit to a hospital with limited resources

s already mentioned a longer follow up modify the ratio of expenditure between groups. An increasing number of cases of oral head necrosis will increase the costs nternal fixation On the other hand the ılts of prosthetic replacement also riorate Thus we may assume that the o of expenditure between the two tment groups will not be significantly ıred with increasing follow up time

The method of internal fixation used in the sent series is probably not the optimal Analysis of a method which gives a more d fixation namely hip screw fixation is in gress. With a more careful reduction cedure combined with a rigid fixation the nary failures following internal fixation could be reduced to 5 per cent (Alho et al 1980) After 1 year the fair and poor results together amounted to 18 per cent. It appears that improvements in therapy are to be expected with this line of treatment which is moreover the superior alternative from the economic point of view

REFERENCES

Alho A. Stray O & Mølster A (1980) Compression hip screw for medial fractures of the femoral neck Proc. Norw Orthop Ass. *Acta orthop scand* (In press)

Bahr V von Syk, B & Walheim G (1974) Osteosynthesis of femoral neck fractures using screws. *Acta chir scand* 140, 277–282.

Christiansen T (1969) A new hip prosthesis with trunnion bearing *Acta chir scand* 135, 43–46

Johansson S H (1964) The prognosis of femoral neck fractures with special reference to com plications and old age *Acta Soc. Med upsalien* 69, 125–160

Johnson J T H & Crothers, O (1975) Nailing versus prosthesis for femoral neck fractures. A critical review of long term results in two hundred and thirty nine consecutive private patients. *J Bone Jt Surg* 57 A 686–692.

Massie W K (1973) Treatment of femoral neck *fractures emphasizing long term follow-up* observations on aseptic necrosis. *Clin Orthop* 92, 16–62.

Søreide O Lerner A P & Thunold J (1975) Primary prosthetic replacement in acute femoral neck fractures. *Injury* 6, 286–293

Søreide O Mølster A & Raugstad T S (1979a) Internal fixation versus primary prosthetic replacement in the treatment of acute femoral neck fractures. A prospective randomized study *Brit J Surg* 66, 56–60

Søreide O Mølster A., Raugstad, T S & Olerud, S (1979b) Internal fixation of fractures of the neck of the femur using von Bahr screws and allowing immediate weight-bearing a prospective clinical study *Injury* 10, 239–244

Søreide O Mølster A. & Raugstad T S (1980) Replacement with the Christiansen endoprosthesis in acute femoral neck fractures. A 5 year follow up study *Acta orthop scand* 51, 137 144

Correspondence to Odd Søreide M D Department of Surgery University Hospital of Bergen 5016 Haukeland Sykehus, Norway

ɔrthop scand. 51, 833–839 1980

EPTIC LOOSENING OF THE)NK HIP PROSTHESIS

LS MOSSING & JES ERIN-MADSEN

ɪrtment of Orthopaedic Surgery, Frederiksborg County Hospital, Hillerød, Denmark

In a preliminary report concerning 104 Monk arthroplasties satisfactory results were found within an observation time of 1 6 years (Hansen & Rechnagel 1977) However an early tendency for aseptic loosening was recorded At a follow-up of the same patients after 5 years it was found that 17 patients, with their primary prostheses in place, had died Of the remaining 86 prostheses not less than 50 per cent had been removed because of loosening causing symptoms Furthermore at re-examination of 39 patients with 43 of the primary prostheses still *in situ* radiological and clinical evidence of progressive aseptic loosening was present

The aetiology of the loosening is discussed and it is suggested that wear of the polyethylene cap plays an important role It is concluded that the "soft top" Monk prosthesis cannot be recommended for replacement arthroplasty of the hip

Key words aseptic loosening, Monk hip prosthesis, revision arthroplasty, uncemented hip arthroplasty

Accepted 26 ii 80

ptic loosening following total hip replace-ıt is a well known complication The pros-ıc design, the operative technique and postoperative load and wear are essential ors in the aetiology In the choice of a sthesis the object is to ensure, as far as sible, that symptoms of loosening do not ɪr in the number of years the patient can ect to live after the arthroplasty

n February 1974 we started to use the nk prosthesis, which is a one-piece block sthesis. In the original design it consists of netal femoral component with the head losed in a polyethylene cup (or cap) The antages of this prosthesis are that it can inserted without the use of cement, thus ɪting the risk of infection, and that the rative procedure is the same as for the ore arthroplasty

n a previous follow-up report concerning the first 104 operations Hansen & Rechnagel (1977) found that 76 per cent of the patients had an excellent result, but after only 1 6 years eight of the prostheses had been removed because of aseptic loosening Subsequently, the incidence of loosening causing clinical symptoms severe enough to necessitate revision increased, and as a consequence the use of the Monk prosthesis was abandoned in January 1978 We have re-examined and further analysed the previously published material and discuss here the problems concerning loosening of the uncemented standard Monk prosthesis.

PATIENTS AND METHODS

The hospital records of the patients included in the previously published series (Hansen &

-6470 80 050833–07$02.50 0

Rechnagel 1977) – 104 operations in 94 patients performed from February 1974 to September 1975 – were reviewed Information about patients who had died within the period of observation was obtained from the National Register The material was divided into three groups

Group A consisted of 18 prostheses in 17 patients who had died during the period of observation Evaluation was based on notes from the outpatient records

Group B "the revision group' consisted of 43 prostheses in 38 patients who had undergone a revision operation Information regarding the indications for the revision the operative findings and the postoperative course were obtained from the hospital records

Group C "the re-examined group" consisted of 43 prostheses in 39 patients These patients with the primary prostheses *in situ* were clinically and roentgenologically examined by the authors

The clinical results of this examination were compared with the results from the follow up in 1976 (Hansen & Rechnagel 1977) using the Merle d'Aubigné scoring system (Merle d'Aubigné & Postel 1954) Comparison between the radiological changes in the revision group' and 'the re examined group" was made

In the revision group' the first postoperative X ray in the A–P projection was compared with the X ray taken just before the revision Measurement of stem tip migration, resorption of the calcar and the radiolucent zone was used as a sign of radiological loosening (see legend to Figure 1) In 'the re-examined group" the comparison was made with the X-ray from the actual re-examination

RESULTS

Table 1 shows the distribution in the groups A, B, and C at the follow up in 1979 Figures from the follow-up in 1976 (Hansen & Rechnagel 1977) are shown for comparison

Group A – Dead without revision of prosthesis

Seventeen patients with 18 prostheses had died during the observation Two patients died pulmonary embolism shortly after The other deaths were all arthroplasty

From the records it was found patients in this group had severe walking and radiological signs of further two patients had been revision operation before they died

Group B – "The revision group

By 1979, 43 of the prostheses in had been removed due to loosening dications for revision became 62 months (average 33 months) primary operation The revision meant an extra hospitalization of 33 average

In all patients the indicat pain after a period of good f patients had pain at rest but pa walking was the most common Radiologically, considerable resorptio calcar was present and thesis had tilted into varus so that the stem invaded the lateral cortex

When an exchange operation w sidered it was required that the E normal and that no local clinical infection were present

The reoperations were performe

Table 1 Monk arthroplasties at follow-up

	1976	1979
A Dead without revision of primary prosthesis	8	18
B Revision performed	8	43
C Primary prosthesis still functioning	88	43
Total	104	104



...ure 1 (a) First postoperative X ray after insertion of a standard Monk prosthesis in a 69 year old ... patient with osteoarthrosis (26 06 1974) (b) Same patient before revision operation because of ...ful aseptic loosening (09 04 1976) Measurement of stem tip migration resorption of the calcar and the ...olucent zone performed

...same posterior approach as the primary ...tion. In all cases the prostheses were ...e and easy to remove During the ...ation it could be demonstrated that ...ement took place both between the ...sthetic components and between the ...ethylene cap and the acetabulum during flexion The capsular tissue was thickened ... a large amount of proliferating granulation tissue was found in the medullary canal and in the acetabulum Biopsy of the capsular tissue was not routinely performed but when it was done it showed a histiocytic reaction with refractile particles, which were thought to be debris from wear of the polyethylene

Cultures for aerobic and anaerobic bacteria were made during the majority of the revisions. In one case *Staphylococcus albus* was



Figure 2 Removed standard Monk prosthesis showing pronounced wear after 36 months

discovered In this patient pus was evident at the operation and a Girdlestone resection arthroplasty was performed The removed prostheses all showed signs of wear on the outer surface of the polyethylene cup due to articulation in the acetabulum Figure 2 shows a very pronounced case This prosthesis was removed 3 years after insertion

Table 2 shows the type of revision procedure used In seven cases the implant was removed and the patients left with a resection arthroplasty In one case this was due to infection as mentioned above [illegible] remaining six cases a new replacement [illegible] considered to be too extensive [illegible] considering the patients' ages and presence of other debilitating diseases [illegible] these patients developed a [illegible] postoperatively in spite of negative operative cultures. In 36 cases [illegible] tion of a new prosthesis was performed [illegible] February 1978 we used a cemented [illegible] prosthesis After the department [illegible] clean air flow the Monk prosthesis [illegible] abandoned and the Muller metal-polyet[illegible] prosthesis with a ceramic head was [illegible] the revision operations.

At the reoperations special care was [illegible] during the preparation of the medullary [illegible] and whenever possible a long stem [illegible] component was used in order to avoid [illegible] the femoral shaft where the tip of the [illegible] the primary prosthesis had invaded [illegible] cortex

Postoperatively bed excercises were [illegible] on the second day, sitting was allowed [illegible] the third day and walking with [illegible] permitted from the tenth day One patient [illegible] out of bed 7 days after surgery and [illegible] his femur just below the tip of the prosthesis [illegible] The fracture healed after 8 weeks in [illegible] There has been no fatal embolism [illegible] postoperative deep infections following [illegible] reimplantations

Group C – 'The re examined group'

At follow up 43 of the primary prostheses [illegible] 39 patients were still in place. As a [illegible] quence of the re-examination the [illegible]

Table 2 Revision procedures for loose Monk arthroplasties

Resection arthroplasty (Girdlestone)	7
New cemented Monk prosthesis	15
New long stem Monk prosthesis	1
Müller's prosthesis with ceramic head	20
Total	43

advised to have a revision operation The ining patients are still satisfied with their and none of them complains of pain st The majority have only moderate pain o pain at all during daily activities. The age age at follow-up was 66 years and the l of activities must be related to this.

able 3 shows the situation before and : the primary operation according to the : of Merle d'Aubigné & Postel (1956) It is ırent that there has been some loss of tion in this the most successful group of ents during the period of observation 1 1976 to 1979 The loss of mobility nt that 50 per cent of the patients ıred help, for example, with putting on kings or tying shoe laces. The main ion for the score for walking being only meaning that the patients are dependent sticks or crutches, is that this group of ients are elderly and suffering from other ditions, especially knee arthrosis.

Table 4 shows the radiological ısurements of prosthetic migration In spite of the shorter period of observation the signs of loosening before reoperation in the revision group were significantly greater compared with the re-examined patients with their primary prostheses still *in situ* Also it is our experience that implants with minimal osteolysis and migration are clinically the best On the other hand several prostheses with marked osteolysis and calcar resorption were still asymptomatic Thus the indications for a revision cannot be established purely on radiological findings

Five patients with subcapital femoral neck fractures and 20 with femoral head necrosis following fracture were evaluated in order to see if the presence of a non-arthrotic acetabulum at the time of the primary replacement was of importance The patients were, however, equally represented in the revision group and in the re-examined group To estimate if the state of activity of the patients was of any importance we compared age and sex in the revision group and the re-examined group No difference was found

Table 3 Average points for function – pain, mobility walking – according to Merle d'Aubigné 43 primary arthroplasties in the re examined group

	Preoperative	1976	1979*
Pain	1 2	5 7	5 1
Mobility	3 3	5 5	4 6
Walking	2 3	4 3	3 7

*42 arthroplasties, in one case re-examination was not performed

le 4 Average figures for the migration of the primary prosthesis comparing first and last postoperative X rays

	No of implants	Time of observation	Stem-tip migration	Resorption of calcar	Radiolucent zone
ision up	43	32 mths	7 2 mm	11 3 mm	6 5 mm
xamined ip	43*	53 mths	4 5 mm	5 6 mm	3 1 mm

* In two patients X-rays were not available

DISCUSSION

Several recent papers have shown that both uncemented and cemented total hip replacements in some cases become loose and painful after good primary results Ring (1974) reports 3 7 per cent revisions due to loosening in his primary series In other series the frequencies are considerably higher (Lindholm & Puranen 1976) In 1042 McKee-Farrar prostheses Dandy & Theodorou (1975) found 6 6 per cent requiring revision after 2 years The low friction metal-polyethylene prostheses seem to give better results. Nolan et al (1975) found revision necessary in only 0 5 per cent after 2 years in 3204 Charnley arthroplasties Although a longer observation time will undoubtly increase the number of loosenings, as seen in *John Charnley's* long-term results (1979), we find the frequency of aseptic loosenings to be so high in the present material that we suspect the design of the Monk prosthesis to be especially unfavourable

The presence of wear products from metal or polyethylene around the prosthesis is presumed to play an important role in the aetiology of loosening The wear particles appear to cause an histiocytic reaction with formation of granulation tissue, bone necrosis and bone absorption leading to loosening In experimental hip arthroplasty in dogs Mendes et al (1974) described the tissue reaction caused by the polyethylene particles around the implant *Dahl & Mikkelsen (1976)* had poor results with the Oscobal system for hemiarthroplasties because of extensive wear of the polyethylene head Recently Wroblewski (1979) demonstrated failures where high-density polyethylene articulated against bone or cartilage He stated that there can be no justification for the use of polyethylene in direct contact with a normal or abnormal acetabulum Willert et al (1978) showed how wear products are transported away from the implant through the perivascular lymphatic spaces In their opinion excessive release of wear products will overload the transportation capacity of the reticuloendothelial system leading to an accumulation of wear particles [illegible] implant accelerating the phenomen[illegible] loosening On the other hand if [illegible] particles is low an equilibrium can [illegible]

The design of the Monk prosthes[illegible] the polyethylene cup (or cap) gre[illegible] hemisphere restricts the articu[illegible] the metal head and the cup This res[illegible] impingement of the femoral neck [illegible] socket during hip flexion of abo[illegible] degrees, after which movement tak[illegible] between the polyethylene and the

In our revised cases we cons[illegible] considerable wear on the outer surfa[illegible] polyethylene (Figure 2) The capsul[illegible] around the prosthesis was thick [illegible] which probably further restric[illegible] movement between the prosthe[illegible] ponents and accelerates the wear The implant was embedded in granulatio[illegible] and biopsies showed foreign body re[illegible] and refractile particles.

We assume that the motion in [illegible] satisfactory prostheses mainly tak[illegible] between the metal head and the poly[illegible] cup At re-examination however we [illegible] significant radiological signs of bone re[illegible] tion (Table 4) and a progressive [illegible] function (Table 3)

The original "soft top" type of Monk [illegible] thesis with minor modifications [illegible] available A 'hard top' type with [illegible] metal head pressed over the [illegible] polyethylene cup is also available. [illegible] can be inserted with or without ce[illegible] the brochure from D Howse & Co[illegible] Limited (1979) it is stated that [illegible] complete the Monk hip system [illegible] need for a "hard top" style of [illegible] accommodate osteoarthritic pa[illegible] marked roughening of the acetabul[illegible] life expectancy of longer than 5 years

In our experience the "soft top" [illegible] been very unsatisfactory In pa[illegible] osteoarthritic hips, as well as [illegible] suffering from sequelae after fem[illegible] fractures, almost 50 per cent of the pro[illegible] had to be removed within 5 years ([illegible] months) because of aseptic loosening [illegible]

ptoms. Although the debris problem oubtedly is less in the metal covered design know that especially in active patients an erosion will take place and cause blems when a metal head is articulating in acetabulum (D'Arcy & Devas 1976) Based n numerous reports, especially Charnley's 79) long-term results, we therefore conclude the conventional cement fixated low tion prosthesis offers a better alternative in treatment of osteoarthrosis of the hip

FERENCES

rnley, J (1979) *Low friction hip prosthesis Theory and practice* Springer Verlag Berlin, Heidelberg New York

J, E & Mikkelsen O A (1976) Wear of the polyethylene head of the Oscobal prosthesis. *Acta orthop scand* 47, 643–647

dy D J & Theodorou, B C. (1975) The management of local complications of the total hip replacement by the McKee-Farrar technique *J Bone Jt Surg* 57 B, 30–35

rcy, J & Devas, M (1976) Treatment of fractures of the femoral neck by replacement with the Thomsen prosthesis. *J Bone Jt Surg* 58 B 279–286

Hansen, F W & Rechnagel, K (1977) The Monk hip arthroplasty Preliminary report on the uncemented standard Monk prosthesis. *Acta orthop scand* 48, 394–399

D Howse & Company Limited (1979) Monk hip prosthesis – Range and instrumentation. Head office Beethoven Street, London W10 4LR, England

Lindholm R V & Puranen J (1976) Ring total hip replacement in osteoarthrosis. *Acta orthop scand* 47, 311–316

Mendes, D G, Walker, P S, Figarola, F & Bullough P G (1974) Total surface hip replacement in the dog *Clin. Orthop* 100, 236–264

Merle d'Aubigne, R & Postel, M (1954) Functional results of the hip arthroplasty with acrylic prosthesis *J Bone Jt Surg* 36-A, 451–461

Nolan R D, Fitzgerald, R H, Beckenbaugh, R D & Coventry, M B (1975) Complications of total hip arthroplasty treated by reoperation *J Bone Jt Surg* 57 A, 977–981

Ring, P A (1974) Total replacement of the hip joint *J Bone Jt Surg* 56-B, 44–58

Willert H G Semlitsch, M, Buchhorn, G & Kreite U (1978) Materialverschleiss und Gewebereaktion bei künstlichen Gelenken *Orthopade* 7, 62–83

Wroblewski, B M (1979) Wear of high-density polyethylene on bone and cartilage *J Bone Jt Surg* 61 B, 498–500

respondence to Niels Mossing M D, Department of Orthopaedic Surgery, Sønderborg County spital 6400 Sønderborg Denmark

orthop scand. 51, 841–844, 1980

:IGHT REDUCTION BEFORE HIP REPLACEMENT

OJKJAER LARSEN & K HARRY SØRENSEN

artment of Orthopaedic Surgery O, Odense University Hospital, Odense, Denmark

Weight reduction before surgery on obese patients has been widely recommended, but its practical possibilities have not been elucidated so far Operation for osteoarthrosis of the hip was offered to 130 obese patients on the condition that they reduced their weight to normal After a minimum observation period of 1 year the weight had returned to normal, and operation was performed, in 73 per cent Only 5 per cent gave up losing weight The weight reduction averaged 8 6 kg (1–25 kg). A weight reduction of up to 15 kg was achieved within less than a year by eating less (94 per cent) or changing the dietary habits (88 per cent), and only 3 per cent had to be admitted to hospital

Key words hip surgery, obesity, preoperative weight reduction

Accepted 26 ii 80

: operative risk and the incidence of toperative complications are considered to increased in obese persons, and pre-rative weight reduction has been ommended by Adolfson (1970), Kasper & rner (1974), and Feinstein & Habermann 77) In total hip replacement by the arnley method, moreover, weight reduction lesirable for technical reasons, as the sub-aneous tissue lateral to the greater chanter, especially in women, may be k, even up to 10 cm It is therefore icult to suture, and haematomas are apt to umulate at this site The tendency for matomas increases with the thickness of subcutis (Ponsford 1974, Sakai & istutz 1976) At the operation the chanter is displaced laterally, so that it trudes into the subcutaneous tissue rthermore, postoperative mobilization is ilitated when the patient is not obese An litional factor is that the various types of tal prostheses for the femur are dimension-in accordance with a given maximum body ight, and in some cases this alone is ficient reason for weight reduction Within the field of internal medicine it has been demonstrated several times that appreciable weight reduction can be achieved in a short time (Genuth et al 1974, Maagø & Mogensen 1970)

PATIENTS AND METHODS

The present study was carried out during the period 1st April 1975–1st April 1978 in the Department of Orthopaedic Surgery O, Odense University Hospital, Odense, Denmark. In the case of overweight patients, it was stipulated that the weight must be reduced to (height in cm less 95) kg before hip replacement This corresponds [illegible]

[illegible] dications made the operation particularly urgent. The difference between the weight at admission and that measured when the patient was first seen constituted the actual weight loss. The patients were given advice and guidance on weight reduction at the first consultation but the rest was left up to them in some cases with the support to their GP

In order to assess the results it is necessary to distinguish three groups of patients

1 6470 80 050841–04$02.50 0

Table 1 Incidence of overweight in 395 patients referred for total replacement of the hip [illegible] year period April 1975–1977 (Group A)

	Not overweight	Overweight	
Not offered operation	58 (32%)	122 (68%)	180
Offered operation	85 (40%)	130 (60%)	215
Total	143 (36%)	252 (64%)	395

Group A During the period April 1975 to April 1977, patients were selected for replacement surgery from among 411 newly referred persons with osteoarthrosis of the hip Of this number 395 had their height and weight measured The achievement of weight reduction and subsequent operation, as well as the reasons why operation was not performed, were analysed after 1 year's observation in 130 overweight patients among the 215 to whom operation was offered

Group B The time taken for the required weight reduction was recorded among the patients who underwent operation during the period April 1975–1978 All 3 years had to be included to get sufficient representation of substantial weight reduction During this period operation was performed on 350 patients, 139 of whom were overweight initially The time taken for weight reduction was recorded by the overweight patients who kept account of their weight at home at intervals of a week or two

Group C One hundred randomly chosen overweight patients were asked how they had reduced their weight, in such a way that they could answer "yes" or "no", and so the[illegible] be analysed, in percentage how many ha[illegible] given precedure

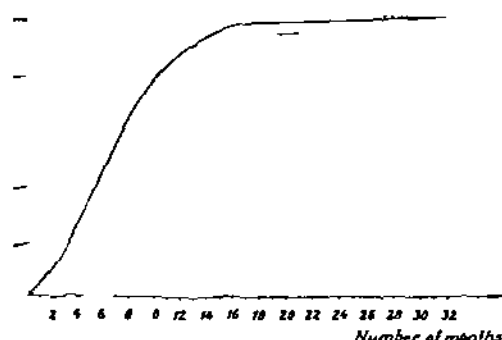
RESULTS

Group A Among the 395 patients 21[illegible] offered operation and 180 were not. Ta[illegible] gives the incidence of overweight in the[illegible] groups Among the 215 patients 60 pe[illegible] were overweight and among the 180 patien[illegible] per cent This difference is not statis[illegible] significant ($\chi^2 = 2.26$, $0.1 > P > 0.05$). Th[illegible] the body weight did not essentially [illegible] the decision to offer operation.

The achievement of weight reduction, [illegible] thereby of the operation, may be se[illegible] Table 2 Of the 130 overweight patien[illegible] whom operation was offered 73 per [illegible] operated upon after a 1 year observa[illegible] period Only 5 per cent gave up [illegible] weight

Table 2 Accomplishment of weight reduction in 130 overweight patients offered oper[illegible] period April 1975–1977 (Group A) The reasons why 35 patients had not been operated on b[illegible] 1978 are given

Waiting, weight normalized	7	[illegible]
Waiting weight not normalized	6	[illegible]
Weight reduction given up	6	[illegible]
Pain abated	6	[illegible]
Complicating disease	6	[illegible]
Operated on in another hospital	2	[illegible]
Waiting for another primary operation	2	
Total not operated	35	[illegible]
Operated	95	[illegible]
Total	130	[illegible]



ure 1 Cumulated percentage of operated patients elation to time elapsing from the first clinical ex- nation until the day of operation

However, the weight reduction sometimes ed more than 1 year A total of 3 years osed from the time that the first patients re admitted to the study Figure 1 shows w long the patients waited from the time of first consultation until operation Only 14 cent waited for more than 1 year A lack capacity made it impossible to operate on patients as soon as they had achieved the ired weight reduction The actual time en for weight reduction may be seen from ure 2 A weight loss of 15 kg or less was ieved within 1 year The greater the essary weight loss the longer the time uired. Judging by the median values, the ults obtained correspond to a mean weekly ight loss of 0 9 kg

oup B Table 3 sets out the extent of the ight loss. The majority only needed a

ble 3 Extent of weight loss among 139 marily overweight patients operated on during period April 1975–1978 (Group B) Mean weight reduction 8 6 kg

Weight loss in Kg	Number of patients	Per cent
0– 5	42	30%
5–10	48	34%
10 15	28	20%
15 20	18	13%
20 25	3	2%

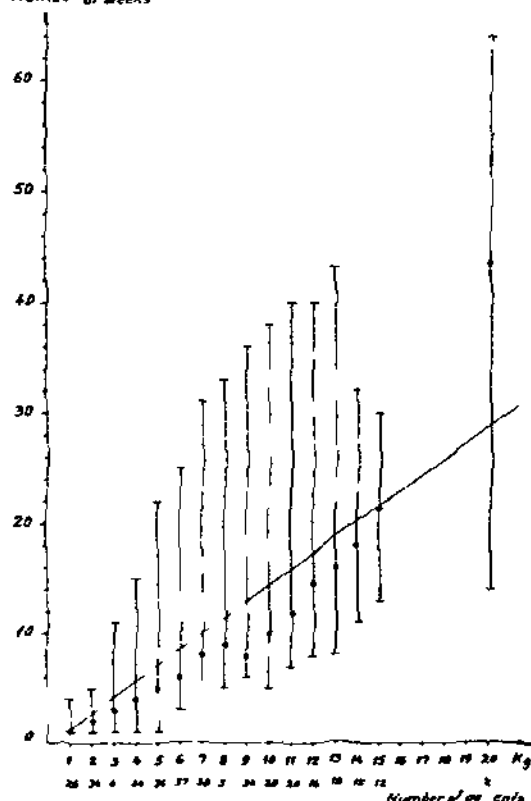


Figure 2 Number of weeks spent in reducing the weight

Table 4 Mode of weight reduction and conditions during reduction in 100 obese patients with OA of the hip (Group C)

Weight reduction achieved by	Number of patients
eating less	94
change in diet	88
checked by general practitioner	42
anoretics	11
Weight Watchers	5
exercise	10
hospitalization	3
Conditions during weight reduction	
pain abated	28
complications (depression)	15

minor reduction in weight During the 3-year period 139 patients underwent operation after weight reduction Among them 90 (64 per cent) had to lose less than 10 kg Only three patients achieved a weight loss of more than 20 kg

Group C The methods of achieving the weight loss even major weight loss were very simple (Table 4) Most patients merely ate less (94 per cent) and altered their dietary habits (88 per cent) Forty-two per cent frequently consulted their own doctor for advice and check weighing Three per cent had to be admitted to a department of internal medicine in order to lose weight

After the weight reduction 28 per cent stated that the pain had decreased and only 15 per cent had complaints in connection with their weight reduction

DISCUSSION

According to several authors the operative risk is increased in obese persons (Adolfson 1970 Strauss & Wise 1978) while others have reported that this risk is not increased or only moderately so (Andersen 1971) In the present study no attempt was made to elucidate this problem but owing to the special reasons for achieving weight reduction before hip replacement it was done to ascertain how far in practice body weight can be reduced preoperatively In at least 73 per cent of our obese patients the weight was reduced to normal.

The weight reduction was on average 0 9 kg weekly with little help from the health sector However patients with osteoarthrosis of the hip probably make up a [illegible] gratifying group Their severe [illegible] them motivated for operation and [illegible] fellow patients they learn about the [illegible] results of operation.

The long waiting times in departments [illegible] orthopaedic surgery where hip replacement [illegible] carried out can be used to [illegible] normalizing the body weight of the candidates for operation

REFERENCES

Adolfson G (1970) Fysisk traning och [illegible] tion vid operation *Svenska Läk*[illegible] 4941–4944

Andersen B (1971) *Praeoperativ* [illegible] *operativ risiko* Thesis FADL [illegible] Århus København

Feinstein P A & Habermann E T [illegible] *Selecting and preparing patients for* [illegible] *replacement* *Geriatrics* 32 91 96.

Genuth L M Castro J H & [illegible] Weight reduction in obesity by [illegible] semistarvation *J Amer Med* [illegible] 987–991

Kasper H & Zwirner R (19[illegible]) [illegible] Therapie der Adipositas bei [illegible] Patienten *Chirurg* 45, 17–20.

Maagoe H & Mogensen E F (19[illegible]) The [illegible] of treatment on obesity A follow-up [illegible] tion of a material treated with [illegible] tion *Dan Med Bull* 17, 206–209

Ponsford G D J (1974) An evaluation [illegible] efficiency of a drain placed in the [illegible] fat after low friction arthroplasty [illegible] Hip Surgery Wrightington Hospital [illegible] Publication 51 1–4

Sakai D N & Amstutz H C (19[illegible]) [illegible] of thromboembolic phenomena [illegible] 121, 108 112.

Strauss R J & Wise L (19[illegible]) Operative [illegible] obesity *Surg Gynec Obstet* 146, [illegible]

Correspondence to K Harry Sørensen M D Department of Orthopaedic Surgery Odense [illegible] 5000 Odense C Denmark

orthop scand 51, 845–851, 1980

TAL FEMUR REPLACEMENT IN SARCOMA THE DISTAL END OF THE FEMUR

ATZNELSON & J NERUBAY

Chaim Sheba Medical Center, Tel-Hashomer, Tel-Aviv University Medical School, Israel

Five patients with sarcoma of the distal end of the femur were treated by a total resection of the femur and its replacement by an endoprosthesis. This [illegible]

vincristine Surgical removal of pulmonary metastases and other local recurrences was performed where and when possible.

The functional results were excellent in four and poor in the remaining patient. All of the patients rapidly achieved physical rehabilitation and developed a stable and painless gait

This approach to the treatment of osteogenic sarcoma attempts to eliminate the primary tumor, the micrometastases and the overt metastatic disease, leaving the patient to follow as normal a life a possible, which is not the case when a high thigh amputation or a hip disarticulation is performed

Key words endoprosthesis, sarcoma, total resection of femur

Accepted 17 iii 80

ck resection of a primary bone tumor owed by a reconstructive procedure is not new method Kronecher in 1896 reported first replacement of a sarcomatous fibula an ivory stem Following this a great iety of methods have been reported for aration of resected bony regions according the skill and ingenuity of the surgeons ilson & Lance 1965, Merle D'Aubigné et 1966).

A patient with an osteogenic sarcoma has a y poor prognosis, and until 1972 survival es ranged from 5 to 20 per cent (Jaffe 58, McKenna et al 1966, Dahlin & ventry 1967, Marcove et al 1970), and this spite of most aggressive and mutilating atment procedures.

With the understanding of the phases of velopment of the primary tumor, crometastases and overt metastatic disease, and the introduction of systemic treatment by aggressive chemotherapy designed to shrink the primary tumor and treat the micrometastases, and with an aggressive approach to the metastases, major progress has been achieved in the treatment of these tumors (Jaffe et al. 1974, Carter & Friedman 1978, Frei et al. 1978)

In 1973 we performed our first total femur replacement for an osteogenic sarcoma (Katznelson & Nerubay 1976, 1977) and this paper reports our experience in five patients who were treated by femoral resection and replacement by a total femur endoprosthesis.

PATIENTS AND METHODS

Five patients with malignant tumors of the distal half of the femur were treated by total femur

31 6470 80 050845–07$02.50 0

Table 1 Clinical features of the patients

Patient	Age	Diagnosis	Time elapsing between onset of symptoms and operation	[illegible]
1	13	Osteogenic sarcoma	5 months	Biopsy of [illegible]
2	16	Osteogenic sarcoma	3 months	Biopsy [illegible]
3	17	Osteogenic sarcoma	8 months	Biopsy [illegible] Radiation
4	19	Chondro sarcoma	4 months	–
5	46	Chondromyxoid sarcoma	9 months	Two local [illegible]

replacement at the Chaim Sheba Medical Center between 1973 and 1977 Three had osteogenic sarcomata, one chondro sarcoma and one chondromyxoid sarcoma Their ages ranged from 13 to 46 years and all were males Each patient was fully investigated a physical examination, laboratory tests, standard x-rays including skeletal survey, chest radiological examination and bone scans were performed One patient with an osteogenic sarcoma was treated preoperatively at another hospital (radiation for 6 months) and the patient with chondromyxoid sarcoma underwent two local resections prior to the total femoral replacement (Table 1)

The chemotherapeutic treatment has changed over the years. Our first patient in 1973 received high doses of metatrexate with citovorum factor, vincristine and adriamycin Today the chemotherapeutic program is intraarterial adriamycin at the time of the preoperative arteriography (125 mg/day/2 days), followed 2 weeks after surgery with methotrexate (3–6 [illegible]

The endoprosthesis employed is of stainless steel having an Austin-Moore type head with a long stem to be inserted into the medullary canal of the tibia with a stabilizing platform that rests on the tibial plateau (Figure 1) The femoral stem is round at its proximal end and there are perforations to permit the reattachment of the trochanters. The tibial component of the stem is square in cross-section and tapering to its end This square shaped stem prevents rotation of the tibia about the end of the prosthesis. The length of the stem and the position of the tibial platform is determined by orthoroentgenometry

The size of the head of the prosthesis is determined by comparing the x-ray measurements of the head of the femur of the patient with standard hip [illegible] the hip of the patient on an equal level

The preparation and construction of [illegible] thesis takes 3 days.

SURGICAL TECHNIQUE

Initially a biopsy is performed, and [illegible] Smith-Petersen approach to the hip [illegible]

Figure 1 Total femur prosthesis with [illegible] Moore head, a platform for [illegible] square tibial stem



ure 2 Intraoperative picture showing the oral prosthesis in place

: skin incision is carried down laterally on the 'h with wide resection of the skin about the psy wound. A lateral arthrotomy of the knee h the incision proceeding down to the upper sis done

The first step of the resection is to approach the i joint, perform an osteotomy of the greater chanter and retract it laterally with the glutei scles, also an osteotomy of the lesser chanter is done with retraction of the psoas scle The hip capsule is then incised anteriorly l the femoral head dislocated. Arthrotomy of i knee joint is performed and all the tissues are nsversally divided, viz. the capsule, the collateral aments, the cruciate ligaments and the posterior 'sule This allows the distal femur to be raised -l by careful blunt dissection the neuro-vascular nents of the popliteal fossa are displaced steriorly and away from the femur

It this stage Hunter's canal is identified and e femoral nerve, artery and vein are ticulously dissected along their full course from upper thigh down to the popliteal fossa All the femoral perforating and the geniculate arteries with their branches are ligated The arteria profunda femoris is also divided

Then, having mobilized the neurovascular




Figure 3 Roentgenogram showing the total replacement of the femur by the prosthetic device

Figure 4 Full weight bearing on the operated limb



Figure 5 The range of abduction and

bundle the adductors are divided this then exposes the sciatic nerve in its fatty envelope and care is taken to ensure that it is not damaged

The patella is maintained and division of the quadriceps tendon performed at its upper pole The vastus lateralis is removed with the femur the fascia lata remaining behind

The stem of the prothesis is introduced into the medullary canal of the tibia and reduction of the



Figure 6 The ability to actively flex

.. of the prosthesis in the acetabulum is formed (Figure 2)

The capsule of the hip joint is repaired to give stability to the femoral head, the trochanters are fixed by wire to the holes in the prosthesis and the wound closed in layers over suction drains.

The average operation time is 3¼ hours, ranging between 3 and 4½ hours, pre- intra- and postoperative prophylactic antibiotics are given (Figure 3)

RESULTS

The postoperative period of all patients was uneventful, and after 2 weeks the patients began to walk, first with the aid of a walker and thereafter with crutches, bearing full weight on the operated limb After 6 weeks they walked with a cane and after 3 months no external support was necessary, except for a patient with chondromyxoid sarcoma who required constant external support One patient developed a peroneal palsy which recovered after 4 months

From a functional point of view, the results were excellent in four patients who achieved full weight-bearing, were free of pain and could walk for considerable distances (Figures 5 and 6) Apart from the inconvenience of a stiff straight knee they were able to return to their normal activities (Table 2)

Of these five patients three died, one 15 months following the replacement and the others after 2¼ years, their deaths were attributed to the pulmonary metastasis in spite of resection of the metastases and chemotherapy The patient with chondromyxoid sarcoma developed after 3 months a pulmonary metastasis that regressed with the chemotherapy, but he experienced severe pains in the knee region and his ability to walk decreased A disarticulation of the hip was performed and a local recurrence in the upper third of the tibia was found Our third patient with osteogenic sarcoma a year following the replacement developed pains in the knee region and x-rays showed a local recurrence in the popliteal fossa, and although an excision of the recurrence was done, the tumor recurred and a disarticulation of hip was performed

DISCUSSION

This paper presents a different approach to the treatment of malignant tumors of the distal femur, the most common location of osteogenic sarcoma, and is based initially upon chemotherapy to shrink the primary tumor, followed by a radical resection of the tumor

Table 2 Results of the total femur replacement

Patient	Diagnosis	Follow-up	Pulmonary metastasis	Complications	Functional results	Final results
1	Osteogenic sarcoma	15 months	Yes (resection)	–	Excellent	Died (15 months)
2	Osteogenic sarcoma	2¼ years	Yes (resection)	–	Excellent	Died (2¼ years)
3	Osteogenic sarcoma	2¼ years	–	Local recurrence (excised)	Excellent	Hip disarticulation
4	Chondro sarcoma	2 years	–	Peroneal palsy (recovered)	Excellent	Good
5	Chondromyxoid sarcoma	2 years	Yes (regressed with chemotherapy)	Local recurrence	Poor	Hip disarticulation Died (2¼ years)

and total femoral replacement, as opposed to the "classical" amputation

The treatment was followed by systematic chemotherapy to combat the micrometastases which were not treated in the past, and if a metastasis was discovered, in place of the old palliative approach, we pursued an aggressive course with resection of pulmonary and local metastases, thereby prolonging the survival time

Different indications and techniques have been described Ottolenghi in 1966 replaced a whole femur by another femur in a patient with Echinococcus disease Buchman (1965) made the first prosthetic replacement of the whole femur for Paget's disease Sim et al (1978) report that at the Mayo Clinic amputation remains the treatment of choice in osteogenic sarcoma but with the recent advances in adjunctive treatment greater stress has been put on radical *en bloc* resection Of 15 patients having *en bloc* resection, two developed lesions in the distal femur and had a segmental total knee arthroplasty fitted, retaining the proximal femur After 6 months the patients are alive and well Marcove & Khafagy (1974) and Marcove et al (1977) have published reports on the use of a more sophisticated prosthesis However, from the reports we note that the prosthesis with a hinged knee had very poor functional results, and only one of their 19 patients had knee flexion of 90° They required a long rehabilitation period and the use of external support We believe that patients after the resection have little or very poor motor muscle power and are incapable of controlling a mobile knee prosthesis, whereas a stable and rigid knee facilitates a quick rehabilitation, gives a stable and pain-free gait, and is more beneficial to the patient

The surgical technique is easier with our prosthesis and a long operating time and all the risks entailed are avoided, Marcove reported an average operating time of 6¾ hours for the fitting of a femur prosthesis with a hinged type knee, while our average operating time was half of this.

With our easy and speedily manufactured prosthesis, there is no waiting [illegible] surgery and the psychological [illegible] patient and his family is prevented [illegible] patient returns to his milieu within [illegible] with "his full body image" [illegible] rehabilitation is good and rapid and [illegible] psychological problems are prevented

It is too early to suggest that this [illegible] is the method of choice in the treatment [illegible] these highly malignant tumors, but as [illegible] (1978) signals "there are winds of [illegible] the initial results are good, the [illegible] preserved and the psychological [illegible] high level amputation is prevented [illegible] further experience the results should be [illegible] more promising

REFERENCES

Buchman J (1965) Total femur and [illegible] replacement with a vitallium [illegible] *Bull Hosp Jt Dis (N Y)* 26, 21 34

Carter K S & Friedman M (19[illegible]) [illegible] sarcoma treatment overview and [illegible] comments on interpretation of [illegible] data *Cancer Treatment Reports* 62, [illegible]

Dahlin D C & Coventry M B ([illegible]) Osteogenic sarcoma A study of [illegible] cases *J Bone Jt Surg* 49A, 101 112

Frei E III Jaffe N, Gero M, [illegible] Watts, H (1978) Adjuvant [illegible] osteogenic sarcoma Progress and [illegible] *J nat Cancer Inst* 60, 3–10

Jaffe H L (1958) *Tumors and [illegible] ditions of the bones and joints* [illegible] Febiger Philadelphia

Jaffe N, Frei E III Traggis D & [illegible] (1974) Adjuvant methotrexate and [illegible] factor treatment of osteogenic [illegible] *Eng J Med* 291, 994–997

Katznelson, A & Nerubay J (19[illegible]) [illegible] replacement *J Bone Jt Surg* 58-B [illegible]

Katznelson A & Nerubay J (19[illegible]) [illegible] replacement *Harefuah* 92, 3[illegible]

Kronecher (1896), cited by [illegible] Prothese en ivoire pour [illegible] substance des os These de Paris [illegible]

Marcove R C, Mike V, Hajek [illegible] A & Hutter, R V P (19[illegible]) [illegible] sarcoma under the age of [illegible] *Jt Surg* 52 A, 411–423

uvos, G A (1977) Total femur and total ıee replacement *Clin. Orthop* 126, 147–152

, E E D (1978) Osteosarcoma – the winds of ıange *S Afr med J* 53, 695–698

: D Aubigne, R, Meary, R & Thomine, J M 966) La resection dans le traitement des meurs des os *Rev Chir orthop* 52,)5–324

enna, R. J, Schawinn, Ch.P, Soong K Y & Ivinbotham N L (1966) Sarcomata of the steogenic series (osteosarcoma, fibrosarcoma,

–25

Ottolenghi, C E (1966) Massive osteoarticular bone grafts. Transplant of the whole femur *J Bone Jt Surg* 48 B, 646–659

Rosen, G, Huvos, G A, Mosende, C, Beattis, E. J, Exelby, P R., Capparos, B & Marcove, R. C (1978) Chemotherapy and thoracotomy for metastatic osteogenic sarcoma. *Cancer* 41, 841–849

Sim, F H, Ivins, J C & Pritchard, D J (1978) Surgical treatment of osteogenic sarcoma at the Mayo Clinic *Cancer Treatment Reports* 62, 205–211

Wilson, D P & Lance M E. (1965) Surgical reconstruction of the skeleton following segmental resection for bone tumors. *J Bone Jt Surg* 47-A, 1629–1656

espondence to A Katznelson, M D, Department of Orthopaedics, The Chaim Sheba Medical Center, ler School of Medicine, Tel Hashomer, Israel.

REFERENCES

Cleveland, M & Winant, E M (1950) An end-result study of the Keller operation *J Bone Jt Surg* 32-A, 163–175

DuVries, H L (1965) *Surgery of the foot*, 2nd ed pp 447–456, The C V Mosby Company, Saint Louis

Fitzgerald, J A W (1969) A review of long-term results of arthrodesis of the first metatarso-ogakabgeak hiubt, *J Bone Jt Surg* 51-B, 488–493

Swanson, A B (1972) Implant [illegible] the great toe *Clin Orthop* 85, [illegible]

Tomeno, B & Meyer, J M (19[illegible]6) [illegible] par implant en silastic de type S[illegible] raideur douloureuse du prem[illegible] *Chir orthop*, Suppl. II, 84–88

Whenger, R J J & Whalley R. C. ([illegible]) [illegible] replacement of the first meta[illegible] joint *J Bone Jt Surg* 60-B 89–92

Correspondence to Anders Mølster, M D, Department of Surgery, Section of O[illegible] Traumatology, Haukeland Hospital, Bergen, Norway

orthop. scand. 51, 857–862, 1980

OCEEDINGS OF
IE NORWEGIAN ORTHOPAEDIC ASSOCIATION

TOR ARNT JAKOBSEN

o, October 25th–27th, 1979

ECT OF INSTABILITY ON EXPERI-

ional Hospital, Bergen

o study the effect of varying stability on ture healing, a bilateral tibio-fibular osteotomy performed on nine Wistar rats weighing –350 g Intramedullary nailing was performed 1 1 4 mm stainless steel nails after reaming Co rigidity 40 kp/mm which corresponds to rigidity of an intact tibia) The nails used in right tibia had a middle part made of Ti-Ni ad covered with PVC, giving the nail a high ree of flexibility (0 3 kp/mm).

After 8 weeks, eight out of nine flexible nails fractured, the continuity being maintained by PVC tube All rats had hypertrophic callus on right side, and scanty callus on the left side re were no non unions. The strength without s was greater on the right side ($P < 0.005$) stron 1193) There was no significant difference rigidity The ratio rigidity/strength was higher the left side ($P < 0.01$)

The findings may indicate a qualitative erence in callus formation

CKED KNEE

Bakke A Melster & A Alho
gional Hospital, Bergen

n a series of 156 patients admitted with acute ension defect of the knee without fracture or tability 119 had a localized tenderness over the dial or lateral joint line, indicative of meniscal king

An arthrotomy confirmed the diagnosis in 106 cases. In two cases a rupture of the meniscus was found on the opposite side, in two there was a rupture of the anterior cruciate ligament and arthrotomy was unnecessary in four cases.

[illegible]

patients were treated expectantly Arthroscopy was performed in 26 cases in the latter part of the series.

It is concluded that locking of the knee joint with localized tenderness over the joint line and [illegible] arthroscopy is necessary to prevent a fairly high frequency of unnecessary arthrotomies.

TREATMENT OF INFECTED NON-UNION

A Alho
Regional Hospital, Bergen

The series consisted of three femoral and eight tibial infected non-unions, four of the latter with bone defect Two femoral and seven tibial cases were immobilized with Hoffmann's external osteotaxis, the others with traction. Antibiotics were given systemically and by local irrigation-suction instituted during the surgical revision In the femoral cases and in one tibial case the final osteosynthesis consisted of intramedullary nailing and cancellous bone grafting Seven tibial cases were treated with external fixation combined with anterior tibial and posterolateral tibiofibular graft When necessary the grafts were performed in two sessions, 2 to 6 weeks after the revision.

In all but one case the drainage ceased in the

1-6470 80 050857-06S02.50 0

course of 1 year from the beginning of the treatment, and 1 5 years from the time of the trauma One tibial non union ended in amputation The functional result was good in seven and satisfactory in two cases.

position some lateral flexion and ... deformity in extremely unstable spines ... observed during the turning Excessive deformation of the spinal canal was not seen. The ... support method used during the turning ... be the best one

CAN RESUSCITATION MANOEUVRES AGGRAVATE CONCOMITANT NECK INJURY ?

I A CLINICAL STUDY

Georg Blikra
Central Hospital in Akershus, Nordbyhagen

The effectiveness of establishing open airways by backward head tilt and the stable lateral position is well documented, but it has been claimed that a possible concomitant neck injury can be augmented

A retrospective study of 150 patients with [illegible]

clinically and radiologically, in only six patients was the lesion judged to be unstable for head tilt, and in only two of these had a period of apnoea or airway obstruction been present

It is concluded that the risk of aggravating a cervical spinal cord injury in an unconscious patient by backward head tilt to open the airways is very small, and when this procedure is indicated it should be performed without delay

CAN RESUSCITATION MANOEUVRES AGGRAVATE CONCOMITANT NECK INJURY ?

II AN EXPERIMENTAL STUDY

Georg Blikra, Knut Bøgseth & Nils Magnus Ulvik
Central Hospital in Akershus, Nordbyhagen

In an experimental model, artificially inflicted lesions to the neck, simulating those most commonly seen in clinical cases, were produced in autopsy cases. The cervical spines were studied radiologically, simultaneously with the performance of common first aid measures to open airways and establish a stable lateral position

In these experimentally produced unstable flexion-type injuries at the levels C4/C5, C5/C6 and C6/C7 no significant deformation of the spinal canal during backward tilt of the head could be demonstrated In establishing a stable lateral

FRACTURES OF THE UPPER END OF THE FEMUR IN OSLO AN EPIDEMIOLOGICAL STUDY

J Falch & U Slungaard
Aker Hospital, Oslo

The records for all patients admitted ... hospitals in Oslo in the year 19[illegible] with fracture proximal to the lesser trochanter ... studied

The total number was 1100 ... females ... 231 males. The age and the sex specific ... increased exponentially for both sexes ... for the oldest age group (80 years and over) ... cent for females and 1½ per cent for males ... this incidence the risk for a 30-year-old ... suffering an upper femoral fracture before ... of 80 years will be 1/6 and for a man ... Compared with other countries the ... reported is surprisingly high.

Twenty-one per cent of the females and ... cent of the males were younger than ... Among other diseases recorded were, for ... and males, respectively previous fracture ... upper end of the femur 14 and 6 per cent ... alcoholism 2 and 12 per cent, and previous ... tomy 4 and 10 per cent

CONGENITAL PSEUDARTHROSIS OF THE CLAVICLE

Rolf Hagen
Martina Hansens Hospital, Sandvika

Congenital pseudarthrosis of the clavicle ... rare malformation which almost ... involves the right side The aetiology ... but Lloyd-Roberts et al. (197[illegible]) ... that the condition is due to the pressure ... by the subclavian artery on the ... clavicle

A 7-year-old girl with this malformation ... with no history of obstetric complications ... cervical ribs or unduly elevated ... neurofibromatosis, dysostosis cleidocranialis ... other familial implications is ... underwent resection of the clavicle ...

plantation of cortico-cancellous bone from iliac crest and fixation with a Kirschner wire. right-sided non-union healed completely in 4 s.

TURES OF THE SUPRASPINATUS DON REPAIRED THROUGH A TEROSUPERIOR TRANSACROMIAL ROACH

r Dregelid
onal Hospital in Tromsø, Tromsø

ur patients with rotator cuff ruptures were ated on using a postero-superior acromial approach *ad modum* Debeyre et al. *Bone Jt Surg* 1965 47 B, 36–42). The nique was slightly modified by using a screw osteosynthesis of the acromion. In two of the nts the trapezius attachment on the spina ulae was osteotomized, and in closing the nd was sutured back by osteosutures. The roach provides sufficient access to the rotator thus making repair easy, and also permits ilization of the supraspinatus muscle in long-ding cases where retraction of the tendon is d.

E PIRIFORMIS SYNDROME

Ivig Fjeld Solheim & Per Stewers
rtina Hansens Hospital, Sandvika

he piriformis syndrome is characterized by back pain and hip pain with sciatic radiation. male patients usually complain of dyspareunia. urological signs are absent. Pain and weakness resisted abduction-external rotation of the h and tenderness over the belly of the formis muscle are typical signs.

Three women treated with section of the formis muscle were reported. The average time follow-up was 7 months. The result was rated good in one patient and as fair in one. In the d patient, who had a generalized pelvic floor algia, the operation had no effect.

MPLICATION AFTER LUMBAR MINECTOMY

ell Harbo
ntral Hospital in Rogaland, Department edics, Sandnes

A 55-year-old man was operated on because of spinal stenosis and had the lamina and the joint pedicles of the two lowest lumbar vertebrae removed. Half a year later while driving his car was hit violently from behind. Radiological examination revealed a 10 mm spondylolisthesis between L 5 and S 1. The patient was later operated on and treated by anterior fusion.

It is concluded that removal of the joint pedicles leaves the lumbar spine with reduced stability and this procedure should be omitted.

LOOSENING OF THE FEMORAL COMPONENT IN HIP ARTHROPLASTIES

A Alho, O Sørede, K. Hendsten & J Lillestøl
Regional Hospital, Bergen

Clinical and radiological data were examined for 318 patients who had received various hemiendo- and total hip prostheses. The data were classified into general, structural and loosening variables. Analysis for multiple qualitative data gave highly significant mutual correlations between medial and axial drift of the shaft, radiolucent zone between bone and cement, lateral cortical thickening resorption of the calcar and cement fracture. The lack of direct correlation between resorption of the calcar and radiolucent zone may indicate that these signs represent different aspects of loosening. Varus position of the femoral component predisposed to medial and axial drift and cement fracture.

The radiological criteria of loosening vary in clinical importance, and the need for reoperation has to be judged individually.

OSTEOARTHRITIS OF THE HIP TREATED BY INTERTROCHANTERIC OSTEOTOMY

A Reigstad & T Grønmark
Kronprinsesse Marthas Institute, Oslo

A follow-up study of 103 intertrochanteric osteotomies in patients with osteoarthritis of the hip was reported. Two-thirds were women. The mean age was 58 years half of the patients were over 60 years of age. The degree of radiographic osteoarthritis according to Kellgren & Laurence was Degree V (severe) = one-fourth, degree IV = one-half and degree III = one-fourth.

One year postoperatively 71 per cent of the patients still reported that the operation had had a good effect, and 11 per cent reported some effect. Seven years postoperatively these figures were reduced to 45 per cent and 6 per cent,

respectively At this time 24 per cent of the patients had required a total hip replacement and 7 per cent an arthrodesis of the same hip

The clinical results after osteotomy were independent of the age of the patients and of the preoperatively recorded radiographic degree of the osteoarthritis.

BIOMECHANICAL STABILITY OF FEMORAL NECK OSTEOTOMIES FIXED BY THORNTON'S SIMPLE NAIL BY McLAUGHLIN S NAIL AND PLATE, AND BY THE HIP COMPRESSION SCREW

A Reigstad & S Syversen
Ullevål Hospital Oslo

The bending and rotational stability of experimental cadaveric femoral neck osteotomies fixed by Thornton's triflanged nail McLaughlin's nail and plate and the Ullevål hip compression screw were reported The bending stability of the three tested devices was statistically equal whereas the rotational stability of the Thornton nail was lower The rotational stability, however of all three tested devices is sufficient under normal clinical circumstances. The bending stability achieved by the three devices on the other hand is insufficient to counteract the forces acting upon the femoral head *in vivo*, and is the most obvious reason for the high rate of non-union in femoral neck fractures.

CLINICAL EXPERIENCES WITH FEMORAL NECK FRACTURES TREATED BY THORNTON S NAIL CEMENTED IN METHYL METHACRYLATE

A Reigstad
Ullevål Hospital & Kronprinsesse Marthas Institute Oslo

Thirteen patients with dislocated subcapital femoral neck fractures of Garden types III and IV, and one patient with a one year old non-union of the femoral neck were treated by a cemented nail. After reduction of the fracture cancellous bone from the head the neck and from the greater trochanter was partly removed by means of a round cutting burr introduced through a small hole in the lateral trochanter area The cavity was filled up with methyl methacrylate cement using a cement syringe and a Thornton nail was then introduced through the cement

The patients were allowed [illegible] bearing postoperatively One patient [illegible] after surgery The remaining [illegible] followed up for 2 to 8 months. [illegible] no redislocations occurred and the [illegible] so far are good

CARCINOMA IN CHRONIC OSTEOMYELITIS

Ludvig Fjeld Solheim
Martina Hansens Hospital, Sandvika

A case of squamous cell carcinoma in a [illegible] old man arising in the sinus tracts of a [illegible] chronic osteomyelitis in the lower leg of [illegible] duration was reported The [illegible] uncommon and chiefly seen in middle [illegible] with fistulating chronic osteomyelitis in the [illegible] extremities. Malignant degeneration [illegible] suspected when there occurs a change [illegible] clinical pattern in cases of chronic osteomyelitis [illegible] Biopsy should include tissue from the [illegible] bone and lymph nodes. The prognosis [illegible] when early adequate amputation is perf[illegible]

Oslo, November 17th, 1979

CONGENITAL HYPOPLASIA OF THE TIBIA

Helge Fjermeros
Central Hospital in Kristiansand
Kristiansand

One case of congenital hypoplasia of the [illegible] with intrauterine fracture and [illegible] reported. At birth anterior bowing and [illegible] angulation were present The fracture [illegible] glass shaped tibia was already [illegible] bridge of newly formed bone on the [illegible] the defect The fibula was [illegible] displaced proximally

The child was operated upon at the [illegible] months From the upper fibula 3 cm was [illegible] extraperiosteally and a 4 cm long [illegible] bowed tibia diaphysis was resected [illegible] and replaced after being turned [illegible] axis and threaded on a [illegible] inserted into the tibia diaphysis [illegible] procedure).

The tibia healed after 6 weeks [illegible] the foot in a good position and [illegible] joint At 20 months of age the child [illegible] in a lively way although the leg [illegible] The prognosis seems to be good [illegible]

ıess of the leg which will require a lengthen- ·osthesis. According to Skou Andersen's and -Robert's classifications this case does not ıent a true congenital pseudarthrosis

GENITAL ANKYLOSIS OF ELBOW

· Fjermeros
-al Hospital in Kristiansand,
ıansand

ngenital ankylosis of the elbow is an mely rare condition Of the 35 cases publish- ·owever, 7 bilateral ones have been reported · Norway The condition may be encountered ·e of two groups 1) As an isolated, usually ·ral deformity 2) In association with other ·alies.

·e case, a boy, was reported who fits into the ·· category He has a left-sided humeroradial ·losis combined with a deformity of the upper ·ral epiphysis and the upper end of the ulna ·a smaller thumb than on the other side At the ·f 17 months the elbow angle was 50°, and the ·arm 5 cm shorter and the forearm 1 cm shorter ·on the other side

·e boy can easily put his left thumb into his ·th and is able to use his deformed arm and · very well In this unilateral case, therefore, · is no indication for surgery

·ATMENT OF BONE INFECTION ·TH IMPLANTATION OF ·TAMYCIN PMMA BEADS

Helland
·tral Hospital in Kristiansand
·iansand

·wo cases of infected tibial fractures were ·ted unsuccessfully for several months ·emically with cloxacillin and lincomycin ·ne to two years after the injury gentamycin ·MA beads were implanted into the tibial ·ulla in one case and into the condyles of the · in the other case In both cases the infection ·ppeared in a few weeks, the wounds closed · the fractures consolidated There were no ·s of recurrence of the infection after 1½ years.

Oslo, December 15th, 1979

VERTEBRAL HAEMANGIOMA

Sverre Skete
Central Hospital in Rogaland,
Department Sandnes, Sandnes

Haemangioma in bone is a centrally growing vascular malformation which accounts for 1 per cent of all primary osseous malformations. Radiological examination usually reveals characteristic changes but these can occasionally be atypical

A female who in 1969 underwent a radical mastectomy for cancer of the breast, had a radiological examination of her spine performed in 1973 because of back pain Changes in the third lumbar vertebra suspiciously like a metastasis were found Medication with corticosteroids and cytostatics was instituted, but her back pain increased, and so did the osseous destruction

In 1979 sciatica and bladder paralysis suddenly developed A laminectomy was performed and a haemangioma in the third lumbar vertebra was found Postoperatively the pain disappeared immediately and bladder function returned to normal

It is concluded that even though the radiological changes are characteristic of a solitary metastasis in bone, a haemangioma should be considered in the differential diagnosis

OPERATIVE TREATMENT OF NEGLECTED MONTEGGIA FRACTURES IN CHILDREN

Kjell Harbo
Central Hospital in Rogaland,
Department Sandnes, Sandnes

Three children 5, 7 and 9 years old, respectively, with neglected Monteggia fractures were operated upon 7 weeks to 6 months after injury In all cases the capitulum of the radius was reduced, and in two cases a new annular ligament was reconstructed using a lateral strip of the triceps tendon In the third case the capitulum had merely slipped out of the unruptured ligament which could be used for reconstruction In all cases the reduction was secured temporarily with the aid of a Kirschner wire inserted through the capitulum humeri into the proximal part of the radius.

The results so far are promising

ANTERIOR INTERBODY FUSION OF THE LUMBAR SPINE

Tor Steinar Raugstad
Central Hospital in Rogaland, Department
Sandnes, Sandnes

In the period 1973 to 1977, 48 patients with incapacitating low-back pain caused by disc degeneration or spondylolisthesis were treated with anterior interbody fusion by the extraperitoneal technique The mean age at operation was 38 4 years

Thirty-three of these patients (17 with disc degeneration and 16 with spondylolisthesis) were followed up an average of 48 months postoperatively Patients' own opinion 15 patients (45 per cent) had no complaints, 12 (36 per cent) were improved, 5 (15 per cent) were unchanged, and one (3 per cent) was worse

Thirty-three discs in 31 patients were examined radiologically, and in 28 (85 per cent) the fusion was solid Probable pseudarthrosis occurred in four patients operated for spondylolisthesis and in *one for disc degeneration* Out of these five patients two had no complaints, two were improved and one was worse than before operation Full working capacity was found in 25 patients (76 per cent)

PROXIMAL TIBIAL OSTEOTOMY FOR GONARTHROSIS

Arvid Høgberg
Central Hospital in Rogaland, Department
Sandnes, Sandnes

A series of 34 patients with gonarthrosis treated by proximal tibial osteotomy was presented Preoperatively 31 of the patients had a [illegible] *three a valgus deformity*

At a 2-year follow-up examination [illegible] were relieved of the pain, two were [illegible] and two were worse. Mobility was [illegible] the operation There were no serious [illegible]plications, but one patient lost the [illegible] dorsiflect the great toe, and three [illegible] minor sensibility disturbances on the [illegible] the foot

EARLY TREATMENT OF SPINAL INJURIES WITH CORD LESIONS

Oddvar Anda
Central Hospital in Rogaland, Department
Sandnes, Sandnes

Correct early treatment of cord [illegible] necessary to avoid later serious [illegible] *Pressure sore* prophylaxis by turning the [illegible] every second hour is started [illegible] physiotherapy with breathing [illegible] passive joint *movements* which [illegible]tractures and reduce spasms.

Urinary tract complications are [illegible] using an indwelling catheter the first [illegible] by *intermittent* catheterization [illegible] bladder training

Operative treatment of a spinal [illegible] necessary *in the acute phase*

orthop. scand. 51, 863–869, 1980

ITIBIOTIC CONTAINING BONE CEMENT BEADS THE TREATMENT OF DEEP MUSCLE AND ELETAL INFECTIONS

N-ÅKE HEDSTRÖM,* LARS LIDGREN,
ISTEN TÖRHOLM & ROLF ONNERFALT

artments of Infectious Diseases* and Orthopaedic Surgery, University Hospital, Lund, Sweden

Forty-eight cases of chronic osteomyelitis or bacterial arthritis operated on with eradication of infections lesions were randomly treated either by insertion of suction-irrigation drainage or by implantation of gentamicin beads. The average follow-up time was 2 years.

There was no difference in the recurrence rate between the two groups. The gentamicin treated patients were however more easily cared for as the suction-

Key words: bone cements, drainage, gentamicins, osteomyelitis

Accepted 5 v 80

ring the past decade antibiotic containing ne cements have been successfully used h as a prophylaxis against infections in erations with joint replacements (Buchholz Gartmann 1972, Gartenmann et al 1973, chholz et al 1977) and as a means of nbating an established infection in revision infected total hip arthroplasties (Buchholz al. 1977, Carlsson et al 1978) The cement s been shown to release antibiotics in such antities *in vitro* and *in vivo* that the local ncentrations exceeded the MIC values of st bacteria considered capable of causing eletal infection (Wahlig et al. 1972, Gardner Medcraft 1974, Picknell et al 1977, Wahlig Dingeldein 1978). Of the various types of ne cement now available Palacos[R] has oved to be the most effective in releasing tibiotics (Gartenmann et al. 1973, Lindberg 79).

On the basis of their experience in revisions of infected total hip arthroplasties, Voorhoeve & Stöhr (1973) treated 17 patients with chronic osteomyelitis by insertion of a gentamicin-polymethylmethacrylate plug However, during an observation period of 20 months, five recurrences occurred In order to increase the release of antibiotics, which occurs in proportion to the surface dimensions of the cement, Klemm (1976) introduced an antibiotic bone cement mixture in bead shape The separate beads were left in place in the first cases operated upon but the technique was later modified so that 30 antibiotic beads were threaded on a twisted stainless steel string which permitted easy extraction. These antibiotic beads (Septopal, Merck, West Germany) have been used principally in deep subacute or acute soft tissue and skeletal infections (Klemm 1976).

01 6470 80 060863 07$02.50/0

The aim of the present study was to compare conventional treatment using suction irrigation drainage with treatment by implantion of antibiotic bone cement beads in a series of patients with severe chronic osteomyelitis and bacterial arthritis.

MATERIAL

This study comprised 47 patients with 48 cases of chronic osteomylitis or bacterial arthritis. All of them would otherwise have been treated with radical eradication of the infected tissue and insertion of a closed suction irrigation drainage (Willenegger & Roth 1962). The indications for operation were an active secreting fistula or severe pain at rest or repeated exacerbations. The series consisted of 32 men and 15 women aged 12–80 years with a mean age of 49 years.

The infection was hematogenous in five cases and post traumatic after open fractures in six cases where no primary operations had been performed. Thirty seven were postoperative infections of which 33 had had foreign material implanted.

The average duration of the disease was 10 years range (1–64 years). In 11 patients the disease had been present for more than 10 years.

The location of the infections is shown in Figure 1. Fourteen were located in a joint, the remaining 34 in the skeleton.

In a prospective study it was decided at random whether the patients would be treated with gentamicin beads or by suction irrigation drainage. Chronic osteomylitis and bacterial arthritis were equally distributed in the two groups. All of the patients had normal kidney function before operation.

BACTERIOLOGY

The bacteriologic cultures were classified as positive only if repeated samples taken from fistulas on several occasions showed growth of the same bacteria or if more than three out of five cultures taken during operation from various sites in the operation area showed identical bacteria (Lidgen et al 1978). Deep biopsy cultures were taken from the infected tissue. If foreign material was present, the biopsies were taken from the adjacent tissue. To avoid contamination each piece of tissue was taken with a separate sterile forceps, put into a separate CO_2 tube and im-

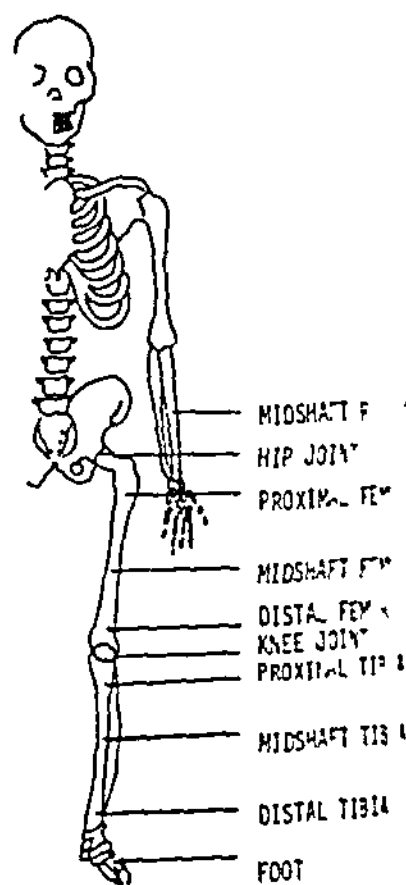


Figure 1. The localization in 48 cases of chronic osteomyelitis

mediately taken to the bacteriologic la... for both anaerobic and aerobic cu... results are shown in Table 1. The most ... bacteria found was *Staphylococcus au...*

Table 1. Results of bacteriological cultures ... cases of chronic osteomyelitis

Staphylococcus aureus
Staphylococcus epidermidis
α streptococci
β -streptococci
Streptococcus faecalis
Escherichia coli
Pseudomonas pyocyaneae
Anaerobic streptococci
Aerobic mixed infection
Anaerobic + aerobic mixed infection
Negative culture

n out of 46 positive cultures showed growth *seudomonas pyocyanea*

THODS

y-eight operations were performed on 47 nts, 23 of whom were treated with amicin beads and 25 by conventional iods. A complete eradication of the infectious n was aimed at in all cases.

l patients received systemic antibiotics after culture specimens were taken This antibiotic ment was continued for an average of 7 ths postoperatively Seven cases from each p are currently undergoing treatment

some cases the treatment deviated in ciple and will therefore be discussed further amedullary reaming was performed in 14 cases rder to revitalize and revascularize the bone ugh improvement of the endosteal circulation gren & Torholm 1980) In one case an nal fixation was carried out with a Küntscher and in one with a Zickel nail In seven cases rnal fixation according to Vidal Adrey was L In five cases of bacterial arthritis partial vectomy was performed four in the knee joint one in the hip, in the latter case resection of femoral head was also carried out. The foreign erial was usually extracted but in cases of ealed fractures the fixation was retained until fracture was healed

o evaluate the extent of devitalized tissue in-ital staining with Disulphine Blue (ICI Great ain) was used in nine cases (Klemm 1976). s also facilitated the extirpation of all granula- tissue and sequestra Disulphine Blue was n intravenously for 10 minutes in the rating theatre by the anesthesiologist 1 hour re operation The Disulphine Blue dis-eared within 2 to 3 days. No side-effects were rved

he antibiotic beads used were 7 mm in neter and had a weight of 0 2 grams. Each d contained 7 5 mg gentamicin corresponding 5 mg of gentamicin sulphate

he beads were inserted into bone as well as soft tissues. The remaining cavities were d at operation with beads, the number varying n eight (36 0 mg gentamicin base) to 540 (2430 gentamicin base). The beads were left in ation, usually with one bead outside the skin to litate removal which was done after 2 weeks ge 8–29 days) without the use of anesthetics. ree of the cases were operated on more than e and when the beads were removed a nsplantation of cancellous bone was carried out asurement of the gentamicin concentration in the serum, urine and blood was carried out in nine cases.

The average treatment time with closed

[illegible]

acetated Ringer's solution at body temperature and without antibiotic additive was heated in a blood warming vessel and circulated continually throughout the operation area.

RESULTS

All patients were re-examined on average 24 months postoperatively (range 9–39 months) Two recurrences were noted in the group with gentamicin beads. One case had had an open fistula for more than 33 years and a poor condition of the skin in the lower leg An attempt to move a skin flap was unsuccessful, the wound split open, and the fistulae recurred, however, after 9 months it was still free from the original strain of *Pseudomonas pyocyanea* The other patient had a small persistent fistula which produced a drop or two of pus daily

Four recurrences were noted in the group treated by suction-irrigation drainage Two abscesses needed incision, one after 1 month, the other after 7 months. The original bacterial strain was cultured in both cases. In another patient the pain continued and a new fistula developed after 9 months The fourth patient retained his fistula during the entire postoperative period, but the condition was painless No significant difference between the two groups was found concerning the recurrence of the infection ($P > 0.05$ [1] Chi-square test)

Some difficulty was encountered in comparing the two groups in terms of the time spent in hospital and in bed, because of other injuries and seven patients were not included in this calculation The average length of time spent in hospital in the group treated with suction-irrigation drainage was 22 days of which 5 were spent in bed The figures for the gentamicin group were 27 and 3 days, respectively



Figure 2 Gentamicin concentrations in serum, wound secretion and urine after implantation of gentamicin – polymethylmethacrylate beads (mean 140 beads, range 18–540) in nine patients with chronic osteomyelitis

Gentamicin concentrations were determined by G Kahlmeter, Department of Medical Microbiology, Lund, Sweden, using a previously described agar well diffusion technique (Kahlmeter et al 1978)

Twenty-two of the patients had unhealed fractures and chronic osteomyelitis These fractures were all healed at re-examination The gentamicin concentration in the wound secretion, blood and urine for the nine patients examined is shown in Figure 2

Case report 1


An 18-year-old girl with a closed femoral fracture and a comminuted fracture of the tibial plateau The patient was operated upon after 2 weeks with open reduction and fixation of the fracture of the tibial plateau by a screw and of the femoral fracture by a Kuntscher nail after intramedullary reaming Postoperatively the patient developed a hematoma, which was evacuated After this a severe infection developed with growth of *Staphylococcus aureus* In spite of treatment with antibiotics (cloxacillin, gentamicin lincomycin in high doses), the patient's septic condition continued On radiographic examination gas was noted in the soft tissues surrounding the femoral fracture The patient was reoperated upon and an abscess was found communicating with the fracture Preoperative cultures growth After débridement, 60 were inserted (Figure 3a). The patient treated with lincomycin parenterally rapidly After 3 weeks there was infection and the beads of which outside the skin were extracted (Figure

Case report 2

A 34-year-old man with an infected fracture after primary fixation with



Figure 3a Radiographic examination gentamicin beads inserted into the to the femoral fracture



'ure 3b The green colouring of a patient shown 1 hour after intravital staining with D sulphine Blue

'ure 4a The operating area is shown with a clearly visible white sequestrum

'ure 4b A couple of beads should be left outside the skin to facil tate extraction.

The plate had been removed after 5 months. The patient was treated with a plaster cast ... but a ...
patien...
(Figur... ... eradication of infected soft tissue and necrotic bone (Figure 4a) and subsequent insertion of 18 gentamicin beads. The fracture was stabilized with the Vidal-Adrey apparatus. Transplantation of cancellous bone was carried out 4 weeks later and the patient was allowed to gradually take weight on the affected leg The external fixation was abandoned after 3 months. The patient was given a below knee brace (Sarmiento 1970) for an additional 3 months and he was allowed full weight-bearing Eight months after the bone transplantation the fracture was united

DISCUSSION

Successful treatment with gentamicin beads in deep acute and subchronic infections of bone and soft tissue has been reported by Klemm (1976) and Jenny et al (1977) The observation period in the present study was 24 months, too short a time to judge the healing results in chronic osteomyelitis, but there was no difference in the recurrence rate between our groups. There was no decrease in the time spent in the hospital but the patients treated with gentamicin beads spent about 2 days less in bed The main advantage was that these patients were more easily cared for as the suction-irrigation drainage required constant attention and often caused difficulties (Asche 1978)

The majority of the infections in this study were caused by *Staphylococcus aureus* but in no less than 16 per cent (7/48) the responsible organism was *Pseudomonas pyocyanea* Systemic treatment with toxic preparations could be avoided and concentration determinations in nine of the patients showed no measurable levels of gentamicin in the blood This is in agreement with other reports (Wahlig et al 1972, Wahlig & Dingeldein 1978) On the other hand, an accumulation of gentamicin could admittedly occur in the kidneys, since a significant quantity of gentamicin is excreted in the urine A rapid release in vitro as well as in vivo has been shown with a certain delay in the case (Picknell et al 1977) There is reason to leave the gentamicin beads ... than about 2 weeks, considering the release of antibiotics found in this ... tion, particularly during the first ... Moreover, the extraction of the beads ... become difficult after more than 2 ... because fibrous tissue grows in between ... beads. Gentamicin is most important ... negative infections especially those ... *Pseudomonas pyocyanea* but is also effe... *Staphylococcus aureus* infections and ... effects some anaerobic bacteria in the ... concentrations which are obtained ... development of resistance against ... during treatment was noted in this ... tion There is reason however ... treatment only against the infectious ... local treatment. Experiments ... antibiotics added to bone cement ... results (Voorhoeve & Stor 1973 Lev... Picknell et al 1977, Lindberg 1979).

Temporary treatment with ... beads should thus be confined ... cases of deep gram-negative ... skeletal infections where it is ... necessary to apply general treatment ... toxic preparations. Tensionless ... skin is a prerequisite for this method ... large cavity remains, this can ... with cancellous bone or muscle

ACKNOWLEDGEMENT

This work was supported by the ... Research Council (Project no. ... 05A and Alfred Österlund ...

REFERENCES

Asche G (1968) ... Gentamycin PMMA Kugeln in der ... fixierter Osteosynthesen ... 463 468

Buchholz H W & ... Infektionsprophylaxe und ...

er schleichende tiefen Infektionen bei totalen ndoprothesen *Chirurg* 43, 446–453
aholz, H W, Engelbrecht, H, Röttger, J & iegel, A (1977) Erkentnisse nach Wechsel von ber 400 infizierten Huftendoprothesen. *Orthop Prax* 12, 1117–1120
sson, Å S., Josefsson, G & Lindberg, L. (1978) Revision with gentamicin impregnated cement or deep infections in total hip arthroplasties. *J Bone Jt Surg* 60-A, 1059–1064
dner, A. D H & Medcraft, J W (1974) Antibiotic bone-cement mixtures in prevention of infection following total joint replacement. *Lancet* ii, 891
tenmann, W, Brodhage, H & Badeira, P (1973) Nebacetin und Knochenzement. Sonderdruck aus der ortopädischen Klinik Wilhelm
[illegible]
a gentamycine dans le traitment de l infection osseuse. *Rev Chir orthop* 63, 491–500
lmeter, G., Hallberg, T & Kamme, C (1978) Gentamicin and Tobramycin in patients with various infections—concentrations in serum and urinary excretion. *J Antimicrob Chemother* 4 Suppl A) 37–45
mm, K (1976) Die Behandlung chronischer Knocheninfektionen mit Gentamycin-PMMA-Ketten und -Kugeln in Gentamycin-PMMA-
[illegible]
antibiotics in methylmethacrylate *J Bone Jt Surg* 57-B, 234–237
Lidgren, L, Kamme, C. & Lindberg, L. (1978) Anaerobic bacteria in bone and joint infections. Report at XIV World Congress of SICOT, Kyoto
Lidgren, L. & Törholm, C. (1980) Intramedullary reaming in chronic diaphysary osteomyelitis. *Clin Orthop* (In press).
Lindberg, L (1979) Infection and antibiotics in relation to bone cement *Biocompatibility of orthopaedic implants*, Vol II *Uniscience Series Biocompatibility* CRC Press. Inc. (In press).
Picknell, B, Mizen, L. & Sutherland, R (1977) Antibacterial activity of antibiotics in acrylic bone cement *J Bone Jt Surg* 59-B, 302–307
Sarmiento, A. (1970) A functional below-the-knee brace for tibial fractures. A report on its use in one hundred and thirty-five cases. *J Bone Jt Surg* 52-A, 295–311
Voorhoeve, A & Stöhr, Chr (1973) Ergebnisse bei der Behandlung der chronisch-eitrigen Osteomyelitis mit einem Palacos-Gentamycin-Gemisch *Münch med Wschr* 115, 924–930
Wahlig H & Dingeldein, E (1978) Gentamicin-polymethylmethacrylate beads Experimental and pharmacokinetic investigations. *Curr Chemother Proc* I, 1021–1023
Wahlig, H, Hameister, W & Grieben A. (1972) Uber die Freisetzung von Gentamycin aus Polymethylmethacrylat *Langenbecks Arch klin. Chir* 331 (Suppl) 169–212.
Willenegger, J & Roth, W (1962) Die antibakterielle Spuldrainage als Behandlungsprincip bei chirurgischen Infektionen *Dtsch med Wschr* 87, 1485–1492.

orrespondence to Lars Lidgren, M D, Department of Orthopaedic Surgery University Hospital, 21 85 Lund Sweden

ıorthop scand. 51, 871–879 1980

ΞE CONTACT AREA AND PRESSURE DISTRIBUTION TTERN OF THE KNEE

ʒtudy of Normal and Osteoarthrotic Knee Joints

RU FUKUBAYASHI & HISASHI KUROSAWA

ıartment of Orthopaedic Surgery, Faculty of Medicine,
versity of Tokyo, Tokyo, Japan

Seven knees were studied to determine the contact area and pressure distribu- [illegible]

without menisci, and the menisci occupied 70 per cent of the total contact area. [illegible]

intact knee and the contact pressure considerably increased. These facts imply that the menisci have load bearing and load spreading functions.

The contact areas were also measured in two osteoarthrotic knees and they were significantly larger than those in normal knees. In these arthrotic knees the menisci seemed to play a less significant role in transmission of weight than in the normal knees.

Key words contact area, knee joint, meniscus, pressure distribution

Accepted 10 v 80


nisci have often been considered worthless l meniscal tear has been an indication for mpt meniscectomy But after Fairbank's ort (Fairbank 1948) it was recognized that menisci have several important functions. ıvener & MacErloy (1941) proposed six mechanical functions of the menisci. ently Tapper & Hoover (1969), Appel 70) Johnson et al. (1974) and Kurosawa et 1976) separately reported long term follow- studies after meniscectomies. Johnson et al wed a higher incidence of degenerative cular changes in meniscectomy cases. At the ıe time he emphasized the necessity of ming the physiological and biomechanical ctions of the menisci

To clarify the function of the menisci in detail and examine the load transmitting pattern of the tibiofemoral joints in normal and osteoarthrotic knees, we performed the present experiment.

MATERIALS

Seven freshly amputated knees were used The specimens were frozen at −20°C and they were thawed gradually at room temperature when used The amputations had been performed because of vascular insufficiency in four cases, malignant tumour in two and osteomyelitis in one. Age distribution was from 41 to 80 years. Mild degenerative changes (articular surfaces were thin and markedly fibrillated) were noted in knee no. 3 and severe changes (articular surfaces of both tibia

1-6470/80/060871–09$02.50/0



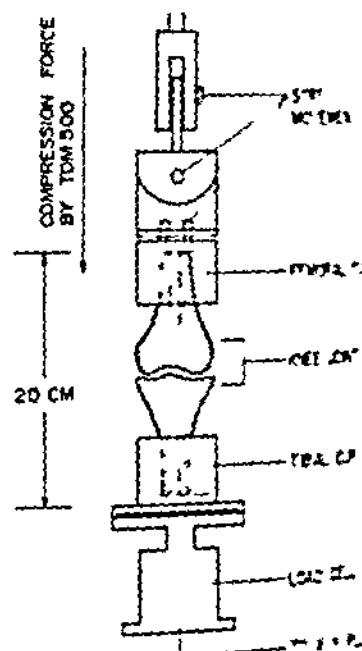


Figure 1 On the left a knee specimen fixed to the special device On the right its schematic [illegible] of three joints on this device the knee specimen can be placed in any desired position

and femur were totally eburnated) were seen in knee no 4 The others were considered to be normal.

METHODS

The specimens were cut about 10 cm above and below the joint line The patellae and muscles were removed, but the ligaments and capsules were left intact until the specimen was in place on the special fixation device (Figure 1). The device which has three linked joints can provide 0°, 30°, 60° and 90° of flexion, and the required varus-valgus angulation and rotation of the knee After reaming the femoral and tibial medullary canals, the knee specimens were fixed to the fixation device using bone cement The tibial component of the device was clamped to the load cell, and the femoral component was attached to the cross-head of an Instron type loading machine (TOM 500 made by Shinko Co., Ltd. Tokyo). In this study the knee specimens were tested at 0° flexion. The tibia stood perpendicular to the floor and physiological valgus and [illegible] femur were chosen. Once the [illegible] position was obtained, the [illegible] changed throughout the experiment [illegible] of the fixation devices had been [illegible] ligaments and capsules of the [illegible] severed The medial collateral [illegible] carefully cut at their femoral [illegible] the meniscotibial ligaments intact.


For direct measurement of pressure [illegible] patterns (knees nos. 5 6 and 7) [illegible] thin, flexible and sensitive [illegible] by Fuji Film Co., Ltd., Tokyo) [illegible] of two polyester films. With [illegible] microcapsules contained in the [illegible] dye stuffs of the capsules [illegible] with the colour-developer [illegible] a red colour to appear By [illegible] of the redness using a densitometer [illegible] the pressures could be obtained [illegible] 10 per cent.

To measure the [illegible] tibiofemoral joints, the [illegible] employed using a silicone rubber [illegible] by Bayer Co., Ltd., [illegible]







...ure 2 Castings with (left row) and without (right row) menisci. Note the obvious boundary of the ...act area and the boundary lines between the menisci and the uncovered cartilage

commonly used as dental impression material* To obtain the momentary deformation and the contact area, the stress-relaxation method was chosen as a loading procedure The specimens were loaded to the set peak load at 10 mm/min deformation rate and then the cross-head of the loading machine was stopped in order to avoid creep deformation In comparison with other loading procedures, this method was able to define a precise contact area which resembled closely the momentary contact pattern

For knees nos. 2, 3 4 5 and 7, the castings were taken before and after the removal of the menisci under loads of 200N, 500N and 1000N For knee no 1 the castings were taken only after removal of the menisci From these castings we could easily measure the contact area of the menisci and the exposed cartilage separately using section papers and a planimeter In knees nos. 5, 6 and 7 the pressure distribution patterns were also measured

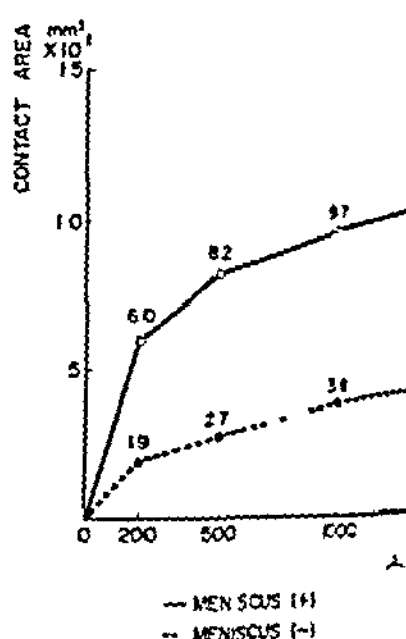


Figure 3 Contact area vs load [illegible] flexion.

RESULTS

Areas of contact

i Contact area before and after the removal of the menisci Figure 2 shows the castings before and after the removal of the menisci The contact area increased as the load increased, but the increasing curve was convex and the rate of enlargement of the contact area gradually reduced (Figure 3) So the average contact stress increased as the applied load increased Table 1 shows the mean values and standard errors of the contact areas of the normal knee joints. The contact area of the knee joint before the removal of the menisci was more than twice as large as that after the removal of the menisci When comparing the medial contact area with the lateral one, the former always occupied a larger area than the latter, but as the load increased, the difference between them gradually decreased This meant that the load distribution to the medial and tibial plateau was gradually balanced as the applied [illegible] ed

ii Contact area on the menisci and [illegible] the unloaded part of the cartilage [illegible] load was applied, areas of contact [illegible] both on the menisci and on the [illegible] part of the cartilage Figure 4 [illegible] contact area of the menisci [illegible] the total contact area in each [illegible] Under low load, the contact was [illegible] on the menisci alone (especially [illegible] compartment). Even when the [illegible] was applied, about 70 per cent of the contact area was on the menisci [illegible] said that the menisci play [illegible] in widening the tibiofemoral [illegible]

iii Contact area of the degenerated [illegible] compared with the normal knees [illegible] and 5b show the load [illegible] degenerated knees compared with [illegible] knees. The former had larger [illegible] than the latter both before and [illegible] removal of the menisci. The [illegible] degenerated knee (no. 4) had a [illegible] larger contact area than the [illegible]

*The physical properties of the material were as follows Maximum mixing time 1 min. Minimum working time 4 min Maximum permanent deformation 2 per cent This material could reproduce a line 0 025 mm wide

Table 1 Mean values and standard errors of the contact areas of normal knees

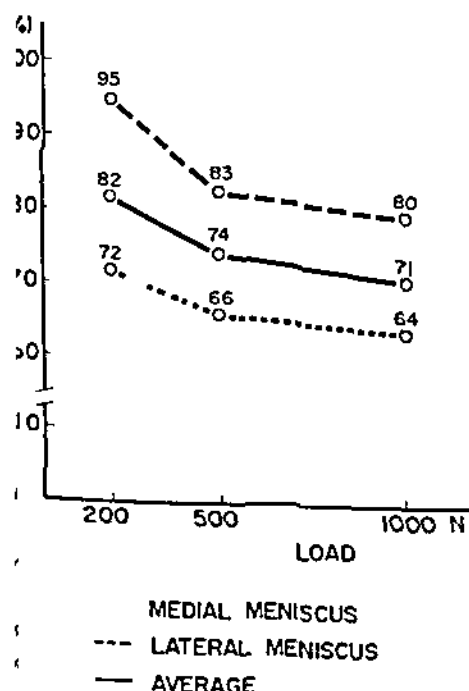
Before the Removal of Menisci

Applied load	200N		500N		1000N	
	× 10² mm²	%	× 10² mm²	%	× 10² mm²	%
Medial side	4 2±1 5	(42)	5 3±1 5	(54)	6 4±1 8	(64)
Lateral side	*2 7±0 5*	*(30)*	*4 2±0 6*	*(48)*	*5 1±0 7*	*(58)*
Total	6 9±1 5	(37)	9 6±1 7	(51)	11 5+2.0	(62)

After the Removal of Menisci

Applied load	200N		500N		1000N	
	× 10² mm²	%	× 10² mm²	%	× 10² mm²	%
Medial side	2 0±0 8	(19)	2 4±0 8	(22)	3 0±0 8	(29)
Lateral side	0 7±0 2	(7)	1 6±0 5	(17)	2.3±0 8	(24)
Total	2 5±0 9	(13)	3 8±1 1	(19)	5 2±1 3	(26)

( ) percentage of the contact area to the respective tibial articular surface



re 4 Percentage contact area of the menisci pared with the total contact area Note the ntage of the lateral side is higher than the al side

degenerative changes (no 3) The decrease in the size of the contact area after the removal of the menisci was less than that in the normal knees this was especially noticeable in the severely degenerated knee

Pressure distribution patterns

By using the special pressure sheet, we measured the pressure across the tibiofemoral joint directly Thus by using the casting method and sensor sheet method the load distribution pattern could be obtained Figure 6 depicts the patterns of knees nos 5, 6 and 7 At 1000N load the peak pressures of the medial and lateral sides of the knees were about 2–3 MPa, and at 1500N load they reached about 3–4 MPa After the removal of the menisci the pressure increased and reached about 6 MPa, though the contact areas decreased to half that of the intact knee, and the points of peak pressure were within the same area of contact In the medial compartment the high pressure areas were on the uncovered cartilage, *but in the lateral compartment* they were on the lateral meniscus as well as on the uncovered cartilage To

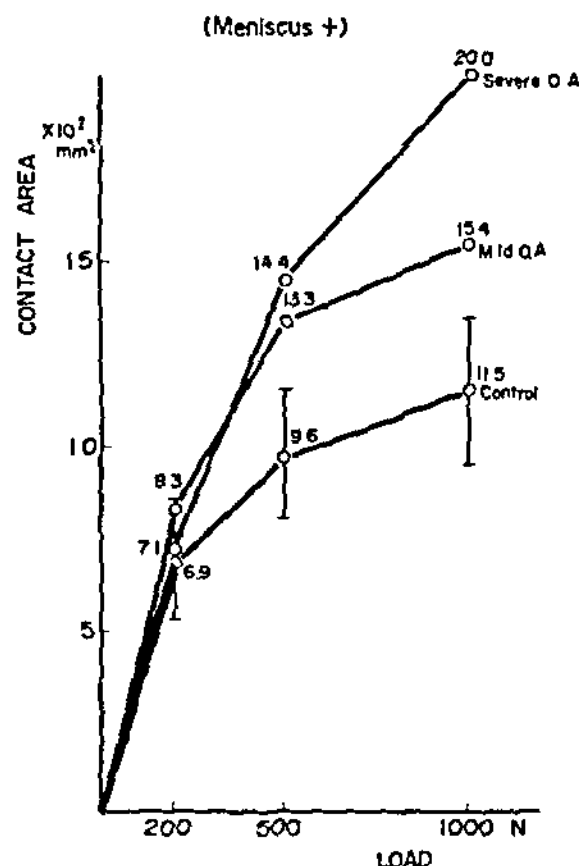


Figure 5a Contact area vs load for degenerated knees with menisci. Note the degenerated knees have larger contact areas than the normal knees

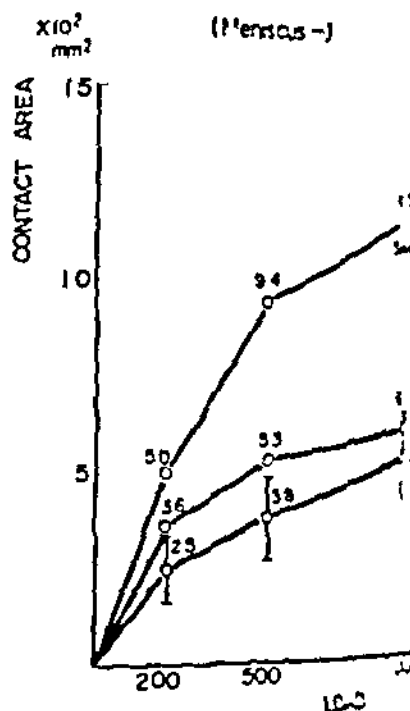


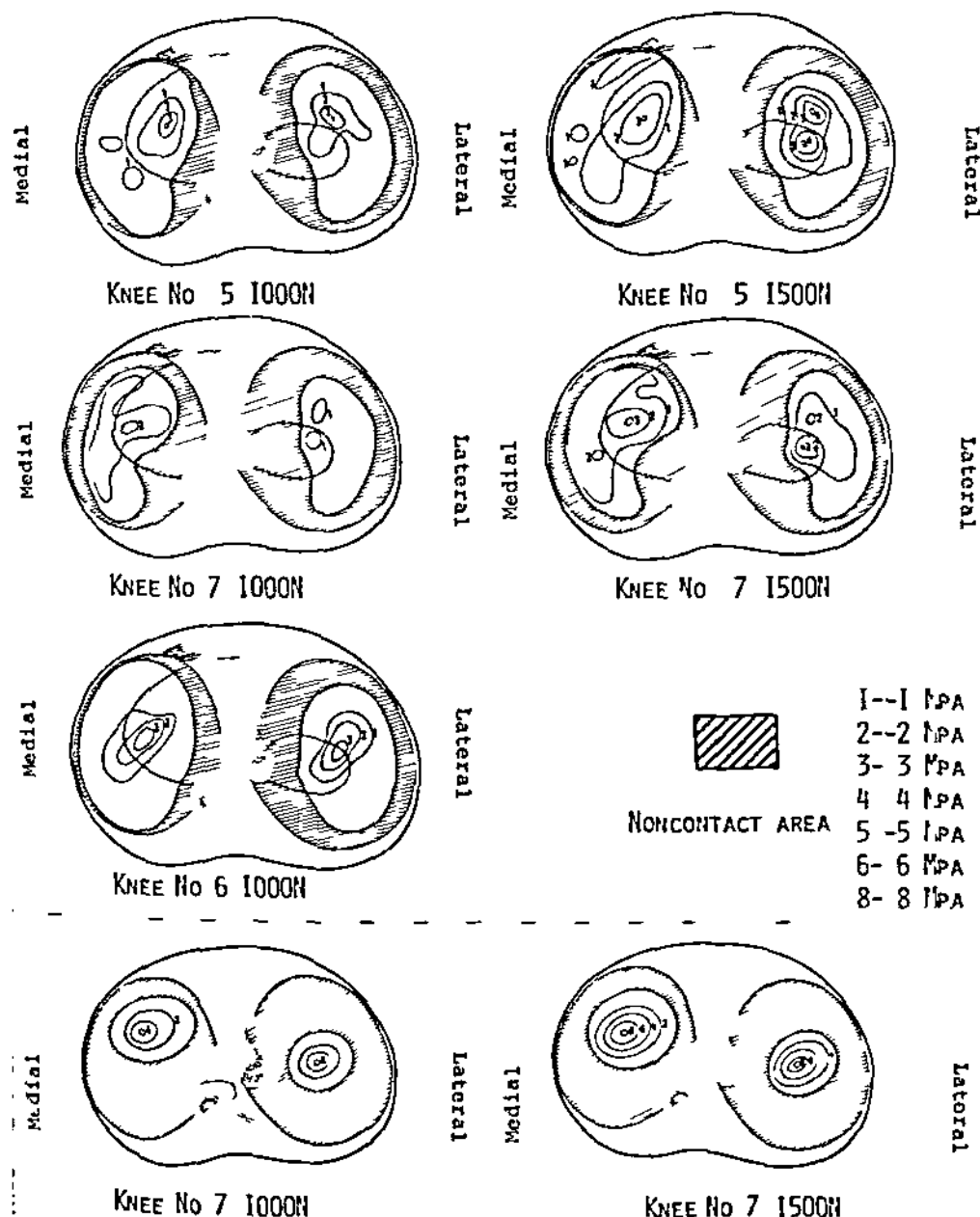
Figure 5b Contact area vs load for [illegible] knees without menisci.

examine the accuracy of these pressure distribution patterns, we integrated the pressure values and the casting areas in knees nos. 5 and 7 The difference between the actual load and the force calculated from the pressure patterns was within 20 per cent

DISCUSSION

1 *Comparison with recent papers*

There have been several reports on the contact area of the knee Kettelkamp & Jacobs (1972) demonstrated the tibiofemoral contact area under a 30–80N load by roentgenographic methods. The contact area after the removal of the menisci was 468 mm² on the medial and 297 mm² on the lateral side Maquet (1976) also showed the contract area under a load of 2500N by similar methods. In the fully extended [illegible] areas were 20 cm² with [illegible] without menisci With knee flexion [illegible] decreased, with 60° flex on the [illegible] 12 cm² with menisci and 7cm² [illegible] menisci The contact areas in [illegible] reports were rather larger than [illegible] reason for this discrepancy is probably due to the experimental methods [illegible] due to the different ethnic [illegible] specimens. We used the casting [illegible] because it is possible to obtain a [illegible] contact area compared [illegible] roentgenographic method, though [illegible] and ligaments had to be [illegible] casting material. From [illegible] Walker s reports (Walker & [illegible] Walker & Erkman 1975) [illegible] acceptable He reported that the [illegible] contact area was 1514 mm² with [illegible] 320 mm² without them at a load of [illegible] These figures, especially those [illegible] of the menisci were smaller than [illegible] was presumably due to the casting [illegible] because he used bone cement [illegible] which is greater than that of [illegible]



ure 6 Schematic views of the pressure distribution patterns at 1000N and 1500N load with and hout menisci. Note menisci undergo certain pressures especially on the lateral side

Kettelkamp et al (1972) and Walker et al. (1972, 1975) reported that the medial side had a larger contact area than the lateral but Maquet (1976) described that they were about the same In our experiment the medial contact areas were 25 per cent greater than the lateral at a load of 1000N After removal of the menisci the difference increased to 30 per cent. However, considering that the medial tibial plateau is bigger than the lateral, the percentage contact areas on the respective condylar surfaces were almost the same at higher loads.

Walker & Erkman (1975) measured the contact pressure with miniature pressure transducers at 30° flexion. They reported that the highest pressures were on the lateral meniscus and on the medial exposed cartilage close to the medial eminentia Walker's results seemed to be consistent with ours. In our cases the highest pressure concentration was on the uncovered cartilage in the medial compartment, and in the lateral compartment on the meniscus as well as on the exposed cartilage. From these results, it is obvious that the menisci, especially the lateral meniscus, carries a significant portion of the total load applied. Thus after removal of the menisci, high pressure is imposed on the small area of exposed cartilage and degenerative processes presumably commence So in cases of meniscal injury, the need for meniscectomy should be carefully assessed From our results partial as opposed to total meniscectomy is to be recommended

2. *Differences in the roles of medial and lateral menisci*

In anatomical terms there are some differences in the medial and lateral menisci. The lateral meniscus is a round-C shape compared with the medial one with a lazy-C shape. Moreover the lateral meniscus has a free periphery not attached to the capsule or tibia in its posterior half and therefore has more mobility than the medial meniscus which is fixed along its entire periphery by the meniscofemoral and [illegible] ligaments.

From the present study it was [illegible] the lateral meniscus occupied a [illegible] percentage area in the lateral [illegible] than did the medial meniscus in the [illegible] compartment and the difference is [illegible] ($P<0.01$). Accordingly it may be said [illegible] lateral meniscus contributes more to [illegible] bearing in the lateral compartment [illegible] the medial meniscus in the medial [illegible] ment In contrast the medial meniscus [illegible] more important role in joint [illegible] does the lateral meniscus [illegible] its anatomy and our results.

3 *Interrelation between degenerat[illegible] and the functions of the menisci*

This is a very interesting [illegible] the genesis and development of [illegible] of the knee. Bennett et al. (194[illegible]) [illegible] two of the earliest and most [illegible] affected areas in the knee were the [illegible] portions of the tibial plateau [illegible] Miwa et al. (1972) pathological [illegible] degenerated knees of Japanese were [illegible] most frequently at the medial and [illegible] uncovered cartilage areas, though the [illegible] of the changes was not constant. From [illegible] facts, presumably one of the functions of [illegible] menisci is to protect the cartilage [illegible] excessive pressure and degeneration [illegible] other hand, from our experiment the [illegible] areas were considerably larger [illegible] degenerated knees compared with the [illegible] ones, and the menisci, which were [illegible] worn out, still played a part in [illegible] area of contact. Widening of the [illegible] in osteoarthrotic knees is [illegible] probably due to wear at the [illegible] spur formation at the peripheral [illegible] tibial plateaus (Bennett et al. [illegible] result the average contact [illegible] smaller in osteoarthrotic knees [illegible] normal knee due to the wider [illegible] but it is not certain that this [illegible] stress attenuation in the subchondral [illegible] osteoarthrotic knees. In a case of [illegible]

rthrosis (no 4) reduction of the contact
. after removal of the menisci was
imal (Figure 5b) From this it can
bably be concluded that in arthrotic knees
menisci play a less significant role in
ismitting weight than they do in intact
es.

KNOWLEDGEMENTS

would like to thank Prof Dr Naoichi
iyama, Chairman, Department of Orthopaedic
gery, Faculty of Medicine, University of
tyo, for his helpful suggestions and encourage-
it.

Ve wish to expresss our appreciation to the
tors of the following hospitals for obtaining the
e specimens Mitsui Memorial Hospital, Asahi
io Hospital, Komagome Metropolitan Hospital,
sashino Red-Cross Hospital and the Hospital
Saitama Medical College.

FERENCES

xel, H (1970) Late results after meniscectomy in the knee joint. *Acta orthop scand*, Suppl. 133

mett, G A, Waine, H & Bauer, W (1942) Changes in the knee joint at various ages with particular reference to the nature and development of degenerative joint disease The Commonwealth Fund, The New York Academy of Medicine, 2 East 103 Street, New York, N Y

Cravener, E K. & MacErloy, D G (1941) Injuries of the internal semilunar cartilage *J Amer med Ass* **117**, 1695–1970

Fairbank, T J (1948) Knee joint changes after meniscectomy *J Bone Jt Surg* 30-B, 664–670

Johnson R J, Kettelkamp, D B, Clark, W & Leaverton, P (1974) Factors affecting late results after meniscectomy *J Bone Jt Surg* 56-A, 719–729

Kettelkamp, D B & Jacobs, A. W (1972) Tibiofemoral contact area-determination and implications. *J Bone Jt Surg* 54 B, 349–356.

Kurosawa, H (1972) Prognosis of meniscectomy Factors affecting the late result. *Orthop Surg* **27**, 825–832 (Japanese)

Maquet, P G J (1976) *Biomechanics of the knee* Springer-Verlag, Berlin Heidelberg New York

Miwa, Y, Akahori, O, Kawahara, S, Uragami, I & Ri, I (1972) Pathogenesis of the knee joint with osteoarthrosis – macroscopic changes of the joint surface of the knee. *Cent. Jap J Orthop Traumat* **15**, 681–683 (Japanese)

Tapper, E. M. & Hoover, N W (1969) Late results after meniscectomy *J Bone Jt Surg* 51-A, 517–526.

Walker, P S & Hajek, J V (1972) The load-bearing area in the knee joint *J Biomech* **5**, 581–589

Walker, P S & Erkman M. J (1975) The role of the menisci in force transmission across the knee *Clin Orthop* **106**, 184–192.

respondence to Dr Hisashi Kurosawa M.D Department of Orthopaedic Surgery, Faculty of licine, University of Tokyo, 7–3–1 Hongo, Bunkyo-ku, Tokyo 113 Japan

ıorthop scand. 51, 881–885, 1980

)MPUTED TOMOGRAPHY IN SOFT TISSUE SORDERS OF THE LOWER EXTREMITIES

ɪSTEɴ LAURSEN & SUSANNE REITER

ͻartment of Radiology and Department of Orthopaedics,
shospitalet (University Hospital of Copenhagen), Copenhagen, Denmark

Computed Tomography (CT) constitutes an important new imaging modality in the evaluation of soft tissue tumors. They are detectable by CT because their density is different from that of muscles and because they cause displacement of normal structures. CT was found to be useful in demonstrating the true extent of lesions in the soft tissue of the lower extremities of 24 patients as confirmed by examination of the surgically removed tumors. CT was also able to define the lesions' relation to and involvement with the surrounding tissue We were not able to distinguish between benign and malignant lesions by CT Generally, the specific attenuation values were not helpful in differentiation between various types of tumors. However, in cases of tumors such as lipomas, cysts and neurofibromas it may be of some use.

Key words Computed Tomography, extremities, soft tissue tumors

Accepted 18 iii.80

recent years the management of primary ılignant soft tissue tumors of the exmities has changed from mainly amputan to either *en bloc* or muscle group resecn. Proper planning of this treatment ɥuires precise knowledge of tumor location, e, margination and involvement of surɪnding structures.

The purpose of the present study was an aluation of our preliminary experience with mputed Tomography (CT) examinations of tients with soft tissue disorders of the ʌer extremities.

ɪTIENTS AND METHODS

ɔm November 1977 to October 1979 24 tients were referred at random for CT evaluon of soft tissue disorders of the lower ex mities. The material comprises 13 males and 11 nales ranging in age from 2 to 85 years with a edian age of 41

Examinations were performed with an EMI 5005 CT whole-body scanner with a scan time of 18 seconds. Slices of the suspected area, 13 mm thick, were obtained at intervals of 2 cm until the scans were similar and symmetrical to those on the normal side For this reason great care was taken to obtain a symmetrical positioning of the lower extremities in the scanner Characteristic bone marks on the two extremities should show the same cross-section.

Attenuation values of the soft tissue lesions were obtained in all cases. Contrast material was not used routinely, however, an attempt was made to differentiate between a lymphangioma and a hemangioma by infusing Urografin® into a 2-year-old boy

In four cases with a suspicion of pulmonary metastases the examination of the lower limb was supplemented by a CT of the lungs.

RESULTS

Table 1 shows the final diagnoses of the 24 patients examined by Computed Tomo-

11–6470/80/060881–05$02.50/0

Table 1 Final diagnoses of patients with lesions of the lower extremities examined by Computed Tomography

Final diagnosis	No of patients
Normal conditions	3
Benign lesions	
Cysts	3
Neurofibroma	1
Lymphangioma	1
Myositis ossificans	2
Abscess	1
Malignant lesions	
Fibrosarcoma	4
Liposarcoma	4
Ewing s sarcoma, extraosseous	2
Lymphosarcoma	1
Leiomyosarcoma	1
Rhabdomyosarcoma	1

graphy

CT scans demonstrated normal conditions in three patients Also histological examinations of surgical biopsies proved normal conditions and the initial clinical suspicion of a lesion was allayed at subsequent clinical ex amination

Cysts and neurofibromas (Figure 1) in CT scans are seen as well-defined uniform appearance and a low value which for cysts equals that (0 Hounsfield Units) and for is 35–40 Hounsfield Units. Normal have an attenuation value of 80 Hounsfield Units

Myositis ossificans and abscesses poorly delineated and had a varied ation pattern Pronounced appeared in scans from two myositis ossificans (Figure 2) in the slight calcifications often malignant soft tissue tumors. and subcutis covered lesions of nature

All patients except one with lesions were treated surgically predicted extent of the disorder confirmed The non-operated patient had abscess and was treated with antibiotics

Patients with malignant tumors had cases the diagnoses as stated histological examinations and the ext the tumors displayed by CT was



Figure 1 Distinctly outlined neurofibroma in the right thigh A rim of fat surrounds the lesion and the muscles are displaced



Figure 2 Myositis ossificans in the left first distinctly delineated with n the most pro calcifications The bone and subcut are unaffected



ure 3 Liposarcoma in the thigh of a 27-year man Attenuation value was minus 80 Hounsfield Units






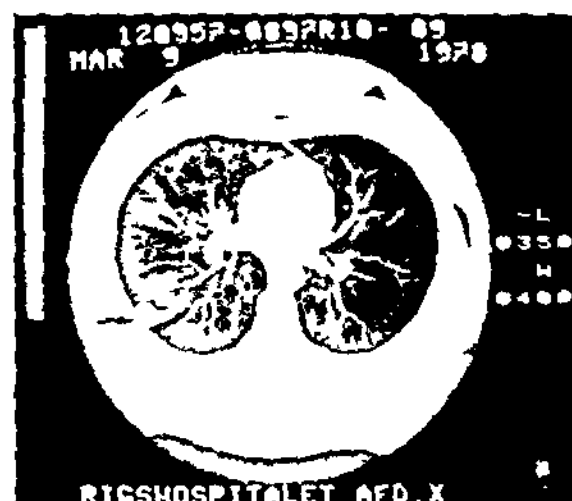
Figure 4 (a) Indistinctly delineated liposarcoma in the left femur Invasive growth into the muscles fat and subcutaneous tissue The attenuation value was positive (b) The proximal extent of the tumor The patient examined in the prone position.

ntly confirmed either after amputation or excision of the tumors from 10 patients. cal treatment was not employed in one ent with general dissemination of a phosarcoma and in another patient with asive tumor growth into the pelvic organs addition bone affection was demonstrated two cases.

The attenuation values in malignant nors varied from 18 to 45 Hounsfield Units l were not correlated with the histological gnoses. However a liposarcoma with a h proportion of fat showed an attenuation ue below zero (Figure 3) and resembled the play of lipomas with attenuation value of proximately 80 negative Hounsfield Units.

Most of the tumors were located in the gh but in two patients the tumors were und in the calf The CT examination gave portant and precise information about the ent of tumors in the proximal femur by ineating lesions in a region which is ficult to examine by other means (Figure 4).

CT examination of the lungs in two patients revealed multiple small metastases not demonstrable by conventional X ray (Figure 5 a,b)



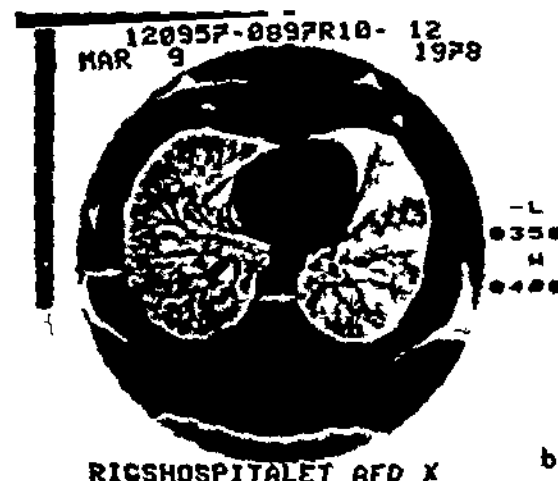


Figure 5 Lung metastases from a fibrosarcoma of the left calf in a 20-year old man. (a) Local resection of the subpleural metastasis, also seen on a conventional lung film, was planned (b) However, CT examination of the lungs revealed multiple small metastases

DISCUSSION

Computed Tomography (CT) provides an excellent means of visualizing the cross-sectional anatomy of the extremities (deSantos et al 1978, Wilson et al 1978, Hermann & Rose 1979) The soft tissue components can be compared bilaterally The muscles are outlined clearly by the surrounding fat and in most cases the major nerves and vessels can be visualized

Figure 6 Liposarcoma in the right m. gra[illegible] invasion of the tumor into the surrounding [illegible]

The present study indicates that CT [illegible] valuable examination for localizing tum[illegible] the soft tissue of the lower extremities [illegible] dimensions of the tumors in all directions [illegible] tumor involvement in the surrounding [illegible] were correctly determined and, moreove[illegible] scans showed that the tumors extended [illegible] further than indicated by clinical exa[illegible]tion

CT was a particularly useful examin[illegible] in obese patients and in patients with t[illegible] localized proximally in the femur wher[illegible] palpable and angiographic information [illegible] be equivocal CT was helpful in the de[illegible] as to whether *en bloc* resection or amput[illegible] should be performed

CT was not always able to distin[illegible] between benign and malignant le[illegible] Benign and non-aggressive malignant [illegible] might have a well-defined outline w[illegible] uniform cross-sectional appearance (Fig[illegible] However, malignant lesions were ofte[illegible] distinctly delineated and the fatty [illegible] around muscles, vessels and nerves [illegible] missing in these cases. The invasive [illegible] growth into the normal structures co[illegible]

y visualized by CT (Figure 4 a) moreover, the malignant tumors often layed a speckled appearance due to ifications, hemorrhage and necrosis. cesses may be well-defined in outline but ndistinctly outlined abscess may give the e appearance in CT as a malignant or

he attenuation value of the lesion may a hint as to the diagnosis in the case of mas, cysts and neurofibromas but an apping of the values of different lesions ricts this possibility (Hunter et al. 1979, antos et al. 1978) Moreover, tumors of same histologic type may display different nuation values. In the present study three sarcomas had positive values and a fourth egative one

ll lesions, benign as well as malignant, attenuation values lower than that of scles so that no problems were ountered in defining the lesions But iors isodense with the surrounding scles have been described (Levine et al 9) In this case infusion of contrast terial may be helpful Intravenous infusion contrast material also facilitates demonstration of the vessels (Levine et al 1979, Heelan et al. 1979)

REFERENCES

Heelan, R. T, Watson, R C. & Smith, J (1979) Computed Tomography of lower extremity tumors. *Amer J Roentgenol.* **132**, 933–937

Herman, G & Rose, J S (1979) Computed Tomography in bone and soft tissue pathology of the extremities. *J Comp Ass Tomography* **3**, 58–66

Hunter, J C Johnston, W H & Genant, H K. (1979) Computed Tomography evaluation of fatty tumors of the somatic soft tissues Clinical utility and radiologic-pathologic correlation. *Skeletal Radiol.* **4**, 79–91

Levine E., Lee, K. R, Neff, J R, Maklad, N F, Robinson, R G & Preston, D F (1979) Comparison of Computed Tomography and other imaging modalities in the evaluation of musculoskeletal tumors. *Radiology* **131**, 431–437

deSantos, L. A, Goldstein H M. Murray J A. & Wallace S (1978) Computed Tomography in the evaluation of musculoskeletal neoplasms. *Radiology* **128**, 89–94

Wilson J S., Korobkin M Genant H K. & Bovill, E G (1978) Computed Tomography of musculoskeletal disorders. *Amer J Roentgenol* **131**, 55–61

respondence to Kirsten Laursen Department of Radiology X 2023 Rigshospitalet, Blegdamsvej 9 2100 Copenhagen, Denmark

ta orthop scand. 51, 887–892, 1980

OMPUTED TOMOGRAPHY OF MUSCULOSKELETAL ISORDERS OF THE TRUNCUS

JSANNE REITER & KIRSTEN LAURSEN

partment of Diagnostic Radiology X 2023, Rigshospitalet, (University Hospital of Copenhagen), openhagen, Denmark

Computed Tomography (CT) is a new diagnostic tool in the evaluation of [illegible]

three-dimensional extent of lesions, but in about one-third of the cases the examinations were not able to distinguish between benign and malignant lesions.

Key words Computed Tomography, bones, Computed Tomography, muscles, bone neoplasma, bone infections

Accepted 25 iv 80

he remarkable advantages of Computed omography (CT) are the graphic and umerical recordings of very small differences radiation attenuation as well as the presentation of a transverse body section (Hounsfield 1973, Schumacher *et al* 1978) he specific X-ray attenuation values obtainable by CT make it, in comparison with onventional roentgenology, a far more pecific and precise method of establishing e presence of calcium, fluid or fat (Hunter al. 1979).

Preoperative evaluation by this technique elps to establish the feasibility of surgical cision and the proper surgical approach especially for lesions in and around the axial keleton and pelvis. If surgery cannot be erformed CT is useful in the planning of diation therapy The purpose of the present udy is to evaluate the value of CT scanning disorders of the musculoskeletal tissues in e body

PATIENTS AND METHODS

The examinations were performed with an EMI 5005 CT whole-body scanner with a scan time of 18 seconds. Slices of the suspected area, 13 mm thick, were obtained at intervals of 2 cm.

Forty-four examinations were performed in 29 patients with known or suspected tumours of the axial skeleton and pelvis during a 2-year period The patients included 11 males and 18 females ranging in age from 1 to 76 years with a median age of 31 Attenuation values of the soft tissue lesions were measured in all cases. In two cases with a primary malignant tumour of the pelvis, the lungs were also scanned in order to look for metastases Intravenous contrast material was used in three patients only In 25 cases the diagnosis was verified either by operation or biopsy

RESULTS

Table 1 shows the final diagnosis in 29 patients with musculoskeletal disorders of

01-6470/80/060887-06$02.50/0

Table 1 Final diagnosis in patients with musculoskeletal lesions of the body examined by CT

Diagnosis	No of patients
Infectious disorders	8
Benign tumours	
Neurofibroma	2
Osteoid osteoma	1
Chondroma	1
Malignant tumours	
Sarcomas	5
Swannoma	2
Clear cell carcinoma	1
Myelomatosis	1
Metastases	8
Total	29

the truncus examined with Computed Tomography

Infections

Three patients suffered from tuberculous spondylitis (Figure 1) CT of the affected bone displayed a characteristic lytic defect of the bone surrounded by a sclerotic zone The lesions extended into the soft tissue as large, well-delineated processes with scattered




Figure 1 Tuberculous abscess in the lumbar spine with bone destruction and a well defined soft tissue component containing calcifications

Figure 2 A well defined lumbar paras ... with bone affection Non specific infection

calcifications Two of these patients ... gravitation abscesses

In three cases with non-specific osseo... fections, central defects surrounded ... sclerotic zones were also seen but ... calcifications were found in the soft ... component of these infections (Fi... Two patients with abscesses had ... of bone Examination of biopsy ... confirmed the infectious disorders.

Sequential examinations by CT ... performed in two patients to estimate ... effect of antibiotic treatment In one ... with spondylitis the soft tissue involve... was seen to diminish in the course of the ... aminations In a case of tuberculous ab... the lack of effect could be seen in contr... tion to the clinical view

Benign tumours

Neurofibromas showed a uniform c... sectional appearance with a well-defin... outline The attenuation values were ... Hounsfield Units CT displayed erosion o... pedicle in one patient with the neurofi... near the spine (Figure 3a and b).

An osteoid osteoma was found near ... sacroiliac joint in a 12 year-old girl ... persistent pain Slight sclerotic alteration...



e 3 a) A paraspinal mass near the right y is seen It can not be distinguished from idney b) After i v contrast enhancement of idney the mass – a neurofibroma – can be guished

by conventional X ray but CT revealed a cteristic well-delineated sclerotic lesion a small rarefied central nidus (Figure 4) chondroma was located in a thoracic bra The lesion was difficult to classify examination of the surgically removed men led to the diagnosis.

gnant tumours

le material includes 17 patients with gnant diseases. Eight of these patients referred because conventional X ray had



Figure 4 An osteoid osteoma of the sacrum showing sclerosing with central rarefication

shown solitary osteolytic tumours in the skeleton Histological examinations of biopsy material disclosed that these lesions were metastases from distant primary tumours located in the prostate gland kidneys or the GI tract The CT examination showed expansive destruction of the bone with involvement of surrounding soft tissue where disperse calcifications were seen These lesions were poorly delineated (Figure 5) and in two patients invasive growth into the subcutis and the cutis was seen

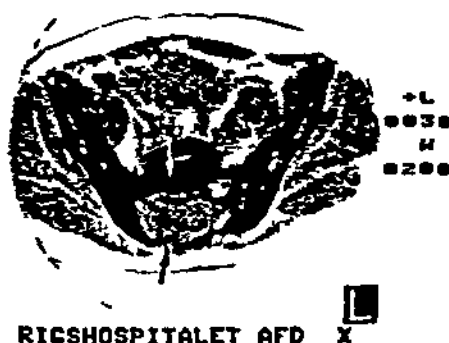


Figure 5 Large soft tissue/osseous metastases to the sacrum not visible on conventional films

The lesions due to myelomatosis displayed *an appearance very similar to that of* metastases

The primary malignant tumours were seen in four of the five patients with sarcomas as indistinct bone destructions with lytic and sclerotic areas and large but poorly defined soft tissue involvement

In the other five patients the malignant tumours were visualized as well-delineated homogeneous lesions in the soft tissue In this group of patients the CT examination in two cases was supplemented by CT of the lungs revealing multiple small metastases in one case

Surgical extirpation of the tumours was only indicated in three cases with benign tumours and in five cases with malignant tumours The extent of the tumours predicted by CT was confirmed in all these cases.

In about half the cases CT contributed definitely to the diagnosis, either by revealing *lesions not suspected clinically (four cases)* or by showing unsuspected extension of tumours and infections. In 25 per cent of the cases CT findings changed the therapy CT was not misleading in any case

DISCUSSION

The material comprises patients with a variety of disorders in the axial musculoskeletal system Most patients were referred for CT scanning in the hope of obtaining more information about suspected lesions or the extent of known lesions A few patients were referred for CT examination in order to gain experience with the CT-scanner in this field of pathology

Because of considerable overlapping it was not possible to differentiate the various lesions on the basis of attenuation values.

CT was not able to *differentiate between* benign and malignant tumours in all cases in accordance with the findings of deSantos et al (1978) Some malignant tumours were well-defined and showed a homogeneous



Figure 6 A malignant Swannoma in the psoas muscle A well defined tumour ... osseous affection.

cross-sectional appearance very simil... that of benign tumours (Figure 6). More... the expansive growth of a benign tumo... the soft tissue could erode the adjacent b... resembling invasive tumour gro... Infections of the musculoskeletal system ... not show any definite characteristics ... but could *mimic* a tumour

However, certain characteristics ... found to give a hint of the correct diag... In the cases of osseous involvement, be... tumours and infections showed a lytic de... surrounded by a sclerotic zone ... malignant tumours displayed p... delineated bone destructions often ... extensive than expected from the ... ventional X-ray The same poor demarca... of the soft tissue component was seen ... aggressive malignant tumours, well-delineated processes could be ... well as malignant

Where surgery was performed ... to the CT examination the predicted ... of the lesions was confirmed. This ... accordance with the findings of Wilson et ... (1978).

In the pelvic and in the paraspinal are... soft tissue lesions were demonstrable by C... (Figure 7) while conventional methods d...

ure 7 Liposarcoma of the pelvis with destruc- of the left iliac bone The extensive intra- and apelvic soft tissue component was larger than ically suspected

ed or gave insufficient information as also ed by Levine et al. (1979) The precise in- nation concerning the size of the tumours the surrounding tissue is of great value the further management of the patient ula et al. (1979) found that CT com- mented the clinical and routine iographic diagnosis in 25 out of 26 tumours of the osseous pelvis studied by CT. Surgery and radiation therapy planning can be optimized (Figure 8) Moreover, with CT reproduction of the cross-sectional cuts is easy and tomography can thus serve as a parameter for medical or radiation therapy by comparing sequential examinations.

CT examinations are non-invasive in most cases. Intravenous contrast injections have been used in a few patients to improve the visualization of major vessels or the urinary organs related to a tumour In tumours isodense with the surrounding tissue, i.v injection of contrast facilitated the detection of a tumour (Figure 3b) In cases of soft tissue tumours and infectious disorders i v control should be used more consequently

In conclusion, CT is an easy and effective method of displaying the full three-dimensional extent of musculoskeletal disorders of the body Only in a few cases was the CT examination *per se* able to establish the diagnosis

F 150262-2419T15- 26 E
SEP 13 1977



RIGSHOSPITALET AFD X

ure 8 Ewing's sarcoma of the right iliac bone a patient with only one kidney In planning the iation field it was important to visualize the ition to the kidney

ACKNOWLEDGEMENT

We are grateful to the Orthopaedic Department and the other clinical departments at Rigshospitalet for their cooperation.

REFERENCES

Gilula L. A, Murphy, W A, Tailor, Ch C & Patel R B (1979) Computed Tomography of the osseous pelvis. *Radiology* 132, 107–114

Hounsfield, G N (1973) Computerized transverse axial scanning (tomography), part 1 Description of system *Brit J Radiol.* 46, 1016–1022.

Hunter, J C. Johnston, W H & Genant, H K. (1979) Computed Tomography evaluation of fatty tumors of the somatic soft tissues [illegible]

[illegible] Comparison of Computed Tomography and other imaging modalities in the evaluation of musculoskeletal tumors. *Radiology* 131, 431–437

deSantos, L. A., Goldstein, H M., Murray, J A.

& Wallace, S (1978) Computed Tomography in the evaluation of musculoskeletal neoplasms. *Radiology* 128, 89–94
Schumacher, T. M., Genant, H K., Korobkin, M & Bovill, E G (1978) Computed Tomography *J Bone Jt Surg* 60-A, 600–607
Wilson, J S, Korobkin, M., Genant, H. Bovill, E G (1978) Computed Tomogr musculoskeletal disorders. *Am Roentgenol* 131, 55–61

Correspondence to Susanne Reiter, Department of Radiology X 2023, Rigshospitalet Blegdams DK 2100 Copenhagen, Denmark.

ta orthop scand. 51, 893–897, 1980

IE EFFECT OF JOINT POSITION ON XTA-ARTICULAR BONE MARROW PRESSURE

lation to Intra-articular Pressure and Joint Effusion – Experimental Study on Horses

C ARNOLDI* I REIMANN,* S MORTENSEN,** S B CHRISTENSEN,* KRISTOFFERSEN*** H V SØNNICHSEN*** & M SMITH***

partments of Orthopaedic Surgery* and Surgery D**, Rigshospitalet and the Royal terinary and Agricultural University, Surgical Institute***, Copenhagen, Denmark

Six metacarpo-phalangeal joints of adult horses were studied Pressure measurements were made in the joint and the metacarpal bone with simultaneous measurement of the systemic arterial blood pressure Investigations performed to study the effect of joint position on juxta-articular bone marrow pressure showed that an increase in joint flexion was always followed by a rise in intraosseous pressure with a significant increase at flexion above 60 degrees. Increase in intra articular pressure which was achieved by injection of saline was always followed by a slower rise in intraosseous pressure Furthermore, it was shown that even a few millilitres of saline in the joint caused a rise in intra articular pressure

The findings indicate that changes in joint position as well as effusion may block the drainage vessels from the bone marrow as they pass through the joint.

Key words intra-articular pressure, intraosseous pressure, joint effusion

Accepted 17 i 80

int effusion as seen in various types of novitis is accompanied by a rise in intra-ticular pressure (Eyring & Murray 1964) It s been shown in patients with rheumatoid thritis of the knee joint that the intra-ticular pressure in the presence of joint usion is least in the mildly flexed position d that further flexion produces extremely gh intra-articular pressure (Favreau & aurin 1963, Eyring & Murray 1964, Jayson Dixon 1970)

Recently, it has been shown (Arnoldi et al 1979) that increasing intra-articular pressure—induced by injection of saline into the knee joints of rabbits – was followed by a rise in the juxta-articular bone marrow pressure of the femoral condyle These findings indicate that changes in the joint position may influence intraosseous pressure, however, no attempt has so far been made to assess the correlation between joint position and intraosseous pressure

This study describes an experimental investigation to find whether such a relationship exists and to explore the correlation between the volume of joint effusion and the intra-articular pressure

---

is study was supported by a grant from the nish Medical Research Council project number –10625

01 6470/80/060893–05$02.50/0

MATERIAL AND METHODS

Six adult horses weighing 255–515 kg were used for the experiments which were performed under Halothane anaesthesia. Blood pressure, intra-articular pressure of the metacarpo-phalangeal joint of the forelegs (fetlock joint) and intraosseous pressure of the juxta articular bone marrow of the metacarpal bone were measured simultaneously

Experimental procedures

Blood pressure was measured continuously through a venflon cannula in an artery of the hindleg

The intra articular pressure of the metacarpo-phalangeal joint was measured through a 1 2 mm cannula. An image intensifier and infusion of isotonic Amipaque (Nyegaard & Co, Oslo Norway) were used to check that the cannula was situated in the joint cavity In three of the experiments a second cannula was placed in the joint and connected to a perfusor pump to record the volume of saline injected simultaneously with the measurement of the pressures. The rate of infusion was 10 ml/min

The intraosseous pressure was recorded through a 1 8 mm marrow aspiration cannula which was drilled into the distal part of the metacarpal bone until the tip of the cannula reached the juxtachondral bone The image intensifier was used to control the position (Figure 1) Before connection to the measuring system the cannula was flushed with heparin saline

The cannulas were connected to the pressure recording system (Hansen HB 66 manometers Simonsen & Weel, Albertslund, Denmark) by means of manometer lines (Portex, Hythe, England) and three-way stop-cocks. For pressure recording an Ultralette 5671 (Atlas Copco, Bromma Sweden) was used

Radiographs of the joints investigated were all normal and no clinical symptoms had been observed In the standing position the metacarpo-phalangeal joints in the horse are loaded in slight hyperextension The attachment of the joint capsule and the extension of the joint cavity with its recesses were demonstrated by arthrography (Figure 2).

The following investigations were carried out

(1) At different degrees of flexion (from hyper extension to maximal flexion, i e about 10 degrees above right angled position) corresponding intraosseous pressures were recorded
(2) At different values of intra articular pressure – obtained by infusion of saline – corresponding intraosseous pressures were recorded simultaneously
(3) In three of the six joints volume of injected saline the pressure and the intraosseous recorded simultaneously in relation of infusion.

RESULTS

Correlation between joint position traosseous pressure

Figure 3 shows intraosseous different degrees of flexion in the investigated The figure shows a traosseous pressure at flexion degrees At 60 degrees significant ($P < 0.05$) and above this from 60 to 80 degrees – the rise traosseous pressure was highly ($P < 0.01$) Intraosseous pressure systemic blood pressure but this exceeded



Figure 1 Radiograph of the left metacarpo-phalangeal joint of a horse (fetlock joint) showing the cannulas one in the juxtachondral bone marrow of the metacarpal bone and one in the joint cavity



igure 2 Arthrography of the metacarpo-ialangeal joint illustrating the dimensions of e joint cavity with recesses communicating ith the joint

orrelation between intra articular and traosseous pressure

igure 4 shows that increasing intra articular essure – with infusion of saline – was ways followed by increasing intraosseous essure The values were positively cor-lated with a coefficient of correlation at 5077 (Spearmann coefficient) and $05 > P > 0\,02$.

orrelation to the volume of jected saline

igure 5 shows simultaneous pressure curves om a single experiment An almost nmediate rise in intra articular pressure was recorded with infusion of saline followed by a much slower rise in intraosseous pressure – after 1 minute – corresponding to 10 ml saline

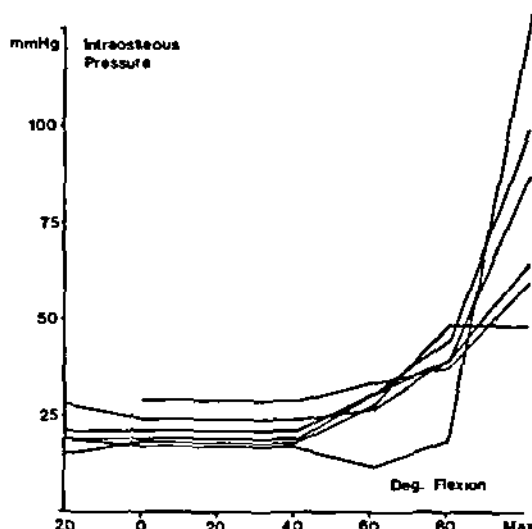


Figure 3 Diagram showing the relationship between degree of flexion and intraosseous pressure in the six joints investigated




Figure 4 Diagram showing the relationship between intraosseous and intra-articular pressures

DISCUSSION

In patients with painful osteoarthritis increased intraosseous pressure accompanied by phlebographic signs of impaired venous drainage is a well known feature

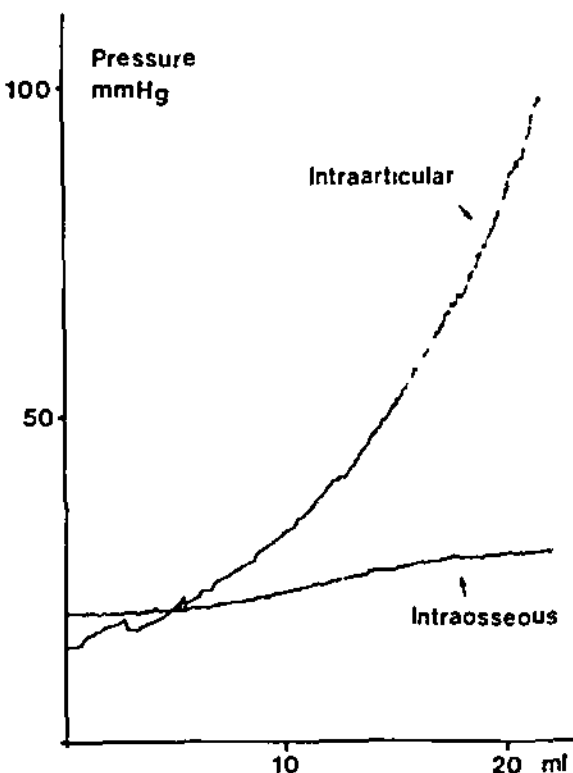


Figure 5 Curves from a single experiment with simultaneously recorded intra articular pressure, intraosseous pressure and volume of injected saline in ml The rate of infusion was 10 ml/min

(Arnoldi et al 1972) The suggestion that this intraosseous hypertension in the juxtachondral bone marrow may be secondary to high pressure in the joint cavity due to synovitic effusion has been supported recently by an experimental study of interdependence between intra-articular and intraosseous pressure in knee joints of rabbits (Arnoldi et al 1979) In the present experiments a similar correlation between intra-articular and intraosseous pressure was found Increased intra-articular pressure – induced by injection of saline into the joint cavity of metacarpophalangeal joints in horses – was followed by increased intraosseous pressure in the juxtachrondal bone marrow of the metacarpal bone

As shown by Eyring & Murray (1964) the intra-articular pressure increases when the volume of synovia increases or when the j space is reduced They have shown a cor- tion between the hydrostatic pressure of j effusion and the joint's position. Therefor seems likely that changes in the postur the joint could cause changes in intraoss pressure

In accordance with the principles of Helsinki declaration this pilot experime study was carried out on metacr phalangeal joints of horses – frequently seat of osteoarthritis This joint is a h joint very similar to human joints recesses communicating with the joint ca as confirmed by arthrography It therefore considered suitable for the vestigations in the present study

We are well aware that in diseased p changes other than effusion in the joint contribute to changes in the intra artic pressure, for example, contractures in joint capsule and swelling of the syno membrane

Our findings have shown that intraoss pressure in the juxta-articular bone mar was influenced by the position of the j Thus flexion above 60 degrees cause significant rise in intraosseous pressure. rise in intraosseous pressure induced flexion is probably due to compression of draining veins from the bone marrow as t pass through the joint

In human osteoarthritis intraoss pressure above 40–50 mmHg causes p (Arnoldi et al 1972, Lynch 1974). The obtained suggest that changes in p position may contribute to pain due elevated intra articular as well as in osseous pressure

The simultaneously recorded curves s that 1–2 ml of saline in the joint cavity sufficient to cause a rise in the intra-artic pressure followed by an increase in traosseous pressure These findings suggest that the intraosseous hyperten observed in patients with painful os arthritis could be caused by compart slight synovitic effusion

FERENCES

ldı, C C , Lınderholm H & Müssbıchler, H 972) Venous engorgement and ıntraosseous rpertensıon ın osteoarthrıtıs of the hıp *J one Jt Surg* 54-B, 409–421

ldı C C., Reımann, I , Chrıstensen, S Bach Mortensen, S (1979) The effect of ıncreased tra artıcular pressure on juxta-artıcular bone arrow pressure. *IRCS Med Scı* 7, 471

g E. J & Murray, W R (1964) The effect joint posıtıon on the pressure of ıntra- tıcular effusıon *J Bone Jt Surg* 46-A, 235–1241

Favreau, J C. & Laurın, C. A. (1963) Joınt effusıons and flexıon deformıtıes. *Canad med Ass J* 88, 575–576

Jayson, M. I V & Dıxon, A St J (1970) Intra-artıcular pressure ın rheumatoıd arthrıtıs of the knee III Pressure changes durıng joınt use *Ann rheum Dıs* 29, 401–408

Lynch, J A (1974) Venous abnormalıtıes and ıntraosseous hypertensıon assocıated wıth osteoarthrıtıs of the knee *The knee joınt* (Ed Ingwesen, O S) Proceedıngs of the Internatıonal Congress, Rotterdam, Sept. 13th–15th, 1973 Excerpta Med , Amsterdam, Amerıcan Elsevıer Publıcatıon Comp Inc., New York

espondence to Professor C. C. Arnoldı, M D , Department of Orthopaedıc Surgery U, Unıversıty ıtal Blegdamsvej 9, DK 2100 Copenhagen Ø, Denmark.

ıorthop scand. 51, 899–902, 1980

STOLOGIC, PHYSICAL AND CHEMICAL 'VESTIGATION OF MYOSITIS OSSIFICANS ŁAUMATICA

'INTÉR, G LÉNÁRT & G RISCHÁK

amelweis University, Department of Orthopaedics, National Geological Survey, Budapest, Hungary

Histologic, physical and chemical analyses of the excised bony mass from a case of myositis ossificans traumatica were carried out. X ray diffraction showed that the newly formed bone was an intermediate fluor-

basic environment.

Key words myositis ossificans traumatica, apatite, X-ray diffraction, infrared spectroscopy

Accepted 12.v 80

yositis ossificans traumatica was first scribed in the 18th century by Frencke & pping (Morger 1964) Various locations ve been reported (Coley 1913), Schneider & k 1966, Jackson & Feagin 1973) and the thology of this condition has been outlined Geschickter & Maseritz (1938)

No physical and chemical analysis of this opic ossification however was found in the ailable literature In the following a patient th myositis ossificans traumatica will be scribed, operation on this patient gave an portunity to carry out a complex investiga-n of the newly formed calcified mass.

TIENT AND METHODS

, male 39 years old sustained a blunt injury on inner side of his left thigh. Two months later calcified mass developed in the adductor isculature causing mild pain and restriction of movement The calcified mass was excised d investigated histologically* and using complex ystallographic methods.

The authors are indebted to Dr K. Aszódi for e histologic examination.

The microscopic examination revealed an enlargement of numerous muscle fibres and the narrowing of others. Between these fibres abundant, actively proliferating connective tissue, more deeply lobulated or insular cartilaginous areas with several mitotic chondrocytes could be observed. In many places the formation of osteoid trabeculae and irregular cancellous bone could also be seen with oedematous hyperaemic connective tissue in the medullary cavities (Figure 1, A and B) Histologic diagnosis myositis ossificans.

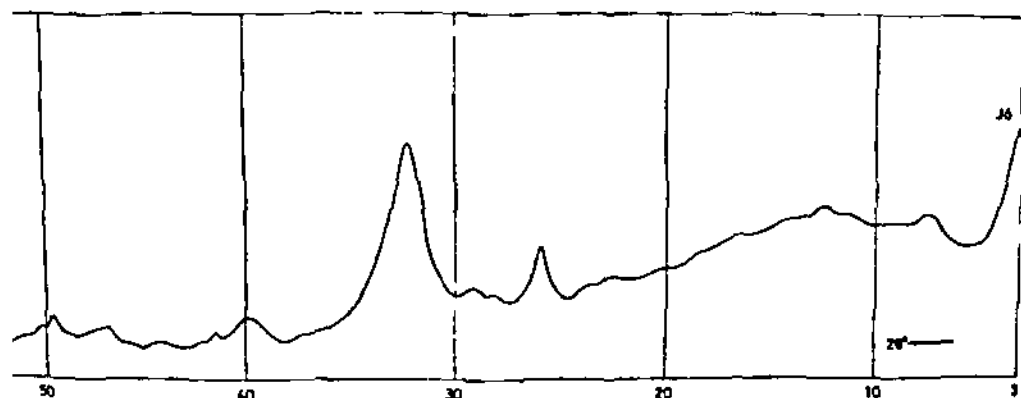
The remainder of the excised mass was prepared and investigated by X-ray diffraction, infrared spectroscopy and chemical analysis as described earlier (Pintér et al. 1979).

RESULTS

X-ray diffraction (Figure 2) This revealed that the excised bony mass contained a low grade crystalline apatite, similar to that of physiological bone hydroxylapatite The crystallites of this mineral were however finer than that of normal bone The average crystallite size of other pathologic calcifications e g calcinosis, osteochondromatosis (Pintér et al. 1975, Pintér et al.

)1 6470.80.060899–04$02.50/0

Figure 1 A, B Photomicrographs demonstrating the typical [illegible]



2 X ray diffractogram of the excised bony mass from myositis ossificans traumatica The pattern an intermediate fluor hydroxylapatite variant

is on the contrary greater than that ysiological bone hydroxylapatite It be assumed that the sample in ated was an intermediate fluor-xylapatite

ed spectroscopy (Figure 3) No signs of late could be found incorporated in the l lattice The characteristic bands of fluor and hydroxylapatite were however visible The specimen contained most probably a fluor hydroxylapatite variant

Chemical analysis The compounds found in the wet chemical analysis are presented in Table 1

Ca P and F seemed to be the major constituents, several minor constituents were

re 3 Infrared spectrum of the excised bony mass from myositis ossificans traumatica The acteristic bands of fluor and hydroxylapatite can be observed together with signs of organic and free contamination

Table 1 Wet chemical analysis of the bony mass excised from myositis ossificans traumatica The minor elements belong to isomorphous substitution in the crystal lattice of the apatite

	Per cent
SiO_2	0 3
TiO_2	0 00
Al_2O_3	0 00
Fe_2O_3	0 05
CaO	28 10
MgO	0 46
SrO	0 00
Na_2O	0 31
K_2O	0 05
P_2O_5	21 80
CO_2	0 10
F	1 28
Cl	0 07
Ignition loss	47 69
H_2O from this	5 0
Organic C	18 5
O loss	0 55
Sum total	99 66

also found The P/Ca ratio proved to be 1 55 It is probable that the sample consists of a rather pure hydroxylapatite variant The crystallochemical formula of the apatite investigated, based on exact crystallochemical calculations, was as follows



$[Ca_{9\ 56}\quad Mg_{0\ 21}\quad Na_{0\ 19}\quad K_{0\ 02}\quad (H_3)_{0\ 02}]$



$[P_{5\ 86}\quad Si_{0\ 10}\quad Fe^{III}_{0\ 02}\quad C_{0\ 04}]$



$[O_{23\ 89}]\quad [F_{1\ 28}\quad Cl_{0\ 04}\quad (OH)_{0\ 68}]$

DISCUSSION

There was an important difference between the mineral parts of the ossified specimen from myositis ossificans traumatica and other pathologic calcifications investigated previously The mineral part of articular osteochondromatosis free bodies and calcinosis resembled apatites built up in a fossilitic environment, i e in an acidic and C(environment (Brophy & Nash McConell 1938)

The apatite investigated here resemb the other hand the accessorical apa the basal rocks. The differences betw specimen investigated and acces apatites were as follows the r crystallite size was less and the inner o the structure less developed in the x part of the mass from myositis oss traumatica than in the rocks mention can be assumed however that similar basal rocks the formation of the mas investigated occurred in alkaline solutio in an environment abundant in O_2 and poor in CO_2

REFERENCES

Brophy, P G & Nash, J T (infrared and X ray analysis of fossil *Amer Mineral* 53, 445–455

Coley W B (1913) Myositis oss traumatica. A report of three cases illu the difficulties of diagnosis from sarcoma *Surg* 57, 305–337

Geschickter C. F & Maseritz, I. H (Myositis ossificans. *J Bone Jt Surg* 661–674

Jackson D W & Feagin J A (19 3) contusions in young athletes. Relatio severity of injury to treatment and prog *J Bone Jt Surg* 55 A, 95 105

McConell D (1938) A structural investiga the isomorphism of the apatite group *Mineral* 45, 209–216.

Morger R. (1964) Zur Myositis ossi traumatica *Helv chir Acta* 31, 390–

Pintér J Lénárt G & Rischák G (Ultrastructure of a mixed form of calc *Clin Orthop* 107, 295–297

Pintér, J Lénárt, G & Rischák, G (Physical and chemical investigation of bodies in articular osteochondromatosis *orthop scand* 50, 533–535

Schneider P G & B ck, J (Ungewohnliche Lokalisation einer ossificans circumscripta. *Med.* 297–298

Correspondence to Dr J Pintér Semmelweis University Department of Orthopaedics, Karolina ut 27 H 1113 Hungary

orthop scand. 51, 903–907, 1980

ıEMANGIOPERICYTOMA OF BONE

·iew of the Literature and Report of a Case

ʿ VANG & ERLING FALK

ıopaedic Hospital The Radium Centre, Municipal Hospital (University of Aarhus),
versity Institute of Pathology, Aarhus Amtssygehus, Denmark

A case of intraosseous haemangiopericytoma of the humerus is described Exarticulation at the shoulder joint was performed and the patient has been followed for 8 years, so far without developing a local recurrence or metastases. The 16 cases of intraosseous haemangiopericytomas on record are reviewed

Key words *haemangiopericytoma, malignant bone tumour, sarcoma*

Accepted 10 v 80

mangiopericytoma is a relatively well-
ʼwn type of tumour, but *its intraosseous*
ıant is extremely rare The intraosseous
ı was first described by Stout in 1956, and
our knowledge only 16 cases have been
lished in the medical literature (Table 1)
aosseous *haemangiopericytoma* is a
ignant tumour characterized histologically
proliferation of fairly uniform, round, oval
spindle-shaped pericytes arranged around
gular vascular lumina lined with a single
er of endothelial cells. The frequency of
oses may vary widely from tumour to
our

s radiological manifestation is usually a
y' process which in some cases may expand
bone, perforate *the cortical* bone, or com-
ely destroy the involved bony area

·SE REPORT

patient was a 69-year-old man, formerly a
er who had always been in good health. In
spring of 1969 he developed pain in the region
e right shoulder The pain subsided *in a few*
ʼs, but returned a couple of months later

Then the patient consulted a doctor The condition was *interpreted* as *humeroscapular* periarthritis and was treated with analgetics. No X-rays were done at that time During the subsequent year the patient had only negligible complaints on account of the arm, but in July 1970 a minor trauma elicited more intense pain in the *right shoulder This time the patient did not visit* his doctor, but in the course of the autumn and winter he noted swelling of the upper arm. In March 1971 he re-visited his doctor who referred him for an X ray examination which revealed a large tumour of the right humerus (Figure 1) *The patient was admitted to the local hospital* where a biopsy was taken. It showed haemangiopericytoma, and the patient was immediately transferred to a tumour centre On admission there he was found to have a firm, indolent tumour proximally in the right upper arm. X-rays of the *skeleton showed no tumours* elsewhere, and chest radiography showed normal appearances. The ESR was 11 mm/h, alkaline phosphatases 16 6 (normal range 3–10). Exarticulation at the shoulder joint was performed on 1 4 1971 The postoperative course was uneventful. *The patient was supplied with a* prosthesis, but he has never learnt to use it Throughout he has been regularly followed in the outpatient department of the tumour centre, where he was last seen in April 1979 There have been no signs of local recurrence and no signs of *metastases. The latest chest radiography, from* April 1979, was normal.

–6470 80, 060903–05$02.50, 0

Table 1 Number of cases, their ages and the localization of primary haemangiopericytom[illegible] the materials published so far

Author	No of cases	Age (years)	Site of tumou[illegible]
Stout (1956)	2	29–32	Femur–Fibul[illegible]
Marcial Rojas (1960)	1	83	Clavicle
Legré et al (1966)	1	58	Femur
Unni et al (1971)	4	33–64	Rib Thoracic verte[illegible] Pelvis (2 cases)
Gerner et al (1974)	1	62	Lumbar verteb[illegible]
Huvos (1979)	6	15–48	Femur (2 case[illegible] Humerus (2 ca[illegible] Scapula Pelvis
Wolkow (1979)	1	13	Femur
Present authors	1	69	Humerus
Total	17		Extremities 9 c[illegible] Trunk 8 cases

HISTOPATHOLOGY

After the humerus had been sawn in the frontal plane a greyish white, lobulated intraosseous tumour, 8 × 6 × 6 cm, was revealed (Figure 2). In places it had destroyed the cortical bone (Figure 1) and infiltrated the surrounding soft tissues. Microscopic examination showed an extremely cellular tumour consisting of many thin-walled, ramifying vessels of varying calibre surrounded by randomly oriented, densely packed cells with round or oval nuclei without major polymorphism (Figure 3) The cytoplasm was on the whole translucent with indistinct cell borders Reticulin staining disclosed that throughout, the tumour cells were separated from the endothelial cells of the vessels by a distinct basement membrane (Figure 4) In some places there was penetration of the bone with destruction of the cortical bone and infiltration of the surrounding muscles. There were 5–10 mitoses per 10 high-power fields, no necroses, and no *haemorrhage* except at the biopsy site. Phosphotungstic acid-*haematoxylin* (PTAH) staining did not disclose any myofibrils, there was no differentiation into a chondroid matrix and no storiform pattern

Histological diagnosis Characteristic haemangiopericytoma According to the criteria of Enziger & Smith (1976) and McMaster et al (1975) it must be classified as malignant

DISCUSSION

Like other malignant tumours of [illegible] intraosseous haemangiopericytoma [illegible] itself primarily by regional pain. [illegible] pain may be intermittent, and in so[illegible] the tumour grows slowly, so that [illegible] years may elapse before the sympto[illegible] marked enough for a diagnosis to be [illegible]

The cases on record so far are fairly [illegible] distributed as to sex and age The tr[illegible] has been by irradiation, surgical exc[illegible] amputation Of Stout's (1959) two ca[illegible] in the femur, was treated exclusi[illegible] irradiation and the other, in the fibula [illegible] by resection These patients are repor[illegible] have had no metastases or recurrence, b[illegible] follow-up period is not mentioned [illegible] patient reported by Marcial-Rojas ([illegible] with a tumour in the clavicle was tre[illegible] excision, but died with pulmonary metas[illegible] 6 years after the operation The ca[illegible] femoral tumour published by Legré e[illegible] (1966) was treated by excision [illegible] recurrence was treated by another re[illegible] but the patient died with pu[illegible] metastases 6 years later Out of the fo[illegible]



re 1 Radiography of the right humerus ing a large lytic process and expansion of the x which is penetrated in places



Figure 2 Frontal section through the upper arm showing greyish-white, lobulated intraosseous tumour tissue, in places destroying the cortical bone and infiltrating the surrounding soft tissues The central haemorrhage is presumably due to the preoperative biopsy

lished by Unni et al (1971) one, affecting ib was treated by resection, but the ent died with metastases 16 months later second case, in the body of the 2nd racic vertebra, was treated by excision owed by irradiation, the patient died with astases 31 years later The remaining two s, in the iliac bone and ischial bone, were ted by resection followed by irradiation hemipelvectomy, respectively These two ents have been followed for 20 months for 9½ years without signs of metastases local recurrence. The vertebral tumour orted by Gerner et al. (1974) was treated X-rays, and it is stated that the patient followed for only a short period. The six cases published by Huvos (1979) were treated by wide surgical excision or amputation, followed by chemotherapy Three of these patients have died with metastases. One – treated solely with X-rays – was alive with a local recurrence 6 years after the treatment One patient with a scapular tumour was alive 15 years after X-ray treatment and subtotal excision of the tumour and, 9 years later, excision of a solitary pulmonary metastasis. In the sixth case the follow-up is still too brief Wolkow (1979) has published one case, but does not report the treatment or the course.

Summing up, then, of the six cases reported so far with sufficient information and a 5-year follow-up, only four have been




Figure 3. Characteristic haemangiopericytoma consisting of thin-walled, ramifying vessels surrounded by fairly uniform, densely packed tumour cells (haematoxylin-eosin × 100)



Figure 4 Reticulin staining [illegible] characteristic haemangiopericytoma patt[illegible] tumour cells being situated outside the [illegible] membrane of the vessels (× 25)

tumour-free 5-year survivors. One developed metastases 6 years after removal of the primary tumour, another patient developed metastases after more than 23 years and died 31 years after primary treatment.

It must be concluded, therefore, that although an intraosseous haemangiopericytoma may be slow-growing in some cases, it is an extremely malignant [illegible] Although our patient is alive without [illegible] stases and local recurrence 8 year[illegible] operation, it should be mentioned t[illegible] tumour cannot be adequately trea[illegible] surgical removal and/or radiotherap[illegible] not yet known whether chemotherap[illegible] alter this dismal outlook

REFERENCES

Enzinger, F M & Smith, B H (1976) [illegible] 106 cases [illegible]

Ge[illegible] ren, J W. (1974) Hemangiopericytoma *Ann Surg* 179, 128–132

Huvos, A G (1979) *Bone tumors* [illegible] *treatment and prognosis* W B S[illegible] Company, Philadelphia, London, T[illegible]

Legré, G, Payan, H & Aubert, [illegible] Hémangiopéricytome osseux. *R[illegible] orthop* 52, 551–559

'ial-Rojas, R. A (1960) Primary hemangio-
ricytoma of bone *Cancer* **13**, 308–311
aster, M J, Soule, E H & Ivins, H C.
975) Hemangiopericytoma A clinico-
thologic study and long-term follow-up of
patients *Cancer* **36**, 2232–2244
, A P (1956) Tumors featuring pericytes,
lomus tumor and hemangiopericytoma. *Lab Invest* **5**, 217–223
Unni, K. K, Ivins, H C, Beabout, J W & Dahlin, D C. (1971) Hemangioma, hemangiopericytoma and hemangioendothelioma (angiosarcoma) of bone *Cancer* **27**, 1403–1414
Wolkow, M W (1979) *Knochenerkrankungen bei Kindern* Verlag Volk und Gesundheit, Berlin.

espondence to Povl S Vang, 95, Holmbjergvej, DK-8420 Knebel, Denmark

a orthop. scand. 51, 909–913, 1980

ACTURE OF THE CARPAL SCAPHOID ' CHILDREN

Clinical and Roentgenological Study of 108 Cases

JO VAHVANEN & MAGNUS WESTERLUND

ora Children's Hospital, Helsinki, Finland

A series of 108 carpal scaphoid fractures in children was analysed with respect to the site, type and treatment of the fracture The patients were followed until radiological fusion occurred. All fractures united and healed completely with conservative treatment. Ninety-four fractures, 41 of which were avulsions, were located in the distal third of the scaphoid. There were 13 waist fractures, and one avulsion fracture was located in the proximal pole of the scaphoid. The great number of avulsion fractures and the location of the fractures in the distal third of the scaphoid is very typical in children. In three neglected cases marked bone resorption was seen on the fracture surface 3 weeks after the injury Because non-union is possible especially in neglected cases of waist fractures, control radiographs should be taken 1 or 2 weeks after the injury if the fracture is not visible on the primary radiographs but is suspected clinically Immobilization with an adequate plaster cast is mandatory in all transverse fractures of the carpal scaphoid in children.

Key words carpal scaphoid, children, fracture

Accepted 10 v 80

ctures of the carpal scaphoid have been sidered rare in children (Blount 1955, indy 1969). According to Müssbichler 61) avulsion fractures occur more fre- ntly and are probably more common than tures across the bone. It is generally own that fracture of the scaphoid waist in lts may occasionally lead to delayed union even to non union According to Watson- es (1976) over 90 per cent of carpal scaphoid tures in adults will unite when treated servatively with a plaster cast for 12 ks. Non union of carpal scaphoid tures is very rare in children (Müssbichler 1, Southcott & Rosman 1977). According Sharrard (1971) non-union seldom occurs l should be treated by bone-grafting in an r child.

Because very few studies of carpal scaphoid fractures in children have been published we report our observations in 108 cases. Special attention was paid to the type and site of the fracture, the treatment and the results.

PATIENTS

A total of 147 children under 15 years of age with an established or suspected carpal scaphoid fracture were treated at the Aurora Children's Hospital, Helsinki, during the years 1962 to 1976 Thirty-nine patients were excluded from the study mainly because the presence of a fracture could not be established in the primary radiographs and there were no signs of a fracture in the control radiographs taken 1–2 weeks after the injury Thus our series consisted of 108 children. At the time of the trauma they were 10–14 years of age

1 647'0'80/060909–05$02.50/0

except for three children, two of whom were 9, and one 6 years of age The mean age was 12 5 years and the series consisted of 75 boys and 33 girls. The left hand was fractured in 64 cases and the right in 44

Seventy-two patients had fallen on the outstretched arm a bicycle accident had caused the fracture in 21 patients, 8 patients had fallen from a height and in the 7 remaining cases the fracture had been caused by twisting or a direct blow to the hand in a game or in a traffic accident

THE SITE AND TYPE OF THE FRACTURE

The generally accepted site distribution into the distal, middle (waist) and proximal third of the scaphoid bone was used In the distal third there were 94 fractures (87 per cent), in the middle third 13 fractures (12 per cent) and in the proximal third one fracture (1 per cent) (Figure 1)

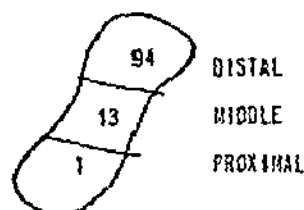


Figure 1 The sites of 108 carpal scaphoid fractures

An avulsion fracture was present in the distal third in 41 cases, 40 of these fractures were located on the dorsoradial aspect and one on the ulnar side of the distal pole of the scaphoid (Figure 2A) One avulsion fracture of the proximal pole of the scaphoid was observed The avulsion type of fracture was always detected in the primary radiographs on the day of injury

The most frequent type of fracture was the transverse fracture located in the distal third of

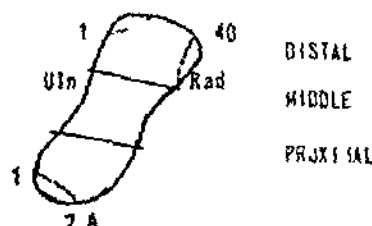




Figure 2A The location of avulsion fractures
Figure 2B The location of fissure and transverse fractures

the bone, 53 cases (Figure 2B). There was n[illegible] placement. In four of these 53 cases a [illegible] or oblique fissure was observed which [illegible] extend through the whole thickness of the [illegible] In five (5/53) cases the fracture line th[illegible] bone could not be seen in the [illegible] radiographs, there were only signs of a [illegible] the contour of the bone However after 2 [illegible] the fracture line through the bone was v[illegible]

Fractures of the middle third were [illegible] cases (Figures 1 and 2B) Displacement [illegible] fracture did not occur The youngest [illegible] years old) had this type of fracture. In [illegible] the fracture line could not be seen [illegible] primary radiographs but a break in the [illegible] contour as in a greenstick type of [illegible] visible After 2 weeks the fracture line [illegible] seen because of osteosclerosis. In [illegible] large bone resorption having a cystic [illegible] was found on the fracture surfaces (F[illegible] two of these three cases the injury [illegible] weeks and in the third case 3 months befo[illegible] first visit to the hospital One of these p[illegible] was 6, and the other two 14 years of a[illegible]

ASSOCIATED INJURY

A fracture of the distal metaphysis of the [illegible] was seen in two patients, distal epiphyseolysis [illegible] the radius in one, a typical fracture of the [illegible] in one and fracture of the base of the [illegible] metacarpal bone in one patient. The[illegible] fractures (5/108 4 6 per cent) were on the [illegible] hand as the fracture of the scaphoid. I[illegible] patient there was a fracture of the first m[illegible] base on the contralateral hand.

TREATMENT

The immobilization time of a fracture [illegible] distal third of the scaphoid varied from 1 [illegible] case) to 9 weeks The most common imm[illegible] tion period was 4 to 8 weeks (59/94 ca[illegible] dorsal plaster splint was used in 30 cases [illegible] plaster cast from below the elbow to the [illegible] phalangeal joint of the thumb (as recom[illegible] by Blount 1955) in the remaining 64 case[illegible]

Fractures of the waist were immobilized [illegible] plaster cast for 4–16 weeks in 12 cases [illegible] splint immobilization for 2 weeks was used [illegible] case One avulsion fracture of the proximal [illegible] of the scaphoid was immobilized with a [illegible] 3 weeks.

Of the three cases with neglected fract[illegible] 6-year-old girl was immobilized for 7 we[illegible] one of the two 14-year-old patients wa[illegible] mobilized for 12 and the other for 15 we[illegible]



re 3A A g rl aged 14 years had fallen on her hand 3 months earlier The patient had red no in t al treatment Radiograph shows a ure of the waist of the scaphoid bone with ked bone resorption



Figure 3C The wrist after 16 weeks' immobiliza tion. The plaster cast has been removed and the fracture is united



e 3B The appearance 8 weeks later Increased resorption and also osteosclerosis can be seen



F gure 3D Radiograph of the wrist 12 years later at the follow-up Sl ght osteosclerosis can still be seen in the m ddle of the scaphoid bone

The mean duration of the plaster cast immobilization was 6 4 weeks and the mean immobilization time when using a plaster splint was 3 3 weeks.

RESULTS

The patients were followed until the fracture was roentgenologically completely fused The radiographs and the clinical data of all the patients were reviewed If the patient still had some symptoms at the last clinical examination or the fusion of the fracture in the last radiograph was suspected to be incomplete the patient was asked to come for a personal follow-up There were 21 such cases.

At the follow-up a clinical and roentgenological examination was carried out All fractures in this series were found to be fused, including the fractures of the three neglected cases (Figure 3) All patients were free from symptoms The range of movement of the carpal and elbow joints was normal Because there was no non-union the result of the treatment was evaluated as good in all 108 patients

DISCUSSION AND CONCLUSIONS

In 1978 at the Aurora Children's Hospital, Helsinki, 17 scaphoid fractures were diagnosed, which is 1 7 per cent of all fractures of the upper extremity (17/1011) in children Fractures of the carpal scaphoid are rare compared with other fractures of the upper extremity The patients with a diagnosed scaphoid fracture were predominantly over 10 years of age and the mean age was 12 5 years This is logical because the ossifying centre appears on the radiograph at approximately 5–6 years of age, the range being 2 5–9 years (Tachdjian 1972)

The site of the fracture was clearly different from the distribution of corresponding fractures in adult series, where fractures of the middle third have been reported to be most frequent (Andersen & Therkelsen 1949, Mazet & Hohl 1963, [illegible] Kankaanpaa 1975) In Alho's (1975) [illegible] a more than 1 mm displacement of [illegible] fracture was present in 23 per cent of [illegible] cases We did not observe such a displacement

Avulsion or incomplete fissure type fractures were present in 42.5 per cent of [illegible] cases and were most frequently located [illegible] distal third of the scaphoid. This [illegible] agreement with Müssbichler (1961), [illegible] reported avulsions in 52 per cent.

The difficulty diagnosing avulsion [illegible] fissure types of fractures and the importance of radiographs of the oblique and [illegible] projections were emphasized by [illegible] (1949) and Müssbichler (1961), with [illegible] we also agree Clinically these types [illegible] fractures have no great significance [illegible] they all heal rapidly Naturally some of [illegible] avulsion or fissure types of fractures, [illegible] are not visible on the primary X-ray [illegible] can be diagnosed in the radiographs taken [illegible] or 2 weeks after the injury

The scaphoid bone is vascularized by [illegible] intra- and extraosseous pathways and [illegible] proximal third of the bone has occasionally [illegible] poor circulation According to Taleisnik [illegible] Kelly (1966) the radiovolar group of [illegible] are most important for the circulation of [illegible] scaphoid and in one case only (1/11 [illegible] specimens) a proximal vessel was [illegible] leading to the proximal surface of [illegible] scaphoid

Even in children non union is [illegible] especially in neglected waist [illegible] (Müssbichler 1961, Southcott & [illegible] 1977) In our series non-union could [illegible] occurred in three neglected cases [illegible] cystic resorption of the bone was [illegible] but fusion was achieved with [illegible] treatment

We suggest that an immobilization [illegible] 3–4 weeks in a plaster splint is [illegible] avulsion and incomplete fissure types [illegible] fractures In transverse fractures the [illegible] plaster cast from below the elbow [illegible] interphalangeal joint of the thumb [illegible]

or 4 to 8 weeks. In neglected cases or in

sary

ERENCES

A. & Kankaanpaa, U (1975) Management of ctured scaphoid bone A prospective study 100 fractures. *Acta orthop scand* 46, 7–743

sen, K. & Therkelsen, F (1949) On fractures the carpal bones, especially of the scaphoid *ta radiol. (Stockh)* 31, 343–357

t, W P (1955) *Fractures in children*, pp –95 Williams & Wilkins Co, Baltimore

dy M (1969) Fractures of the carpal aphoid in children. *Brit J Surg* 56, 3–524

ren, E (1949) Some radiological aspects on the carpal scaphoid and its fractures. *Acta chir scand* 98, 538–548

Mazet, R Jr & Hohl, M (1963) Fractures of the carpal navicular *J Bone Jt Surg* 45-A, 82–112.

Müssbichler, H (1961) Injuries of the carpal scaphoid in children *Acta radiol (Stockh)* 56, 361–368

Sharrard, W J W (1971) *Paediatric orthopaedics and fractures*, p 1002 Blackwell Scientific Publishers, Oxford and Edinburgh

Southcott, R. & Rosman, M A. (1977) Non-union of carpal scaphoid fractures in children. *J Bone Jt Surg* 59-B, 20–23

Tachdjian, M. O (1972) *Pediatric orthopedics*, p 41 W B Saunders Co, Philadelphia–London–Toronto

Taleisnik, J & Kelly, P J (1966) The extraosseous and intraosseous blood supply of the scaphoid bone *J Bone Jt Surg* 48-A, 1125–1137

Watson Jones, R (1976) *Fractures and joint injuries*, pp 729–744 Ed. Wilson, J N 5th edition. Churchill Livingstone, Edinburgh–London–New York.

spondence to Dr Veijo Vahvanen, Aurora Children's Hospital, Nordenskioldinkatu 20, 0250 Helsinki 25 Finland

ıorthop scand. 51, 915–919 1980

/MOBILIZATION AFTER PRIMARY DISLOCATION F THE SHOULDER

KIVILUOTO, M PASILA, H JAROMA & A. SUNDHOLM

partment of Orthopaedics and Traumatology, University Central Hospital,
ılsinki, Finland

A total of 226 patients with primary shoulder dislocation were followed up for 1 year, the primary object being to observe the effect of immobilization on the incidence of redislocation The shoulders were immobilized in a mitella for 1 week in all the 127 patients older than 50 years of age, and in 53 of the patients under 50 years of age. The shoulders of the remaining 46 patients (under 50 years) were completely immobilized with a stockinette-Gilchrist bandage for a period of 3 weeks.

Thirteen per cent (30/226) suffered from one to four redislocations each during the follow up period Because most recurrences occurred in the [illegible]

for 1 week, presented a higher frequency of redislocation than the remaining 27 patients subjected to 3 weeks' immobilization ($P<0.05$) Manual labourers experienced more numerous redislocations than office workers ($P<0.01$). The greater the initial trauma to the shoulder, the lower was the incidence of recurrence There were only two among the 57 patients with early complications of the primary shoulder dislocation who had a redislocation ($P<0.001$) Residual stiffness was encountered more often in the patients over 30 years than in the younger ones ($P<0.001$)

Following primary shoulder dislocation, 1 week's immobilization in a sling is sufficient in patients over 30 years, while in the case of most of the younger patients 3 weeks' complete immobilization of the shoulder is recommended.

Key words shoulder dislocation, immobilization

Accepted 25.iv 80

he mechanism which centres the humeral ead in the glenoid cavity may be deficient by heritance or damaged by trauma Primary id recurrent dislocations occur most fre-iently in those doing manual labour The pical patient who presents a history of current dislocation is a young man of hletic habits in his second or third decade life (Moseley 1961) The greater the initial auma to the shoulder, the higher is the com-ication rate (Pasila et al. 1978), and the incidence of recurrence seems to be reduced accordingly (McLaughlin & MacLellan 1967, Pasila et al 1980, Rowe & Sakellarides 1961) A second dislocation occurred in 42 per cent in a series of 324 primary dislocations described by Rowe & Sakellarides (*1961*), redislocations occurred in 94 per cent of patients below 20 years, and in 14 per cent of those over the age of 40 years (Rowe & Sakellarides 1961) Of the first redislocations, 64–85 per cent ensued within 1 year in the

01-6470/80/060915–05$02.50/0

series reported by McLaughlin & MacLellan (1967) and Moseley (1961) and in Rowe's series (1956) there were 70 per cent redislocations within 2 years. According to Moseley (1961), Hippocrates stressed the value of immobilization in cases where pain and inflammatory tension did not prevent the use of the shoulder

Immobilization periods of a few days (Apley 1977, Gjores & Nilsonne 1965, London 1971, Turek 1977), 3 weeks (Bateman 1955, DePalma 1970, Rokkanen et al 1975, Rowe & Sakellarides 1961, Wilson 1977) and up to 6 weeks have been recommended (Neer & Welsh 1977, Watson Jones 1948) However, Rowe & Sakellarides (1961) found no convincing evidence in favour of immobilization periods longer than 3 weeks

The effects of 1 week's partial and of 3 weeks' complete immobilization on primary shoulder dislocations were compared in a prospective study of 1 year's duration

PATIENTS AND METHODS

In the Department of Orthopaedics and Traumatology, University Central Hospital Helsinki Finland 226 patients with primary shoulder dislocations were each followed up by one investigator for 1 year during the period September 1st 1973–December 31st 1977 Initially the patients visited the Department of Physical Medicine weekly and later at intervals implied by the treatment. There were 126 men and 100 women 127 (56 per cent) were older than 50 years Ninety seven were manual labourers, 45 office workers, 71 in retirement and 13 were students.

No patients with fractures visible on routine X ray projections were included in this study Axillary nerve and plexus lesions were diagnosed by the localization of paretic muscles and defects of skin sensitivity Diagnosis of rotator cuff rupture was postponed a few weeks it was only made in rotator cuff perforations presenting a persistent clinical picture (Pasila et al 1978)

Fifty seven patients (25 per cent) presented a total of 70 complications 25 were plexus lesions, 19 axillary nerve lesions and 26 rotator cuff ruptures. A single lesion was observed in 45 shoulders, whereas 12 shoulders presented more

There were no patients with multiple [illegible] and the mechanism of trauma to the shoulder [illegible] accurately determined in 142 primary dislocations. Falling from a height (15/142) represented [illegible] most severe and a torsion injury (35/142) [illegible] least severe dislocation mechanism. Twenty[illegible] primary dislocations had been incurred [illegible] participating in sports activities. Eighty[illegible] shoulders were reduced within 1 hour after [illegible] location the "non reduced period" being [illegible] hours in 81 patients, 3–12 hours in 44 and 12 [illegible] hours in 14

Because it was doubtful whether the shoulders of the patients over 50 years could tolerate [illegible] immobilization for 3 weeks, the shoulders of the 127 patients older than 50 years were [illegible] mobilized for 1 week in a mitella. Of the [illegible] patients under 50 years 53 had their shoulders similarly immobilized for 1 week in a mitella. The shoulders of the remaining 46 patients under [illegible] years were completely immobilized for 3 weeks with a stockinette-Gilchrist bandage (Gil[illegible] 1967) which was changed weekly At the termina[illegible]tion of the period of immobilization, the patients were encouraged to use the shoulder and [illegible] same physiotherapist who changed [illegible] stockinette-Gilchrist bandages supervised [illegible] mobilization if there were any difficulties. The patients were followed up for 1 year In assess[illegible] the results the age activity and disability of the patients the severity of the initial trauma and [illegible] complications caused by it (to the shoulder) [illegible] well as the duration of the "non-reduced period" and the first redislocation were taken into con[illegible]sideration The results were analysed and tes[illegible] by the χ^2 test

RESULTS

Thirteen per cent (30/226) of the patients i e, 23 men and 7 women experienced [illegible] four redislocations each during the follow[illegible] period The first redislocations were [illegible] distributed over the follow-up year [illegible] earliest two of them occurring during the mitella immobilization.

The disposition to redislocation was [illegible] in the patients under 30 years ($P<0$[illegible] compared with the older patients [illegible]

Table 1 First redislocation, occurring after primary dislocations immobilized for 1 or 3 weeks, in the different age groups

Age (years)	Number of first redislocations after the primary immobilization for		Number of primary dislocations	First redislocations/ primary dislocations (per cent)
	1 week	3 weeks		
–20	6	4	18	56
–30	7	2	35	26
–40	1	1	30	7
–50	0	1	16	6
–60	4	–	49	8
–70	3	–	54	6
–80	1	–	20	5
–86	0	–	4	0
Total	22	8	226	13

sposition remained within the same limits the higher age groups (Table 1)

Of the 53 patients under 30 years (44 men d 9 women), 26 were immobilized for 1 and for 3 weeks. Thirty-six per cent (19/53) of e first redislocations (in 18 men and one oman) were seen in these 53 young patients. fty six per cent (13/26) in the group mobilized for 1 week suffered from a dislocation, whereas this occurred in only per cent (6/26) of the patients immobilized r 3 weeks ($P<0\,05$)

Manual labourers had more redislocations an office workers ($P<0\,01$) (Table 2) The udents, all of them under 30 years, had ore redislocations than the other patients $<0\,001$)

The shoulders primarily easily dislocated by torsion were most frequently redislocated (Table 3) There was a statistically significant difference when these shoulders were compared with the shoulders dislocated in connection with falling on the same level ($P<0\,05$) or falling from a height ($P<0\,01$) However, there was no statistically significant difference between the recurrences in shoulders dislocated in connection with falling on the same level and those dislocated by falling from a height.

The recurrence rate was 17 per cent (28/169) in the shoulders without complications and 4 per cent (2/57) in the shoulders with complications ($P<0\,001$) Two men, both under 20 years and suffering

Table 2 First redislocations divided according to the patients social groups

Social group	Number of first redislocations	Number of primary dislocations	First redislocations/ primary dislocations (per cent)
Student	7	13	54
Manual labourer	17	97	18
Retired	5	71	7
Office worker	1	45	2
Total	30	226	13

Table 3 First redislocations after the various mechanisms of the primary dislocation

Mechanism of primary trauma	Number of first redislocations	Number of primary dislocations	First redislocations/primary dislocations (per cent)
Fall from a height	0	15	0
Fall in the same plane	9	92	10
Torsion	11	35	31
Total	20	142	14

Table 4 The median duration of sick leave

Age (years)	Number of working patients	Duration of immobilization (weeks)	Median period of sick leave (weeks)
<50	44	1	2 8
<50	40	3	3 8
>50	58	1	3 9

from a transient axillary lesion, experienced a redislocation after recovery from the nerve lesion In 42 shoulders with some degree of residual stiffness no redislocations were encountered Among 154 shoulders in patients over 30 years of age, immobilized for 1 week, 26 per cent (40/154) suffered from residual stiffness at the final follow-up On the other hand, the shoulders of 26 patients under 30 years of age immobilized for 1 week resumed their normal range of motion in all cases but one (4 per cent) ($P<0\ 001$)

The difference between the median number of days on sick leave (Table 4) in the two immobilization groups of patients younger than 50 years is statistically significant ($P<0\ 01$), as is that between the groups with 1 week's immobilization of patients under and over 50 years, respectively ($P<0\ 01$)

DISCUSSION

One year is considered a satisfactory follow-up period since most redislocations occur within 1 year (McLaughlin & MacLellan 1967, Moseley 1961) The frequency of recurrences was 13 per cent (30/226) in the study Even better results, however without any redislocations whatsoever have been reported in extensive personal series both with shorter (London 1971) and longer (Aronen & Welsh 1977, Watson-Jones 1948) periods of immobilization

The longer follow-up, up to 10 years, in the series of Rowe & Sakellarides (1961) provides an explanation for their observation that nerve injuries did not affect the frequency of recurrence The two recurrences observed in the 44 nerve injuries in the present study both occurred after recovery from the axillary nerve injury

The less the energy required to cause the primary dislocation the more liable was the shoulder to redislocate during the follow-up (Table 3) The earliest mobility recovery was seen in the shoulders easily dislocated by torsion whereas the shoulders dislocated by the most severe mechanism, by falling from a height, took the longest time to recover mobility (Pasila et al 1980) The frequency of complications was highest among the shoulders dislocated in connection with falling from a height (Pasila et al 19[illegible] [illegible] 10 of the 13 working patients (77 per cent [illegible]

…s group needed a longer sick leave period . than 1 month) compared with the '66 patients (35 per cent) who fell on the ne level or with the 4/24 patients (17 per nt) whose shoulders were dislocated by sion.

Despite there being many factors with me relation to the incidence of redislocan, age seemed to be the most important gle factor The 24 shoulders dislocated ile participating in sports activities were one to redislocations, 33 per cent (8/24) dislocated but these patients were all under years of age Furthermore 20/35 (57 per nt) of the patients whose primary dislocan was caused by a torsion injury were der 30 years of age compared with 16/92 tients (17 per cent) sustaining the primary slocation in connection with falling on the me level and 3/15 patients (20 per cent) no fell from a height

Patients under 50 years can be safely mobilized with a stockinette-Gilchrist ndage maintained for 3 weeks (Pasila et al 980), but immobilization in order to prevent dislocations is only important in patients der 30 years of age, as is also *prevention of* oulder pain and stiffness only applicable in der patients (McLaughlin & MacLellan 967). A low incidence of redislocation in the oulders subjected to considerable initial auma was also observed by Rowe & akellarides (1961) and by McLaughlin & MacLellan (1967) in shoulders with comlications conforming with the results in this tudy Some young patients with hypermobile ints give a history of instability of the houlder prior to the primary dislocation and is doubtful whether prolonged immobilization is indicated in shoulders such as these.

Following primary shoulder dislocation, 1 week's immobilization in a sling is sufficient n patients over 30 years, but in most of the younger patients 3 weeks' complete immobilization of the shoulder is recommended.

REFERENCES

Apley, A G (1977) *A system of orthopaedics and fractures* 5th ed. p 359 Butterworths, London and Boston.

Bateman, J E (1955) *The shoulder and environs* 1st ed p 503 The C. V Mosby Company, St Louis.

DePalma, A F (1970) *The management of fractures and dislocations* 2nd ed Vol 1 pp 583–584 W B Saunders Co, Philadelphia, London, Toronto

Gilchrist, D K (1967) A stockinette-Velpeau for immobilization of the shoulder girdle *J Bone Jt Surg* 49-A, 750–751

Gjores, J E & Nilsonne, U (1965) Prognosis in primary dislocations of the shoulder *Acta chir scand* 129, 468–470

London, P S. (1971) Treatment and after-care for dislocation of the shoulder *Physiotherapy* 57, 2–6

McLaughlin, H L & MacLellan, D I (1967) Recurrent anterior dislocation of the shoulder A comparative study *J Trauma* 7, 191–201

Moseley, H F (1961) *Recurrent dislocation of the shoulder* 1st ed. pp. 35–37 E. & S Livingstone Ltd, Edinburgh and London

Neer, C. S & Welsh, R P (1977) The shoulder in sports. *Orthop Clin. N Amer* 8, 583–591

Pasila, M, Jaroma, H, Kiviluoto, O & Sundholm, A (1978) Early complications of primary shoulder dislocations. *Acta orthop scand* 49, 260–263

Pasila, M, Kiviluoto, O, Jaroma H & Sundholm A (1980) Recovery from primary shoulder dislocation and its complications. *Acta orthop scand* 51, 257–262.

Rokkanen, P., Slatis, P, Alho, A., Ryoppy, S & Huttinen, V-M (1975) *Traumatologia* 2nd ed [illegible]

Rowe, [illegible]
the [illegible]

Rowe, [illegible]
related to recurrences of anterior dislocations of the shoulder *Clin Orthop* 20, 40–48

Turek, S L (1977) *Orthopaedics* 3rd ed. p 840 J B Lippincott, Philadelphia, Toronto

Watson-Jones, R (1948) Editorials. *J Bone Jt Surg* 30-B, 6–8

Wilson, J N (1977) Watson-Jones, R *Fractures and joint injuries* Vol. 2. pp. 562–563 5th ed Churchill Livingstone, Edinburgh, London and New York

Correspondence to M Pasila, M D., HUCH, Tolo Hospital, 00260 Helsinki 26, Finland.

ta orthop. scand. 51 921–923 1980

ULMONARY EMBOLIC SYNDROME CAUSED BY EMENTING OF HIP ENDOPROSTHESIS

W BARRON

1e Withers Orthopaedic Centre, Musgrave Park Hospital, Belfast, Northern Ireland

Previous studies have indicated that cementing of the femoral component in total hip replacement produces the features of the pulmonary embolic syndrome (P E S). The present investigations have been carried out to ascertain if newer methods of insertion modify these features.

There was no evidence to suggest that any of these approaches has any advantage over the others in relation to the various components of P E S

Key words arthroplasty, bone cement, pulmonary embolic syndrome, venting

Accepted 6 v 80

1 a previous communication by Alexander & arron (1979) it was established that the sertion of methyl methacrylate and a pros-iesis into the femoral marrow cavity results 1 the pulmonary embolic syndrome (P E S) This condition is characterized by a lative hypoxaemia, elevation of serum lipase ccompanied by a fall in triglycerides and the evelopment of anaemia

Attempts have been made to prevent or iodify this syndrome, either by the method f venting carried out by the surgeon or by 1e use of intravenous alcohol as described by lexander & Barron (1980) Studies with itramedullary pressures by Tronzo et al 1974) and by Barron (1979) have shown that itramedullary hypertension is a feature of he insertion of both cement and prosthesis. Vhile acrylic pressures can be modified by he method of venting, prosthetic pressure is naffected and may be more than 600 mmHg t is considered that the hypertension is esponsible for the intravasion of medullary ontents which produce P E S

PATIENTS AND METHODS

The present investigations have been carried out to examine the effects of using a cement gun (Howmedica) as outlined by Lee et al. (1978) to introduce the cement into the marrow cavity, and of blocking off the lower half of the cavity by means of either a bone block (Wroblewski 1979) or a plug of cement (Indong et al. 1978) Twenty patients were involved in each of the three methods.

Patients were not selected and the method used was the choice of each individual surgeon. Venous and arterial samples were obtained as described previously by Alexander & Barron (1979) except that in patients having bone or cement blocks additional arterial samples were taken before and after their insertion.

RESULTS

Blood gas analyses showing arterial oxygen values are presented in Table 1 while serum triglyceride and lipase values are shown in Tables 2 and 3 It can be seen that these follow very closely the results obtained in

001-6470.80/060921-03$02.50/0

Table 1 Arterial oxygen tension values at various stages of the operation
Arterial Oxygen

	Before block	After block	Before cement and prosthesis	After cement and prosthesis	P_aO_2
Cement gun	—	—	15 18 ± 5 04	14 01 ± 4 41	18
Bone block	16 77 ± 2 58	17 10 ± 4 05	16 11 ± 4 35	13 86 ± 2.98	23
Cement block	16 38 ± 3 89	17 90 ± 4 02	17 16 ± 5 78	14 92 ± 3 56	2

Table 2 Serum triglyceride values obtained with the three alternative methods
Triglycerides

	Control	4 hours	24 hours	4 days
Cement gun	1 29 ± 0 50	0 97 ± 0 33	0 92 ± 0 23	1 09 +
Bone block	0 96 ± 0 41	0 58 ± 0 32	0 74 ± 0 31	1 0 +
Cement block	1 06 ± 0 36	0 56 ± 0 31	0 63 ± 0 28	0.94 +

Table 3 Serum lipase values obtained with the three alternative methods
Lipase

	Control	4 hours	24 hours	4 days
Cement gun	1 01 ± 0 41	1 30 ± 0 51	1 17 ± 0 44	1 10 ±
Bone block	0 84 ± 0 37	1 35 ± 0 50	1 13 ± 0 43	0.68 +
Cement block	0 92 ± 0 38	1 30 ± 0 51	1 41 ± 0 43	1 0 ±

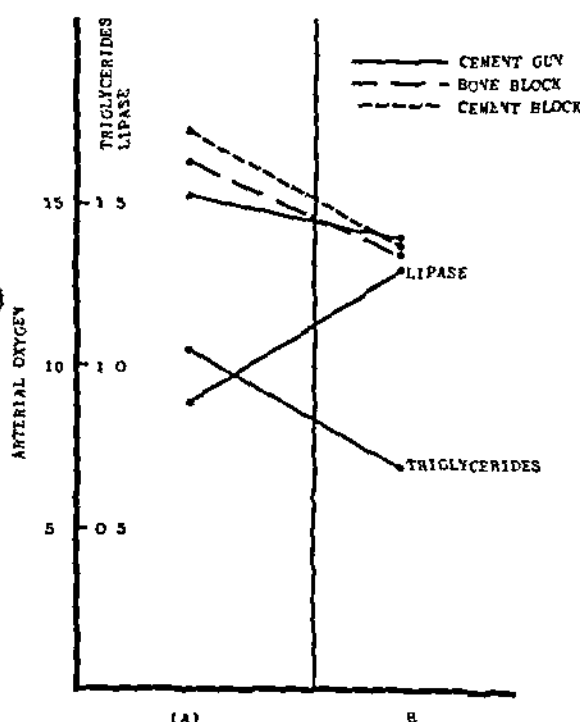


Figure 1 Arterial oxygen triglyceride and lipase values –
(A) before insertion of cement and prosthesis, and
(B) after insertion

previous studies using drill hole or ca venting or when intravenous alcohol employed as described by Alexand Barron (1980) The results are pre graphically in Figure 1

DISCUSSION

Attempts to modify P E S by the su have been mainly concerned with the m of venting These have included the use plastic catheter, the drilling of a hole junction of the upper one-third and the two-thirds of the femoral shaft, the ma of the methacrylate by means of a gun and the blocking of the distal half marrow cavity with a plug of either bo cement It should be said that the objective has been to obtain a tight f prosthesis rather than the prophylac P E S The only attempt at modification the anaesthetist concerns the use intravenous alcohol

t would appear from the results of the sent study that the most recently induced surgical manoeuvres do not prevent modify P E S This is not surprising since y in no way affect the final intra dullary hypertension produced by the *nmering into position of the femoral pros- sis.*

FERENCES

xander J P & Barron, D W (1979) Biochemical disturbances associated with total up replacement. *J Bone Jt Surg* **61 B** 101–106

xander J P & Barron, D W (1980) The effect of alcohol on the pulmonary embolic syndrome. *Anaesthesia* **35**, 506–508

Barron, D W (1979) Intra-medullary pressure patterns. *Clin Orthop* **145**, 183–186.

Indong, O H, Carlson, C E., Tomford, M. D & Harris, W H (1978) Improved fixation of the femoral component after total hip replacement using a methacrylate intra medullary plug *J Bone Jt Surg* 60-A 608–613

Lee, A. J C, Ling R. S M. & Vangaea, S. S (1978) Some clinically relevant variables affecting the mechanical behaviour of bone cement. *Acta Orthop Traumat. Surg* **92**, 1–18

Tronzo, R. G Kallos, T & Wyche, M. Q (1974) Elevation of intra medullary pressure when methylmethacrylate is inserted in total hip arthroplasty *J Bone Jt Surg* **56-A**, 714–718

Wroblewski, B M. (1979) Personal communication.

respondence to David W Barron, 47 Balmoral Avenue Belfast, BT9 6NX, Northern Ireland.

Acta orthop scand. 51, 925–927, 1980

OSTEOARTHRITIS OF THE HIP AND KNEE JOINT IN RETIRED FOOTBALL PLAYERS

KURT BJØRNØ KLÜNDER, BJARNE RUD & JØRGEN HANSEN

Department of Surgery, Vejle General Hospital, Vejle, Denmark

The possible relationship between football playing and osteoarthritis in the hip and knee joints has been examined. The results of clinical and radiographic examinations of 57 retired football players and a corresponding control group were compared. Osteoarthritis of the hip joint was found to occur significantly more often in the football players than in the controls. Such a relationship could not be found regarding the knee joint.

Key words football, hip joint, knee joint, osteoarthritis

Accepted 24.iv 80

Several studies have been made to investigate the ill-effects of sports on the kinetic system (Carvalho & Langfeldt 1977, Heiss 1929, Kuranen et al. 1975), Baetzner (1936) was one of the first to notice the frequent occurrence of degenerative joint changes in top athletes.

Football is probably the most popular ball game in the world, and as such is played by a considerable number of young men. It is, therefore, natural that there has been a growing interest in the possible relation between the development of osteoarthritis in the lower extremities and football playing and several studies have been published on this subject (Brodelius 1961, Köhler 1955, Solonen 1966, Thorseth 1972) These investigations demonstrated a greater prevalence of osteoarthritic changes in the ankles of football players (Brodelius 1961, Köhler 1955, Solonen 1966), but not in the hip and knee joints (Köhler 1955, Solonen 1966). As a result of the introduction of professional football in Denmark, we found it of interest to re-examine these results. The purpose of this study was to elucidate a possible relationship between top-level football playing over many years and the prevalence of osteoarthritis in the hip and knee joints.

PATIENTS AND METHODS

In cooperation with Vejle football club's secretariat, 62 previously active football players were randomly selected, and 57 agreed to participate in the study Radiographs of the hip and knee joints were taken and a clinical examination was made The following information was recorded age, weight, average number of playing hours per week during the period of activity, the length of the period of sporting activity, occupation, injuries requiring treatment as well as surgery to the lower extremities.

Thereafter, a control group was formed of 57 men admitted to the local hospital for complaints other than neurological and not for problems in the lower extremities. These men had never been active football players. Each person in the control group matched one of the football players with regard to age (± 2 years) and weight (± 5 kg) and all were examined clinically and radiographically, in the same way as the football players.

The radiographic examination used the hospital's routine source-to-film distance of 1 metre. The hip joints were radiographed in the supine position with one film registering the pelvis and both hip joints. The knee joints were radiographed in A–P and lateral projections. The X-rays were all made in the recumbent position, which is the routine in the department, and therefore only distinct changes of osteoarthritis are included in the material.

The radiographs were evaluated by a qualified

0001-6470/80/060925-03$02.50/0

radiologist Radiographic signs of osteoarthritis which were accepted were diminution of the joint space, sclerosis and/or subchondral cyst formation In this way, those whose only sign of change was osteophyte formation were eliminated The rationale for this was that in previous studies, the relationship between osteophyte development and the subsequent occurrence of osteoarthritis could not be confirmed (Danielsson 1964)

The χ^2 test was used to evaluate statistical significance

RESULTS

The 57 football players had an average age of 56 4 years (40–79), their average weight was 78 5 kg (61–104), the average number of playing hours per week in the period of activity was 6 7 (3–10), and the average period of activity was 22.8 years (11–41) In the control group, the corresponding values were 56 6 years of age (42–80) and 78 1 kg body weight (61–104)

Among the football players, positive signs of osteoarthritis were seen in 30 (52.7 per cent), while the same changes were seen in 19 (33 3 per cent) of the men in the control group This difference is statistically significant ($P<0\ 05$) Twenty-eight (49 1 per cent) of the 57 retired football players demons[illegible] positive signs of osteoarthritis in the hip [illegible] The same changes were seen in only 15 ([illegible] per cent) of the 57 controls. This differe[illegible] statistically significant ($P<0\ 05$). There [illegible] difference regarding the knee joints as [illegible] arthritis was found in eight previous fo[illegible] players and in seven of the controls.

The localization of the osteoar[illegible] changes is shown in Table 1 The averag[illegible] of the 30 football players with radiogr[illegible] signs of osteoarthritis was 59 5 years [illegible] the 19 in the control group, 60 2 years. Of [illegible] 49 individuals with radiographic os[illegible] arthritis, seven presented subj[illegible] symptoms Thirteen football players [illegible] three of the control group with [illegible] osteoarthritis had suffered previous in[illegible] to the lower extremities (see Table 2).

Five of the thirteen football players [illegible] sustained injuries to the meniscus, fr[illegible] which had been treated conservatively [illegible] player had been meniscectomized in [illegible] knees and had osteoarthritis in both k[illegible] The other four players suffered from bil[illegible] hip joint osteoarthritis, and two of these [illegible] presented osteoarthritic changes in [illegible] injured knee

Of the 30 football players with os[illegible]

Table 1 Localization of radiographically distinct osteoarthritis in 30 football players and [illegible] controls

	Hip joint		Femoro-tibial joint		Femoro-pa[illegible] joint	
	Unilat	Bilat	Unilat	Bilat	Unilat.	Bil[illegible]
Football players	9	19	4	1	2	4
Control group	3	12	1	4	0	[illegible]

Table 2 Number and type of injuries to 13 football players and 3 controls with radiograph[illegible] verified osteoarthritis

	Football players	Control group
Fracture	3	1
Meniscus lesion	6	2
Other *	7	0

* Distortion, ligament injuries, ruptured tendons, etc

hritis, 8 (26 7 per cent) were doing jobs olving heavy physical labour, while of the in the control group, there were 9 (47 4 cent) doing similar heavy jobs.

SCUSSION

he aetiology of osteoarthritis is as yet torily defined The disease apparently results m a combination of factors, such as age, ic endocrine balance, injury as well as cational strain (Isdale 1975, Jurmain 1977) is study demonstrated a significantly gher prevalence of osteoarthritis among ired football players, as compared with a ntrol group As seen in Table 1, the fference between the groups lies in the quency of osteoarthritic changes in the hip nt, while the occurrence of changes in the ee joint is rather similar This finding rees with Thorseth (1972) who studied the ee joints of 208 retired top football players e hip joint was not examined In contrast, e present study did not agree with the dings of Köhler (1955) or Solonen (1966), ho found no correlation between football aying and osteoarthritis of the hip joint A ssible explanation could be that the average e in the above studies was 24 5 and 26 0 ars, respectively Moreover, the material om both studies is incomplete, as radiographs ere taken of only some of the players amined.

Previous investigations (Puranen et al. 975, Carvalho & Langfeldt 1977) have shown at the frequency of osteoarthritic changes is ot increased by running The fact that we und an increase in the prevalence of osteo-rthritic changes among previous football layers could be explained by the fact that inning is a physiologic activity while otball often involves excess strain on the lower extremities in the form of non-physiologic attitudes and numerous injuries

It is concluded that after many years participation in top level football the prevalence of osteoarthritis of the hip joint, but not of the knee, is increased

ACKNOWLEDGEMENT

This work was kindly supported by Vejle County Hospital s legacy for medical research founded by Director Åge Holm Madsen and his wife Lilly Viola Madsen.

REFERENCES

Baetzner, W (1936) *Sport und Arbeitsschaden* p 98 *George Thieme*, Leipzig

Brodelius A (1961) Osteoarthrosis of the talar joints in footballers and ballet dancers. *Acta orthop scand* **30**, 309–314

Carvalho A De & Langfeldt B (1977) Løbetraening og arthrosis deformans. *Ugeskr, Laeg* **139**, 2621–2622.

Danielsson L G (1964) Incidence of osteoarthritis of the hip *Acta orthop scand.*, Suppl. 66 1–114

Heiss, F (1929) Røntgenologische gelenkuntersuchungen an olypiakampfern. *Klin Wschr* **8**, *648–651*

Isdale I C. (1975) Aetiology of osteoarthritis. *Aust Radiol.* **19**, 344–347

Jurmain R D (1977) Stress and etiology of osteoarthritis. *Amer J phys Anthrop* **46**, 353–366

Kohler, R. (1955) Zur Frage typischer Fussballschaden der Kniegelenke und des Beckens. *Z artzl Forbild* **49**, 743–747

Puranen, J, Ala Ketola, L., Peltokallio P & Saarela, J (1975) Running and osteoarthrosis of the hip *Duodecim (Helsinki)* **91**, 659–664

Solonen K. A (1966) The joints of the lower extremities of football players. *Ann. Chir Gynaec Fenn* **55**, 176–180

Thorseth K. (1972) Idraetslaesioner F a d.L.'s forlag

orrespondence to Kurt Klunder M D Lervangen 31 DK 7100 Vejle Denmark

ta orthop scand 51, 929–935, 1980

'OTAL HIP REPLACEMENT *AD MODUM* RING

URT SIMESEN

partment of Orthopaedic Surgery, Kolding, Denmark

A 2–9 y
sented
Charnley
mobility
mortality rate was 0 3 per cent. Early deep infection occurred in 0 7 per cent and late deep infection in 0 3 per cent, 4 4 per cent needed revision for

patients required reoperation when the short prosthesis was used Even apart from those reoperated on the results were significantly poorer when the short prosthesis was used

It is concluded that the Ring prosthesis can still be recommended, but that the long prosthesis should be used whenever possible When this is not possible, a cemented prosthesis should, perhaps, be used.

Key words hip joint, metal-to-metal prosthesis, Ring total arthroplasty

Accepted 10 v 80

1968 Ring introduced a total hip replacement in which both replacement components were made of metal, and where no cement was used in the fixation (Ring 1968) Since 968 this method has been used at the Department of Orthopaedic Surgery, Kolding Our preliminary results, together with the results of 10 other orthopaedic surgery departments have been published previously Paaby 1974) Our preliminary findings indicate that this method gives results that are as satisfactory as those achieved by cemented prostheses. It has been put forward by Evarts et al. (1972) that the Ring prosthesis has a significant tendency to work loose with a detrimental effect on the original result. Apart from Ring's own findings (1968, 1970, 1971, 1973, 1974) there are no other reports with an acceptable number of patients and a reasonable observation time, so we have reviewed all our patients operated during the period 1968–1976, with the intention of evaluating the results after a minimum follow-up period of 2 years.

PATIENTS AND METHODS

During the period 1968–1976, 309 patients were treated with a total hip replacement *ad modum* Ring At the time of the follow-up 38 had died, and 19 did not attend. There were therefore 252 patients of whom 43 had been operated on bilaterally A total of 295 operated hips were therefore included in the study

Sex and age distribution are shown in Figure 1, the average age was 66 years (range 35–81 years).

Operative indication was pain and impaired function combined with clinical and radiographical signs of irreversible hip disease. The preoperative diagnosis is shown in Table 1 In 78 per cent of the cases the indication for operation was

)001–6470 80/060929–07$02.50/0

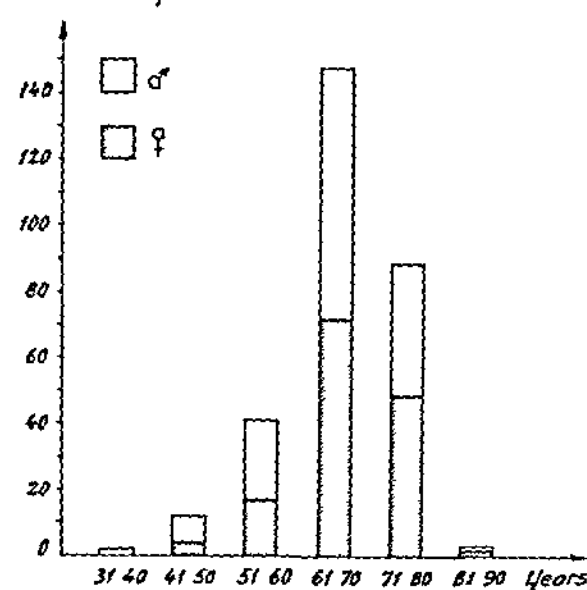


Figure 1 Sex and age distribution at operation

arthritis Thirty-one patients had been operated on previously (osteotomy 13 nailing of fracture of the neck of the femur 9, femoral head replacement 6, other procedures 3)

The operations had been performed in a conventional operating theatre mainly as the first operation of the day and most often on the day after admission The operative technique was as described by Ring (1968 1970, 1974) Prophylactic antibiotic treatment with penicillin was given until the removal of the sutures One of the surgeons has also given streptomycin for 5 days (63 operations) The patients were given prophylactic anti-coagulation treatment with Phenprocoumon (Marcoumar®) from the day before the operation until discharge After the operation skin traction (2 kg) was applied for 7 days in all patients. After this they were mobilized with two elbow crutches. They were allowed to bear weight on the operated hip and were advised to use elbow crutches until the first follow up examination 2–3 months after the operation The patients were discharged when they could manage alone and were able to negotiate stairs. At the follow-up the results were evaluated using the Merle D Aubigné classification as modified by Charnley (Merle D Aubigné & Postel 1954, Charnley 1972) The construction of the scale is shown in Table 2

RESULTS

The average observation period was 5 4 years (range 2–10 years) In Figures 2, 3 and 4, the pre- and postoperative results c[illegible] pain, movement, and walking a[illegible] given in points. Sixteen of the [illegible] excluded as these had been reopera[illegible] the time of the follow up leaving [illegible] The average number of points for [illegible] 1 4 preoperatively and 5 4 postop[illegible] Fifty-seven per cent became comple[illegible] of pain, whereas 27 per cent had [illegible] termittent pain, in most cases taking [illegible] of slight pain on starting to move. [illegible] operative points for movement [illegible] compared with 5 0 postoperatively [illegible] per cent achieved a range of flexio[illegible] degrees or more The average po[illegible] walking ability were 2.2 compared [illegible] postoperatively The average patient [illegible] stick for longer distances. Thirty-six [illegible] of the patients did not use sticks at all.

Complications

The local complications are shown [illegible] 3 One per cent had a superficial [illegible] that did not affect the prosthesis. E[illegible] infection occurred in two cases. Th[illegible] theses were removed and the patien[illegible] given Girdlestone hips. There was one [illegible] late deep infection, with increasing [illegible] 2 years after the operation. Inves[illegible] showed the growth of non-ha[illegible] streptococci After 3 months of a[illegible] treatment the prosthesis was remo[illegible] Lubinus prosthesis fixed with ceme[illegible] taining gentamicin was used instead. [illegible] was no sign of infection a year la[illegible]

One prosthesis dislocated immedi[illegible] the operation and was treated b[illegible]

Table 1 Preoperative diagnosis

Diagnosis	No. of op[illegible]
Primary osteoarthritis	211
Post traumatic osteoarthritis	25
Rheumatoid arthritis	1[illegible]
Anchylosing spondylitis	5
Miscellaneous	1[illegible]
Total	25[illegible]

'able 2 The evaluation of pain movement and walking ability according to Charnley (1972)

?ain		Movement		Walking
Severe and spontaneous	1	0– 30 degrees.	1	Few yards or bedridden. Two sticks or crutches.
Severe on attempting to walk Prevents all activity	2	31– 60 degrees.	2	Time and distance very limited with or without sticks.
Tolerable permitting limited activity	3	61–100 degrees.	3	Limited with one stick (less than 1 hour) Difficult without a stick Able to stand long periods.
Only after some activity Disappears quickly with rest	4	101–160 degrees.	4	Long distances with one stick. Limited without a stick.
Slight or intermittent. Pain on starting to walk but getting less with normal activity	5	161–210 degrees.	5	No stick but a limp
No pain	6	211–260 degrees.	6	Normal

uction there has been no dislocation ce In three cases a break appeared in the ew of the acetabular component of the ly design of prosthesis with a slim stem one case the prosthesis had to be replaced etabular components with a conical screw ve been used since 1974

The roentgenograms at the time of the low up showed among 279 non reoperated ?s, 118 cases with radiolucent zones surunding the femoral component (42 per nt) In 20 cases the zone was at least 3 mm de (7 per cent) The prosthesis had settled into the femur in 37 cases (12 per cent) Fifty seven acetabular components were found to have radiolucent zones (20 per cent) measuring at least 3 mm in 13 cases (5 per cent) Increased density in the bone structure surrounding the acetabular screw was found in 142 prostheses (51 per cent) In 104 prostheses no radiolucent zones were found (1 mm or less)

In 18 cases considerable ectopic bone formation was found surrounding the prosthesis evident as a bridging of the prosthesis cranially and/or caudally

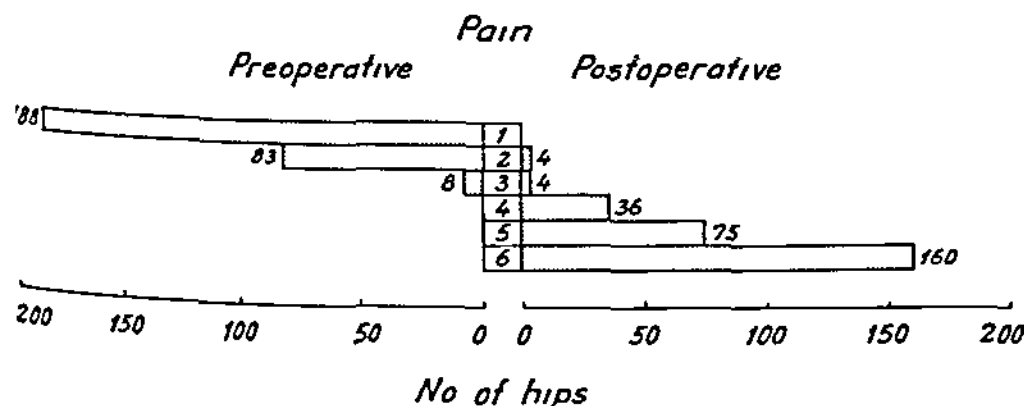


Figure 2 Grading of pain according to Charnley (1972)

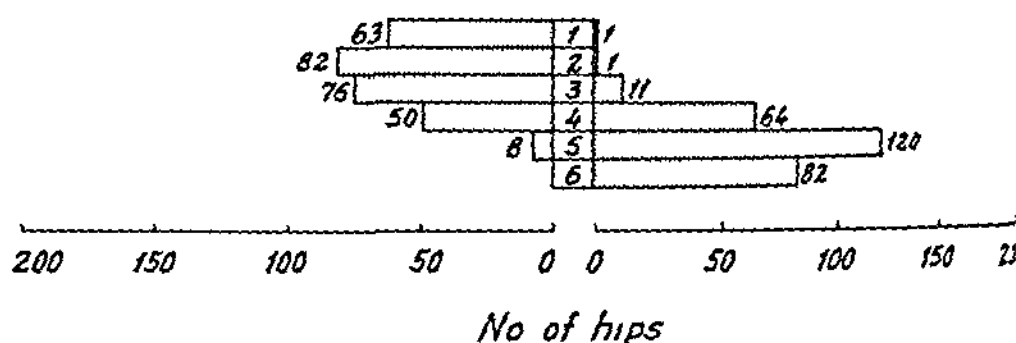


Figure 3 Grading of movement according to Charnley (1972).

One patient died 4 hours after the operation as a result of haemorrhage from the iliac vein caused by the acetabular screw There were no other mortalities during hospitalization Eleven patients contracted deep vein thrombosis Two patients had minor pulmonary embolisms

Twenty-five per cent were actively employed preoperatively, although all were disabled to some extent, and many had been unfit for work for long periods. Twenty-four per cent were receiving disablement pensions, and 51 per cent were old-age pensioners At the time of the follow-up 12 per cent w actively employed Two patients h however, changed to less physic demanding work Twenty per cent w receiving disablement pensions, and 67 p cent old-age pensions.

DISCUSSION

In Table 4 our results are compared w those of others. Mossing & Holm (197) Lindholm & Puranen (1976) used t

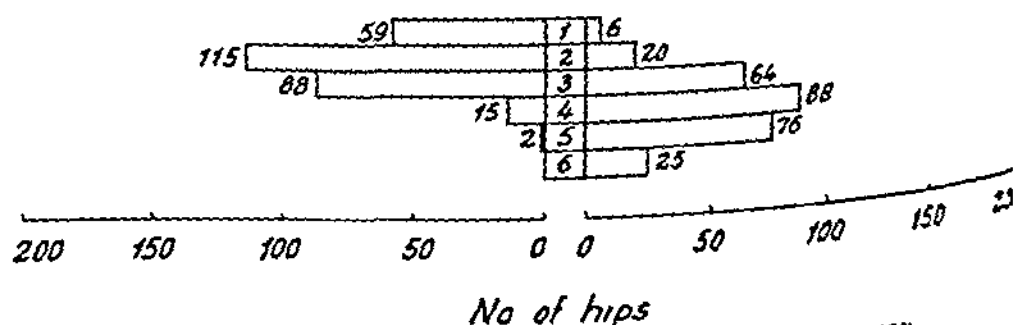


Figure 4 Grading of walking ability according to Charnley (1972).

Table 3 Local complications after 295 total hip replacements ad modum *Ring*

	Number of hips	Per cent
rficial infection	3	1 0
deep infection	2	0 7
deep infection	1	0 3
cation	1	0 3
l failure	3	1 0
ening requiring revision	12	4 1

ıbigné's method of classification, while in other results Charnley's modification of le D'Aubigné's scale has been used The age result in our material, to the nearest mal was identical using either method of ıation It is therefore possible to compare results with all of the others. Our results similar to those achieved using the more and the Charnley prosthesis. rnley has excluded those patients with r diseases affecting gait Ring (1974), in a w up after 1–5 years of 535 hips ated with the present type of prosthesis, d 'excellent' and 'good' results in 90 per of the cases. Our results show 87 per 'excellent' and 'good', and therefore ely agree with Ring's.

he complication frequency is another hod of evaluation The infection rate in results (1 per cent) agrees with Ring's per cent) Fitzgerald et al (1977) found, after a follow-up period of 2–5 years, an infection rate of 1 3 per cent among 3210 hips operated *ad modum* Charnley and in the report of Dandy & Theodorou (1975) the comparable figures were minimum follow-up 2 years, infection rate, 1 6 per cent, hips, 1042 operated *ad modum* McKee-Farrar

With an infection rate of 1 per cent we do not consider it necessary to alter the present prophylactic antibiotic treatment with penicillin We will also continue to use a standard operating theatre, without the use of a 'green house' or similar precautions.

The mortality rate was 0 3 per cent We consider the prophylactic anticoagulant treatment responsible for the fact that there were no fatal cases of thromboembolism

Loosening is a considerable problem in all types of prostheses. Dandy & Theodorou (1975) found 6 6 per cent had been revised because of loosening in 1042 McKee-Farrar

Table 4 Comparative results

	Charnley (1972)	Patterson & Brown (1972)	Mossing & Holm (1979)	Visuri et al (1977)	Lindholm & Puranen (1976)	Own results (1979)
sthesis	Charnley	McKee-Farrar	Stanmore	Brunswik	Ring	Ring
nber of lacements	379B	368A	205A	189B	40A	279A B
n	5 9	4 5	5 9	5 4	4 1	5 4
vement	5 2	4 2	5 5	4 8	4 2	5 0
lking	5 9	3 4	4 6	4 6	3 7	4 0

A Evaluated according to Merle D'Aubigné & Postel (1954)
B Evaluated according to Charnley (1972)

prostheses with a minimum follow up of 2 years. Ring (1974) found loosening that required revision in 3 7 per cent of 942 hips fitted with the Ring prosthesis. In another 535 hips also with Ring's prosthesis, he found 2 per cent that required revision after a minimum follow up of 1 year

In our material 4 1 per cent were revised because of loosening In one case the loosening was caused by osteoporosis due to high voltage radiation for a bladder cancer In nine cases it was the short femoral component that had loosened. These were all replaced by long femoral components. Three short prostheses were in functionally poor positions due to previously performed dis placement osteotomies, with a displacement of approximately 2 cm In our material 35 per cent were fitted with the short femoral com ponents. We did not, perhaps, put enough emphasis on using the largest possible pros thesis. The bone marrow cavity was therefore not adequately filled by the prosthesis. The results are clearly less satisfactory when the short prostheses were used, 8 6 per cent of these were revised because of loosening compared with only 1 per cent of the long prostheses. There are also, apart from the reoperated patients, significantly poorer results in the cases where the short compared with the long (χ^2 test $P = 0\ 05$) prosthesis was used Among 184 long pros theses there were 119 'excellent', compared with 48 'excellent' among 95 short prostheses.

Among the non reoperated prostheses there was no significant difference in the results of the patients who had radiolucent zones of at least 3 mm surrounding the prosthesis, and those who had none Patients with ectopic ossification around the prosthesis had, as expected, a significantly poorer range of movement (χ^2 test $P = 0\ 05$) As also found by Ring (1974) it was characteristic that ectopic ossification was most evident within the first 6 months, and then remained largely unchanged. Two patients who had been operated on bilaterally had an equal amount of ectopic ossification on both sides. It is therefore reasonable to suppose as did Ring that ectopic ossification is depend[illegible] constitutional conditions. We have, [illegible] case, attempted to remove ectopic bone [illegible] surgery, but the long term result was [illegible]ble

Only 12 per cent of the patients [illegible] actively employed at the time of the [illegible] up Considering that the average age of [illegible] patients at this stage was 71 years, this [illegible] so surprising Wilcock (1978), in a [illegible]pective investigation of 49 patients oper[illegible] *ad modum* Charnley has shown the [illegible] greatest advantage of total hip replacement [illegible] elderly people apart from the fact the [illegible] great number of patients became pain[illegible] that they are more capable of carrying [illegible] daily tasks. It was concluded that total [illegible] replacement contributed to improv[illegible] quality of life of the patients and the [illegible] around them while also helping to reduce [illegible] demand for community health and [illegible] services.

CONCLUSIONS

The Ring prosthesis can still be recomm[illegible]ed The results when using the short [illegible] thesis are clearly less satisfactory [illegible] therefore the long prosthesis should be [illegible] possible. In the cases where this can [illegible] done a cemented type of prosthesis shou[illegible] used Using these guidelines the results [illegible] not unlike those achieved with cemented [illegible] theses as far as the frequency of loose[illegible] requiring revision is concerned (D[illegible] Theodorou 1975 Nolan et al. 19[illegible])

The great advantage of this method is [illegible] relative ease with which the prosthesis ca[illegible] changed whether because of infection [illegible] loosening The opposite is the case with [illegible] cemented prosthesis.

ACKNOWLEDGEMENT

This study was kindly supported by [illegible] the Medical Foundation for [illegible]

RENCES

ey, J (1972) The long-term results of low-tion arthroplasty of the hip performed as a nary intervention. *J Bone Jt Surg* 54-B, 76

, D J & Theodorou, B C (1975) The nagement of local complications of total hip lacement by the McKee-Farrar technique *Bone Jt Surg* 57-B, 30–35

igne, R. M. & Postel, M (1954) Functional ults of hip arthroplasty with acrylic pros-sis. *J Bone Jt Surg* 36-A, 451–475

, C. M, Gramer, L. J & Bergfeld, J A 72) The Ring total hip prosthesis. *J Bone Surg* 54-A, 1677–1682.

rald, R. H., Nolan, D R., Ilstrup, D M, n Scoy, R. E., Washington, J A. & ventry, M B (1977) Deep wound sepsis lowing total hip arthroplasty *J Bone Jt rg* 59-A, 847–855

olm, R V & Puranen, J (1976) Ring al hip replacement in osteoarthrosis. *Acta hop scand* 47, 311–316

ng N & Holm, N J (1979) Hoftealloplastik n. Stanmore. *Ugeskr Læg* 141, 495–499

Nolan D R., Fitzgerald, R H, Beckenbaugh, R. D & Coventry, M B (1975) Complications of total hip arthroplasty treated by reoperation *J Bone Jt Surg* 57-A, 977–981

Paaby, H (1974) Follow-up of results from 11 orthopaedic-surgical departments of about 400 cases of hip arthrosis, treated with Ring's total plasty *Acta orthop scand* 45, 798

Patterson, F P & Brown, C. S (1972) The McKee-Farrar total hip replacement *J Bone Jt Surg* 54-A, 257–275

Ring, P A (1968) Complete replacement arthroplasty of the hip by the Ring prosthesis. *J Bone Jt Surg* 50-B, 720–731

Ring, P A. (1970) Replacement of the hip *Clin. Orthop* 72, 161–169

Ring, P A. (1971) Replacement of the hip joint. *Ann roy Coll Surg Engl* 48, 344–355

Ring, P A. (1973) Total replacement of the hip joint *Clin Orthop* 95, 34–37

Ring, P A. (1974) Total replacement of the hip joint *J Bone Jt Surg* 56-B, 44–58

Visuri, T, Salenius, P & Laurent, L E. (1977) Total hip replacement by the Brunswik pros-thesis. *Acta orthop scand* 48, 197–203

Wilcock, G K. (1978) Benefits of total hip replacement to older patients and the com-munity *Brit med J* 2, 37–39

spondence to Kurt Simesen, M D, Kløvervænget 26 C III th 5000 Odense Danmark

a orthop. scand. 51, 937–941 1980

JNCTION OF FIFTY-SEVEN SEPTIC, REVISED AND EALED TOTAL HIP ARTHROPLASTIES

S CARLSSON,* G JOSEFSSON** & L LINDBERG***

Department of Orthopaedic Surgery, General Hospital, University of Lund, Malmo, ** Department Orthopaedic Surgery, Gavle Hospital, Gavle, and *** Department of Orthopaedic Surgery, University ospital, Lund, Sweden

An evaluation of hip function was made 2–5 years postoperatively in 57 patients reoperated using gentamicin-containing bone cement because of deep infection after total hip arthroplasty Forty patients were completely free from pain and 17 had slight intermittent pain. Fifty-one had normal or nearly normal walking ability Most patients managed dressing and getting in and out of a bath without help It is concluded that revision in most cases offers a satisfactory solution for the patient and gives a better functional result than simple removal of the prosthesis.

Key words hip joint, arthroplasty, gentamicin

Accepted 26 iv 80

he discussion regarding infected total hip throplasties has until quite recently been cused mainly on cure of the infection Many thopaedic surgeons have advocated definive removal of the prosthesis as the best ethod of treatment (Hunter & Dandy 1977, hlgren et al 1980) It has now been shown, owever, that good results with 70–80 per cent ealing of the infection can be achieved by vision operations using gentamicin-ontaining bone cement and re-insertion of the rosthesis (Buchholz et al 1977, Carlsson et al 978, Rottger et al. 1979) A survey of the unctional rehabilitation of these revision perations is therefore now needed for comparison purposes.

A search of the literature did not reveal any detailed study concerning the function of the hip joint after revision arthroplasties for deep nfection whereas several studies of the unctional results after removal of the prosthesis have been published during recent ears (Patterson & Brown 1972, Haw & Gray 1976, Clegg 1977, Ahlgren et al 1980, Petty 1979)

The purpose of this study was to evaluate the function of the hip joint after successful revision with gentamicin-containing cement in a series of total hip arthroplasties with deep infection

MATERIAL AND METHODS

This study is part of a more comprehensive in-

[illegible]

method have been reported on in an earlier publication (Carlsson et al. 1978). Fifty-two of these 77 hips were included in this investigation. The remaining 25 were excluded, ten because of persistent infection, two owing to elevated erythrocyte sedimentation rate which suggested persistent infection, seven because of new bacteriological criteria for deep infection (Kamme & Lindberg 1980), four because of non-infectious

0001 6470.80.060937–05$02.50/0

Table 1 Method of grading functional status of the hip

Grade	Pain	Mobility* (degrees)	Walking ability
1	Severe and spontaneous	0–30°	Bedridden or only able to walk a few meters
2	Severe on attempting to walk, prevents all activity	31–60°	Walking distance very limited with or without a walking [illegible]
3	Tolerable, permits limited activity	61–100°	Limited but able to stand for long periods
4	Present only after activity, disappears quickly with rest	101–160°	Long-distance walking possible, limited without aid
5	Slight or intermittent, decreasing with activity	161–210°	Walks without aids but limps
6	No pain	More than 210°	Walks normally for age

* Passive range Sum of degrees of flexion, rotation, and abduction adduction.

loosening and two because the patients have died. To the remaining 52 hips were added five infected, revised and healed arthroplasties operated on subsequently in the participating departments. The evaluated series thus consisted of 57 hips in 57 patients where the infection was classified as healed after revision We use the term "healed", irrespective of the degree of pain, to denote hips in which wounds and sinuses are healed, where there are no radiographic signs of infections and where the sedimentation rate is normal (Carlsson et al 1978)

Twenty-nine of the patients were revised in Lund, 16 in Gavle, and 12 in Malmo The primary hip arthroplasty was performed because of osteoarthritis in 47 patients, rheumatoid arthritis in four, fracture of the femoral neck in four, ankylosing spondylitis in one and congenital dislocation in one patient At the revision arthroplasty 29 Brunswik, 14 Christiansen 9 Charnley and 5 Lubinus prostheses were inserted Forty-three of the revisions were made in one stage (immediate exchange) and 14 in two stages. The interval between removal and reinsertion in the two-stage cases averaged 12 months (range 1–41 months)

The function of the hip was assessed after 37 months on average (range 24–62 months) The mean age of the patients at the review was 67 years (range 50–80 years)

The hip function was assessed according to the numerical system of Merle d'Aubigné & Postel (1954) as modified by Charnley (1972, 1979). The modification used by Charnley means that the patients are put into three categories. The category A patient is physically fit in all respects relating to function, having no defect other than the one hip affected. In category B patients both hips are affected but the patient is otherwise physically fit Category C is reserved for [illegible] with conditions other than diseases of the [illegible] impairing the act of walking such as cardiac [illegible] sufficiency, rheumatoid arthritis, osteoarthritis [illegible] the knee etc. In our series, 27 patients [illegible] classified as category A (mean age 66 years) [illegible] category B (mean age 69 years) and 14 as category C (mean age 69 years).

The patients were examined by senior [illegible] physiotherapists without previous knowledge [illegible] the patients. The hip function, the [illegible] capacity the ability to climb stairs, the [illegible] walking aids, shortening of the leg [illegible] Trendelenburg's sign were evaluated. The [illegible] were interviewed with regard to activities of [illegible] living and need for special equipment [illegible] raised seats, high toilet seat) estimate of [illegible] walking distance and subjective opinion of [illegible] results of the revision.

FINDINGS

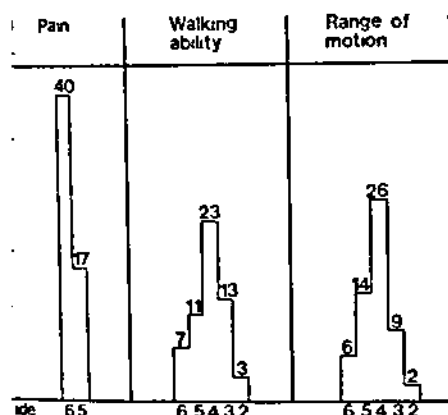
No difference was found between the [illegible] stage and two-stage operations.

The number of patients was too small [illegible] make a statistical analysis meaningful.

The findings as regards pain, walking ability and range of motion after the [illegible] arthroplasty are summarized in Figure 1

Forty patients were completely free [illegible] pain The remaining 17 had slight or [illegible] termittent pain decreasing with [illegible] The average grade for pain was 5 7

Normal gait was recorded for 7 [illegible]



number of pat ents is ind cated above the columns

re 1 Assessment of hip function according to le d'Aubigné & Postel (1954)

reas the walking ability was slightly aired in 34 patients. Sixteen patients had ted or very limited walking capacity The rage grade for this group was 4 1

The passive range of motion was more 101 degrees in 46 patients. Two patients a severely decreased range, less than 60 rees. The average grade was 4 1

The category A patients were those best ecting the hip function after revision rations, whereas in categories B and C the essment was also influenced by factors er than the operated hip (Table 2)

The walking ability was normal or nearly mal for half of the patients in category A. lf of this category also had a walking tance of more than 2 kilometres and tword managed without walking aids or with e stick outdoors.

Twenty six patients had *no shortening of e leg*, 21 a shortening less than 2 cm and 8 etween 2 and 3½ cm Two patients had a ngthening of between 1 and 2 cm of the erated leg Seventeen patients walked ithout a *limp* and 40 with a limp of varying egree Twenty three had a positive Trendelenburg sign on the revised side All atients managed to climb stairs with regular alking aids. Concerning personal *dressing* 38 atients had no difficulty in putting on rousers or stretch tights, 9 used an appliance and 10 needed help from another person Fifty-five patients could put their shoes on unaided with or without an appliance, 2 needed help from another person Thirty-nine patients managed getting in and out of a bath by themselves. A *high toilet seat* was needed by 24 patients and a *raised seat* was used by 22 patients.

The subjective opinion of the result of the operation was very satisfactory in 40 patients and satisfactory in 15 Two patients, both category C, were not satisfied

DISCUSSION

The natural history of the infected total hip arthroplasty has already been described by many authors (Salvati 1976, Hunter & Dandy 1977, Petty 1979) The outcome is in reality nearly always a loss of hip joint function, due either to removal of the prosthesis or persistent infection This is the reason why this in-

Table 2 Walking distance (estimated by the patient) need for walking aids and grade of walking ability The patients are grouped in categories A, B and C (Charnley 1972)

	Number of patients in category		
	A	B	C
Walking distance			
> 2000 m	15	3	0
2000 m – 500 m	10	9	9
500 m – 100 m	2	3	4
< 100 m	0	1	1
No walking aids	12	0	0
1 stick outdoors	6	7	2
1 stick also indoors	8	5	7
2 sticks outdoors	1	1	1
Always 2 sticks or crutches	0	3	4
Ability to walk			
Grade 6	7	0	0
Grade 5	8	3	0
Grade 4	8	8	7
Grade 3	4	4	5
Grade 2	0	1	2

vestigation was confined to revised and healed cases

Andersson (1972) compared nine different methods of assessment of hip joint function and emphasized the importance of uniformity in publishing results The Merle d'Aubigné-system as modified by Charnley (1972, 1979) is at present probably the one most used Hence this was the system of grading chosen for this investigation However, as we wished to present a more detailed report on our cases, we added a few variables

As this study was not prospective as regards the function of the revision arthroplasties the preoperative gradings were not recorded

The average grade of pain (5 7), walking (group A 4 7 and B 3 8) and range of movement (4 1) in this series can be compared with the corresponding values reported by Griffith et al (1978) in a series after primary total hip replacements which healed without infection Their material consisted of 547 hips. The postoperative mean value for pain was 5 8 For walking category A 5 8 and category B 5 4, respectively and for range of movement 4 9 The values in this report after revision arthroplasty are fairly consistent with the values reported by Griffith et al (1978) after uncomplicated, primary total hip replacements as far as pain and range of movement are concerned

Twenty-eight patients in our series had a shortening of the operated leg This demonstrated the difficulty involved in achieving full compensation for the destruction of bone often connected with a deep infection When embarking on a reoperation of this kind the orthopaedic surgeon must have a supply of different prostheses to choose between, in order to achieve the best possible result

Clegg (1977) and Ahlgren et al (1980) reported the functional results after removal of altogether 57 infected total hip prostheses. It was possible to compare their results with ours as regards some of the findings. Five of their patients used axillary crutches or were confined to a wheelchair after removal [illegible] prosthesis. This was not observed [illegible] our patients after revision arthroplasty [illegible] patients who had their prostheses [illegible] needed one or two sticks or crutches [illegible] and had a shortening of the limb [illegible] than 3 cm, in many cases up to 6 cm [illegible] series of 57 patients, 12 did not [illegible] walking aids at all and 26 had no [illegible] of the leg A shortening of up to [illegible] encountered in six cases only Another [illegible] is the rate of healing of the infection [illegible] revision with gentamicin-containing [illegible] the healing rate in our series (Carlsson [illegible] 1978) was 78 per cent, when the [illegible] patients, excluded from this [illegible] because of non infectious loosening [illegible] included among the failures [illegible] removal of the prosthesis the figure [illegible] almost the same (Hunter & Dandy [illegible] Clegg 1977, Ahlgren et al. 1980).

Petty (1979) discussed the results [illegible] patients in which the prostheses had [illegible] removed because of infection. He [illegible] all but two patients required [illegible] crutches for walking One patient [illegible] satisfied with the result of her [illegible] arthroplasty Some authors still [illegible] that a septic total hip arthroplasty [illegible] treated by removal of the prosthesis [illegible] an insertion of a new prosthesis [illegible] made only if the functional outcome [illegible] satisfactory for the patient (Slooff et al. [illegible] Vidal et al. 1977 Ahlgren et al. [illegible] Other authors (Buchholz & Gartmann [illegible] advocate revision with antibiotic-containing bone cement, preferably using [illegible] procedure The healing rate of the [illegible] between 70 to 80 per cent with this [illegible] (Buchholz et al 1977, Rottger et al. [illegible] Certainly there are cases in which [illegible] the prosthesis is the best [illegible] instance in very old patients or [illegible] repeated failed revisions. A modified [illegible] stage revision (Hovelius & Josefsson [illegible] may be preferable in other cases [illegible] those with widespread deep infection [illegible] Gram negative bacteria and/or [illegible] prehensive destruction of bone when [illegible]

...n has failed. At these revisions, the ...ens is extracted and the wound cavity ...led with gentamicin-containing poly-...l methacrylate beads for 3 to 4 weeks. A ...prosthesis is then inserted, using ...micin-containing bone cement.

...most cases the method of choice is, ...ver, the one-stage revision with ...micin-containing bone cement, per-...ed at an early stage of the infection. ...wing these operations the functional ...s will be better than after a removal of ...prosthesis.

...NOWLEDGEMENT

...work was supported by the Swedish Medical ...arch Council (Project No. K79-16P-04636-05B-...04636).

...ERENCES

...n, S. A., Gudmundsson, G. & Bartholdsson, ... (1980) Function after removal of a septic ...tal hip prosthesis. *Acta orthop. scand.* **51**, ...41–546.

...ersson, G. (1972) Hip assessment. A com-...arison of nine different methods. *J. Bone Jt Surg.* 54-B, 621–625.

...holz, H. W. & Gartman, H. D. (1972) ...fektionsprophylaxe und operative Behand-...lung der schleichenden tiefen Infektion bei der ...totalen Endoprothese. *Chirurg* **43**, 446–453.

...holz, H. W., Engelbrecht, H., Rottger, J. & Siegel, A. (1977) Erkenntnisse nach Wechsel ...von über 400 Infizierten Huftendoprothesen. *...Orthop. Prax.* **12**, 1117–1120.

...sson, A. S., Josefsson, G. & Lindberg, L. (19..) Revision with gentamicin impregnated ...cement for deep infections in total hip ...arthroplasties. *J. Bone Jt Surg.* 60-A, 1...9–1064.

...rnley, J. (1972) The long-term results of low ...friction arthroplasty of the hip performed as a ...primary intervention. *J. Bone Jt Surg.* 54-B ...61–76.

Charnley, J. (1979) *Low friction arthroplasty of the hip. Theory and practice*. Springer Verlag Berlin, Heidelberg, New York.

Clegg, J. (1977) The results of the pseudoarthrosis after removal of an infected total hip prosthesis. *J. Bone Jt Surg.* 59-B, 298–301.

Griffith, M. J., Seidenstein, M. K., Williams, D. & Charnley, J. (1978) Eight year results of Charnley arthroplasties of the hip with special reference to the behaviour of cement. *Clin. Orthop.* **137**, 24–36.

Haw, C. S. & Gray, H. (1976) Excision arthroplasty of the hip. *J. Bone Jt Surg.* 58-B, 44–47.

Hovelius, L. & Josefsson, G. (1979) An alternative method for exchange operation of infected arthroplasty. *Acta orthop. scand.* **50**, 93–96.

Hunter, G. & Dandy, D. (1977) Diagnosis and natural history of the infected total hip replacement. *The hip* pp. 176–191. The C. V. Mosby Comp., Saint Louis.

Kamme, C. G. & Lindberg, L. (1980) Aerobic and anaerobic bacteria in deep infections after total hip arthroplasty. Differential diagnosis between infectious and non-infectious loosening. *Clin. Orthop.* (In press).

Merle d'Aubigne, R. & Postel, M. (1954) Functional results of hip arthroplasty with acrylic prosthesis. *J. Bone Jt Surg.* 36-A, 451–475.

Pattersson, E. P. & Brown, C. S. (1972) The McKee Farrar total hip replacement. Preliminary results and complications of 368 operations performed in five general hospitals. *J. Bone Jt Surg.* 54-A, 257–275.

Petty, R. W. (1979) The results of resection arthroplasty for the treatment of infected total hip arthroplasty. Annual meeting of the Amer. Acad. Orthop. Surg., San Francisco.

Rottger, J., Buchholz, H. W., Engelbrecht, E. & Siegel, A. (1979) Erbgebnisse beim Prothesenwechsel unter Verwendung von Refobacin-Palacos in Hamburg. *Akt. Probl. Chir. Orthop.* **12**, 211–213.

Salvati, E. (1976) Infection complicating total hip replacement. *The hip* pp. 200–218. The C. V. Mosby Comp., Saint Louis.

Slooff, T. J., Schaapsmeerders, F., Van de Sandt, H. M. & Van Rens, Th. (1976) Treatment of forty loosened total hip replacements. *Acta orthop. belg.* **42**, 492–500.

Vidal, J., Escare, P. & Buscayret, Ch. (1977) Reste-t-il une place pour le resection tête el col du femur a l'epoque des prosthèses de hanche? *Rev. Rhum.* **44**, 395–401.

...respondence to: Lars Lindberg M.D., Department of Orthopaedic Surgery, University Hospital, S-...5 Lund, Sweden.

rthop scand. 51 943–948 1980

ETABULAR PROTRUSION FOLLOWING DOPROSTHETIC HIP SURGERY: MULTIFACTORIAL STUDY

O SØREIDE, JOSTEIN LILLESTØL, ANTTI ALHO
ONDRAD HVIDSTEN

artments of Surgery and Diagnostic Radiology University Hospital of Bergen, Norway and the
weg an School of Economics and Business Administration, Bergen Norway

Acetabular protrusion was found in 56 out of 211 patients fitted with a hemiprosthesis. The indication for operation was acute femoral neck fracture or failure following a previous internal fixation. A number of radiological variables were analysed with respect to their possible association with preoperative, operative and follow up variables. After a preliminary screening of variables a deeper analysis was performed by fitting

who now receive a hemiprosthesis as a secondary operation. Acetabular protrusion was significantly associated with the development of postoperative pain, while the other clinical symptoms and signs lacked any direct association with protrusion. Although acetabular protrusion and loosening of the prosthetic stem showed a significant association the analysis indicated that pain was primarily due to protrusion.

Key words acetabular protrusion hip prosthesis

Accepted 13 v 80

imary prosthetic replacement has become a pular method of treatment for acute moral neck fractures and is now recognized f many authors as the treatment of choice e elderly patients (Johnson & Crothers 1975, & Devas 1976 Whittaker et al 1972) Acetabular protrusion is a well recognized finding which has been linked to the of late pain and dysfunction Arcy & Devas 1976 Andersson & Moller 1972). However, very few authors presented details concerning the ce and clinical relevance of the ogical findings.

This study has been performed to answer the following questions 1 Are there preoperative and operative variables that can be related to protrusion, and if so what is their relative importance? 2 How does increasing follow up time affect protrusion? 3 Can we find some association between the various clinical variables and possibly link them with protrusion?

MATERIAL AND METHODS

The clinical and radiological data of 211 patients who had been fitted with Christiansen's hemiprosthesis (Søreide et al. 1975) during the

64 0.80 060943 06$02.50 0

period 1971–1978 and had been followed up for from 1 month to 7 years postoperatively were recorded The indication for operation was acute femoral neck fracture in 173 patients and failure following previous hip operation (mostly internal fixation) in 38 patients.

The most recent X-ray films available for each patient were compared with the first post operative X-ray films for that patient Acetabular protrusion was measured in millimeters as seen in the antero-posterior view Variations in the magnification effect between the first and the most recent antero-posterior X ray films were minimal (10–20 per cent) and did not affect the measurements. *No effort was made to separate the* collapse of cartilage from other types of prosthetic migration

Relevant data concerning preoperative status, indication for operation the operative and clinical results at the time of the latest available radiological examination as well as the follow up time were recorded A total of 52 different variables were available and were prepared for computer analysis

Statistical analysis

The variables under study here are given in [illegible] 1 variables 2–13 are preoperative oper[illegible] planatory variables and 14–19 are [illegible] up variables.

Information about variables which [illegible] importance was obtained by pairwise [illegible] the variables (mostly dichotomies) The [illegible] for testing no association based on [illegible] statistics were used as a screening device [illegible] relationship between the variables was [illegible] elucidated by analysing various [illegible] frequency tables by fitting log linear models [illegible] observations (Fienberg 1977 Søreide et al [illegible] The main purpose was to uncover and [illegible] the effects of each variable direct [illegible] between pairs of variables and higher [illegible] interactions between more than two [illegible] An interaction is in this paper regarded as [illegible] when the effect parameter in the log-linear [illegible] magnitude twice that of the standard error [illegible] greater weak if it is of lesser magnitude [illegible] greater than the standard error The [illegible]

Table 1 Variables under study

Variable	Categories	
1 *Protrusion*	*No (0)*	Yes (1)
2 Indication for operation	Acute fractures (0)	*Old fractures* (1)
3 Walking ability before operation	Normal (0)	Limited (1)
4 *Previous hip* operation	No (0)	Yes (1)
5 Incision used	Anterolateral (0) (*Watson Jones*)	*Posterolateral* (1) (Osborne)
6 Fixation	Normal (0)	Others (1)
7 Infection	No (0)	Yes (1)
8 Follow up time	0–12 *months* (0)	> 12 months (1)
9 Type of hemi prosthesis	Short stem (0)	Long stem (1)
10 Ectopic ossification	No (0)	Yes (1)
11 Quantity of cement	Not optimal (0)	Sufficient (1)
12. Position of femoral stem	Varus (0)	Neutral (1) Valgus (2)
13 Age at the operation	≤ 75 years (0)	> 75 years (1)
14 Personal opinion	Good (0)	Not satisfactory (1)
15 Ability to walk	Normal (0)	Restricted (1)
16. Pain	No (0)	Yes (1)
17 Range of movement	Good (0)	Restricted (1)
18 Varus migration	No (0)	Yes (1)
19 Distal migration	No (0)	Yes (1)

.tions were performed with the ECTA-
gram package implemented on the UNIVAC-
} installation at the University of Bergen.

-SULTS

otrusion and preoperative/operative planatory variables

the 211 patients studied, 56 (26 per cent) re found to have acetabular protrusion nging from 1–19 mm (mean 5 3 mm) The velopment of protrusion showed a signifi- nt time-dependency ($P<0\ 01$) and the quency table demonstrating the develop- ent of protrusion in relationship to the low up time is given in Table 2 During e first year a frequency of protrusion of 8 9 r cent was noted This increased to 28 2 r cent during the second year After 4 or ore years of follow-up, acetabular protru- on was found in 54 3 per cent of the tients, and in nearly half of these patients, e protrusion was greater than 5 mm.

Acetabular protrusion was significantly sociated with previous hip operation ' 0 04) Sixteen out of 39 patients (41 per nt) previously operated showed protrusion, hereas only 40 of the 172 patients (23 per nt) without previous hip operation veloped protrusion The other explanatory riables showed no significant association ith protrusion ($P>0\ 10$)

A log linear analysis of a three-way table volving the parameters protrusion follow- p time and previous hip operation assuming no interaction between follow-up time and previous hip operation and no higher order interaction, gave good fit to the data The variable age at the time of operation could theoretically be of importance in explaining protrusion However, a four-way log-linear analysis showed that age can be excluded as an explanatory variable for the development of protrusion

Protrusion and the clinical results

Protrusion was analysed in relationship to the clinical variables 14–17 The pairwise analyses showed that protrusion had a signifi- cant association with pain and the patient's personal opinion ($P<0\ 01$) but neither to ability to walk or to range of movement ($P>0\ 10$) We also found significant associations between most pairs of the clinical variables.

The possible interactions between protru- sion and the clinical variables were further studied by fitting log-linear models to the 5- way table to the observations. The model schematically displayed in Figure 1 gave good fit to the data. It assumes no direct interac- tion between the variables not connected in the figure and no higher order interactions. Personal opinion shows a positive direct association with both pain and range of movement and also though somewhat weaker with walking ability There is no significant direct association between pain and range of movement, and between ability to walk and range of movement but possibly

Table 2 Follow-up time (in months) and degree of protrusion (in mm) (Row-wise relative frequencies in parenthesis)

Follow-up time	Protrusion 0	1–5	6–20	Sum
1–12	93 (91 2)	7 (6 9)	2 (2.0)	102
13–24	33 (71 7)	10 (21 7)	3 (6.5)	46
25–48	13 (46 4)	8 (28 6)	7 (25 0)	28
49–	16 (45 7)	10 (28 6)	9 (25 7)	35
Sum	155 (73 5)	35 (16 6)	21 (10 0)	211

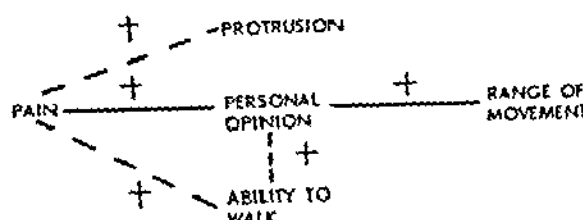


Figure 1 Associations between acetabular protrusion and clinical variables

a weak direct association between pain and ability to walk. The variable personal opinion seems to pick up three different aspects of the clinical status. The ability to walk seems to be the least important factor in determining the patient's personal opinion Protrusion was not directly linked to personal opinion, or to ability to walk and range of movement Consequently the association between protrusion and personal opinion revealed in the two-way analysis above is attributable to their common association to pain Pain appears as the best clinical parameter for protrusion

Protrusion, loosening of the prosthetic stem and pain

A pairwise analysis showed that the variables related to loosening of the prosthetic stem, varus and distal migration both had significant association ($P<0\cdot01$) with protrusion and they are strongly related ($P<0\cdot01$) Varus migration had some association with the patients personal opinion and with pain ($P<0\cdot05$) whereas distal migration showed no association with the clinical variables.

A log linear analysis involving the variables distal and varus migration protrusion and pain showed a positive association between distal migration and protrusion but not between varus migration and protrusion In addition a second order interaction for the group distal migration varus migration and protrusion was found This means that varus migration interacts with protrusion only if it occurs in conjunction with distal migration (as it often does) The migration variables were linked to pain via protrusion It appears that in patients who have both protr[...] and loosening of the stem, protrusion is the main pain inducing factor

DISCUSSION

Despite numerous papers presenting [...] clinical results and radiological fin[...] following endoprosthetic surgery, the amo[...] of information available on acetabular protr[...]sion is limited

The usual manner of studying [...] problems has been a pairwise analysis of [...] variables Although this often leads [...] important insights, the results must be [...] with care One can easily misinterpret [...] marginal relationships between pairs of variables when other variables are present and may interact A two-dimensional analysis does not provide the needed insight [...] these possible interactions. We have found the fitting of multidimensional log-linear models to our data very helpful in order to disclose such interactions among the variables.

In the present study protrusion was [...] to be clearly time-related This is in [...] agreement with a previous study in [...] hospital (Søreide et al. 1979) as well as [...] the findings of Whittaker et al. (19[...]).

The reported incidence of acetabular [...]trusion following surgery varies from 3[...] (Lindholm et al. 1976) to 50 per cent (Danielson 1965). Such figures are of [...] value as the observation time varies [...]siderably The time-related [...] presented in Table 2 could be proposed [...] important However our data should be [...] with care in this respect. It is possible [...] some selection occurred due to more freq[...] follow up examinations of patients with [...]trusion (note the close association [...] postoperative pain), which may lead [...] longer follow-up time With these [...]siderations in mind, we have found [...] incidence of protrusion of approximately [...] per cent after 4 or more years of [...] This is an alarming figure especially [...]

e note the association between protrusion . In view of the fairly long survival of . treated with primary prosthetic eplacement for acute femoral neck fractures Søreide & Lillestøl, in press), the question of whether primary prosthetic replacement is indicated, especially in patients below the age f 80, should be seriously discussed Stable fixation of a well-reduced subcapital appear to be the preferable lternative It is clearly of interest to model a elationship where the probability and degree f protrusion is expressed in terms of other ovariates found to be significant Models of he logistic type may be helpful here

We observed that the follow-up time was not the only factor which influenced the occurrence of protrusion Protrusion was also clearly correlated with previous operation(s) on the hip On this basis a total hip replacement may sometimes have to be considered instead of a hemiprosthesis.

We could not demonstrate any direct or indirect effect of age of the patient on the development of protrusion. This seems to be in conflict with the findings of D'Arcy & Devas (1976) and Dickreuter (1978) who stated that protrusion was more common in younger patients. Their findings may be explained by the longer life expectancy and greater demands of the young patients.

In several earlier studies pain has been the most prominent symptom associated with acetabular protrusion (Coventry 1964, Peyer 1971, Lindholm et al 1976, Sarmiento & Gerard 1976) On the other hand, D'Arcy & Devas (1976) and Barr et al (1964) reported that the severity of symptoms did not always correspond with the radiographic changes, while Hinchey & Day (1964), Whittaker et al (1972) and Johnson & Crothers (1975) were concerned about the lack of correlation between the clinical results and protrusion The present study supports the observation that protrusion is associated with pain In addition we found interesting links between pain and clinical variables with no direct association with protrusion

We found that variables related to loosening of the prosthetic stem were significantly associated with protrusion This reflects the occurrence of protrusion and loosening of the stem simultaneously, which may simply indicate a time dependency Our analysis also indicates that in patients with both protrusion and loosening of the prosthetic stem, protrusion is the most pain-inducing factor This has to be kept in mind when planning a reoperation.

REFERENCES

Andersson, G & Moller-Nielsen, J (1972) Results after arthroplasty of the hip with Moore's prosthesis. *Acta orthop scand.* **43**, 397–410

Barr, J S, Donovan, J F & Florence, D W (1964) Arthroplasty of the hip Theoretical and practical considerations with a follow-up study of prosthetic replacement of the femoral head at the Massachusetts General Hospital *J Bone Jt Surg* 46-A, 249–266

[illegible] *orthop scand* **35**, 348–357

D'Arcy, J & Devas, M (1976) Treatment of fractures of the femoral neck by replacement with the Thompson prosthesis. *J Bone Jt Surg* 58 B, 279–286

Dickreuter, W (1978) Indikation und Spatresultate bei Versorgung von Schenkelhalsfrakturen mit Kopfendoprosthese *Helv chir Acta* 45, 403–411

Fienberg S E (1977) *The analysis of cross-classified categorical data* The MIT Press.

Hinchey J J & Day P L (1964) Primary prosthetic replacement in fresh femoral neck fractures. A review of 294 consecutive cases *J Bone Jt Surg* 46-A 223–240

Johnson J T H & Crothers C (1975) Nailing versus prosthesis for femoral neck fractures. A critical review of long term results in 239 consecutive private patients *J Bone Jt Surg* **57-A** 686–692

Lindholm R V Puranen J & Kinnunen, P (1976) The Moore vitallium femoral head prosthesis in fracture of the femoral neck *Acta orthop scand* **47**, 70–78

Peyer J (1971) Zur Frage der Pfannenwanderung nach Implantation von Kopfendoprothesen am Hüftgelenk *Helv chir Acta* **38**, 381–388

Sarmiento, A & Gerard, F M (1978) Total hip arthroplasty for failed endoprostheses. *Clin. Orthop* **137**, 112–117

Søreide, O, Lerner, A P & Tunold, J (1975) Primary prosthetic replacement in acute femoral neck fractures. *Injury* **6**, 286–293

Søreide, O, Mølster, A. & Raugstad, T S (1980) Replacement with the Christiansen endoprosthesis in acute femoral neck fractures. A 5-year follow-up study *Acta orthop scand* **51**, 137–144

Søreide, O & Lillestøl, J (1980) Survival patterns following primary prosthetic [illegible] acute femoral neck fractures [illegible] *Scand J soc Med* (In press)

Søreide, O (1980) Treatment of [illegible] neck fractures in the elderly [illegible] the internal fixation-prosthetic [illegible] controversy Thesis, Bergen, 1980 [illegible]

Whittaker, R. P., Abeshaus, M. M., [illegible] & Chung C. M. K. (1972) [illegible] perience with metallic endoprosthesis [illegible] ment of the femoral head for [illegible] fractures. *Trauma* **12**, 799–806

Correspondence to Odd Søreide, M D, Department of Surgery, University of Bergen, [illegible] Haukeland Sykehus, Norway

Acta orthop scand. 51, 949–962, 1980

UNSTABLE TROCHANTERIC FRACTURES

A Comparative Analysis of Four Methods of Internal Fixation

STEEN JENSEN, S SONNE-HOLM & E TØNDEVOLD

Departments of Orthopaedic Surgery T-2 & T-3, Gentofte Hospital, Department of Orthopaedic Surgery A Frederiksberg Hospital and Department of Orthopaedic Surgery U, Rigshospitalet, University of Copenhagen, Denmark

Deep infection was encountered in 2.5 per cent of the cases following surgery in the hip region and in 3 3 per cent of the Ender nailings.

Statistical analyses showed that the quality of the reduction was determined by the comminution of the fracture, and the technical failure of fixation or secondary displacement of the fracture was determined by the quality of the reduction

Sliding screw-plate fixation was found to be the only suitable fixation method for unstable trochanteric fractures, because of a low failure rate, a low re-operation rate and the possibility of secondary impaction without disturbing the fracture union

Key words fractures, internal fixation, femoral neck fractures, internal fixation

Accepted 21 ii 80

The internal fixation of unstable trochanteric fractures is primarily a mechanical problem (Dimon 1973, Fielding 1973, Frankel 1963, Johnston 1973, Jensen 1980 a, b, Jensen et al 1978, Kaufer et al 1974, Sonstegard et al 1974) The instability of the fractures is due to lack of bony support over the medial aspect of the femur, because the lesser trochanter and part of the calcar femorale are missing from the mechanical load transmission system Another cause of instability is posterior detachment from the greater trochanter, resulting in mechanically unreliable reduction with anterior diastasis (Evans 1949, Jensen 1980 d)

The modern trend in the postoperative management of hip fractures in the elderly is early mobilization with full weight-bearing (Ainsworth 1971, Bosacco et al 1973, Jensen et al 1978, Parker & Reitmann 1976, Rennie & Mitchell 1976, Sahlstrand 1974, Sarmiento & Williams 1970) This makes great demands on both the implant and the osteoporotic bone

The purpose of the present study was to compare the results of the internal fixation of trochanteric fractures treated with Jewett or McLaughlin nail plates, the sliding screw-plate or by condylocephalic nailing according to Ender In the present paper only unstable trochanteric fractures (Evans 1949, Jensen 1980 d) will be considered The results obtained with stable fractures are reported in a separate paper (Jensen et al. 1980)

0001-6470 80 060949-14 $02.50 0

PATIENTS AND METHODS

During the period April 1st 1971 to June 30th 1979 a total of 1 646 patients with trochanteric fractures were admitted to the four departments of orthopaedic surgery participating in the study There were 1 225 cases of unstable fractures according to the Evans classification system (Evans *1949* Jensen *1980* d) *503* were 3 fragmentary without postero-lateral support 188 were 3 fragmentary without medial support and 564 were 4-fragmentary fractures

Nineteen patients were treated by other methods, 140 died before fracture union and 25 were lost to follow up This study thus includes 1 071 patients treated by one of the four methods and followed radiologically until fracture union or technical failure were encountered

The fracture reduction was evaluated from the postoperative X rays Anatomical reduction was defined as a diastasis of 4 mm or less over the fracture line Fracture diastasis of 5 mm or more was looked for medially or laterally in the AP projection and anteriorly or posteriorly in the lateral projection The nail plate angles were measured as well as the distance from the nail tip to the bone confinements The fractures were X-rayed regularly until fracture union with registration of the occurrence of technical failures, telescoping of the sliding screw plate or distal sl pping of the Ender nails with or without secondary dislocation of the fracture Technical failures were defined as any complicating fracture bend ng or breakage of the implant or dislocation of the implant in relation to the bone *All X-rays* were evaluated by the three authors. Furthermore the rates of deep infection or osteitis non union and re-operations were recorded Prophylactic antibiotics were not applied

In the statistical evaluation of the results multivariate logistic analysis as well as multiple contingency table analysis with successive [illegible] described by Madsen (1976) were applied.

The median age of the patients at the [illegible] examination was 79 years (range 24–10[illegible]) and the mean age 76 ± 11 years (s.d.). Females [illegible] 78 per cent (837/1 071) of the patients.

RESULTS

A multiple contingency table analysis [illegible] that the number of unstable troch[illegible] fractures increased with age ($P < 0.00$[illegible] especially in females.

The distribution of the four methods of treatment in relation to the three types of fracture is shown in Table 1

Deep infection or osteitis was enc[illegible] in 3 4 per cent (10/293) following McL[illegible] nail plate fixation in 2 3 per cent ([illegible] after Jewett and 2.0 per cent (7/3[illegible]) [illegible] sliding screw-plate fixation. The t[illegible] infection rate following surgery in the h[illegible] region was thus 2.5 per cent ([illegible] whereas the infection rate was 3.3 per cent (4/123) following Ender nailing and [illegible] to the knee region These differences [illegible] significant ($P = 0 8$ Chi square test).

The quality of the fracture reduction [illegible] relation to the method of fixation and the nail plate angles applied is listed in Table 2 A multiple contingency table analysis [illegible] that the quality of reduction was [illegible] determined by the comminution of the fracture ($P < 0.00005$) This means that the 4-fragmentary fractures were more [illegible] *reduced* with diastasis than the 3-fragmentary The quality of reduction was

Table 1 Treatment of unstable trochanteric fractures

Fracture type	McLaughlin nail plate	Jewett nail plate	Sliding screw plate	Ender nailing	Total
3 fragmentary ÷ postero-lat support	128	116	152	43	[illegible]
3 fragmentary ÷ medial support	56	36	42	12	[illegible]
4-fragmentary	109	157	152	69	[illegible]
Total	293	309	346	123	[illegible]

Table 2 Quality of reduction and applied nail plate angles

Reduction	McLaughlin nail plate	Jewett nail plate	Sliding screw plate	Ender nailing	Total
Anatomical in both planes	69 (24%)	102 (33%)	99 (29%)	29 (24%)	299 (28%)
Diastasis in lateral plane	46 (16%)	53 (17%)	75 (22%)	25 (20%)	199 (19%)
Diastasis in AP plane	57 (19%)	62 (20%)	40 (11%)	21 (17%)	180 (17%)
Diastasis in both planes	121 (41%)	92 (30%)	132 (38%)	48 (39%)	393 (37%)
Nail-plate angles					
≤139°	95	43	264		
≥140°	198	266	82		

also correlated with the method of treatment ($P < 0.004$) Fractures treated according to McLaughlin or Ender were reduced with diastasis more frequently than those treated by the other methods

The results of the treatment of unstable trochanteric fractures are listed in Table 3 Union in the postoperative position was obtained in 43 per cent of cases (458/1 071) In 60 per cent (208/346) of sliding screw-plate fixations secondary displacement through telescoping of the screw was experienced and union was obtained in the resulting position with bony contact Secondary displacement following Ender nailing was observed in 42 per cent (52/123) of cases with distal slipping of the nails In an additional 11 per cent (13/123) the distal slipping of the nails occurred without fracture displacement In most instances the distal slipping caused knee pain

Non union was observed in 0 7 per cent (2/293) of the McLaughlin cases and in 2 per cent (6/309) of the Jewett cases, but in none of the fractures treated with sliding screw-plate fixation or Ender nailing

Table 3 Results of treatment of unstable fractures

Result	McLaughlin nail plate	Jewett nail-plate	Sliding screw plate	Ender nailing	Total
Union in post operative position	137 (47%)	156 (50%)	117 (34%)	48 (39%)	458 (43%)
Secondary displacement with union			208 (60%)	52 (42%)	260 (24%)
Non-union	2 (0 7%)	6 (2%)	—	—	8 (0 7%)
Technical failure	154 (53%)	147 (48%)	21 (6%)	23 (19%)	345 (32%)
Total	293	309	346	123	1 071

Technical failures were encountered in 53 per cent (154/293) following McLaughlin fixation A total of 175 technical failures were observed, as listed in Table 4 In 30 per cent (88/293) isolated failure of the nail-plate junction was seen (Figure 1) Implant failures occurred in a total of 38 per cent (110/293) of the cases The remaining failures were due to osteoporosis allowing the nail tip to move within the femoral head or neck confinements or to penetrate them (Figure 2) A combination of implant failure and failure due to osteoporosis thus occurred in 21 cases. The technical failures caused a varus dislocation of 10° or less in 22 per cent (63/293) and of 20° or more in 25 per cent (74/293) of the cases The remaining fractures impacted without varus dislocation Re-operations were performed in 17 per cent (50/293) of the cases following McLaughlin fixation In 9 per cent (26/293) the re-operations were caused by implant failure The remaining re-operations were due to infection or to penetration or severe varus dislocation

Jewett nail-plate fixation was followed by technical failure in 48 per cent (147/309) of the patients, representing 161 failures, as listed in Table 4 Implant failure was observed in 5 per cent (16/309) of the cases (Figure 3) The majority of failures were due to osteoporosis of the femoral head or neck (Figure 4). Varus dislocation of 10° or less was observed in 8 per cent (26/309) and of 20° or more in 12 per cent (36/309) of the cases. Re-operations were performed in 12 per cent (37/309) of the cases. Only 2 per cent (7/309) were due to implant failure, whereas the remainder were caused by infection, penetration or severe varus dislocation.

Sliding screw-plate fixation was followed by technical failure in 6 per cent (21/349) of the cases, as listed in Table 4 Implant failure was experienced in only one case, the remaining cases being due to osteoporosis. Secondary impaction with telescoping of the nail was encountered in 60 per cent (205/349) of the cases (Figure 5). Varus dislocation of 10° or less occurred in 2 per cent (6/349) and

Table 4 Technical failures following internal fixation of unstable fractures

	McLaughlin nail plate	Jewett nail plate	Sliding screw plate	Ender nailing	Total
Migration/cutting < 10 mm	25	63	1	4	93
Migration/cutting > 11 mm	4	5	2	1	12
Penetration of fem head	9	31	2	13	[illegible]
Penetration of acetabulum	15	33	3	1	[illegible]
Cutting through fem head	12	13	12	1	[illegible]
Failure of nail plate junct	100				100
Nail bent or broken	7	12	—	—	19
Plate loose	1	2	1	—	4
Plate bent or broken	2	2	—	—	4
Number of patients	154	147	21	20	362
Varus dislocation < 10°	63	26	6	3	[illegible]
Varus dislocation > 20°	74 (25%)	36 (12%)	13 (4%)	6 (5%)	129 ([illegible])
Re-operations	50 (17%)	37 (12%)	11 (3%)	51 (41%)	149 ([illegible])

Figure 1 A A 3 fragmentary fracture without postero-lateral support reduced with diastasis medially and anteriorly

Figure 1 B Failure of the nail plate junction with fatigue fracture of the washer following ...tion.

Figure 2 A. A 4-fragmentary fracture reduced with diastasis medially and anteriorly



Figure 2 B. Secondary impaction of the fracture followed by penetration of the femoral head





Figure 3 A 3-fragmentary fracture reduced with medial and anterior diastasis Weight bearing led to bending of the Jewett nail and varus dislocation of the fracture






Figure 4 Unstable reduction of a 3 fragmentary fracture without postero-lateral support. W[illegible] bearing was followed by penetration and varus dislocation



Figure 5 A 4 fragmentary fracture reduced with medial diastasis Weight-bearing was followed impaction of the fracture facilitated by telescoping of the implant until bony support was ob...

of 20° or more in 4 per cent (13/346) Re-operations were performed in 3 per cent (11/346) of the cases due to penetration and

three cases supracondylar or femoral shaft fractures were sustained during the nailing procedure All the remaining failures were due to movement of the nail tips in the os-

cases, in 42 per cent (52/123) in connection with secondary fracture impaction, as demonstrated in Figure 7 The re-operation rate was 41 per cent (51/123) because of technical failure, infection or knee problems in connection with distal slipping of the nails.


Secondary fracture dislocation and technical failures were observed within the first 4 weeks following the operation in 79 ... cent (481/605) of the cases. An additional ... per cent (114/605) were encountered be... the 12th week and only 2 per cent after t... time

Technical failures or secondary displa... ment followed bi plane anatomical redu... in 17 per cent (51/299) of the cases. The r... increased to 82 per cent (322/393) of fract... with diastasis in both planes. Diastasis in t... AP projection was responsible for the d... placement in 62 per cent (112/1?0) of ... cases, compared with 59 per cent (11?/1... following diastasis in the lateral projection.

A multivariate logistic analysis revea... that fracture diastasis following the reduc... was the main cause of secondary displace... ment or technical failures ($P < 0.0005$, ... fracture type as such determined the qua... of reduction ($P < 0.00005$). A ... contingency table analysis revealed highly sig...




gure 6 A Unstable reduction of a 4 fragmentary fracture with medial and anterior diastasis



cant correlations ($P < 0.0005$ to 0.035) between the method of treatment and the positioning of the implant as regards the angle and the position of the nail tips in relation to the femoral head confinements. Further multivariate logistic analyses showed that the method of treatment ($P < 0.0005$) and the position of the nail tip influenced the rate of technical failures and secondary displacement ($P < 0.001$) This means that a mechanically reliable reduction of the fracture is the primary safe-guard against technical failures, and that even the distance from the nail tip to the bone confinements is important and should be between 11 and 15 mm. If anatomical reduction cannot be achieved the sliding screw plate is the only method to avoid complications

Figure 6 B Weight bearing followed by penetration of the nails and varus dislocation of the fracture until bony support is obtained



Figure 7 A Unstable reduction of a 4-fragmentary fracture with medial and anterior das

DISCUSSION

Internal fixation of hip fractures with nail-plate implants has been claimed to be followed by fairly high infection rates (Tengve & Kjellander 1978), but the infection rate of 2.5 per cent in the present series confirms the figures given in several other previous observations (Jensen & Michaelsen 1975, Laskin et al 1979, Mulholland & Gunn 1972, Sarmiento 1963), whereas 3.3 per cent of the Ender nailings were followed by in-fect [illegible]

[illegible] internal fixation is to achieve a mechanically reliable fracture reduction (Clawson 1957, Kennedy et al 1957) and consequently a classification system taking these difficulties into account must be applied for t[illegible] parison of the results obtained by [illegible] methods (Jensen 1980 d). In the prese[illegible] the fractures were classified acco[illegible] detachments from the lesser or [illegible] trochanter (Evans 1949, Jensen 19[illegible] highly significant correlation was [illegible] between the fracture type and the p[illegible] of achieving sufficient fracture r[illegible] (Jensen 1980 d), thus only 25 pe[illegible] unstable fractures were anatomically [illegible] in both planes.

As every X-ray was described by t[illegible] authors according to the same clas[illegible] system a comparison of the results [illegible] different types of treatment is per[illegible] Mistakes in the comparison caused [illegible] retrospective, uncontrolled design [illegible] minor importance, as this is a ra[illegible] study and thus unbiased by the author[illegible]



gure 7 B *Weight bearing was followed by varus dislocation and distal slipping of the nails, causing* ee *complaints A supracondylar bone fragment had even broken off during the nailing procedure*

Technical failures following McLaughlin ration of unstable fractures have been ported in 20–46 per cent (Bremner & raham 1958, Clawson 1957, Foster 1958, nedenberg et al 1972, Jensen & Michaelsen 975, Laros & Moore 1974, McLaughlin & arcia 1955) In the present series a total of per cent technical failures were countered About one-third of the failures ere due to displacement of the nail tip in lation to the osteoporotic bone and in about e-half of these cases the nail protruded rough the bone Two-thirds of the failures ere, however, implant failures, the vast ajority caused by varus dislocation at the il plate junction Biomechanical studies nsen 1980 a,b) showed that loosening of e nail-plate junction in McLaughlin implants occurs at loads of less than 30 kg At normal level walking the hip joint load is about three to five times the body weight (Paul 1976, Rydell 1966), thus greatly exceeding the holding power of the nail-plate junction As the implant is obliged to transmit the hip joint load to the femoral shaft in inadequately reduced trochanteric fractures, the McLaughlin nail-plate is unsuitable for the internal fixation of unstable trochanteric fractures

The failure rate of Jewett nail plate fixation of unstable fractures has been reported to range from 14–51 per cent (Boyd & Griffin 1949, Dimon & Hughston 1967, Evans 1951, Fielding 1973, Jacobs et al 1976, Johnson et al 1968 Kyle et al 1979, Laros & Moore 1974, Morrison et al 1978 Parker 1955,

Robey 1956) In the present series technical failures were observed in 48 per cent of cases. Less than 10 per cent were due to implant failures The failure load of Jewett nail plates has been reported to be about 100 kg (Jensen 1980 a) *The vast majority of failures with these implants are due to displacement of the nail tip, which often protrudes through the osteoporotic bone* As secondary fracture impaction takes place until bony contact over *the fracture line is achieved, the implant must* either give way or protrude through the bone Alterations in the operative technique using a shorter Jewett nail might solve the problems of penetration, but lead to a greater number of cuttings with varus dislocation (Boyd & Griffin 1949, Evans 1951) Consequently the Jewett nail plate cannot be recommended for the internal fixation of unstable trochanteric fractures

The sliding screw-plate was originally designed with the aim of allowing secondary fracture impaction (Clawson 1964) The telescoping is often painful and followed by leg shortening of 1–2 cm (Clawson 1964, Ecker et al 1975, Harrington & Johnston 1973, Jensen et al 1978, Laskin et al 1979) In the present series secondary impaction was experienced in about 60 per cent of cases but technical failures occurred in only 6 per cent This low failure rate is consistent with other publications (Clawson 1964, Doherty & Lyden 1979, Ecker et al 1975, Harrington & Johnston 1973, Jacobs et al 1976, Jensen et al 1978 Mulholland & Gunn 1972) Implant failures are extremely rare, which can be explained by a high failure load which exceeds the hip joint load at walking (Paul 1976, Rydell 1966) at least after telescoping (Jensen 1980 c) The failures experienced are displacements and protrusion of the screw tip through the osteoporotic bone Friedenberg et al (1972) reported this to occur in 19 per cent of cases, but as in the present series re-operations were necessary in only 3 per cent Jacobs et al (1976) found the sliding screw-plate fixation to be significantly better than the Jewett nail-plate The present series confirmed this and also found the former method to be better than McLaughlin nail-plate fixation and Ender nailing

In 1970 an internal fixation system with intramedullary rods for trochanteric fractures was introduced (Ender 1970, Ender & S[illegible] Weidner 1970, Simon Weidner 19[illegible]) Th[illegible] system has gained wide popularity [illegible] reports on the use of the system have [illegible] included about 70–80 per cent [illegible] *fractures or have not used comparable* classification systems. Wynn Jones et al (1977) published a series and compared the results with those after McLaughlin nail-plate fixation There were the same number of *technical failures, but a higher rate of re-operations* occurred in Ender nailings as a consequence of distal slipping of the nails In the present series technical failures were observed in 19 per cent of cases, which [illegible]

[illegible]

quently re-operations. In former series re-operations have been performed in 8–13 per cent of cases (Poigenfürst & Schabl 19[illegible] Wynn Jones et al 1977), but technical failures or distal slipping led to re-operations in [illegible] per cent of the cases in the present series [illegible] more detailed description of the results of most of the Ender cases included in the present series will be published (Jensen & Sonne-Holm 1980). With the problems involved in reducing unstable trochanteric fractures the failure rate and re-operation rate is all too high with the Ender nailing The system is *thus* considered unsuitable for the internal fixation of unstable trochanteric fractures.

The present analysis clearly demonstrates that the sliding screw plate is, compared with the *McLaughlin Jewett or Ender* fixation methods the only suitable implant for the internal fixation of unstable trochanteric fractures.

ACKNOWLEDGEMENTS

This study was kindly supported by [illegible] Gjenforsikrings Jubilaeumsfond. Gratitude is expressed to Sv Kreuzer-Møller [illegible] Department for Data Processing [illegible] for statistical aid.

'ERENCES

worth, T H (1971) Immediate full weight-earing in the treatment of hip fractures *J 'rauma* **11**, 1031–1040

cco, D N, Breman, A. T, Cesare, J G, abiani, J A. & Conner, J H (1973) Early eight-bearing for intertrochanteric fractures mer Acad Orthop Surg, Meeting in Washington D C

l, H. B & Griffin, L L (1949) Classification id treatment of trochanteric fractures. *Arch urg* **58**, 853–866

iner, R A & Graham, W. D (1958) 'reatment of pertrochanteric fractures of the mur by immediate operation with a two-iece nail and plate *J Bone Jt Surg* **40**-B, 94–700

rson, D K. (1957) Intertrochanteric fractures f the hip *Amer J Surg* **93**, 580–587

rson, D K (1964) Trochanteric fractures reated by the sliding screw plate fixation iethod *J Trauma* **4**, 737–752

on, J H (1973) The unstable in-ertrochanteric fracture *Clin Orthop* **92**, 00–107

on, J H & Hughston, J C (1967) Unstable itertrochanteric fractures of the hip *J Bone t Surg* **49** A, 440–450

erty, J H & Lyden, J P (1979) ntertrochanteric fractures of the hip treated with the hip compression screw – Analysis of roblems. *Clin Orthop* **141**, 184–187

r, M L., Joyce III, J J & Kohl, E J (1975) The treatment of trochanteric fractures using a ompression screw *J Bone Jt Surg* **57**-A, 3–27

ler, J (1970) Probleme beim frischen per- und subtrochanteren Oberschenkelbruch. *Hefte Unfallheilk.* **106**, 2–11

er J & Simon-Weidner, R (1970) Die Fixierung der trochantere Brüche mit runden elastischen Condylennägeln *Acta chir austriaca* **2**, 40–42

ns, E. M. (1949) The treatment of trochanteric fractures of the femur *J Bone Jt Surg* **31**-B, 190–203

ns, E M. (1951) Trochanteric fractures. A review of 110 cases treated by nail-plate fixation. *J Bone Jt Surg* **33** B, 192–204

lding J W (1973) Subtrochanteric fractures *Clin Orthop* **92**, 86–99

ter, J C. (1958) Trochanteric fractures of the femur treated by the vitallium McLaughlin nail and plate *J Bone Jt Surg* **40**-B, 684–693

nkel, V H (1963) Mechanical fixation of unstable fractures about the proximal end of the femur *Bull. Hosp Jt Dis* **24**, 75–84

Friedenberg, Z B, Gentchos, E & Rutt, C (1972) Fixation in intertrochanteric fractures of the hip *Surg Gynec Obstet* **135**, 225–228

Harrington, K. D & Johnston, J O (1973) The management of comminuted unstable intertrochanteric fractures. *J Bone Jt Surg* **55**-A, 1367–1376

Hult, L & Nilsson, M H (1978) Ender-spikning av trochantära femurfrakturer *Lakartidn* **75**, 4603–4608

Jacobs, R. R, Armstrong, J, Whitaker, J H & Pazall, J (1976) Treatment of intertrochanteric hip fractures with a compression hip screw and a nail plate *J Trauma* **16**, 599–603

Jensen, J Steen (1980 a) Mechanical strength of Jewett and McLaughlin hip nail plates manufactured from Cobalt-Chromium-Molybdenum alloy *Acta orthop scand* **51**, 145–156

Jensen, J Steen (1980 b) Mechanical strength of McLaughlin hip nail plates manufactured from 316 LVM stainless steel *Acta orthop scand* **51**, 439–444

Jensen, J Steen (1980 c) Mechanical strength of sliding screw-plate hip implants. *Acta orthop scand* **51**, 625–632

Jensen, J Steen (1980 d) Classification of trochanteric fractures. *Acta orthop scand* (In press)

Jensen, J Steen & Michaelsen, M. (1975) Trochanteric femoral fractures treated with McLaughlin osteosynthesis *Acta orthop scand* **46**, 795–803

Jensen, J Steen & Sonne-Holm, S (1980) Critical analysis of Ender nailing in the treatment of trochanteric fractures *Acta orthop scand* (In press)

Jensen, J Steen, Tøndevold, E & Mossing, N (1978) Unstable trochanteric fractures treated with the sliding screw-plate system *Acta orthop scand* **49**, 392–397

Jensen, J Steen, Tøndevold, E & Sonne-Holm, S (1980) Stable trochanteric fractures. A comparative analysis of four methods of internal fixation *Acta orthop scand* (In press).

Johnson, L L, Lottes, J D & Arnot, J P (1968) The utilization of the Holt nail for proximal femoral fractures *J Bone Jt Surg* **50**-A, 67–78

Johnston, R C (1973) Mechanical considerations of the hip joint. *Arch Surg* **107**, 411–417

Kapral, W (1976) Osteosynthese pertrochanterer Frakturen mit Federnägeln nach Ender *Aktuel Chir* **11**, 371–388

Kaufer, H, Matthews, L. S & Sonstegard, D (1974) Stable fixation of intertrochanteric fractures. *J Bone Jt Surg* **56**-A, 899–907

Robey 1956) In the present series technical failures were observed in 48 per cent of cases. Less than 10 per cent were due to implant failures. The failure load of Jewett nail-plates has been reported to be about 100 kg (Jensen 1980 a) The vast majority of failures with these implants are due to displacement of the nail tip, which often protrudes through the osteoporotic bone As secondary fracture impaction takes place until bony contact over the fracture line is achieved, the implant must either give way or protrude through the bone Alterations in the operative technique using a shorter Jewett nail might solve the problems of penetration, but lead to a greater number of cuttings with varus dislocation (Boyd & Griffin 1949, Evans 1951) Consequently the Jewett nail-plate cannot be recommended for the internal fixation of unstable trochanteric fractures

The sliding screw-plate was originally designed with the aim of allowing secondary fracture impaction (Clawson 1964) The telescoping is often painful and followed by leg shortening of 1–2 cm (Clawson 1964, Ecker et al 1975, Harrington & Johnston 1973, Jensen et al 1978, Laskin et al 1979) In the present series secondary impaction was experienced in about 60 per cent of cases but technical failures occurred in only 6 per cent This low failure rate is consistent with other publications (Clawson 1964, Doherty & Lyden 1979, Ecker et al 1975, Harrington & Johnston 1973, Jacobs et al 1976, Jensen et al 1978, Mulholland & Gunn 1972) Implant failures are extremely rare, which can be explained by a high failure load which exceeds the hip joint load at walking (Paul 1976, Rydell 1966), at least after telescoping (Jensen 1980 c) The failures experienced are displacements and protrusion of the screw tip through the osteoporotic bone Friedenberg et al. (1972) reported this to occur in 19 per cent of cases, but as in the present series re-operations were necessary in only 3 per cent Jacobs et al (1976) found the sliding screw-plate fixation to be significantly better than the Jewett nail-plate The present series confirmed this and also found the former method to be better than McLaughlin nail-plate fixation and Ender nailing

In 1970 an internal fixation system with intramedullary rods for trochanteric fractures was introduced (Ender 1970 Ender & Simo[illegible] Weidner 1970, Simon-Weidner 1970). Th[illegible] system has gained wide popularity Mo[illegible] reports on the use of the system have eith[illegible] included about 70–80 per cent stab[illegible] fractures or have not used comparab[illegible] classification systems. Wynn Jones et [illegible] (1977) published a series and compared th[illegible] results with those after McLaughlin nail-pla[illegible] fixation There were the same number [illegible] technical failures, but a higher rate of r[illegible] operations occurred in Ender nailings as [illegible] consequence of distal slipping of the nails. I[illegible] the present series technical failures we[illegible] observed in 19 per cent of cases, which [illegible] higher or in accordance with previous repor[illegible]
[illegible]
([illegible]
e [illegible]
a [illegible]
d [illegible]
q [illegible]
operations have been performed in 8–13 pe[illegible] cent of cases (Poigenfürst & Schnabl 19[illegible] Wynn Jones et al 1977), but technical failure[illegible] or distal slipping led to re-operations in [illegible] per cent of the cases in the present series. [illegible] more detailed description of the results o[illegible] most of the Ender cases included in th[illegible] present series will be published (Jensen [illegible] Sonne-Holm 1980). With the problem[illegible] involved in reducing unstable trochanter[illegible] fractures the failure rate and re-operation ra[illegible] is all too high with the Ender nailing Th[illegible] system is thus considered unsuitable for th[illegible] internal fixation of unstable trochanter[illegible] fractures.

The present analysis clearly demonstra[illegible] that the sliding screw plate is, compared wit[illegible] the McLaughlin, Jewett or Ender fixatio[illegible] methods, the only suitable implant for th[illegible] internal fixation of unstable trochanter[illegible] fractures.

ACKNOWLEDGEMENTS

This study was kindly supported by Nordisk[illegible] Gjenforsikrings Jubilaeumsfond. Gratitude [illegible] expressed to Sv Kreiner-Møller (cand. stat.) [illegible] Department for Data Processing Herlev Hospit[illegible] for statistical aid

Acta orthop scand. 51, 963–970, 1980

TECHNICAL ACCURACY IN HIGH TIBIAL OSTEOTOMY FOR GONARTHROSIS

BENGT HAGSTEDT[1], OLOF NORMAN TORD H OLSSON[1] & BJÖRN TJORNSTRAND

Departments of Orthopaedic Surgery and Diagnostic Radiology, University Hospital, Lund Sweden

A preoperative roentgenological analysis of the whole leg in the standing position is presented as an aid in high tibial osteotomy for medial oestoarthritis of the knee This analysis provides information about the mechanical condition of the knee the extent of the deformity and the exact [illegible]

Key words gonarthrosis, osteoarthritis, tibial osteotomy

Accepted 24 iii 80

High tibial osteotomy is universally accepted as the treatment of choice for early stages of medial gonarthrosis. The effect of the operation is correlated with the correction obtained (Bauer et al 1969, Coventry 1965, 1973, Hagstedt 1974, Seal & Chan 1975)

The closing wedge osteotomy above the tibial tubercule is a safe operation (Jackson & Waugh 1974) but it needs improvement as regards accuracy In an earlier series from this hospital (Hagstedt 1974) in 59 out of 166 knees the planned correction was not achieved

This paper describes our efforts to increase the precision in high tibial osteotomy by improving the preoperative roentgenological examination and modifying the operation method

MATERIAL

In the Orthopaedic Department of the University Hospital of Lund 59 high tibial osteotomies were performed during the years 1975–1977 Seven osteotomies were performed at the Orthopaedic Department of the Hospital in Eksjö during the years 1976–1977 The same indications and pre- and postoperative routines were used for these 66 knees in 60 patients, 29 men and 31 women.

The indication for operation was medial gonarthrosis stages I–III (Table 1, Ahlback 1968, Hagstedt 1974 Norman 1974) The condition was primary in 58 knees and secondary to osteonecrosis in three knees and to trauma in three knees. One young women (two knees) had *genu varum* without pain. The ages of the patients ranged from 22 to 81 years with a mean of 56 years (Table 1)

METHODS

ROENTGENOLOGICAL METHOD

Theoretical background On a long roentgenogram (Figure 1), the line between the centre of the femoral head and the centre of the talus represents the mechanical axis of the lower extremity Normally this axis goes through the middle of the knee at the tibial spine Any deviation from the

[1] Present address Hospital in Eksjo S-575 00 Eksjo Sweden

0001-6470/80/060963–08$02.50/0

Table 1 Major radiographic stages of the medial type of gonarthrosis

Stage I	Joint space narrowing
Stage II	Joint space obliteration
Stage III	Minor bone attrition
Stage IV	Moderate bone attrition
Stage V	Major bone attrition

Subluxation (translation) of the tibia with secondary arthrosis of the lateral compartment is [illegible] 1979).

mechanical axis represents the degree of varus or valgus malalignment of the knee (Fick 1916, Maquet et al. 1967, Mikulicz 1878).

Theoretical biostatic models of the knee have been developed by Maquet et al (1966, 1967). They, Ramadier (1967), and Harris & Kostuik (1970) have used this model in practical w during high tibial osteotomies. However, prev descriptions of the roentgenological techn have not been sufficiently accurate to permit exact re-examination. In order to standardize roentgenological examination, every angle sh [illegible] the knee for reference and defined the fro *plane as perpendicular to the lateral view*

Roentgenological technique The patient examined standing on one leg The lateral view the knee is monitored by fluoroscopy or by ordinary roentgenogram. The frontal view is th taken perpendicular to this lateral view on a l cassette (100 cm) from a distance of 200 cm w the central ray passing through the knee (Fig 1a, b).

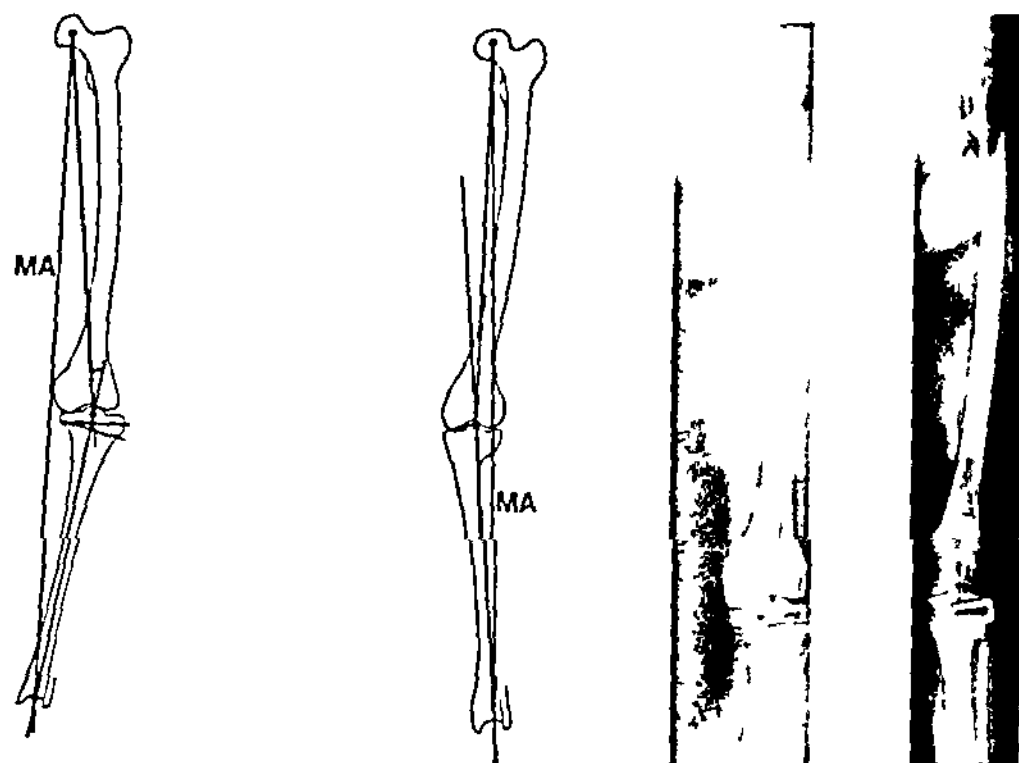


Figure 1a Schematic drawing of the lower extremity showing the mechanical axis (MA), the angle of deformity and the change in the mechanical axis after tibial osteotomy b The roentgenological appearance of the situation described in a A slight overcorrection is obtained after the osteotomy

To correct the deformity with a high tibial closing wedge osteotomy the wedge to be excised should have the same angle in the same plane as the deviation angle (Figure 1a). Wedges with the desired angle are drawn on the roetgenogram at different levels parallel to the joint surface. The of the wedge can then be measured on the lateral cortex, and the distance used by the

by geometrical calculation. The vertical height is equal to the wedge angle in radians multiplied by the true width of the tibia,

$$1° = \frac{2\pi}{360} \text{ radians}$$

Postoperatively the correction was calculated from roentgenograms as the change in the angle between the plane of the tibial condyle and the longitudinal axis of the proximal half of the tibial shaft

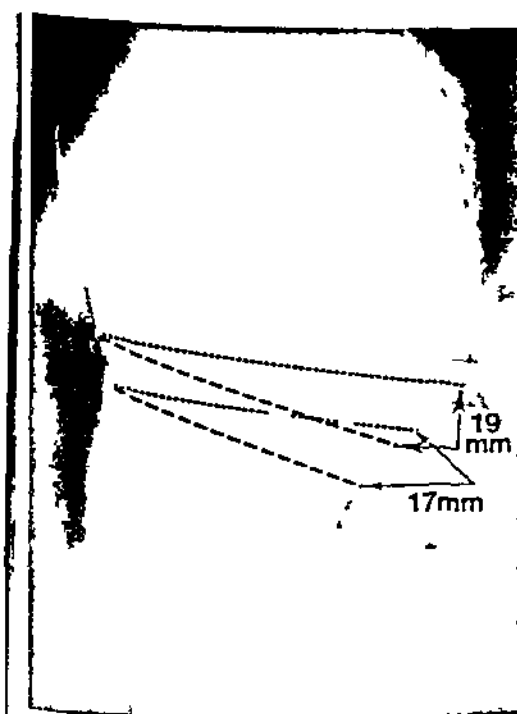


Figure 2 Medial gonarthrosis with a varus malposition of 12° To correct the deformity with tibial osteotomy a wedge with the same angle should be excised Two cm below the joint surface the distance on the lateral cortex is 19 mm and at 3 cm below 17 mm Note that the proximal cut is parallel to the joint line

OPERATION

A closing wedge osteotomy was performed above the tibial tubercle according to Coventry (1965) The fibular head was partially resected parallel to the lateral tibial cortex, saving the lateral attachment of the collateral ligament The dorsal aspect of the tibia was exposed with subperiosteal dissection to the medial margin of the tibia. The level of the osteotomy was decided and the height of the wedge on the lateral cortex was obtained from the roentgenological calculation. The osteotomy was made with an oscillating saw from behind and forwards The osteotomy gap was closed with an intact periosteal lambeau medially and fixed laterally with a Coventry staple

It should be noted that 1–2 mm of bone are lost as saw-dust and that it is important to place the wedge angle exactly at the medial cortex. When the osteotomy is done more distally, still above the tibial tubercle, every millimetre of bone lost laterally corresponds to a greater angle compared with that obtained with a more proximal osteotomy (Figure 2). Roentgenographic fluoroscopy was used during the operation to monitor these variables.

Postoperatively the patients were in plaster for 6 weeks and immediate weight-bearing was allowed Roentgenological examination was made 1 day after the operation at 1 week at 6 weeks after the plaster was removed and then at 1 year

RESULTS

Our aim at the operation of the first 55 cases was to correct the angular deformity in the knee so as to make the weight-bearing line identical with the ideal mechanical axis, i e the line through the centre of the femoral head, the tibial spine and the midpoint of the talo-crural joint For the last 11 osteotomies we have tried to achieve a valgus overcorrection of 4°

Immediately after the operation four-fifths of the knees were corrected to within ± 3° (Figure 3) At the 1 year follow-up the correction had been lost in several cases, however two-thirds of the knees remained within ± 3° of the planned correction Thirty-two knees

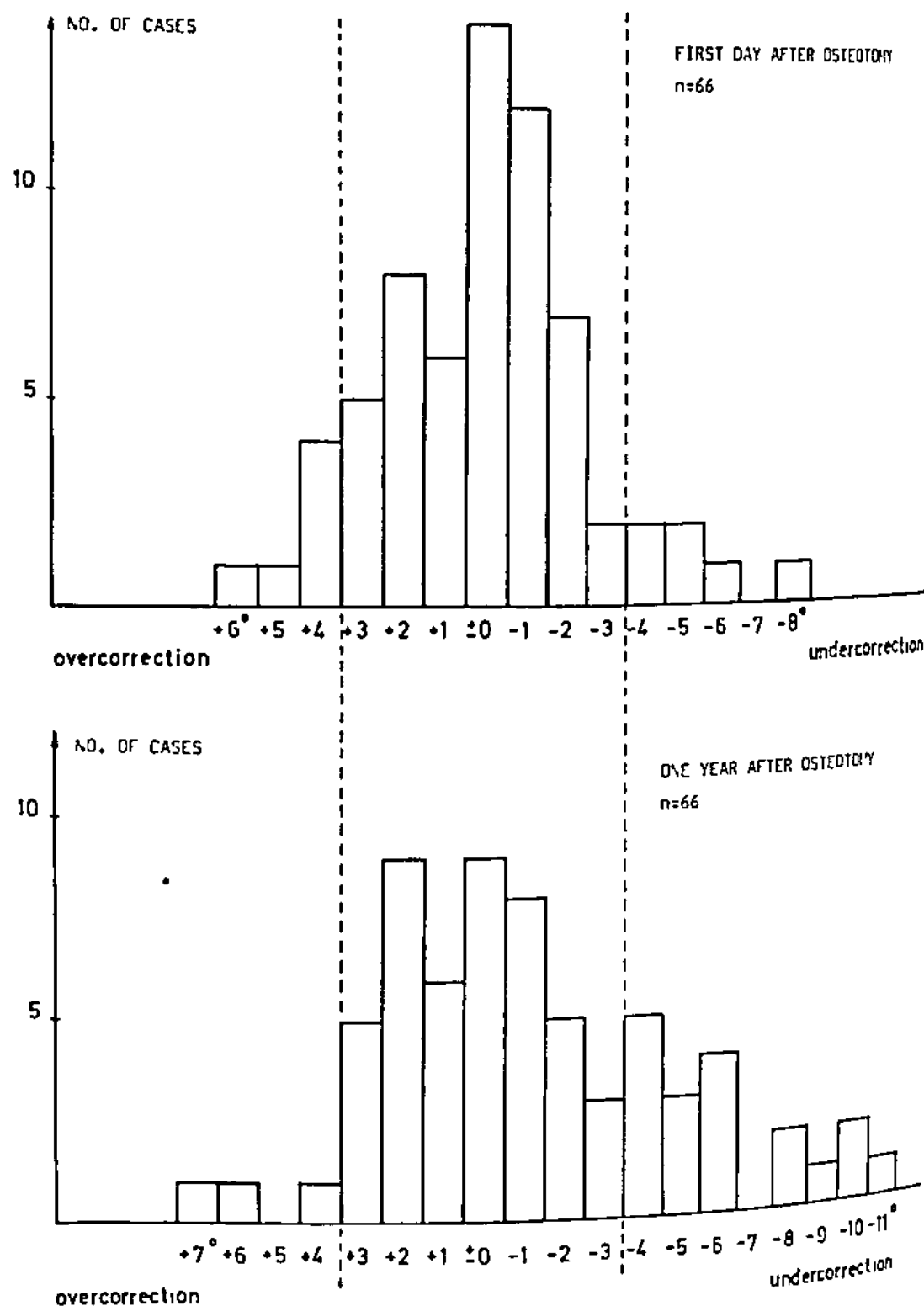


Figure 3 Deviation from the predicted correction (above) First day after operation (below) Situation 1 year after operation

showed a decrease in their correction, 17 knees an increase and 17 knees maintained their initial correction (Figure 4) The loss of correction was less than or equal to 4° in 21 out of 32 knees. Only one knee had an increased correction of more than 4°

DISCUSSION

In high tibial osteotomy a variety of principles have been applied in order to calculate the deformity that should be corrected Some authors have suggested that the

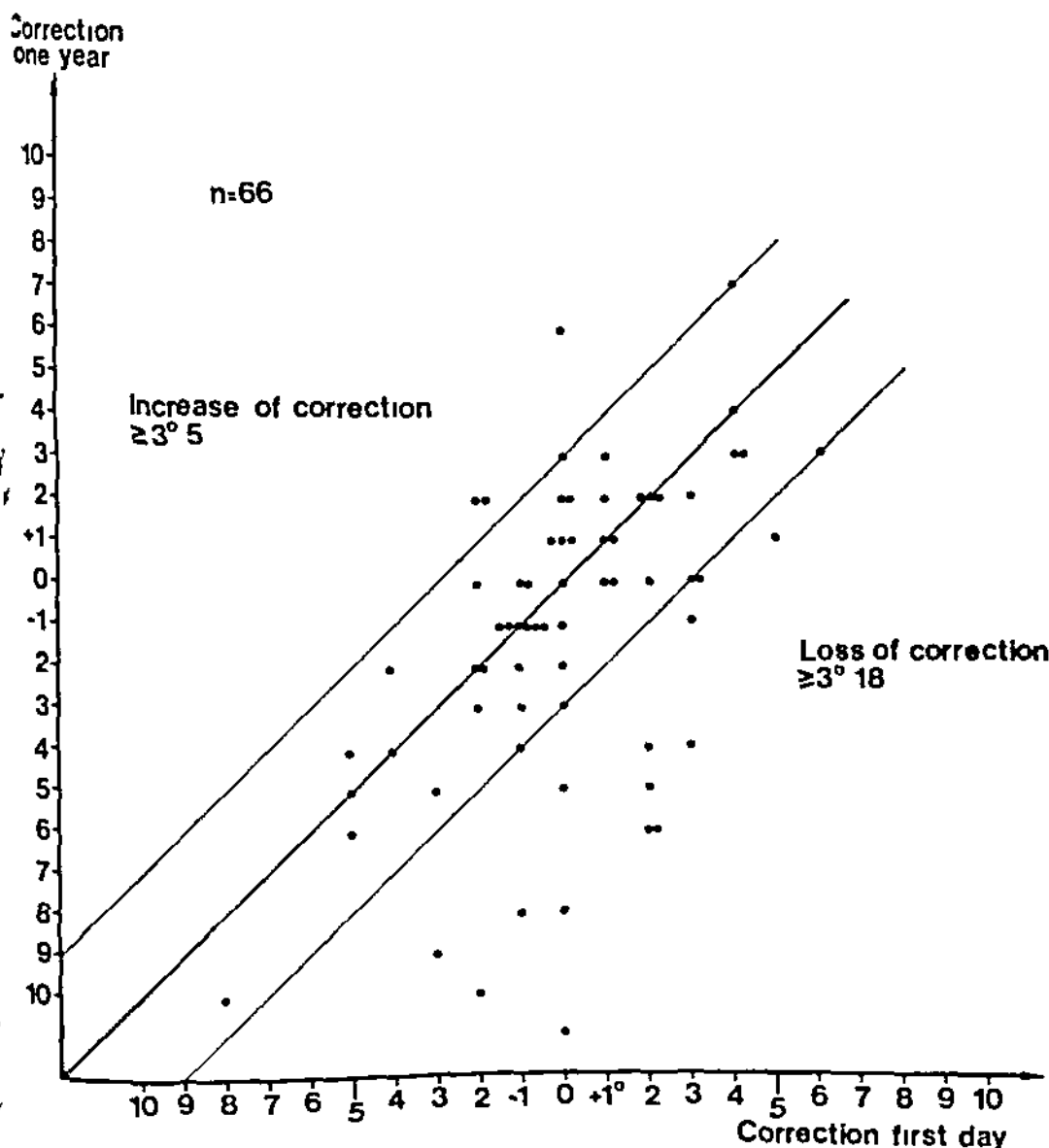


Figure 4 Increase or loss of correction in 66 osteotomies The Zero line and the lines for ± 3° are drawn

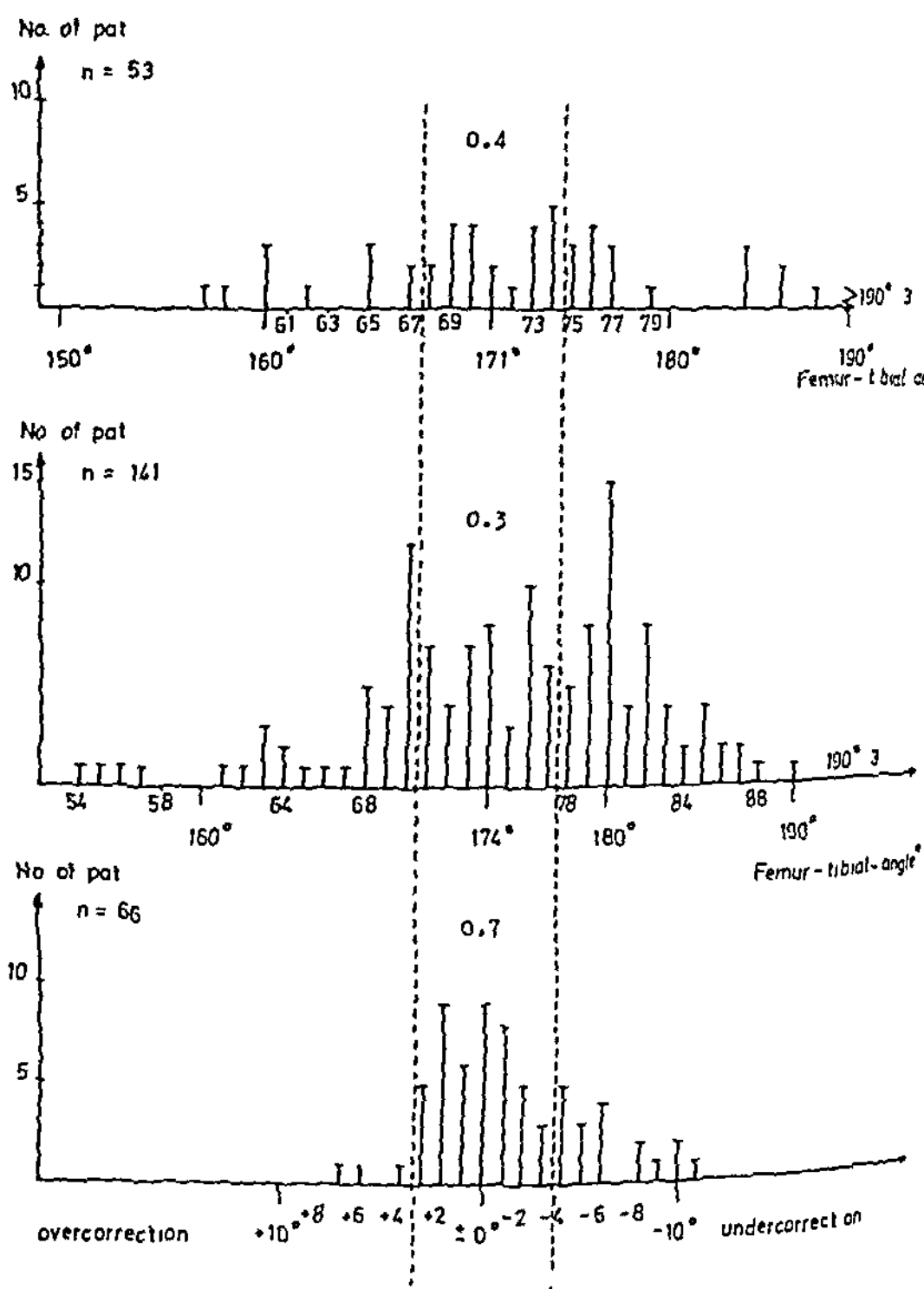


Figure 5 Comparison of the correction in the follow-up materials from (top) Bauer et al. (1969) (middle) Hagstedt (1974), and (bottom) present material

angle between the axes of the shafts of the femur and the tibia should be within the interval 164–178° with 174° as the ideal angle. Both weight bearing and non-weight-bearing pictures have been used (Bauer et al 1969 Coventry 1973, Hagstedt 1974, Kettelkamp et al 1976, Shoji & Insall 1973, Slocum et al. 1974) Others have tried to determine the mechanical axes of the knee (Harris & Kostuik 1970 Maquet et al 1966, 1967, Ramadier 1967) and at the operation corrected the deformity in such a way that the mechanical axis should then pass through the centre of the knee

In an earlier series of 166 osteotomies we aimed at a femoro-tibial angle of 174° at weight bearing (Hagstedt 1974), the wedge height was calculated using 1° equal to 1 mm (Bouillet & van Gaver 1961) which is true when the width of the tibia is about 6 cm The method was abandoned because of the low level of accuracy of the correction at the follow-up Instead the calculation was made on the roentgenogram of the whole leg where the weight bearing conditions were visualized. The film was taken with the patient standing on one leg with the frontal plane exactly defined In this way we avoid the errors in measurement caused by too small films, by curvation of the femur and tibia in the frontal plane, and by partial weight-bearing

The procedure is as close as we can get to the theoretical biostatic model of the knee under weight bearing conditions Earlier reports of similar methods have not described any standard methods for the measurements and the frontal plane has not been defined

Edholm et al (1977) have reported a roentgenological method with the orthoradiographic technique adding also another parameter, joint laxity The non weight-bearing leg is examined under standardized conditions but the assumption that the mechanical axis should coincide with the arithmetic medium of the laxity in an osteoarthritic knee has not been proven.

The method described here gives precise preoperative information to the surgeon The postoperative results show that it is also useful in practice (Figure 5) At 1 year following surgery in our series two-thirds of the cases were within ± 3° of the planned correction as compared to about one-third of the cases of Bauer et al (1969) and Hagstedt (1974) Bauer et al used an interval of around 171° and out of 53 cases of medial arthrosis 23 were found to be within ± 3° Hagstedt described 141 cases of medial arthrosis and in 45 cases the correction was within ± 3°

The surgically obtained correction had the same level of accuracy as that obtained when operating with a saw jig (Myrnerts 1978)

In our series the postoperatively obtained correction had changed by the time it was measured at the follow-up after 1 year Initially 54 out of 66 knees were found to be within ± 3° of the planned correction, 1 year later when the osteotomy was healed there were 45 cases with ± 3° Half of the osteotomies lost correction and in one-fourth the loss exceeded 3° (Figure 3)

Postoperative loss of correction has been observed previously (Hagstedt 1974, Seal & Chan 1975) but it has not been quantified It appears that loss of correction is a factor which cannot be completely controlled This together with biomechanical arguments suggests that an overcorrection should be performed in knees with medial gonarthrosis. Therefore in a continued prospective study we now aim at an overcorrection of 4°

REFERENCES

Ahlback S (1968) Osteoarthrosis of the knee A radiographic investigation *Acta radiol.* Suppl 277

Bauer G C H., Insall, J & Koshino, T (1969) Tibial osteotomy in gonarthrosis (osteo-arthritis of the knee). *J Bone Jt Surg* 51 A, 1545 1563

Bouillet R & van Gaver P (1961) L arthrose du genou. *Acta orthop belg* 27, 6–170

Coventry M B (1965) Osteotomy of the upper portion of the tibia for degenerative arthritis of the knee *J Bone Jt Surg* 47 A 984–990

Coventry, M B (1973) Osteotomy about the knee for degenerative and rheumatoid arthritis. *J Bone Jt Surg* 55-A, 23–47

Edholm, P, Lindahl, O, Lindholm, B, Myrnerts, R., Ohlsson, K. E & Wennberg, E (1977) Knee instability and tibial osteotomy *Acta orthop scand* 48, 95–98

Edholm, P., Lindahl, O, Lindholm, B, Myrnerts, R., *Ohlsson, K. E & Wennberg, E (1977)* Knee instability *Acta orthop scand* 47, 658–663

Egund, N & Norman, O (1979) *Pre- och* postoperativ röntgenundersökning vid hög tibiaosteotomi Nordisk Kongress Med Radiol, Stockholm

Fick, R (1916) Mechanik des Kniegelenkes. *Handbuch der Anatomie des Menschen* 2, 1 III, 525–535

Hagstedt, B (1974) High tibial osteotomy for gonarthrosis. ISBN 91-7222-069-4, Lund, Sweden

Harris, W R. & Kostuik, J P (1970) High tibial osteotomy for osteoarthritis of the knee. *J Bone Jt Surg* 52-A, 330–336

Jackson, J P & Waugh, W. (1974) The technique and complications of upper tibial osteotomy *J Bone Jt Surg* 56-B, 236–245

Kettlkamp, D B, Wenger, D R, Chao, E. Y S & Thompson, C. (1976) Results of proximal tibial osteotomy *J Bone Jt Surg* 58-A, 952–960

Maquet, P, Simonet, J & de Marchin P (19[illegible]) *Étude photoélastique de genou. Rev Ch orthop* 52, 3–1[illegible]

Maquet, P., Simonet, J & de Marchin, P (19[illegible]) Biomèchanique du genou et gonarthro[illegible] *Rheumatologie* 19, 51–70.

Mikulicz, J (1878) Über individuel[illegible] Formdifferenzen am Femur und an der Ti[illegible] des Menschen *Archiv für Anatomie u[illegible] Physiologie* 351, 404 (Wien, July).

Myrnerts, R (1978) The SAAB jig An aid [illegible] high tibial osteotomy *Acta orthop scand.* 4[illegible] 85–90

Norman, O (1974) In Hagstedt, B (1974)

Norman, O (1976) Ett fall av hjulbenthet ut[illegible] genuvarum *Läkarsällskapets Medicinsk[illegible]* Riksstamma (Stockholm). In Swedish.

Ramadier, J-O (1967). Etude radiologique d[illegible] deviations dans la gonarthrose In Symposiu[illegible] les gonarthroses d'origine statique *Rev. chi[illegible] orthop* 53, 139–147

Seal, P V & Chan, N W (1975) Tibi[illegible] osteotomy for osteoarthritis of the knee. *Act[illegible] orthop scand.* 46, 141–151

Shoji, H & Insall, J (1973) High tibial osteotom[illegible] for osteoarthritis of the knee with valgus defor[illegible]mity *J Bone Jt Surg*, 55-A, 963–973

Slocum, D B., Larson, R L, James, S L [illegible] Grenier, R (1974) High tibial osteotomy *Cli[illegible] Orthop* 104, 239–243

Correspondence to Dr Björn Tjörnstrand, Department of Orthopaedic Surgery, University Hospital S-221 85 Lund, Sweden

ta orthop scand. 51 971–973, 1980

ADAMANTINOMA TIBIAE

A Report of a New Case

J JOHANSEN & E WENNBERG

Department of Surgery, Aust Agder Sentralsjukehus, Arendal, Norway

This report describes a new case of adamantinoma of the tibia which is a rare primary malignant bone tumour Just over 100 cases have been reported The symptoms, treatment and problems of diagnosis are briefly discussed

Key words adamantinoma tibiae, primary malignant bone tumour

Accepted 3 iii 80

damantinoma of the long bones was first escribed by Fischer in 1913 The name ndicated a histological resemblance to the enign but locally invasive tumour of proferating odontogenic epithelium, known as ameloblastoma, which occurs in the axilla and mandible This is the second case adamantinoma tibiae reported to the orwegian Cancer Registry in 25 years here have been very few Scandinavian ports on the subject (Fossa 1973, Hierton et 1979)

ASE REPORT

65-year-old man was first seen in 1975 As a ld he susta ned a fract re of he right leg whch

Radiographs showed a 4 cm long destructive cess in the right tibia and the possibility of fuse malignant disease was discussed Curettage s performed and the histological diagnosis was tastases from a malignant tumour The patient s examined very carefully to find the primary nour but none was found
ecurrence of the tumour led to a new curettage 1976 The microscopic examination showed rs of stellate cells arranged in anastomosing ngated masses supported by fibrous stroma gure 2a b) The diagnosis was adamantinoma iae En bloc excision was tried, but a relapse urred in 1977 and amputation of the femur was formed. The patient now has a prosthesis and at the 2-year follow-up there were no signs of recurrence or metastases

DISCUSSION

Adamantinoma tibiae may metastasize even after an interval of many years (Morgan & Mackenzie 1956) There is a great deal of controversy regarding the pathogenesis (Spjut et al 1970, Weiss & Dorfman 1977, Hierton et al 1979) The importance of pre-existing trauma is stressed by several authors (Morgan & Mackenzie 1956, Krishnan et al 1974)

This slow-growing tumour may occur at any age and in the reported cases the ages of the patients have varied from 8 to 74 years

The symptoms may be a painless swelling in the leg, mild aching or more severe pain Some patients have no symptoms and some tumours have been discovered incidentally (Krishnan et al 1974)

Identification of the tumour is seldom made before the surgical exploration The most common roentgenographic differential diagnoses include chondrosarcoma and metastatic carcinoma from an unknown primary site, as in this patient

Amputation is the treatment of choice if the site of the tumour makes it unsuitable for "en bloc" resection (Hierton et al 1979) The patients should be followed up for many years.

01 6470/80 060971–03$02.50 0



Figure 1 The lesion located in the distal third of tibia The destructive process extends a distance of about 4 cm Areas of cortical destruction and small cysts are seen There is a marked periosteal reaction and also cortical sclerosis of the fibula



[Fig]ure 2a *Microscopic examination of the tumour [sho]ws rows of stellate cells arranged in [an]astomosing elongated masses supported by [fib]rous stroma (×30)*



Figure 2b *Trabeculae of epithelial cells with differentiation into squamous epithelium (×430)*

[R]EFERENCES

[Ab]ssaa, S D (1973) Adamantinoma tibiae Kasuistische Mitteilung *Acta chir scand* 193, 100–103

[Ab]erton, T, Kolstad, K., Lindgren, A & Sahlstedt, B (1979) Adamantinoma tibiae *Acta orthop scand* 50, 97–101

[Kri]shnan, K U Dahlin, D C, Beabout, J W & [Iv]ings, J C (1974) Adamantinoma of long bones *Cancer* 34, 1796–1805

Morgan, A D & Mackenzie, D H (1956) A metastasising adamantinoma of the tibia. *J Bone Jt Surg* 38-B, 892–897

Spjut, H J, Darfman, H D, Feckner, R. E & Ackermann, L V (1970) *Tumours of bone and cartilage Atlas of tumour pathology* A F I P Washington

Weiss, S W & Dorfman, H D (1977) Adamantinoma of long bones. *J Hum Path* 8, 141–153

[Co]rrespondence to Svein E Johansen, M D, Department of Surgery Aker Sykehus, Trondheimsvn. 235, [Os]lo, Norway

Acta orthop scand. 51 975–979, 1980

ANKLE AND FOOT FRACTURES IN DIABETICS PROVOKING NEUROPATHIC JOINT CHANGES

BJARNE KRISTIANSEN

Department of Orthopaedic Surgery, Frederiksborg Central Hospital, Hillerød, Denmark.

Neuropathic joint changes, Charcot joints, in diabetics developing after ankle or foot fractures have received little attention in the literature Three cases are presented here, one in a previously undiagnosed diabetic The pathogenesis and the management are discussed, and the importance of adequate protection of these fractures is emphasized Even fractures of the metatarsal bones should be immobilized and weight bearing must be postponed until the bone is firmly united

Key words ankle fractures Charcot joint, diabetic arthropathy, metatarsal fractures, neuropathic joint changes

Accepted 3 iii 80

Diabetic neuroarthropathy is a complication of diabetes mellitus with spontaneous bone and joint destruction, developing in diabetics with unstable metabolism (Forgasc 1977, Johnson 1967)

The disease ranks among the neurogenic arthropathies which include among others tabes dorsalis and syringomyelia The main feature is the absence or depression of pain sensation which in the presence of weight-bearing may result in the ultimate breakdown the Charcot joint characterized by severe, degenerative changes in the joint without pain (Ammitzboell & Jarloev 1975)

The incidence of arthropathy in diabetics is 0 1–0.5 per cent (Forgasc 1977, Lippmann et al. 1976) The ankle (11 per cent), the tarsus (24 per cent), the tarsometatarsal joints (30 per cent) the metatarsophalangeal joints (30 per cent) and the interphalangeal joints (4 per cent) are the most common sites (Forgasc 1977)

The role of fractures in the production of neuropathic joint changes has largely been neglected in the literature, and in spite of an increasing number of observations of diabetic arthropathy in recent years only a few reports have described the progression and management of these fractures

This paper presents three cases of fractures, in diabetics, initiating neuropathic joint changes, and includes a case in a previously undiagnosed diabetic. The pathogenesis and the management are discussed

CASE REPORTS

Case 1 62-year-old male Diabetes for 20 years, controlled by insulin First seen in the casualty ward in February 1979 because of persistent [illegible]

He was treated with a supporting bandage and [illegible]




Figure 1 X-rays, taken 2 months after an injury to the right foot showing fracture of the second metatarsal bone with callus formation (A) After a further 3 months' weight bearing total degeneration of all the tarsometatarsal joints is seen (B)

sing to a typical Charcot foot 3 months later (Figure 1) He was completely free of pain No ulcers were seen He was provided with a soft leather shoe with a moulded insole One year after the injury he still had no pain, but because of the deformity and the varying amount of swelling of the foot he had some trouble in acquiring a suitable shoe

Case 2 61-year-old female Diabetes mellitus had not been previously diagnosed In May 1979, after a rotational trauma of the right ankle, a comminuted trimalleolar fracture with subluxation of the talo-crural joint was found Reposition and osteosynthesis was performed and a crural circular plaster was fitted (Figure 2) Weight-bearing was not allowed On the day after admission the patient was found to have a raised blood sugar, and sugar and ketoacid in the urine Ophthalmoscopy showed simple retinopathy Insulin treatment was started After 4 weeks X-ray films showed unchanged anatomical position in the fractures, and weight-bearing was allowed Eight weeks after the injury the plaster was removed There had been no intercurrent trauma or episodes of pain Some swelling of the ankle, but no ulcers and no tenderness was found X-ray films showed the fractures to be totally redislocated Reposition was again tried, but was found to be impossible, so another plaster cast was fitted and worn for 3 months Weight-bearing was allowed after 6 weeks After removal of the cast the ankle was stable with limited mobility and without pain. X-ray showed a Charcot joint (Figure 2) A special shoe was made and 7 months after the injury the condition was unchanged She was managing well without crutches

Case 3 28-year-old male Diabetes controlled with insulin for 7 years. Signs of neuropathy and proliferative retinopathy had been found In March 1977, after a fall, he developed swelling but only minor pain in the left foot X-ray films were taken 12 days after the injury and showed a fracture of the lateral malleolus and of the talus (Figure 3). A plaster cast was applied and weight bearing not allowed until 6 weeks later The fractures were healing but in a poor position and changes characteristic of a Charcot joint were observed (Figure 3) The patient had no pain, but because of great discomfort with swelling and because he could only walk on the lateral side of the foot, being unable to wear even tailor-made shoes, a crural amputation was performed in October 1977 He has since been wearing a prosthesis

DISCUSSION

The occurrence of typical Charcot type bone and joint changes secondary to diabetic





gure 2 Radiographs of the right ankle.(A) Osteosynthesis of a comminuted trimalleolar fracture (B) The acture redislocated between 4 and 8 weeks after the injury After 5 months the fracture healed in a poor i tion with degeneration of the ankle joint





gure 3 X ray of the left ankle (A) X ray showing a fracture of the talus 12 days after a fall In the frontal ane a fibula fracture is visible (B) After 6 weeks in plaster severe d generation of the ankle and tarsal nts can be seen

neuropathy has been demonstrated by various authors (Knutsson 1951, Martin 1952, Petersen 1960) Neuropathies associated with diabetes mellitus have generally been considered a late manifestation of the disease (Forgasc 1977, Lundbaek 1979) Tile (1973) however, reported eight cases of diabetic mononeuropathy presenting as intervertebral disc herniation in previously undiagnosed diabetics. A case of diabetic arthropathy, occurring prior to the onset of the classic condition of diabetes, has not been reported previously In Case 2 in this paper, the arthropathic changes developed only a few weeks after the diagnosis diabetes mellitus had been suggested

It is widely accepted that neuropathic fractures in diabetics are associated with diabetic osteolysis (Rathery 1973, de Leeuw et al 1975, Forgasc 1977), which is explained by microangiopathy leading to loss of bone mass (Levin et al 1976) and mineral content (Ringe et al 1976) Fractures in an already spontaneously destroyed joint have been described by among others Lippmann et al (1976) who reported one case of ankle fracture and two cases of cuboid fractures and de Leeuw et al (1975) who presented a case of spontaneous bilateral bimalleolar fracture

Johnson (1967) in a review of 118 cases of neuropathic fracture and joint injuries included 10 cases of diabetic origin one of these progressing to Charcot joint changes. This case and the three cases described in the present paper indicate that a fracture in a radiologically normal ankle or foot of a diabetic may produce these changes.

Although only 1–2 per cent of all diabetics have subjective symptoms of neuropathy, nearly all have neurological abnormalities such as some grade of depressed vibratory sense reduced motor conduction velocity or depressed sensation (Lundbaek 1979) Thus when a fracture of the foot or ankle occurs leading to mechanical instability of the joints (Lippmann et al 1976) and sensory deprivation also exists the stresses of continued weight-bearing may result in the ultima[te] breakdown

Considering this relationship and the pro[-]gression of the cases described in this pape[r] the importance of adequate protection [of] neuropathic fractures in general and [of] fractures in the foot or ankle of diabetics [in] particular, must be emphasized All diabetic[s] must be told to present for examination aft[er] foot/ankle injuries, even those causing onl[y] mild pain After fracture the bones must b[e] immobilized and weight bearing postpone[d] until the bone is firmly united This include[s] simple, undisplaced metatarsal fracture[s] Because diabetics often have impaired pa[in] sensation pain is not a reliable indication [of] the state of the fracture

Once a Charcot joint has developed th[e] management in most cases consists [of] providing proper weight support in [in-]dividually made shoes (Harris & Brand 196[6] Lippmann et al 1976) In cases where th[e] joints are totally disintegrated or the fracture[s] are healing in such a poor position that th[e] wearing of shoes will be intolerable surgica[l] intervention may be necessary Successf[ul] cases of surgical fusion of the tarsus in th[e] anaesthetic foot have been reported (Harris & Brand 1966), but considering the delayed healing of fractures in Charcot joints in general (Johnson 1967, de Leeuw et al 1975) and in diabetics in particular (Cozen 1972) amputation often has to be performed.

REFERENCES

Ammitzboell F & Jarloev N I (1979) *Medicinsk kompendium.* Vol 2, 11th ed. pp 1533 Nyt nordisk forlag Arnold Busck, Copenhagen

Cozen L (1972) Does diabetes delay fracture healing? *Clin Orthop* 82, 134–140

Forgasc S (1977) Stages and roentgenological picture of diabetic osteoarthropathy *Fortschr Rontgenstr* 126, 36–42.

Harris, J R & Brand P W (1966) Patterns of disintegration of the tarsus in the anaesthetic foot *J Bone Jt Surg* 48 B 4–16

Johnson J T H (1967) Neuropathic fractures

and joint injuries *J Bone Jt Surg* **49-A**, 1-30

Knutsson, F (1951) Diabetic arthropathy *Acta radiol. (Stockh)* **36**, 114–120

de Leeuw I, Lahaye, E & Ranquin, R (1975) "Spontane" bilaterale bimalleolaire breuk bij een diabetica met viscerale neuropathie *Ned T Geneesk* **119**, 875–879

Levin, M. E, Boissean, V C. & Avioli, L V (1976) Effects of diabetes mellitus on bone mass in juvenile and adult-onset diabetes. *N Engl J Med* **294**, 241–245

Lippmann, H T, Perotto, A & Farar, R. (1976) The neuropathic foot of the diabetic. *Bull N Y Acad Med* **52**, 1159–1178

Lundbaek, K (1979) Neuropathia diabetica *Nord Med* **94**, 290

Martin, M M (1952) Charcot joints in diabetes mellitus. *Proc roy Soc Med* **45**, 503–506

Petersen, A (1960) Arthropathia diabetica *Acta orthop scand* **30**, 217–225

Rathery, M. (1973) Les osteo-arthropathies du diabete sucré *Gaz méd Fr* **80**, 4589–4599

Ringe, J-D, Kuhlencordt F & Kuhnau Jr, J (1976) Mineralgehalt des Skeletts bey Langzeitdiabetikern *Dtsch med Wschr* **101**, 280–282.

Tile, M (1973) Diabetic neuropathy in orthopaedic practice (Proc) *J Bone Jt Surg* **55-B**, 662

Correspondence to Bjarne Kristiansen Kroengen 1, DK-3230 Graested Denmark

Acta orthop scand. 51, 981–990 1980

ANKLE FRACTURES: SUPINATION-EVERSION FRACTURES OF STAGE IV

Primary and Late Results of Operative and Non operative Treatment

JOHANNES YDE & KRISTIAN D KRISTENSEN

Department of Orthopaedic Surgery, Hjørring Hospital,
Department of Surgery, Frederikshavn Hospital, Denmark

Supination-eversion fractures of stage IV, 60 treated operatively and 29 non-operatively, were seen at follow up after 3–10 years This disclosed a statistically significant difference between the results of the two methods Operation which attempted to re-establish the anatomical position was apparently the better method in the presence of more than minimal displacement or a suspicion of deltoid ligament rupture

Key words ankle fractures, arthrosis, non-operative/operative treatment, supination-eversion fractures stage IV

Accepted 21 ii 80

From the present study of malleolar fractures the findings in stage II supination-eversion fractures (SE II) have already been presented (Yde & Kristensen 1980) Unlike the stage II fractures, supination-eversion fractures of stage IV (SE IV) (Figure 1) (N Lauge Hansen 1942) do not constitute a well-defined sub-group of ankle fractures (Cedell 1967, Yde 1980) This applies particularly to injury to the posterior tibial margin and the medial malleolus, whereas lateral injury shows less variation At the posterior tibial margin there may be a major or minor fracture of the tibial joint surface or merely a ligamentous injury Medially there may be fracture of the malleolus or rupture of the deltoid ligament Furthermore, this type of fracture may be complicated by dislocation causing dorso-lateral displacement of the talus.

Treatment in the various clinics ranges from non-operative (Baek Kristensen 1953, Watson-Jones 1955, Bar 1966, Pohlmann 1971) to operative with attempts being made to re-establish the anatomical position to a greater or lesser extent In some clinics severely displaced fractures of the posterior tibial margin and displaced fractures of the medial malleolus are considered indications for operative treatment (Muller 1945, Klossner 1962) Other clinics try, as far as possible, to re-establish the anatomical position in bony and ligamentous injuries especially as regards the lateral malleolus (Willenegger 1961, Weber 1966, Cedell 1967)

In the present study the course of treatment and the late results (subjective, objective, and radiological) of operative and non-operative treatment of SE IV injuries were compared and evaluated

PATIENTS AND METHODS

During the 8 year period 1968–1976 a total of 488 malleolar fractures were treated in the Department of Orthopaedic Surgery Hjørring Hosp

0001/6470, 80, 060981–10$02.50/0

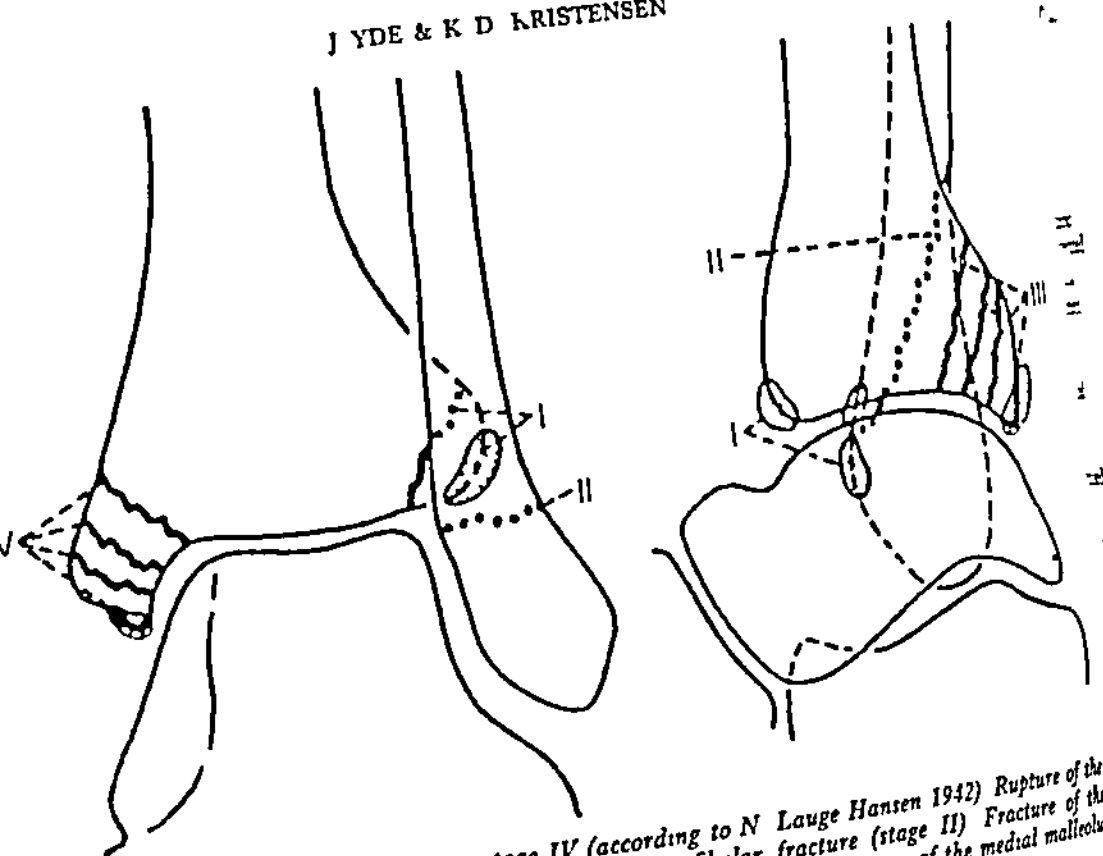


Figure 1 Supination eversion fracture stage IV (according to N Lauge Hansen 1942) Rupture of the anterior tibiofibular ligament (stage I) Distal oblique fibular fracture (stage II) Fracture of the posterior tibial margin (stage III) Rupture of the deltoid ligament or fracture of the medial malleolu (stage IV)

Table 1 Distribution of fracture types according to the classification of Lauge Hansen (194) Percentage

Fracture types	Hjørring n = 488	Frederikshavn n = 247
Supination-adduction	20 1	18 6
Supination-eversion		
stage II	33 2	35 2
III	2 3	3 3
IV	21 5	17 4
V–VI	0 4	0 4
	57 4	56 3
Pronation abduction/ pronation-eversion	20 9	21 1
Others	1 6	4 0
	100 0	100 0

Table 2 Criteria and reasons for the exclusion of patients from the study of supination-eversion injuries stage IV

	Hjørring	Frederikshavn
Total SE IV material	102	43
Not operated on (Hjørring)	23	
Secondary operative treatment (Frederikshavn)		4
Treatment completed elsewhere	4	2
Follow-up not practicable		
dead	6	2
systemic disease	5	0
remote domicile (>50 km)	2	2
refused, others	2	4
Total excluded	42	14
Total seen at follow up	60	29

Denmark, and another 247 in the Department of Surgery, Frederikshavn Hospital, Denmark The materials do not include patients under 15 years of age epiphyseal fractures "pure" ligamentous injuries, or fractures caused by direct violence The Lauge Hansen (1942) classification was used for typing and staging the fractures (Table 1) on the basis of physical and radiological findings and, in the case of the operated group also the operative findings were used in particular as regards injury to the deltoid ligament In cases where the deltoid ligament was not explored the [illegible] amination under fluoroscopy, swelling and [illegible]

Primary osteosynthesis was performed on 79, and these 79 cases form the basis of the follow-up study of the operated SE IV injuries Operation

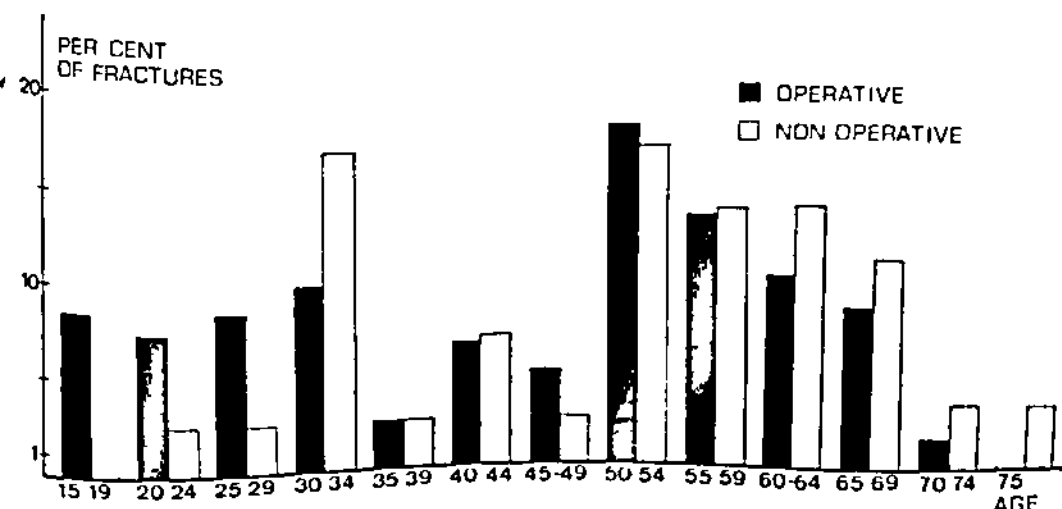


Figure 2 Age distribution.

Table 3 Occupational strain on ankle joint Percentage

Group	Occupation	Operative treatment $n = 60$	Conservativ treatment $n = 29$
1	*unprotected, heavy* fisherman, farmer, woodcutter, shipyard worker	28 3	27 2
2	*unprotected* factory worker, shopkeeper, cleaner (full time)	23 4	14 0
3	*possibility of protection* cleaner (part-time) country housewife	20 0	7 0
4	*little strain on legs* housewife, teacher, student	28 3	51 8

was not performed in 23 cases because of minor displacement (13 patients, all over 50 years of age) poor condition of the soft tissues (3 patients all over 50) patient refusal (6 patients) and late arrival (1 patient) 6 days after the trauma In Frederikshavn 43 fractures were treated 6 of which had talo-crural dislocation Non-operative treatment was tried first in all cases but in 4 cases osteosynthesis was required a few days later because of pronounced fracture displacement The remaining 39 fractures constitute the non-operated group

Sixty patients treated by operation (Hjørring) and 29 treated non-operatively (Frederikshavn) were seen at follow-up in the course of the winter 1978/79 The reasons for the reduction in the size of the materials are given in Table 2 The sex ratio (males/females) was 0 8 for the operated patients and 1 1 for the non-operatively treated ones Figure 2 illustrates the age distribution The main aetiological groups (operated/non-operated) were sport 5/2 traffic 6/3 'fall at same level 43/19 and fall to another level' 3/4 The occupational strain on the ankle joint in the two materials is shown in Table 3 The primary fracture displacement according to the classifications of Baek Kristensen (1953) and Cedell (1967) (cf Table 4) is shown in Table 5 Tables 6 and 7 give the types of injury to the posterior tibial margin and the medial malleolus

OPERATIVE TREATMENT (HJØRRING)

As a rule the operations were done in a bloodless field The injuries were exposed through slightly arcuate incisions at the lateral and medial malleolus In fractures of the lateral malleolus the aim was accurate reduction and stable fixatio (Table 8) Until the middle of 1974 the steel wi cerclage advocated by Cedell & Wiberg (1962) w used (Figure 3), but since that time small scre applied by the technique recommended by the A group have been used in most cases (Figure 4). I a few cases another method was employed. In th event of rupture in the ligament proper th anterior tibio-fibular ligament was sutured. [illegible]

by the staple designed by [illegible] placed parallel with the ligament (Figure 3) Rupture of the deltoid ligament was sutured Fractures of the medial malleolus were reduce and fixed by Palmer pins (Figure 3), but in one case by small cancellous screws. Displaced fractures of the posterior tibial margin comprising more than one-quarter of the joint surface were, if possible accurately reduced and fixed by cancellous screws inserted from the anterior aspect (Figure 4) A suction drain was inserted, and after a below knee plaster cast had been applied the leg was positioned in elevation for about 5 days. Thereafter the patients were mobilized but without weight bearing on the affected leg When the plaster cast was removed 6–8 weeks after the operation the patients were instructed in exercises, and increasing weight bearing was permitted Within the first 6 months after the operation as a rule 2 weeks after removal of the plaster cast, the osteosynthesis material was totally removed in 29 patients and partially in 25 In 6 patients the implant was left. Thus 48 patients were under general anaesthesia twice The mean stay in hospital was 15 days, range 5–21 days.

Table 4 Comparison of the classifications of radiological fragment displacement

	Back Kristensen (1953)	Cedell (1967)
ateral malleolus		
Anatomical		No displacement.
Good	No lateral displacement Dorsal displacement ≤ 2 mm	Slight rotation
Medium	Lateral displacement ≤ 2 mm. Dorsal displacement 2–5 mm.	
Poor	Lateral displacement > 2 mm Dorsal displacement > 5 mm	Lateral and/or dorsoproximal displacement Marked rotation. Valgus position
ledial malleolus		
Anatomical		No displacement.
Good	No lateral displacement No angulation Dorsal and ventral displacement and fracture diastasis ≤ 2 mm	Slight rotation. Dorsal or ventral displacement ≤ 1 mm.
Medium	Dorsal and ventral displacement and fracture diastasis 2–5 mm. Medial displacement ≤ 2 mm	
Poor	Displacements larger than above Lateral displacement Angulation	Dorsal or ventral displacement >1 mm. Lateral or medial displacement Marked rotation Valgus position
eltoid ligament pture		
Anatomical		No displacement of the talus.
Good		No displacement of the talus
Poor		Lateral displacement or valgus position of the talus.
osterior tibial argin		
Anatomical		No displacement.
Good	Fragment > thin shell. Displacement ≤ 2 mm.	Fragment ≤ ¼ of the articular surface with displacement ≤ 2 mm.
Medium	Displacement 2–5 mm	
Poor	Displacement > 5 mm	Fragment < ¼ of the articular surface with displacement > 2 mm. Fragment > ¼ of the articular surface with displacement.

Table 5 Radiological degree of displacement before treatment (classifications according to Baek Kristensen 1953 and Cedell 1967) Percentage

	Operative treatment $n = 60$	Conservative treatment $n = 29$
Baek Kristensen		
good	3 4	17 3
medium	18 3	37 8
poor	78 3	44 9
Cedell		
anatomical	0 0	0 0
good	1 7	10 3
poor	98 3	89 7

NON-OPERATIVE TREATMENT (FREDERIKSHAVN)

Reduction was performed under general anaesthesia in 15 patients and without general anaesthesia in one Thirteen patients were fitted with plaster casts without attempts at reduction All were admitted for an elevation regimen At the end of 1–3 weeks weight-bearing was started in a below knee walking cast which was removed 7–9 weeks after the trauma and thereafter full weight-bearing was allowed The mean stay in hospital was 14 days, range 5–21 days.

The patients were examined at the follow up clinically and radiologically by the authors. The mean follow-up period was 5 6 years for the operated fractures and 6 8 years for the non-operatively treated ones range 3–10 years

Table 6 Injuries to the posterior tibial margin Percentage

	Operative treatment $n = 60$	Conservative treatment $n = 29$
No fracture	25 0	44 8
Shell	28 3	17 2
Affection of the articular surface		
$\leqslant \frac{1}{4}$	28 3	34 5
$> \frac{1}{4} \leqslant \frac{1}{3}$	11 7	0 0
$> \frac{1}{3}$	6 7	3 5

Table 7 Injuries to the medial aspect of the ankle joint Percentage

	Operative treatment $n = 60$	Conservative treatment $n = 29$
Deltoid ligament	41 6	27 6
Shell $< \frac{1}{2}$ cm	5 0	17.2
Transverse fracture	43 4	41 4
Oblique fracture	10 0	13.8

RESULTS

Primary results

The radiological results of reduction wer recorded about 2 weeks after treatment wa started (Table 9) Within the operated grou 70 0 per cent obtained "anatomical" reduc tion a result which was not achieved in an patient in the non-operatively treated group The main cause of a non anatomica reduction after operation was fracture of th posterior tibial margin No operated cas remained in the "poor" group according t the Baek Kristensen classification. Followin closed reduction the position of the fractur was not improved according to the Cedel classification, whereas 10 had changed fro "poor" to "medium" when the classification o Baek Kristensen was applied

Local complications occurred in tw patients after operative treatment. One o these patients developed deep thrombo phlebitis and the other skin necrosis afte removal of the osteosynthesis material. In th

Table 8 Fixation devices used for the fibula fracture

	[illegible]
Cerclage	[illegible]
Palmer pin/Kirschner wire	[illegible]
Small screws	[illegible]
Small plates	[illegible]
Combination	[illegible]
	[illegible]



Figure 3 Fixation of the distal oblique fibular fracture by cerclage and fixation of the medial malleolar fracture by Palmer pins The anterior tibiofibular ligament is sutured and strengthened by a staple

latter case healing was obtained in 3–4 months Non-operative treatment was not associated with any complications

The period off work was recorded after excluding the patients in the group exposed to least strain on the legs (cf Table 3, group 4) Patients treated by operation were off work for an average of 16 0 weeks, those treated non-operatively for 18 8 weeks

Late results

The follow-up included a clinical and a radiological examination Symptoms were classified according to Baek Kristensen (1953) and Cedell (1967) signs according to Baek Kristensen (1953) Cedell (1967) and Weber (1966) Articular changes on the X-ray films were recorded according to the criteria of Magnusson (1944) and Weber (1966). Comparison of subjective and objective results was according to the classifications of Cedell, as they make the strictest demands.

Subjective results (Table 10)

(1) good — The patient is completely symptom free or rarely has quite negligible symptoms of pain, swelling, stiffness or tiredness, but only after extra exertion

(2) medium — Moderate symptoms of pain, swelling stiffness, or tiredness after exertion, but no reduced capacity for work and in most cases a normal capacity for exercise and sports.

(3) poor — Severe symptoms of pain, swelling, stiffness, or tiredness especially on exertion, and as a rule reduced capacity for work

In the operated group the medium and poor results were due to mild cicatricial pain (1 patient) a tendency to swelling (2) moderately restricted mobility in the ankle joint combined with unprotected, heavy work (1), and arthrosis pain (3) In the remaining 3 patients there was no objective or radiological explanation for the complaints In the non-operatively treated group the symptoms were due to arthrosis in all 13 cases The materials are too small for the purpose of demonstrating a definite association between the position obtained by the reduction and the subjective results in the two groups.

Objective results (Table 12) Cedell's classification, with minor modifications, was



Figure 4 Fixation of the distal oblique fibular fracture by small AO screws and fixation of a posterior tibial fragment by cancellous screws

Table 9 Radiological result of reduction after operative and conservative treatment (classifications according to Baek Kristensen 1953 and Cedell 1967) Percentage

	Operative treatment $n = 60$	Conservative treatment $n = 29$
Baek Kristensen		
good	91 7	20 7
medium	8 3	69 0
poor	0 0	10 3
Cedell		
anatomical	70 0	0 0
good	16 7	6 9
poor	13 3	93 1

used (Table 11) The most important findings after operative treatment were· a limp (1 patient), moderately increased circumference of the lower leg (2), reduced calf circumference (1), tenderness of ligaments (3), and reduced range of motion (1) After non-operative treatment a limp (1), moderately increased circumference of the lower leg (2), reduced calf circumference (2), tenderness of ligaments (4), and reduced range of motion

Radiological results (Table 13) The injured ankle joint was X-rayed in three views and compared with the good side The oblique view was that used by Bolin (1961) which best reproduced the fibular-malleolar rotation and the joint between the fibula-malleolus and talus

No changes in position had occurred since the primary radiological result of reduction Two non-operatively treated patients had pseudarthrosis at the medial malleolus Both had mild arthrosis causing in one of them moderate symptoms and objective findings, while the other patient was symptom-free Radiological arthrosis was present in 12 of the operated patients and in 19 of those treated non-operatively, but with no complaints and normal objective findings in 8 of the former and in 6 of the latter group

The therapeutic results after operative and non-operative treatment were subjected to two-sided statistical tests This gave the following probabilities Symptoms $P = 0\ 009$ (Fisher's exact test), signs $P = 0\ 013$ (Fisher's exact test), radiological arthrosis $P < 0\ 001$ (χ^2 test). At significance level of $P < 0\ 05$ the results of the two methods differ operative treatment showing better results than non-operative treatment

DISCUSSION

The age distribution and sex ratio in the two materials are similar On the other hand, the occupational strain on the ankle joint (cf Table 3), the primary displacement of the fracture (cf Table 5), and the frequency of major fractures of the posterior tibial margin (cf Table 6) were greater in the operatively treated than in the non-operatively treated group In the non-operatively treated group the staging is based exclusively upon clinical and radiological data Therefore, a few type SE II and III fractures may have erroneously been included in the non-operative group (Cedell 1967) In other words, the operated fractures are loaded with more strain factors than the non-operated ones, but the severity of these factors and their role in the late results cannot be definitely evaluated

Baek Kristensen (1953), in a follow up of 45 SE IV fractures which had been treated by closed reduction according to the principles of Lauge Hansen (1942) found the following subjective results 77 8 per cent ‘good", 20 0 per cent "medium", and 2.2 per cent "poor"

Table 10 Late subjective results (classification according to Cedell 1967). Percentage

	Operative treatment $n = 60$	Conservative treatment $n = 29$
Good	83 3	55.2
Medium	13 3	31 0
Poor	3 4	13 8

ɩle 11 *Classification of late objective results (+) increase, (−) decrease (modification of Cedell's classification)*

nponents	Good	Medium	Poor
t	normal	normal	limp
lower leg (+)	⩽ 1 cm	> 1–2 cm	> 2 cm
f size (−)	⩽ 1 cm	> 1–2 cm	> 2 cm
ament tenderness	none	slight	marked
soplantar flexion (−)	< 15°	16–30°	> 30°
nation-supination (−)	< ⅓	< ⅓	> ⅓
transverso-planus	none	slight	marked

the present material the results obtained ɛk Kristensen's classification) were after rative treatment 88 3 per cent, 8 3 per and 3 4 per cent, respectively, after non-rative treatment, in which reduction was mpted in 51 per cent of the cases, the results e 69 0 per cent 24 1 per cent and 6 9 per t, respectively Cedell (1967) in his follow-of 55 operatively treated SE IV fractures nd subjectively 83 6 per cent "good", 9 1 cent "medium", and 7 3 per cent "poor", ɛctively 43 6 per cent "good", 50 9 per cent edium", and 5 5 per cent "poor", arthrosis 61 8 per cent, '(+)" 21 8 per cent, "+" 12 8 cent, "++" 1 8 per cent, and "+++" 1 8 cent. The subjective result is almost ntical with that in the present group treated osteosynthesis, while the objective result l the arthrosis rate differ significantly from present findings.

In addition to the two studies mentioned ɔve, several authors have reported on the e results of non-operative (e g Bar 1966, ɩschter & Götz 1974, Pohlmann 1971) and nous operative (e g Burwell & Charnley 65, Nonnemann & Brautigam 1977, nkarter 1977 Weber 1966) treatments of malleolar fractures, but only a few of these studies have been comparative (Gay & Evrard 1963, Kett et al 1965, Klossner 1962, Lecestre & Ramadier 1976, Martinez et al 1970, Willenegger et al 1971) Comparison with the results of the last-mentioned authors is difficult because they have used another, less differentiated classification and a different registration of clinical and radiological findings

Cedell (1967) comparing [illegible] late results of operative treatment with [illegible] (1944) after non-operative treatment, [illegible] operative treatment when (i) the [illegible] tibio-fibular ligament is [illegible] with a [illegible] of avulsed bone, (ii) the lateral malleolar fragment is displaced, (iii) a fragment of the posterior tibial margin [illegible] more than one-quarter of the [illegible] is displaced (iv) a medial malleolar fracture is displaced, or (v) when there is a [illegible] of rupture of the deltoid [illegible]

The present [illegible] a significant difference between the results of the two

ɩle 12 *Late objective results (classification according to Cedell 1967) Percentage*

	Operative treatment $n = 60$	Conservative treatment n 29
od	86.6	62.0
edium	11 7	34 5
or	1 7	3 5

Table 13 [illegible] arthrosis [illegible] according to [illegible] (1944) Percentage

	Operative treatment n [illegible]	[illegible]
0	[illegible]	[illegible]
(+)	[illegible]	[illegible]
+	[illegible]	
++	[illegible]	
+++	[illegible]	
	[illegible]	

methods, operative treatment giving better results. It is therefore recommended that operative treatment is used in SE IV fractures with more than minimal displacement, a major displaced fragment of the posterior tibial margin, or with a suspicion of deltoid ligament rupture In this operation an attempt should be made to re-establish an anatomical position, and this applies both to the ligamentous and bony injuries.

REFERENCES

Bar, W (1966) Über Spätergebnisse konservativ behandelter Luxationsfrakturen im oberen Sprunggelenk. *Beitr Orthop Traum* 13, 408–417

Bolin, H (1961) The fibula and its relationship to the tibia and talus in injuries of the ankle due to forced external rotation *Acta radiol. (Stockh)* 56, 439

Burwell, N H & Charnley, A. D (1965) The treatment of displaced fractures at the ankle by rigid internal fixation and early joint movement. *J Bone Jt Surg* 47-B, 634–660

Cedell, C-A & Wiberg, G (1962) Treatment of eversion-supination fracture of ankle (2nd degree) *Acta chir scand* 124, 41–44

Cedell, C-A (1967) Supination-outward rotation injuries of the ankle *Acta orthop scand*, Suppl 110

Gay, R & Evrard, J (1963) Les fractures récentes du pilon tibial chez l'adulte *Rev Chir orthop*, 49, 397–512.

Kett, K., Aichner, H & Wesseli, E (1965) Der Einfluss der Reposition des Malleolus lateralis bei der Behandlung bimalleolaren Knochenbruche. *Mschr Unfallheilk* 68, 82–89

Klossner, O (1962) Late results of operative and non-operative treatment of severe ankle fractures. *Acta chir scand.* Suppl 293

Kristensen, T Baek (1953) *Ankelbrud* Nyt nordisk forlag, København.

Lauge Hansen, N (1942) *Ankelbrud I Genetisk diagnose og reposition* Munksgaard, København

Lecestre, P & Ramadier J O (1976) L fractures bimalléolaires et leurs équivale *Rev Chir orthop* 62, 71–89

Magnusson, R (1944) On the late results in n operated cases of malleolar fractures. Fractures by external rotation. *Acta c scand*, Suppl 84

Martinez, C, Rieunau, G., Gay, R. & Mansat, (1970) Résultats du traitement sanglant fractures malléolaires. *Rev Chir orthop* 665–682.

Muschter, K & Gotz, K. (1974) Ergebn konservativ behandelter Sprunggelenkstraum mit Beteiligung der Syndesmose. *Zbl. C* 99, 267–274

Müller, G M (1945) Fractures of the inter malleolus. *Brit med J* 2, 320

Nonnemann H C. & Brautigam, T (1977) Ber uber 938 bimalleolare Luxationsfraktur *Chirurg* 48, 380–394

Pankarter, F (1977) Spatergebnisse na operativer Versorgung von Verletzung (Frakturen) des oberen Sprunggelenk *Unfallheilk* 80, 243–248

Pohlmann, H (1971) Über Ergebnisse konservativen Behandlung von Mall larfrakturen *Dtsch Ges wesen* 26, 2107–2111

Watson-Jones, R (1955) *Fractures and jo injuries* Vol 2, 4th ed, E & S Livingsto Edinburgh & London.

Weber, B G (1966) Die Verletzungen des obe Sprunggelenkes. In *Aktuelle Probleme in Chirurgie*, Vol. 3 Verlag Hans Huber B und Stuttgart.

Willenegger, H (1961) Die Behandlung Luxations-frakturen des oberen Sprunggelen nach biomechanischen Gesichtspunkten *He chir Acta* 28, 225–239

Willenegger, H, Tauber, J, Landolt, M, Müll J, Plaass, U & Broghammer, H (19 Spatergebnisse nach konservativ und oper behandelten Malleolarfrakturen. *Helv ch Acta* 38, 321–340

Yde, J (1980) The Lauge Hansen classification malleolar fractures. *Acta orthop scand.* 181–192

Yde, J & Kristensen K. D (1980) An fractures Supination-eversion fractures st II Primary and late results of operative non-operative treatment *Acta orthop scan* 51, 695–702.

Correspondence to Kristian D Kristensen M.D, Arsenalvej 68, DK 9800 Hjørring Denmark

Acta orthop scand 51, 991–993, 1980

ON-OPERATIVE TREATMENT OF
[I⁻ˢ TENDON RUPTURES

)M-HARALD EDNA

partment of Surgery, Innherred Hospital, Levanger, Norway

A study of 10 patients treated non-operatively for Achilles tendon ruptures is reported Re-ruptures occurred in three patients. The end-results as regards plantar flexion power and ankle mobility were comparable with those obtained in 24 patients treated operatively

Key words Achilles tendon rupture, treatment

Accepted 24 iv 80

has generally been accepted that total pture of the Achilles tendon should be ated by operation The first series of tients treated systematically with plaster mobilization alone appeared in 1968 (Lea Smith 1968)

The purpose of the present study was to mpare the results previously obtained with erative procedures with those obtained in a n-operatively treated series.

ATIENTS AND METHODS

the years 1976–1978, 10 patients with total chilles tendon ruptures were treated non-eratively according to the method of Lea & nith (1972) by immobilization in a below knee lking plaster cast with the foot in equinus sition for 8 weeks. For an additional 4 weeks a el raise of 2.5 cm was applied Admission to the spital ward was not required

The patients were examined at follow-up 2.1 inge 1 2–2.7) years after the injury The metric plantar flexion force was measured by a essure transducer (LX1420A National miconductor Corporation USA) Three tests ere performed for each leg with the hip, knee d ankle points at right angles. The highest score as used and the unaffected leg served as a ured control A mathematical correction of the easurements was performed as the right leg is 5 7 per cent stronger on average than the left (Damholt & Termansen 1978)

Pronation, supination plantar flexion and dorsiflexion were recorded by an electro-mechanical device measuring the angular movements with an accuracy of ± 1 degree

RESULTS

Re-ruptures occurred in three cases, all within 5 weeks after cast removal One happened apparently without a new trauma. In two patients the non-operative treatment was repeated, but led to a second re-rupture in one case Eventually, two patients were treated operatively

The results of the clinical follow-up examination are shown in Table 1 Of the ten patients, eight were very satisfied with the end-result, and none was dissatisfied They had been absent from work for 6 4 (range 0 5–26) weeks Sports activities were resumed by five out of eight of the patients.

DISCUSSION

The operative treatment of Achilles tendon ruptures has been complicated by skin necrosis, sural nerve affection and

)01-6470/80/060991-03 $02.50/0

Table 1 Results of the clinical follow-up examination of 10 patients treated non operatively for Achilles tendon ruptures

Reduced power	(per cent)	11 (range 19 to −12)
Reduced dorsiflexion	(degrees)	4 (range 14 to − 1)
Reduced plantar flexion	(degrees)	2 (range 12 to − 4)
Reduced pronation	(degrees)	2 (range 15 to −10)
Reduced supination	(degrees)	4 (range 14 to − 4)
Increased tendon width	(mm)	8 (range 19 to 4)

venous thrombosis This has been a stimulus to try non-operative procedures In the 1970s encouraging results of non-operative treatment were published (Gillies & Chalmers 1970 Lea & Smith 1972, Lildholdt & Munch-Jørgensen 1976, Nistor 1976) Others (Inglis et al 1976, Jacobs et al 1978) still found operative treatment to be superior The frequency of re-ruptures reported is listed in Tables 2 and 3

In our series the mobility of the ankle and the power of plantar flexion were both in the same range as that obtained in 24 patients previously treated by operation (not published). Re-ruptures, however, were much more frequent in the non-operatively treated series. Non-operative treatment saves hospital beds. However, in the event of a re-rupture the duration of treatment will be considerably prolonged for the patient

Table 2 Re ruptures in Achilles tendons primarily treated operatively

Author	Year published	No of cases	No of re-ruptures
Solheim	1960	79	1
Kristensen & Andersen	1970	37	1
Lea & Smith	1972	255	4
Inglis et al	1976	48	0
Heim & Heim	1977	99	1
Høgh & Lauritzen	1977	80	0
Dekker & Bender	1977	21	0
Jacobs et al	1978	26	0
Percy & Conochie	1978	77	0
Borgi et al	1978	36	1
Ma & Griffith (percutaneous repair)	1977	12	0
Total		770	8 (1 per cent)

Table 3 Re ruptures in Achilles tendons primarily treated non-operatively

Author	Year published	No of cases	No. of re-ruptures
Lea & Smith	1972	66	7
Lildholdt & Munch Jørgensen	1976	14	1
Nistor	1976	12	0
Inglis et al	1976	31	9
Jacobs et al	1978	32	7
Borgi et al	1978	23	2
Present series		10	3
Total		188	29 (15 per cent)

The disadvantage then of non-operative treatment is the high proportion of re-ruptures, and in this respect it cannot at all compete with operative treatment. The results of non-operative treatment therefore are not good enough for it to be recommended as a routine procedure. Nevertheless, in patients in a high risk category as regards operative treatment or in patients refusing an operation conservative treatment as described by Lea & Smith (1972) should be considered.

ACKNOWLEDGEMENTS

This study was supported in part by grants from the fund of Trøndelag Medical Society

REFERENCES

Borgi, R., Oberlin, P & Faure Cl (1978) La rupture du tendon d Achille, traitement orthopédique ou traitement chirurgical? *Acta orthop belg* 44, 560–566

Damholt, V & Termansen, N B (1978) Asymmetry of plantar flexion strength in the foot. *Acta orthop scand.* 49, 215–219

Dekker M. & Bender J (1977) Results of surgical treatment of rupture of the Achilles tendon with use of the plantaris tendon. *Arch. chir neerl.* 29, 39–46

Gillies, H & Chalmers, J (1970) The management of fresh ruptures of the tendo Achillis. *J Bone Jt Surg* 52-A, 337–343

Heim, U & Heim, C. (1977) Die subkutane Achillessehnenruptur Ergebnisse bei 99 operativ behandelten frischen Verletzungen. *Helv chir Acta* 44, 581–590

Høgh, J & Lauritzen, J (1977) Operativ behandling af subkutan achillesseneruptur *Ugeskr Læg* 139, 941–943

Inglis, A E Scott, W N, Sculco, T P & Patterson, A. H. (1976) Ruptures of the tendo Achillis. An objective assessment of surgical and non surgical treatment. *J Bone Jt Surg* 58-A, 990–993

Jacobs, D, Martens, M., Audekercke, R. van, Mulier, J C. & Mulier, F (1978) Comparison of conservative and operative treatment of Achilles tendon rupture *Amer J Sports Med* 6, 107–111

Kristensen J K. & Andersen, P T (1970) Subkutan achillesseneruptur *Ugeskr Læg* 132, 1661–1666

Lea, R. B & Smith, L. (1968) Rupture of the Achilles tendon. Nonsurgical treatment. *Clin. Orthop* 60, 115–118

Lea, R. B & Smith, L. (1972) Non surgical treatment of tendo Achillis rupture. *J Bone Jt Surg* 54-A, 1398–1407

Lildholdt, T & Munch-Jørgensen, T (1976) Conservative treatment of Achilles tendon rupture. A follow-up study of 14 cases. *Acta orthop scand* 47, 454–458

Ma, G W C & Griffith, T G (1977) Percutaneous repair of acute closed ruptured Achilles tendon. *Clin. Orthop* 128, 247–255

Nistor, L. (1976) Conservative treatment of fresh subcutaneous rupture of the Achilles tendon. *Acta orthop scand* 47, 459–462.

Percy, E. C. & Conochie L. B (1978) The surgical treatment of ruptured tendo Achillis. *Amer J Sports Med* 6, 132–136

Solheim, K. (1960) Subkutan achillesseneruptur En oversikt og et etterundersøkt materiale. *T norske Lægeforen* 80, 689–694

Correspondence to Dr Tom Harald Edna, Department of Surgery, Innherred Hospital, 7600 Levanger, Norway

Acta orthop scand. 51, 995–1006, 1980

HEALING OF ULCERS ON THE FEET CORRELATED WITH DISTAL BLOOD PRESSURE MEASUREMENTS IN OCCLUSIVE ARTERIAL DISEASE

HOLSTEIN & N A LASSEN

Department of Clinical Physiology and Department of Surgery M, Bispebjerg Hospital, Copenhagen, Denmark

The freque[illegible] arterial oc[illegible] pressure ([illegible] measured [illegible] heel (SPP, [illegible] with ulcerations) had diabetes mellitus. The treatment was conservative In 42 feet the ulcers healed after an average period of 5 8 months, in 24 feet major amputation became necessary after an average of 4 3 months. The frequency of healing correlated significantly with the three distal blood pres[illegible]

feet as regards the healing rates although infection and peripheral neuropathy were frequent in the diabetic group The data show that the systolic digital blood pressure is a particularly valuable prognostic parameter

Key words amputation, ankle blood pressure, arteriosclerosis diabetes mellitus, diabetic gangrene, distal blood pressure, ischaemic ulcers, neuropathic ulcers, photocell, skin perfusion pressure, strain gauge plethysmography

Accepted 14.xii.79

The assessment of the prognosis of ulceration or gangrene of the foot determines the treatment of patients with occlusive arterial disease of the legs. Arterial reconstruction or amputation may be necessary when ischaemia is progressive, on the other hand spontaneous healing is not uncommon (Mathiesen et al. 1970). Pedal pulses are often absent even in mild claudication and cannot be used in the prognosis. Rest pains are alarming but may be transient, and objective signs of local ischaemia are often difficult to evaluate

Healing of skin lesions on the feet has been shown to correlate with the systolic digital and the systolic ankle blood pressure (Carter 1973) and healing of surgical wounds following major amputations correlates well with the local skin perfusion pressure (Holstein 1973, Lassen & Holstein 1974, Holstein et al 1979 a and b) and the segmental systolic blood pressure (Barnes et al 1976 Raines et al 1976, Wagner & Buggs 1978).

The present study was undertaken to

0001 6470 80 060995–12 $02.50 0

Table 1 Age distribution in 66 cases of ulcers on the feet

		41–50	51–60	61–70	71–80	81–90	Total	*Age (years)
Cases without diabetes mellitus	Healing	1	2	8	6	0	12	66 4
	Major amputation	0	1	3	7	3	14	72.6
Cases with diabetes mellitus	Healing	0	4	13	8	0	25	63 2
	Major amputation	0	2	1	4	3	10	72.4

*arithmetic mean age
male/female ratio 39/27 = 1 44 Arithmetic mean age without diabetes mellitus (DM) 69 2 years wi
DM = 68 0 years.

compare three different distal blood pressure parameters in relation to healing of ulcers on the feet in occlusive arterial disease the systolic digital blood pressure (SDBP), the systolic ankle blood pressure (SABP) and the skin perfusion pressure on the heel (SPPH)

PATIENTS AND METHODS

Patients In a 1 year period (1 3 1973 to 28 2 1974) 68 patients with 72 ulcerated feet evaluated in the Department of Clinical Physiology for arterial insufficiency were included in the series. Six patients died leaving 62 patients with 66 ulcerated feet for study The distribution [illegible]

in the 32 diabetic patients was 5 years or less in 7 patients and 10 years or more in 20 patients Eleven patients were taking insulin

The patients inclusion in the study was based on the following criteria

(1) The presence of an ulcer on the toes or foot distal to the ankle joint and comprising a skin area of at least 5 by 5 mm and penetrating at least to the subcutis
(2) The presence of occlusive arterial disease of the legs as determined by the strain gauge technique (see below) on the ankle and on the first toe
(3) Duration of the lesion of at least 1 month after the first examination in the department Thereby lesions were excluded which were so severe that major amputation had to be carried out as soon as the patient s condition allowed surgery as well as those lesions which healed rapidly and uneventfully
(4) Treatment of the arterial condition durin follow up by vascular reconstruction sympathectomy or treatment in the form o induced hypertension by mineralocort co d (Lassen et al. 1968) caused the patients to b excluded from the series. However patient with skin lesions previously treated wit vascular reconstruction were include provided that a skin lesion and significant occlusive arterial disease was still present.
(5) Patients with clinical signs of chronic venou disease – in addition to the arterial occlusion – were excluded from the study

The treatment was thus conservative consisti of relevant dressing antibiotics (after culture) w the case of deep infection and surgical drainag and revision in the presence of pus. Whe necessary, footwear was corrected and externa pressure on the lesions was relieved by in dividually fitted insoles (Holstein et al 1976).

Methods The following parameters were recorde with intervals of about 1 to 3 months (1) Th systolic digital blood pressure (SDBP), (2) Th systolic ankle blood pressure (SABP) and (3) Th skin perfusion pressure on the heel (SPPH). Th SDBP and the SABP were measured by the stra gauge technique (Strandness & Bell 1965 Gundersen 1972, Nielsen et al. 1972) using miniature cuff inflatable part 2 4 × 10 cm on th first toe and a 12 × 26 cm cuff at the ankle Th presence of ulcerations on the first toe did no prohibit measurements However in two case where the first toe was necrotic, measurement were performed on the second toe using a 1 6 c broad cuff Before inflation of the miniature cuff the toes were carefully emptied of blood b squeezing them gently with the fingers. Th SPPH was measured by the photoelectr

Table 2 Neurological findings

	No of cases With DM*	Without DM
Reflexes		
Ankle reflex absent knee reflex absent	14	0
Ankle reflex absent knee reflex present	17	6
Ankle reflex present, knee reflex present	4	25
Sensation in the toes		
**Vibration sense absent	16	3
**Vibration sense decreased	16	15
[illegible]on of temperature absent	12	2
[illegible]on of temperature decreased	14	4
Perception of pinprick absent	8	2
Perception of pinprick decreased	16	4
Perception of light touch absent	3	2
Perception of light touch decreased	10	1
Position sense absent	2	0
Intact sensation	3	13

* DM – diabetes mellitus.

** Vibration sense examined objectively by biothesiometry Decreased vibration sense 30–50 Volt Absent on sense > 50 Volt.

The finding of two or more abnormal neurological parameters was considered as peripheral neuropathy

technique (Nielsen et al 1973, Holstein et al 1979 c) using a photoelectric surface probe for recording of the skin blanching threshold external pressure measured with a small plastic cushion connected to a mercury manometer The presence of arterial insufficiency was indicated by the finding in all the patients of an SABP below systolic auscultatory brachial blood pressure or by an ankle to toe gradient of 64 mmHg or more (Nielsen et al. 1972) Moreover the presence and the severity of peripheral neuropathy was determined by clinical examination with the exception of the vibration sense, which was measured by biothesiometry on the pulp of the first toe (Steiness 1963) Table 2 shows the neurological findings.

Table 3 The healing rates at different distal blood pressures

	First and final measurements		First and final measurements		First and final measurements	
SDBP	< 20 mmHg		20–29 mmHg		≥30 mmHg	
Non-diabetics	3/12	0/13	1/3	4/5	13/16	13/13
Diabetics	4/12	2/9	3/5	3/6	18/18	20/20
Total	7/24	2/22	4/8	7/11	31/34	33/33
SABP	< 50 mmHg		50–99 mmHg		≥100 mmHg	
Non-diabetics	1/7	0/8	8/16	11/17	8/8	6/6
Diabetics	0/2	1/5	10/18	9/15	15/15	15/15
Total	1/9	1/13	18/34	20 32	23/23	21/21
SPPH	< 20 mmHg		20–39 mmHg		≥40 mmHg	
Non-diabetics	1/5	3/14	7/16	7/10	9/10	7/7
Diabetics	2/5	0/2	7/13	9/17	16/17	16/16
Total	3/10	3/16	14/29	16/27	25/27	23/23

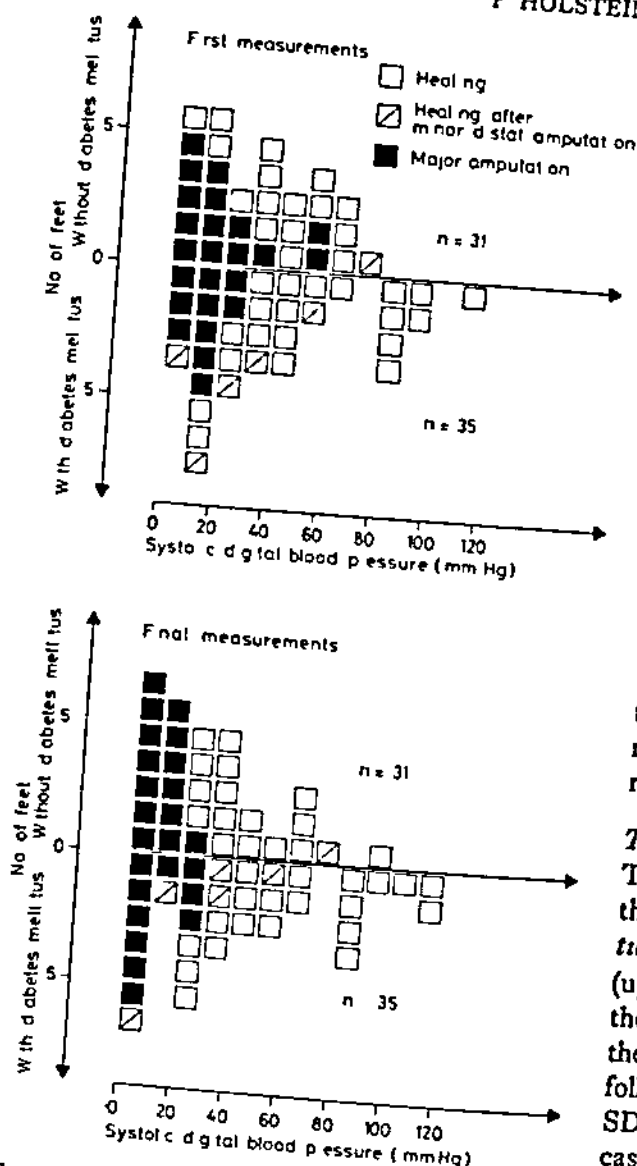


Figure 1 Healing of 66 ulcerated feet in relation to the systolic digital blood pressure (SDBP)

Experimental conditions The patients were examined in the supine position with legs horizontal and at a room temperature of 25° ± 2°C The temperature of the toes was at least 25°C before measurements were started and the systemic blood pressure was measured repeatedly by auscultation using a 26 by 12 cm cuff round the left arm

RESULTS

Mortality Six patients (9 per cent) with six ulcerated feet died before the final outcome, i e healing or major amputation was established Two of these patients had diabetes mellitus The time of observation was from 1 to 6 months in five cases and 45 months in one case These six cases are excluded from the following analysis concerning the rate of healing in relation to the distal blood pressure

Healing Healing took place in 42 out of the 66 ulcerated feet (64 per cent) In six of these feet the healing took place after a minor amputation or resection on the foot, i e the limb was saved The time to healing from the first examination averaged 5 8 months (1 to 23 months) In 24 extremities major amputation below or above the knee became necessary because of rest pains or progressive tissue destruction by ischaemia and/or infection The time until major amputation was required averaged 4 3 months (1 to 22 months)

The systolic digital blood pressure (SDBP). The correlation between the healing rate and the SDBP as measured at the *first examination* in the department is shown in Figure 1 (upper panel) and Table 3 When classifying the ulcerations into three groups according to the appearance of this histogram the following healing rates are found With SDBP of below 20 mmHg only 7 out of 24 cases healed (29 per cent) With SDBP of 20 to 29 mmHg four out of eight cases (50 per cent) healed – and with SDBP of 30 mmHg or above 31 out of 34 cases (91 per cent) healed

During the long period of observation, however, spontaneous improvements as well as deteriorations of the arterial supply obviously took place and when relating the SDBP measured at the *final examination* viz the SDBP measured just after healing or just before an inevitable major amputation, the following healing rates appear (Figure 1 lower panel, and Table 3) With SDBP below 20 mmHg only two out of 22 ulcerated feet (9 per cent) healed In both these cases healing took place only after a minor distal amputation eliminating the low pressure tissue

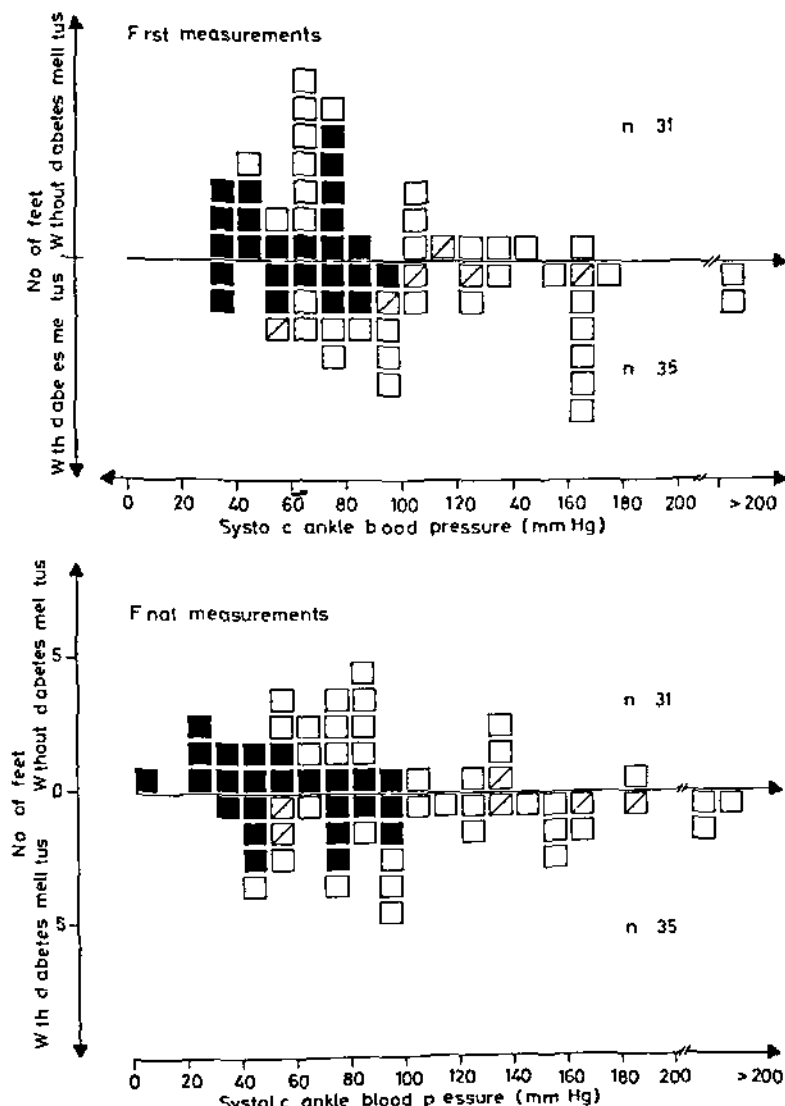
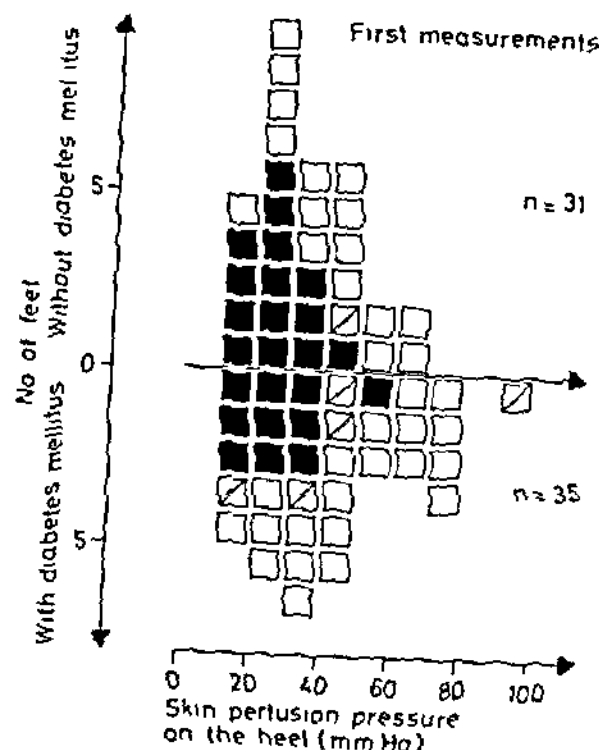


Figure 2 Healing of 66 ulcerated feet in relation to the systolic ankle blood pressure (SABP)

th SDBP of 20 to 29 mmHg 7 out 11 cases (64 per cent) healed and with BP of 30 mmHg or above all 33 cases (100 cent) healed The correlations between SDBP and the healing rates are highly nificant for the first measurements as well for the final measurements ($P < 0\,001$, the k sum test)

e systolic ankle blood pressure (SABP)

ure 2 and Table 3 show the healing rates in relation to the SABP measured at the *first examination* and at the *final examination* The histograms show that the ulcerations can be classified into three groups with SABP below 50 mmHg with SABP of 50 to 99 mmHg and with SABP of 100 mmHg or more The correlations between the healing rates and the SABP are highly significant ($P < 0\,0001$ the rank sum test) There are no apparent differences between the healing rates with identical pressure range at the first and at the final measurements.



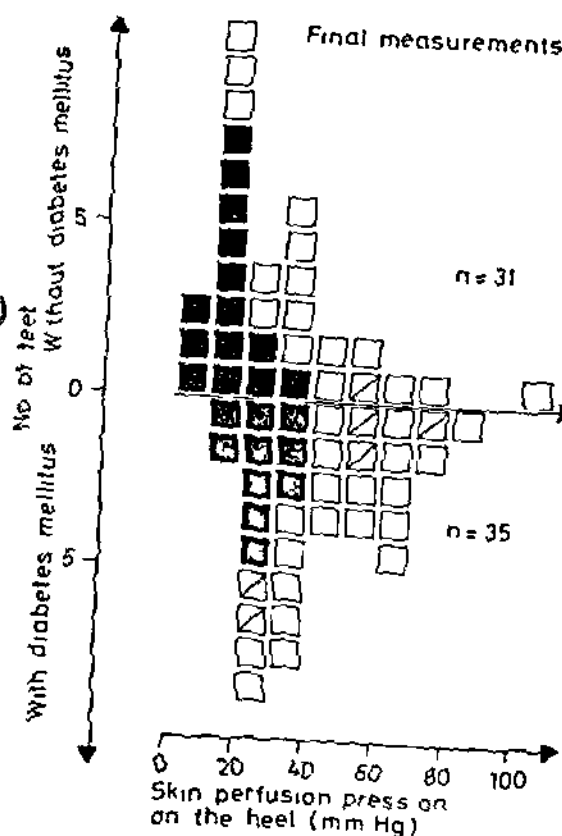


Figure 3 Healing of 66 ulcerated feet in relation to the skin perfusion pressure on the heel (SPPH)

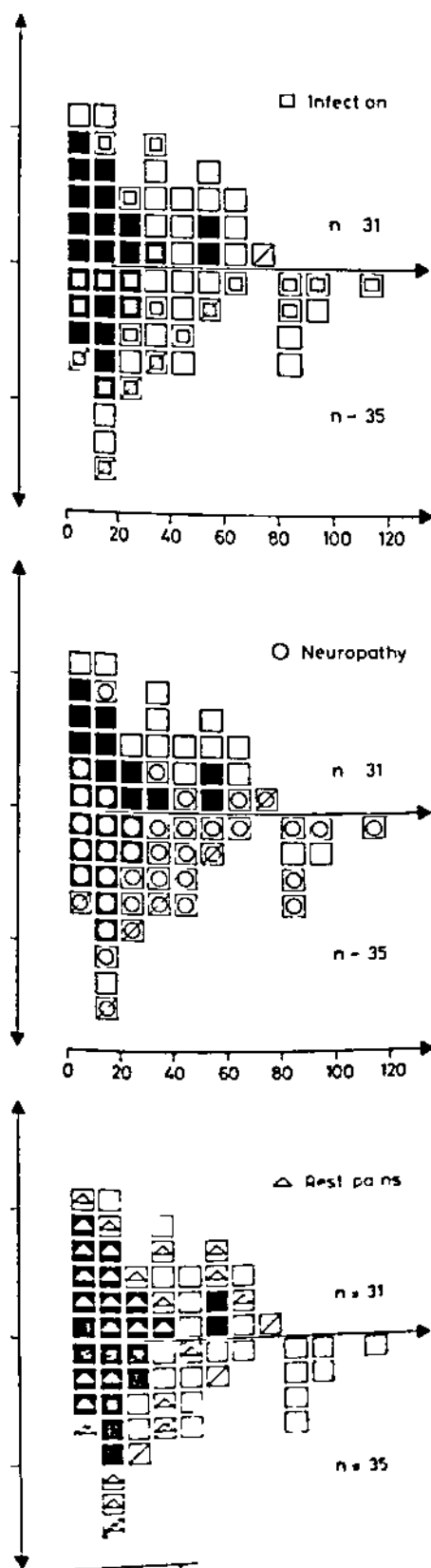
The skin perfusion pressure on the heel (SPPH) Figure 3 and Table 3 show that the

relations between the healing rates and the SPPH are highly significant ($P<0.001$ the rank sum test)

Diabetes mellitus There was no signific difference between the healing rate in diab cases (25 out of 35 cases = 71 per cent) non-diabetic cases (17 out of 31 cases = per cent) ($P>0.10$, chi square test), eit *when* comparing the total numbers or wh *relating the* healing rates to the distal blo pressure parameters (Table 3 and Figu 1–3) The time taken for healing to occ aver[illegible] the o[illegible] to 1 [illegible] ($P>0.10$, the Mann-Whitney test) Nevertheless the distal pressure parameters in the diabetic group were on average highe than in the non-diabetic group (Table 4)

The first pressure measurements were on average equal to the final pressure measurements for all three parameters (Table 4) ($P>0.1$, the Wilcoxon test for paired comparisons) The variation with time – as expressed in standard deviations of the difference between the first and the final pressures – was greatest for the digital pressures

Neuropathy and infection Figure 4 (upper panel) shows the distribution of peripheral neuropathy in relation to the results and the initial measurement of SDBP Thirty two out of 35 cases in the diabetic group (91 per cent) had peripheral neuropathy against only 8 out of 31 cases in the non diabetic group (26 per cent) ($P<0.001$, the chi square test) *The* presence of peripheral neuropathy *was not* correlated with the rate of amputation *or with the SDBP*



As could be expected infection (Figure 4, intermediate panel) was also especially characteristic of the diabetic group 19 out of 35 cases (54 per cent) against 4 out of 31 cases (13 per cent) ($P<0.001$, the chi square test) in the non-diabetic group Infection was not correlated with the rate of amputation or with the SDBP

Rest pains At the first examination rest pains were present in 29 feet and correlated significantly with the distal blood pressure (Figure 4, lower panel) ($P<0.001$, the rank sum test) However, rest pains disappeared in 15 feet, i e in all cases that healed

On the other hand, in 22 out of the 24 extremities which required major amputation, rest pains were the main reason for this outcome Thus rest pains when persistent and severe are a major determinator of the result But rest pains may be transient (15 cases) or may develop at a late stage even in the case of an ulcer in combination with a critically low digital blood pressure This is the case in particular in diabetic cases where rest pains may even fail to develop at all

Prognostic value of the three distal blood pressure parameters Table 5 lists the prognostic value of the initial pressures as determined by (1) risk of major amputation at low pressures, (2) chance of healing at high pressures, (3) the number of cases with intermediate pressures viz borderline values which do not indicate the prognosis We prefer the SDBP with only a few borderline cases (12 per cent) and in particular an SDBP of above 30 mmHg indicates a good prognosis In the two exceptions with an initial SDBP of the order 50 to 60 mmHg who required major amputation (Figure 1 upper panel) the patients sustained occlusive arterial deteriorations in spite of this high distal pressure In one patient

Figure 4 Infection, neuropathy and rest pains at the first examination in relation to the first measurements of the systolic digital blood pressure The symbols are added to the histogram of Figure 1 upper panel

Table 4 The first distal blood pressures compared with final distal blood pressures and distal pressures in non diabetics compared with distal pressures in diabetics

		First measurements			Final measurements			The difference First measurement minus final measurement		
		mean mmHg	P	range mmHg	mean mmHg	P	range mmHg	mean mmHg	SD mmHg	range mmHg
SDBP	non-diabetics ($n=31$)	30 7	>0 1	[0 71]	29 4	>0 1	[0, 117]	+1 3	21 8	[−61, 56]
	diabetics ($n=35$)	40 2		[0, 117]	42.7		[0, 118]	−2 5	21 5	[−87, 52]
SABP	non-diabetics ($n=31$)	79 2	<0 05	[31, 164]	75 0	<0 05	[0, 187]	+4 2	26 3	[−31, 112]
	diabetics ($n=33$)*	105 3		[30, 248]	102 6		[35, 243]	+2 7	17 3	[−38, 48]
SPPH	non-diabetics ($n=31$)	31 7	0 1> >0 05	[10, 68]	30 4	<0 01	[0, 110]	+1 3	12 3	[−42, 20]
	diabetics ($n=35$)	41 7		[10 90]	41 3		[16, 85]	+0 4	11 7	[−15 27]

P = P value by the Mann-Whitney test in comparing pressures in non-diabetics with pressures in diabetics.
The comparison of the first and the final pressures is made by the paired Wilcoxon test All P values were above 0 10 (not indicated on the table)
* The SABP figures of diabetics are calculated for 33 cases only In the remaining two cases it was technically impossible to record the ankle pressures which were above 300 mmHg

Table 5 The prognostic value of the first measured SDBP SABP and SPPH

Risk of amputation at low pressure in per cent (confidence limits (95%))	No of borderline cases in per cent of whole series	Chance of healing at high pressure in per cent (confidence limits (95%))
(SDBP < 20 mmHg) 71% (49–87%)	(SDBP 20–29 mmHg) (8/66 = 12%)	(SDBP ≥ 30 mmHg) 91% (80–99%)
(SABP < 50 mmHg) 89% (55–99%)	(SABP 50–99 mmHg) (34/66 – 52%)	(SABP > 100 mmHg) 100% (85–100%)
(SPPH < 20 mmHg) 70% (35–93%)	(SPPH 20–39 mmHg) (22/66 = 44%)	(SPPH ≥ 40 mmHg) 93% (76–99%)

the occlusive event accompanied a fall in systemic blood pressure (Figure 5) and in the other patient a thromboembolic attack rendered a well nourished leg severely ischaemic. Such unpredictable occlusive events may at any time change the prognosis for an ulceration

The SABP and the SPPH distributions contain many borderline cases although the very low as well as the very high ankle blood

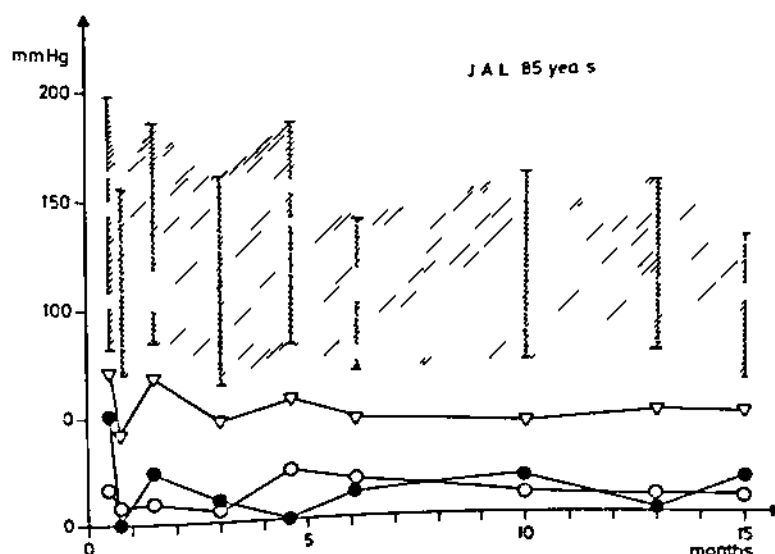


Figure 5 The measurements on a leg with ulceration of the toes in a patient aged 85 years Filled circles Systolic digital blood pressures Open circles Skin perfusion pressure on the heel Open triangles Systolic ankle blood pressure Hatched area The systemic pulse ...asured as the auscultatory arm blood pressure Initially the

pressures indicate the prognosis very precisely

We also analysed the prognostic value of the combination of two out of three distal blood pressure parameters as well as of all three parameters combined These combinations were not, however, significantly better than the SDBP

DISCUSSION

Carter (1973) has previously published a study of the systolic digital and systolic ankle blood pressure in relation to healing of skin lesions on the feet Using a single determina tion of the distal blood pressures he found that digital blood pressures of above 30 mmHg or ankle blood pressures of above 80 mmHg indicated healing of the lesions in *non diabetic* patients which is in good agreement with our findings as also recently confirmed by Tønnesen et al (in press) In Carter's series (1973) several *diabetic* patients, however, required major amputation even when the digital or the ankle pressures con siderably exceeded the critical values found in non-diabetic patients This is in contrast to our data which show no significant difference between the healing rates in diabetics and non-diabetics at identical distal blood pressure This discrepancy deserves a detailed discussion

From a methodological point of view Carter s results might suggest that distal blood pressure measurements are less reliable in diabetic patients i e perhaps falsely high due to mediasclerosis prohibiting proper transmission of the cuff pressure through the walls of the arteries (Nielsen & Munkgaard Rasmussen 1973 Holstein et al 1975) Such falsely high pressures were recorded in at least two cases of our series for *ankle* blood pressures, viz the arteries were not occluded by cuff pressures of 300 mmHg the systolic arm blood pressure being 130 and 140 mmHg respectively Direct intra arterial blood pressure measurements however have shown that at the ankle level mediasclerosis is only occasionally a source of error (Carter 1973) Our data for healing show that at the *digital* level mediasclerosis can not be a significant cause of erroneously high pressures

The occurrence in Carter s series (1973) of major amputations in diabetic cases with high digital pressure might support the presumption of a haemodynamically significant diabetic microangiopathy as a cause of gangrenous skin lesions. However recent studies (Strandness et al. 1964 Conrad 1967 1968 Nielsen 1973) strongly argue against this hypothesis, as also pointed out by Carter (1973) Moreover the results of our study on digital pressures do not support microvascular blocking as a haemodynamic pathogenetic factor in a lesion of the diabetic foot.

Carter explained the non ischaem c major amputations in diabetics in his series by the presence of peripheral neuropathy and infection In our series the conservative therapy was aimed especially at the elimination of the effect of these conditions and this is probably why the healing rate in diabetics was equal to the healing rate in non-diabetics.

Finally our cases were selected as having passed over into a subchronic phase suitable for the study of healing i e the legs with the lesions had survived at least 1 month Thirty four legs including 17 diabetic legs, undergoing major amputation during the first month were thus excluded from our series. These cases were severely ischaemic except for one case a diabetic leg with normal distal pressures but with a septic inflammation in the calf originating from a plantar abscess. Adequate therapy was initiated too late and a below knee amputation was made This case illustrates that diabetic lesions may lead to major amputation in spite of adequate blood supply, if treatment is delayed or inadequate.

Oakley (1954) classified diabetic foot lesions as ischaemic septic neuropathic or due to a combination of these causes. This classification gives the key to the proper therapy and should replace the non-specific term 'diabetic gangrene which is still commonly used At present Oakley s

classification is more useful than ever because ischaemia can be defined objectively by measurement of the distal blood pressure. If the local blood pressure is too low for healing of a lesion revascularization must be considered. In this instance it should be emphasized that patients with digital blood pressures of below 20 mmHg but without skin lesions and without rest pains are not uncommon. However, if a traumatic skin lesion occurs or if gangrene develops the leg is threatened. We therefore also consider these patients as potential candidates for vascular surgery.

The three parameters studied were all significantly correlated with healing. The SABP being valuable in the diagnosis of the arterial occlusion is, however, less helpful in judging the prognosis. The figures for healing in relation to the SDBP and SPPH agree with previous studies on wound healing after major amputation (Holstein 1973, Holstein et al. 1979 a, b) and the SDBP is particularly valuable. On the basis of our initial pressure measurements in combination with the final pressure measurements we feel justified in concluding that when the digital blood pressure lies constantly below 20 mmHg healing of an ulcer will only rarely take place whereas at digital pressures of above 30 mmHg ischaemia is not a problem in wound healing.

ACKNOWLEDGEMENTS

This investigation was supported in part by "Hjerteforeningen" by Den laegevidenskabelige forskningsfond for Storkøbenhavn og Faerøerne og Grønland" and by the Danish Medical Research Council.

REFERENCES

Barnes, R W, Shanik G D & Slaymaker E E (1976). An index of healing in below-knee amputation. Leg blood pressure by Doppler ultrasound. *Surgery* 79, 13–20

Carter, S A (1973) The relationship of distal systolic pressures to healing of skin lesions in limbs with arterial occlusive disease with special reference to diabetes mellitus. *Scand J clin Lab Invest*, Suppl 128, 239–243

Conrad, M C (1967) Large and small artery occlusion in diabetics and nondiabetics with severe vascular disease. *Circulation* 36, 83–90

Conrad, M C (1968) Abnormalities of the digital vasculature as related to ulceration and gangrene. *Circulation* 38, 568–581

Gundersen J (1972) Segmental measurements of systolic blood pressure in the extremities including the thumb and the great toe. Thesis. *Acta chir scand.*, Suppl 426

Holstein, P (1973) Distal blood pressure as angiographical findings in distal occlusive arterial disease of the legs. *Folia angiol. (Pisa)* 23, 185–193

Holstein, P, Larsen, K & Sager, P (1976) Decompression with the aid of insoles in the treatment of diabetic neuropathic ulcers. *Acta orthop scand* 47, 463–468

Holstein, P, Sager, P & Lassen, N A. (1979a) Wound healing in below knee amputations in relation to skin perfusion pressure. *Acta orthop scand* 50, 49–58

Holstein P, Dovey, H & Lassen N A. (1979b) Wound healing in above-knee amputations in relation to skin perfusion pressure. *Acta orthop scand* 50, 59–66

Holstein, P, Nielsen, P E & Barras, J-P (1979c) Blood flow cessation at external pressure in the skin in normal human limbs. Photoelectric recordings compared to isotope washout and to local intra-arterial blood pressure. *Microvasc Res* 17, 71–79

Lassen N A., Larsen, O A., Sørensen, A W S, Hallbook, T, Dahn, I, Nielsen, R. & Westling H (1968) Conservative treatment of gangrene using mineralocorticoid induced moderate hypertension. *Lancet* i, 606–611

Lassen N A & Holstein P (1974) Use of radioisotopes in assessment of the distal blood flow and distal blood pressure in arterial insufficiency. *Surg Clin N Amer* 54, 39–55

Mathiesen F R, Errebo Larsen, E & Wulff, M. (1970) Some factors influencing the spontaneous course of arterial vascular insufficiency. *Acta chir scand* 136, 303–309

Nielsen P E., Bell, G & Lassen, N A (1972) The measurement of digital systolic blood pressure by strain gauge technique. *Scand J clin Lab Invest* 29, 371–379

Nielsen P E (1973) Does diabetic microangiopathy cause development of gangrene *Scand J clin Lab Invest*, Suppl 128, 229–234

Nielsen, P E & Munkgaard Rasmussen, S (1973) Indirect measurement of systolic blood pressure by strain gauge technique at finger, ankle and toe in diabetic patients without symptoms of occlusive arterial disease *Diabetologia* 9, 25–29

Nielsen P E, Lønsman Poulsen, H & Gyntelberg F (1973) Arterial blood pressure in the skin measured by a photoelectric probe and external counterpressure *VASA* 2, 65–74

Oakley, W (1954) Diabetes in surgery *Ann roy Coll Surg Engl* 15, 108–119

Raines, J K, Darling R C, Buth J, Brewster, D C & Austen, W G (1976) Vascular laboratory criteria for the management of peripheral vascular disease of the lower limbs. *Surgery* 79, 21–29

Steiness, I (1963) Diabetic neuropathy Vibration sense and abnormal tendon reflexes in diabetics. pp 22–37 University Publishers, Aarhus.

Strandness D E Jr & Bell J W (1965) Peripheral vascular disease Diagnosis and objective evaluation using a mercury strain gauge *Ann Surg* 161, Suppl 4 3–35

Strandness, D E Jr, Priest R E & Gibbens, G E (1964) Combined clinical and pathologic study of diabetic and non-diabetic peripheral arterial disease *Diabetes* 13, 366–376.

Tønnesen, K H, Sager P Noer I Holstein P, Tønnesen P A & Lassen N A Pre- and postoperative distal pressure measurements in reconstructive procedures in patients with multiple level arterial occlusions *Ischaemic limb disease* (Ed Tønnesen K. H & Lassen N A) F A Y L Publishers, Copenhagen, Odense Aarhus (In press)

Wagner, F W & Buggs, H (1978) Use of doppler ultrasound in determining healing levels in diabetic dysvascular lower extremity problems *Gangrene and severe ischemia of the lower extremities* (Ed Bergan J J & Yao, J S T) Grune & Stratton New York San Francisco, London.

Correspondence to P Holstein, Bredland 3, DK 2850 Narum Denmark

Acta orthop scand. 51, 1007–1012, 1980

MECHANICS OF THE HALLUX VALGUS FOOT AND THE EFFECT OF KELLER'S OPERATION

M. DHANENDRAN*, J P POLLARD** & W C HUTTON*

*Polytechnic of Central London, and **Middlesex Hospital, London, U K.

Using a system for measuring the load distribution under the foot, patients with hallux valgus were compared, before and after undergoing Keller's operation, with a group of normal subjects. Preoperatively the patients showed reduced loading under all their toes and increased loading under their lateral metatarsal heads, the decrease under the hallux was found to correlate with an increase in hallux valgus angle. Postoperatively there was a further decrease in loading under the hallux and an increase under the first metatarsal head.

Key words hallux valgus, Keller's operation, load distribution

Accepted 24 iii 80

There are many factors which contribute to the aetiology of hallux valgus. The full range has been reviewed extensively (Hardy & Clapham 1952, Kelikian 1965, Du Vries 1973, Edgar 1976) There are three basic types of operations that are performed to correct hallux valgus osteotomy, arthrodesis and arthroplasty, of which there are numerous variations. However, the excision arthroplasty of the proximal phalanx described by Keller (1904) and earlier by Davies–Colley (1887) is possibly the most commonly used

In normal walking the medial side of the forefoot is heavily loaded with the hallux carrying about twice as much load as the other toes combined and about the same as the first metatarsal head (Hutton & Dhanendran 1979) It was thus felt relevant to compare the loading pattern under the hallux valgus foot with that under the normal foot and correlate any differences with the severity of the deformity To complete the comparison it was of interest to compare the loading pattern obtained from the patients before and after Keller's operation.

It is hoped that the results presented here will better explain the progressive changes occurring with hallux valgus and allow treatment to be planned accordingly

SUBJECTS STUDIED

Sixty-five feet from thirty four female patients with hallux valgus were studied Their mean weight was 59 1 kg and their ages ranged from 16 years to 78 years with a mean of 46 8 years. Thirty-one patients had bilateral hallux valgus. The three normal feet of the patients with unilateral hallux valgus were not included in this study

The results were compared with those from sixty-four normal feet of thirty-two females with no previous history of foot or gait abnormalities. Their mean weight was 59.3 kg and their ages ranged from 15 years to 66 years with a mean of 40 7 years. They all had full foot and ankle movements. None of them had ever sought treatment for their feet and none had toe deformities or painful callosities.

Eleven of the thirty four patients were measured about a year after a Keller procedure. In five of these patients only one foot was operated

0001 6470. 80. 0601007–06$02.50/0

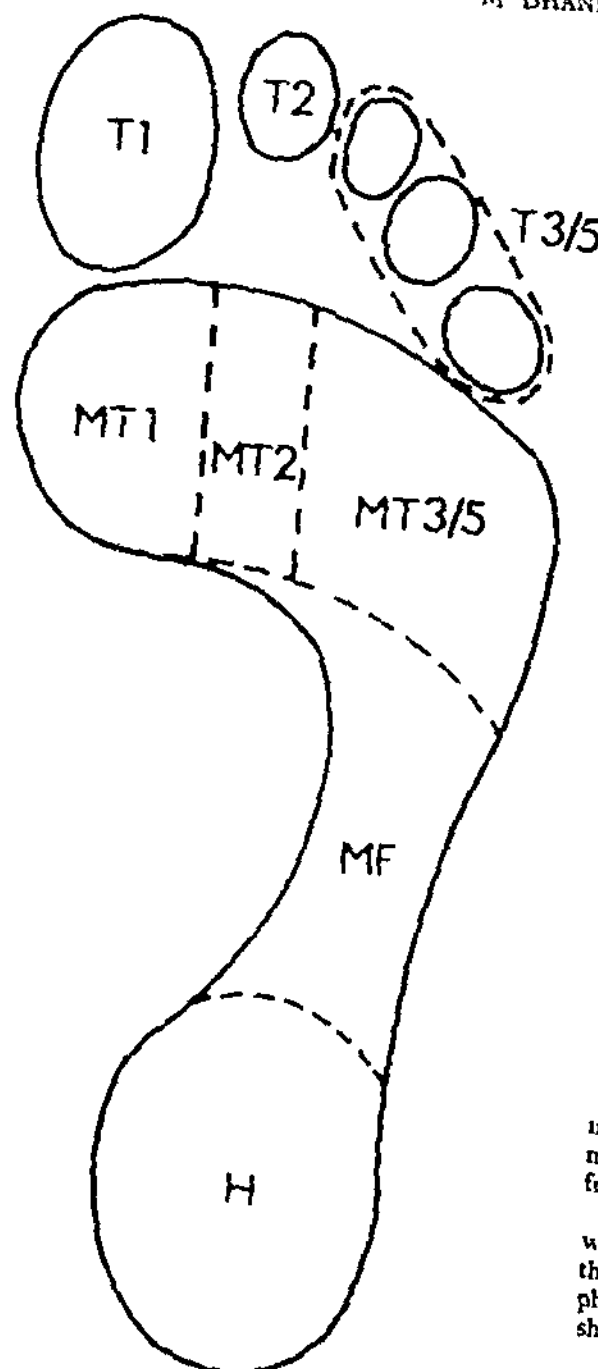


Figure 1 The eight areas of the foot

on, making a total of 17 feet for comparison before and after surgery Their ages ranged from 51 to 78 years with a mean of 63 3 years.

METHOD

The distribution of vertical load under the feet of the patients and the normal subjects was measured using a system of 128 strain load cells connected to a minicomputer storage and processing The load cells were packed in a 16 × 8 matrix giving an over sensitive surface of 25 by 12.5cm. The d the system have been described el (Dhanendran et al. 1978).

The load cell matrix was set in an 8 walkway upon which subjects walked bare their normal walking speed. Their s position was adjusted so that the required f on the load sensitive surface without any tion to their normal gait. A piece of paper the outline of the load cells printed on i sandwiched between a cloth sheet and the cells. The cloth sheet had a water-proof surface and its under surface was coated printer's ink so that when a subject stepped o load cells an inked impression of the foo correct register, was printed on the sheet of p The upper surface of the cloth sheet was pa the same colour as the walkway so that subject was unaware of the exact location of load cells.

For ease of analysis the foot was divided eight areas as shown in Figure 1 For each w the force against time waveform was stored each load cell. From this the force waveform for t eight areas of the foot was computed. T parameters were extracted from the e waveforms.

1 The peak force in each area normaliz for the subject's body weight
2. The contact time for each area, normalize for the contact time for the entire foot.

For convenience, the three lateral toes we included together as were the three latera metatarsal heads. The means of the measurements from four walks were computed for each foot.

The hallux valgus angle was measured from weight-bearing radiographs This was defined as the angle between the long axes of the proximal phalanx of the hallux and the first metatarsal shaft

RESULTS

Comparison between the normal groups of subjects and the preoperative group of patients

The means of the peak force and contact time parameters for the 65 feet with hallux valgus are compared with the means for the 64

*[illegible]le 1 The mean values of the peak forces for normal and hallux feet Significant differences between the means are indicated (**—1 per cent *—5 per cent Mann Whitney Test)*

	Peak Force							
	T1	T2	T3/5	MT1	MT2	MT3/5	MF	[illegible]
ormal feet	17 8	3 2	5 2	25 3	24 3	30 9	10	[illegible]
allux Valgus feet	11 1**	2.3**	4 8*	26 5	26 0	41 5**	11 9	[illegible]

Table 2 The mean values of the contact times for normal and hallux [illegible]

	Contact T[illegible]							
	T1	T2	T3/5	MT1	MT[illegible]	MT[illegible]	[illegible]	[illegible]
ormal feet	56 2	26 1	38 7	80 8	84 3	[illegible]	[illegible]	[illegible]
allux Valgus feet	43 4**	24 3	34 4	80 5	[illegible]**	[illegible]**	[illegible]	[illegible]

ormal feet in Tables 1 and 2 The Mann Whitney statistical test was used for the com arison and only results significant at the 5 er cent level or better will be discussed

In the hallux valgus feet the first and econd toes carried less load while the lateral hree metatarsal heads carried more load The ontact time showed a similar trend with a educt on for the hallux and increases for the lateral three [illegible] and the heel [illegible]

Comparison [illegible] patients

There was [illegible] (P – 0 1 per [illegible] the hallux [illegible]

Table 3 The mean values of the peak forces for the pre- and postoperative hallux valgus feet

	Peak Force							
	T1	T2	T3/5	MT1	MT2	MT3/5	MF	H
Preoperative feet	7 7	2 1	5 4	27 4	26 9	41 9	12 4	63 8
Postoperative feet	2 5**	1 3	3 6	33 3*	29 4	38 9	11 7	59 2

second toe also showed a significant negative correlation in load ($P = 1$ per cent) with the hallux valgus angle

Comparison between the preoperative and the postoperative group of patients

Tables 3 and 4 show the mean values of the peak force and contact time parameters measured for the 17 feet pre- and postoperatively The only differences postoperatively were a further reduction in hallux loading, an increase in loading under the first metatarsal head and a further decrease in contact time for all the toes.

DISCUSSION

As compared to the normal group, the preoperative group of patients showed a reduction in loading and contact time under the hallux and a reduction in loading under the second toe The reduction under the second toe, although statistically significant, should not affect foot function to any great extent because it carries only a small percentage of the body weight This reduction in loading may have been caused by the displaced hallux crowding the second toe and thus preventing sufficient activity of the plantar flexors.

The activity of the short and long flexors of the hallux determines the degree of at kick-off The sesamoids are incorporated into the tendons of the flexor hallucis brevis as they pass under the metatarsal head while the flexor hallucis longus tendon passes between the two branches of the flexor hallucis brevis. The valgus deformity of the hallux is usually accompanied by a rotation so that the medial border moves downwards (everts) Additionally, the sesamoids slip their position beneath the metatarsal head, moving laterally relative to the metatarsal head. This means that the long and short flexors no longer act as true flexors but more as adductors of the hallux (Kelikian 1965). This impairment in function can account for the reduction of hallux loading with any stiffening of the metatarsophalangeal joint due to arthritic changes being an additional compounding factor

The preoperative group of patients had higher than normal loading under the lateral metatarsal heads, probably as a result of a readjustment of their walking pattern over a long period of time. This could be the result of an effort to protect the affected medial side by reducing the amount of pronation that occurs in the early phase of foot contact (Hutton et al 1976) Kaplan (1955) found, in routinely dissected feet that those with

Table 4 The mean values of the contact times for the pre and postoperative hallux valgus feet

	Contact Time							
	T1	T2	T3/5	MT1	MT2	MT3/5	MF	H
Preoperative feet	35 2	26 7	43 7	79 5	86 8	91 4	56 5	57 4
Postoperative feet	7 9**	9 2**	28 5*	75 4	81 9	86 2	49 4	53 9

hallux valgus showed a thickening of the tendon of the tibialis posterior muscle which is the strongest inverter of the foot

A comparison of the contact time parameters showed that patients with hallux valgus spent a longer percentage of time on their heel, midfoot and lateral three metarsal heads in comparison to the normal subjects This could be the mechanism by which they compensate for the shorter duration of loading on all their toes. This is further evidence of an alteration in their gait pattern Postoperatively the contact time of the toes was further reduced while none of the other areas showed a significant change This suggests that the reduction in hallux function effectively means a reduction in function for all the toes.

Preoperatively, the significant correlation between hallux loading and hallux valgus angle suggests that patients showing lower values of hallux valgus angle carry higher loads under the hallux. Therefore Keller's operation, which tends to de-function the first metatarsophalangeal joint and the hallux, has a highly detrimental effect on these patients Furthermore, Keller's operation results in a corresponding increase in load on the first metatarsal head What is the effect of this?

First let us consider normal feet during walking In the early phase of foot contact, when the heel and forefoot are simultaneously load bearing, the longitudinal arch of the foot is supported in part by the bones being in mutual compression, like a masonry arch, and in part by the plantar ligaments and the long flexor muscles. In the latter phase of foot contact, when the heel and midfoot are no longer load bearing, the plantar aponeurosis braces the longitudinal arch through the windlass mechanism (Hicks 1954) This effect is more pronounced on the medial side of the foot since the radius around the first metatarsophalangeal joint is greater At this phase of foot contact the loads acting across the metatarsophalangeal joints and on the metatarsals reach a maximum (Stokes et al 1979) Assisting the supporting action of the plantar aponeurosis on the longitudinal arch is the load carrying ability of the toes since this ligament attaches onto the proximal phalanges.

In hallux valgus, and even more so after Keller's operation, the two medial toes carry less load and thus the bracing of the longitudinal arch by the plantar aponeurosis is reduced This has the effect of increasing the stress on the plantar ligaments at the base of the metatarsals. Furthermore, any increase in load taken by the metatarsal heads, as occurs after Keller's operation, aggravates this situation

CONCLUSION

Patients with hallux valgus show reduced loading under all their toes and increased loading under their lateral metatarsal heads. After Keller's operation there is a further decrease in loading under the hallux and an increase under the first metatarsal head The results also suggest that the hallux valgus angle could be used to assess the load bearing ability of the great toe

ACKNOWLEDGEMENTS

This work is supported by a grant from the Medical Research Council

REFERENCES

Davies-Colley, N (1887) On contractures of the metatarsophalangeal joint of the great toe (hallux flexus). *Brit med J* **7**, 728

Dhanendran M Hutton W C. & Paker Y (1978) The distribution of force under the human foot an on line measuring system. *Measurement and Control* **11**, 261–264

Du Vries, H L. (1973) Static deformation of the fore-foot *Surgery of the foot* (Ed. Inman V T) pp 379–467 C. V Mosby Co., St Louis.

Edgar M A (1976) Hallux valgus and associated conditions. *The foot and its disorders* (Ed Klenerman, L) pp 83–130 Blackwell Scientific Publications, London.

Hardy R H & Clapham, J C. R. (1951) Observations on hallux valgus. *J Bone Jt Surg* 33 B 376–391

Hicks, J H (1954) The mechanics of the foot. II The plantar aponeurosis and the arch *J Anat (Lond)* **88**, 25–30

Hutton, W C. & Dhanendran, M (1979) A comprehensive study of the distribution of load under the normal foot during walking *Int Orthop* (SICOT) 3, 153–157

Hutton W C., Stott, J R. R & Stokes, I A F (1976) The mechanics of the foot *The foot and its disorders* (Ed Klenerman, L) pp 30–48 Blackwell Scientific Publications, London.

Kaplan, E B (1955) The tibialis posterior muscle in relation to hallux valgus. *Bull. Hosp Jt Dis (N Y)* 16, 88–93

Kelikian H (1965) *Hallux valgus allied deformities of the forefoot and metatarsalgia* pp 54–95 W B Saunders Company Philadelphia

Keller, W L. (1904) The surgical treatment of bunions and hallux valgus. *N Y med. J* 741–742.

Stokes, I A F, Hutton, W C. & Stott, J R R (1979) Forces acting on the metatarsals during normal walking *J Anat. (Lond)* 129, 579–590

Correspondence to W C Hutton Principal Lecturer, Polytechnic of Central London, 115 New Cavendish Street, London W1M 8JS

POSTGRADUATE SEMINAR ON BONE PATHOLOGY AND CLINICAL MANAGEMENT

A postgraduate seminar on *Bone Pathology and Clinical Management* will be held in Nijmegen, The Netherlands, from June 15–19, 1981.

The lectures will be given by:

Prof Dr W. Enneking, M D, Florida, USA
Prof Dr M Campanacci, M D, Bologna, Italy
Prof Dr Th G van Rijssel, Leiden, Holland

Official Language	: English
Participants	: Limited to 70
Place	: Catholic University of Nijmegen, The Netherlands
For information contact	: Office of Post-Academic Education Mrs. I Sjakshie Geert Grooteplein Noord 31a Postbus 9101 6500 HB Nijmegen, The Netherlands. Tel 080-51 70 50

THIRD WORLD CONGRESS ON PAIN

(Sponsored by the International Association for the Study of Pain)

September 4–11, 1981, Edinburgh, Scotland

For information

Third World Congress on Pain
University of Edinburgh
Centre for Industrial Consultancy and Liaison
16 George Square
Edinburgh EH8 9LD, Scotland, U K

or

Louisa E Jones, BS, Executive Secretary
International Association for the Study of Pain
Dept. of Anesthesiology RN-10
University of Washington
Seattle, WA 98195 USA

3rd EUROPEAN REGIONAL CONFERENCE OF REHABILITATION INTERNATIONAL

"The Handicapped Person in Society"

April 6–10, 1981, Vienna

Information

Interconvention
P O Box 104, A-1014 Vienna
Tel (0222) 57 63 05

THIRD MEETING OF THE EUROPEAN SOCIETY OF BIOMECHANICS

January 21–23, 1982, University of Nijmegen, The Netherlands

Papers are solicited on the application of methods and theories of Mechanics to Medical and Biological problems, in all fields, e g

* Orthopaedic Biomechanics
* Cardiovascular and Respiratory Biomechanics
* Dental Biomechanics
* Rehabilitation Biomechanics
* Sports Biomechanics
* Biomechanics of Hard and Soft Tissues
* Dynamics of the Musculoskeletal System
* Mechanical Properties of Biomaterials
* Methodology in Biomechanics Research
* General Subjects

For information, author's instruction and abstract forms, contact

Rik Huiskes, Conference Chairman
Ton de Lange, Conference Secretary
c/o Miss Cora Rooker
Dept of Orthopaedics
6500 HB Nijmegen The Netherlands
Tel (080)-513918

THE SECOND CONGRESS OF THE INTERNATIONAL SOCIETY OF THE KNEE

will be held in New Orleans Louisiana, USA April 6–11, 1981

Program

* Treatment of arthritis other than prosthesis
* The posterior cruciate ligament
* Osteochondritis dissecans
* Free communications

European Program Chairman H Dejour Pavillon I, H E-Herriot 69374 Lyon Cédex 2, France

Secretary IId Congress of th International Society of the Knee 6262 Hamilton Road, Columbus, Georgia 31995, USA

ERRATUM

In Vol 51, pp 429–437 "*Mechanical Property Distributions in the Cancellous Bone of the Human Proximal Femur*" the MN/m^2 modulus and yield strength values were erroneously inflated by a factor of ten

SUBJECT INDEX

FEMORAL HEAD

FEMORAL HEAD NECROSIS

FEMORAL NECK FRACTURES

HALLUX

HAND

HIP

[illegible]

HIP JOINT

HISTIOCYTOSIS X

HOSPITALIZATION

HUMERAL FRACTURES

HUMERUS

HYPERSENSITIVITY

IMMOBILIZATION

INDOMETHACIN

PULMONARY EMBOLISM

RADIOGRAPHY

RADIONUCLIDE IMAGING

REGIONAL BLOOD FLOW

REHABILITATION

SARCOMA

SCIATICA

SCLERODERMA, SYSTEMIC

SCOLIOSIS

SEMILUNAR CARTILAGE

SHOULDER DISLOCATION

AUTHOR INDEX

Acta

Scandinavica

ITOR: KNUD JANSEN, Copenhagen, Denmark

ACTA ORTHOPAEDICA SCANDINAVICA

is the official publication of the Scandinavian Orthopaedic Association

Acta Orthopaedica Scandinavica publishes original papers on orthopaedic surgery including traumatology Authors are also invited to publish follow-up notes and comments. Papers previously published in other periodicals are not accepted

Editorial Correspondence Manuscripts should be addressed to the Editor No part of this journal may be reproduced by any process without written permission from the author(s) and the editor

Business communications including subscriptions and orders for offprints or advertisements, should be sent to the publishers *Munksgaard*, International Booksellers and Publishers Ltd., 35 Nørre Søgade DK-1370 Copenhagen K, Denmark

Acta Orthopaedica Scandinavica is published bimonthly The subscription price per volume of six issues is at present Danish kroner 300 00 plus postage D kr 60 00 (US $68 40, £32.40, DM118 60) payable in advance Prices are subject to exchange rate fluctuation.

INSTRUCTIONS TO CONTRIBUTORS

expected that any manuscript submitted represents published original work that is not being considered for publication elsewhere.

The paper should be written in English The title which is not to exceed 12 words, should be chosen with great care Most of the indexing and abstracting services depend on the accuracy of titles. The manuscript must be typewritten on one side of the paper only (quarto), with wide margins and be double spaced The first page should contain, on separate lines, the title of the article and the authors names and institutions. If the title is longer than 45 letters and

postal address of the author to whom communications and proofs are to be sent and from whom reprints are to be requested

The manuscript including tables and figures should if possible, be sent in duplicate to facilitate rapid referee-

... for his ... text. ... must ... n by

"per cent" The minus sign should be shown as ... are by ... poor ... sizes. ... at a ... more

rate of 400 Danish kroner per page ... than 20 pages are not accepted.

Papers should normally be divided into the following sections

Abstract The purposes of the abstract are to convenience the readers of the journal and to expedite the work of the abstracting journals. The opening sentence

(Cont. cover page 3)

Second-class postage paid at Jamaica, N Y Airfreight and mailing in the U S by Publications Expediting Inc. Elmont, N Y 11003 Printed in Great Britain by The Whitefriars Press Ltd London and Tonbridge